


The Great Tooth Killer: Epidemic of Cracked Teeth, the Science of Strong Teeth

drclark
@bioclearmatrix.com

For a copy of today's presentation,
Learning Center info or the essential
Learning Center Library



A serene sunset scene over a calm lake. The sky is filled with vibrant orange and yellow clouds, with the sun low on the horizon. A dark silhouette of a forest line is visible in the middle ground, and its reflection is clearly visible in the still water of the lake. The overall mood is peaceful and natural.

Disclosures:
Dr. Clark has financial interest in Bioclear



DC BIOCLEAR LEARNING CENTER

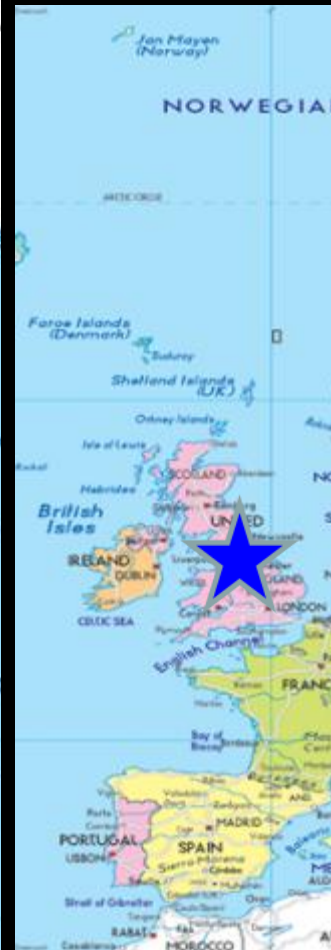
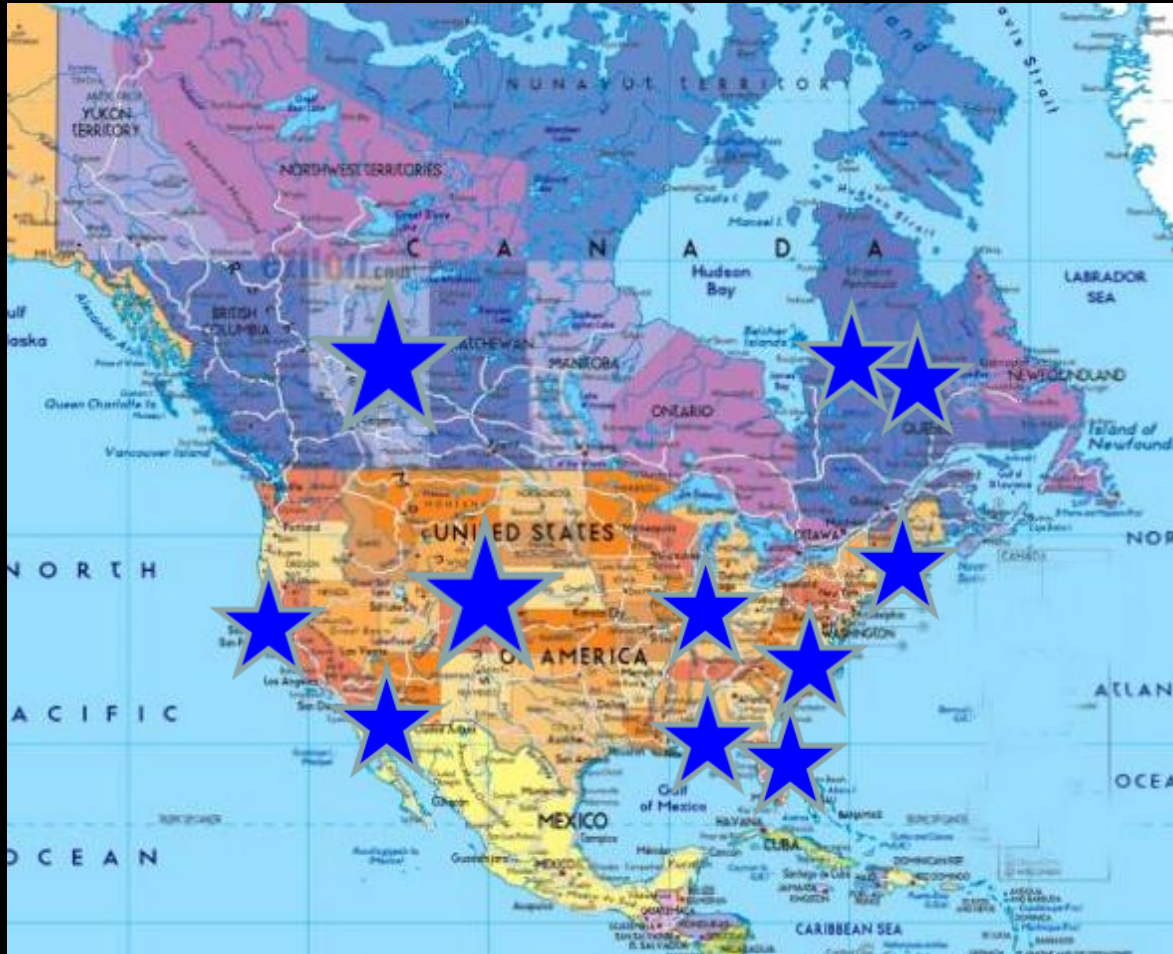
Tacoma USA · Solihull UK
Varberg Sweden · Cairo Egypt
Syracuse Italy · Taubate Brazil
Livermore CA (Bioclear pediatrics)
Seoul Korea · Madrid/Barcelona
Sydney Australia · Baghdad Iraq



The **Bioclear Learning Center** provides a new pathway for dentists and their office to transition from traditional **GV Black dentistry**, to the extraordinary world of **modern direct dentistry**.



Dental schools/GPR integrating the Bioclear Method



English pg. 21 Issues pg. 130 Microissues pg. 100

DENTISTRY TODAY
October 2004

BETTER RESULTS THROUGH MAGNIFICATION

Let's meet the Best Dentists in the World pg. 34

How Common is Dental Fear? pg. 52

Continuing Growth in Transplant Dentistry pg. 61



The Epidemic of Cracked and Fracturing Teeth



David Clark, DMD

Teeth are fracturing faster in dental numbers. Cracked and fractured teeth are now the third leading cause of tooth loss in industrialized nations.¹ Fractured teeth with conservative analgesic and antibiotic use, sealing, and being crown, cracked teeth, both posterior and anterior, are fracturing off at three levels. Fractured teeth treated with veneers, inlaying off, and bridge (Figures 1). Additionally, endodontics are reporting that cracked teeth are now replacing crown teeth for restorative strategy in a number of patients referred for endodontic treatment.

We assume that the reason of this period and growing problem are not so lacking longer. In our stress levels are rising, and chewing and bruxism are also more general, it is the subject of the full-speed loadings, repeated billions of hermetic (V.V. Heli) every preparation that have work and powder teeth (Figure 2) and the deep color correction preparation in the case of powder condition, and yet aggressive "cross-link" endodontic change is definite, new metal resin.

Dentistry has great capacity (evolution) is a poorly understood process. A dramatic change in the form of combining dental education, financial, scientific, marketing, and legislative has shifted our attention away from some of the most integral aspects of the building and developing dental care that has. We now find our profession faced with a tremendous problem that will require a significant reevaluation and reevaluation of

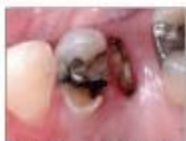

Figure 2. In an anterior right, and fractured with a horizontal crack (top preparation) and has been placed the back to the back, and the other cracked has been of an anterior having immediate therapy.

measures to address appropriately. There is no need to assess. Many, to start simply will require diagnosis and part to work.

BRINGING DIAGNOSIS AND PREVENTION OUT OF THE SHADOWS
Microscopic and operator-driven diagnosis have been the accepted modalities for the diagnosis of cracked teeth. The following list

of signs of the lack of visual confirmation create therapies that education can be able to the treatment process. One looking first impression of cracks through the clinical microscope is the staggering array of cracks that exist within tooth structures (Figure 3). Traditional visual examination (or longer) limits the clinician's ability to assess the pro-

Table 1. How Can We Eliminate Teeth Fracturing?

Phase 1:	Phase 2:	Phase 3:	Phase 4:	Phase 5:
Diagnose the crack or deepness (to front and deep gaps) shown in the preparation (7 to 10 years) crown.	Recognize if or not really preparation or preparation tooth from actual better surface needs and indicate the restorative.	Recognize the crack and avoid crown and avoid crown inlaying based on any factor and condition.	Repair teeth to achieve appropriate built-up material, seal, aesthetic with new resin or based preparation of all fractured part.	Re-control the preparation by understanding, controlling, and protecting the situation.

Table 2. Quick Reference Guide for Microscopic Cracks in Posterior Teeth.

1. Most teeth in aging adults display enamel cracks.
 2. Cracked teeth, even traumatic cracks, do not necessarily indicate that the tooth is cracked.
 3. Only enamel cracks do not penetrate significantly (70-80%).
 4. Only enamel cracks that display features, many with oral multiple cracks.
 5. Three types of crack propagation will produce enamel cracks:
 - Enamel cracks, decay, and subclinical enamel (not contributing to microleakage enamel's restorative).
 - Enamel cracks should be considered as structural cracks.
 - Enamel cracks that penetrate into dentin, generally positioned in the middle of the pulpal floor, are "structural" and do cause generally confirmed at low magnification (operator) (Figure 4).
 - Only teeth with both types of enamel cracks (enamel cracks) are also structural. (Figure 5) restorative will be not improve their early recognition and treatment. All teeth with enamel cracks should be considered as structurally unsound.
- Reevaluation/Prevention Plan:**
1. Microscopic cracks in restorative materials can indicate a lack of correct structural integrity.
 2. Evaluation of distribution of a crack in enamel or cracks a lack of structural integrity.
 3. If usual or a better (padding between) or a better restorative and both structure can indicate a lack of structural integrity.

2004 • Volume 16 • Number 5

JOURNAL OF ESTHETIC AND RESTORATIVE DENTISTRY

Official Publications of the American Academy of Esthetic Dentistry,
Japan Academy of Esthetic Dentistry, International Federation of Esthetic Dentistry,
American Academy of Cosmetic and Adhesive Dentistry,
Belgian Academy of Esthetic Dentistry, Dutch Academy of Esthetic Dentistry,
and the Scandinavian Academy of Esthetic Dentistry

www.bndecker.com

Prognostic Diagnosis of Early Enamel and Dentine Cracks Based on Microscopic Evaluation

DAVID J. CLARK, DMD
CURELITH G. SHEETS, DDS
JACINTHE M. BAQUETTE, DDM

OBJECTIVE: Cracks and fractures of cracked teeth and incomplete coronal fracture have historically been symptoms of the dental operating microscope at x16 magnification can fundamentally change a clinician's ability to diagnose such conditions.

We have been observing cracks under extreme magnification for nearly a decade. Patients come clear that can lead to appropriate treatment prior to symptoms or deterioration to fracture occur. Conversely, many cracks are not structural and can lead to misdiagnosis treatment. Methodically microscopic examination, an understanding of crack progression, appreciation of the types of cracks will guide a doctor to making appropriate decisions.

Teeth can have structural cracks in various stages. To date, diagnosis and treatment are very often at an end stage of crack development.

CLINICAL SIGNIFICANCE

This article gives new guidelines for recognition, visualization, classification, and treatment of cracked teeth based on the realistic use of x16 magnification. The significance of enamel cracks as they relate to dentinal cracks is detailed.

(J Esthet Restor Dent 15:XXX-XXX, 2003)

Microscopic and symptom-driven diagnoses have been the accepted modalities for cracked teeth. The inherent limitations of the lack of visual confirmation mask it therapies that often come too late in the treatment process. One lacking first impression of vision through a clinical microscope is the staggering array of cracks that exist within tooth structures. Traditional visualization is limited

or ocular (visual) limits the clinician's ability to assess the presence or severity of the majority of these cracks (Figure 1).

At extreme magnification levels (x14 and greater), the translucent nature of enamel yields a wealth of information. Subtle color changes within the enamel may indicate early decay, microleakage, and a lack of structural integrity of dentin and

enamel. Being able to see previously invisible cracks can lead restorative dentists to more appropriate early treatment of compromised teeth before devastating fractures, pulpal involvement, and periodontal breakdown occur. The value of early diagnosis of the structural breakdown of teeth will become even more significant with our aging population coupled with increased tooth retention in this population.

¹President, Academy of Microscopic Esthetic Dentistry.
²Consultant, Director, Non-past Great Oral Facial Institute, Newport Beach, CA, clinical professor, Restorative Dentistry, USC School of Dentistry, Los Angeles, CA, USA.
³Consultant, Director, Non-past Great Oral Facial Institute Newport Beach, CA, associate professor, Restorative Dentistry, USC School of Dentistry, Los Angeles, CA, USA.

THE SCIENCE OF STRONG RESTORED TEETH



DR. DAVID CLARK



DR. ALEX FOK



Dr Alex Fok is a Mechanical Engineer with expertise in solid mechanics, structural analysis and mathematical modeling. He is currently the Academic Director of the Minnesota Dental Research Center for Biomaterials and Biomechanics (MDRCBB). The MDRCBB is an international leader in the development and application of novel characterization techniques for dental biomaterials, with long-standing collaboration with dental materials manufacturers. Dr Fok's research focuses on the development of techniques for material characterization, nondestructive examination, lifetime prediction and shape optimization of dental restorations. A principal aim of his research is to instill more engineering principles and analytical techniques into the design and assessment of dental restorations and treatments so as to improve their longevity and effectiveness.

In this case-based lecture
today we explore:

- Coronal (vertical and cuspal)
Fracturing
- Snap-Off Fracturing

A close-up clinical photograph of a tooth with a snap-off fracture. The fracture is a transverse break in the enamel and dentin, exposing the pulp chamber. The pulp chamber is filled with a dark, necrotic material, likely a cast resin core. The surrounding gingiva is pink and appears slightly inflamed. The text "Snap-Off Fracturing" is overlaid in a dark grey box with light blue text.

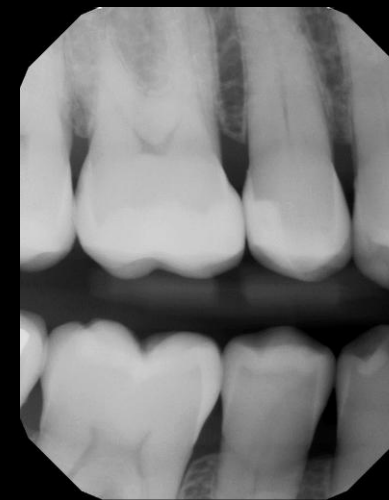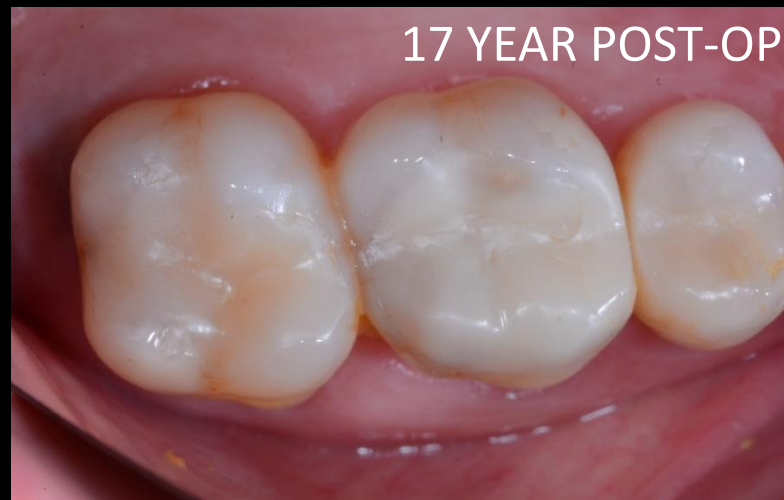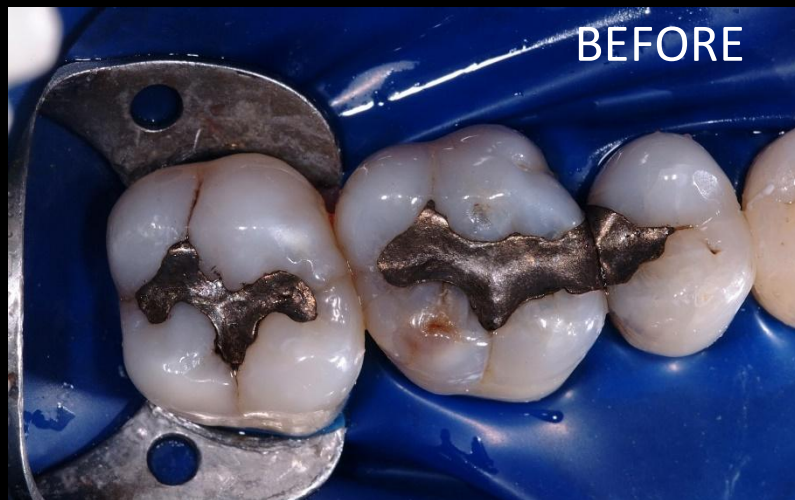Snap-Off Fracturing

Today's Summary

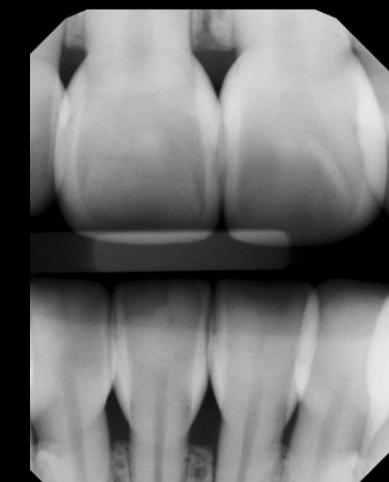
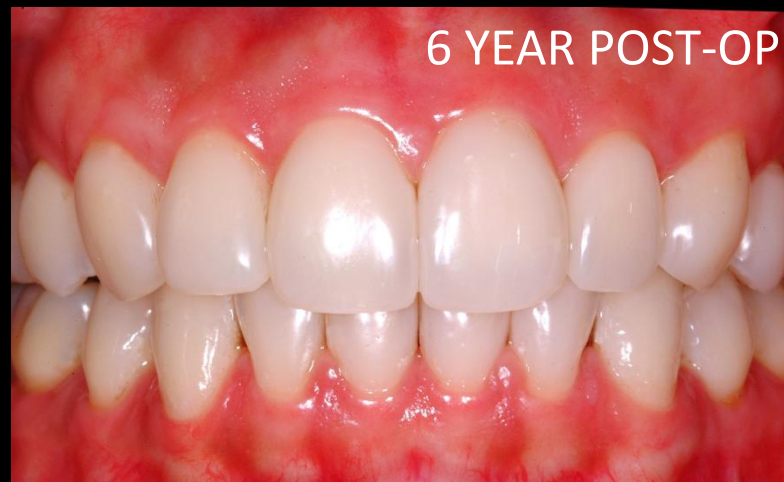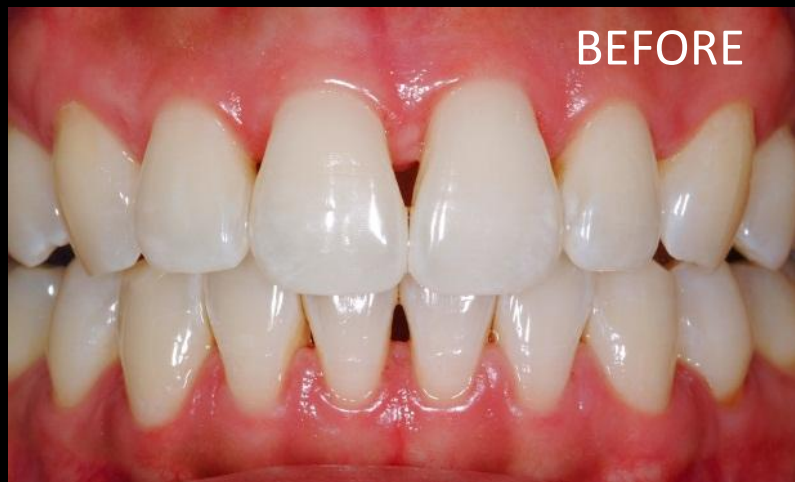- Why things break...
- Modern cavity preparations
- Injection Overmolding as a 3rd option
- FEA of loading of teeth & composite
- Long term outcomes & case studies of composite overlays for cracked teeth
- When to endo, when to extract.

Modern Approach to Composite Restorations

Posterior
Restoration



Black Triangle



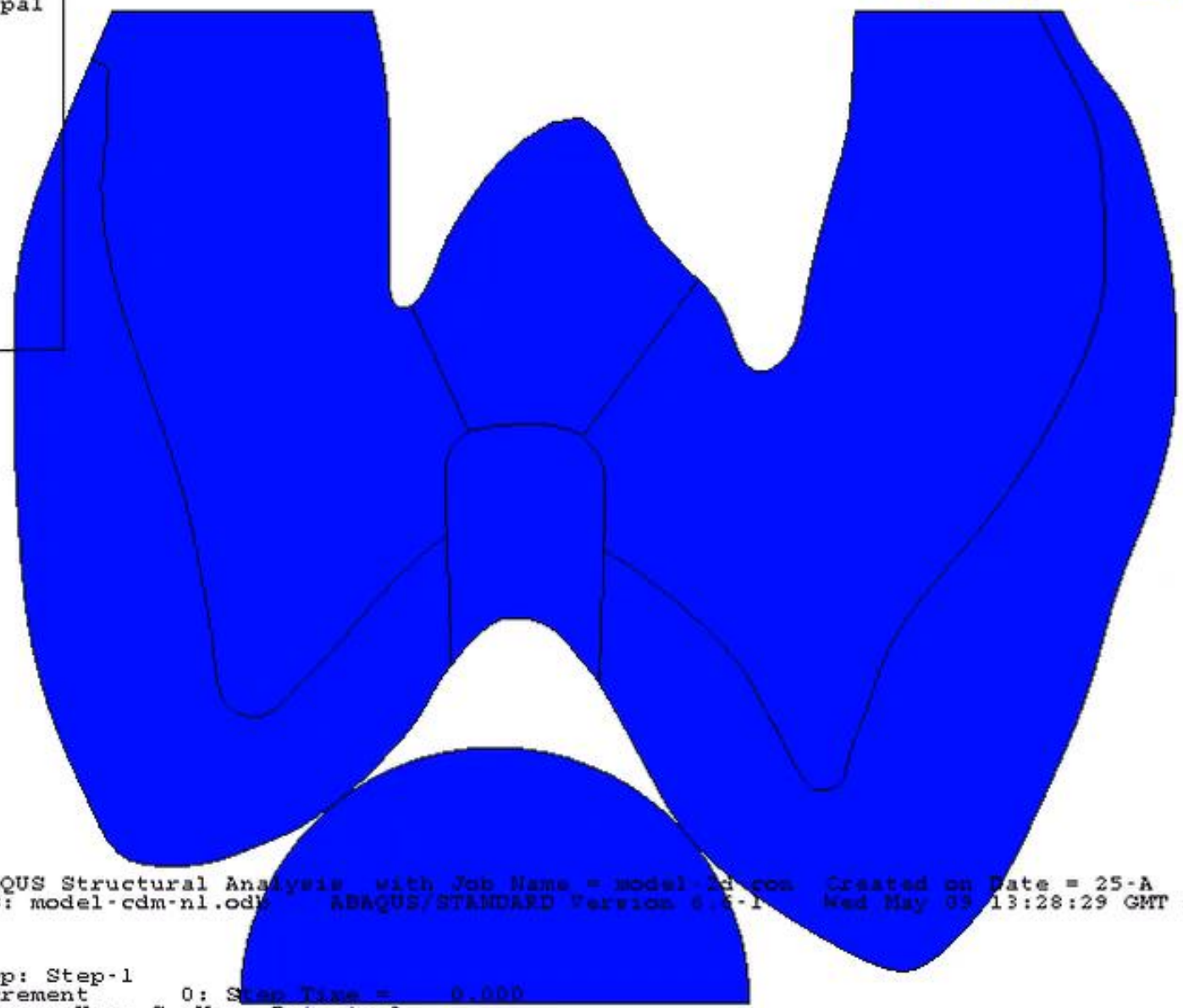
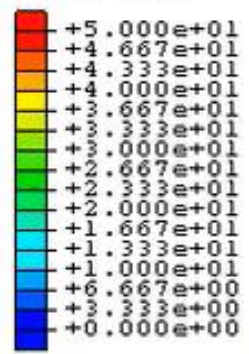
Glossary

- Bending
Mode of loading that creates curvature, resulting in tension on one side and compression on the other
- Compression
Squeezing of an element
- Hooke's law
This is obeyed when the strain of a material is proportional to the stress applied
- Shear
Force or displacement that results in an angular change in shape of an element
- Spring
Most fundamental structural element in solid mechanics
- Strain
Displacement per unit length
- Strength
Maximum stress required to cause fracture or debonding
- Stress
Force per unit area
- Stress concentrator
A structural feature that results in raised stresses within a small region
- Structural analysis or design triangle
Material, geometry and load
- Tension
Stretching of an element
- Toughness
Energy required to create unit surface area
- Shape Optimization
- Modulus
- Brittle Materials vs. Ductile and Tough Materials
- Surface Resilience
- Cyclic Fatigue

Epidemic of Cracked Teeth



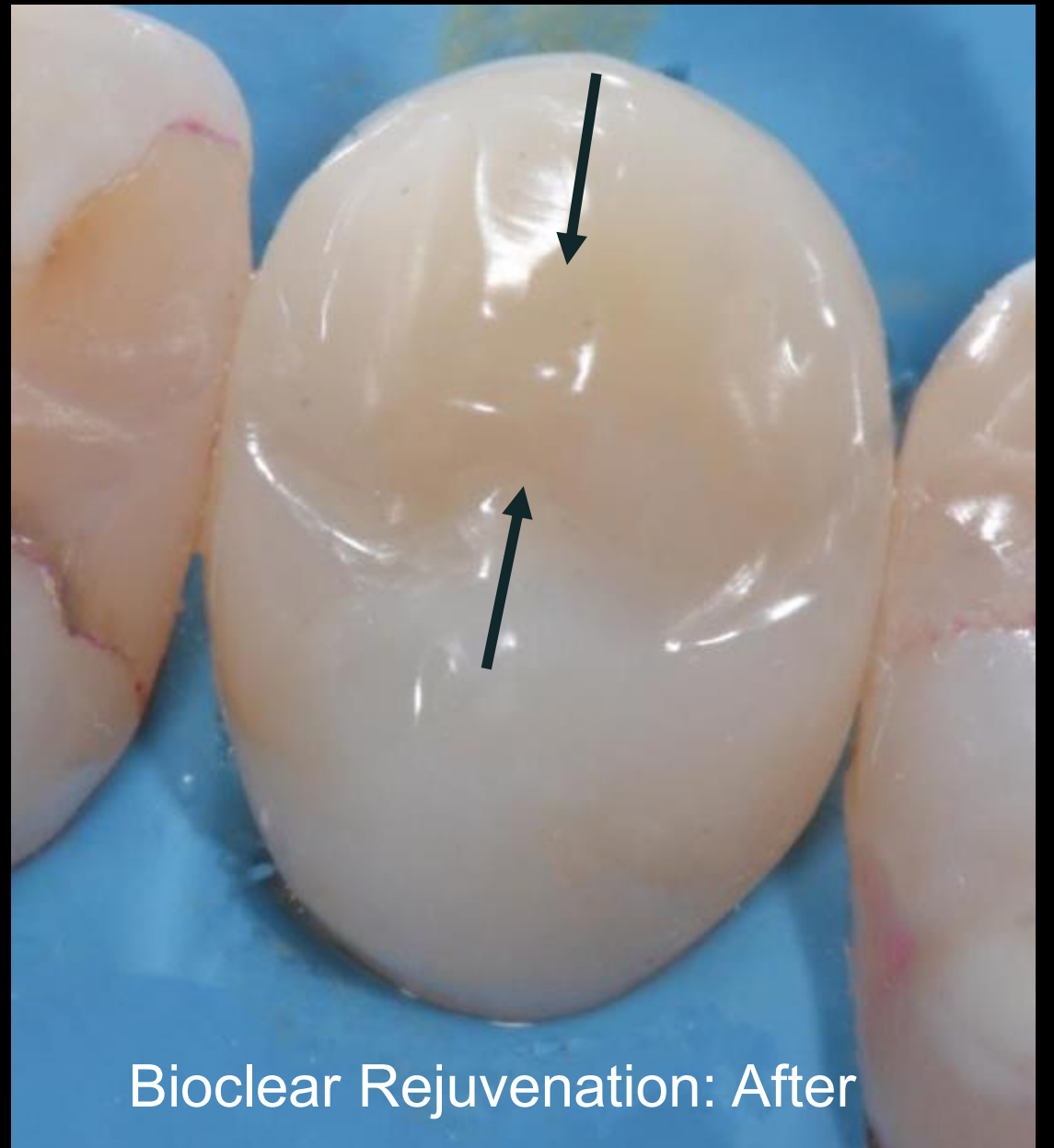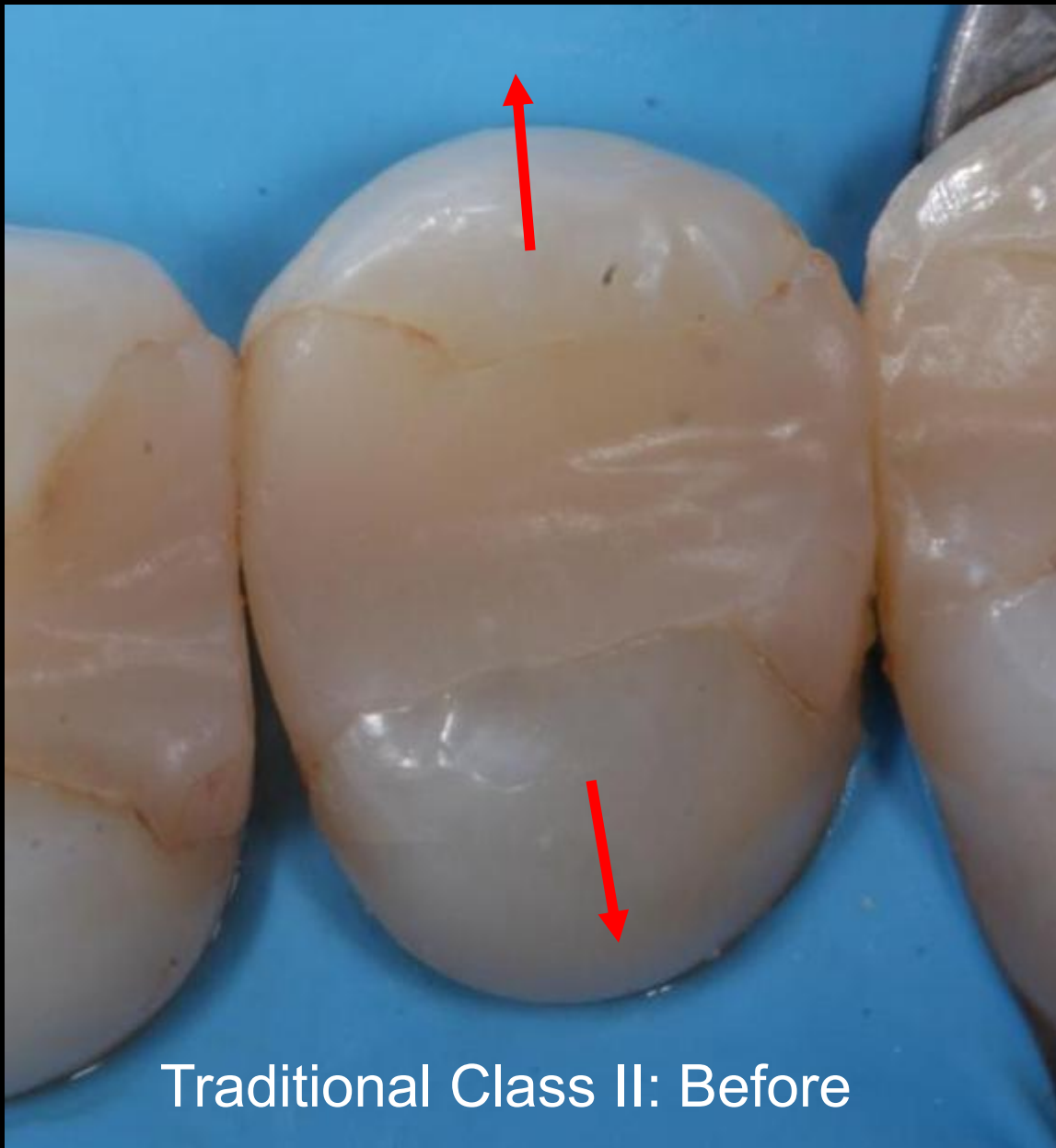S, Max. Principal
(Avg: 75%)



2
3

ABAQUS Structural Analysis with Job Name = model-cdm-nl.odb Created on Date = 25-A
ABAQUS/STANDARD Version 6.5-1 Wed May 03 13:28:29 GMT Daylight

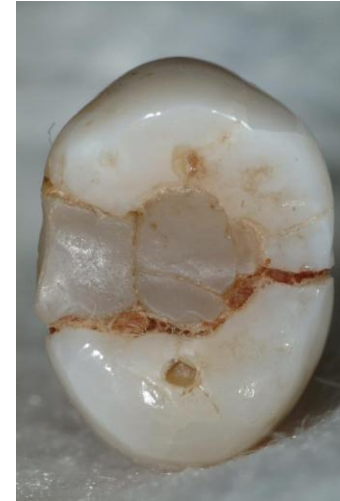Step: Step-1
Increment 0: Step Time = 0.000
Primary Var: S, Max. Principal
Deformed Var: U Deformation Scale Factor: +1.000e+01



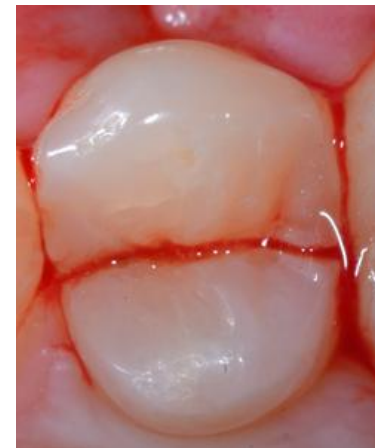Courtesy Dr. Charlie Regalado

Case Study “Joe”: Contralateral bicuspids fracture nine years apart

2012: Catastrophic fracture tooth #12. Endo
tooth w/ traditional Class II Resin Restoration

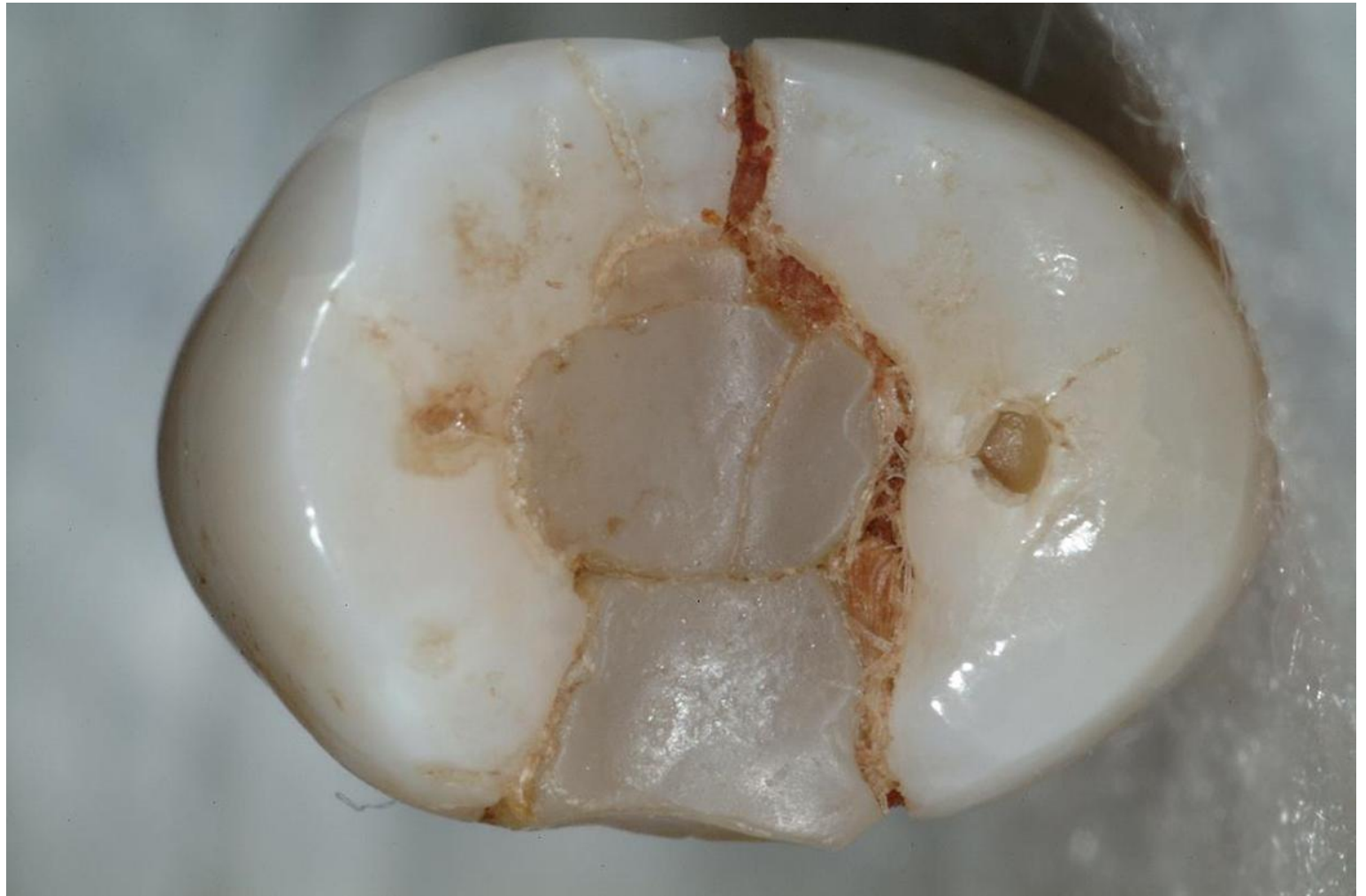


2021: Catastrophic fracture tooth #5. Virgin
Tooth

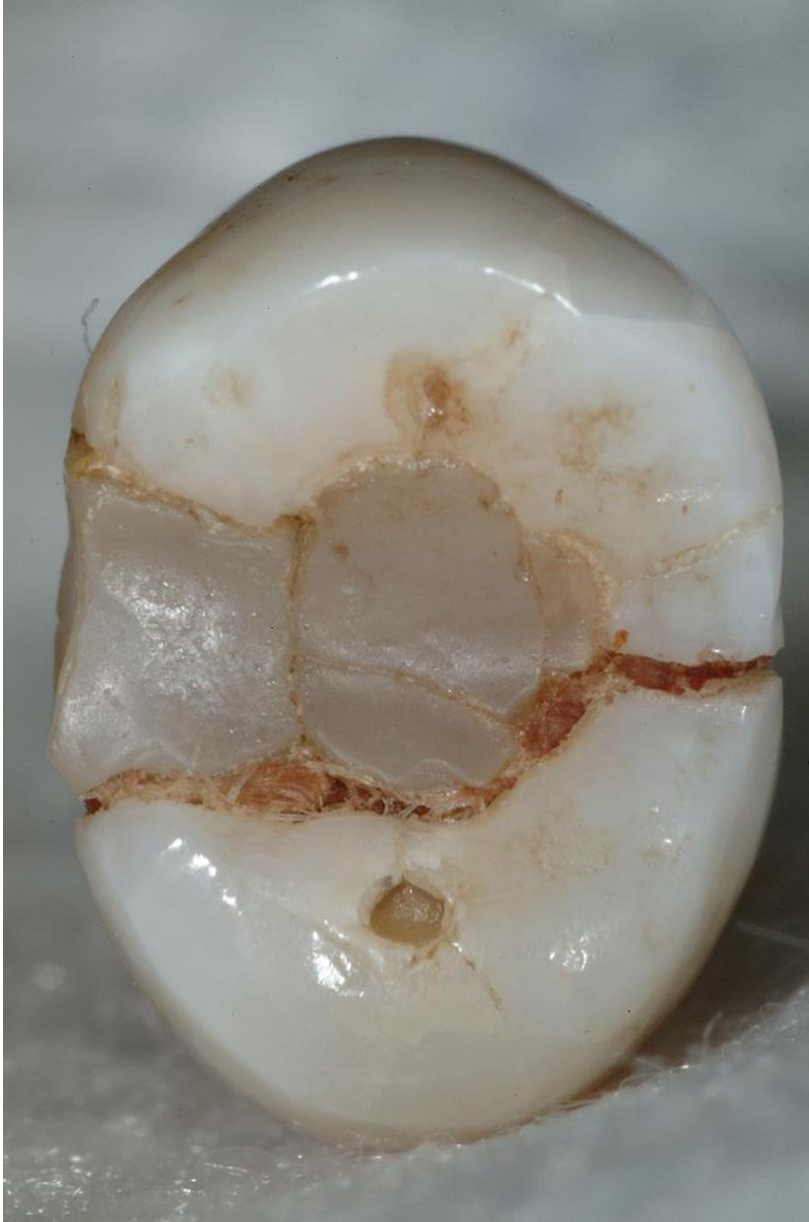

Case Study 1 “Joe”: Contrateral bicuspids fracture nine years apart

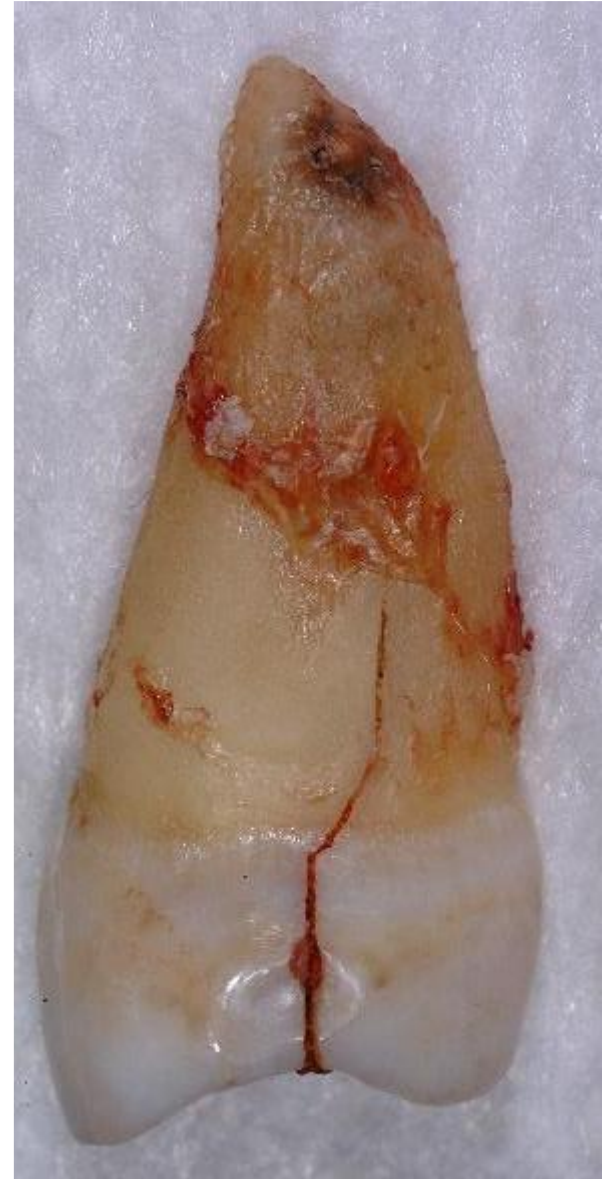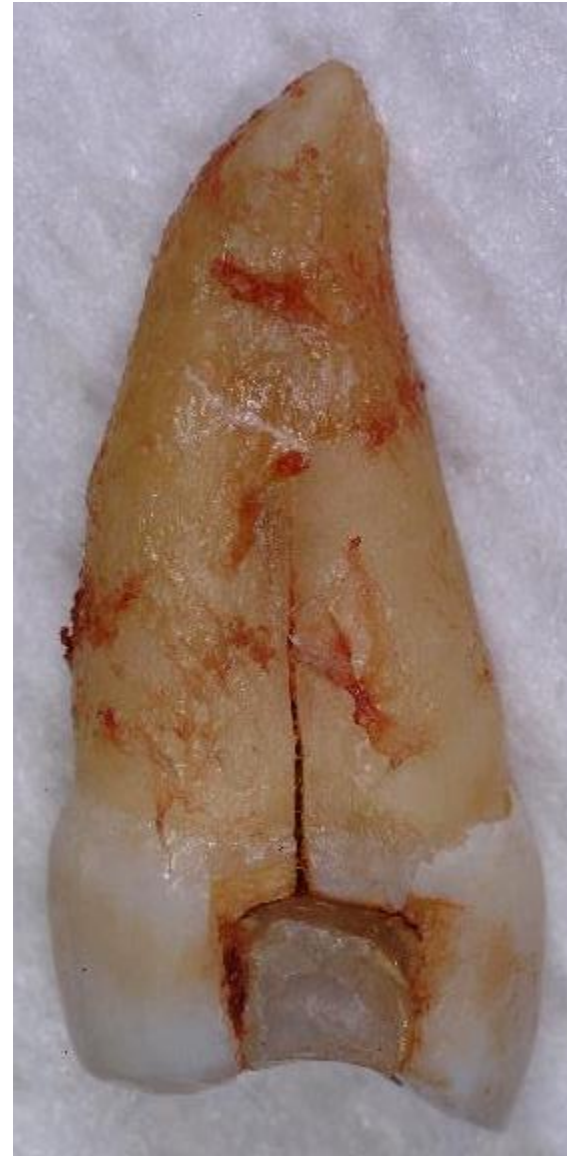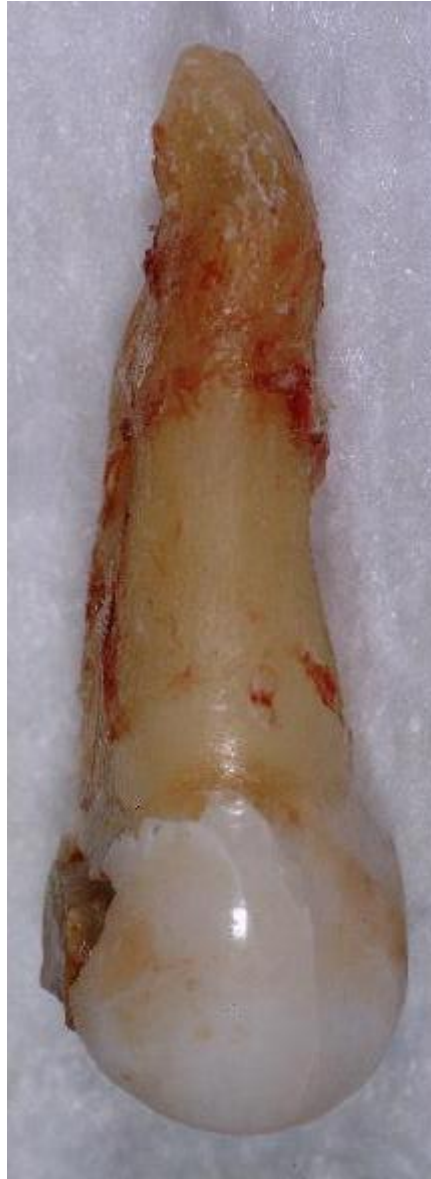2012: Catastrophic
fracture tooth #12.
Endo tooth w/
traditional Class II
Resin Restoration



Case Study Joe bilateral bicuspid fractures

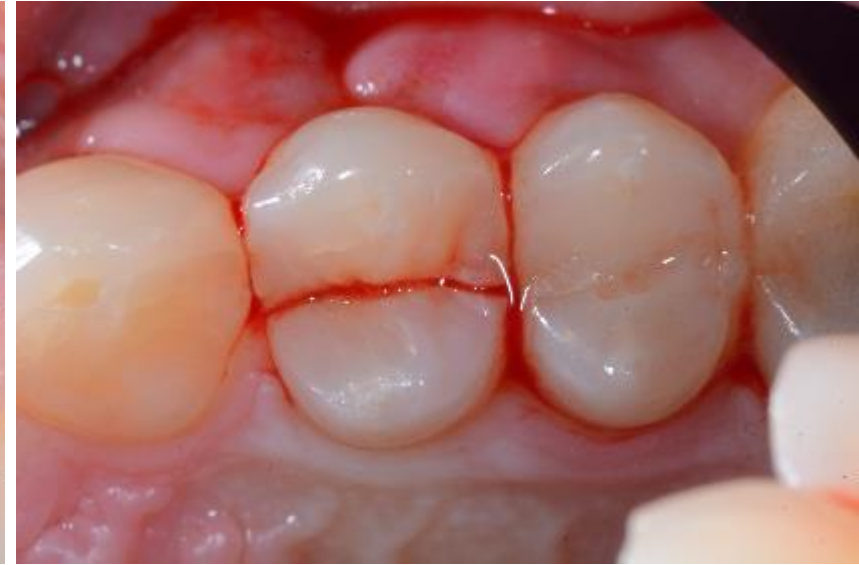
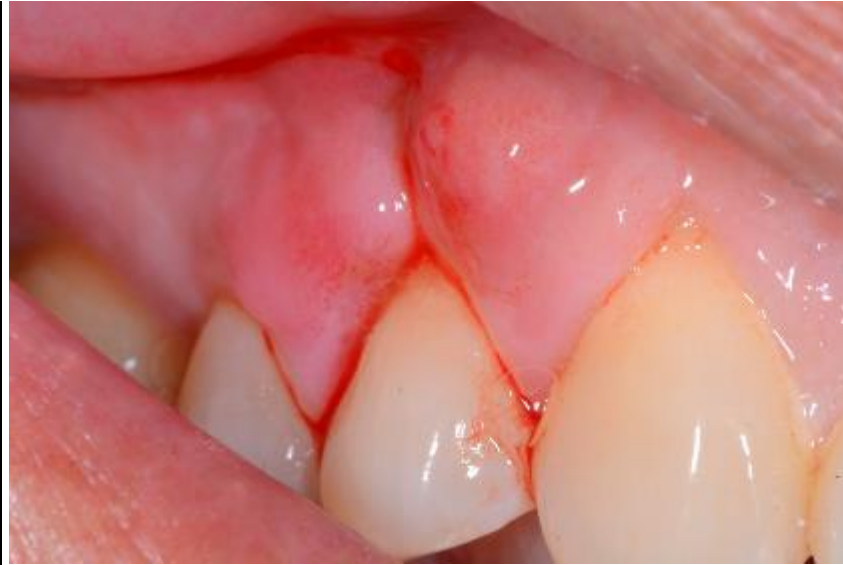
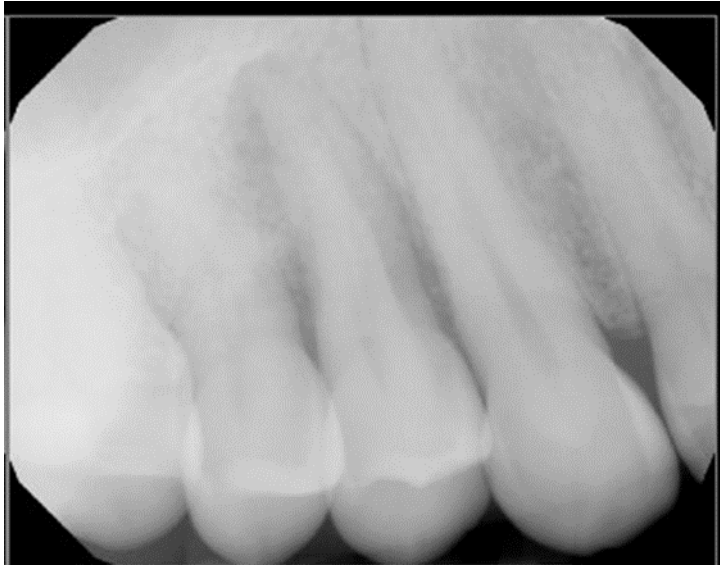2005: Catastrophic fracture tooth #12. Endo tooth w/ traditional Class II Resin Restoration



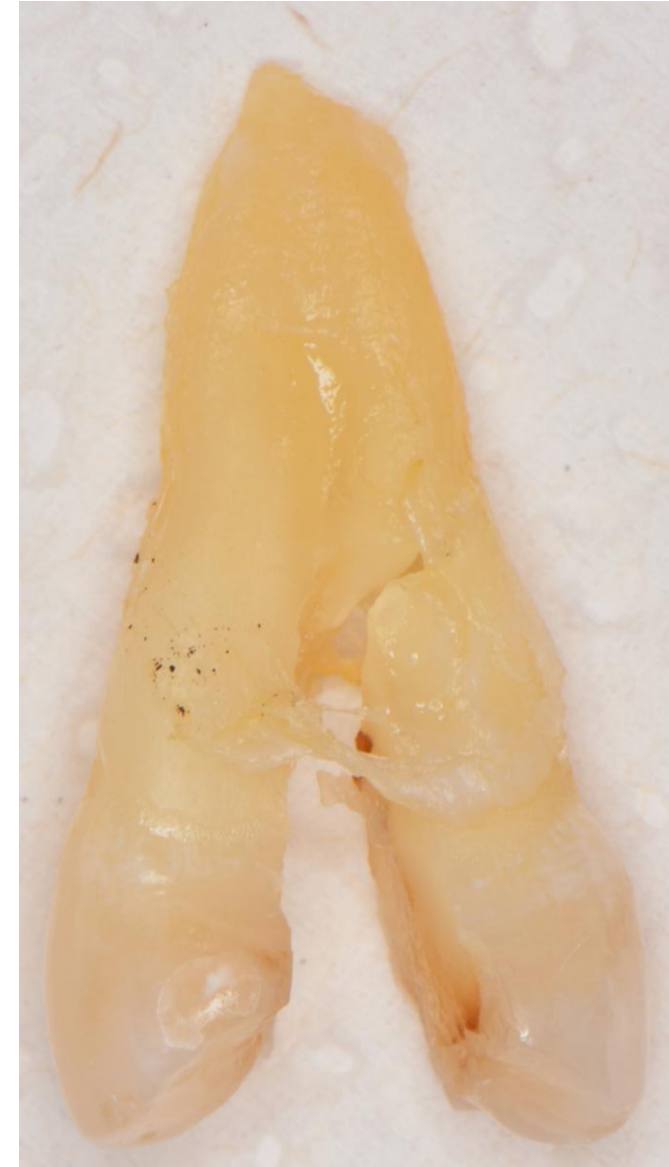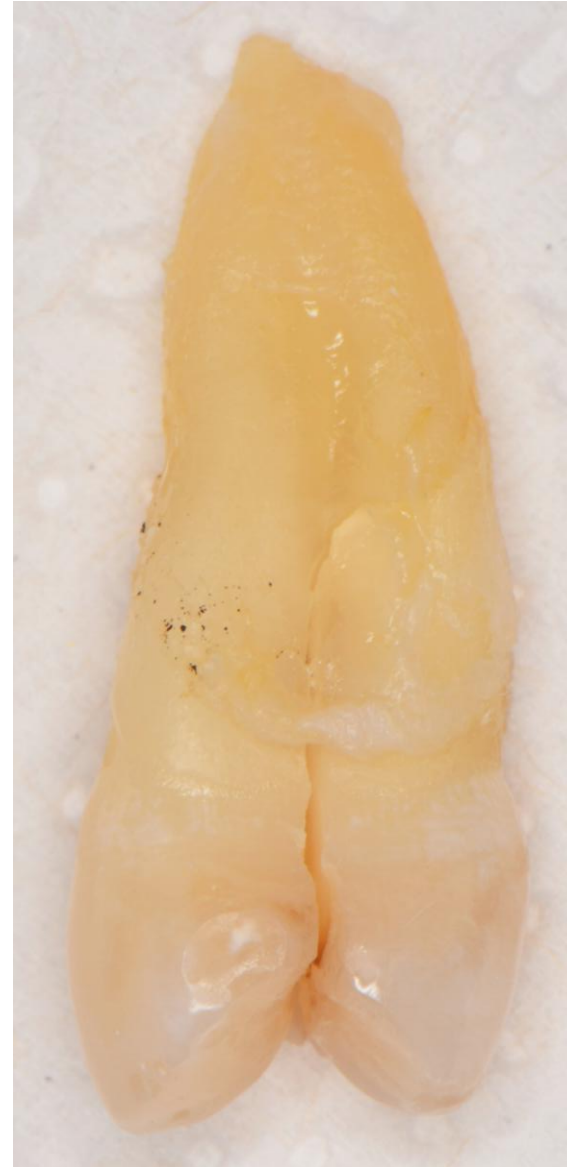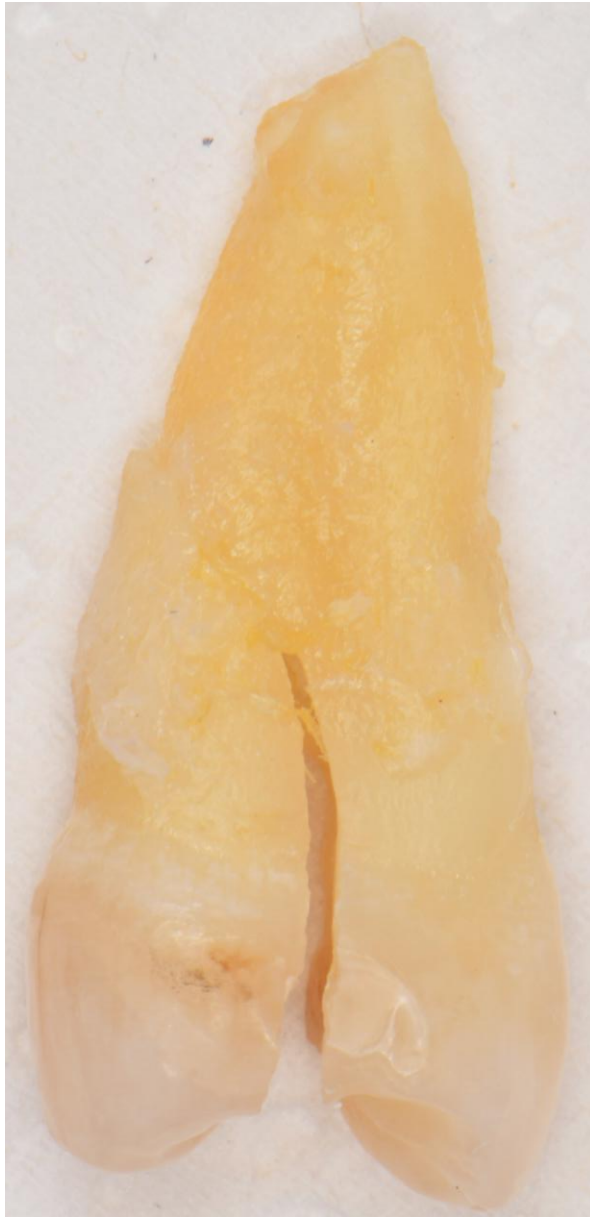Case Study Joe bilateral bicuspid fractures

2021: Catastrophic fracture of #5. Virgin Tooth



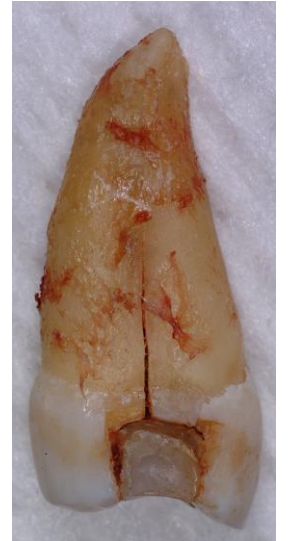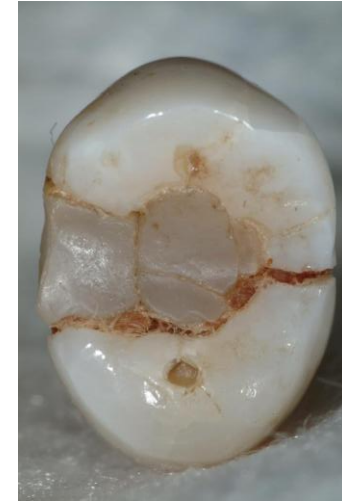Case Study Joe bilateral bicuspids fractures

2021: Catastrophic fracture #12. Virgin Tooth

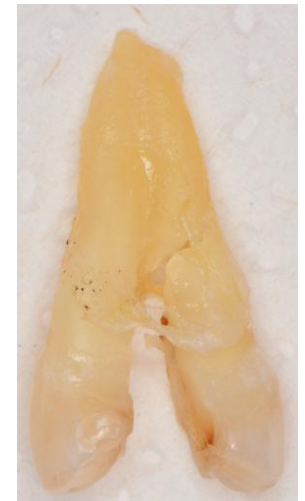
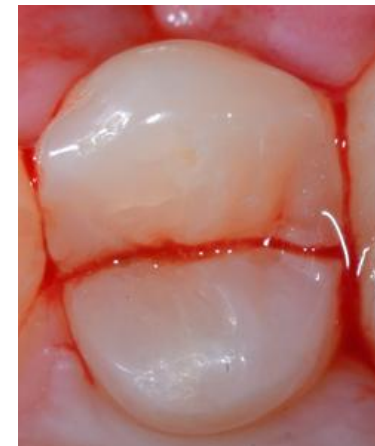
Case Study “Joe”: Discussion

2012: Catastrophic fracture tooth #12. Endo tooth w/ traditional Class II Resin Restoration



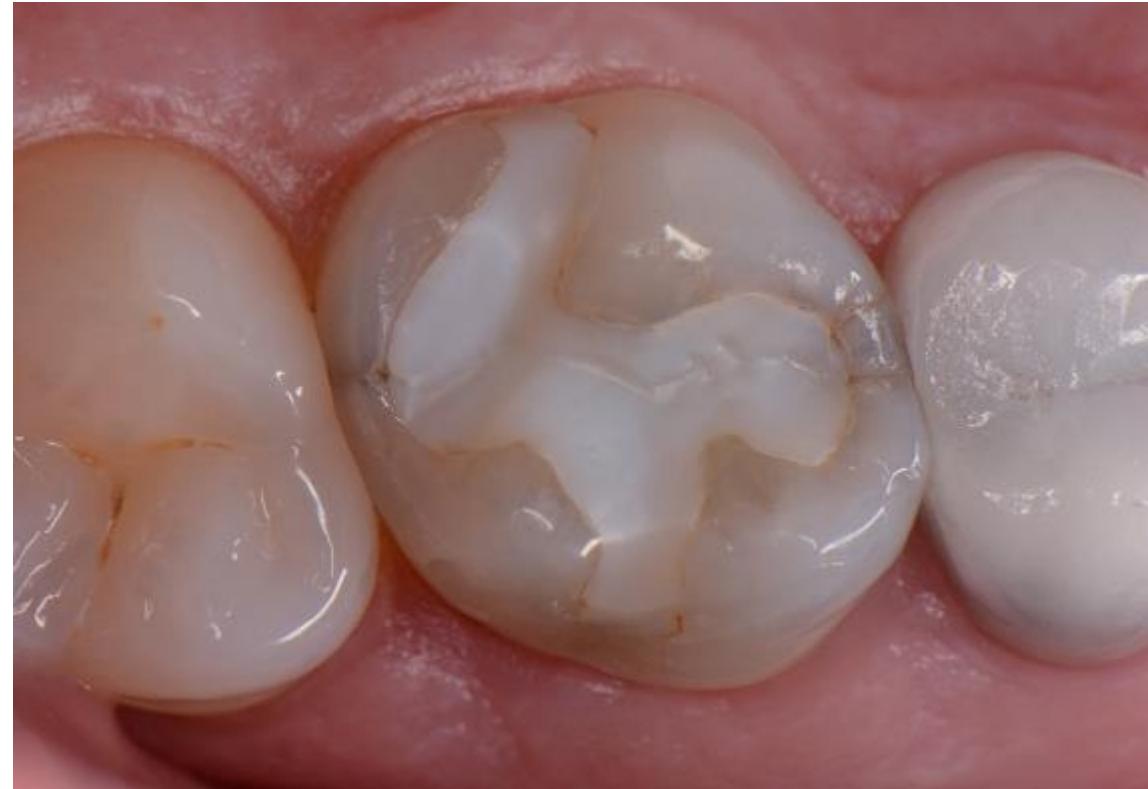2021: Catastrophic fracture tooth #4. Virgin Tooth



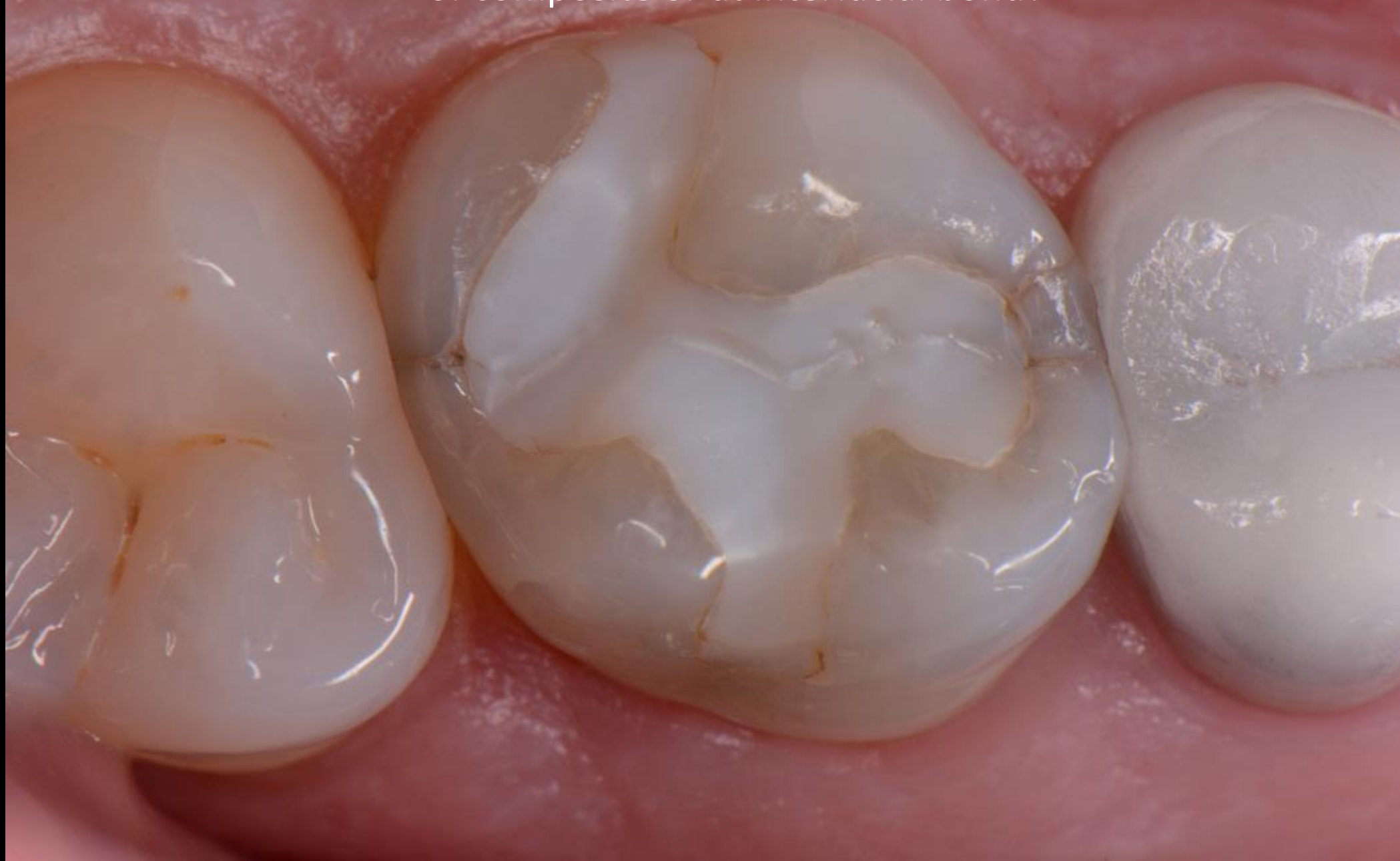Case Study “Sue”: Traditional Parallel Walled Cavity Preparation (PWCP) 10 years post operative

2021: Asymptomatic tooth at New Patient Examination

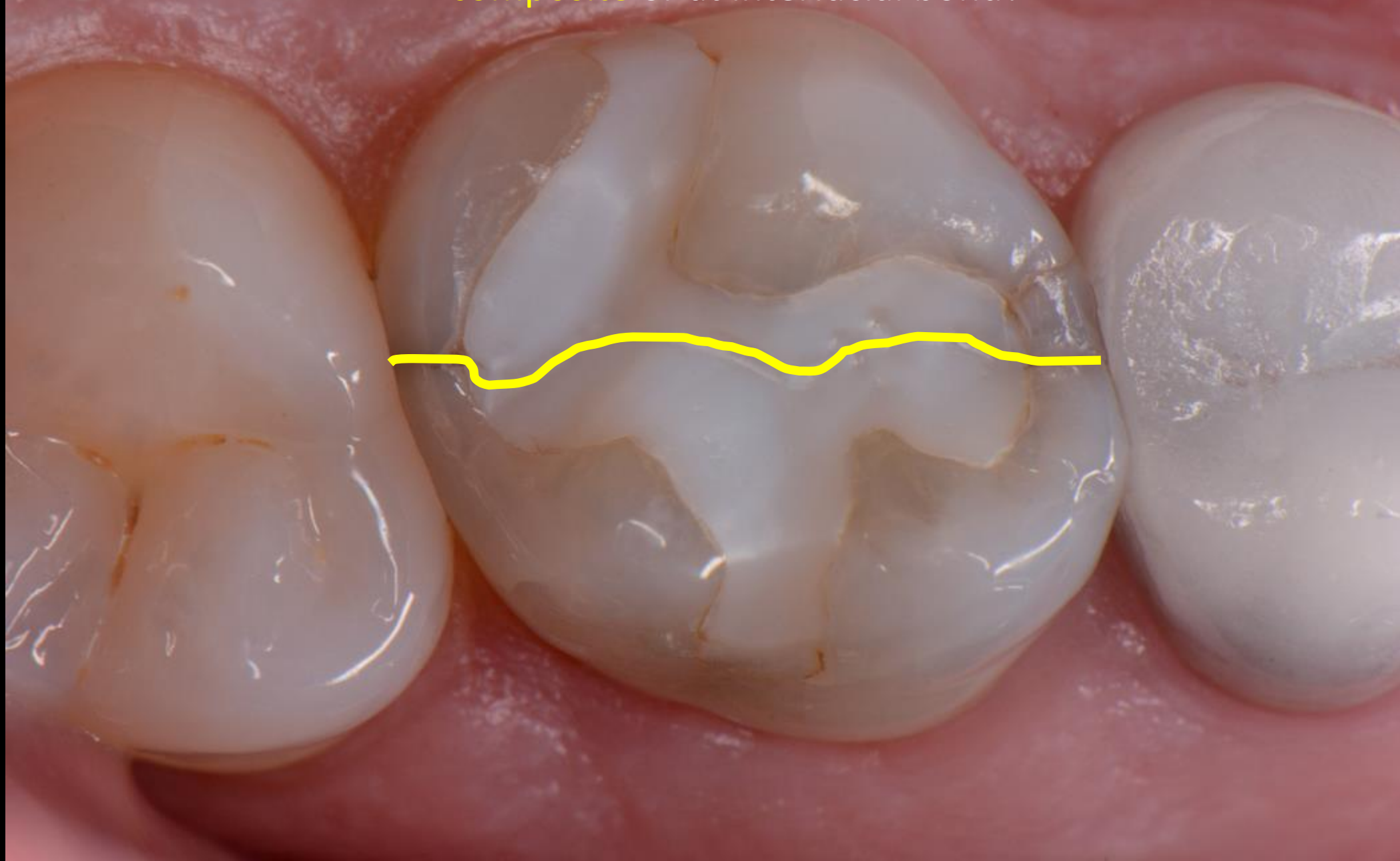
When the tooth fractures: Crack initiates at the central groove of composite or at interfacial bond.



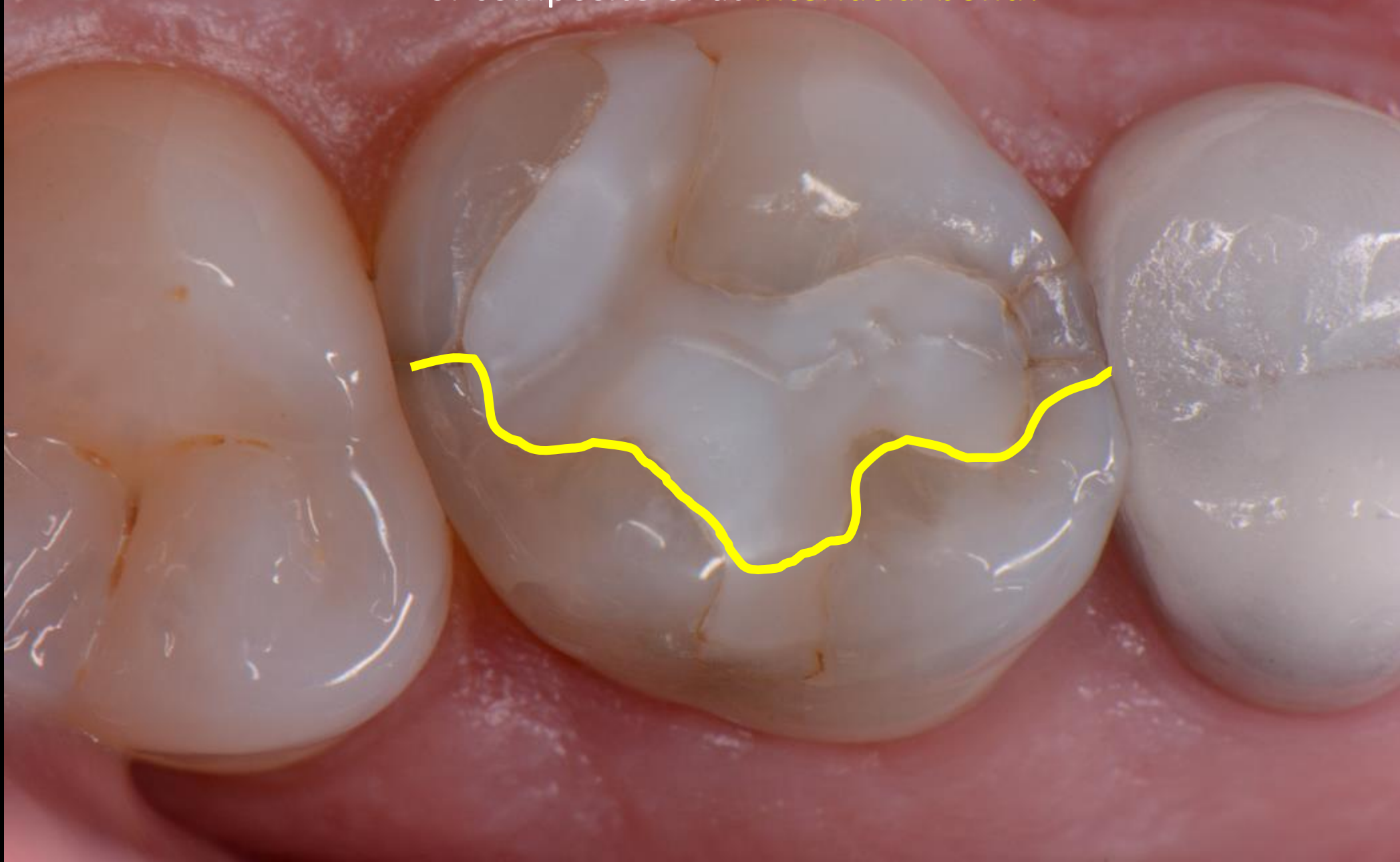
When the tooth fractures: Crack initiates through the central groove of composite or at interfacial bond?



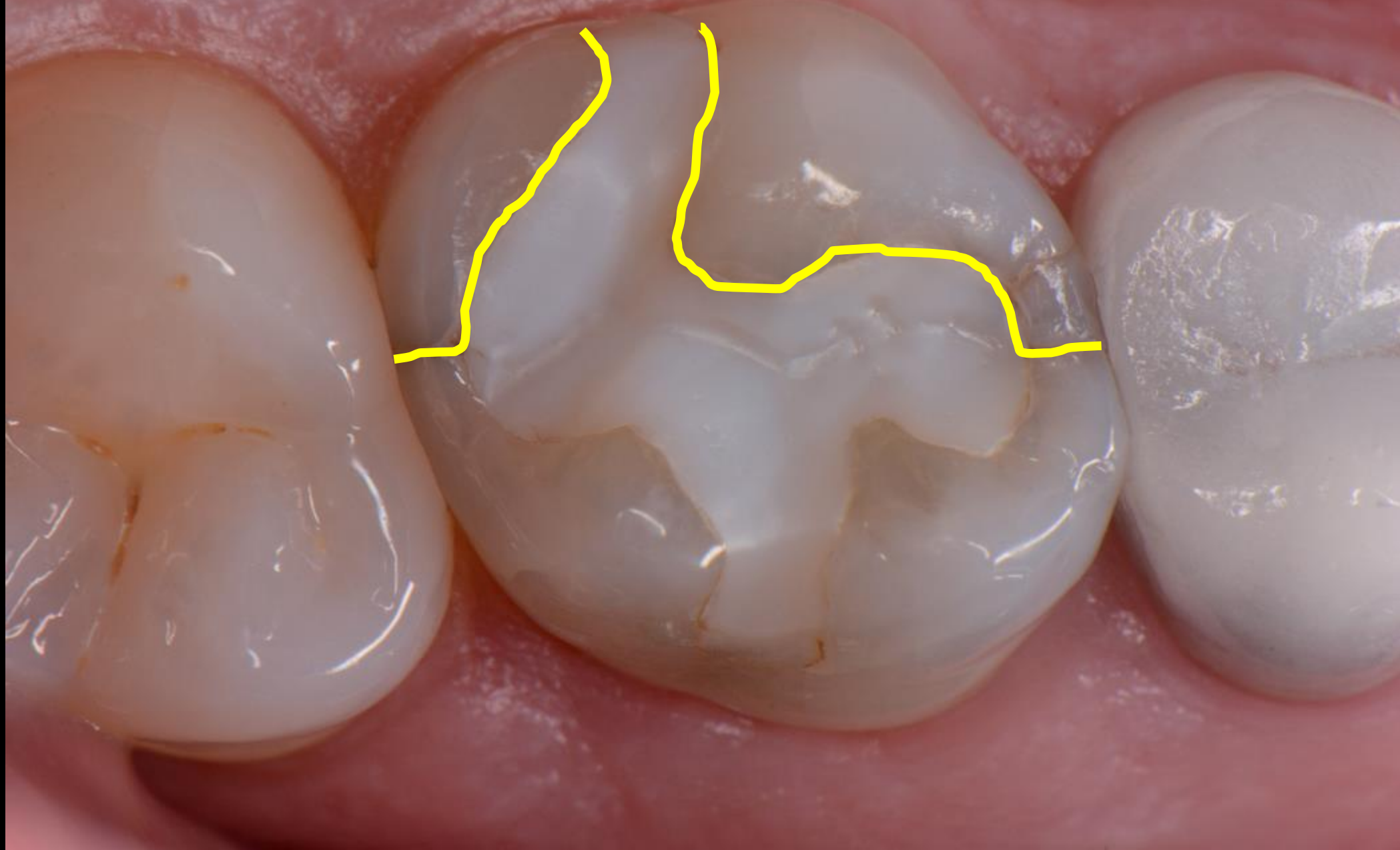When tooth fractures: Crack initiates through the **central groove of composite** or at interfacial bond?



When the tooth fractures: Crack initiates through the central groove of composite or at **interfacial bond**?



When the tooth fractures: Crack initiates through the central groove of composite or at **interfacial bond**?

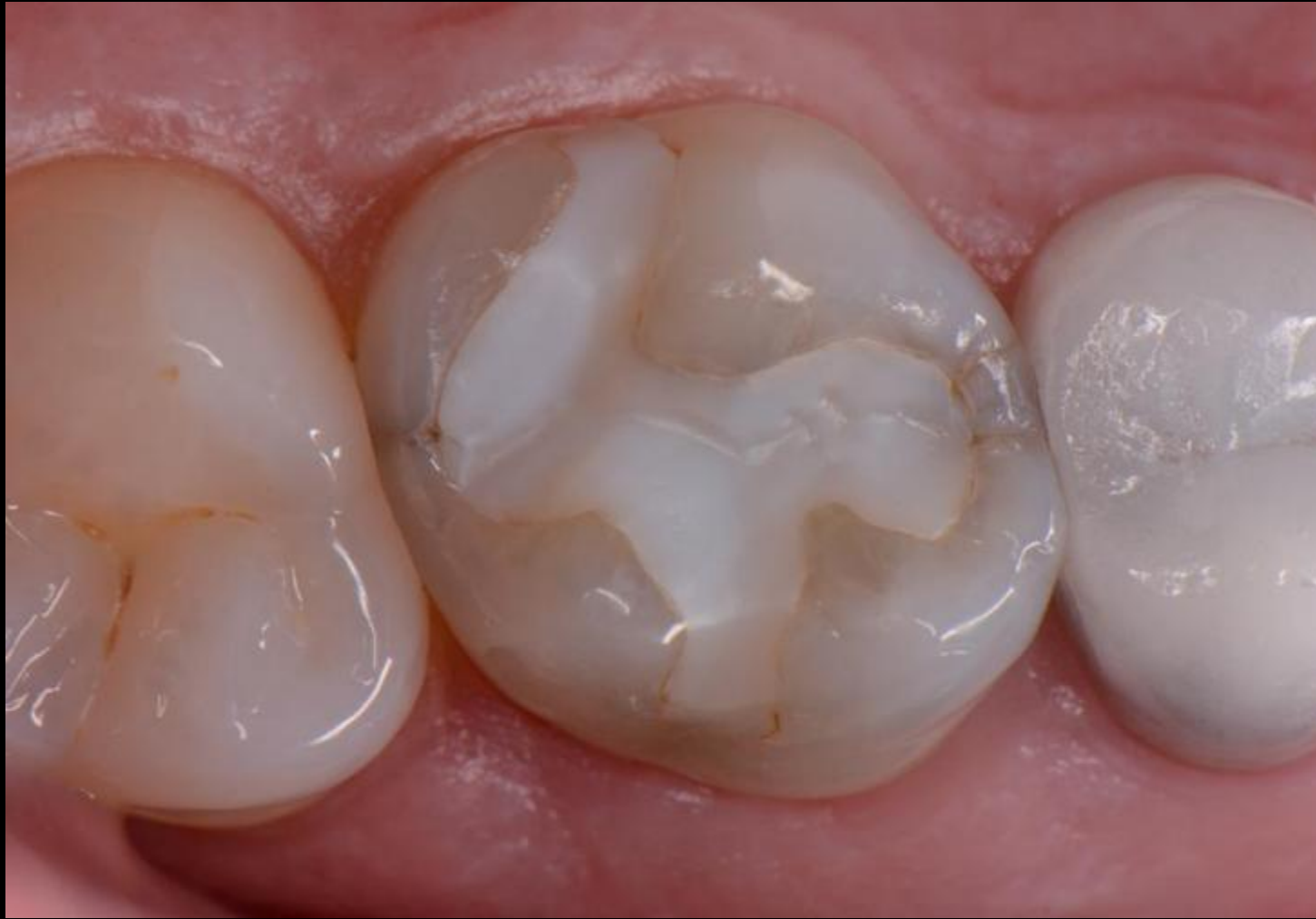

A close-up photograph of a human tooth showing a significant crack and a grayish discoloration on its surface. The crack runs vertically down the center of the tooth. The surrounding gum tissue is pink and appears slightly inflamed. The text is overlaid in white, bold, sans-serif font.

If the tooth is
gray, the tooth is
cracked

According to the FEA, what two things need to happen to eliminate fracturing?

- 1) No Central Groove
- 2) Horizontalize the prep to create compression (eliminate vertical walls with massive radius bevel in enamel, the prep will look like a trumpet or a calla lily)



Studies Supporting the Bioclear Method

Complete

- Comparing Conventional to Saucer-Shaped Cavity Designs

Dr. Alex Fok, BEng, PhD, MSc

Dr. Hooi Pin Chew, BDS, PhD, FDSRCS

MN Dental Research Center for Biomaterials and Biomechanics

- Comparison of Class II Adaptation and Placement Times

Dr. Richard Price, BDS, DDS, MS, FDS RCS, FRCD(C), PhD

Dept. of Clinical Dental Sciences & Biomedical Engineering Dalhousie University

- Effect of Preheating/Fatiguing/Thermocycling on Mechanical Properties

Taiseer A. Sulaiman, DDS, PhD



Assistant professor, Division Director of Operative Dentistry and Biomaterials, UNC School of Dentistry

- 3M Extraction and Pulp Temperature Testing

Brad Bagley, PhD, DABT Advanced Toxicology Specialist

- 3M Material Property Testing Including Injection Molding

Timothy D. Dunbar, Ph.D. Advanced Product Development Specialist



In Process

- Biofilm Adhesion Study

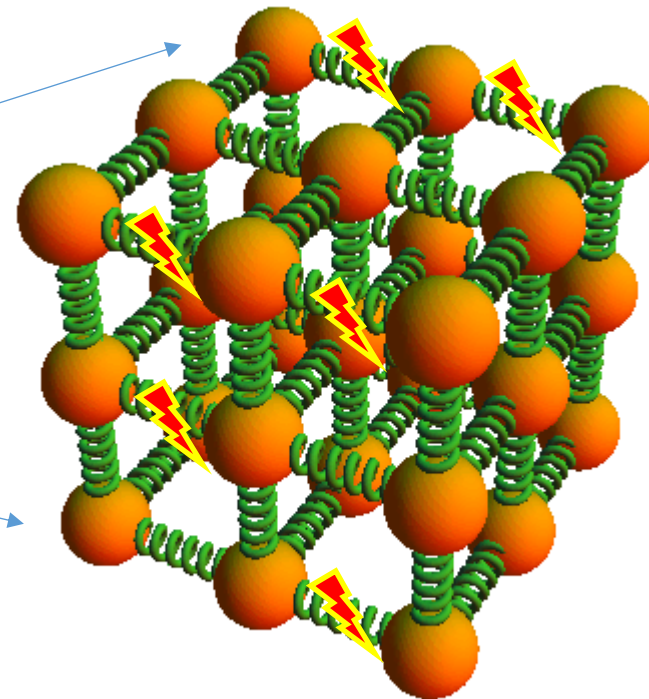
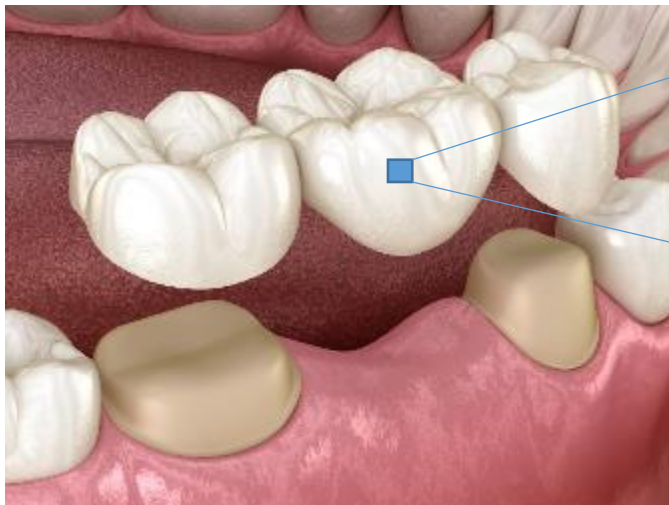
Sabrina F. Sochacki, DDS, MS, PhD

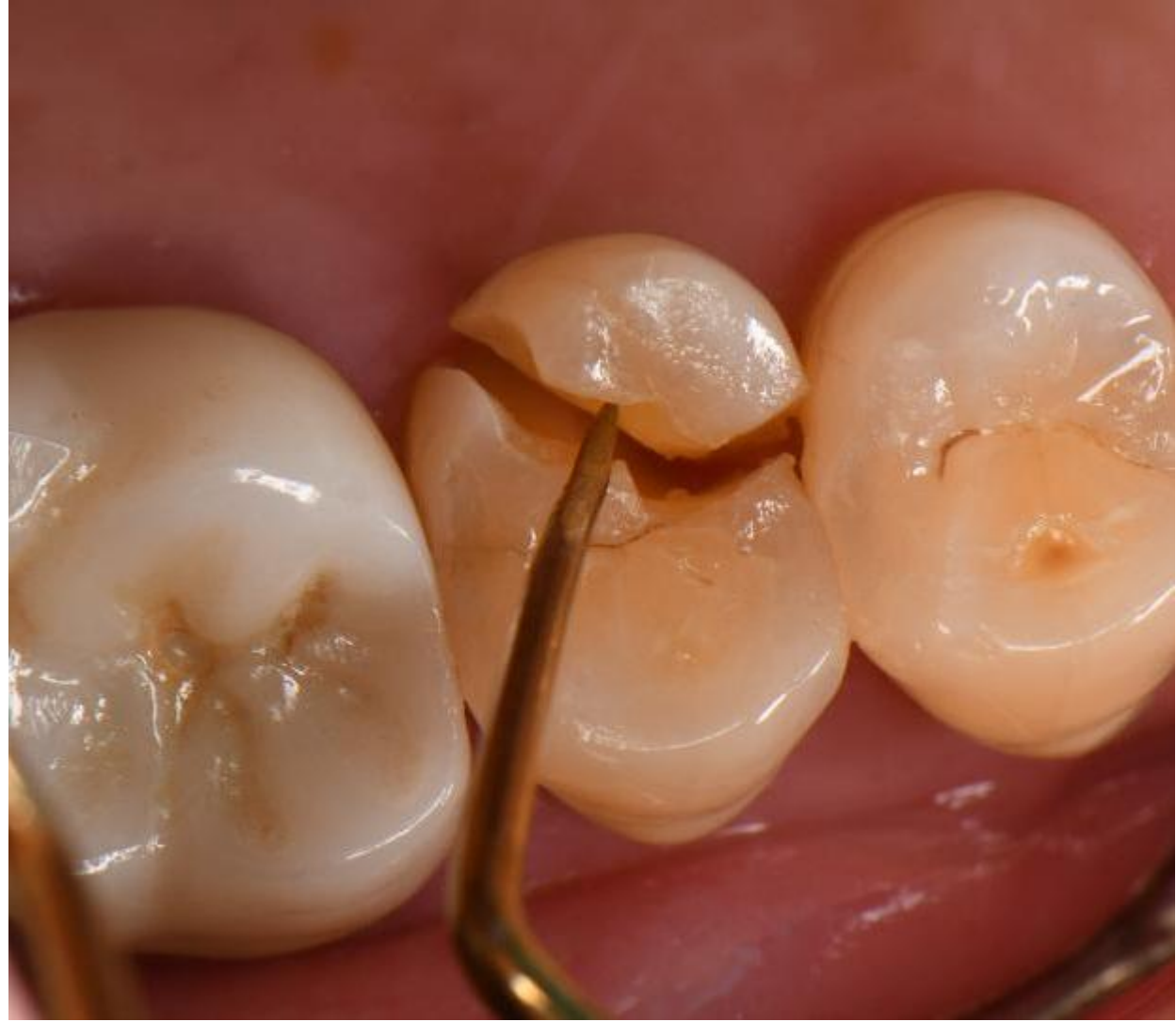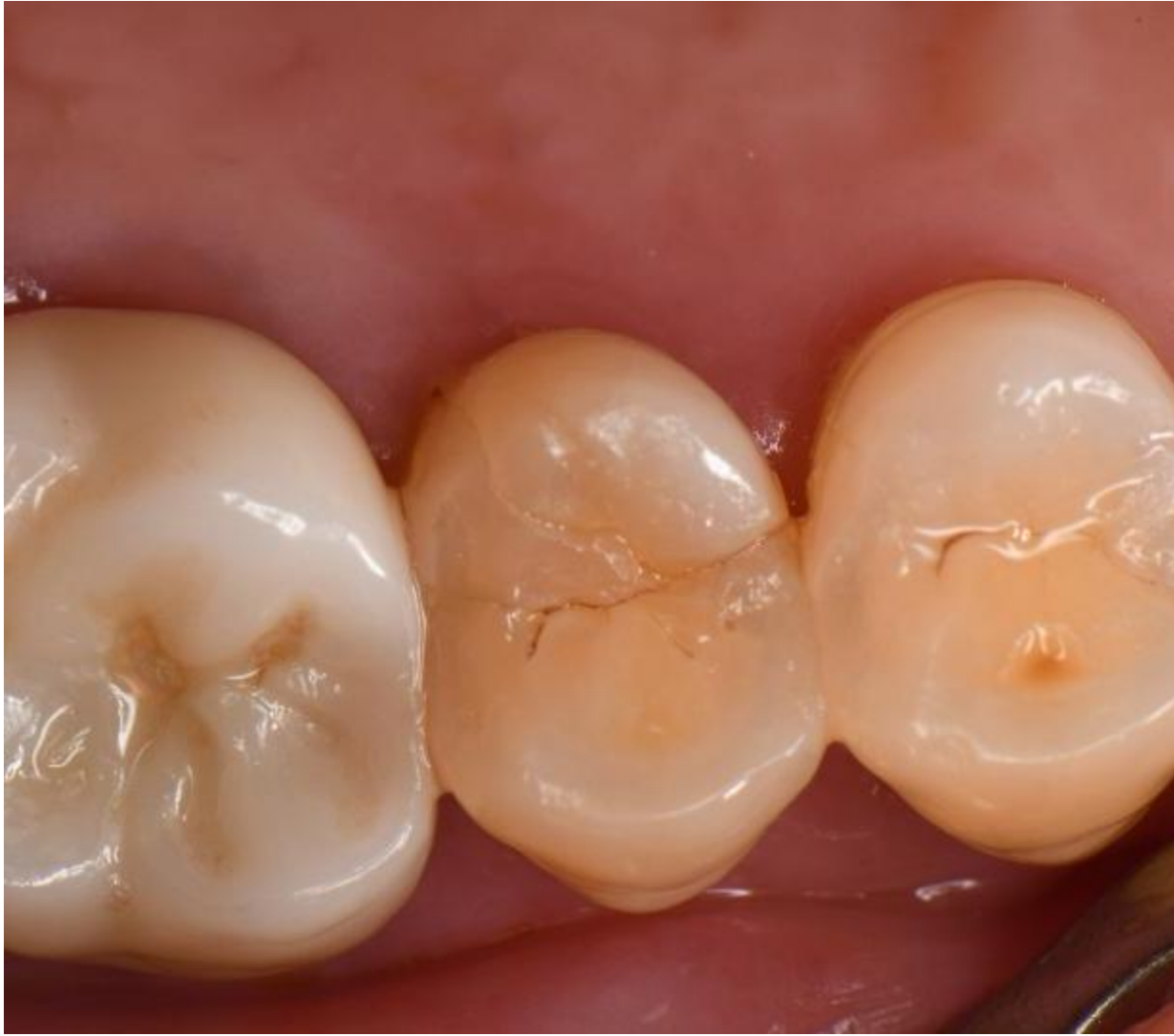Indiana University School of Dentistry

Basics of Solid Mechanics



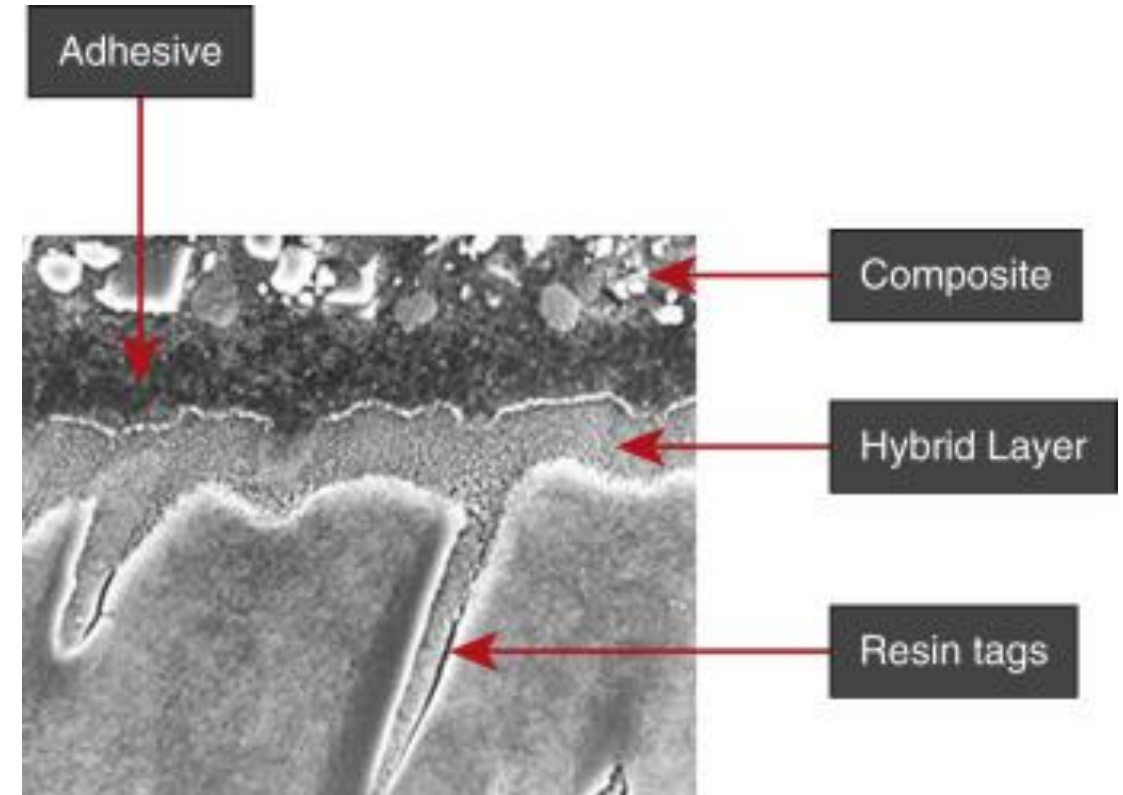

All solid structures can be considered as an assembly of many interconnected springs.





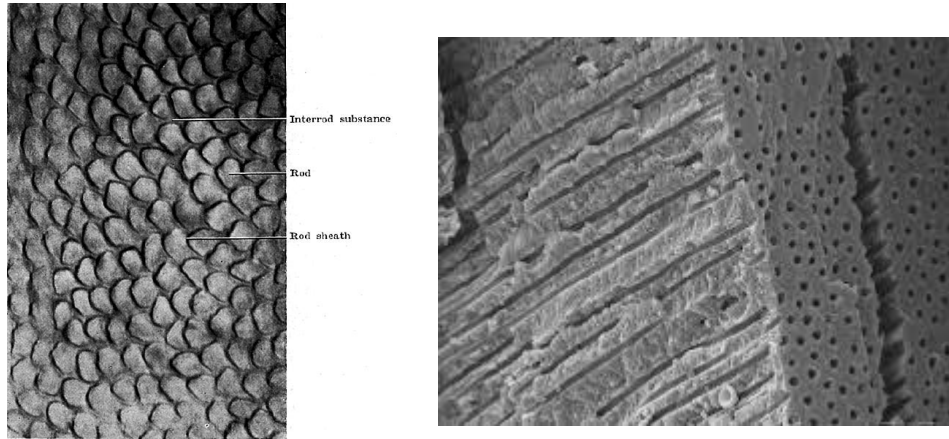
Enamel vs. Dentin Bonding

Bonding to enamel is mostly micromechanical.

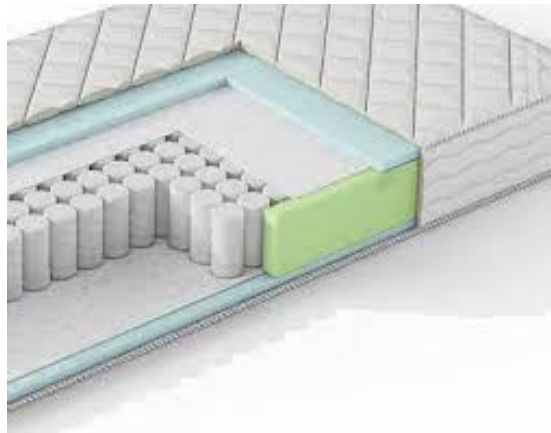


Bonding to dentin is more complicated, involving a hybrid layer and exposed collagen that are prone to enzymatic attack.

Anisotropy : tooth tissues




From Orban (1949) Oral Histology and Embriology, St. Louis: C.V. Mosby.



No bending stresses

Isotropy: resin composite



VS.



JOURNAL OF ESTHETIC AND RESTORATIVE DENTISTRY

Official Publication of the American Academy of Esthetic Dentistry,
Japan Academy of Esthetic Dentistry, International Federation of Esthetic Dentistry,
American Academy of Cosmetic and Adhesive Dentistry,
Belgian Academy of Esthetic Dentistry, Dutch Academy of Esthetic Dentistry,
and the Scandinavian Academy of Esthetic Dentistry



www.blackwell.com

Definitive Diagnosis of Early Enamel and Dentinal Cracks Based on Microscopic Evaluation

DAVID J. CLARK, DDS*
GERRYLEE G. SHEETS, DDS†
JACINTHE M. PAQUETTE, DDS‡

ABSTRACT

The diagnoses of cracked teeth and incomplete coronal fractures have historically been symptom based. The dental operating microscope at $\times 16$ magnification can fundamentally change a clinician's ability to diagnose such conditions.

Clinicians have been observing cracks under extreme magnification for nearly a decade. Patterns have become clear that can lead to appropriate treatment prior to symptoms or dissemination to tooth structure occur. Conversely, many cracks are not structural and can lead to misdiagnosis and overtreatment. Methodic microscopic examination, an understanding of crack progression, and an appreciation of the types of cracks will guide a doctor to making appropriate decisions.

Teeth can have structural cracks in various stages. To date, diagnosis and treatment are very often at end stage of crack development.

CLINICAL SIGNIFICANCE

This article gives new guidelines for recognition, visualization, classification, and treatment of cracked teeth based on the routine use of $\times 16$ magnification. The significance of enamel cracks as they relate to dentinal cracks is detailed.

(*J Esthet Restor Dent* 15:XXX-XXX, 2003)

Macroscopic and symptom-driven diagnoses have been the accepted modalities for cracked teeth. The inherent limitation of the lack of visual confirmation result in therapies that often come too late in the treatment process. One having first impression of vision through a clinical microscope is the staggering array of cracks that exist within tooth structures. Traditional visualization limited

or ocular acuity limits the clinician's ability to assess the presence or severity of the majority of these cracks (Figure 1).

At extreme magnification levels ($\times 14$ and greater), the translucent nature of enamel yields a wealth of information. Subtle color changes within the enamel may indicate early decay, microleakage, and a lack of structural integrity of dentin and

enamel. Being able to see previously invisible crazes can lead restorative dentists to more appropriate early treatment of compromised teeth before devastating fractures, pulpal involvement, and pericoronal breakdown occur. The value of early diagnosis of the structural breakdown of teeth will become even more significant with our aging population coupled with increased tooth retention in this population.

*President, Academy of Microscopic Enhanced Dentistry
†Governor's Dentist, Newport Coast Oral Facial Institute, Newport Beach, CA, dental professor,
Restorative Dentistry, USC School of Dentistry, Los Angeles, CA, USA
‡Governor's Dentist, Newport Coast Oral Facial Institute Newport Beach, CA, associate professor,
Restorative Dentistry, USC School of Dentistry, Los Angeles, CA, USA

Nomenclature and Classification System for Enamel Cracks

Type I: Have little or no risk of underlying pathology

Type II: Have moderate risk of underlying pathology

Type III: Have high risk of underlying pathology

Type I: Have little or no risk of underlying pathology

- A) Craze lines
- B) Small vertical cracks
- C) Cracks that follow natural anatomic grooves
- D) Cracks with superficial stain penetration

Type II: Have moderate risk of underlying pathology

- E) V-shaped enamel ditching with or without an adjoining restoration often associated with a wear facet centered over an otherwise benign crack
- F) Cracks that detour from or do not follow natural anatomic grooves

Type III: Have high risk of underlying pathology

- G) Diagonal cracks branching off a vertical crack
- H) Horizontal or diagonal cracks that emanate from the corner of a restoration
- I) Cracks that house debris

Type III: Have high risk of underlying pathology

- J. Pair of cracks that outline an area (cusp or marginal ridge) of discolored enamel
- K. Crack with corresponding halo of brown, grey or white centered on crack
- **The tooth or the cusp is gray**

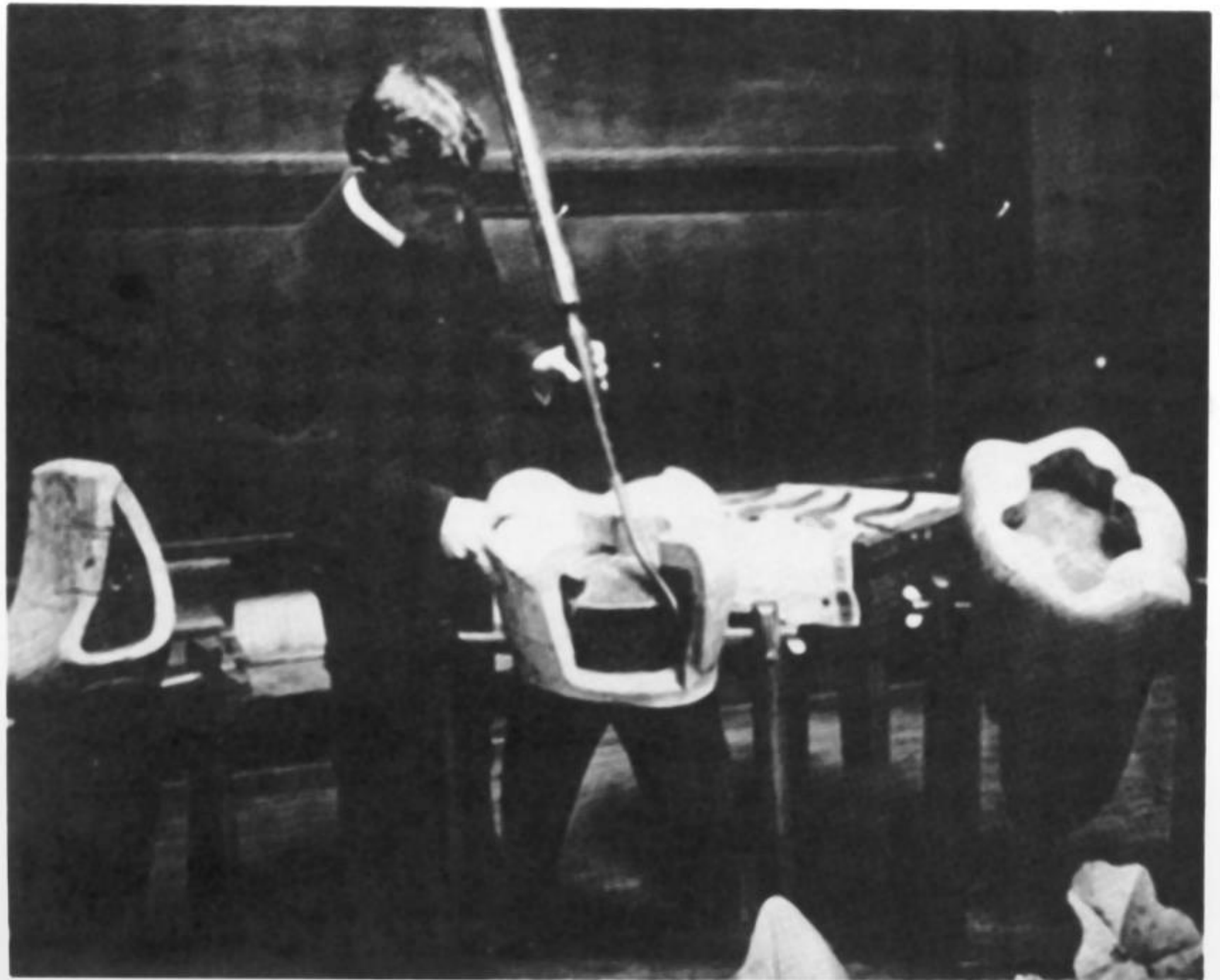
**WHERE ARE WE WITH
CAVITY SHAPES?**

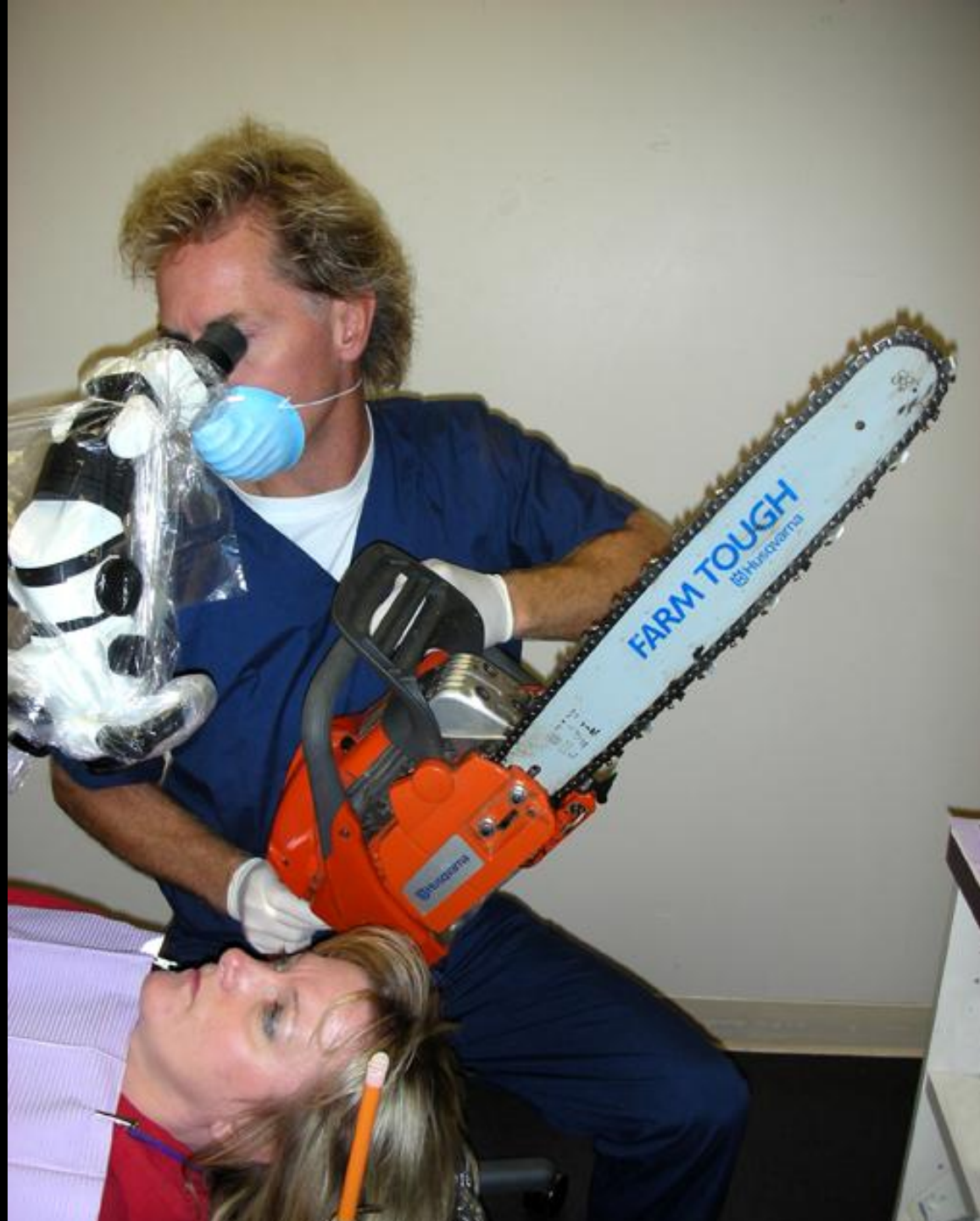
1890

**G. V. BLACK,
M.D., D.D.S.,
Sc.D., LL.D.,
1836-1915**



**MORTICE AND
TENON JOINTS
NECESSARY FOR
MECHANICAL
RETENTION OF
AMALGAM**





EDGETAPER
PLATINUM™



PER GOLD® \$67/6pk
Taper Platinum™

95/6PK

ROTAPER GOLD®
ROTAPER®

FIREWIRE™ NITI

ance as PROTAPER GOLD®
ance as PROTAPER®

THE JOURNAL OF MULTIDISCIPLINARY CARE

Decisions™ IN DENTISTRY

CONSERVATIVE APPROACH TO DEEP CARIES LESIONS

NATHANIEL LAWSON, DMD, PhD, and
AUGUSTO ROBLES, DMD, MS

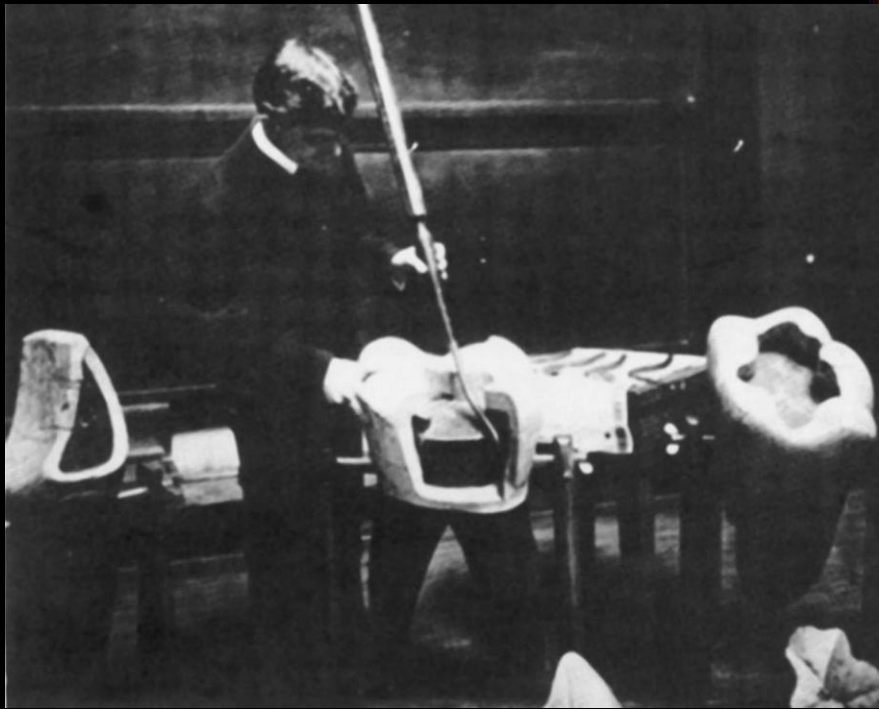
RISK FACTORS IN
ORAL CANCER
SCREENING
SARAH GLASS, DDS

HOW MANAGED
CARE WILL IMPACT
DENTAL PRACTICE
JOEL H. BERG, DDS, MS

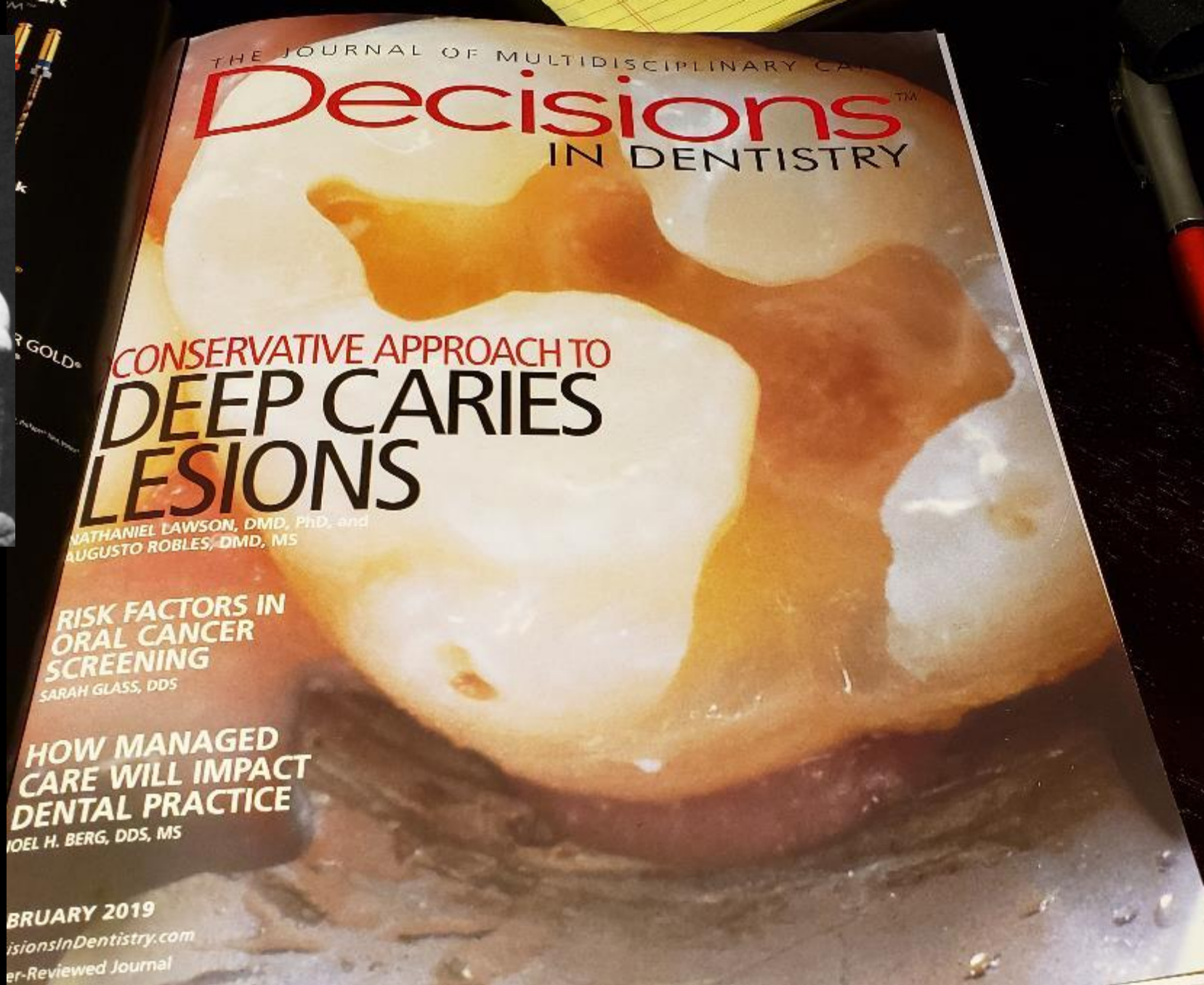
FEBRUARY 2019

DecisionsInDentistry.com

A Peer-Reviewed Journal



Is this the
year 2026
or 1890?

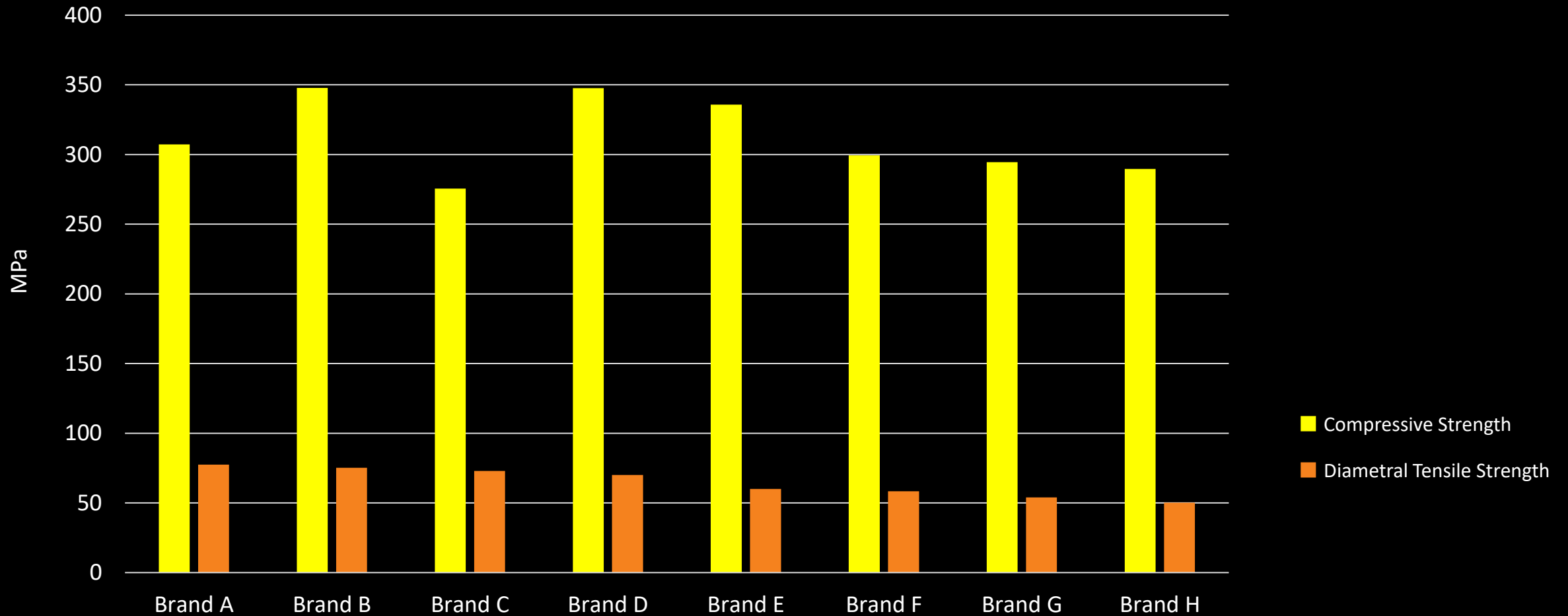


Epidemic of Cracked Teeth...Why?

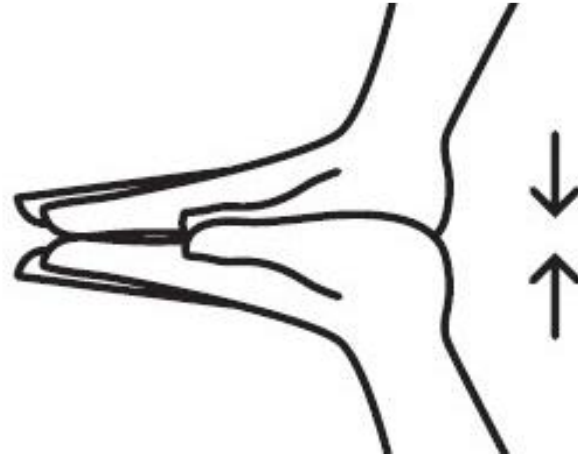
**Brittle Materials with
Tension joints**

Composite Resin Material Properties

Compressive vs Diametral Tensile Strength



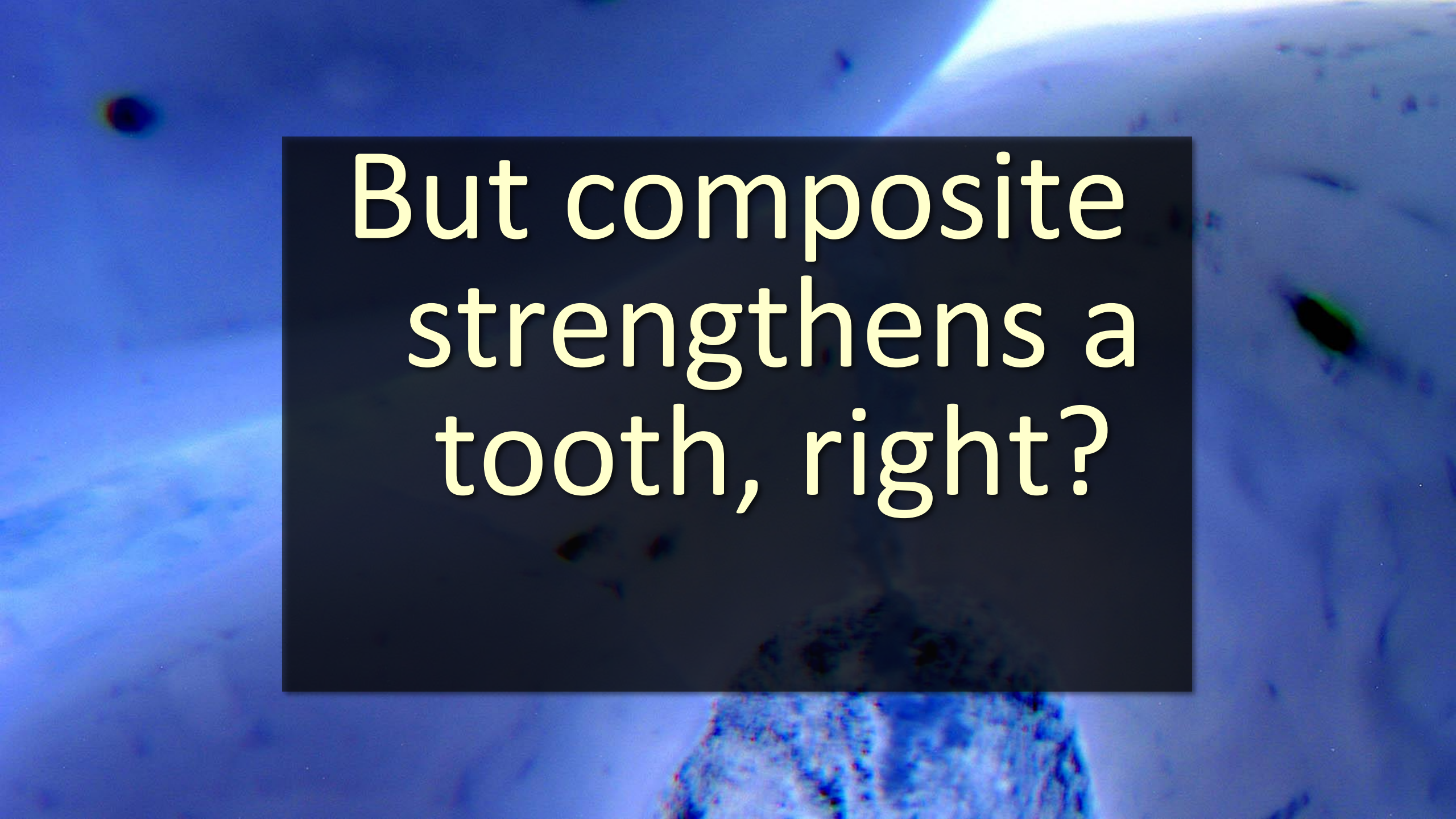
Compression vs. Tension is “Engineering 101”



compression



tension

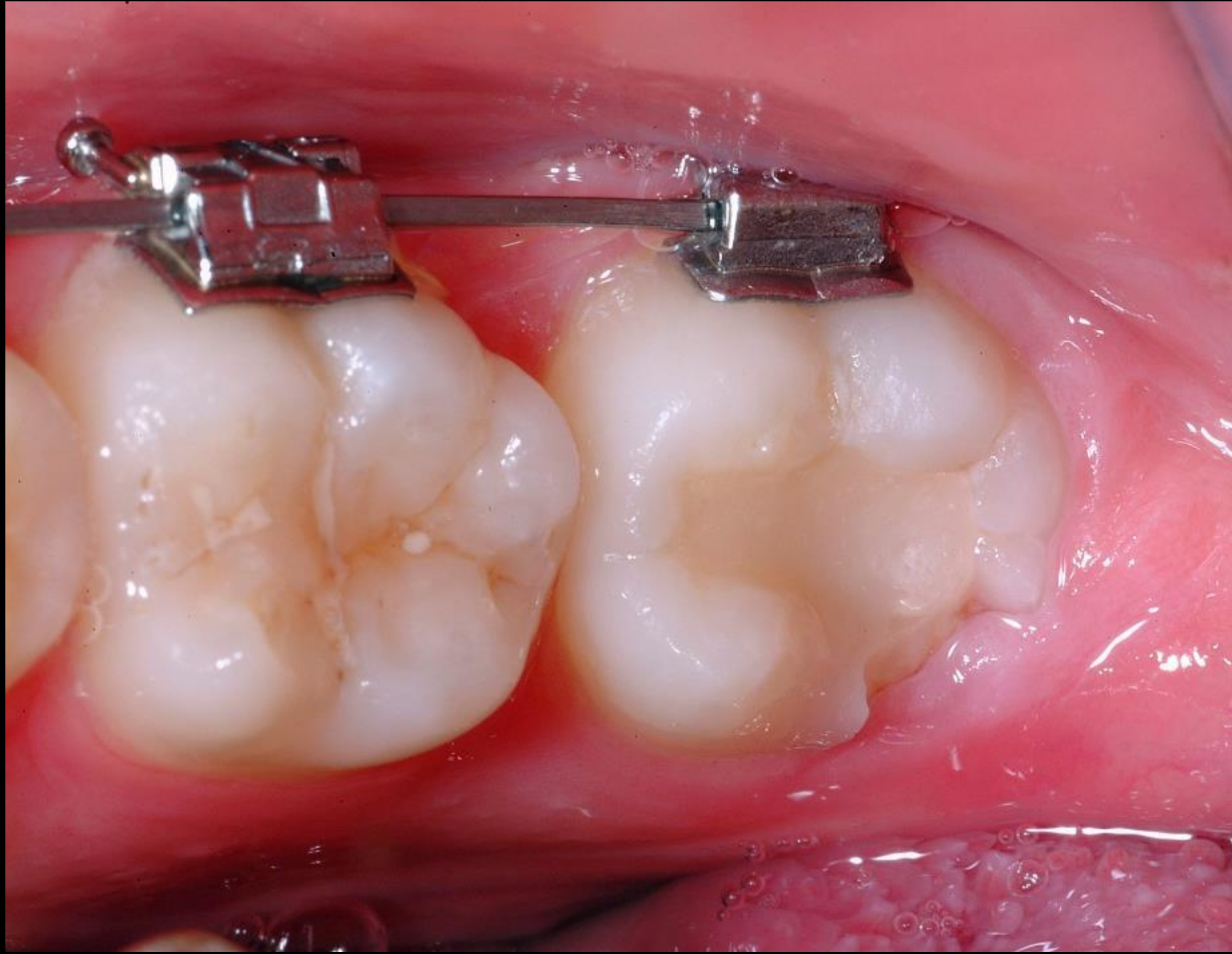
A microscopic image of a tooth with a composite filling. The background is a light blue, textured surface representing the tooth's enamel. A dark, rectangular area in the center represents the composite filling. The text is overlaid on a black rectangular background in the center of the image.

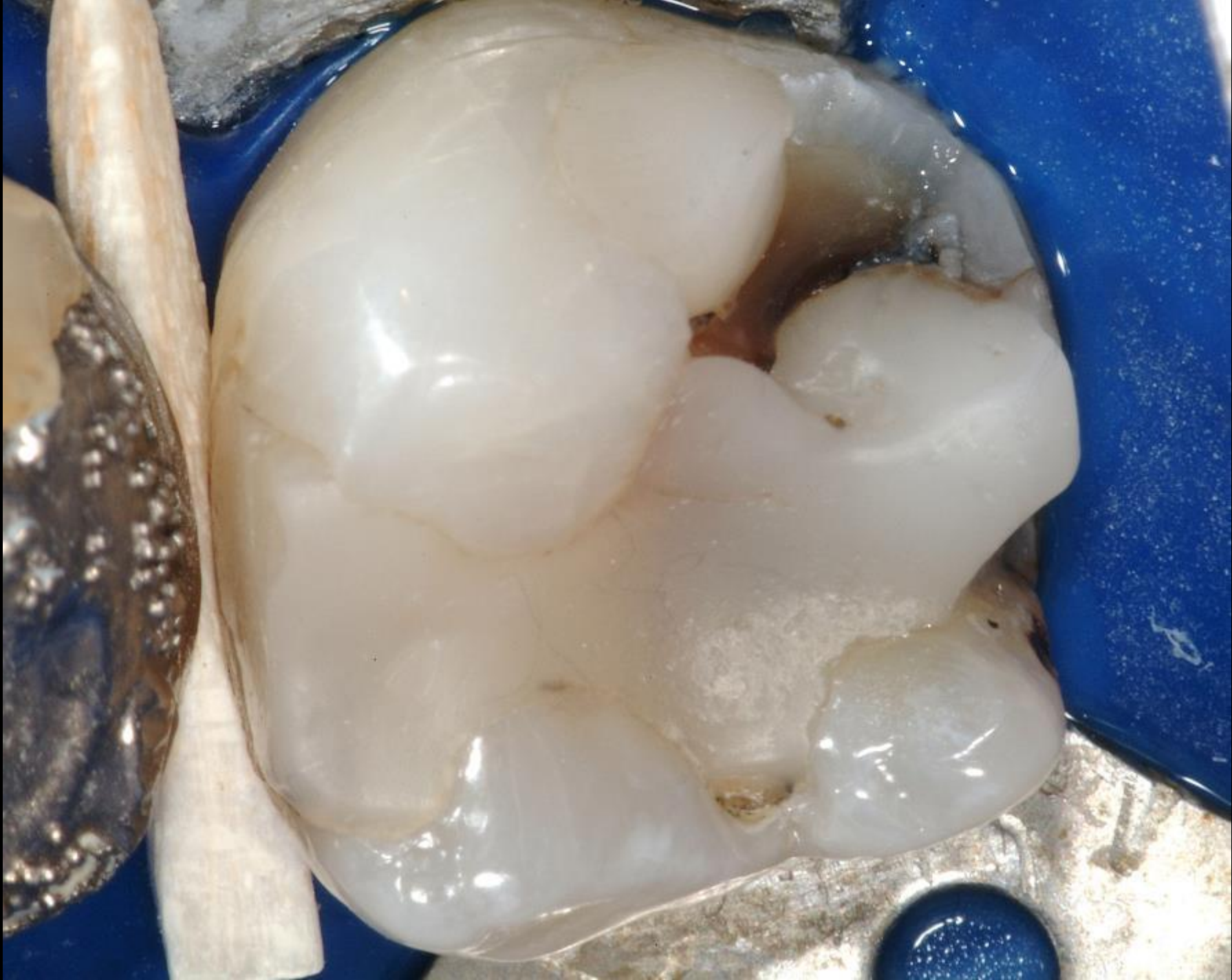But composite
strengthens a
tooth, right?

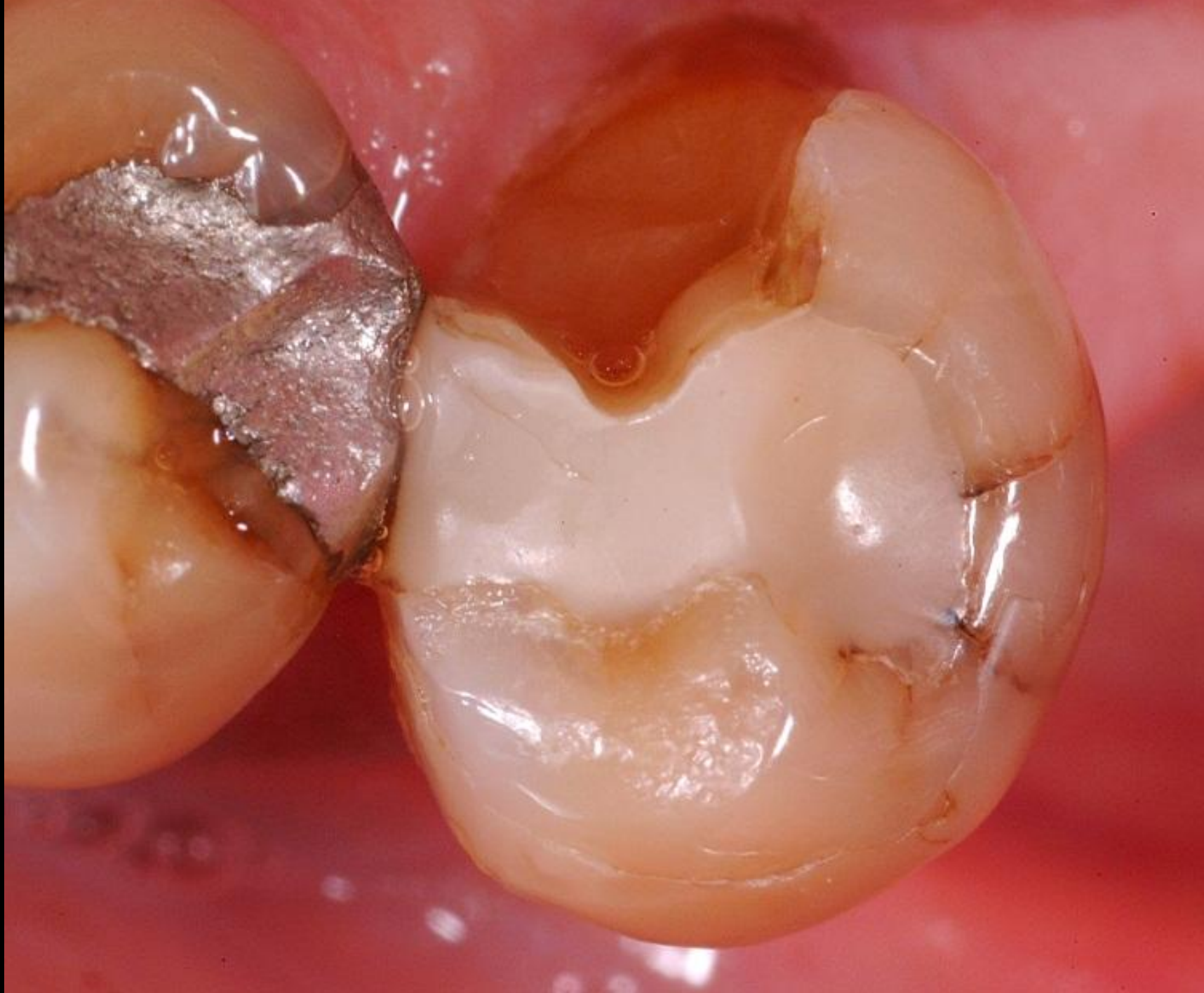Does composite strengthen the tooth?

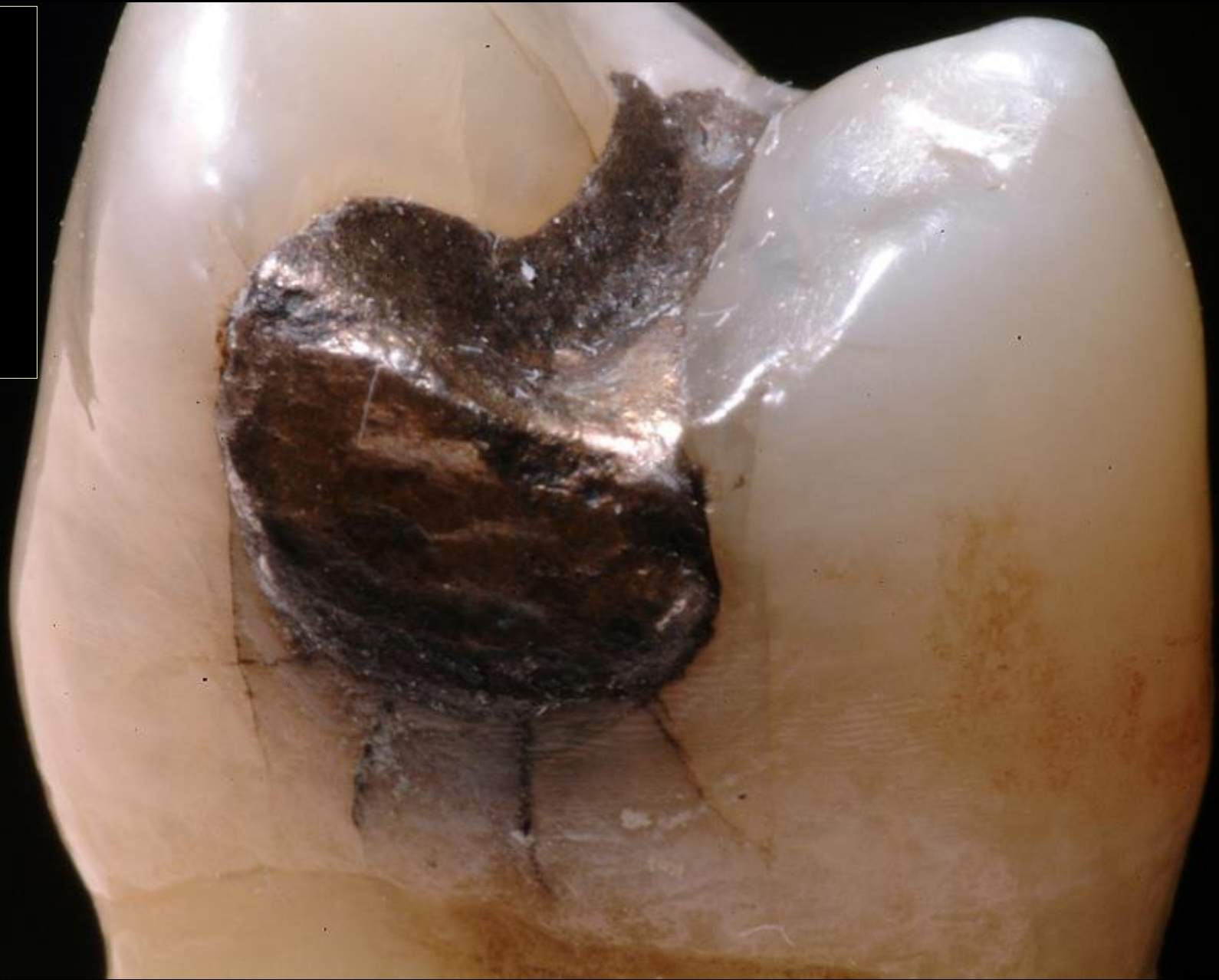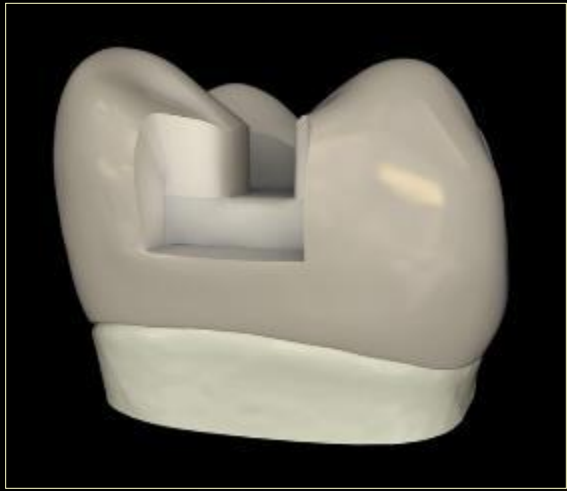
No more than does amalgam

Wahl MJ, Schmitt MM,
Overton DA, Gordon MK.
Prevalence of cusp
fractures in teeth restored
with amalgam and with
resin-based composite.
JADA 135:1127-1132
(2004)





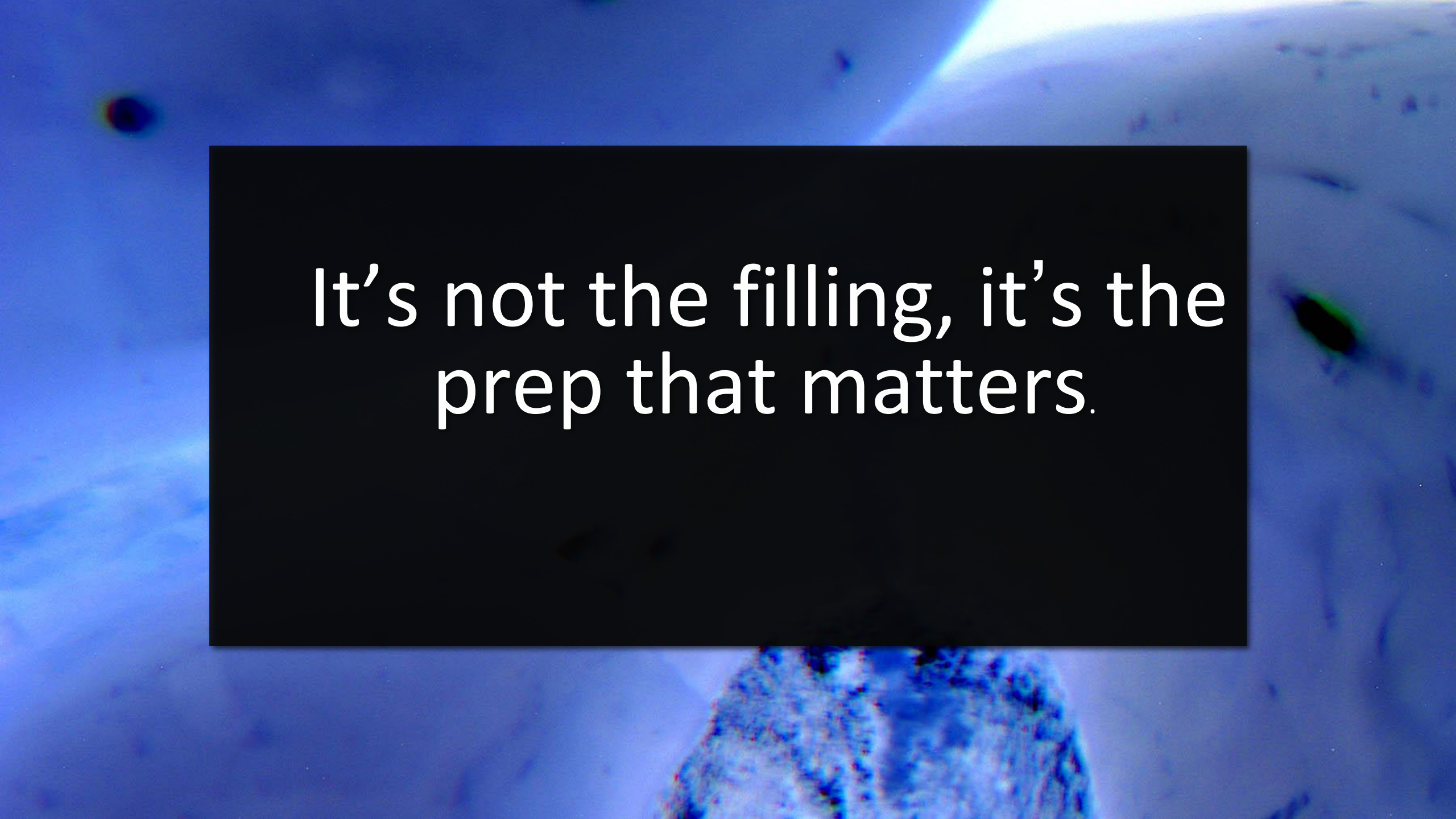




Boxes are bad.

Bevels make them less bad.

The Clark Class II replaces
beveling with radius walls.



It's not the filling, it's the
prep that matters.

The New Science of Strong Materials

or Why You Don't Fall through the Floor

J. E. Gordon



MAGNIFICATION

The Epidemic of Cracked and Fracturing Teeth



Tooth and jawbone fractures are on the rise. A study published in the *Journal of Endodontics* in 2007 found that the number of cracked teeth has increased significantly since 1990. The study also found that the number of fractured teeth has increased significantly since 1990. The study also found that the number of fractured teeth has increased significantly since 1990.

REVERSE CAUSING AND PREVENTION
The study also found that the number of fractured teeth has increased significantly since 1990. The study also found that the number of fractured teeth has increased significantly since 1990.

Phase 1	Phase 2	Phase 3	Phase 4
Initial and early stages of tooth fracture	Progression of tooth fracture	Advanced stages of tooth fracture	Severe stages of tooth fracture

- 1) Initial and early stages of tooth fracture
- 2) Progression of tooth fracture
- 3) Advanced stages of tooth fracture
- 4) Severe stages of tooth fracture

Associated Medications/Drugs
The study also found that the number of fractured teeth has increased significantly since 1990. The study also found that the number of fractured teeth has increased significantly since 1990.

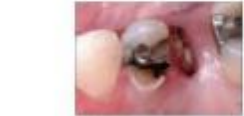

Figure 1. An orthodontic space maintainer can be used to prevent tooth fracture. The orthodontic space maintainer can be used to prevent tooth fracture.

RESTORATIVE

Fracture Resistant Endodontic and Restorative Preparations



Figure 1. Photograph of a tooth with a fracture.



Figure 2. Photograph of a tooth with a fracture.



Figure 3. Photograph of a tooth with a fracture.

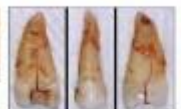

Figure 4. Photograph of a tooth with a fracture.



Figure 5. Photograph of a tooth with a fracture.




Figure 6. Photograph of a tooth with a fracture.



Figure 7. Photograph of a tooth with a fracture.




Figure 8. Photograph of a tooth with a fracture.




Figure 9. Photograph of a tooth with a fracture.



Figure 10. Photograph of a tooth with a fracture.



Figure 11. Photograph of a tooth with a fracture.



Figure 12. Photograph of a tooth with a fracture.

INTRODUCTION
The number of cracked teeth has increased significantly since 1990. The study also found that the number of fractured teeth has increased significantly since 1990. The study also found that the number of fractured teeth has increased significantly since 1990.

Restoratively, It's Not the Size of the Hole, but the Shape of the Hole

The formula for determining stress concentration due to a cavity preparation is $(1+2\sqrt{\frac{L}{R}})$ where L is length of the cut and R is the radius of the cut. In simple terms, the longer the cut, the worse the cut. A long narrow cut, interestingly, is worse than a wide, round-bottomed cut. One reason that intracoronal composites do not protect the tooth from long-term from

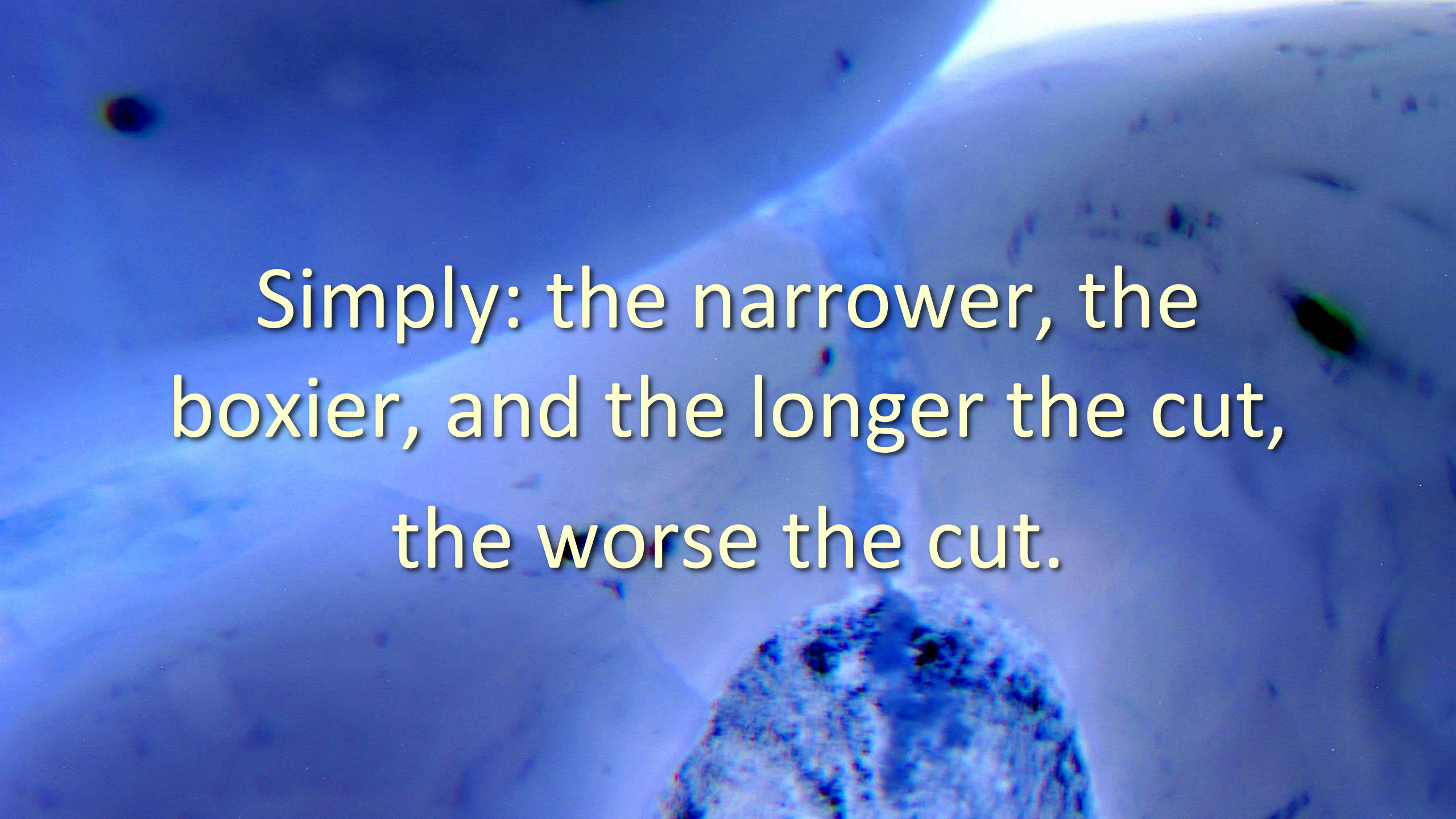


The formula for stress concentration in a cavity is

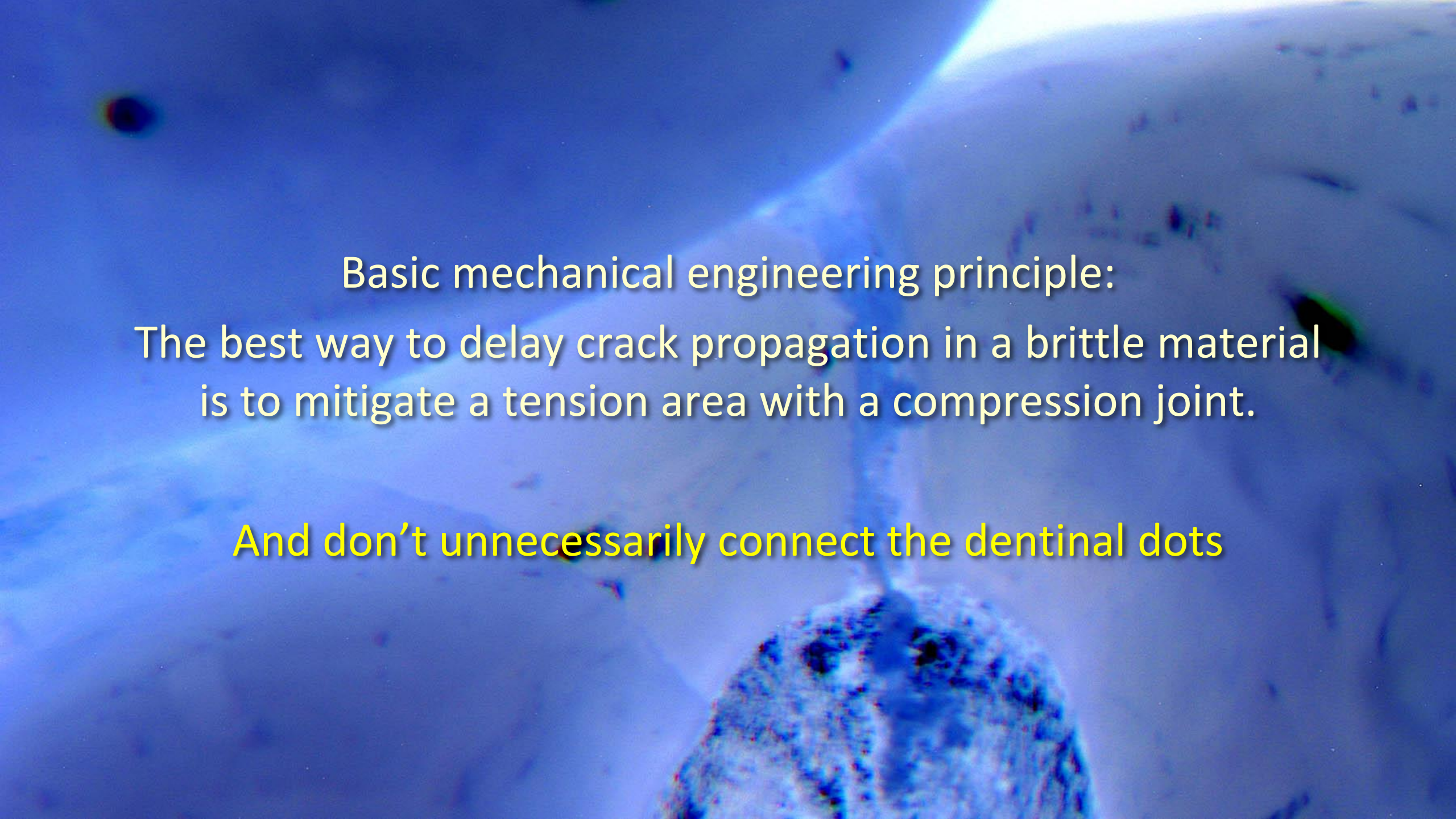
$$1 + 2 \sqrt{L/R}$$

L is the depth of the cut.

R is the radius of the cut.

A close-up photograph of a diamond being cut. The diamond is the central focus, showing its facets and the cutting process. The background is a dark, textured surface, likely the cutting table. The lighting is bright, highlighting the facets of the diamond.

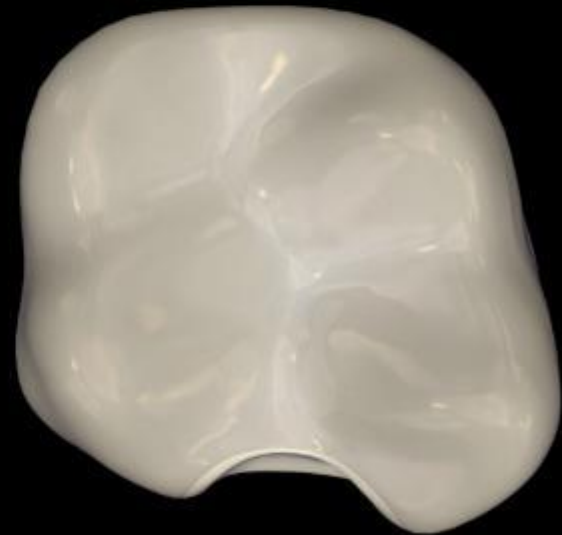
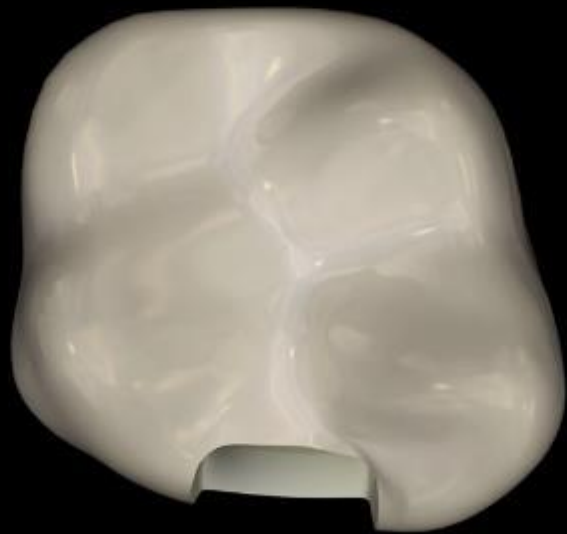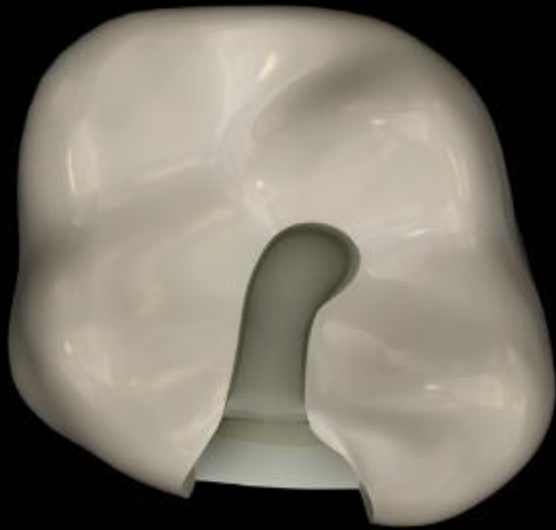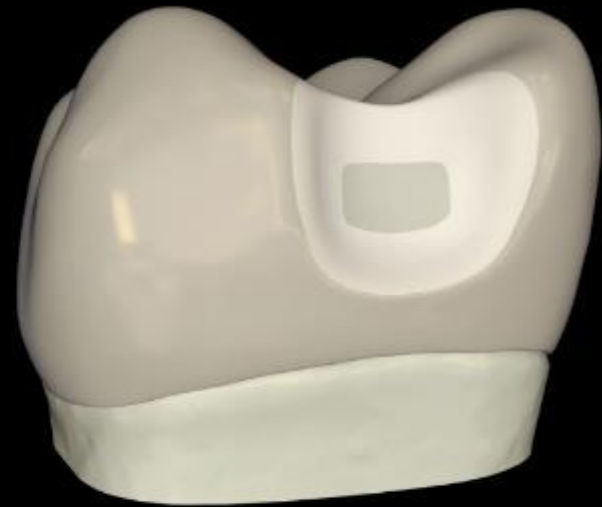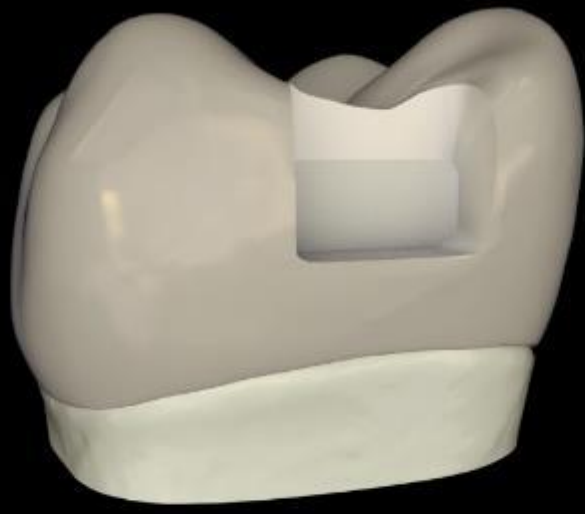
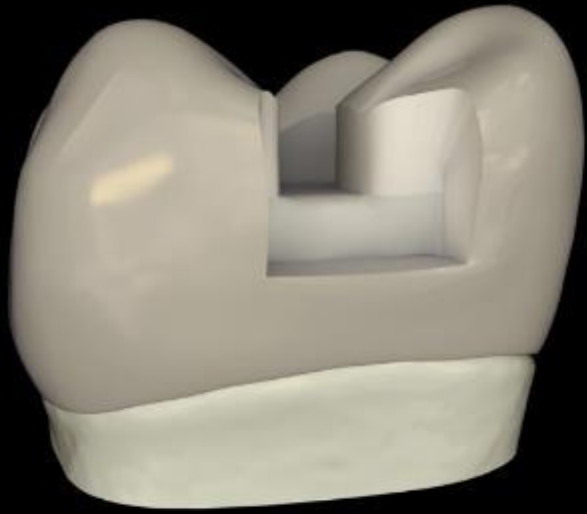Simply: the narrower, the
boxier, and the longer the cut,
the worse the cut.

A microscopic image of a material surface, likely a metal or ceramic, showing a crack. The crack is a dark, irregular line running diagonally across the frame. The surface has a granular texture with various small features and imperfections. The lighting is bright, creating highlights and shadows that emphasize the surface topography.

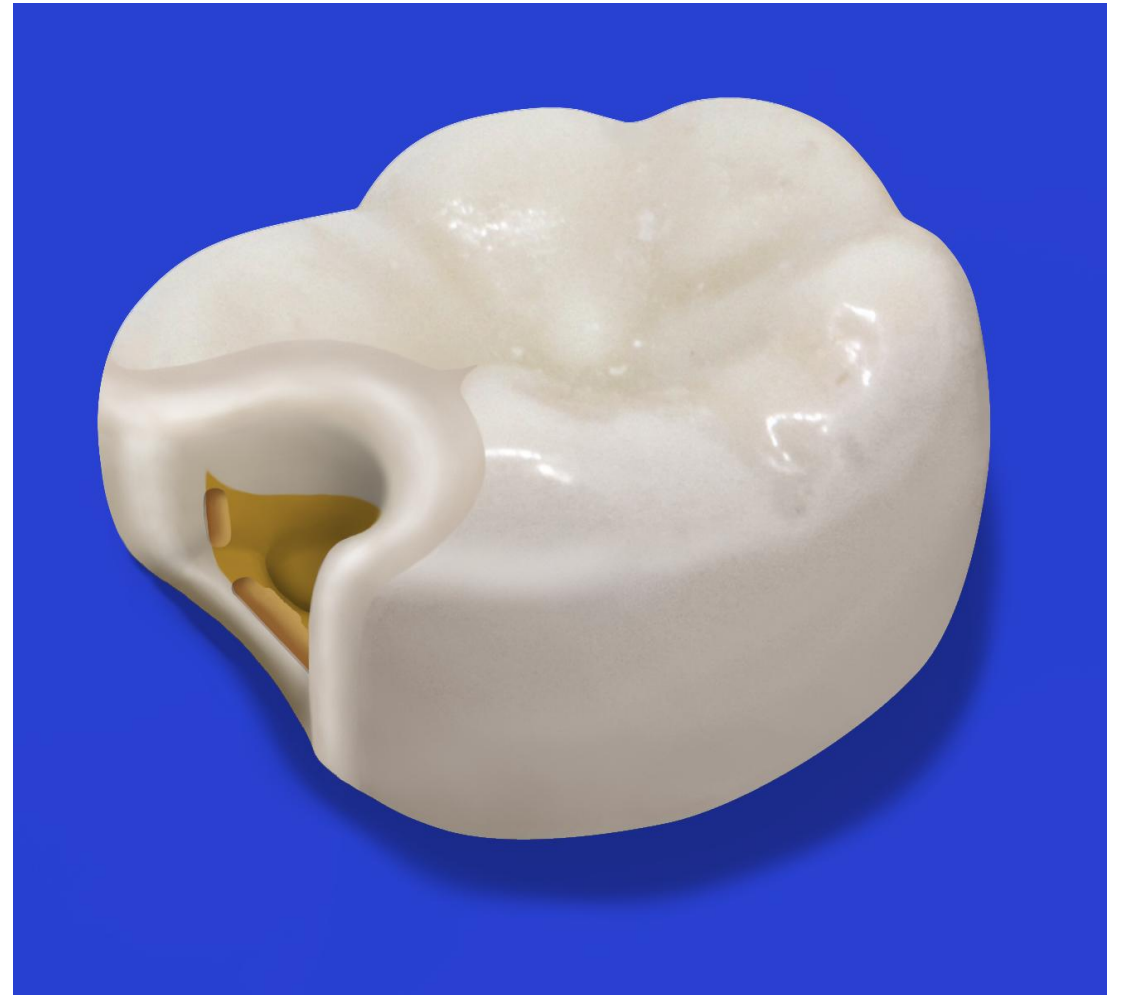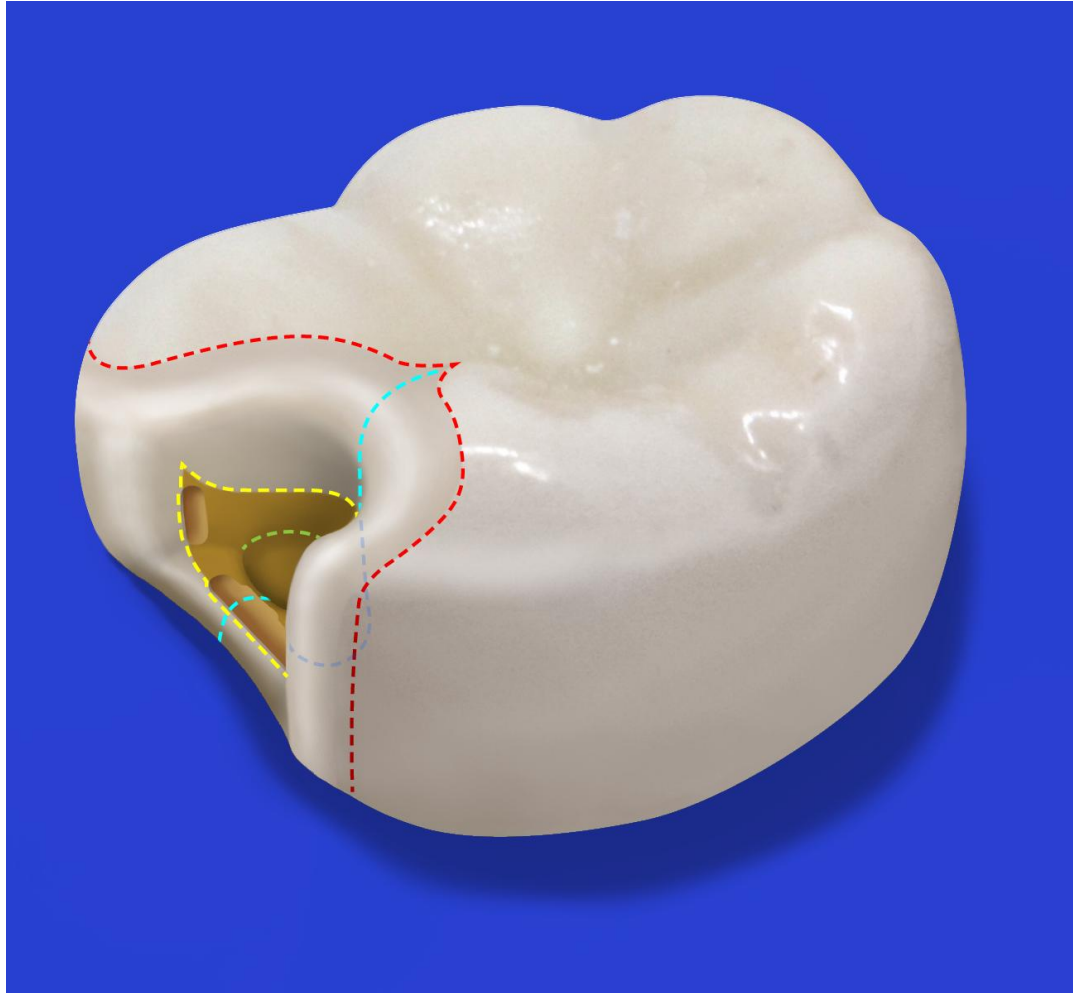
Basic mechanical engineering principle:
The best way to delay crack propagation in a brittle material
is to mitigate a tension area with a compression joint.

And don't unnecessarily connect the dentinal dots

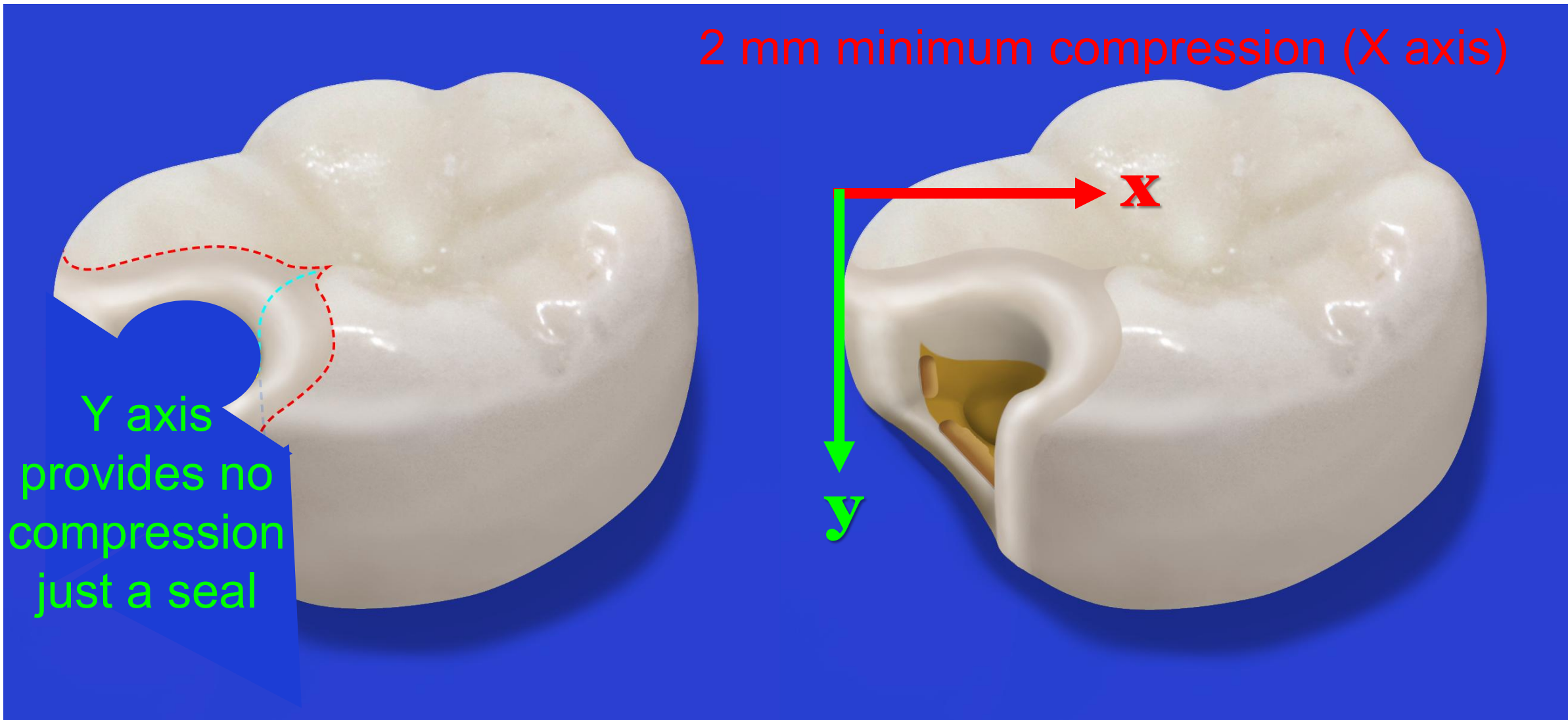
The Prep?



Final views of completed Bioclear Class II Preparation.



To eliminate mechanical retention, we need 2 mm of enamel in compression at the primary strike point of occlusion



Modern Restoration

Design=**I.C.E.**

Infinity edge

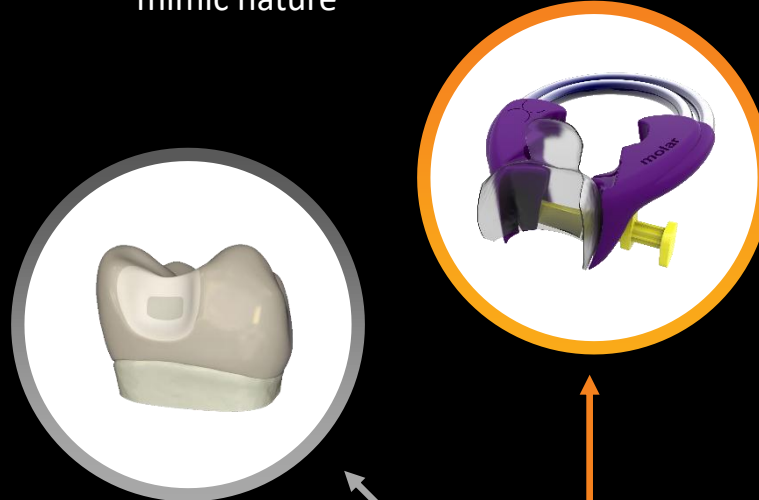
Compression based

Enamel driven

Modern Method for Composite Restorations

Clear Anatomic Matrices

- Anterior & Posterior Matrices designed to mimic nature



Injection Mold Composite

- Injection mold warmed Restorative materials
- Industry leading polish, esthetic, strength & wear

Preparation Design

- Designed for composite
- Minimizes stress concentration
- Maximizes enamel involvement

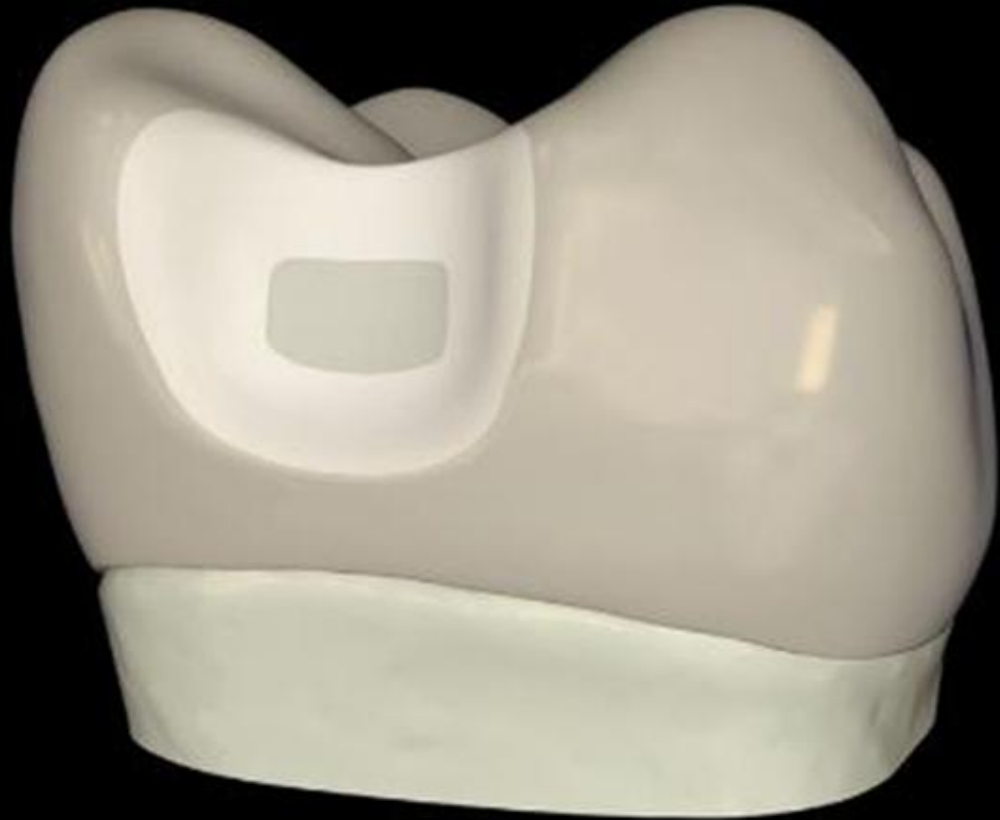Biofilm Removal

- Remove biofilm before bonding
- Allows bonding to uncut enamel
- Allows infinity edge margins

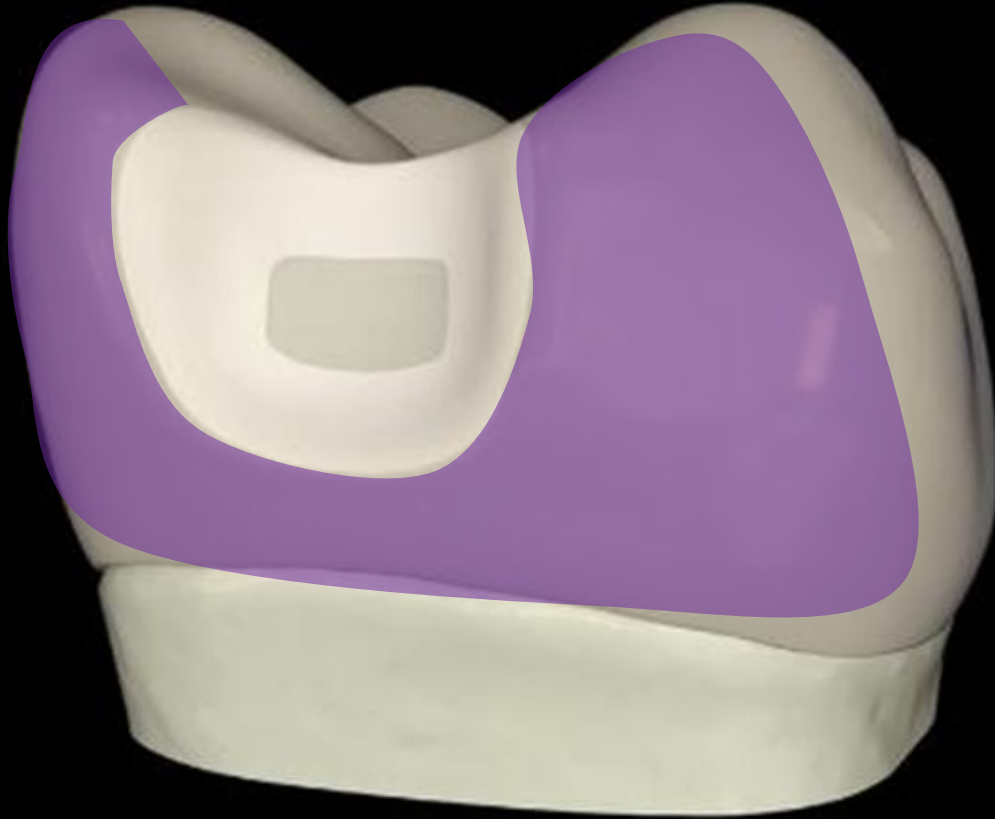Final Polish

- 3M™ Sof-Lex™ XT coarse discs for reduction
- “Rock Star” polish with Bioclear Magic Mix & RS Polisher

Clark Class II Prep Design

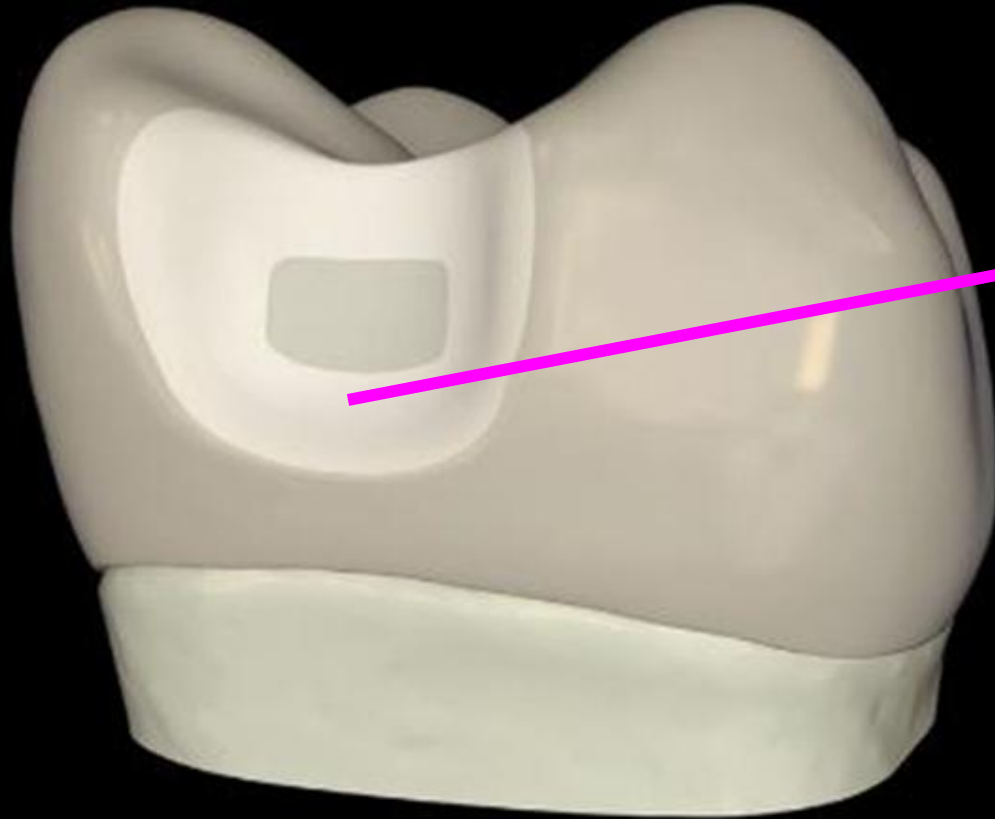

Unique Aspects of the Clark Class II Prep Design



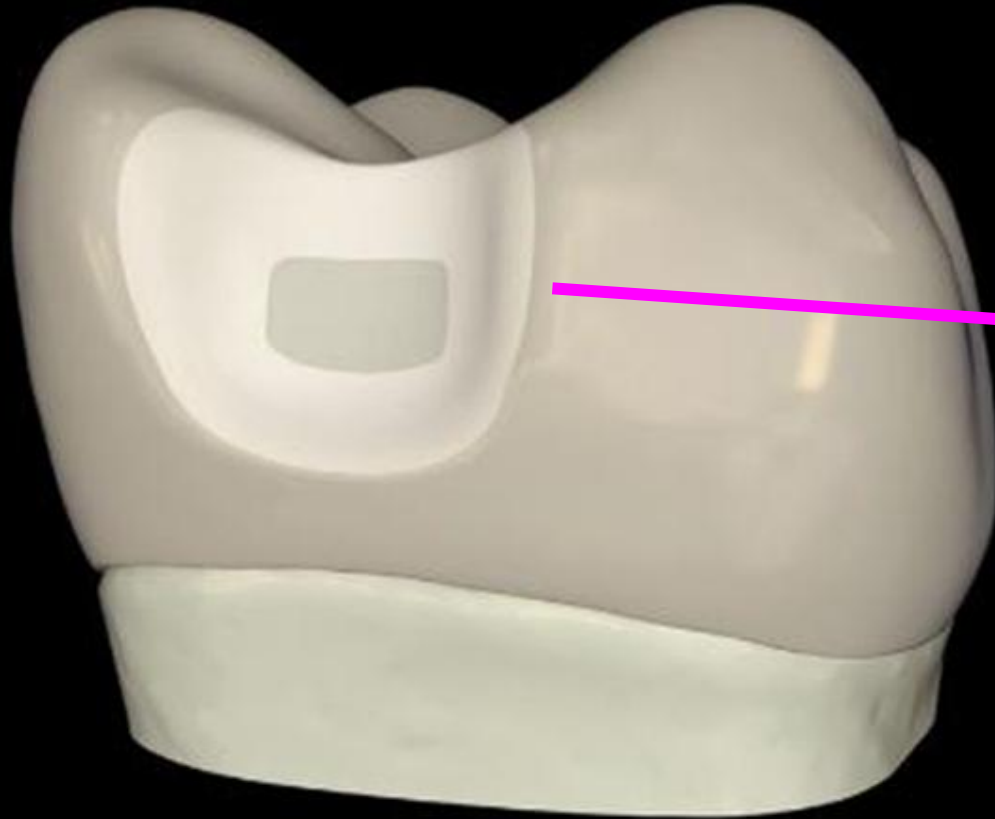
- Removal of biofilm

Unique Aspects of the Clark Class II Prep Design



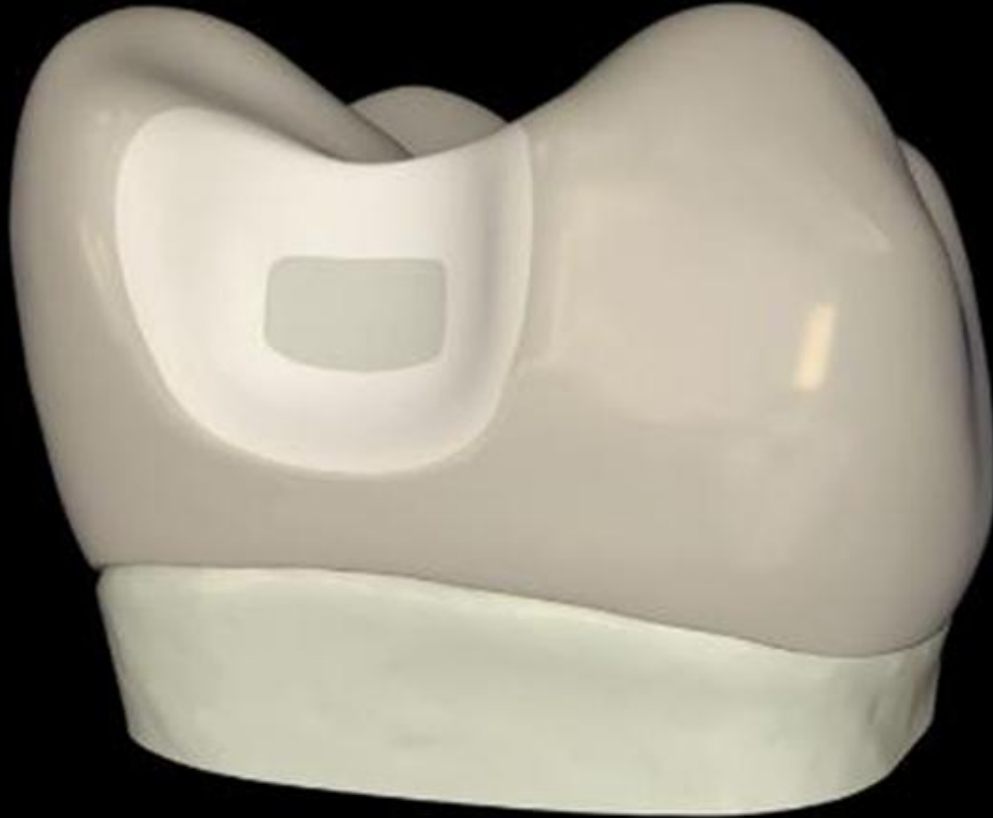- Removal of biofilm
- Rounded internal line angles

Unique Aspects of the Clark Class II Prep Design



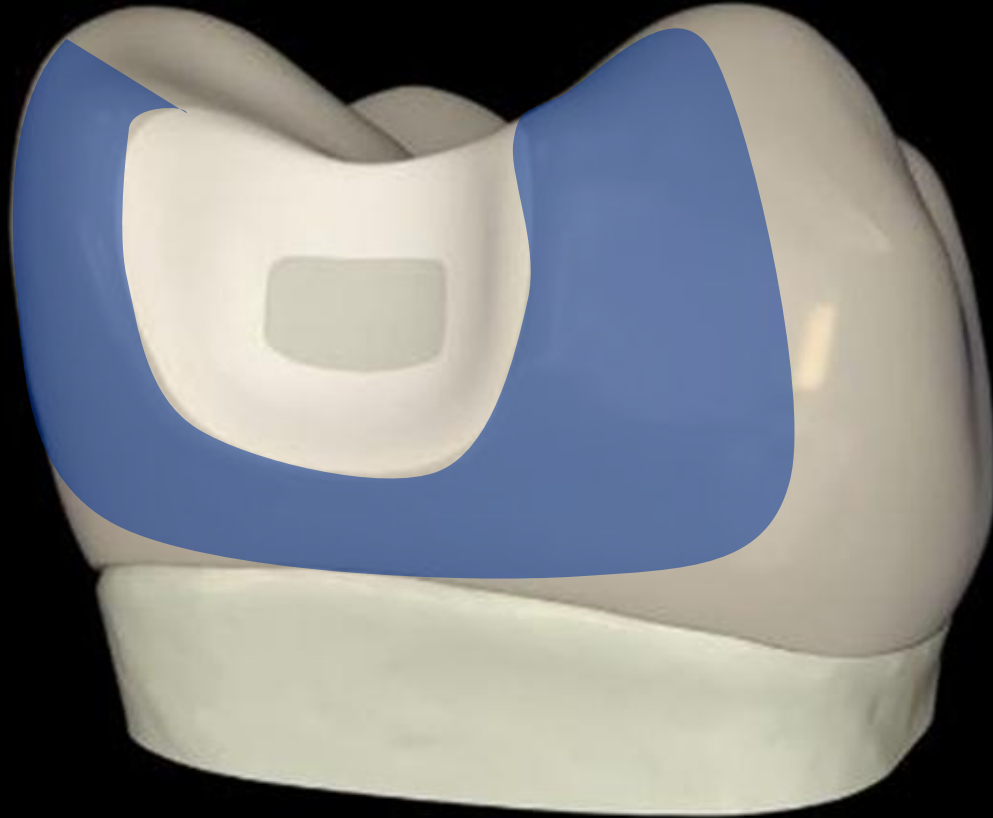- Removal of biofilm
- Rounded internal line angles
- Rounded external line angles via the ***Radius Bevel***

Unique Aspects of the Bioclear Prep Design

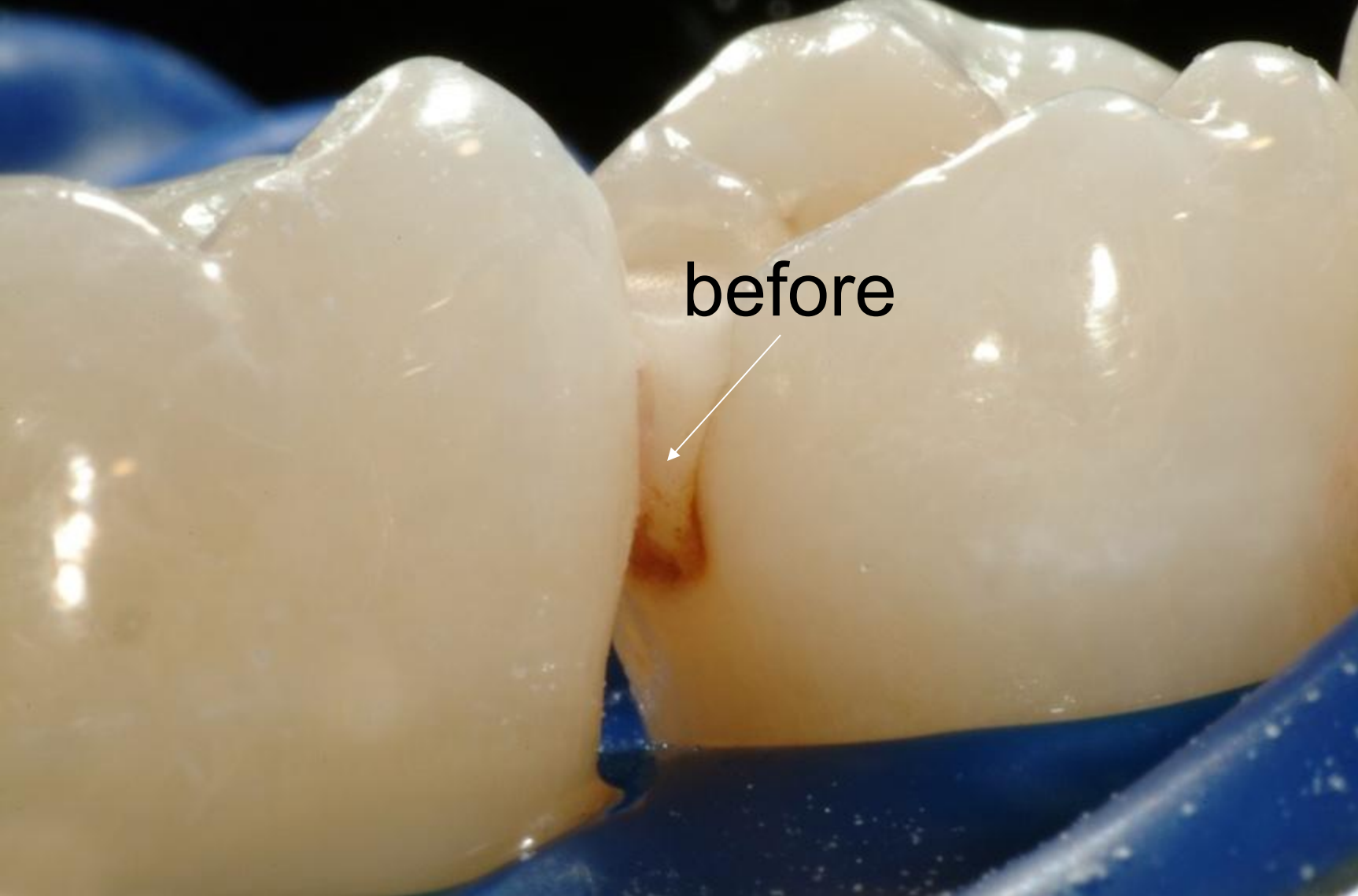

- Removal of biofilm
- Rounded line angles
- Injection mold rather than place incrementally

Unique Aspects of the Clark Class Prep Design

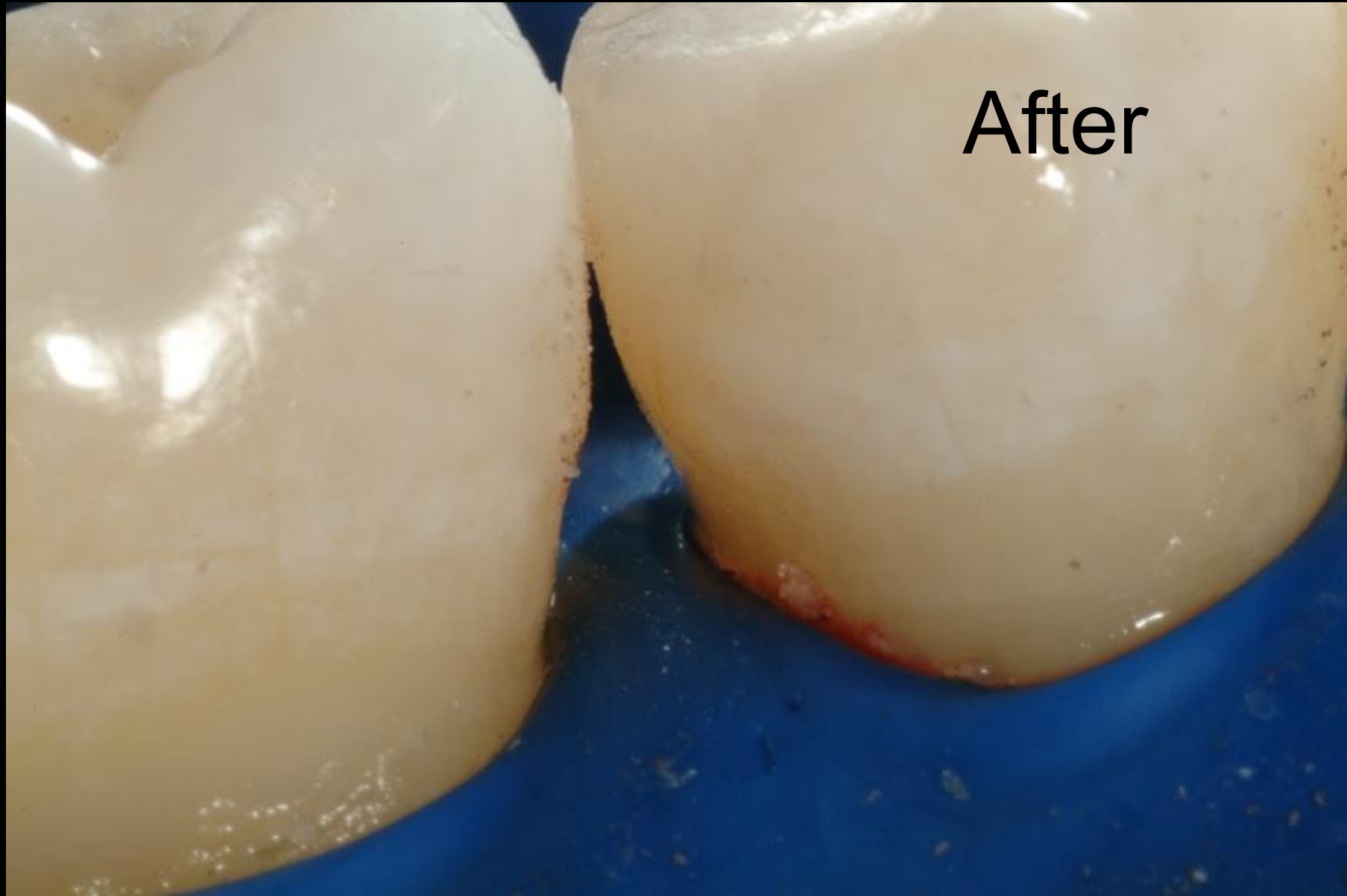

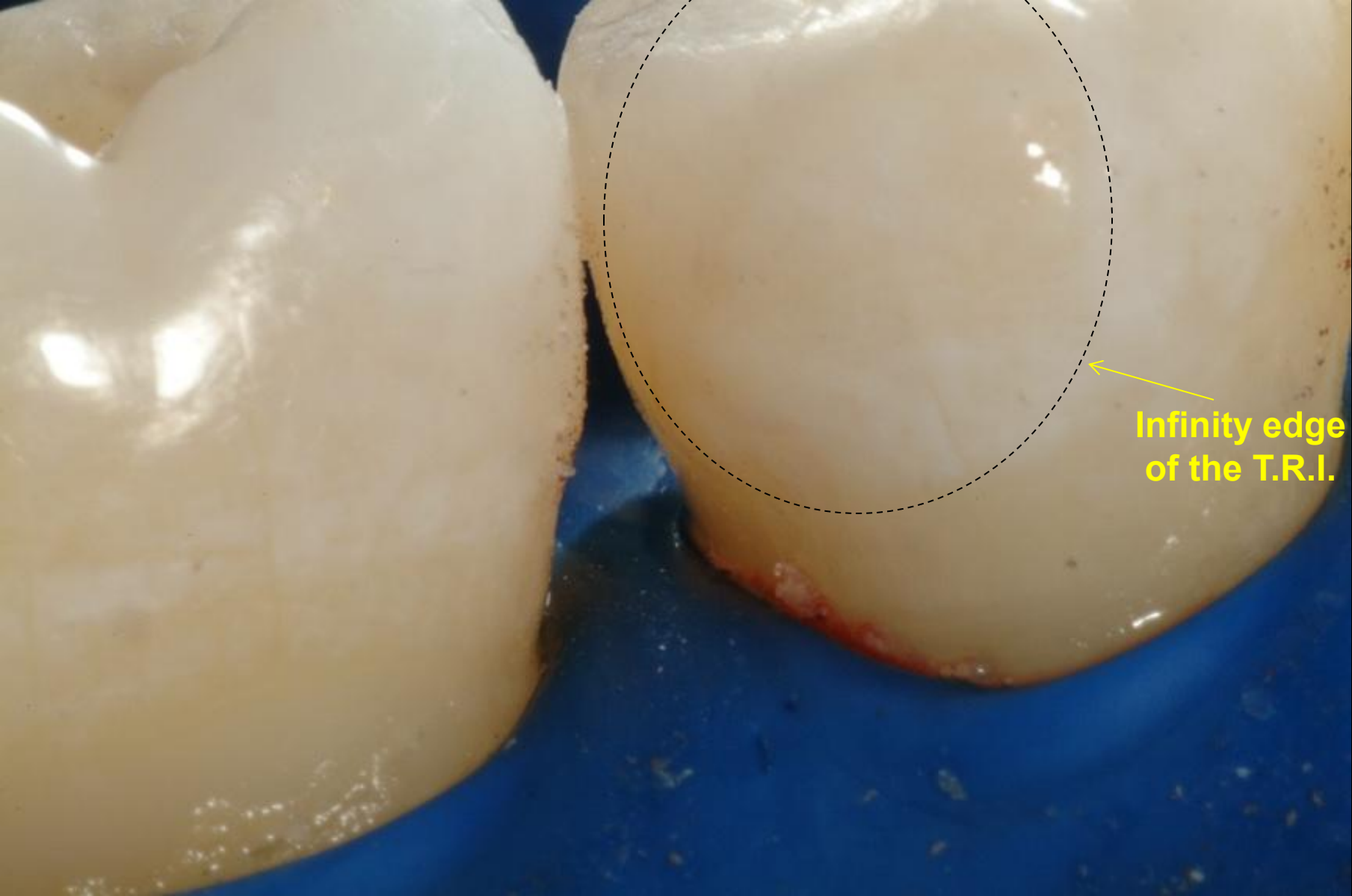- Removal of biofilm
- Rounded line angles
- Rounded external line angles via the *Radius Bevel*
- Infinity Edge margins
 - Maximized enamel rod Engagement *with Large Areas of Additive Dentistry*



before

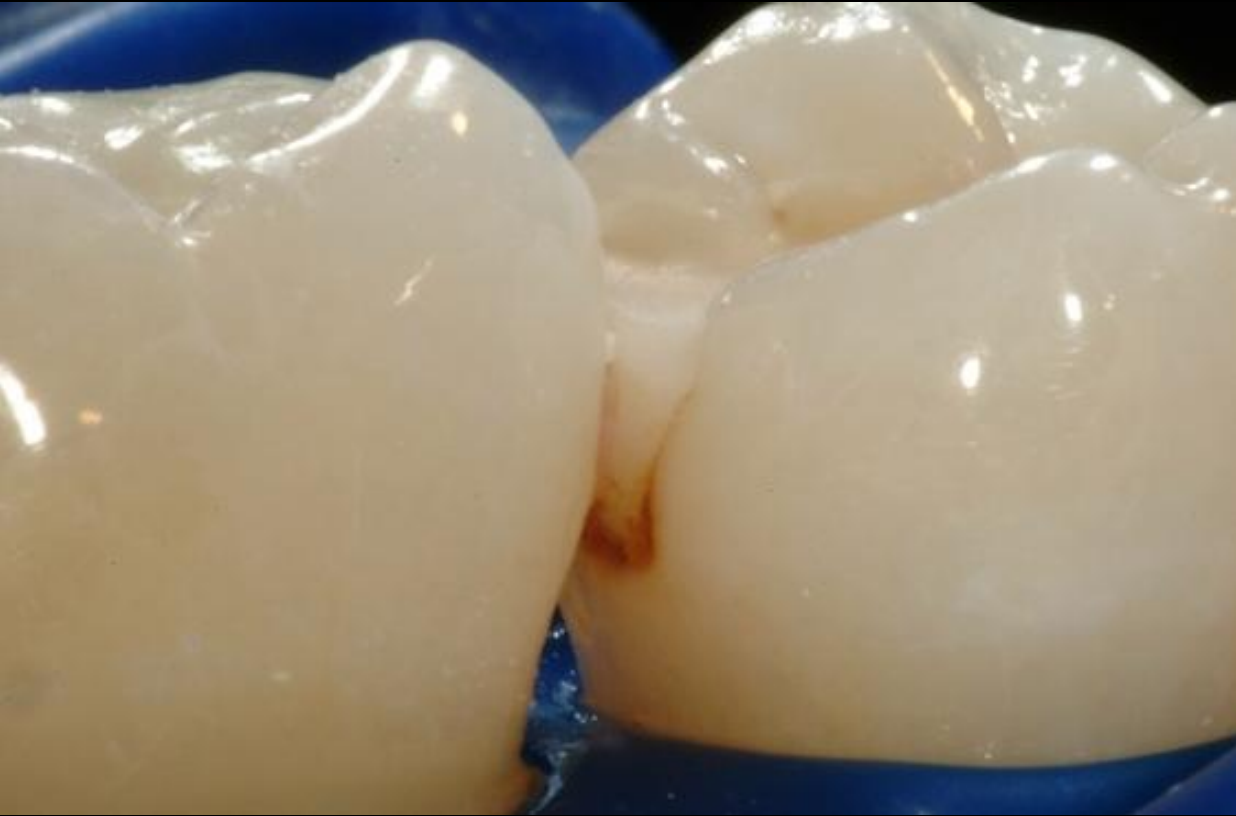The Bioclear method



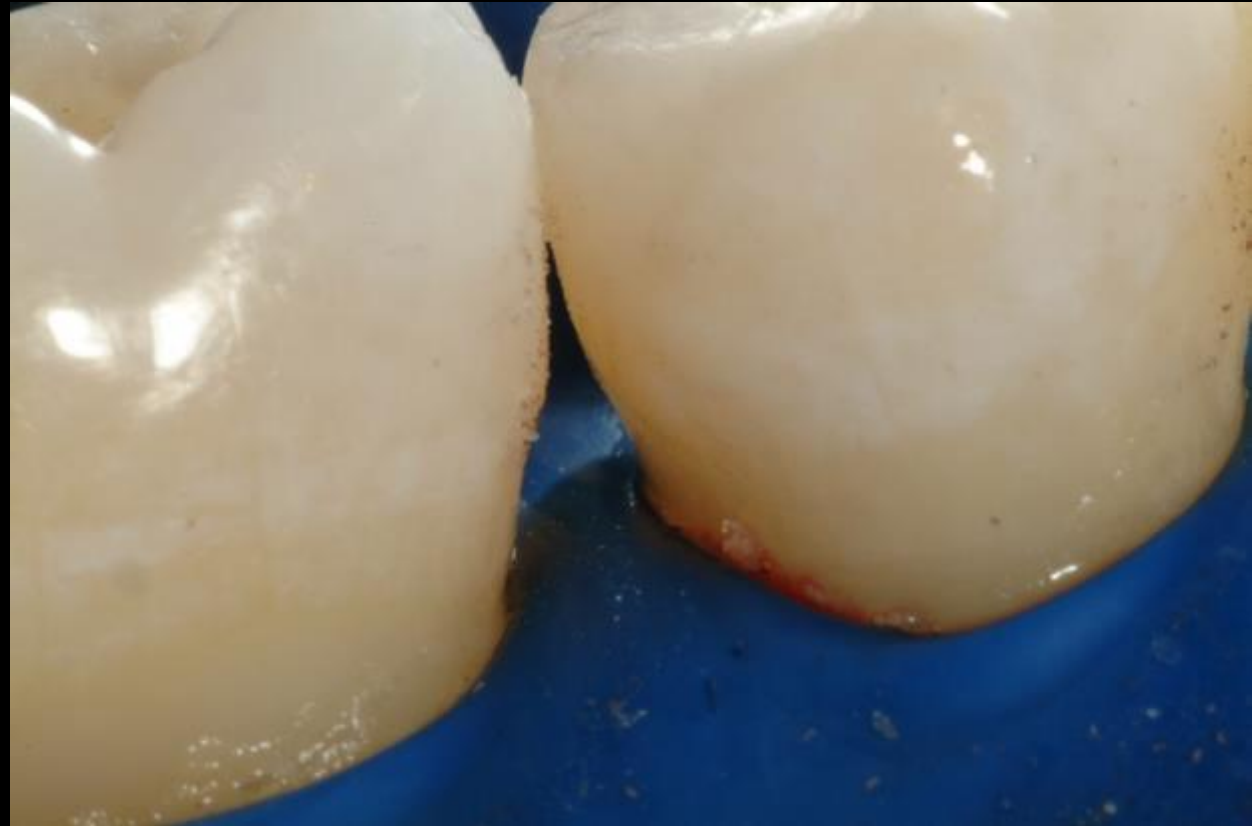

Infinity edge
of the T.R.I.

The Bioclear Injection Molding Approach



Failing composite;
traditional preparation



Re-restored using the
Bioclear approach



Step by Step Guide for Injection Molded Class II

Studies Supporting the Bioclear Method

Complete

- Comparing Conventional to Saucer-Shaped Cavity Designs

Dr. Alex Fok, BEng, PhD, MSc

Dr. Hooi Pin Chew, BDS, PhD, FDSRCS

MN Dental Research Center for Biomaterials and Biomechanics

- Comparison of Class II Adaptation and Placement Times

Dr. Richard Price, BDS, DDS, MS, FDS RCS, FRCD(C), PhD

Dept. of Clinical Dental Sciences & Biomedical Engineering Dalhousie University

- Effect of Preheating/Fatiguing/Thermocycling on Mechanical Properties

Taiseer A. Sulaiman, DDS, PhD



Assistant professor, Division Director of Operative Dentistry and Biomaterials, UNC School of Dentistry

- 3M Extraction and Pulp Temperature Testing

Brad Bagley, PhD, DABT Advanced Toxicology Specialist

- 3M Material Property Testing Including Injection Molding

Timothy D. Dunbar, Ph.D. Advanced Product Development Specialist



In Process

- Biofilm Adhesion Study

Sabrina F. Sochacki, DDS, MS, PhD

Indiana University School of Dentistry

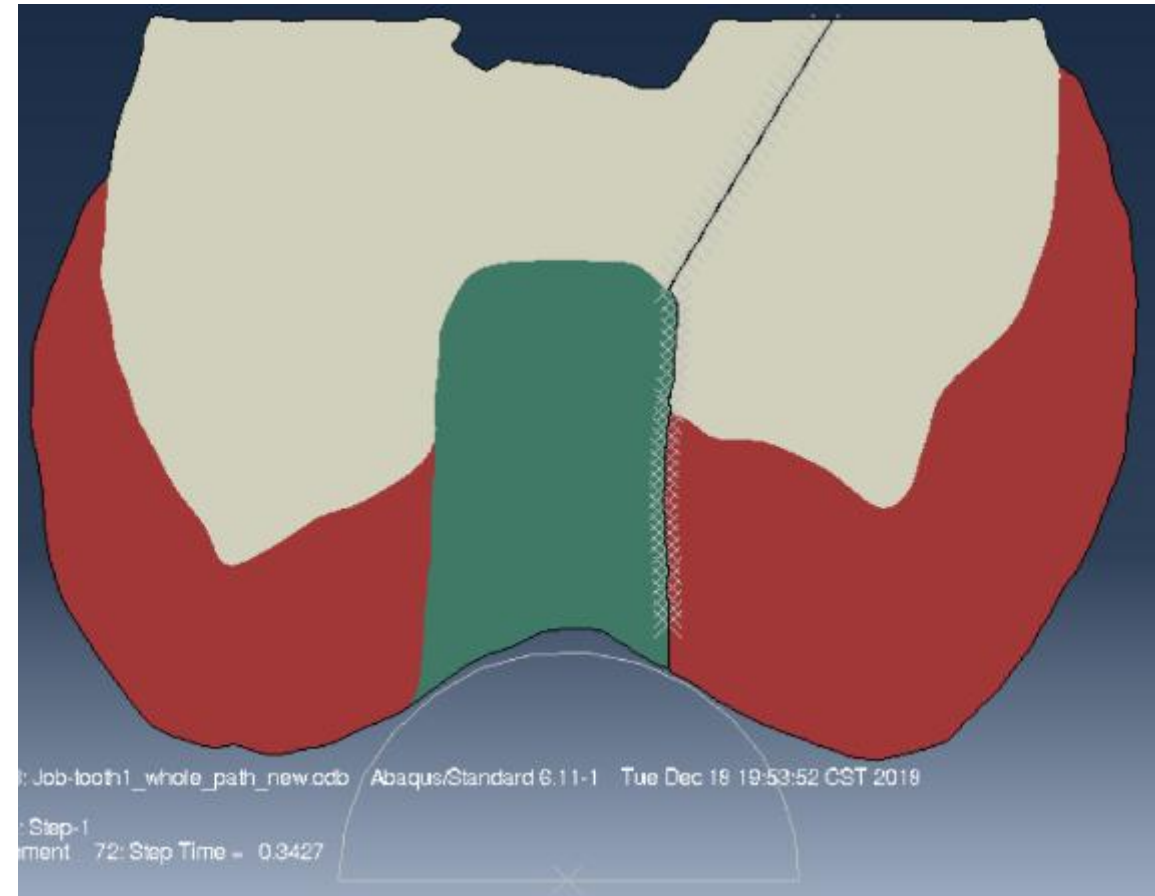
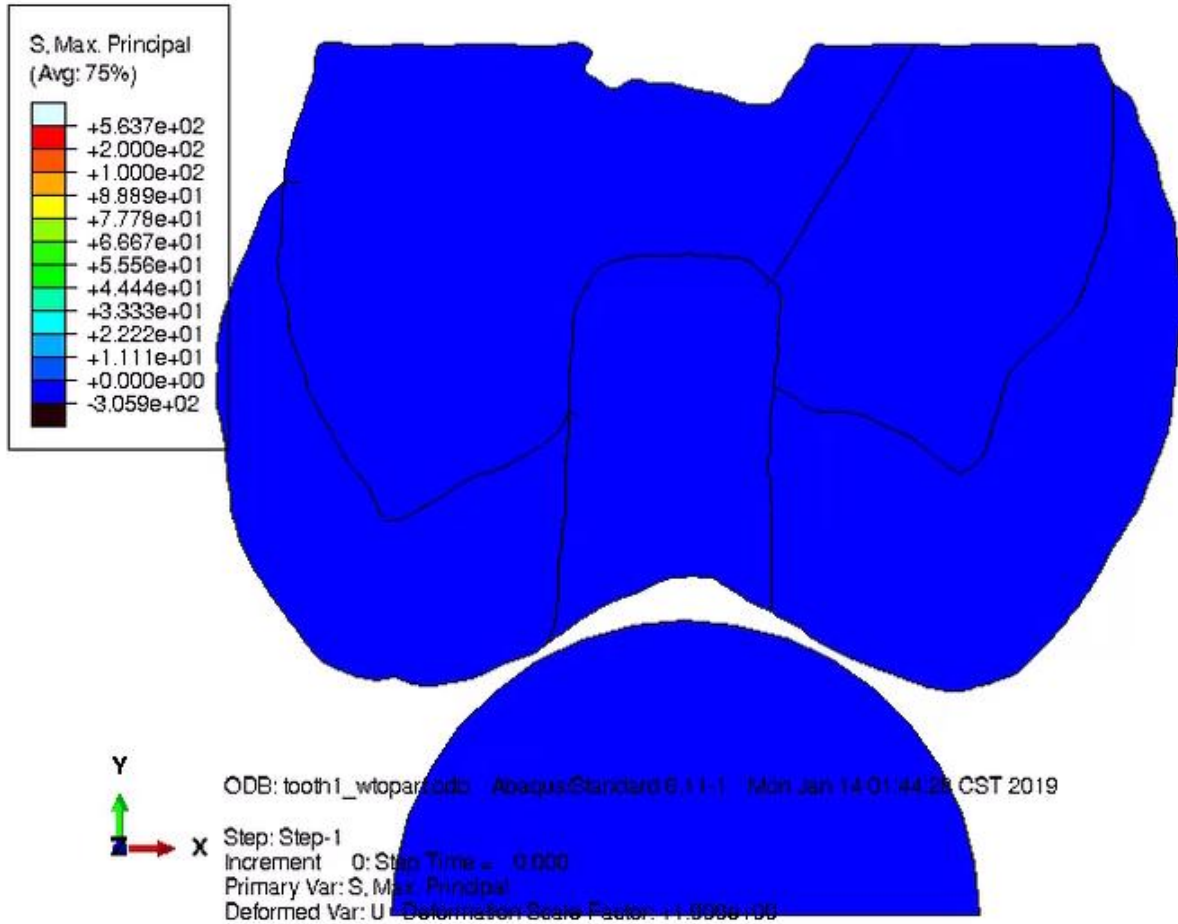
Fracture Simulation of Class-I Restorations



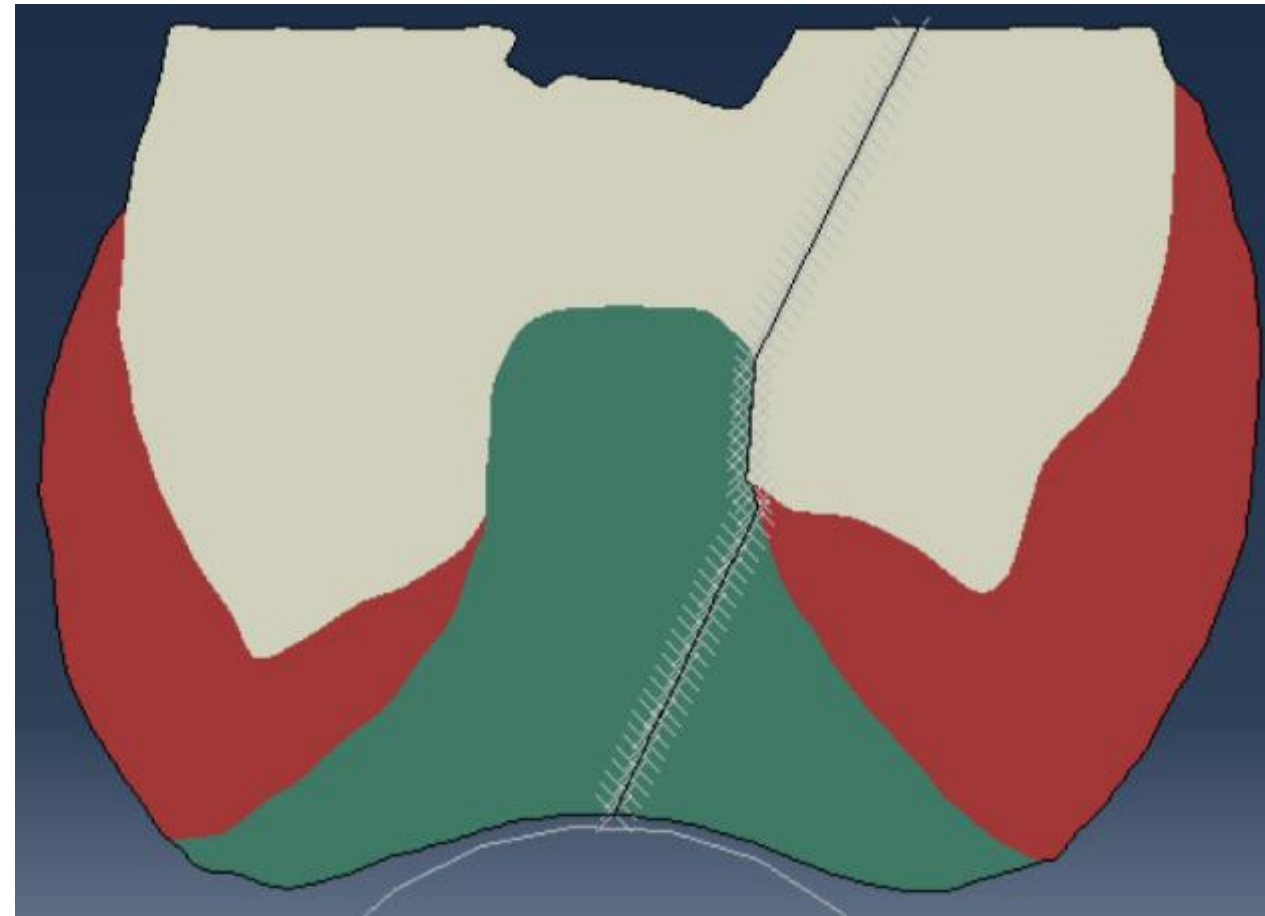
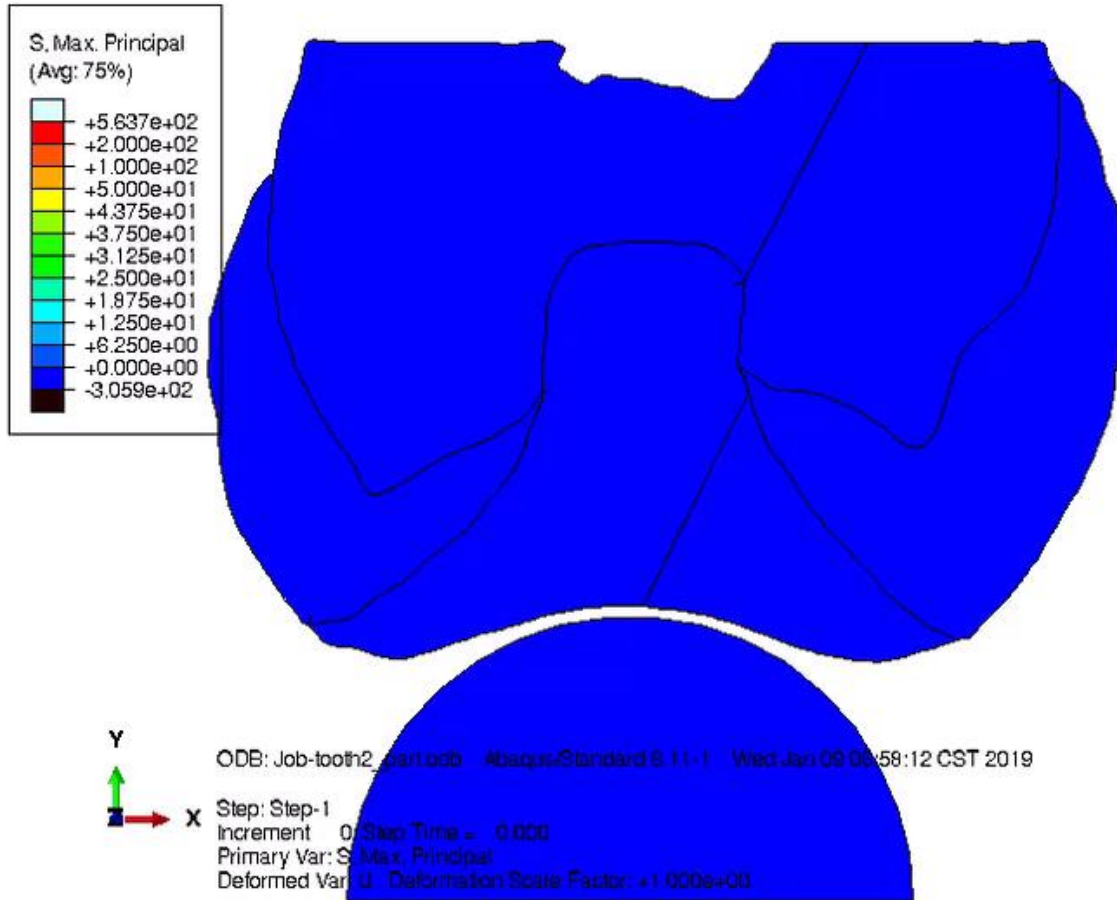
Prepared by: Ning Ye
Date: 1/11/2019

Reference no. MDRRCBB-NY-JAN11-2019

Traditional Class I Prep



Calla Lily Class I Prep



$$A_1 N_1^B = A_2 N_2^B \frac{N_1}{N_2} = \left(\frac{A_2}{A_1} \right)^{1/B}$$

...if Restoration 1 has a fast fracture strength that is **10% higher than Restoration 2**, then its fatigue life is roughly 3 times as long.

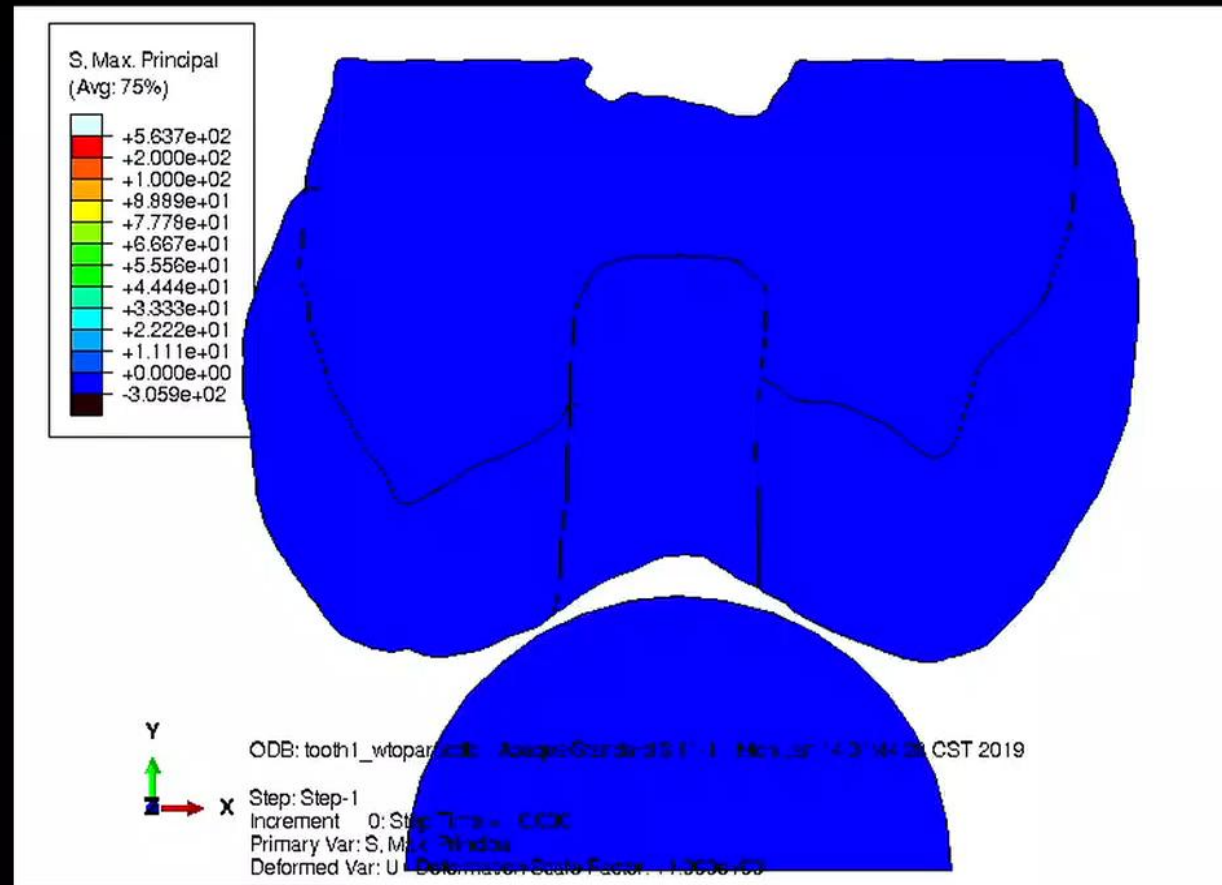
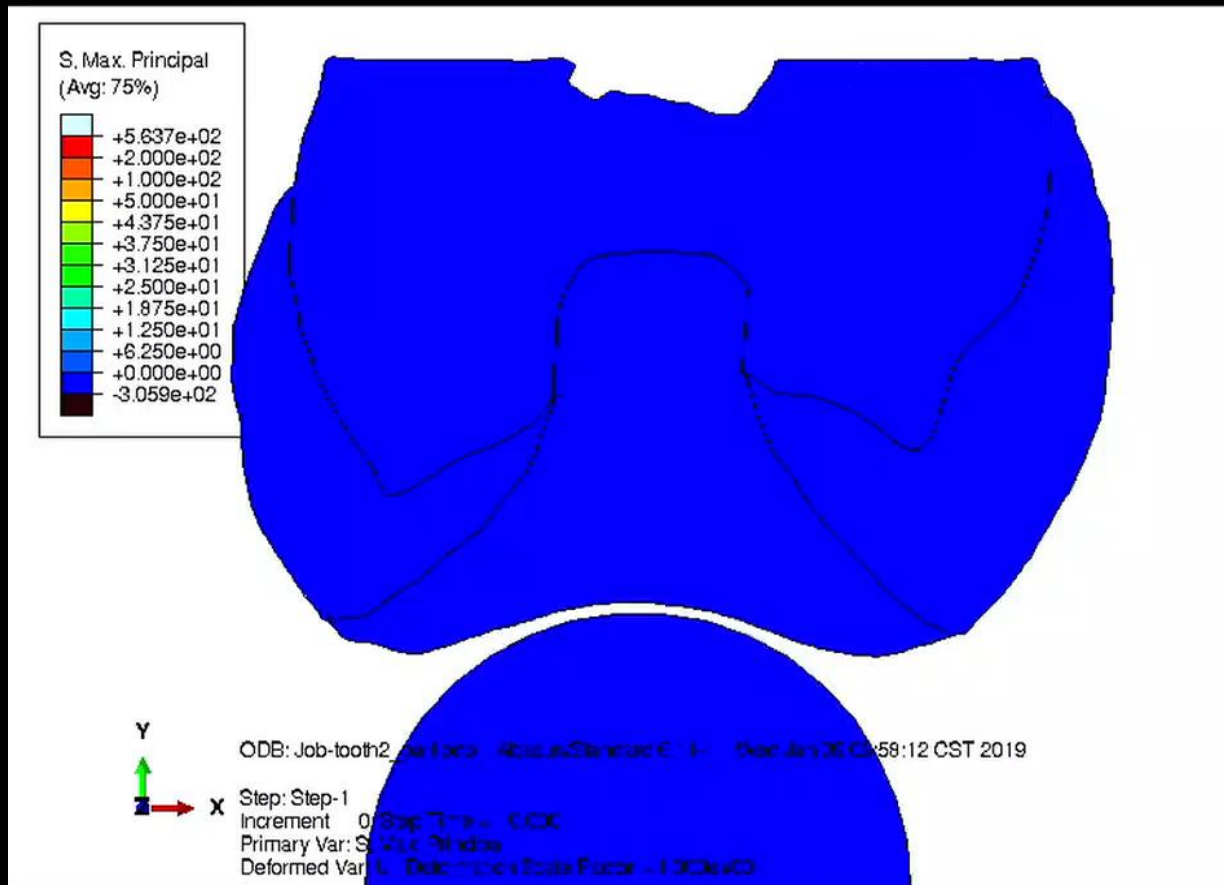
If the difference in fast fracture strength is 20%, then Restoration 1 will last roughly 8 times as long, etc.

Alex Fok

Minnesota Dental Research Center
for Biomaterials and Biomechanics

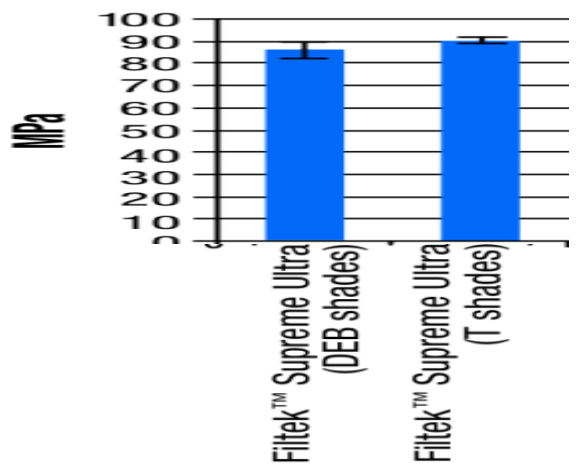
Calla Lily: moderate occlusal caries or re-treatment of Traditional prep

Traditional Class I filled with composite resin

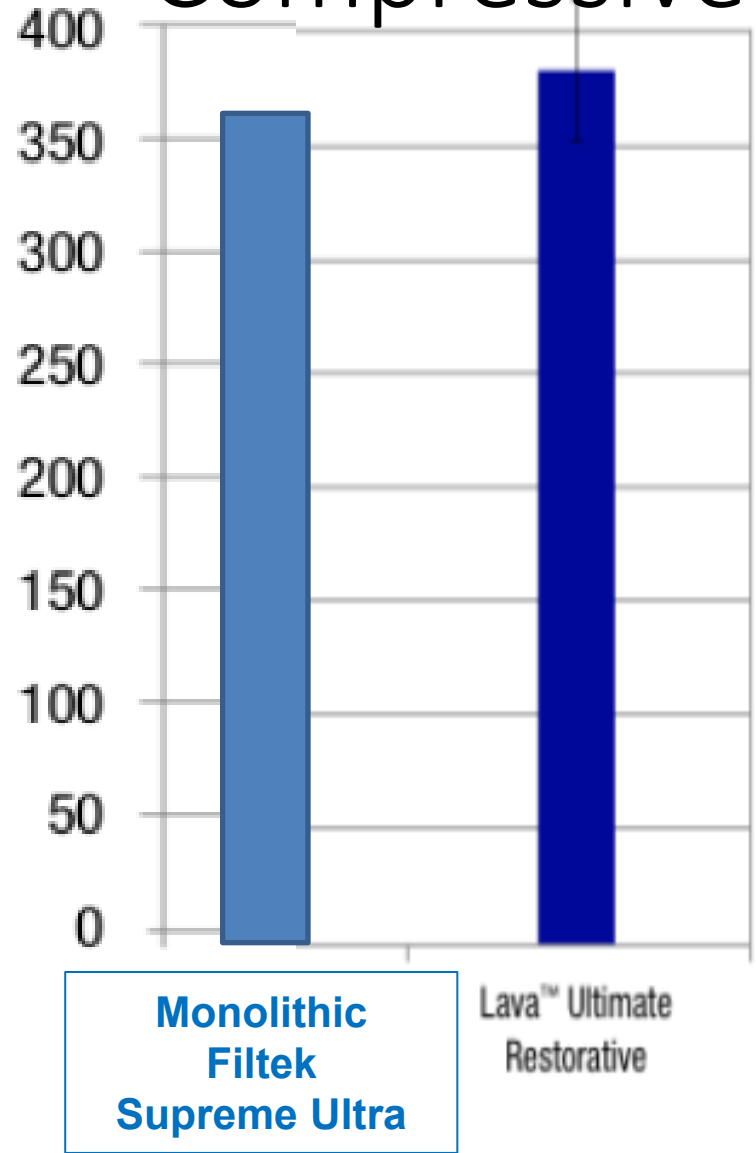


The compressive strength of composite is about 4x the diametral tensile strength.

Tensile



Compressive

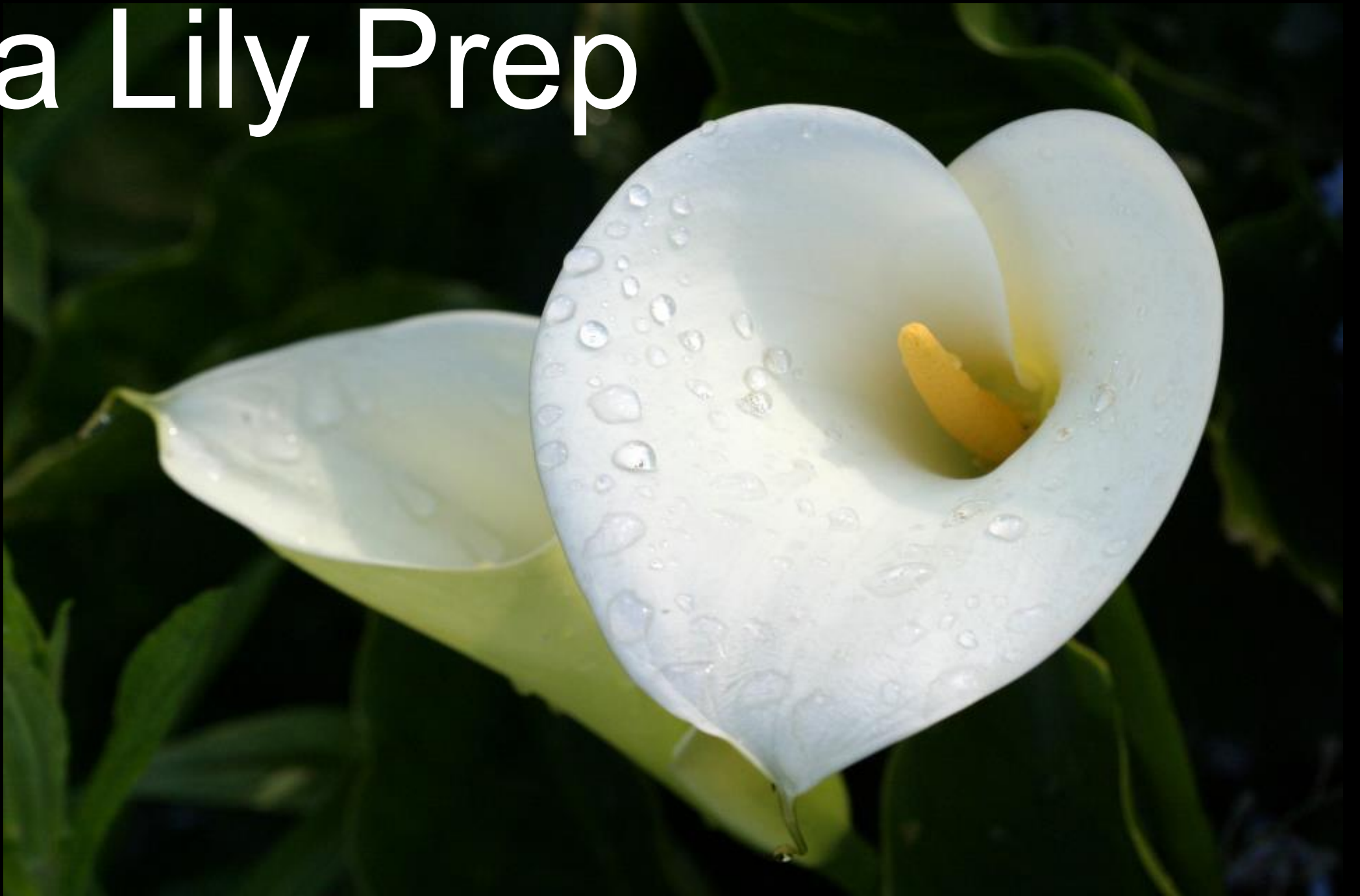

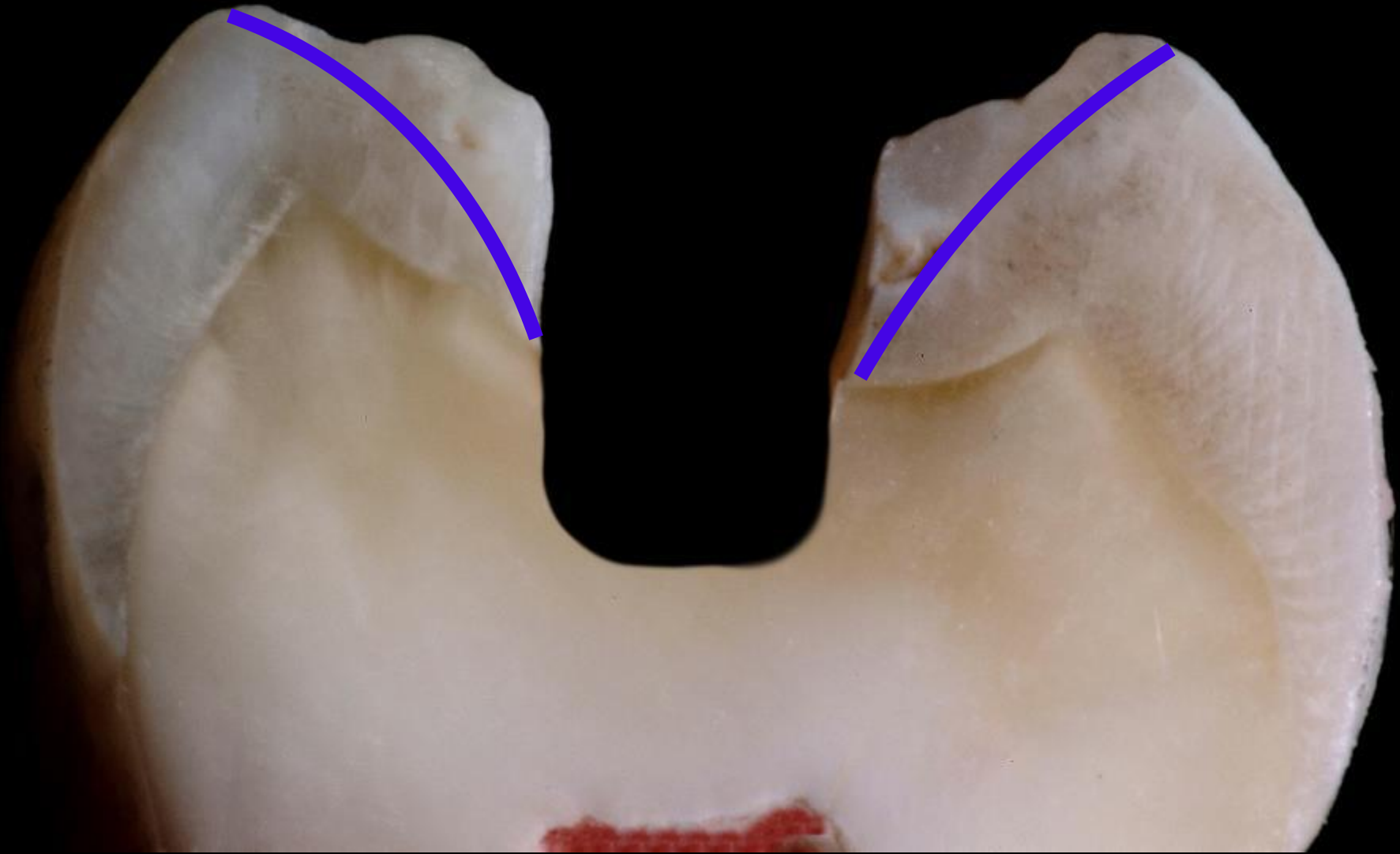Bioclear Learning Center Guidelines:

- In compression, resin over enamel has no minimum thickness requirement
- In compression, resin over dentin needs at least 2mm thickness
- For Incisal Edges and cusp tips we need 2 mm (occluso gingivally and buccal-lingual)
- All monolithic-no seams or grooves

Calla Lily Prep

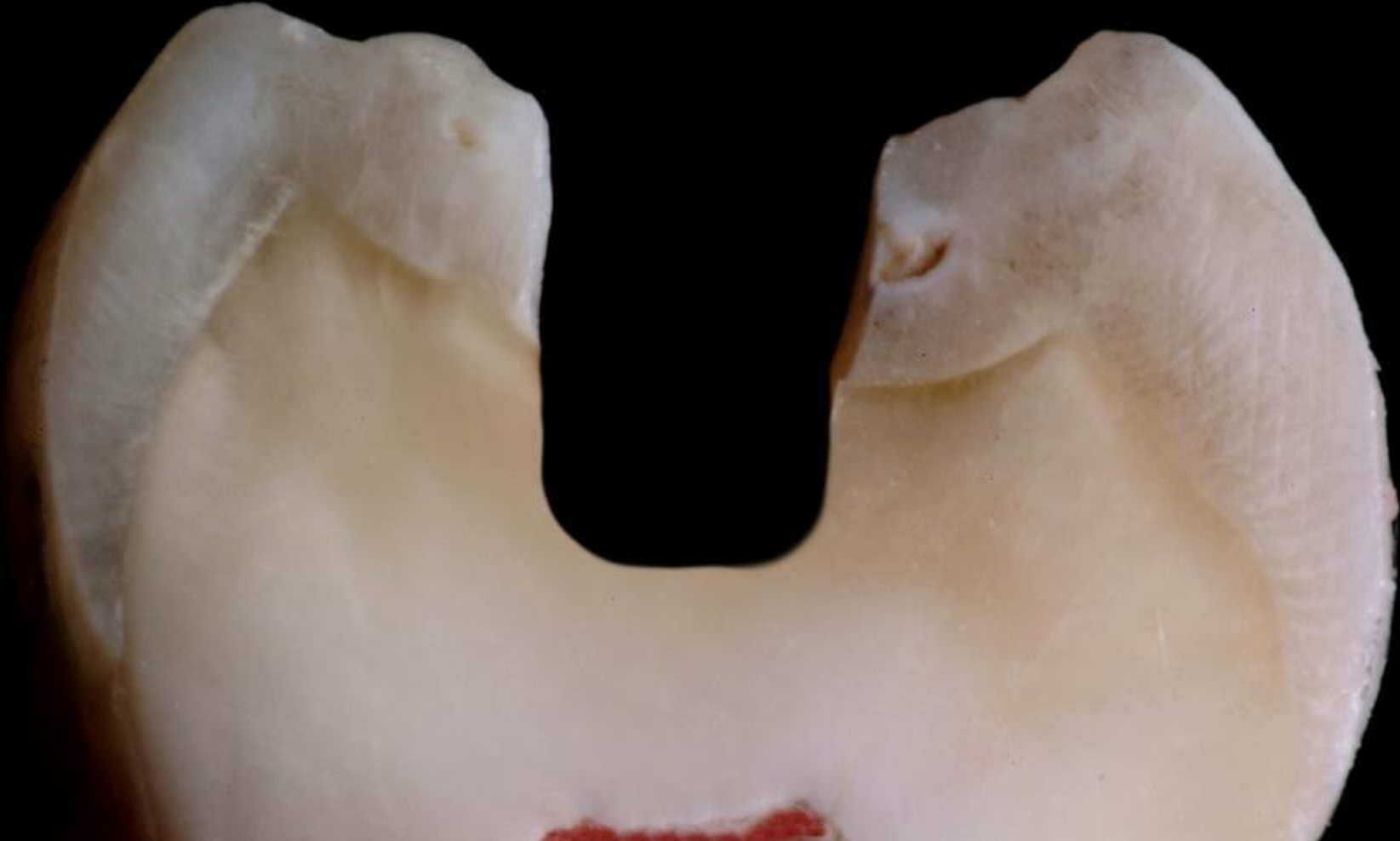
Calla Lily Prep






Enamel

Dentin



Enamel

Dentin

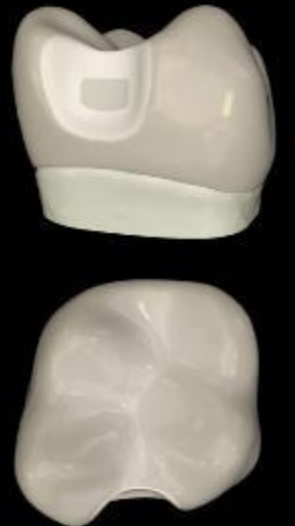


Do you trust enamel bonding or **dentin bonding**?

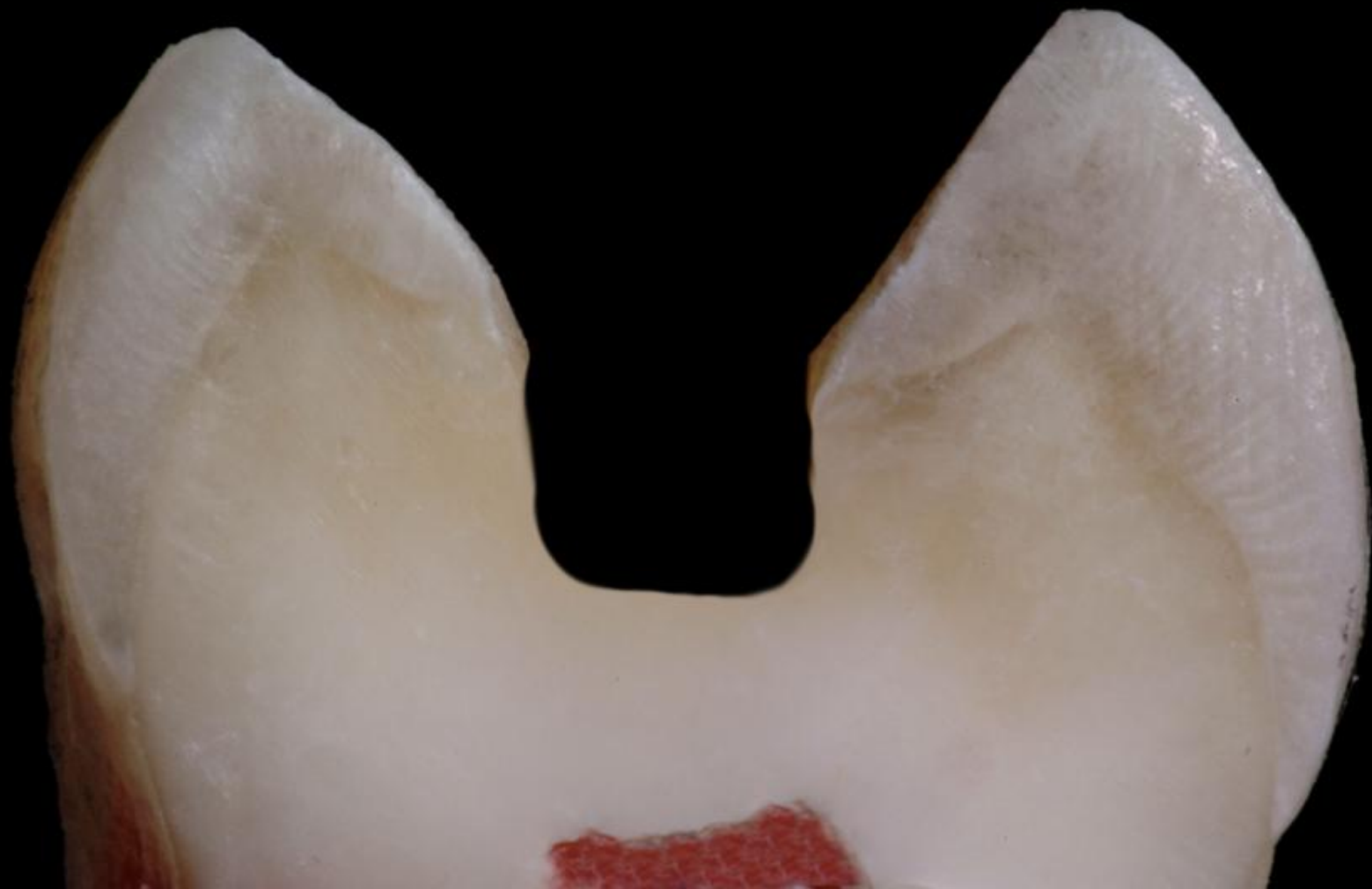Enamel

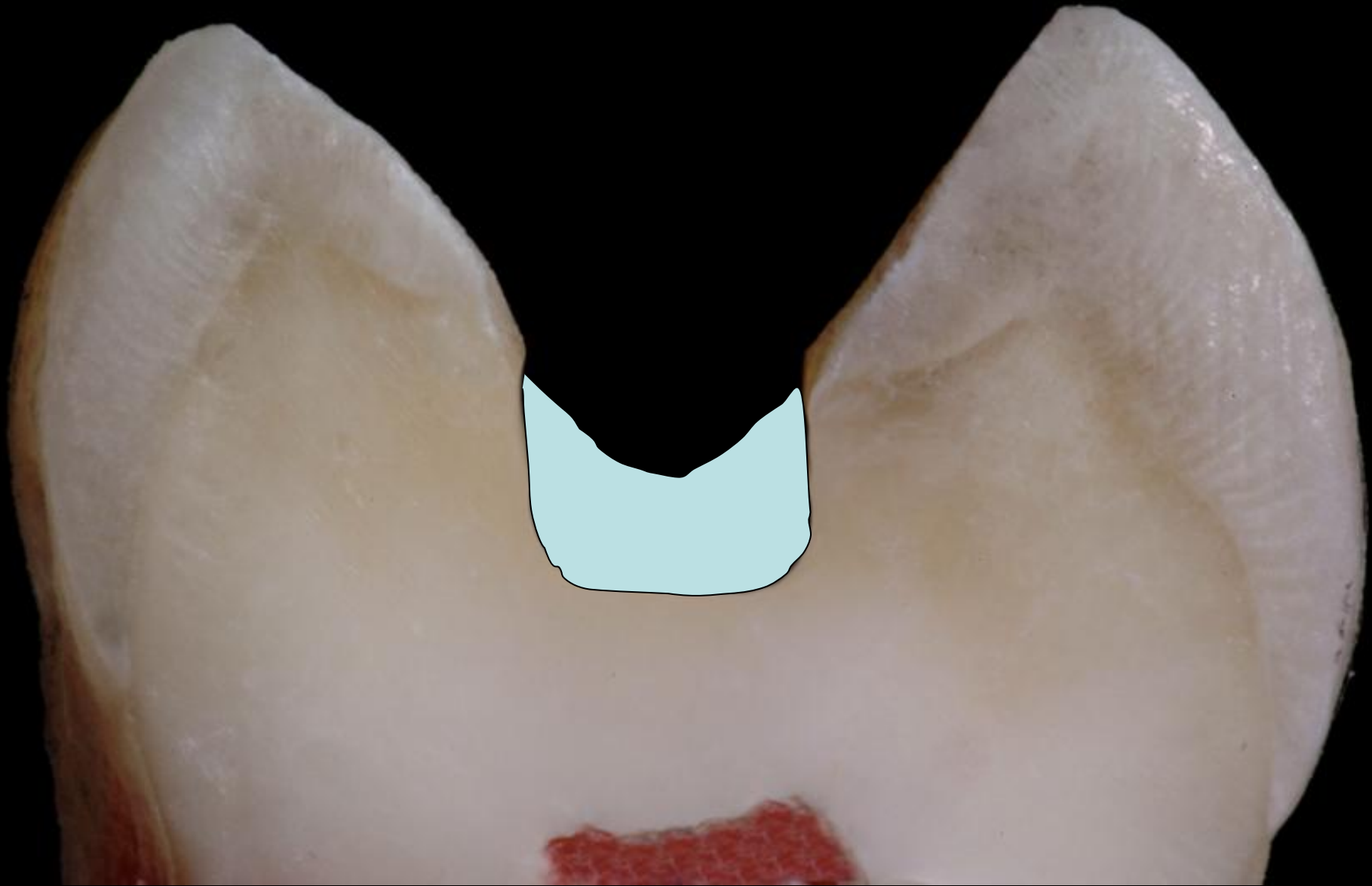


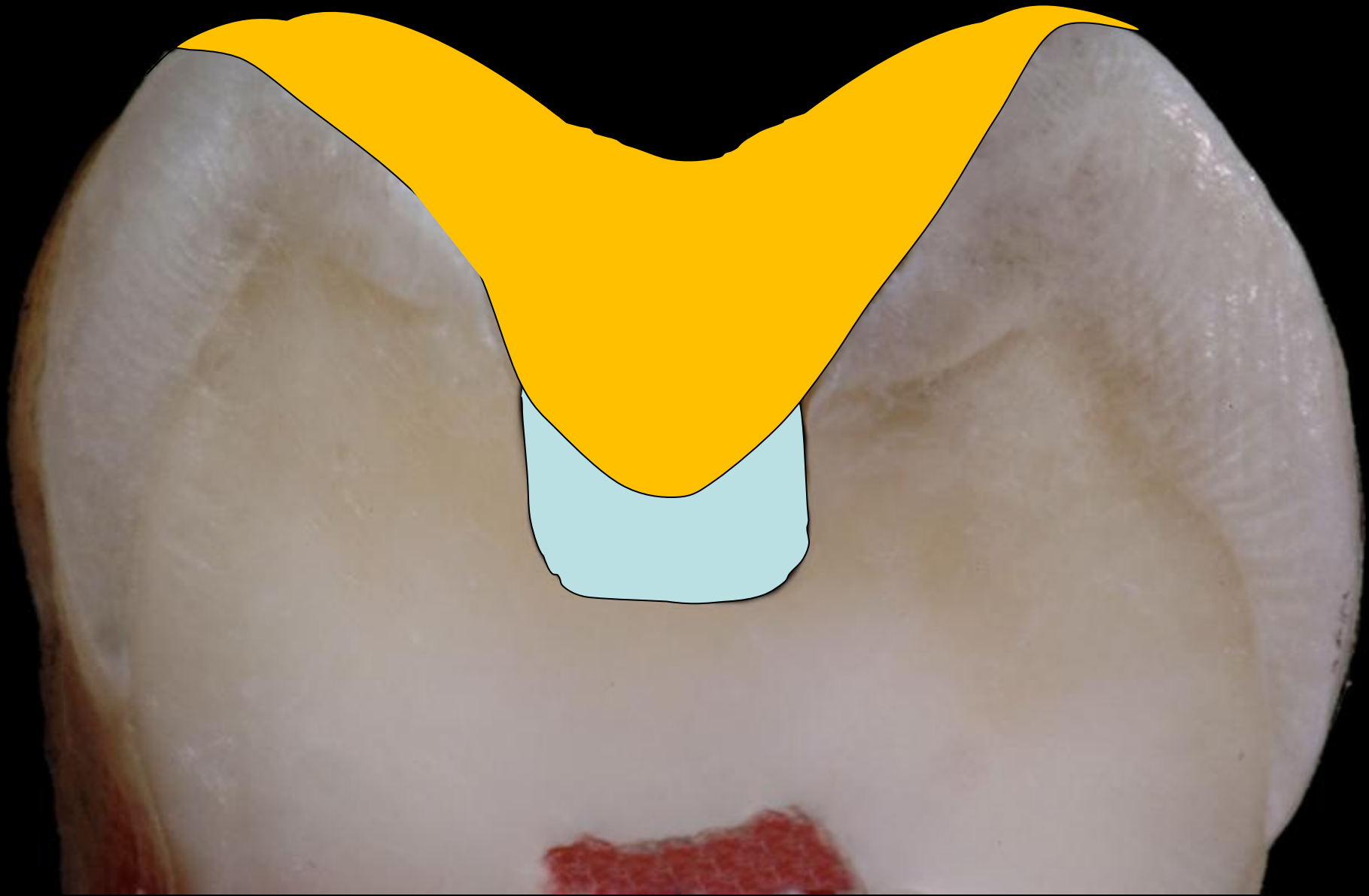Enamel

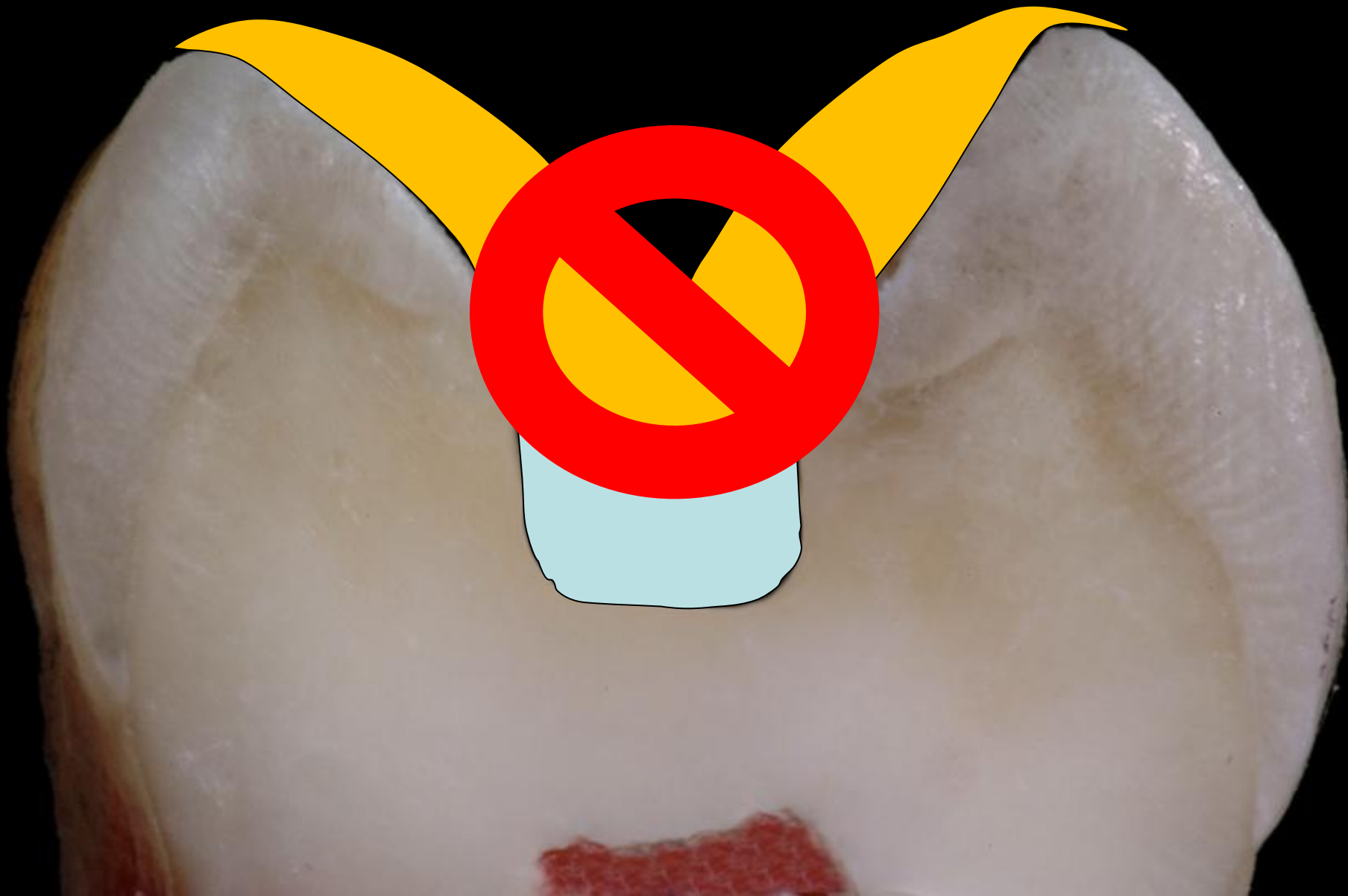



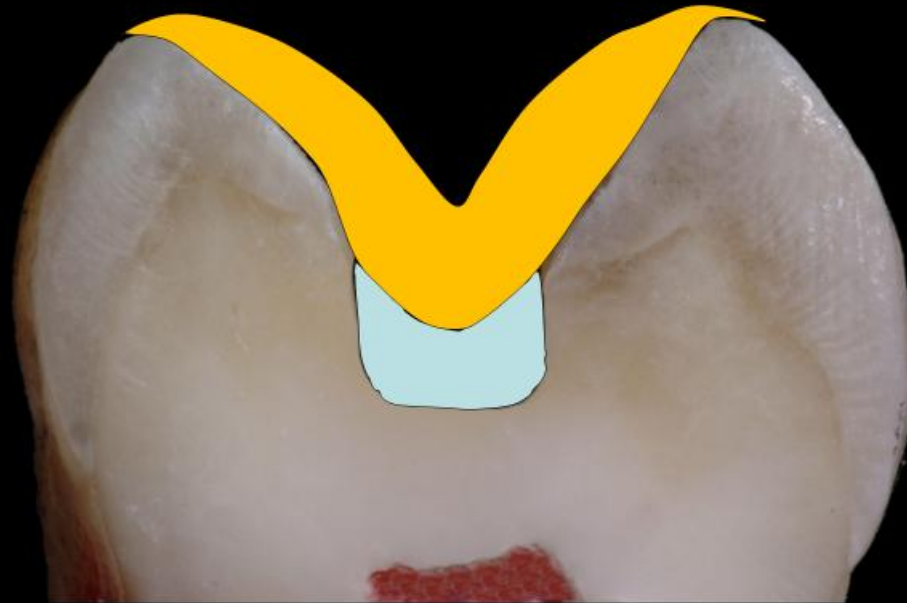





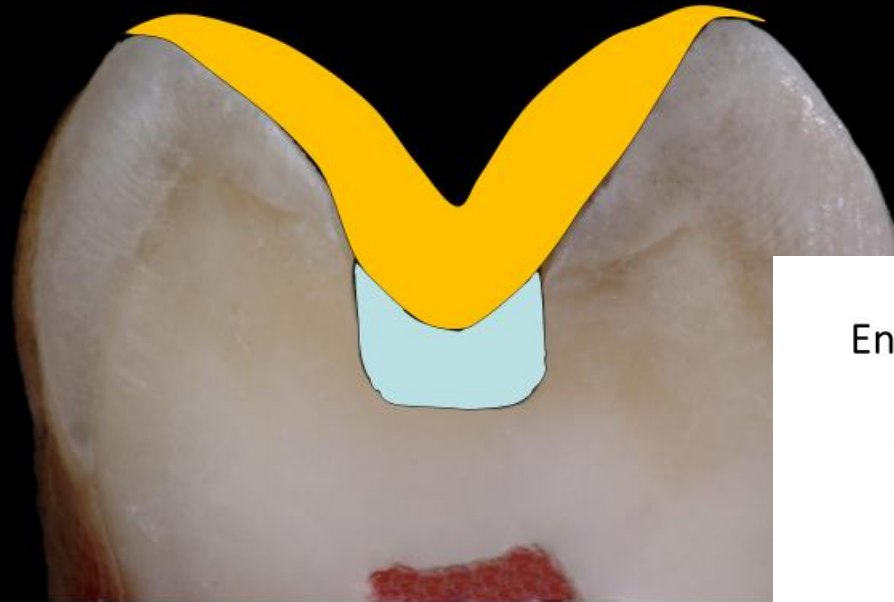


At what point will this tooth go from compression into tension, and vice versa?



Shape Optimization:
As operators we can *flatten cusps* or *fill in the fossae* (or both).



Enamel vs. resin composite

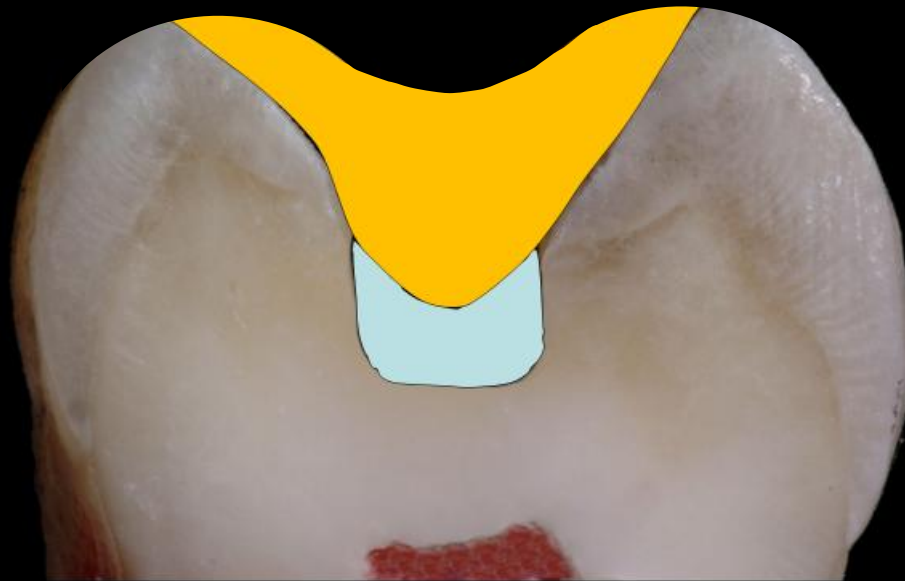


Enamel rods?

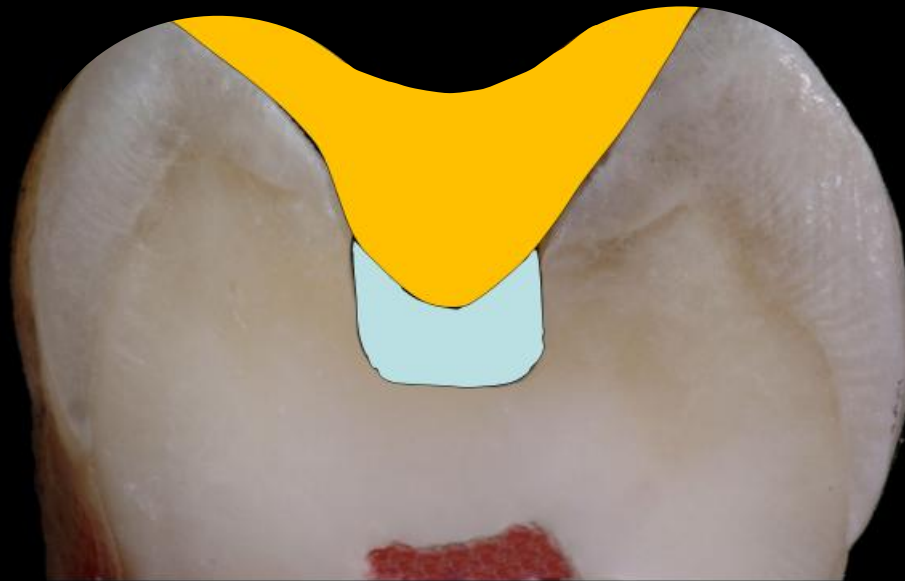
Resin composite



Shape Optimization:
Operators we can *flatten cusps* or *fill in the fossae* (or both).

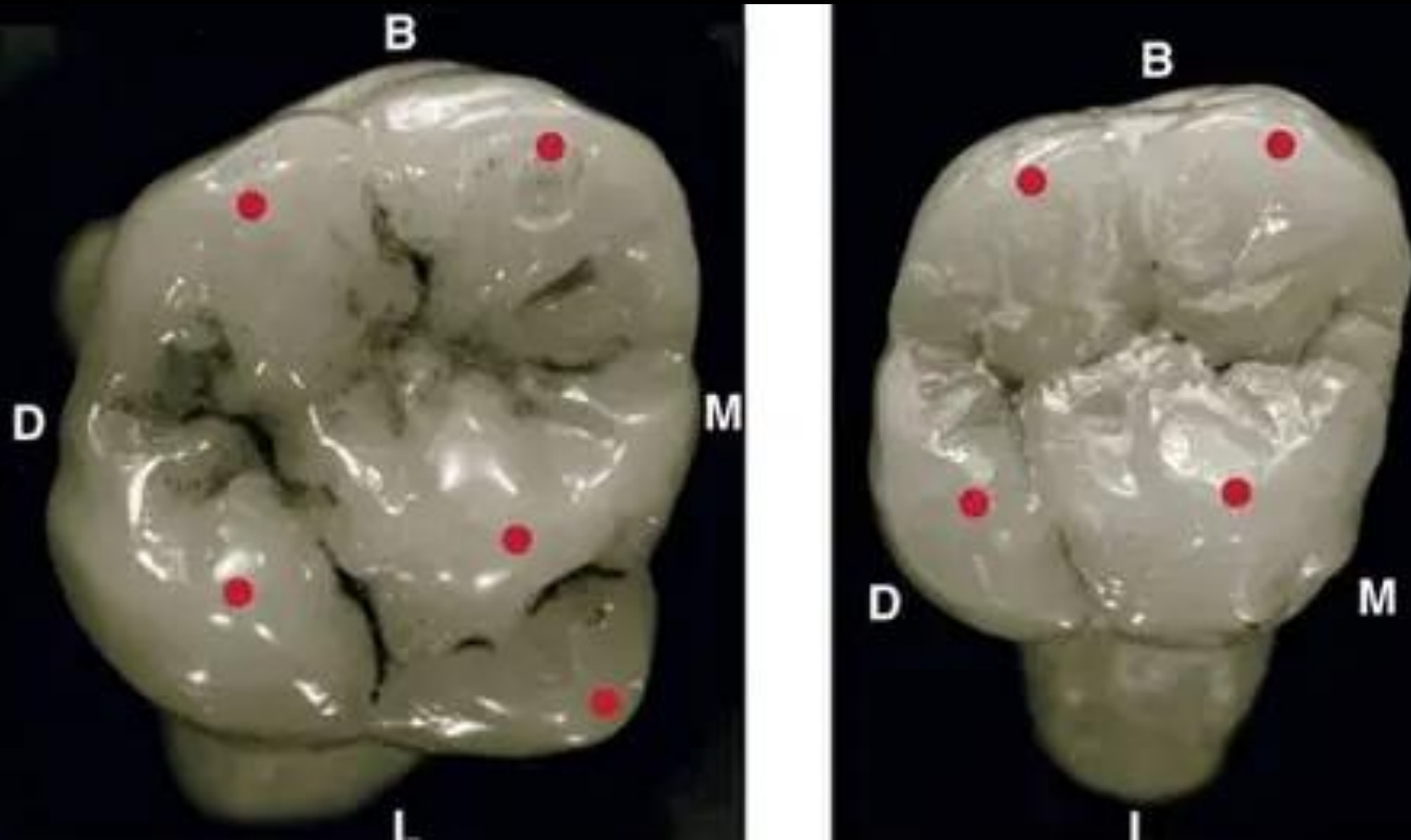


Shape Optimization:
Build a bridge from buccal to lingual

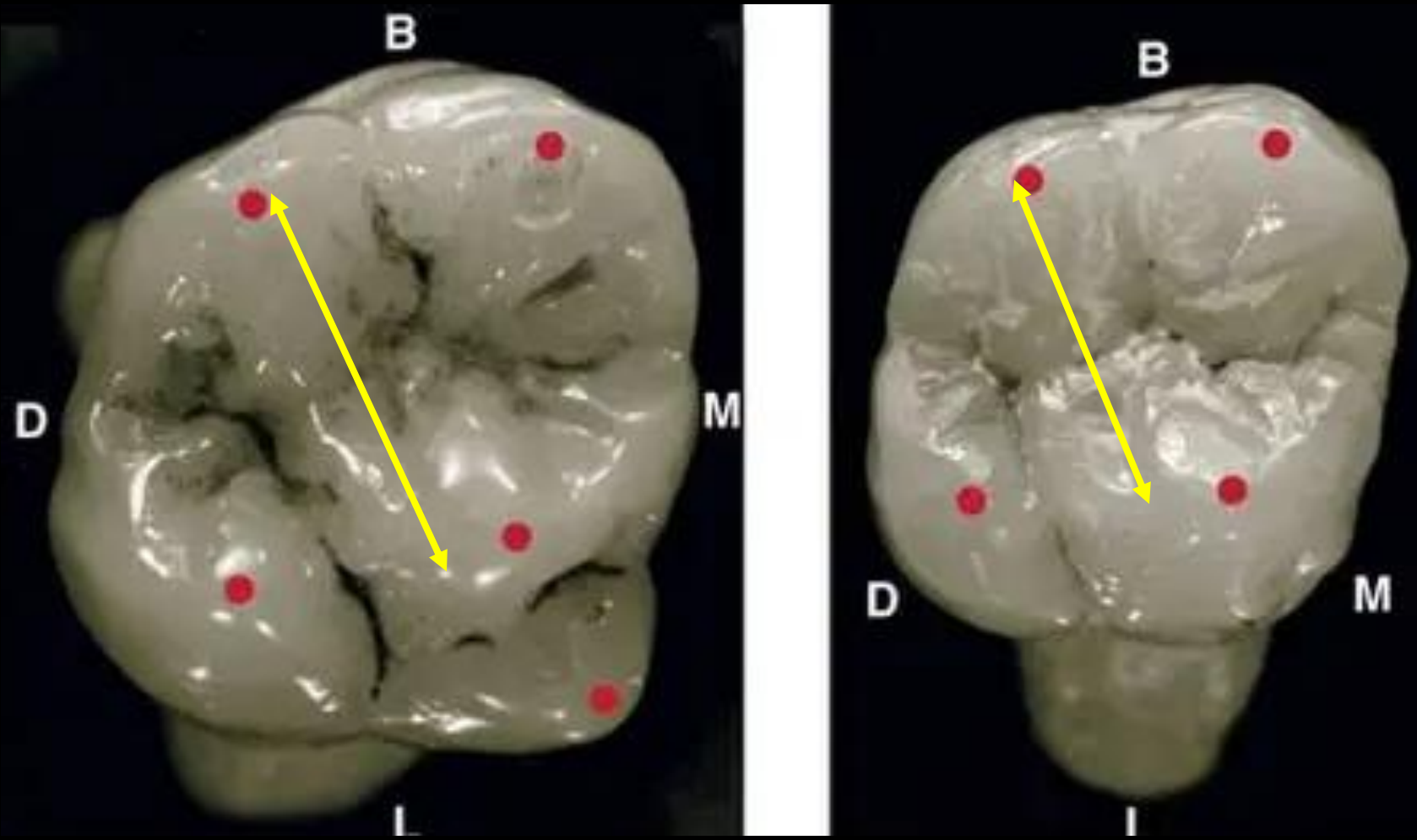


Is there anything illegal or immoral
about the anatomy of a maxillary
first molar?

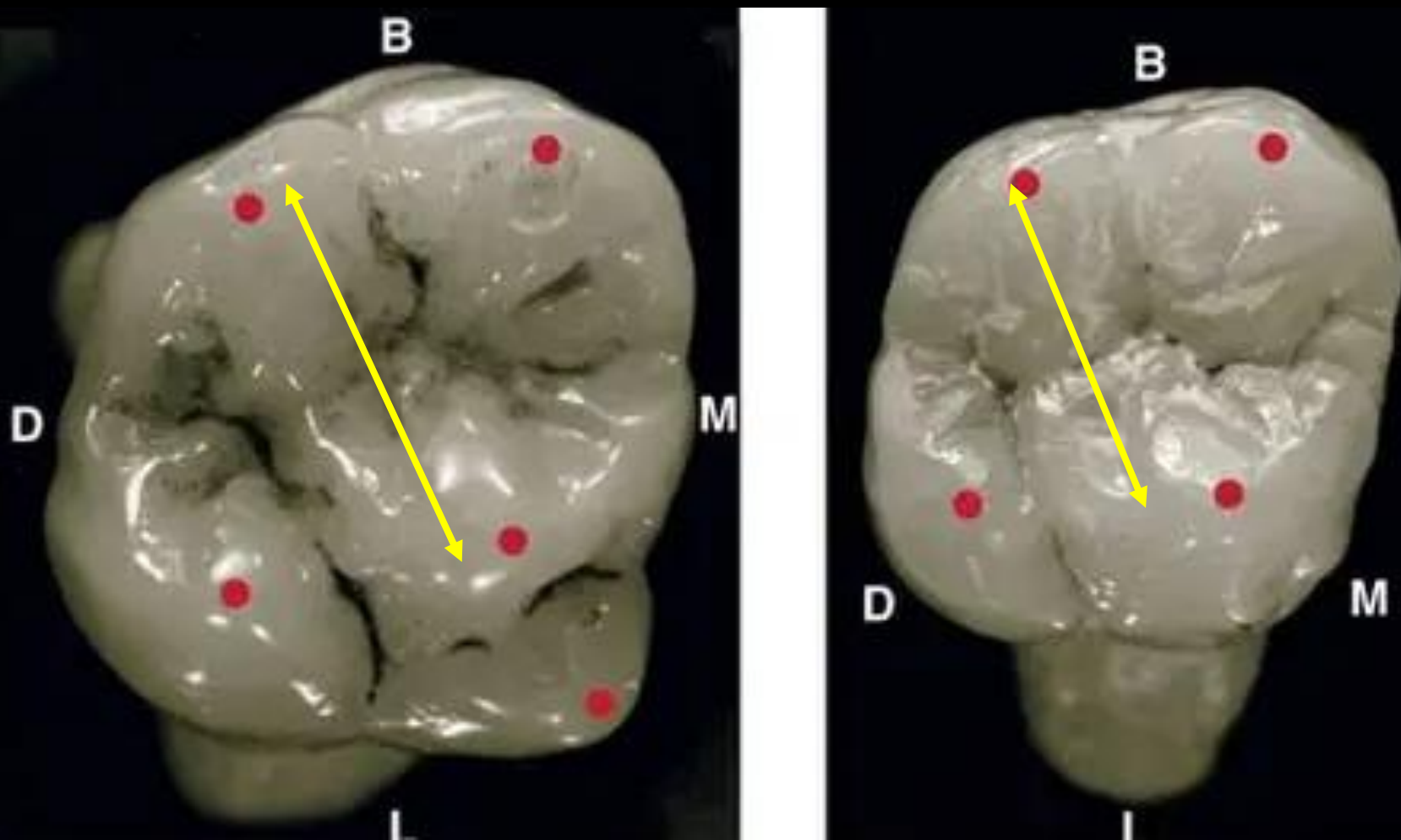
What unique trait does a maxillary first molar possess that protects it from cracking?



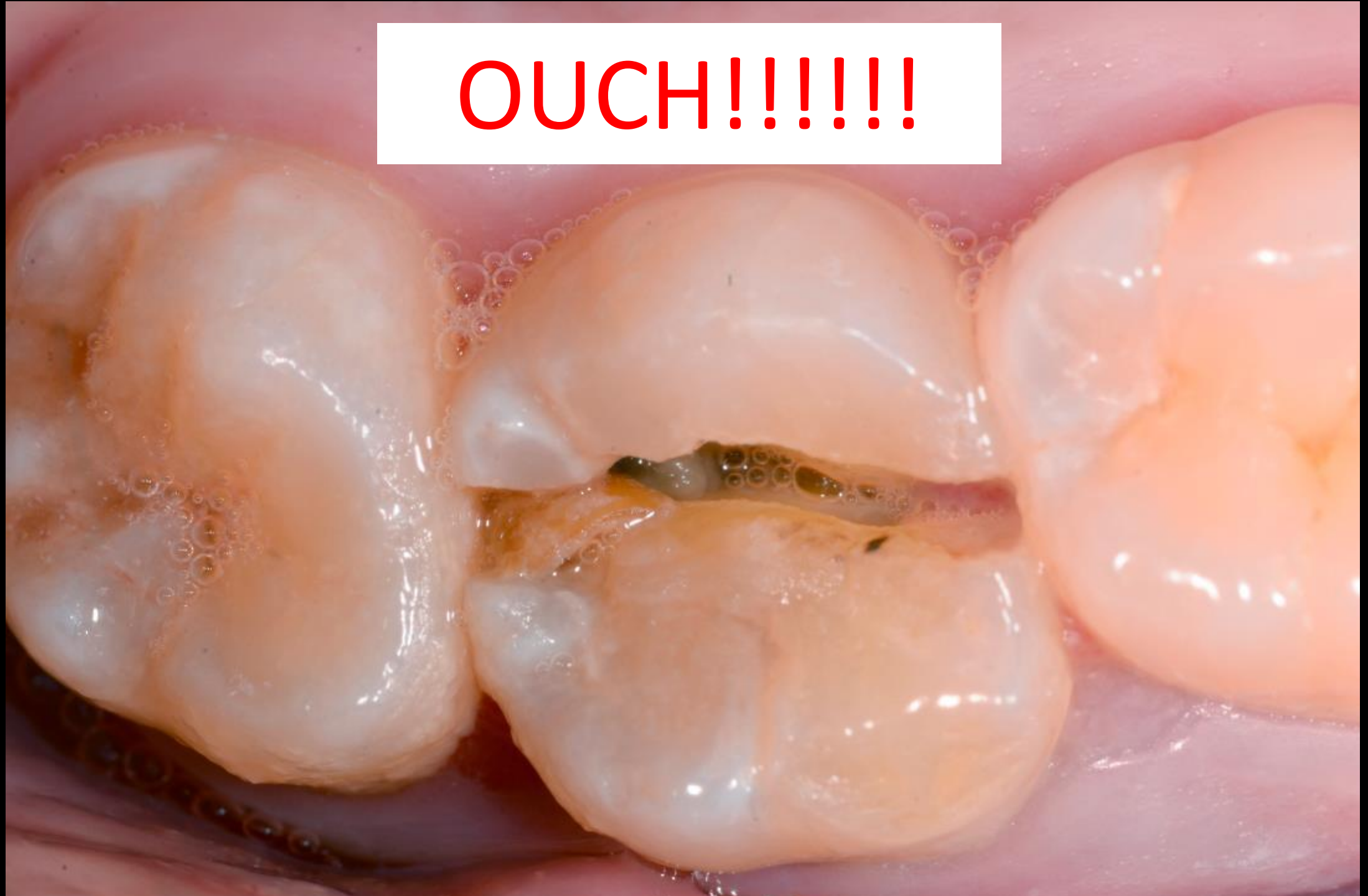The oblique ridge



The oblique bridge

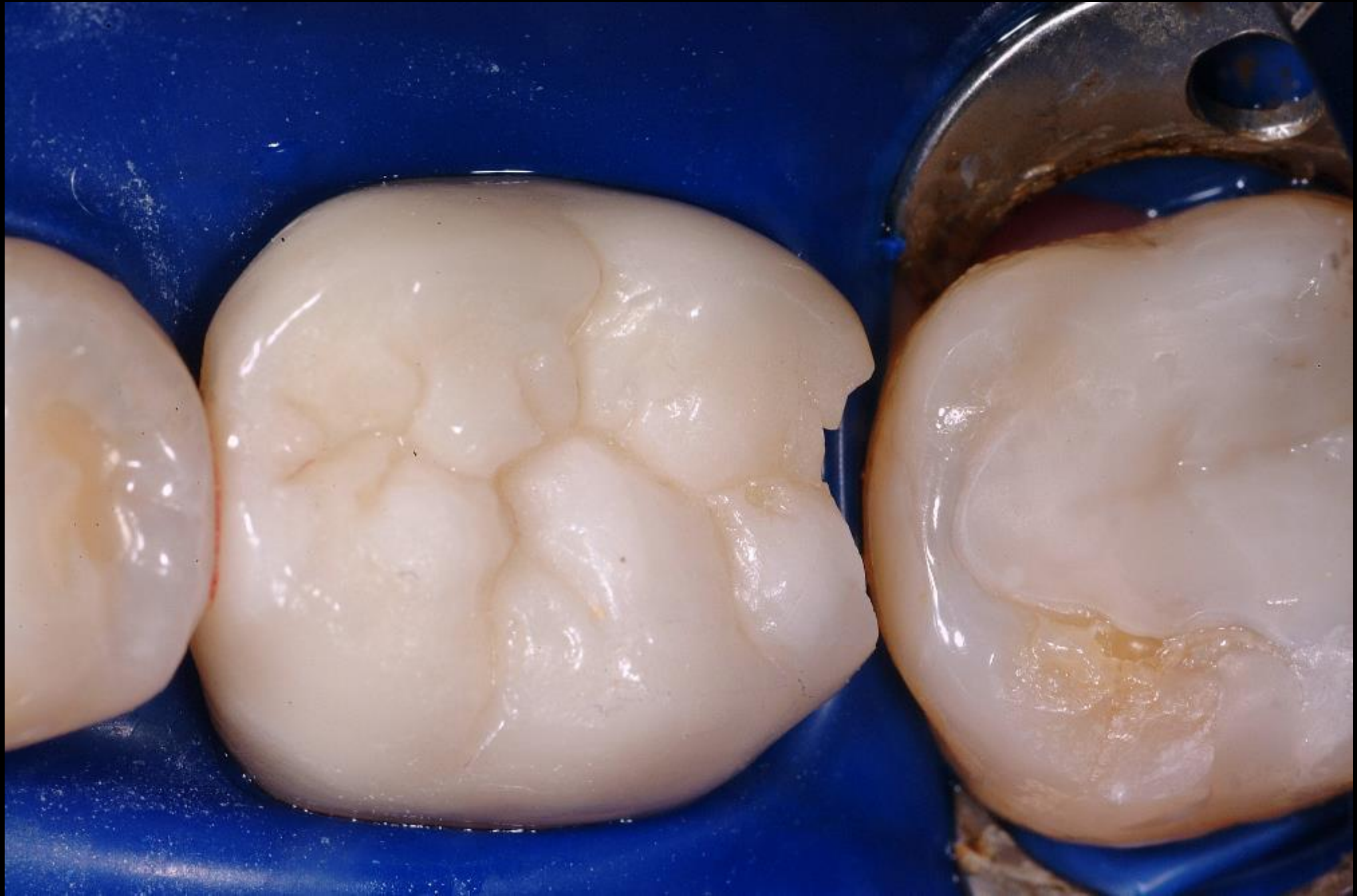

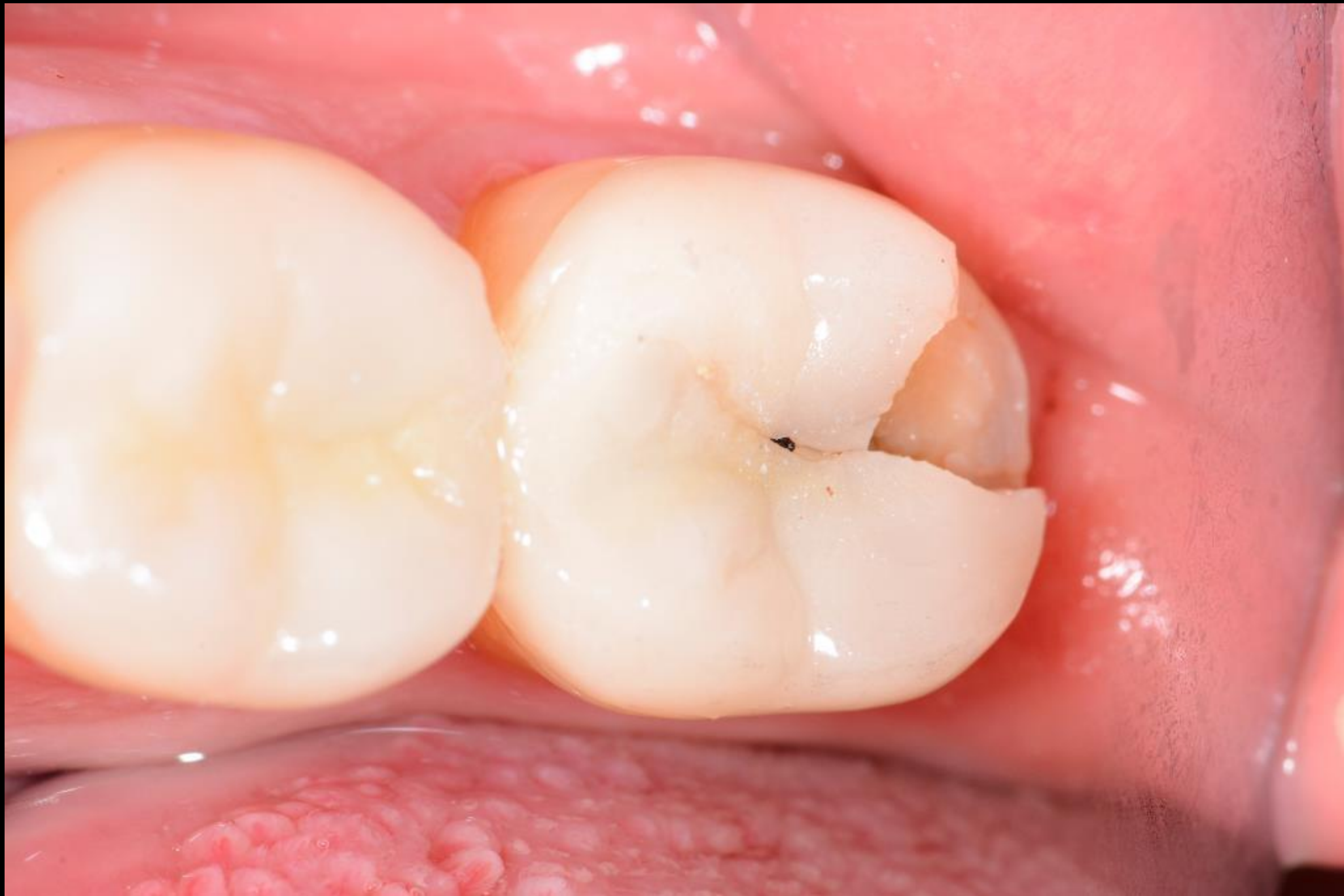OUCH!!!!!!

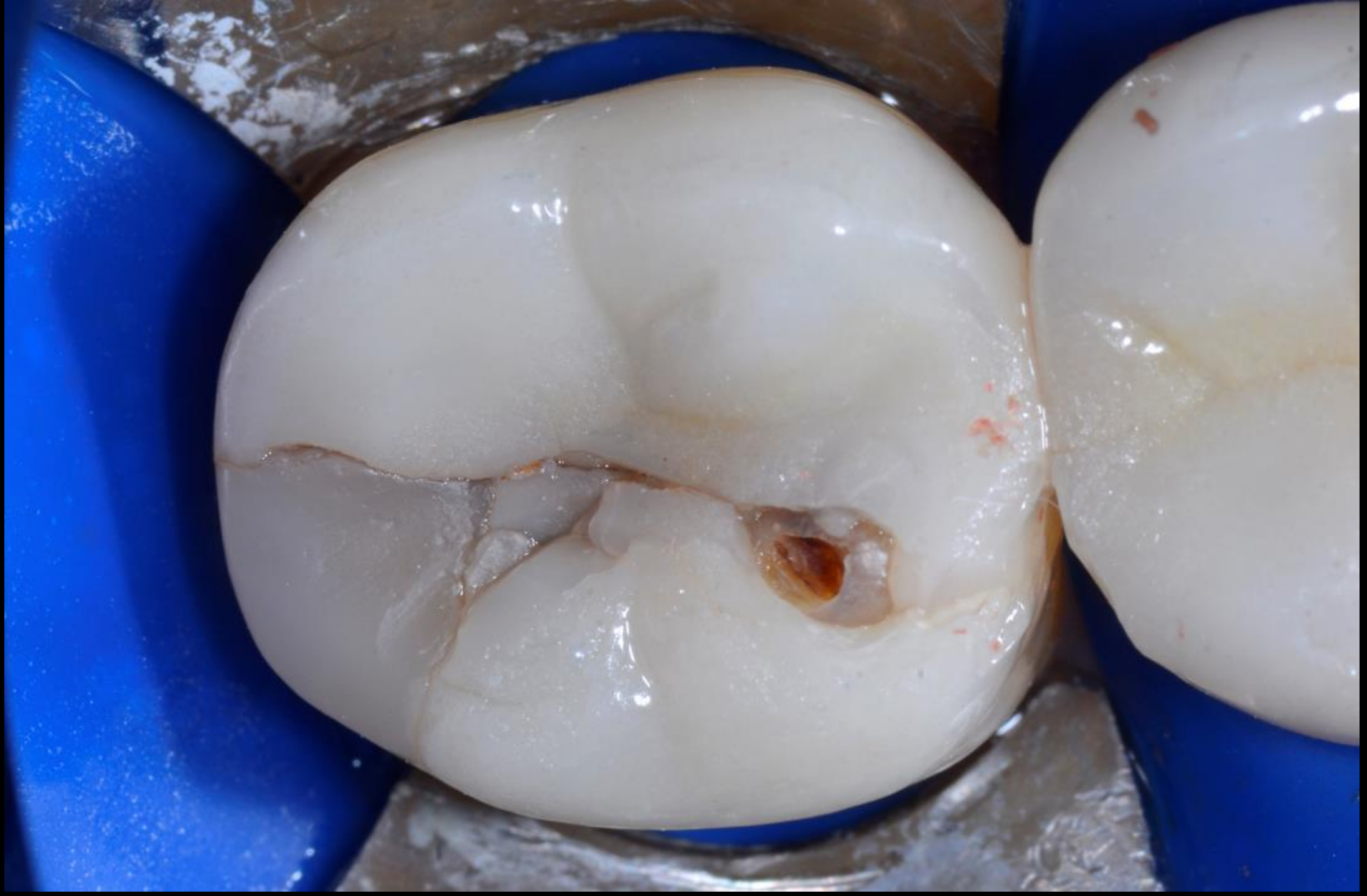

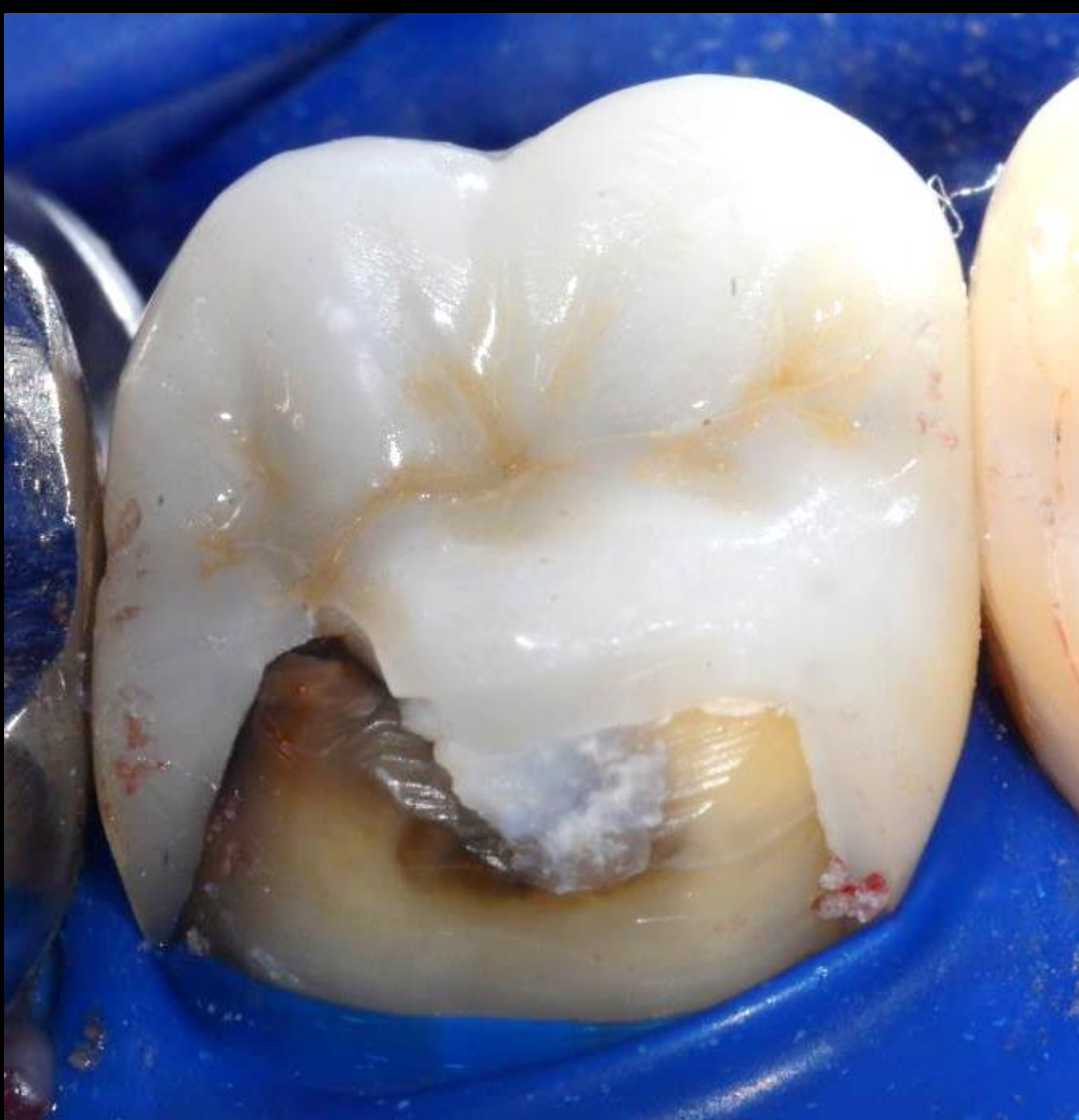Man Copies Nature's Mistake:

Vertical Layering and Deep Continuous Grooves in a Brittle Material (Composite or Ceramic)










5 year post-op fracture of monolithic zirconia

Stress/Strain Concentration

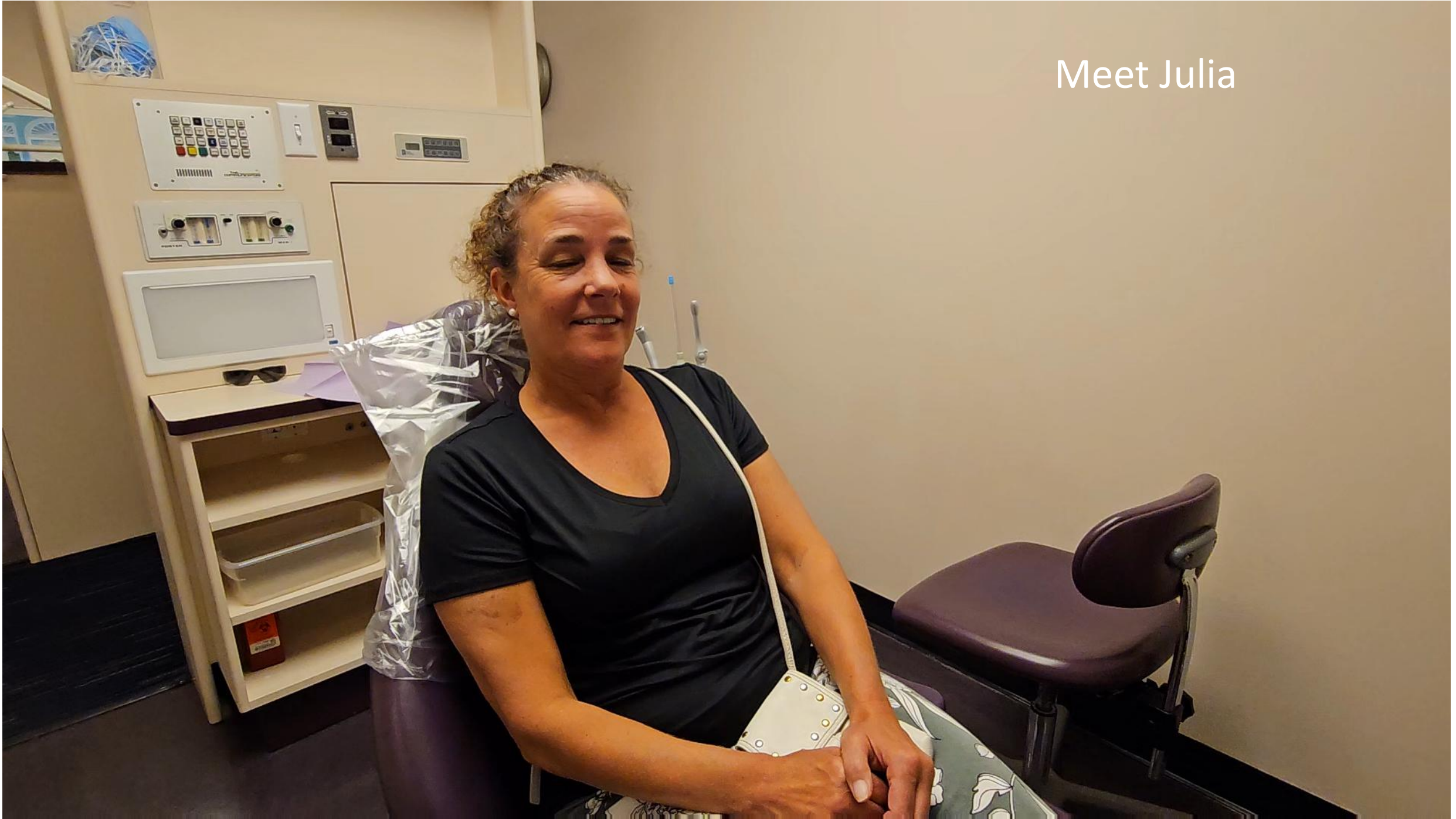- Abrupt changes in geometry
- Mismatches in mechanical properties
- Concentrated loads

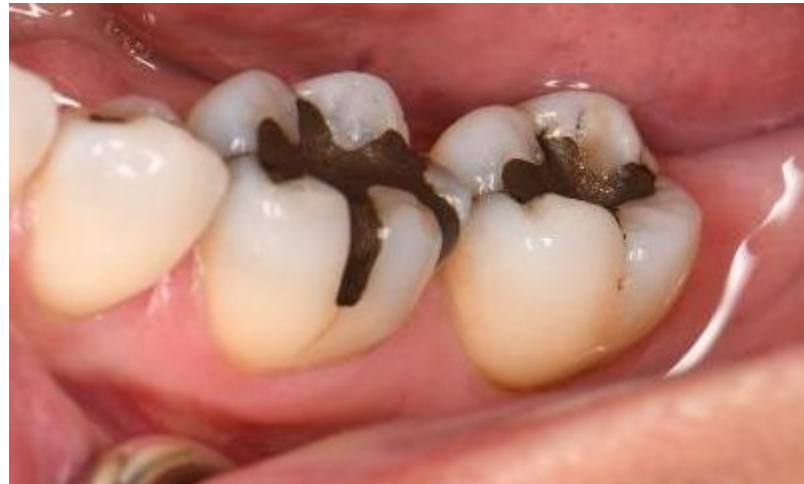
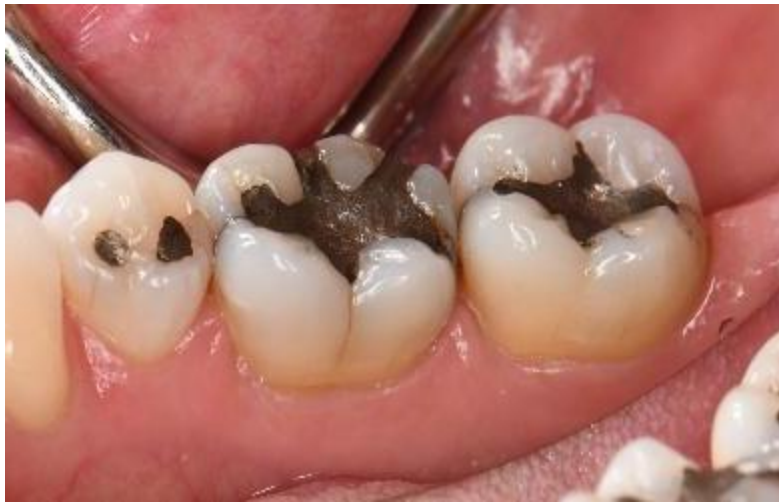
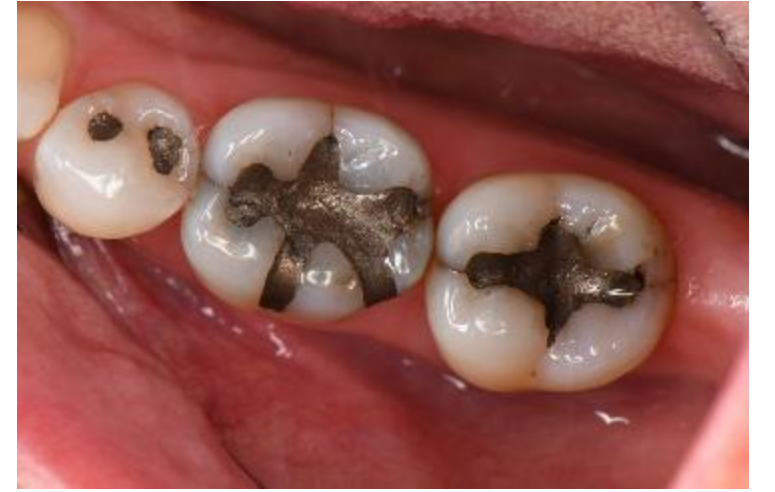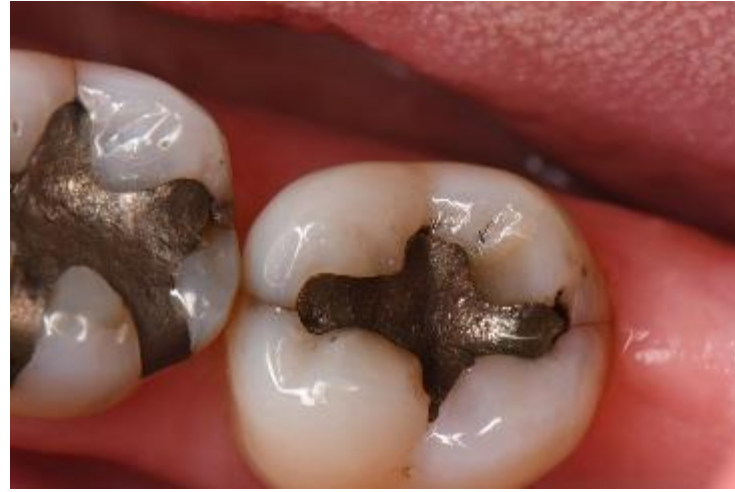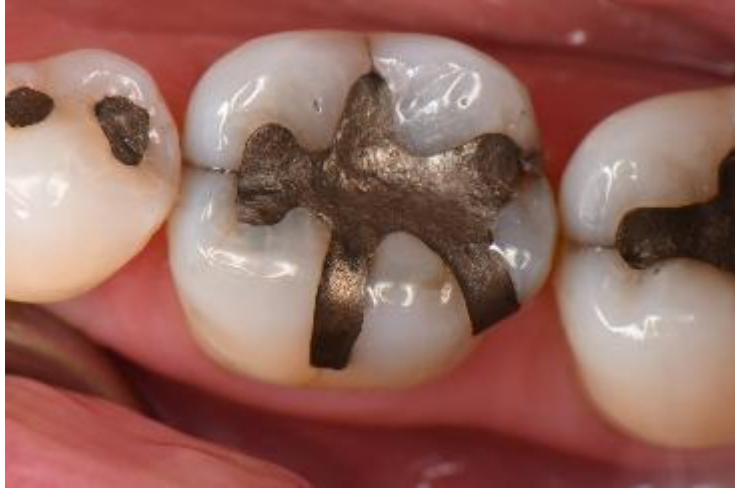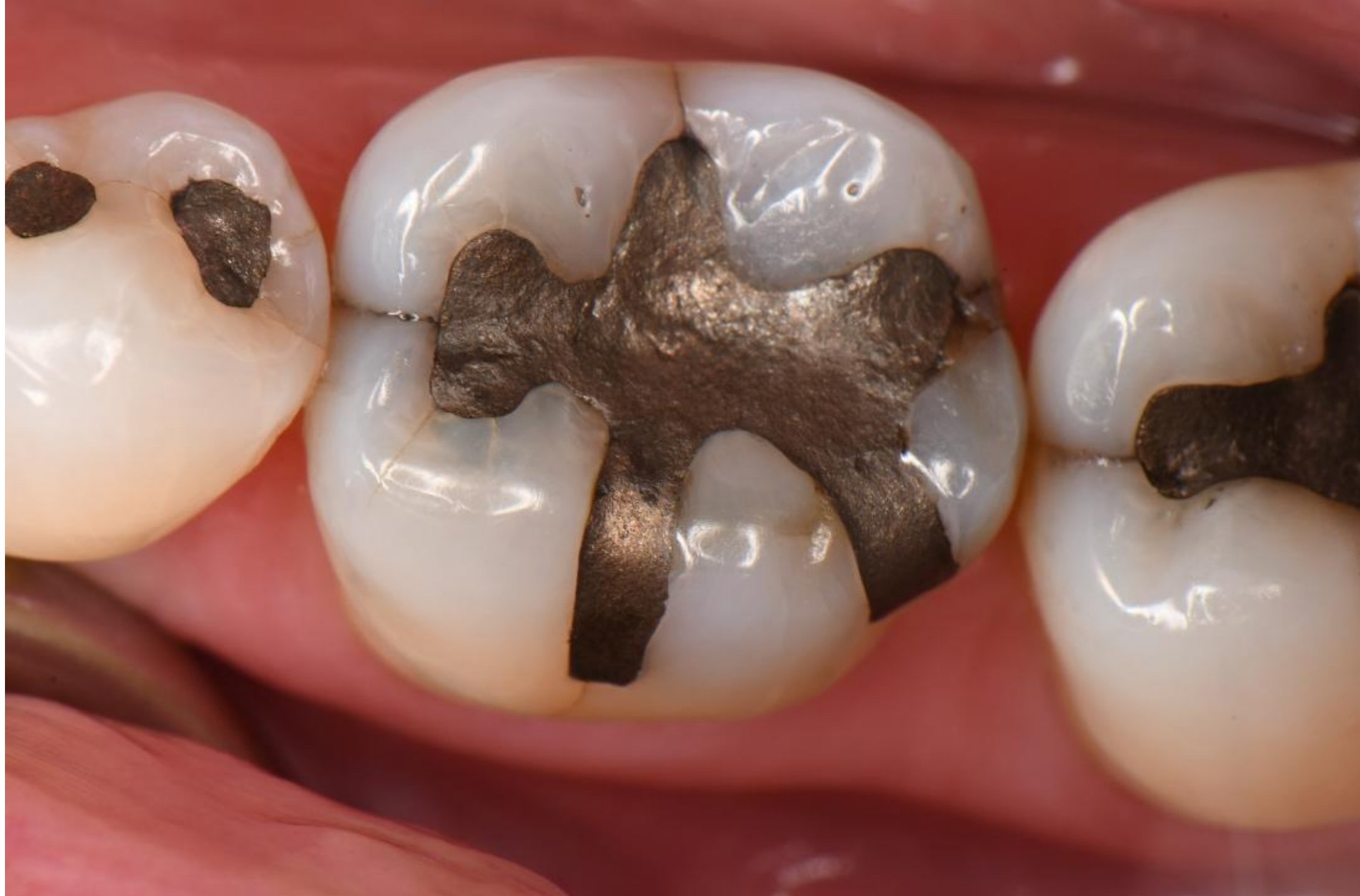Symptomatic Cracked Lower Molars: Bioclear Consult (2nd Opinion)

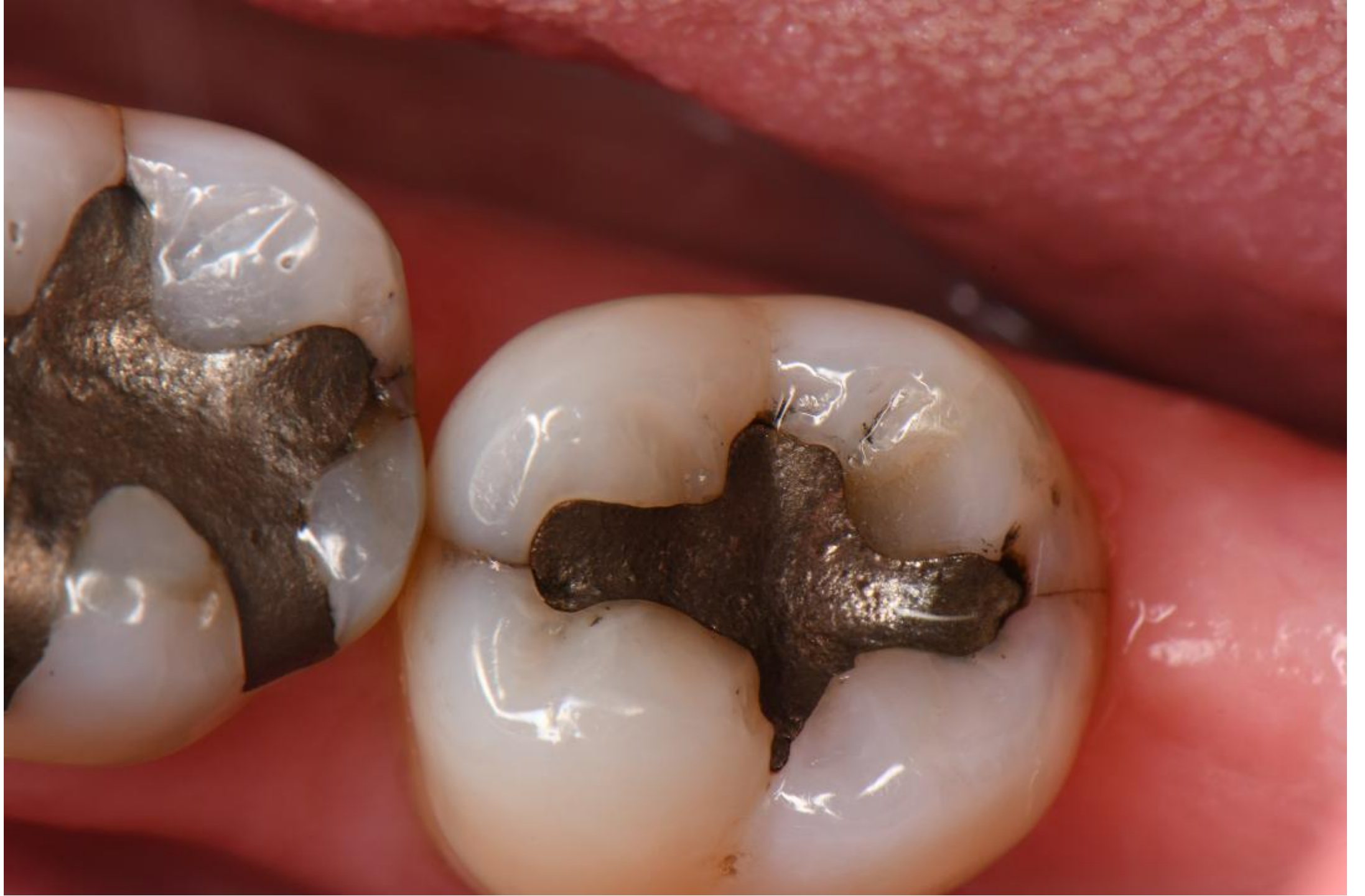Julia's Seattle dentist has treatment planned her for at least one root canal and crown lower left 1st molar (#31 or 4-6)

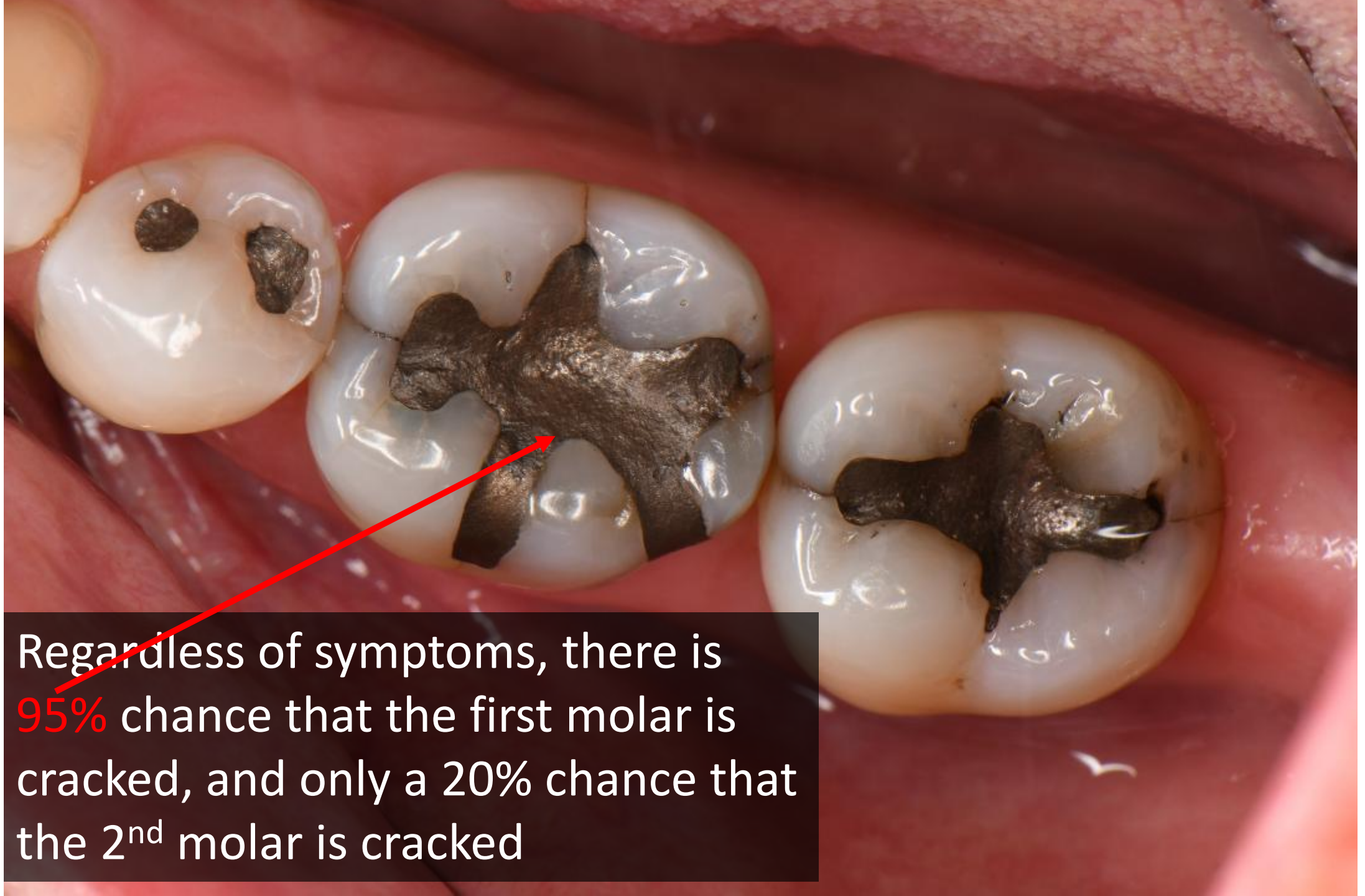
Meet Julia



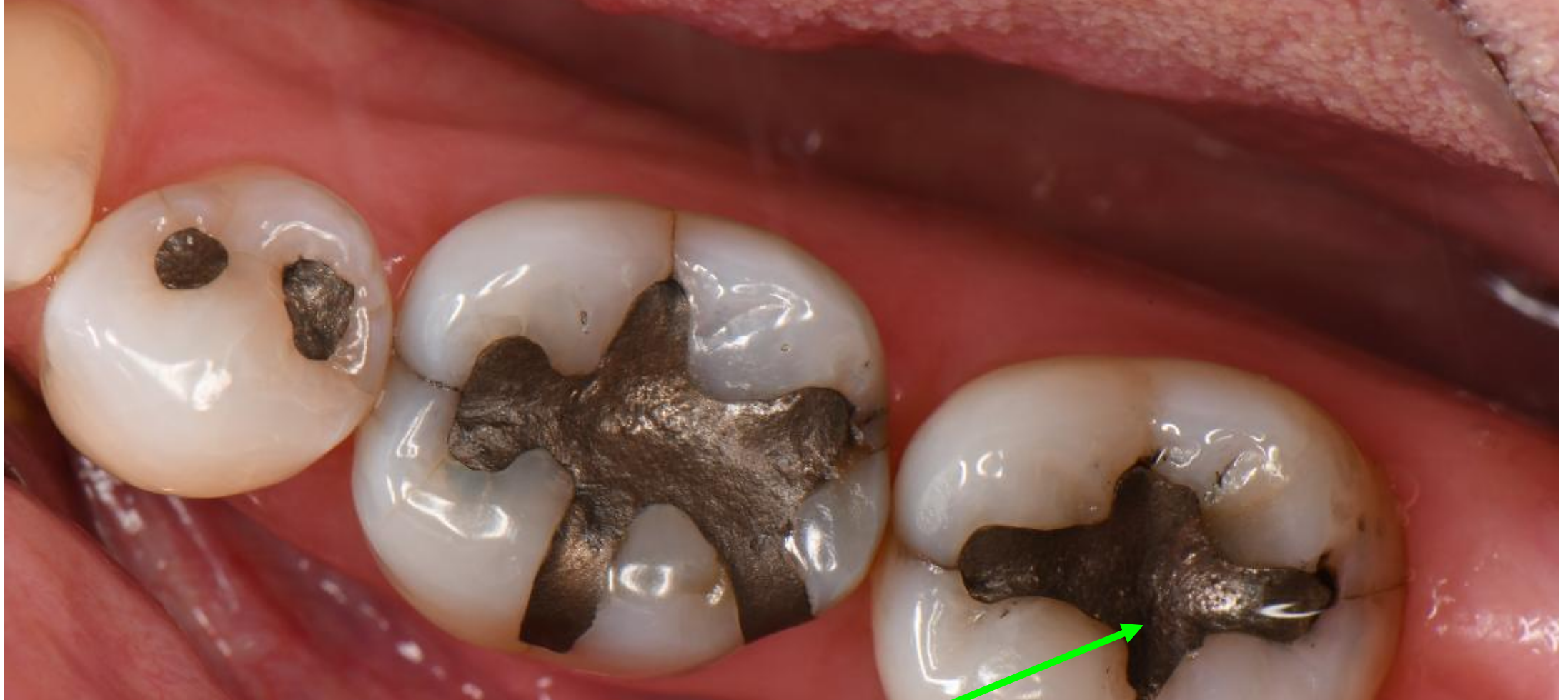




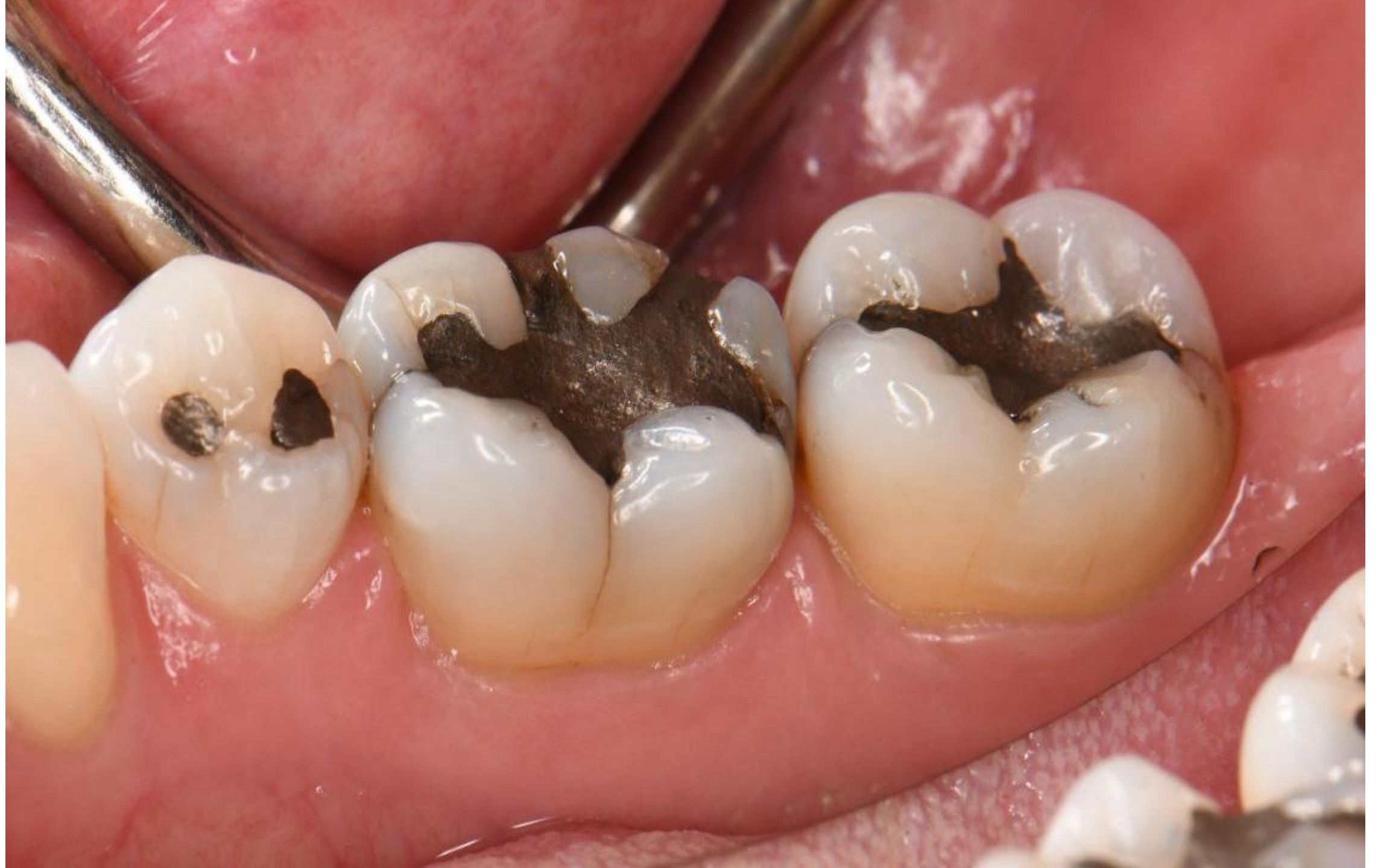


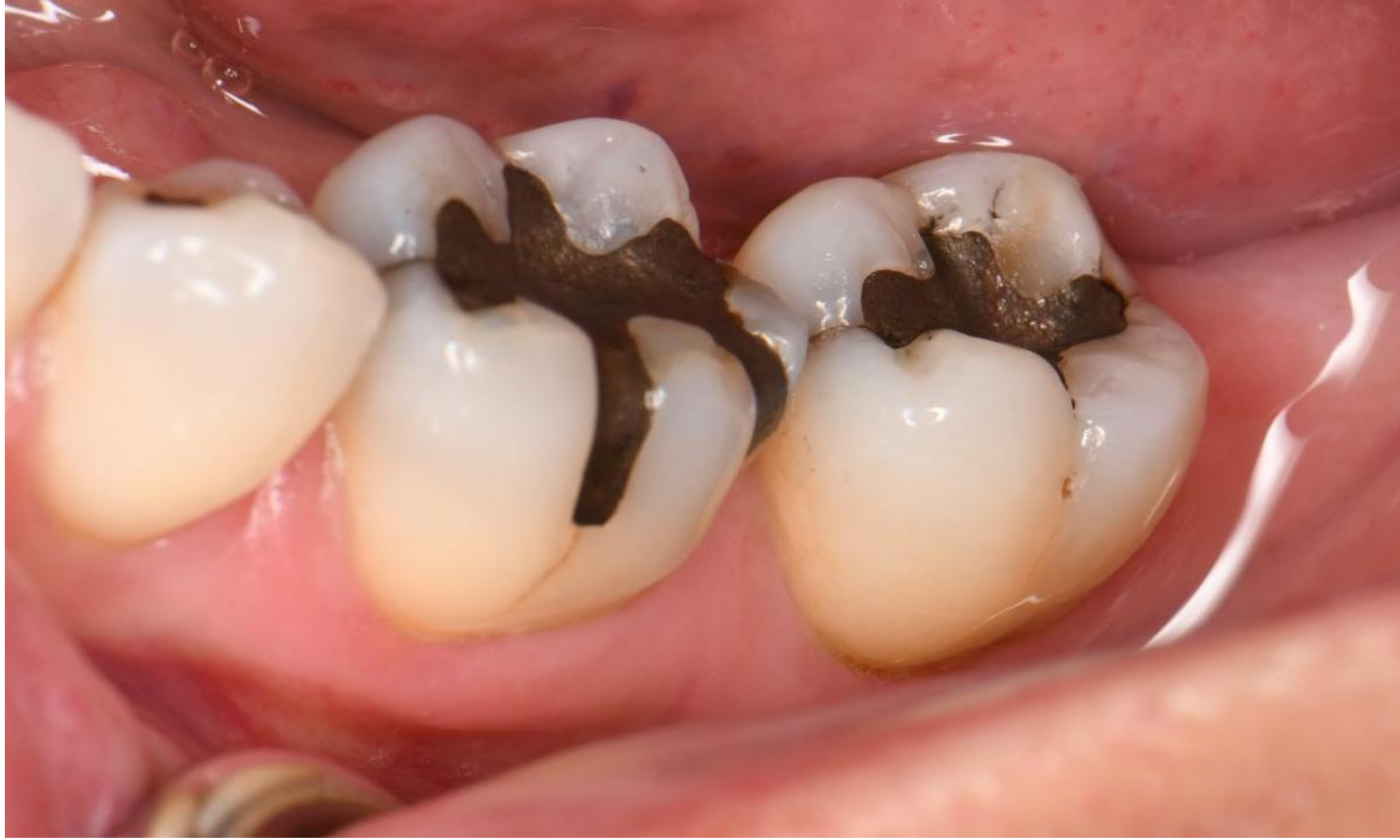Regardless of symptoms, there is **95%** chance that the first molar is cracked, and only a 20% chance that the 2nd molar is cracked



Regardless of symptoms, there is **95%** chance that the first molar is cracked, and only a **20%** chance that the 2nd molar is cracked





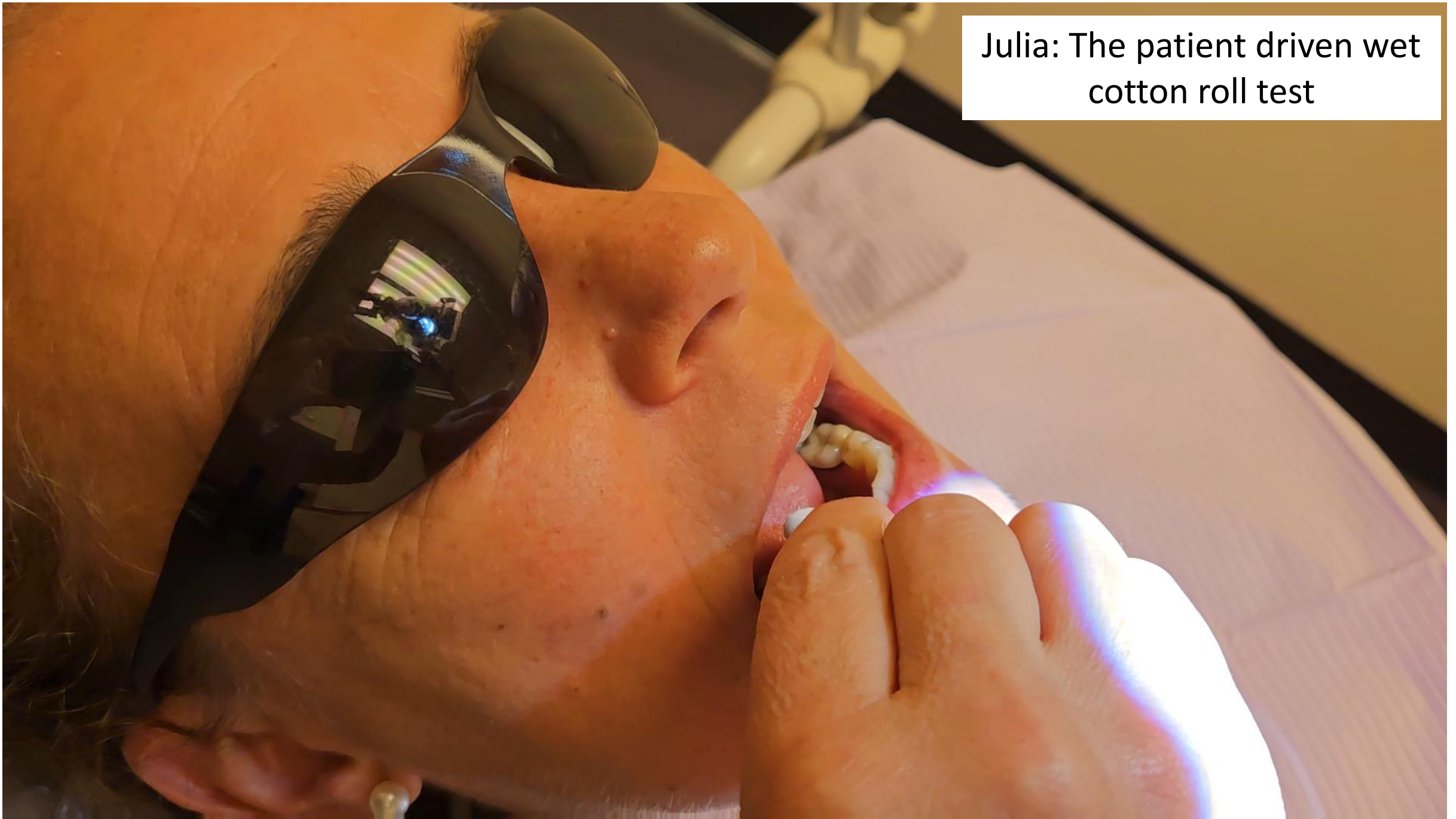Julia: The wet cotton roll test **benefits:**

- **Trust:** Patient owns the diagnosis
- **Time:** Patients are often confused about which tooth is the problem, this saves time consuming and trust degrading debate
- **Efficiency and Prevention:** You may find two or more cracked teeth

Julia: The wet cotton roll test:

- For reversible pulpitis (RP) cases
- Irreversible pulpitis (IP) gets the percussion test
- Get one end of the cotton roll wet
- Patient holds on to the dry end
- Start at the canine (a negative control)
- Repeat the full test at least once

Julia: The patient driven wet
cotton roll test

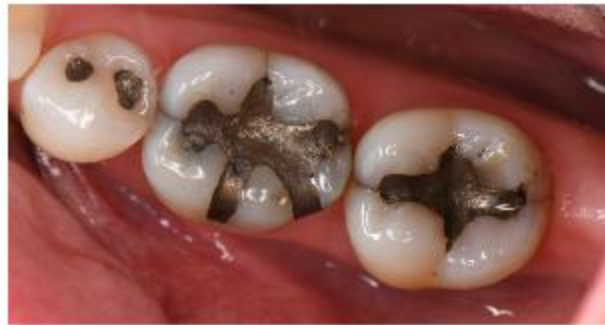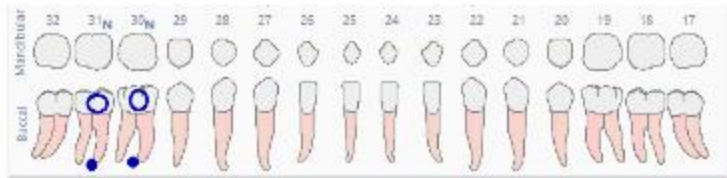


Julia: The wet cotton roll test:

- For reversible pulpitis (RP) cases (irreversible pulpitis (IP) gets the percussion test)
- Get one end of the cotton roll wet
- Patient holds on to the dry end
- Start at the canine (a negative control)
- Repeat the full test at least once

Patient Name: Julian R.
Treating Doctor: David Clark
TX Date: 10/23/2023

Lower Arch



OPTION A

Existing restorations will be removed to place the Bioclear restoration. Important step to ensure monolithic color unity and strength to the Bioclear restoration.

- **Disassembly**

- Tooth # 30 \$150
- Tooth # 31 \$150

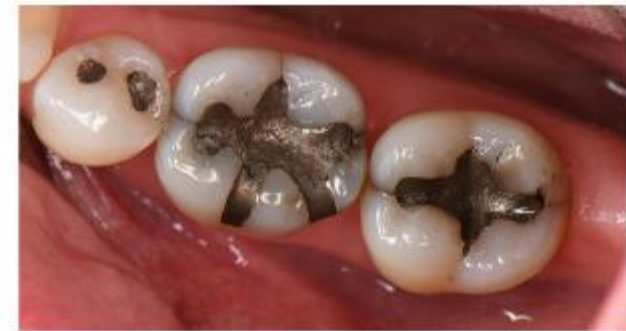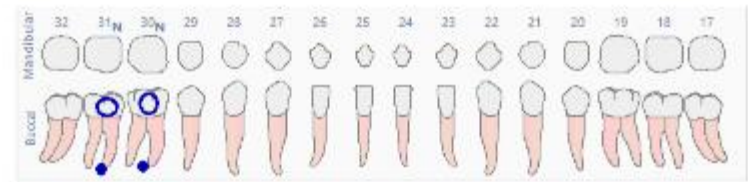
Posterior Overlay: Replace existing failing restorations, cracked tooth, rejuvenation of tooth appearance and color.

- **Bioclear Posterior Overlay**

- Tooth # 30 \$836
- Tooth # 31 \$836

Patient Name: Julian R.
Treating Doctor: David Clark
TX Date: 10/23/2023

Lower Arch



OPTION A

Existing restorations will be removed to place the Bioclear restoration. Important step to ensure monolithic color unity and strength to the Bioclear restoration.

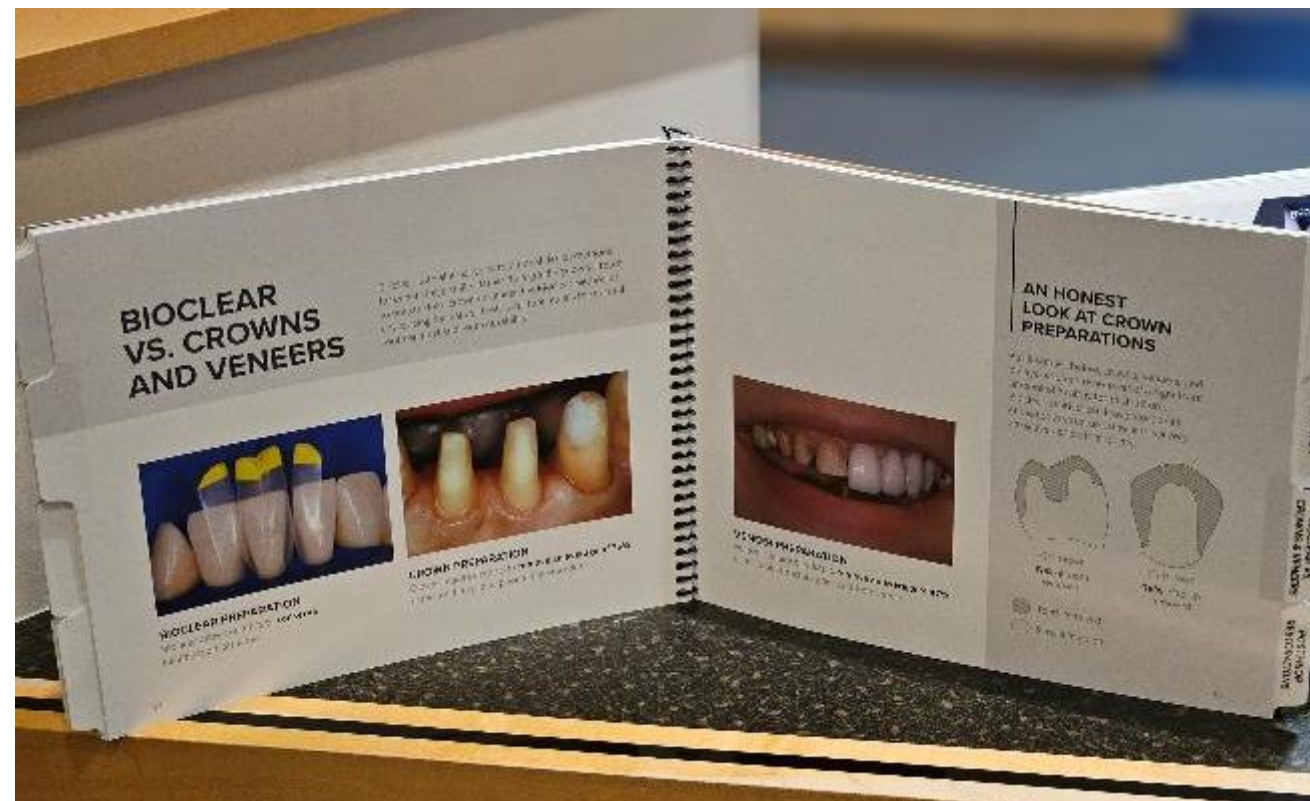
- **Disassembly**

- Tooth # 30 \$150
- Tooth # 31 \$150

Posterior Overlay: Replace existing failing restorations, cracked tooth, rejuvenation of tooth appearance and color.

- **Bioclear Complex Posterior Overlay**

- Tooth # 30 \$1,200
- Tooth # 31 \$1,200

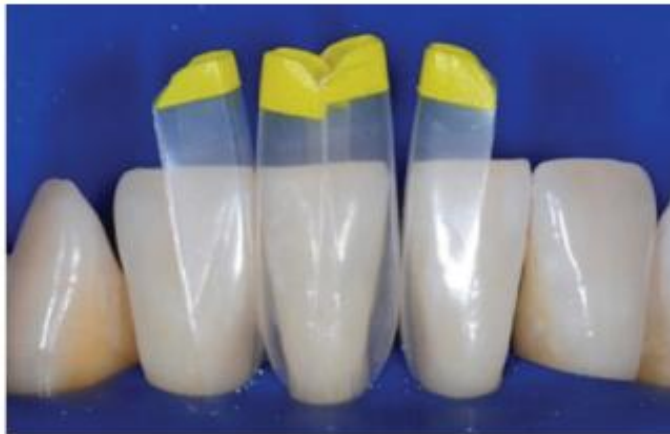

We show her the patient book and cracked teeth pamphlet. Go straight to page 42. Then she chooses a crown or Bioclear. She will get a little insurance coverage for Bioclear. (We are PPO)

Getting paid to be conservative

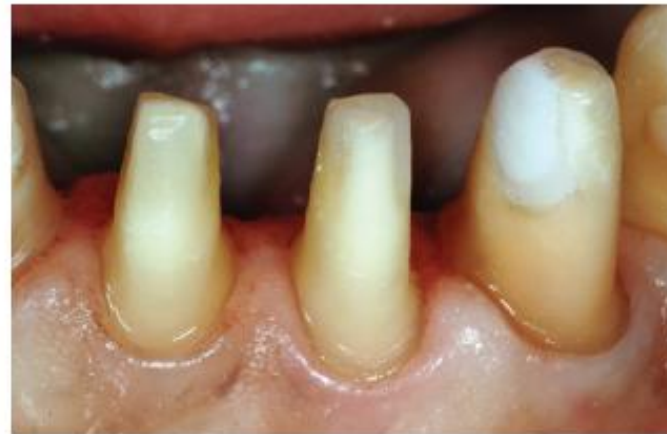BIOCLEAR VS. CROWNS AND VENEERS

Bioclear is an alternative to traditional dental methods for enhancing a smile. Rather than grinding down a tooth to prepare for a crown or veneer, the Bioclear Method of encasing the natural tooth structure retains the natural tooth enamel and tooth durability.



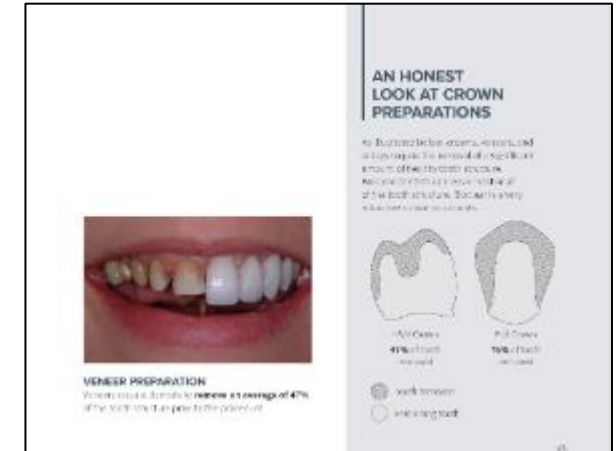BIOCLEAR PREPARATION

Bioclear allows dentists to **conserve** healthy tooth structure

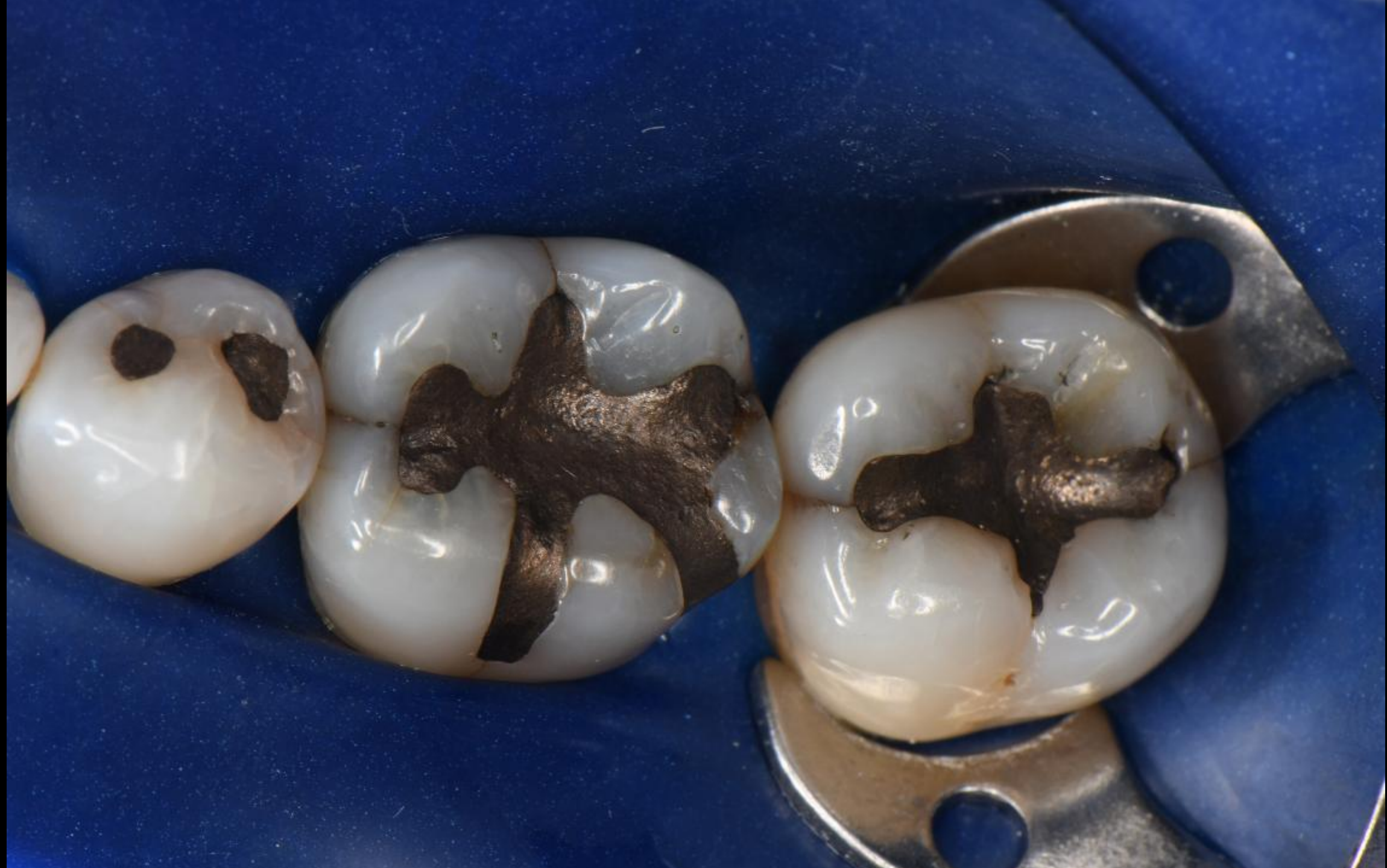

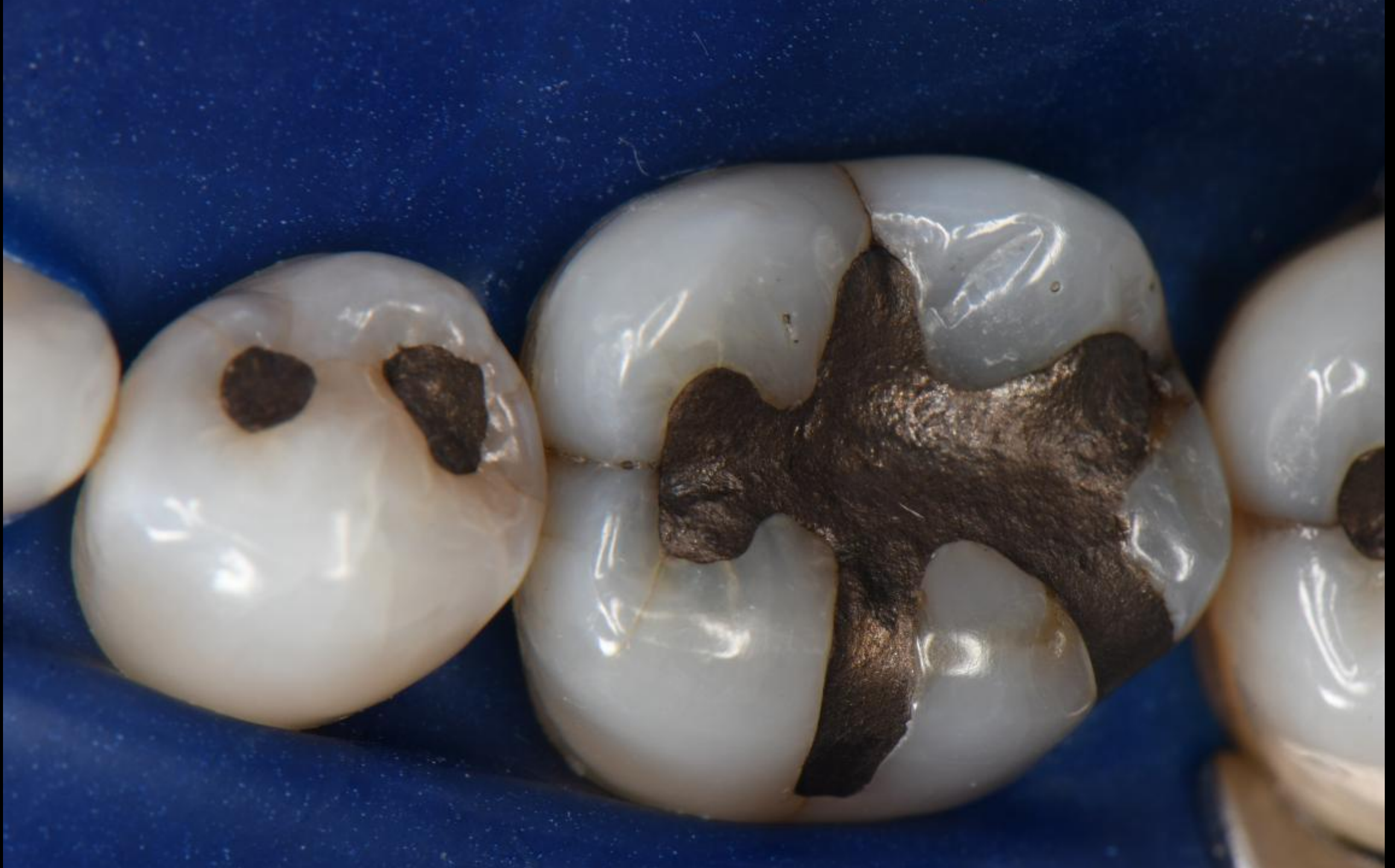CROWN PREPARATION

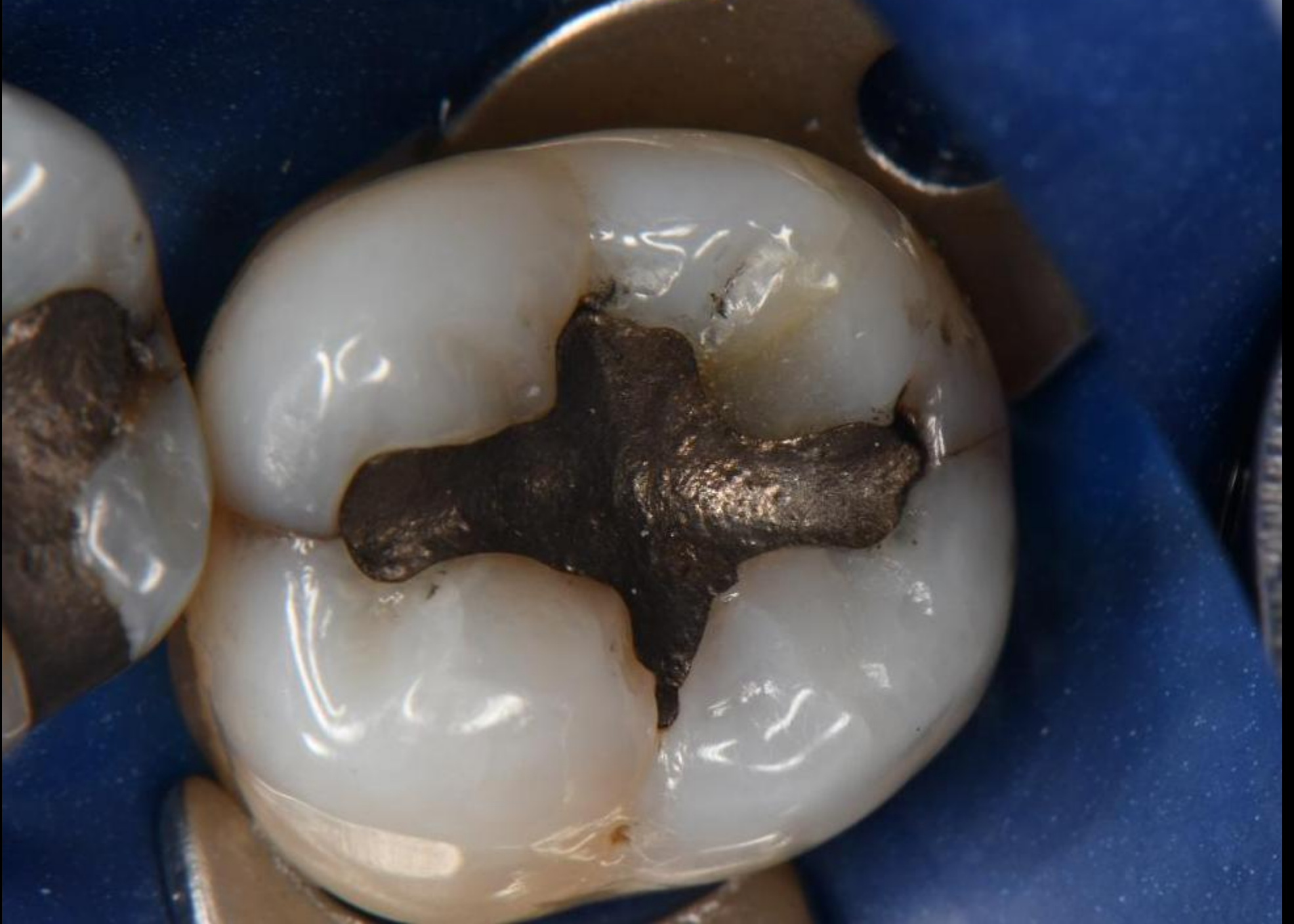Crowns require dentists to **remove an average of 76%** of the tooth structure prior to the procedure

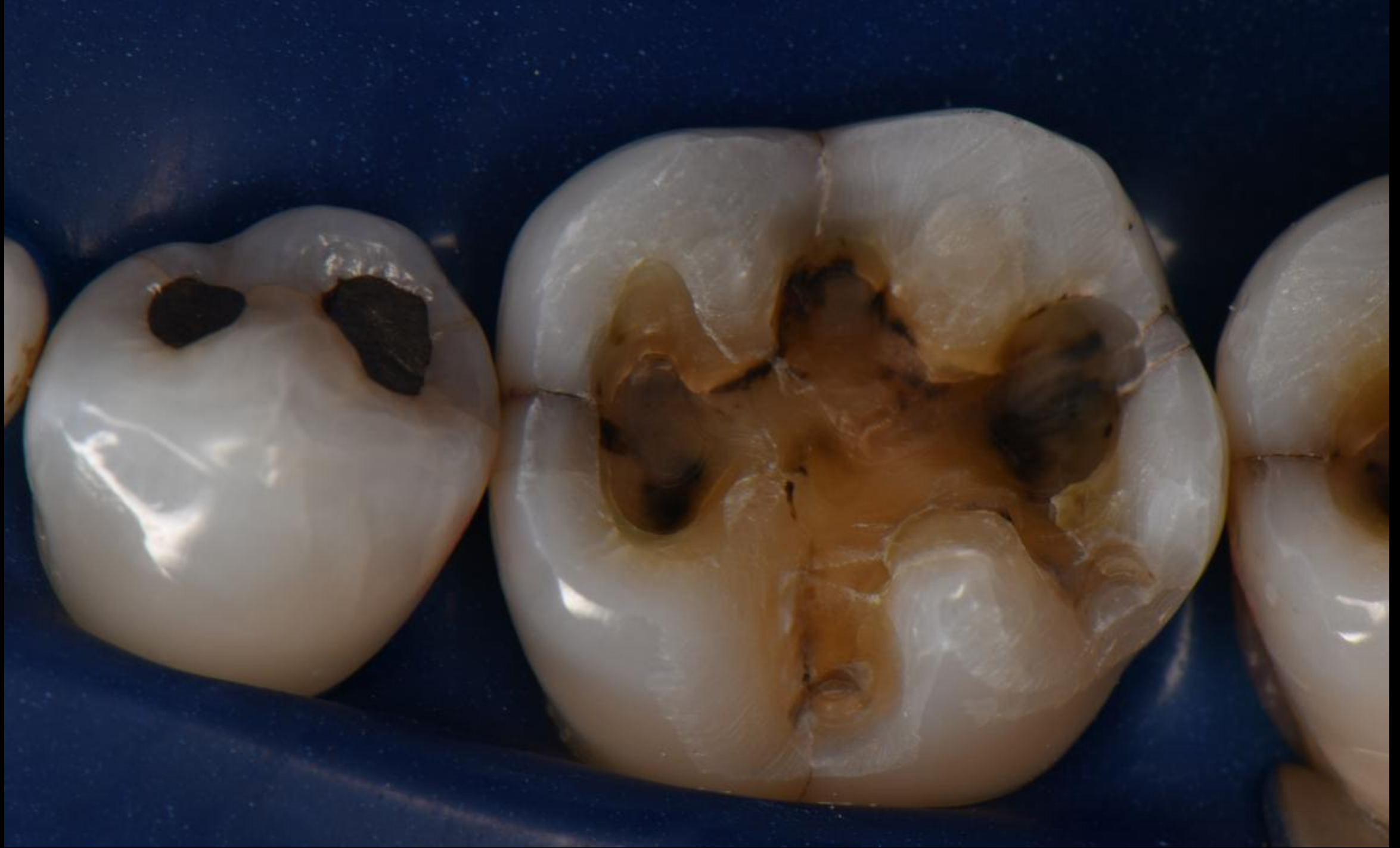

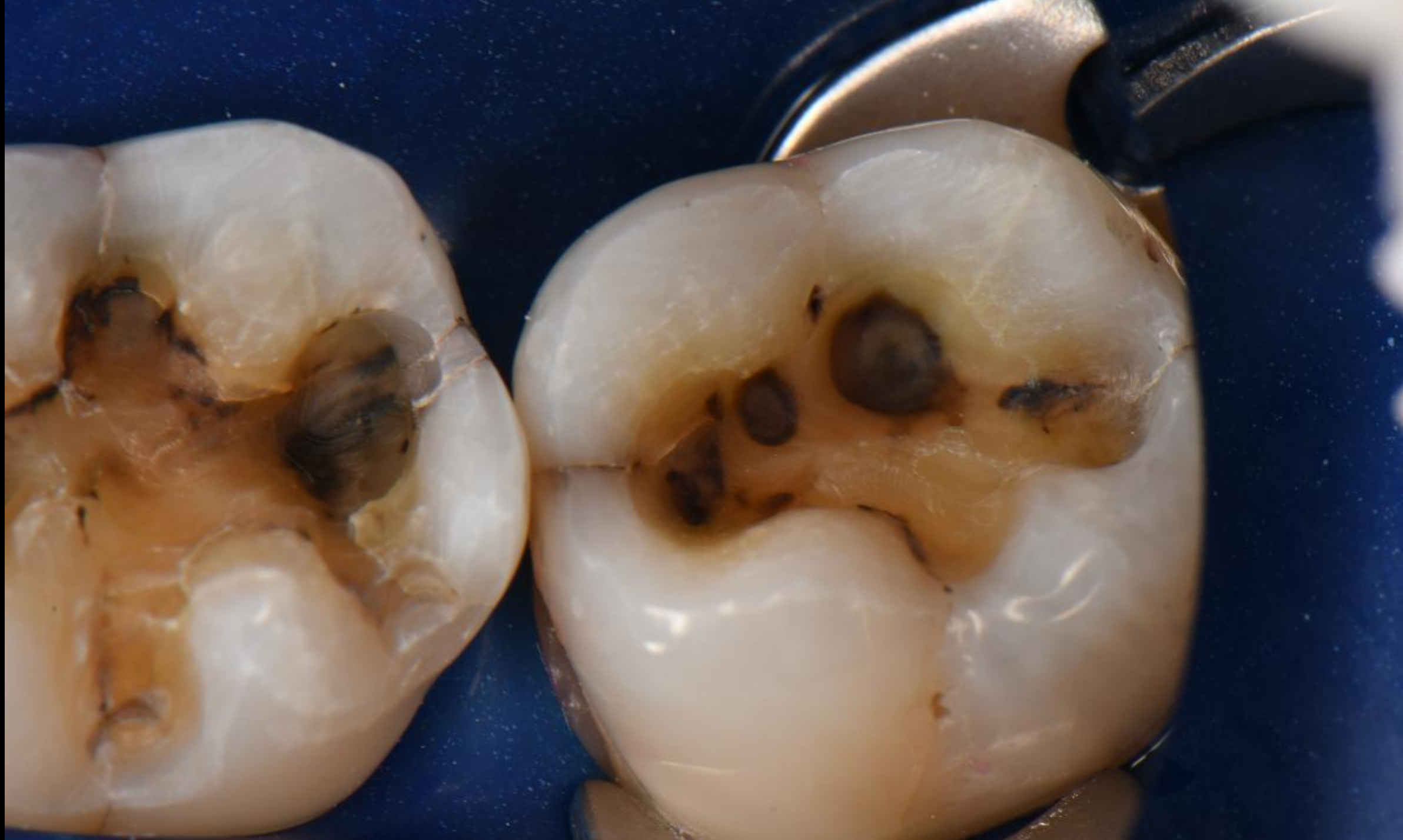Julia's overlay treatment images

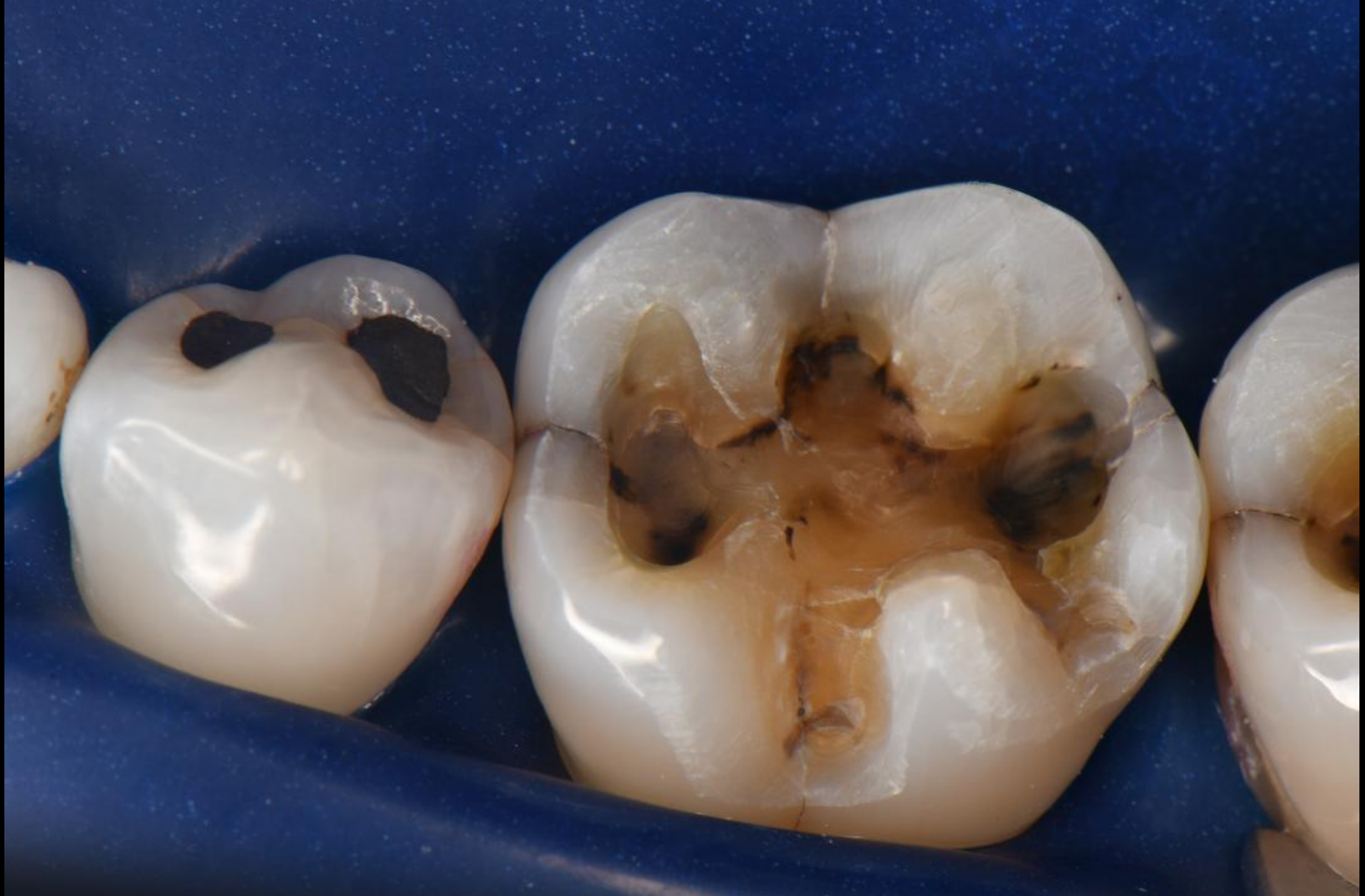


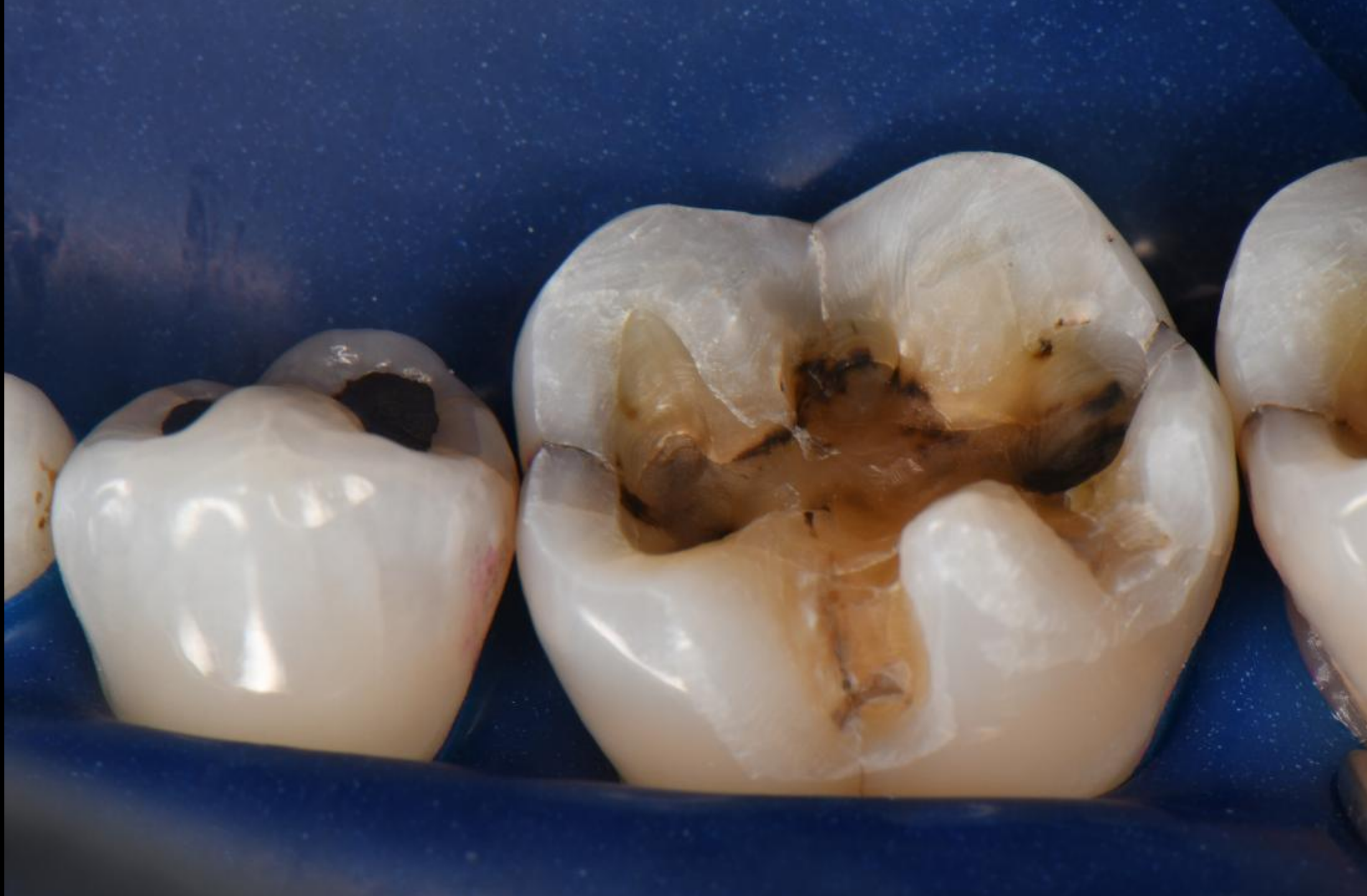


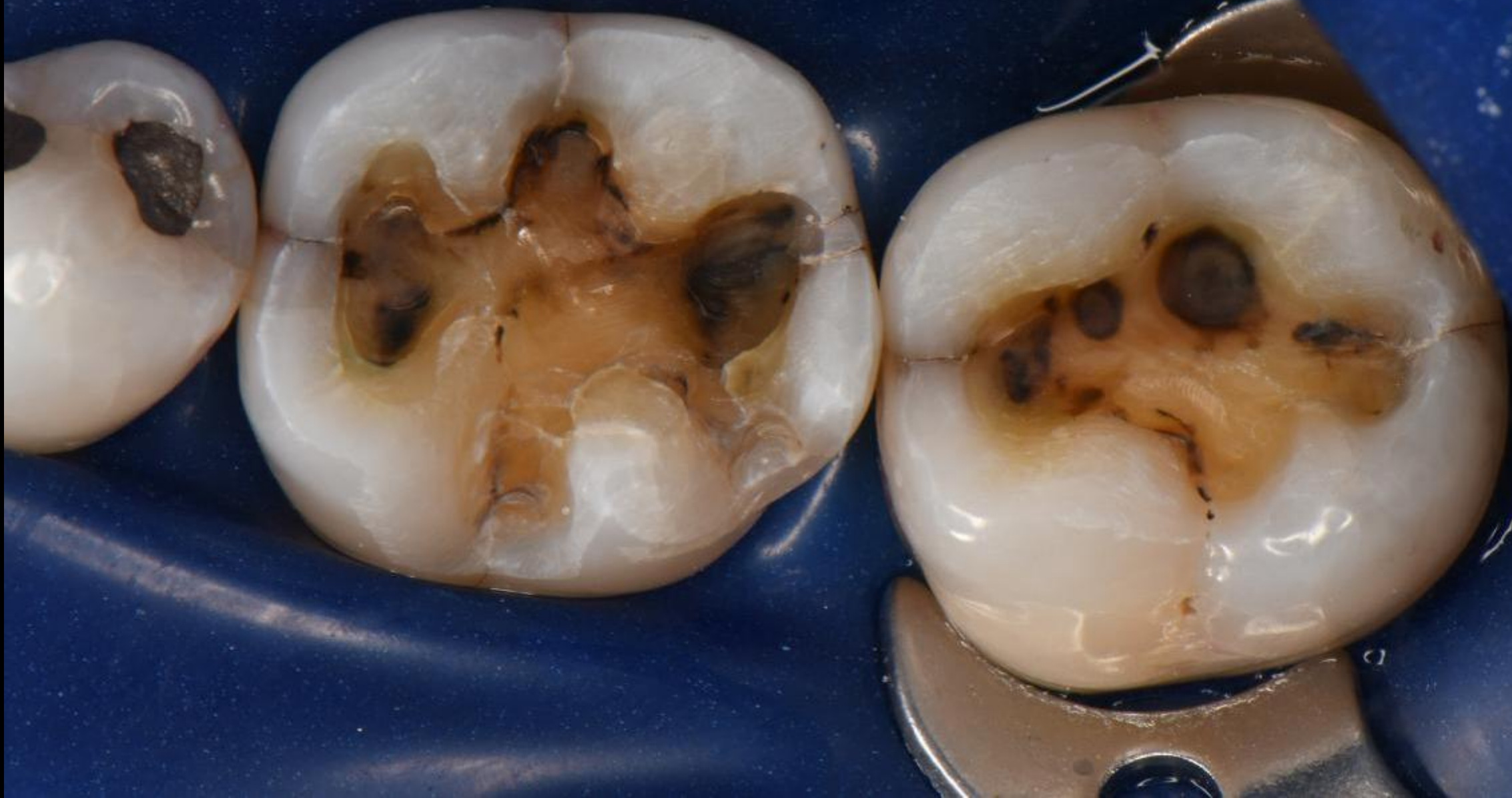


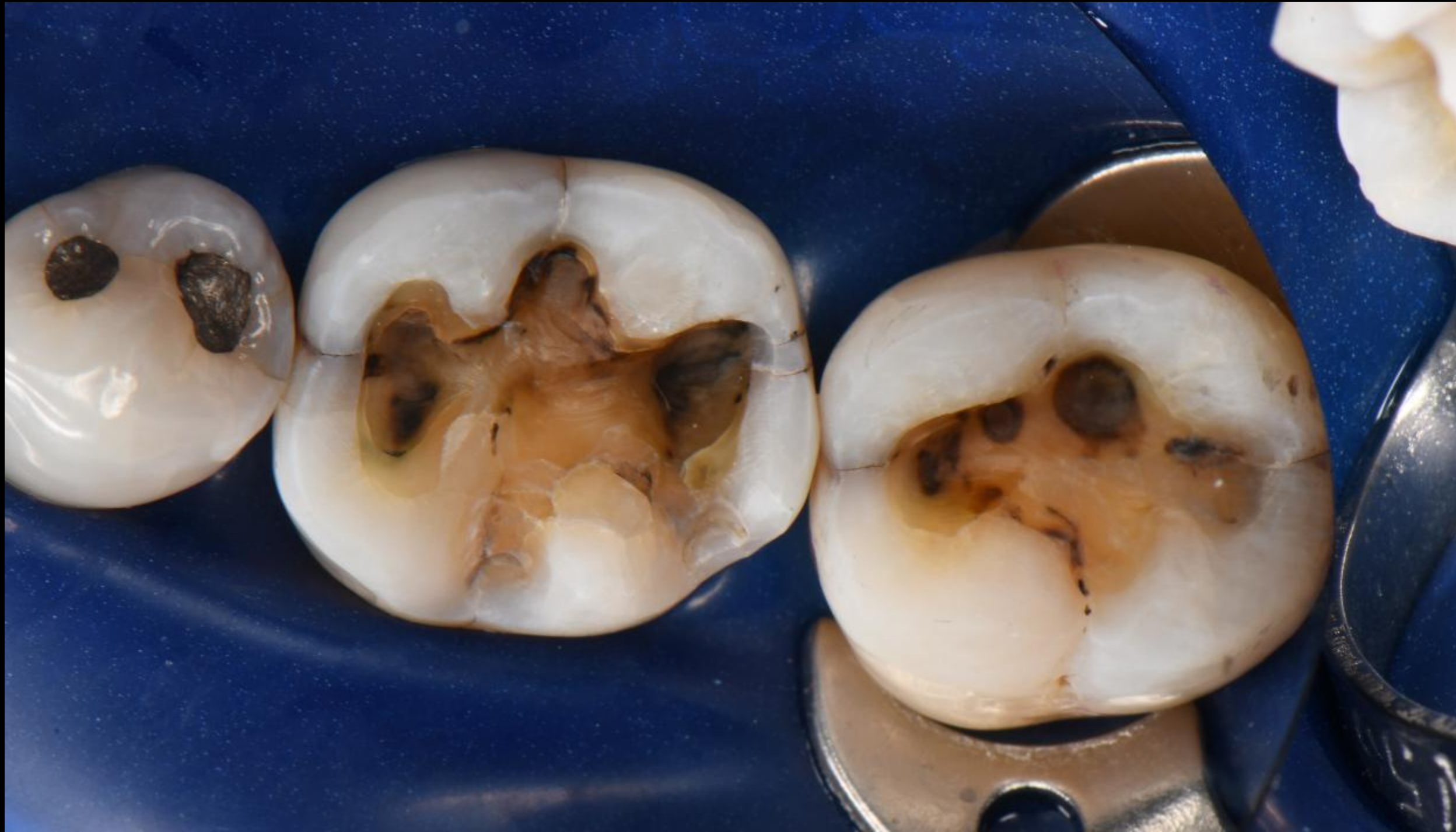


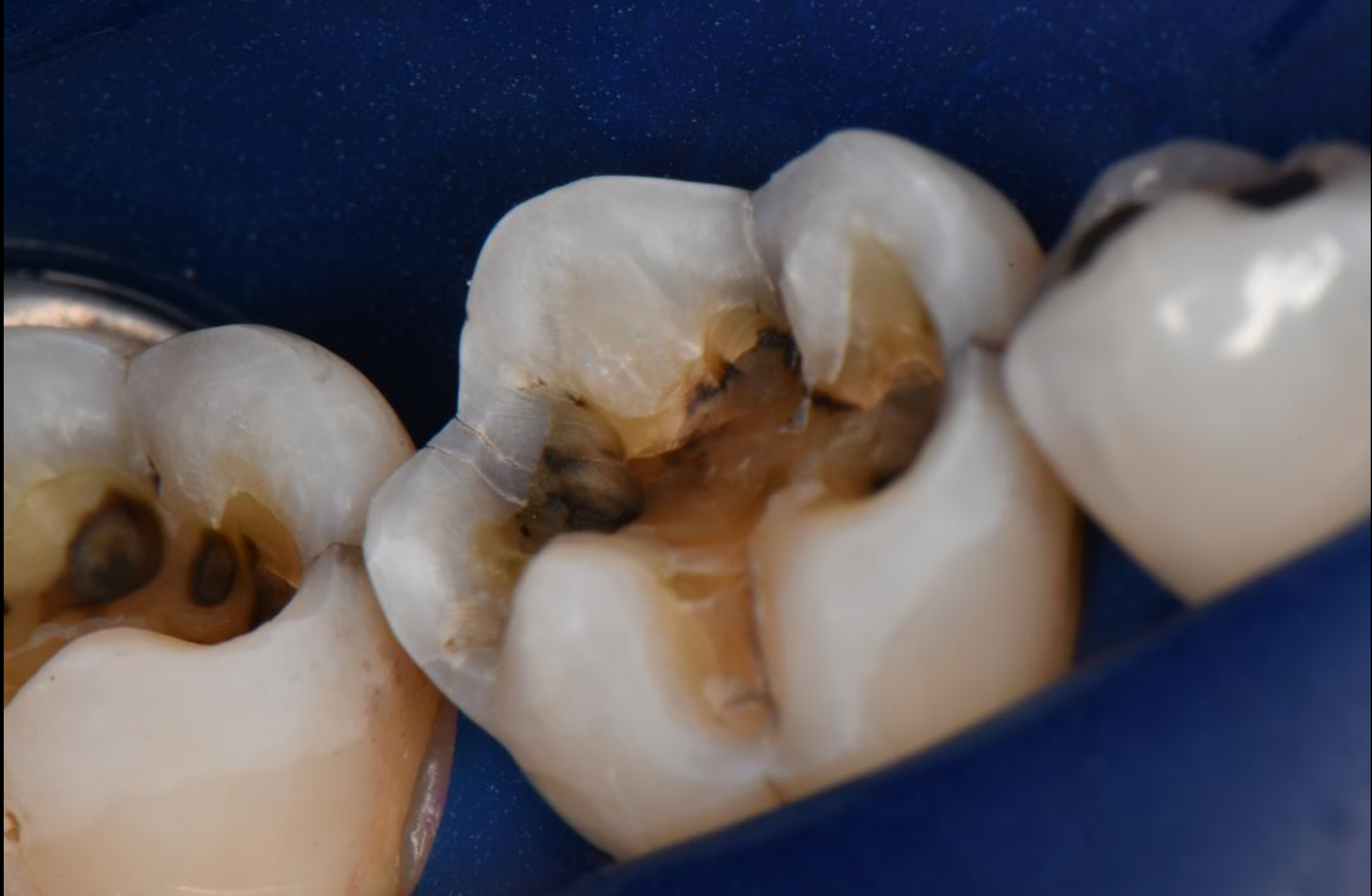


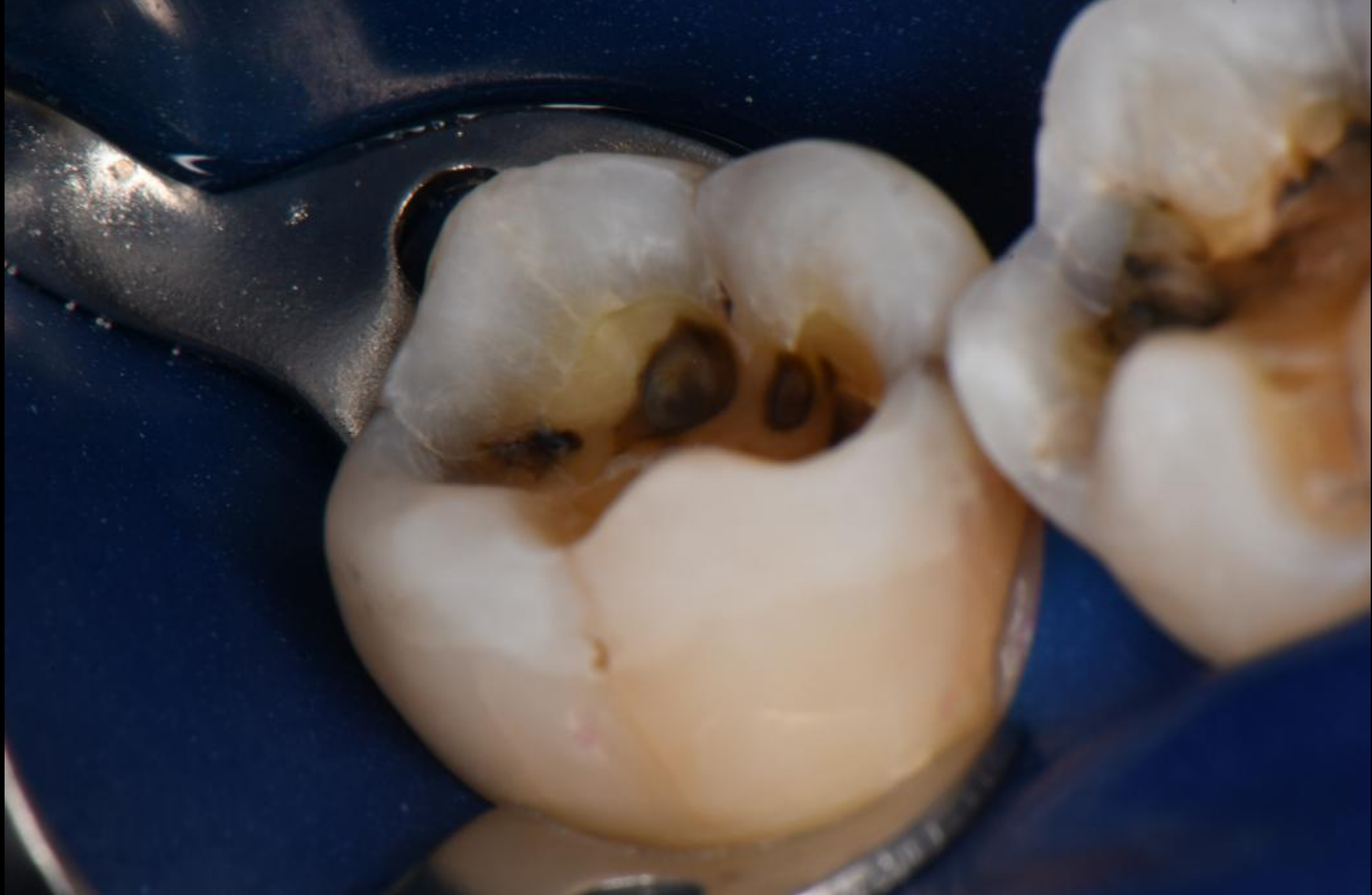


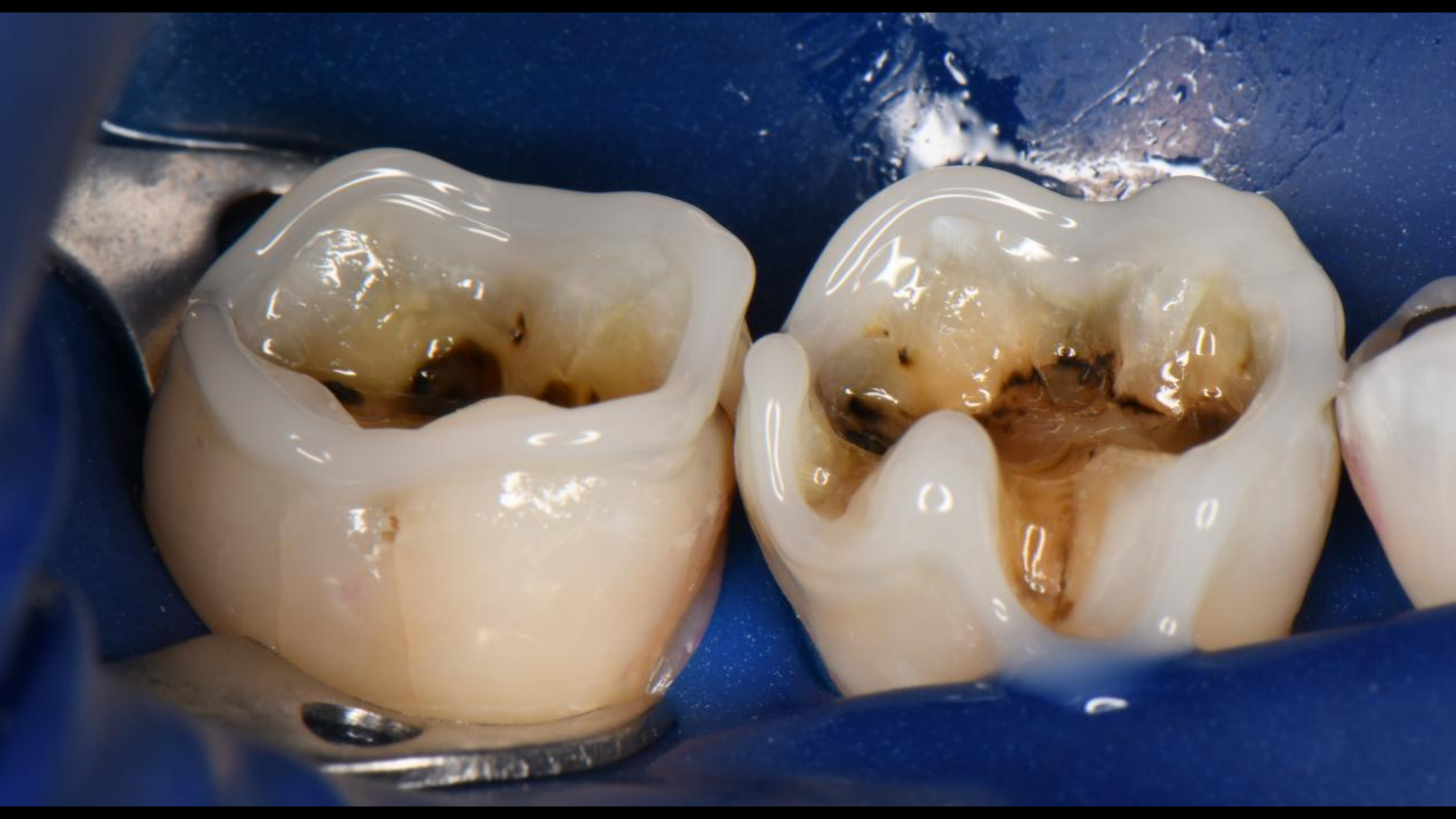


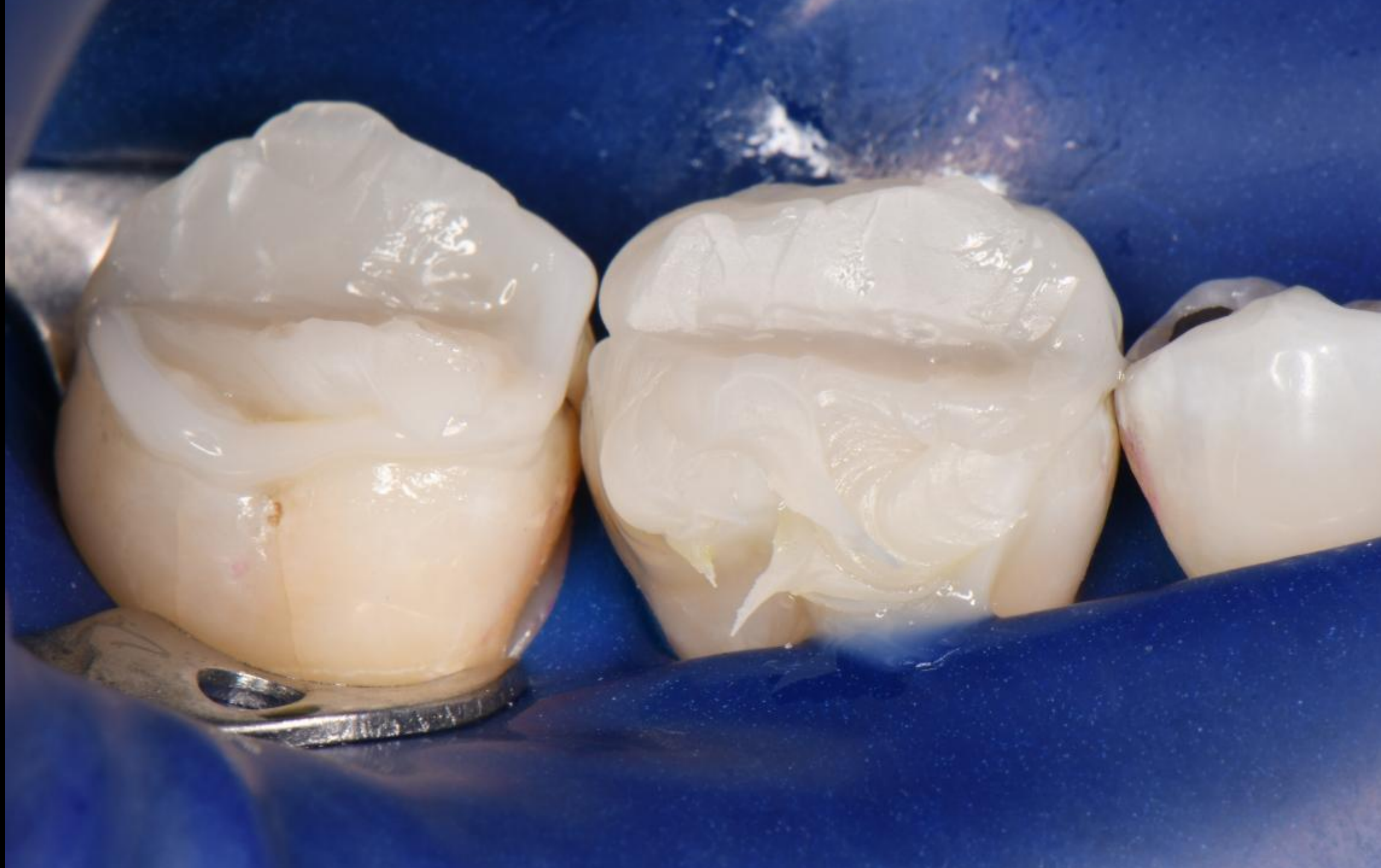




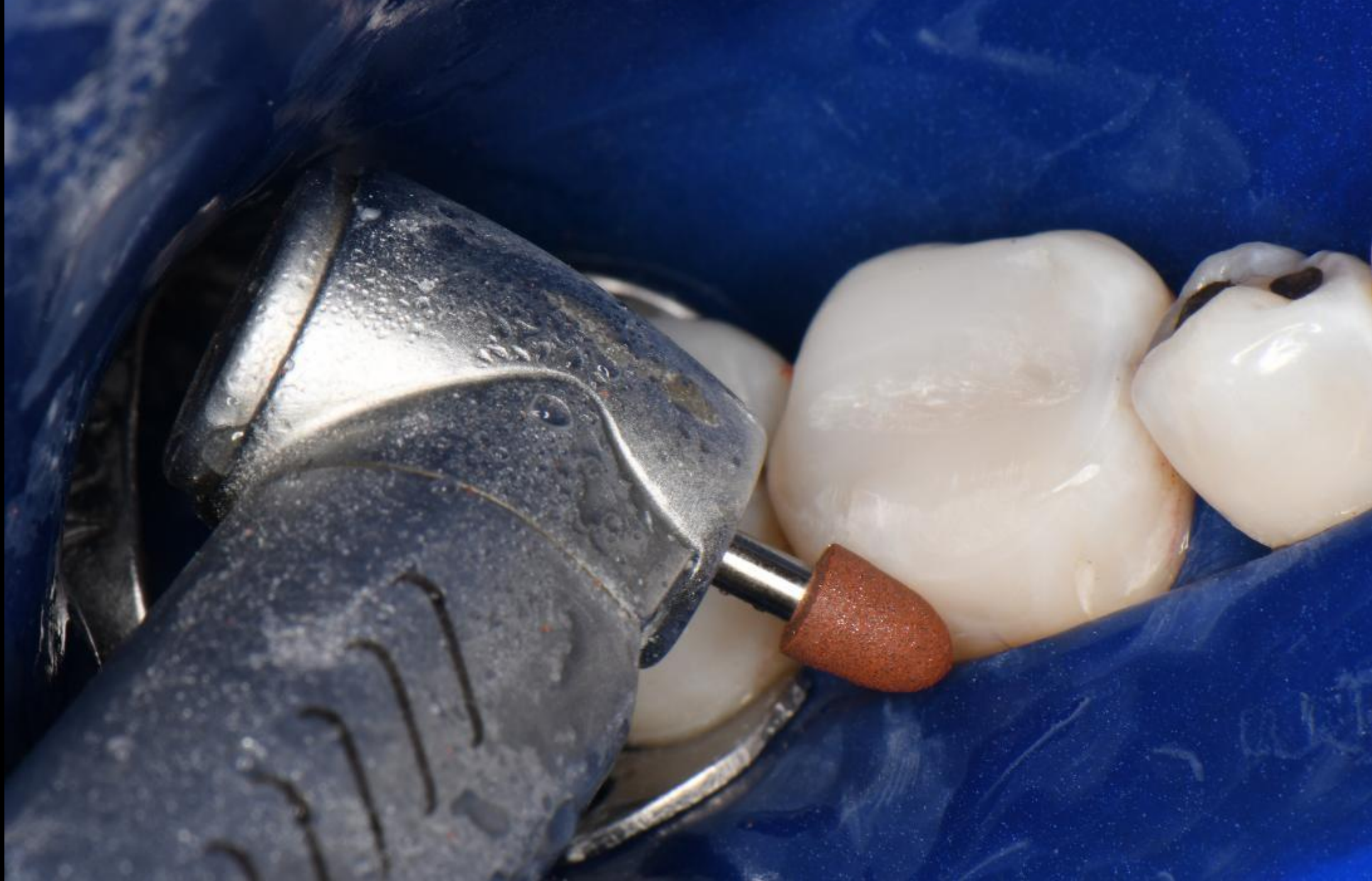


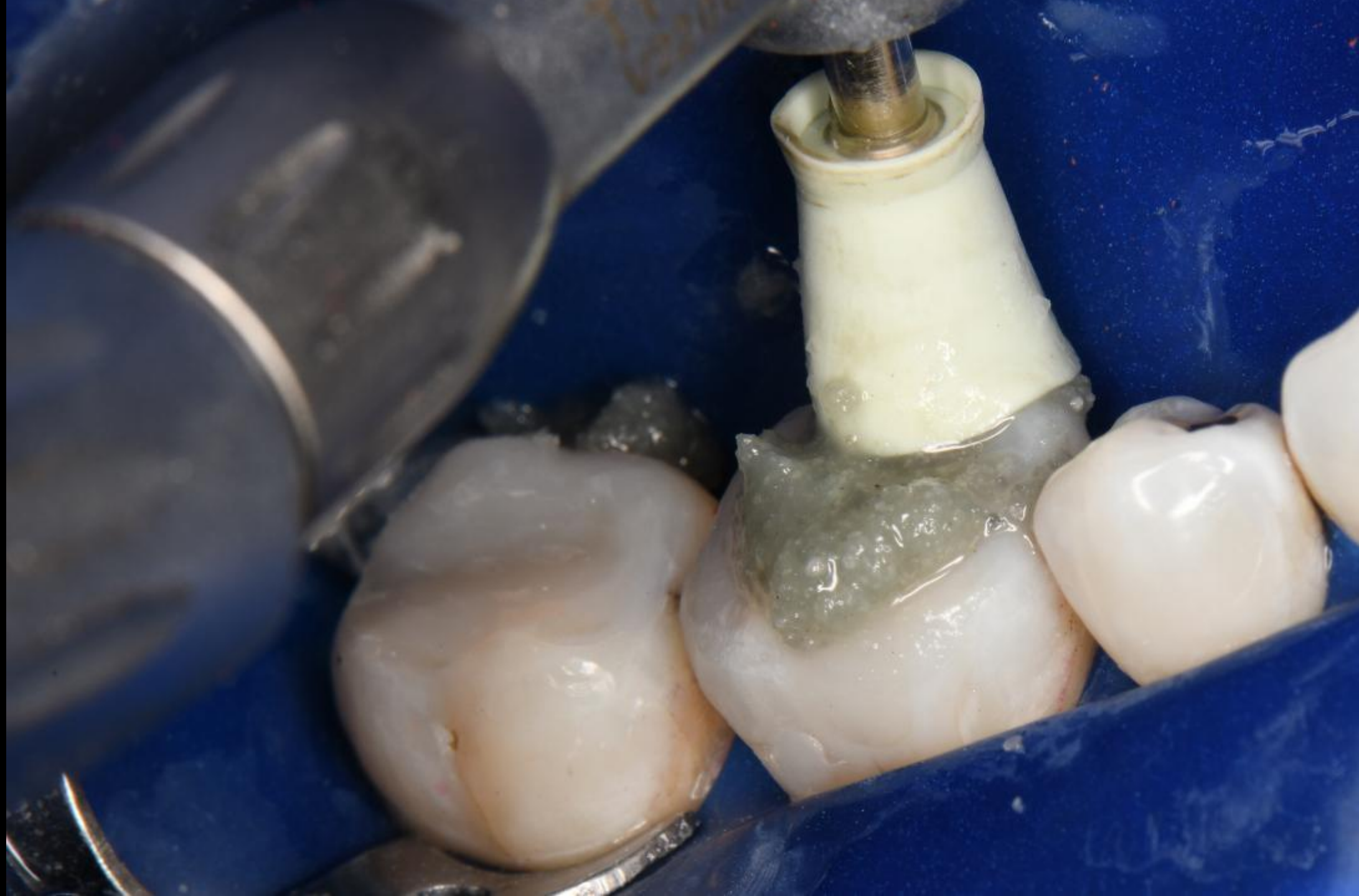


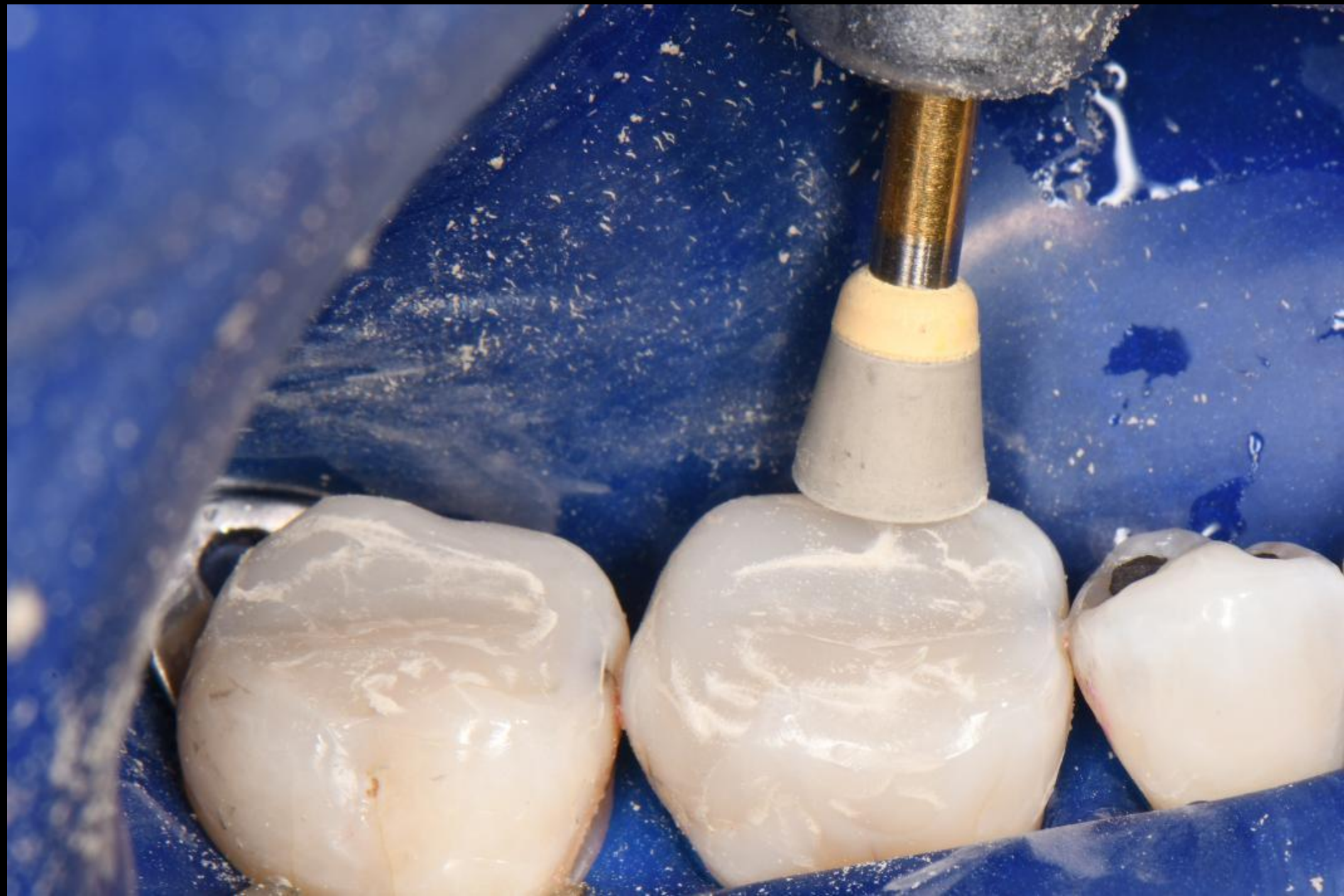


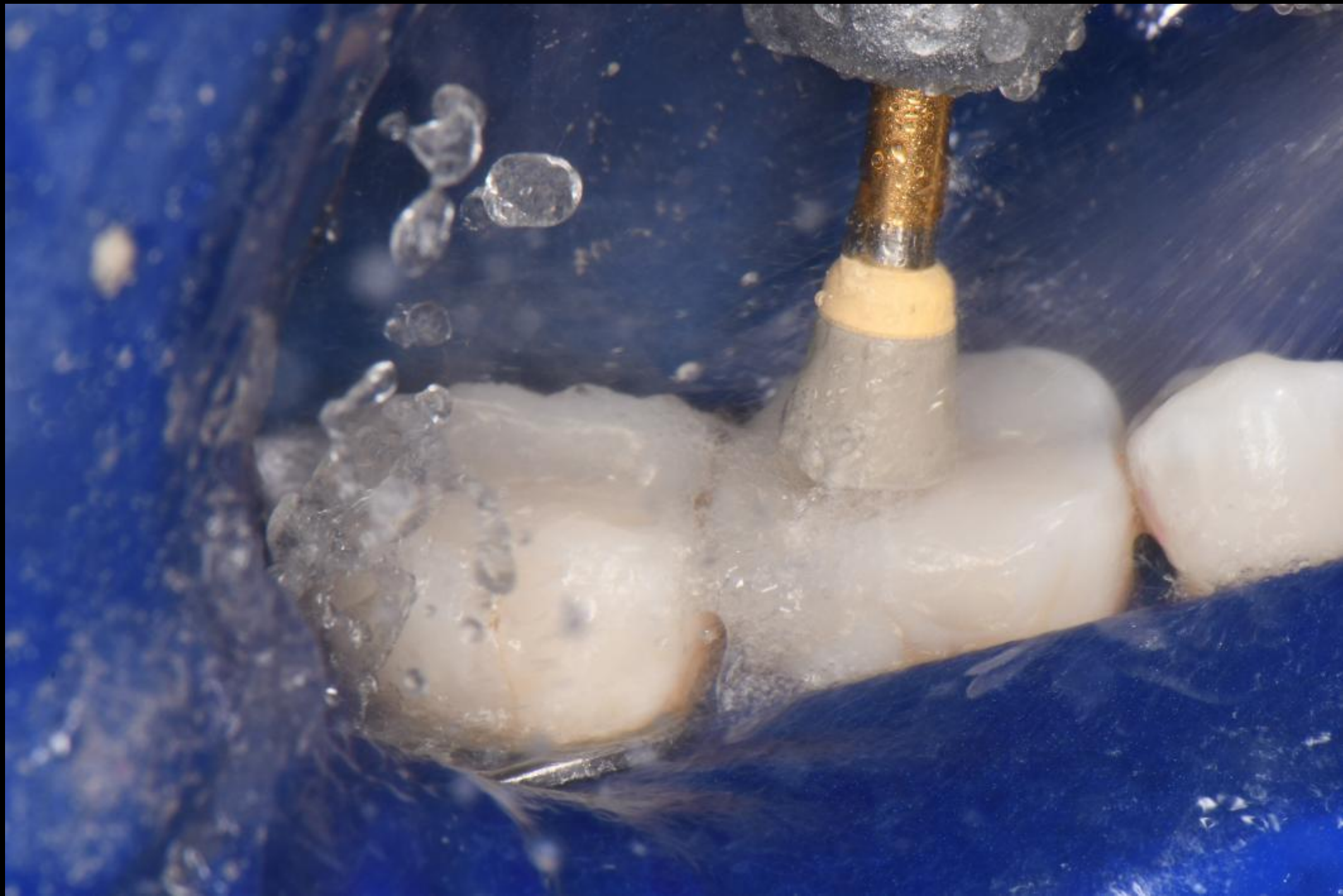
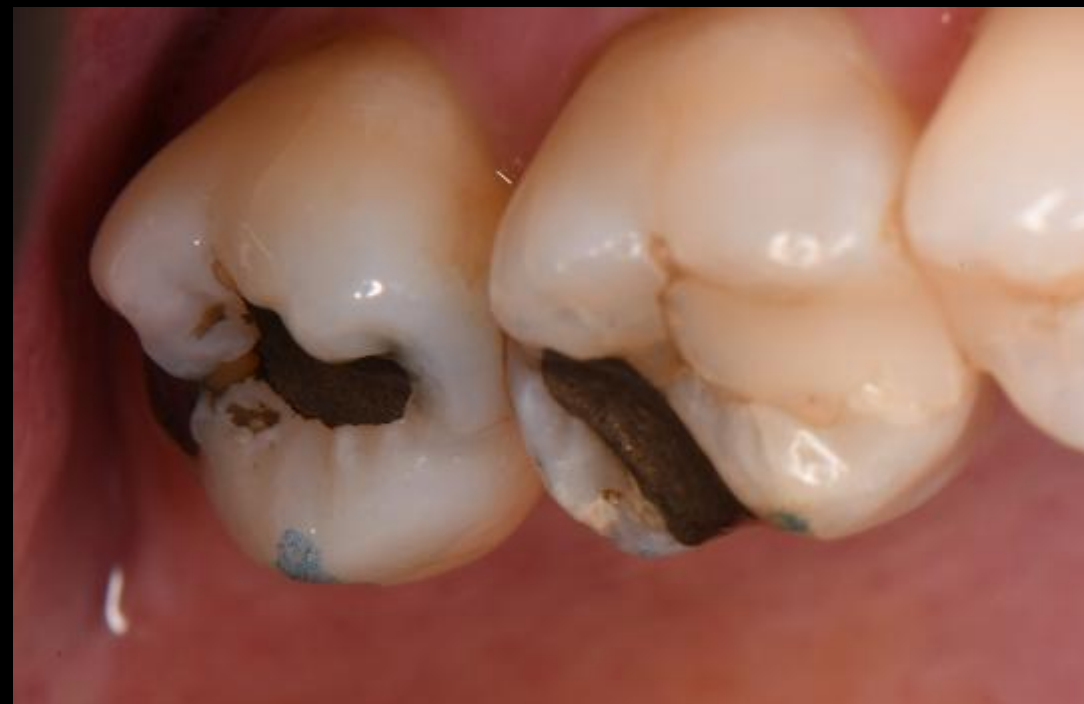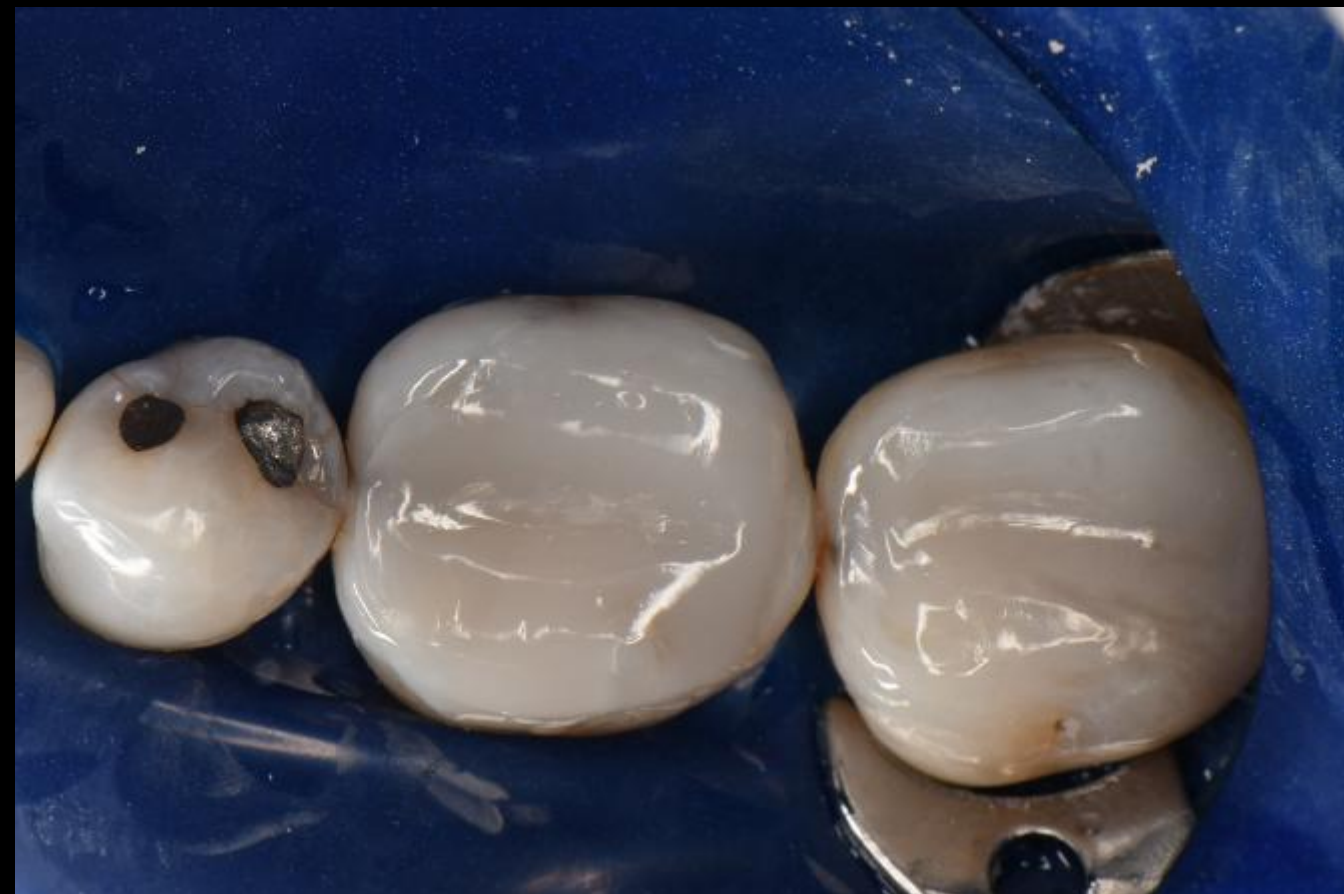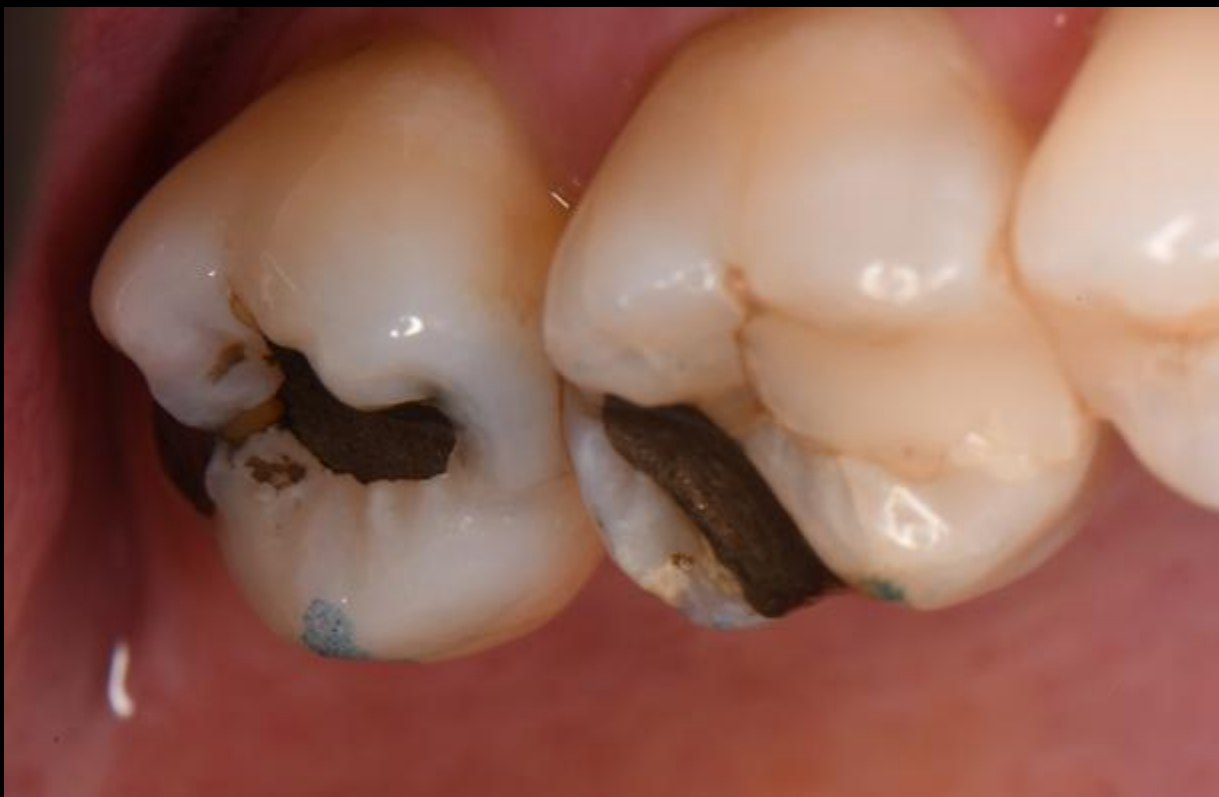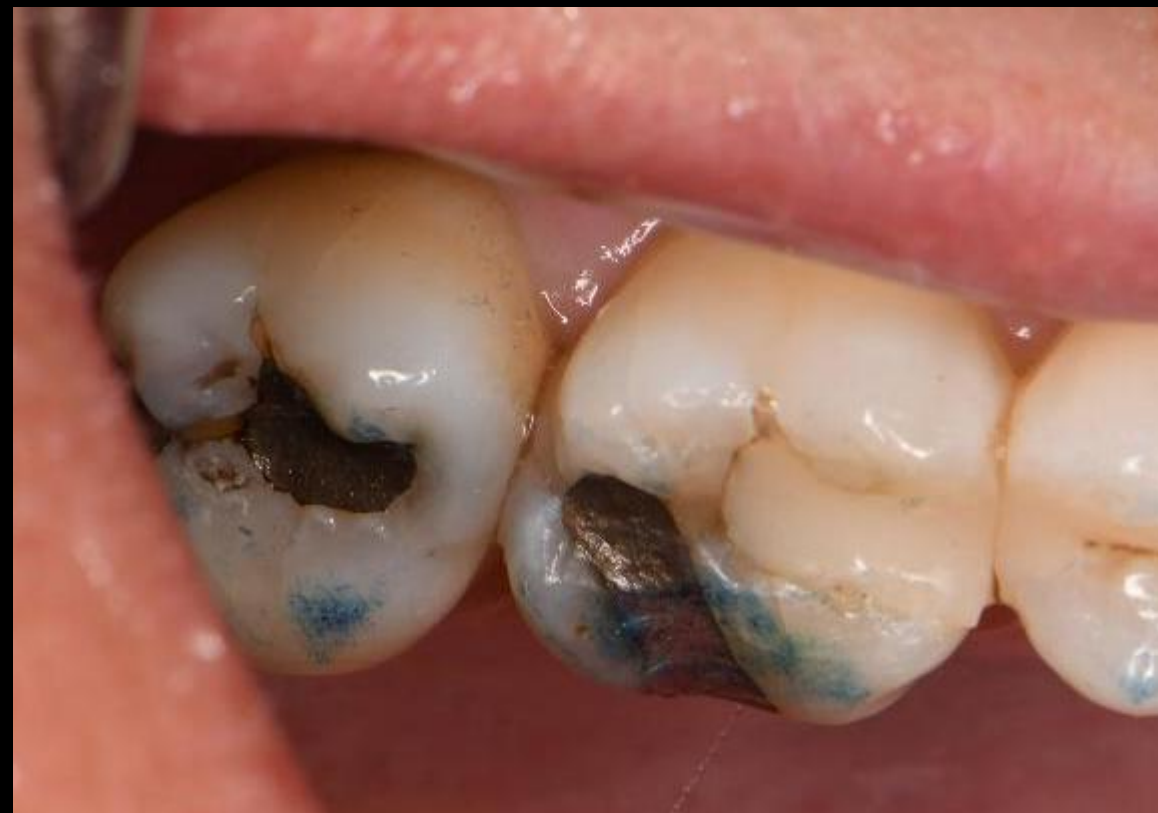Time to *harmonize* the occlusion



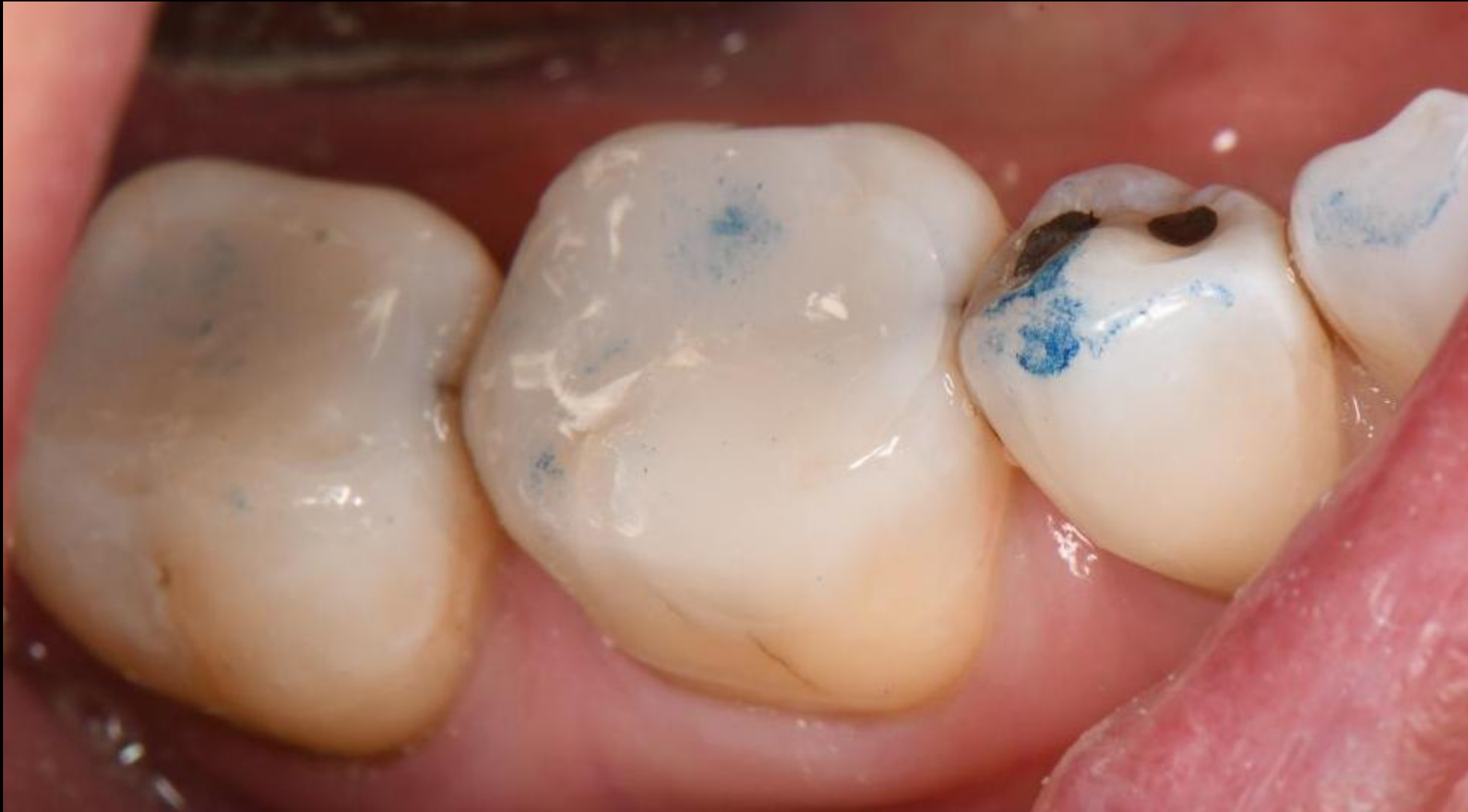

Before Harmonizing



After Harmonizing

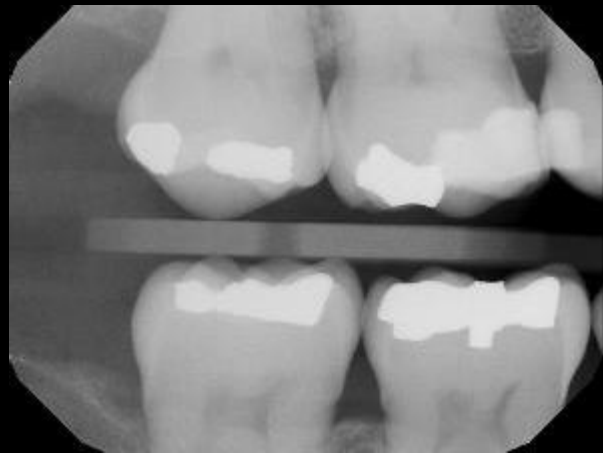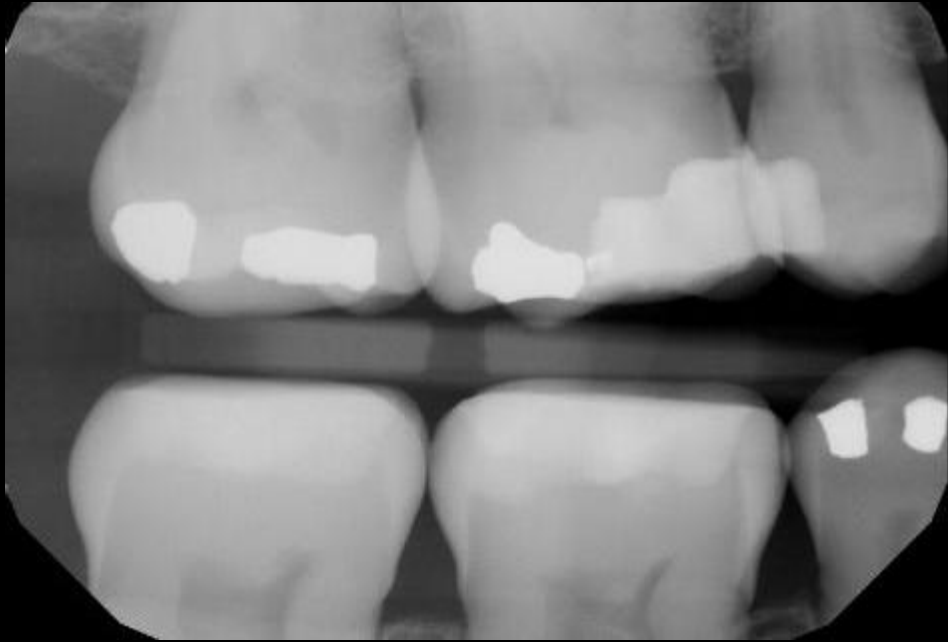Remember that composite absorbs 1% of its volume in water in 24 hours, so you need HYPO OCCLUSION on composite



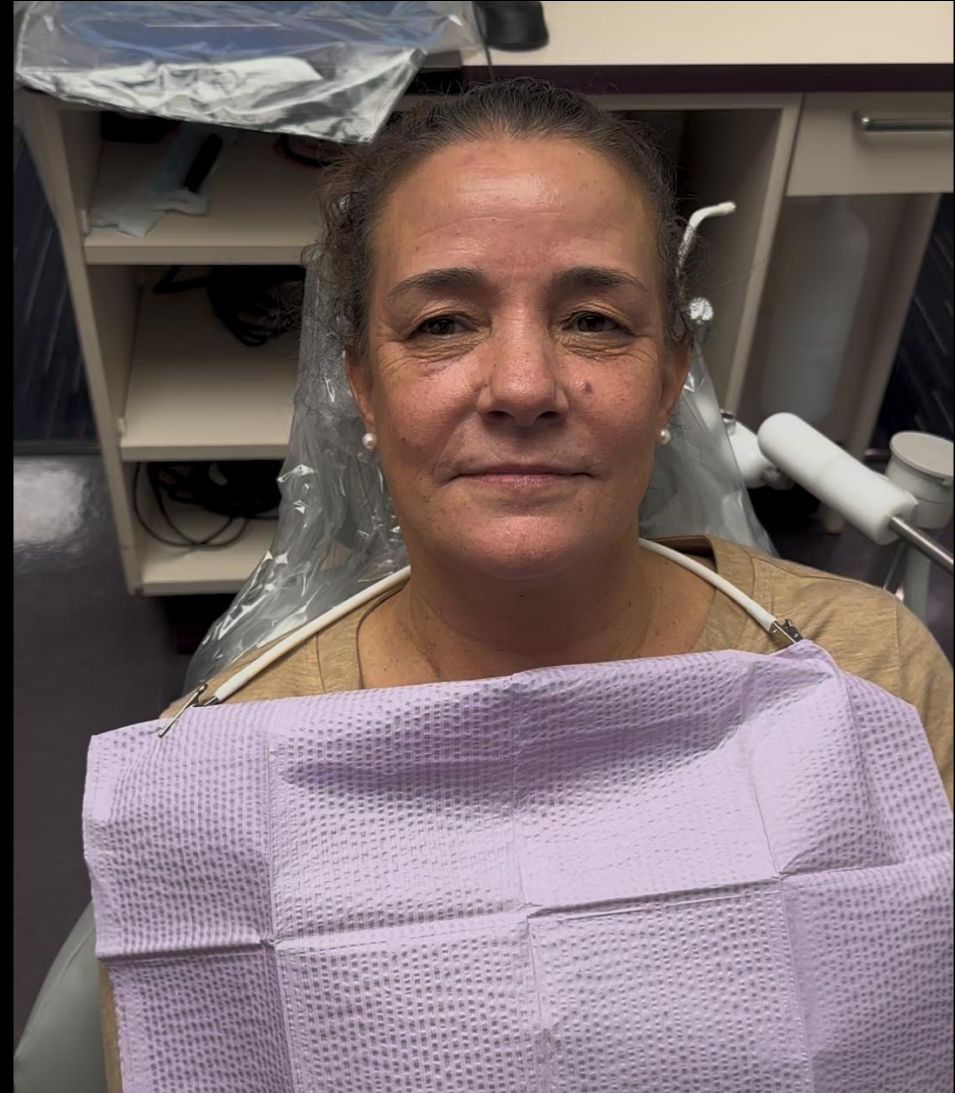6 week
follow up



2.5 year follow up



Pre-op

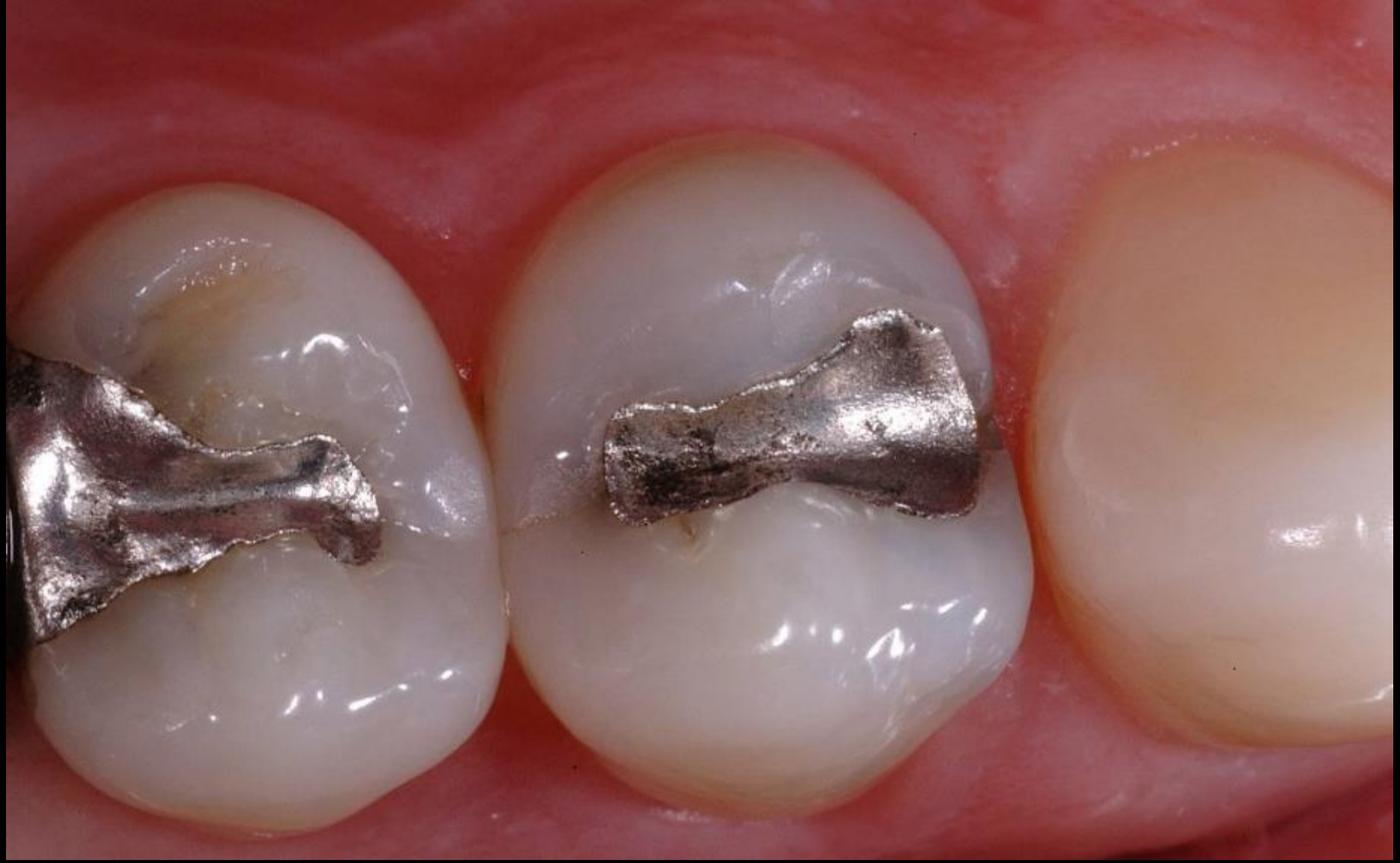

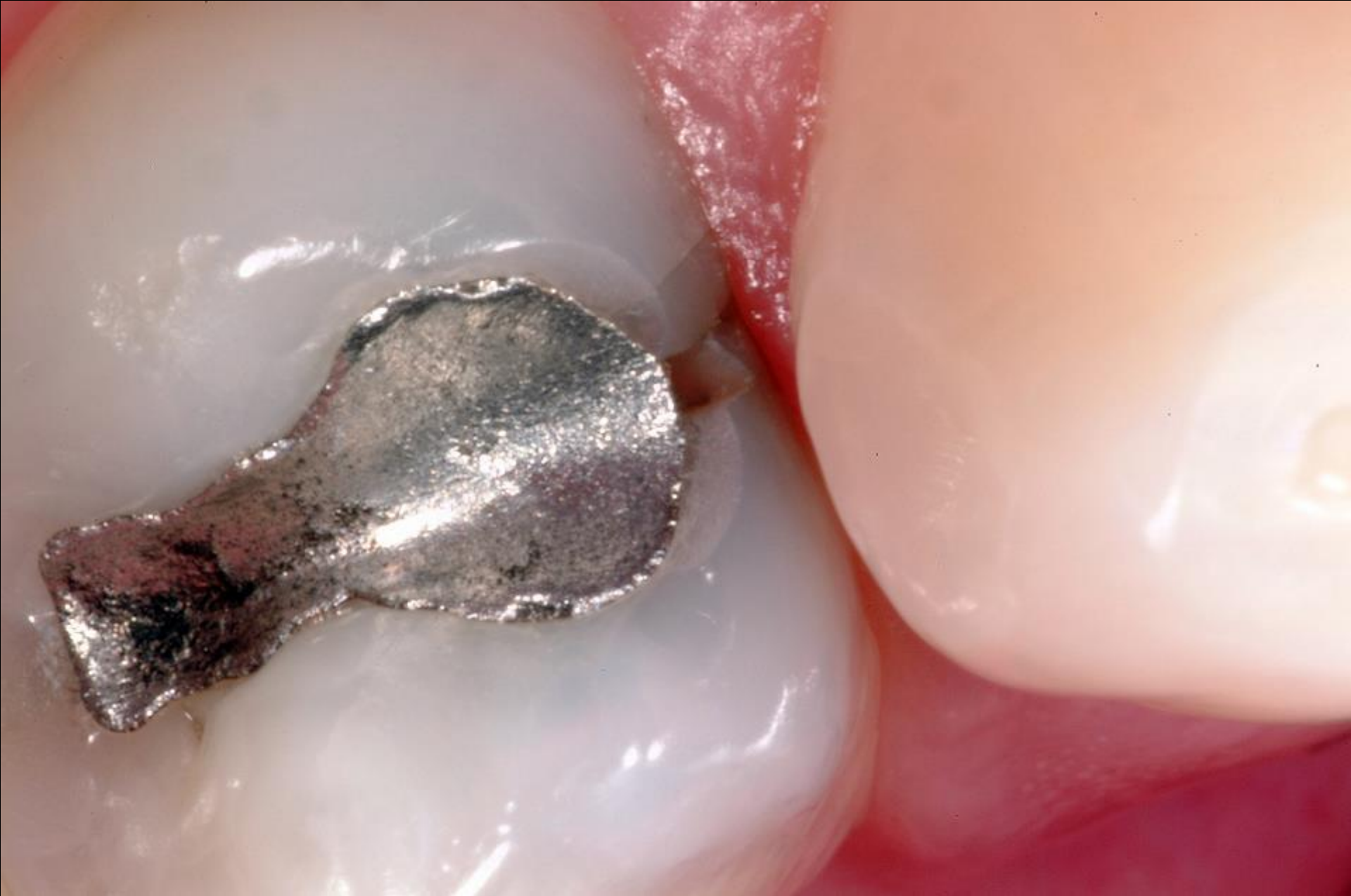What are the **modern occlusal** cavity preps?

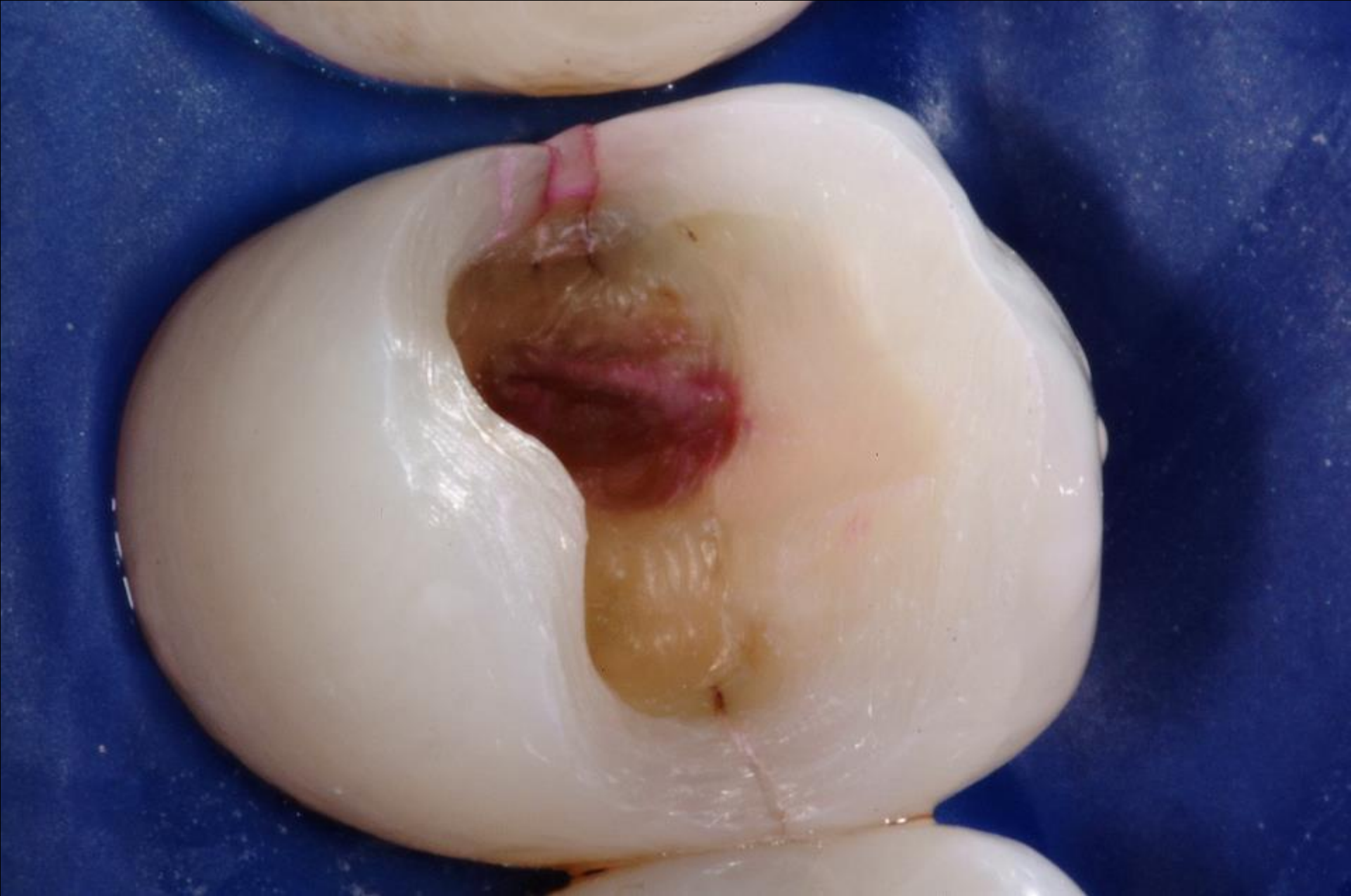1. Fissurotomy
2. Calla Lily
3. Flattened Calla Lily
4. Cuspal Overlay

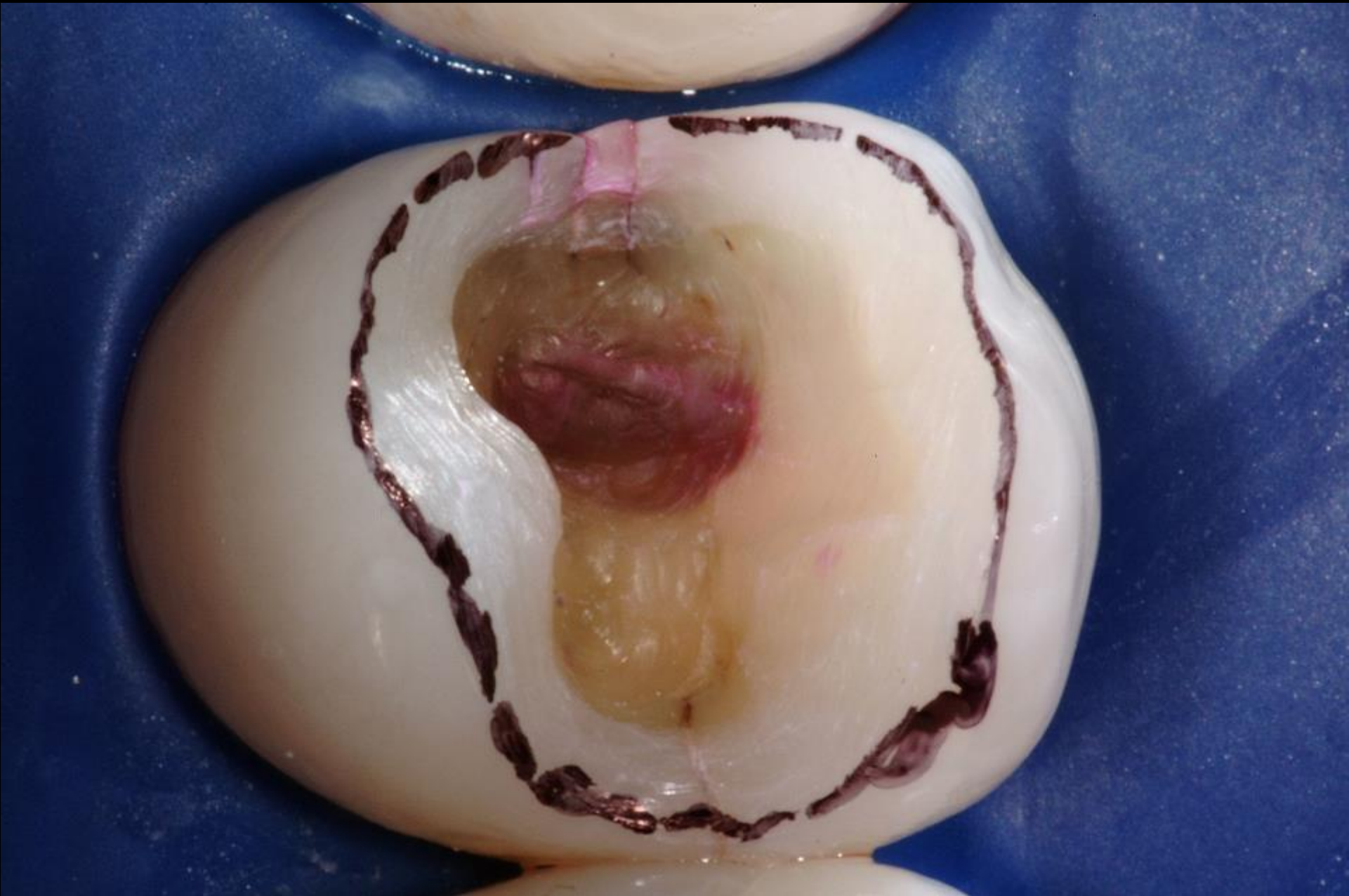What are the modern Interproximal cavity preps?

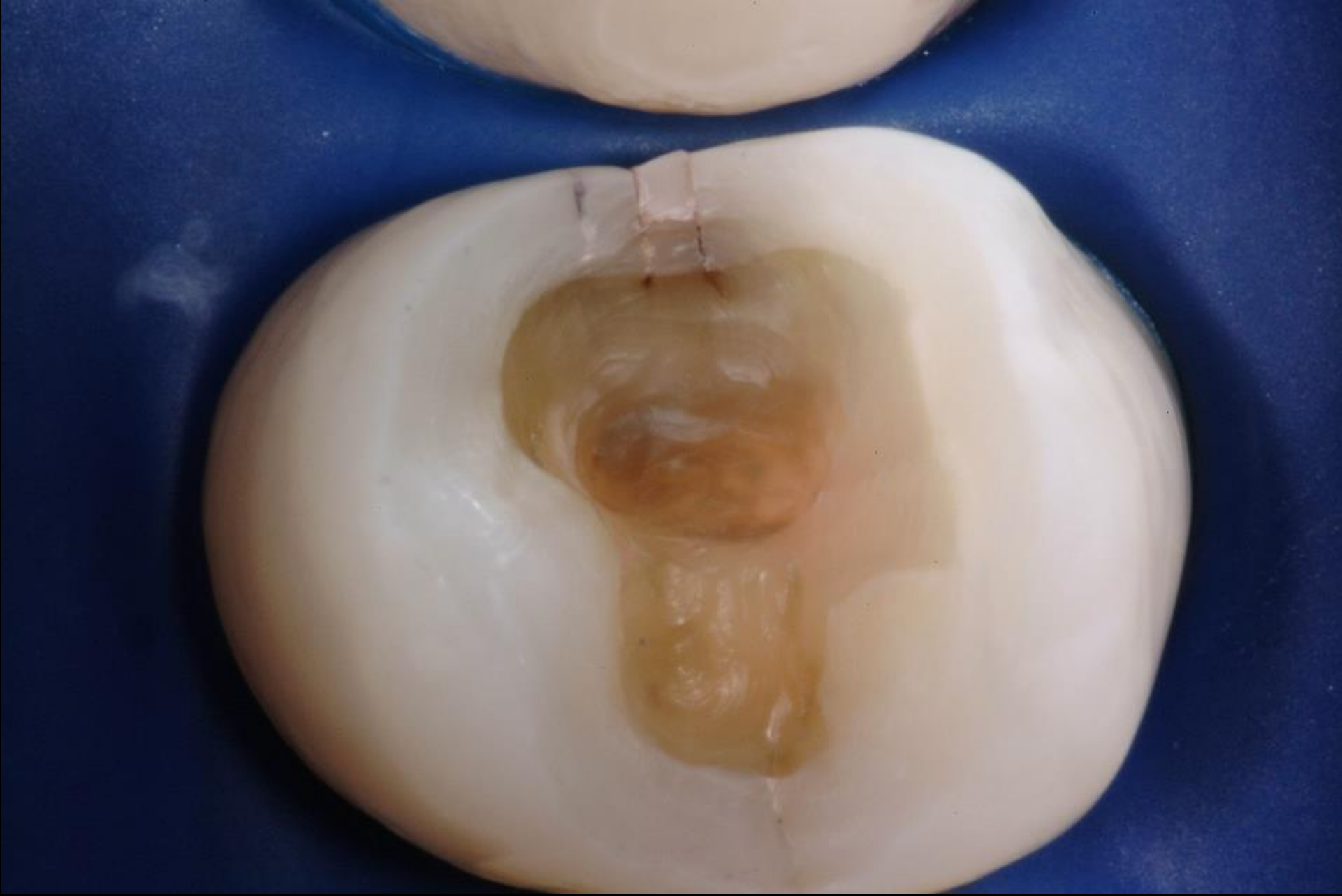1. Opportunistic Class II
2. Clark Class II...double serpentine,
additive and compression based
3. Clark Class II plus Lateral Partial
Cuspal Overlay

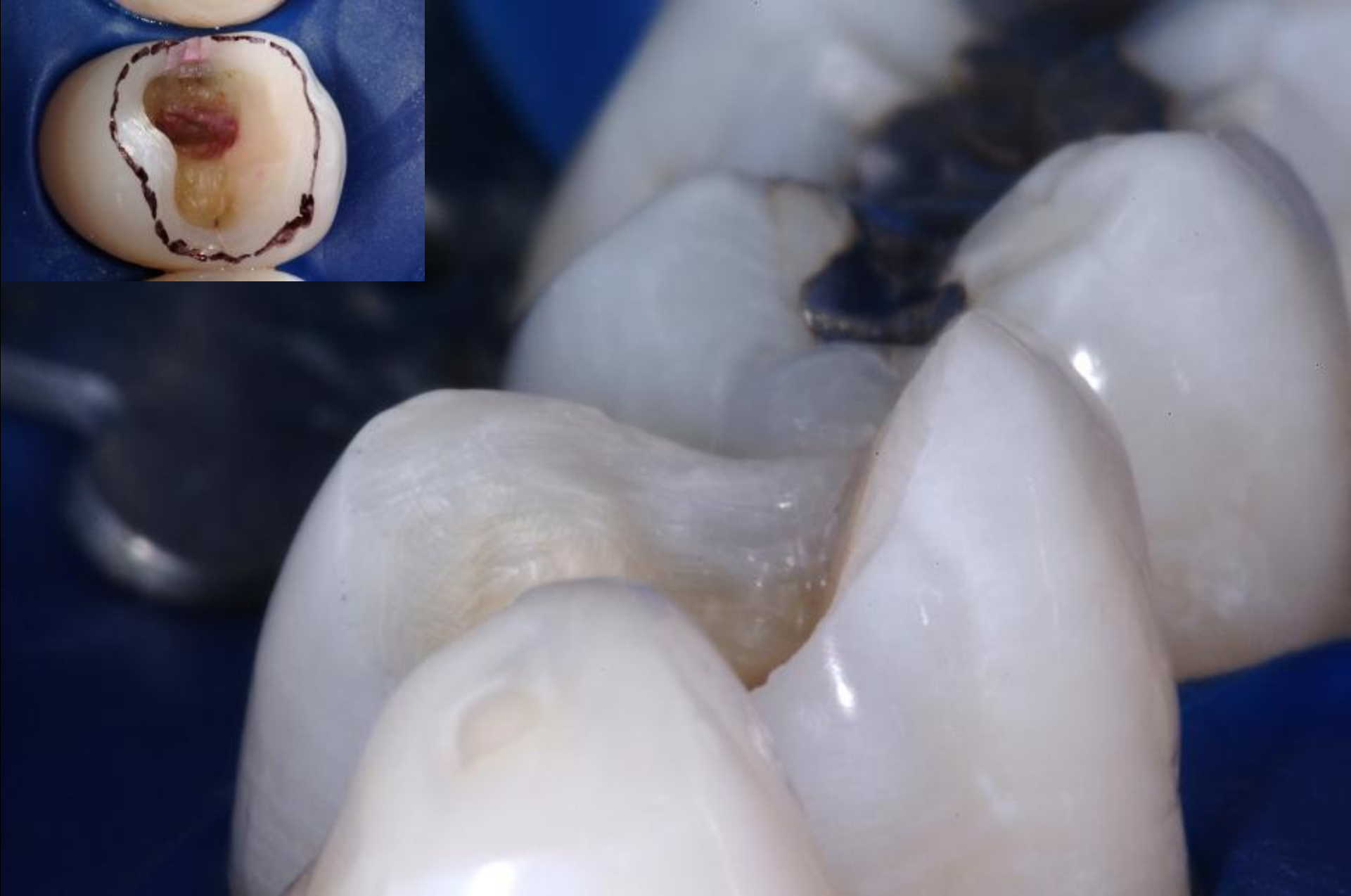
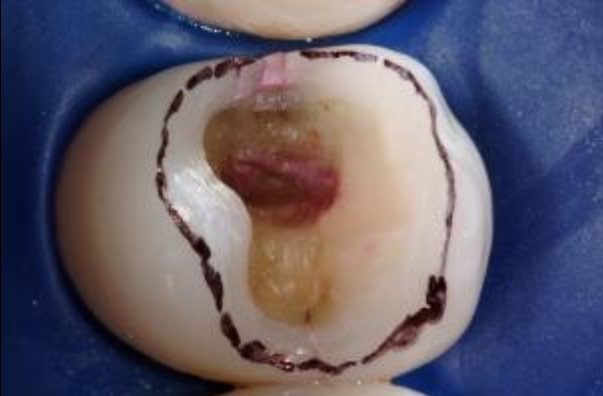




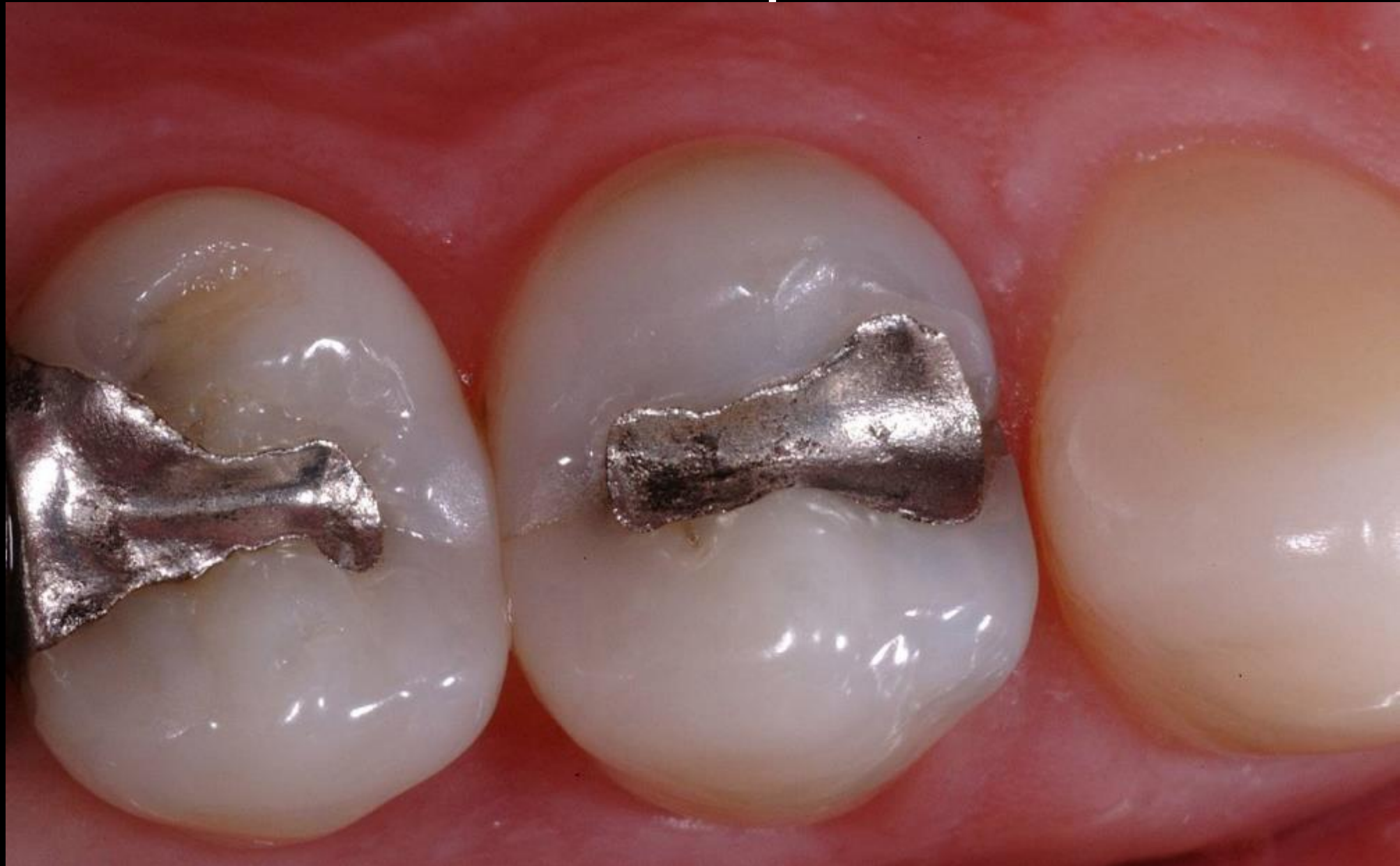




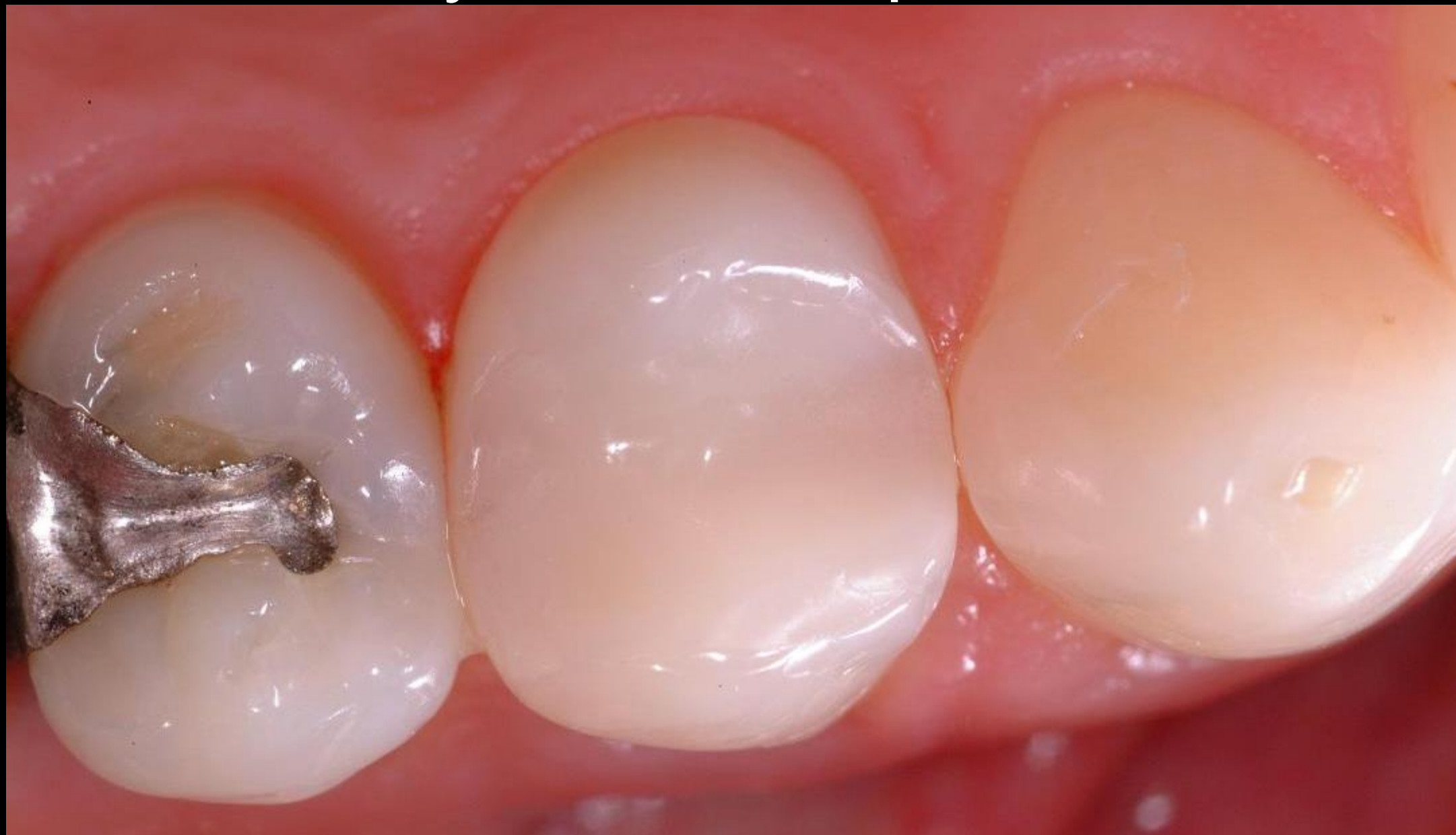
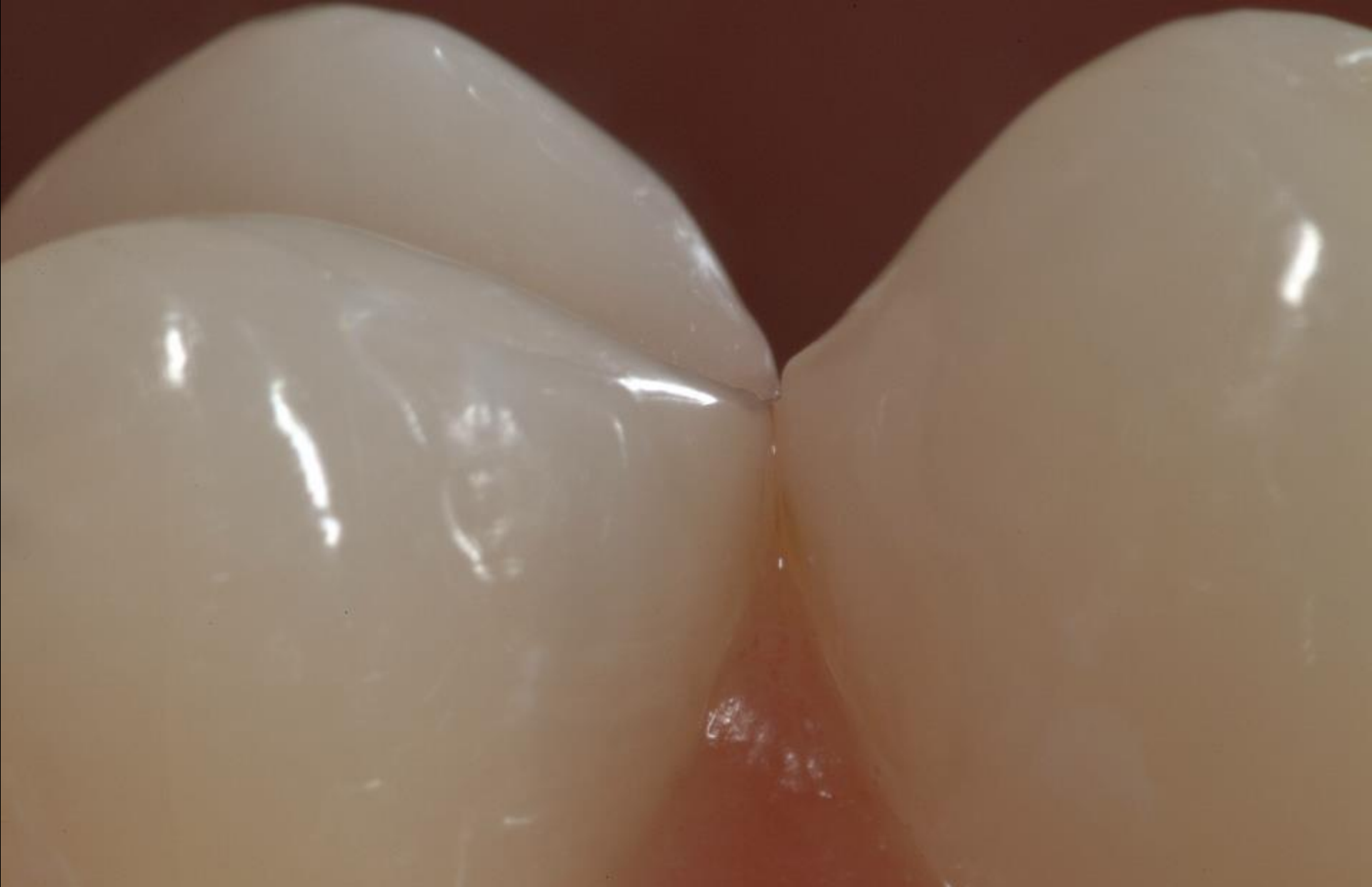Pre-op



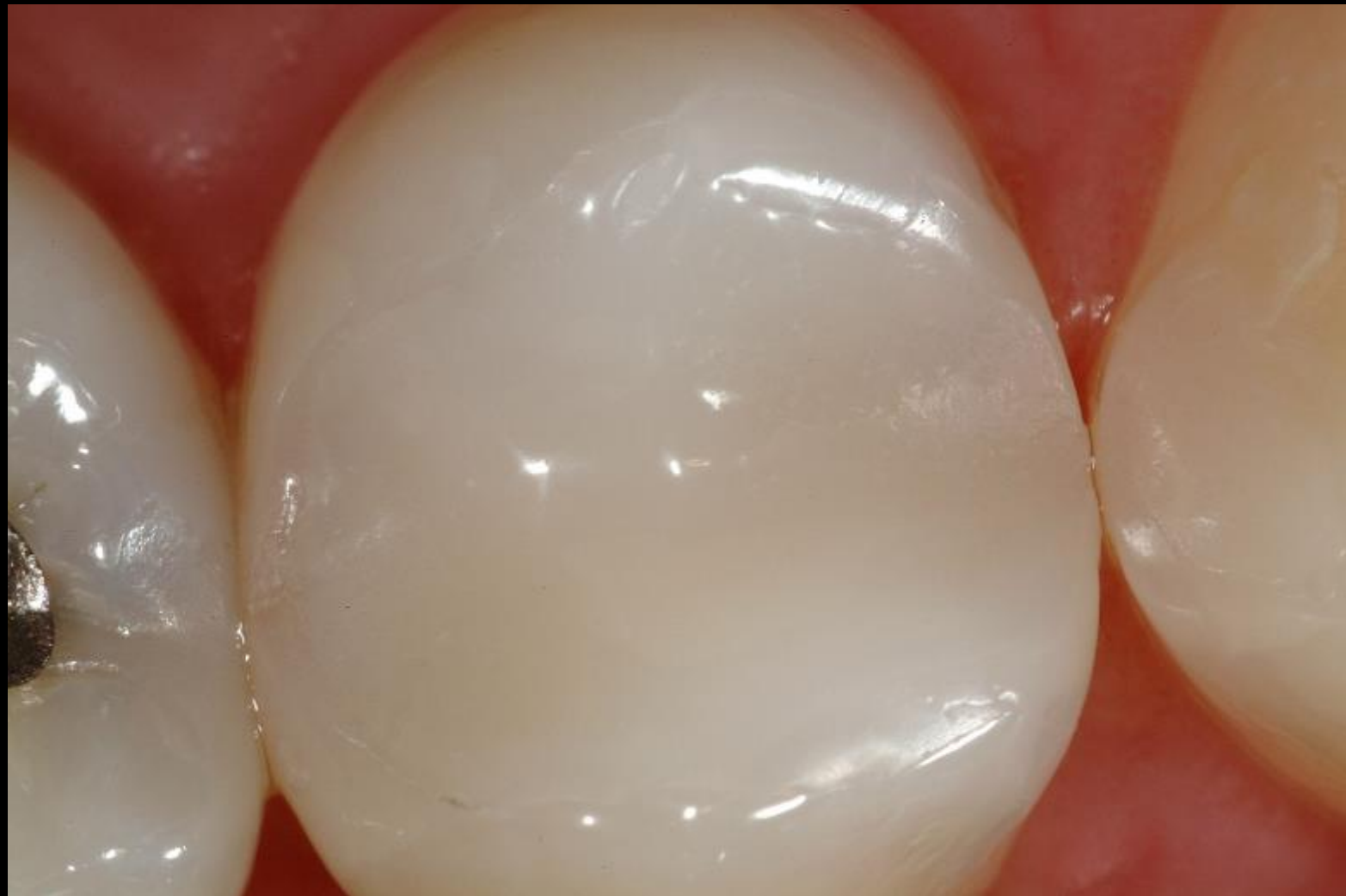1 year follow up



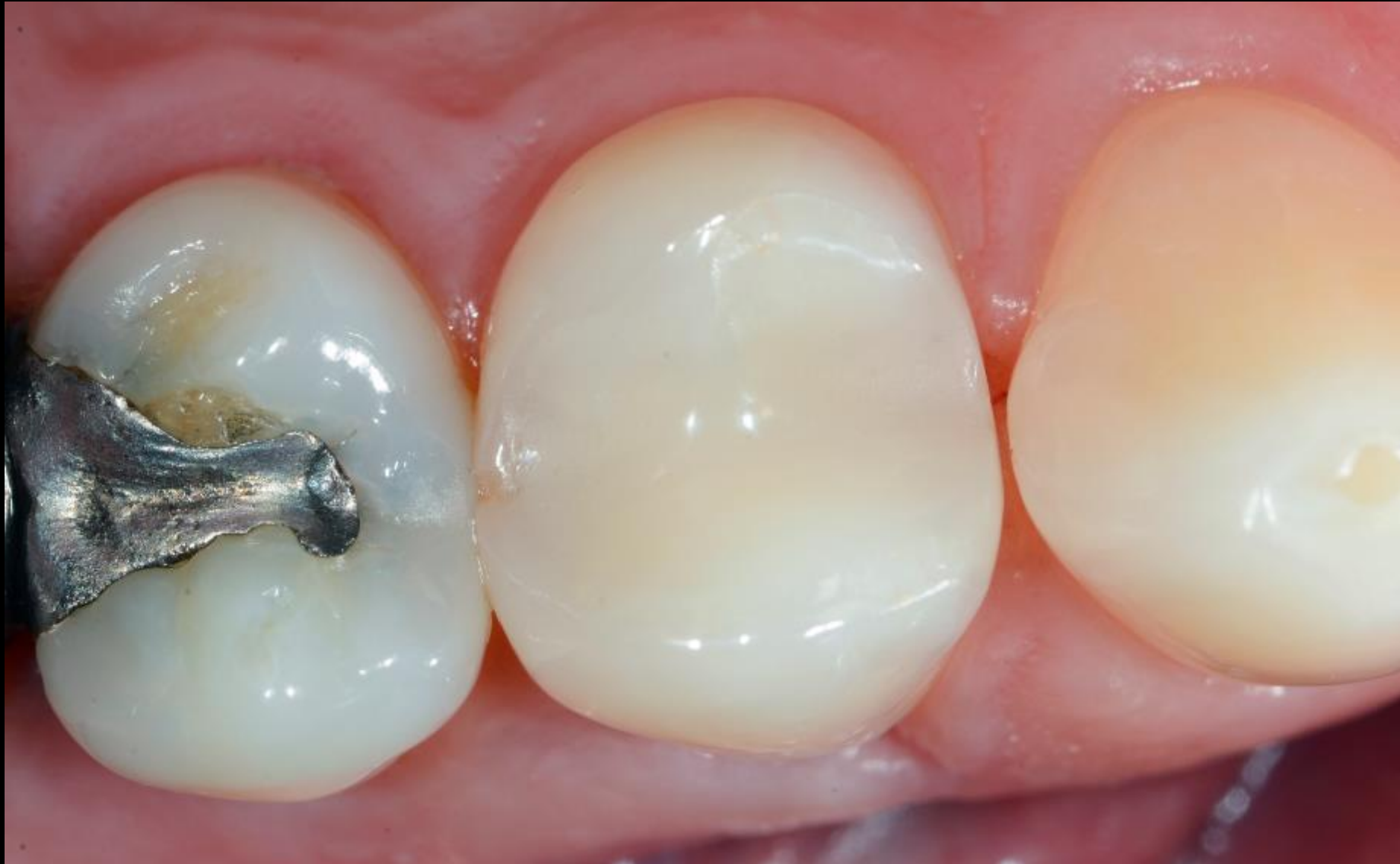1 year follow up



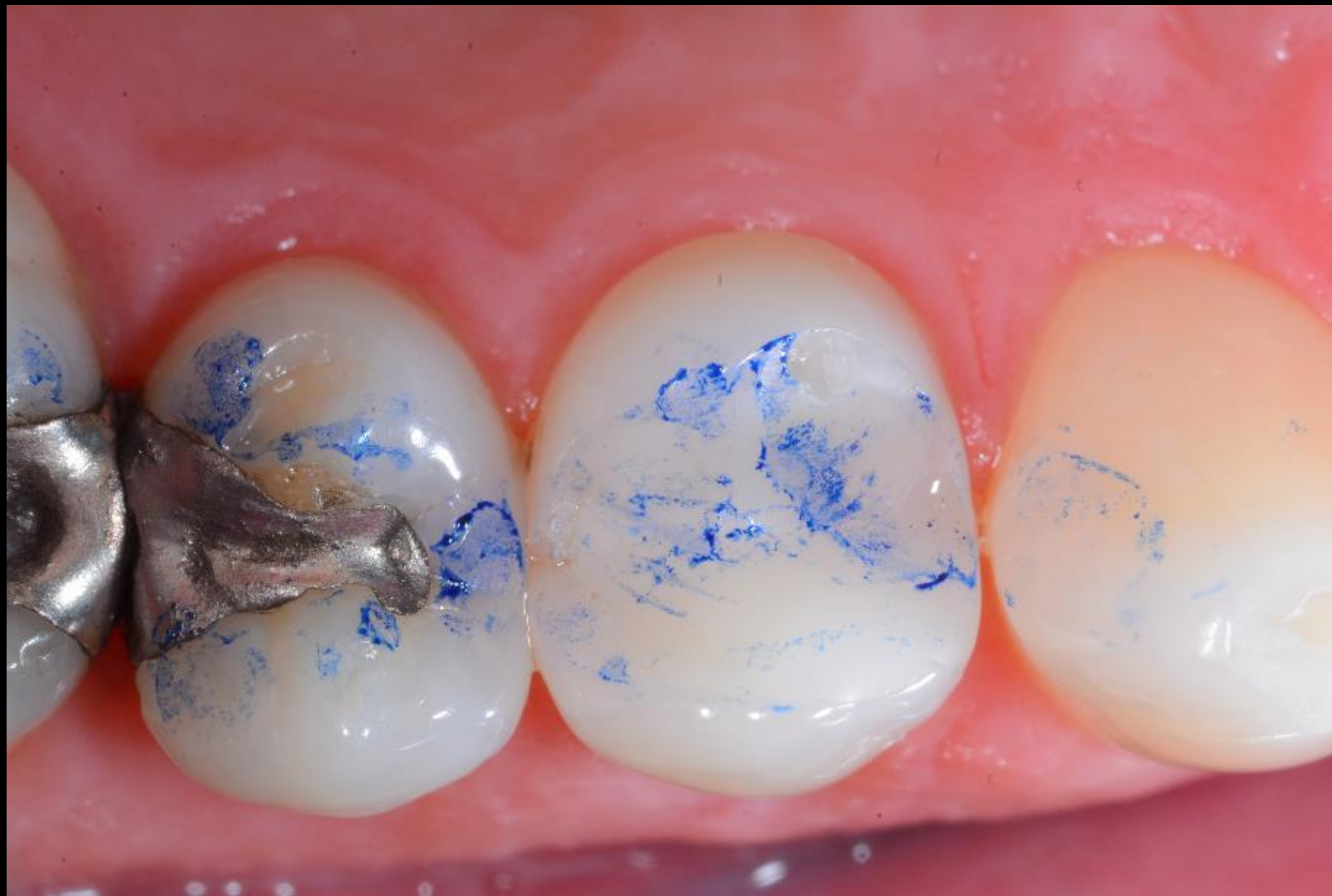2 year follow up



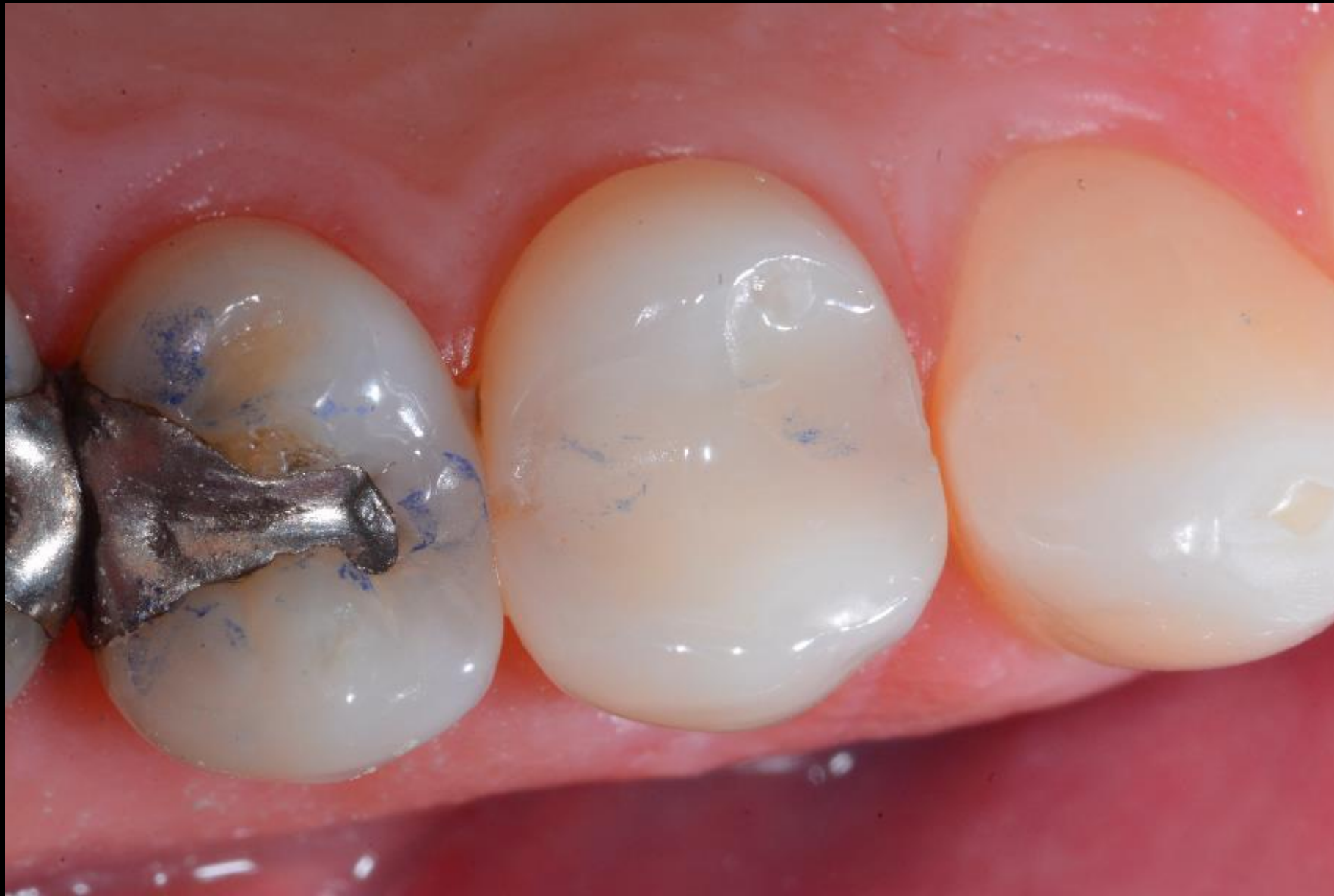7 year follow up



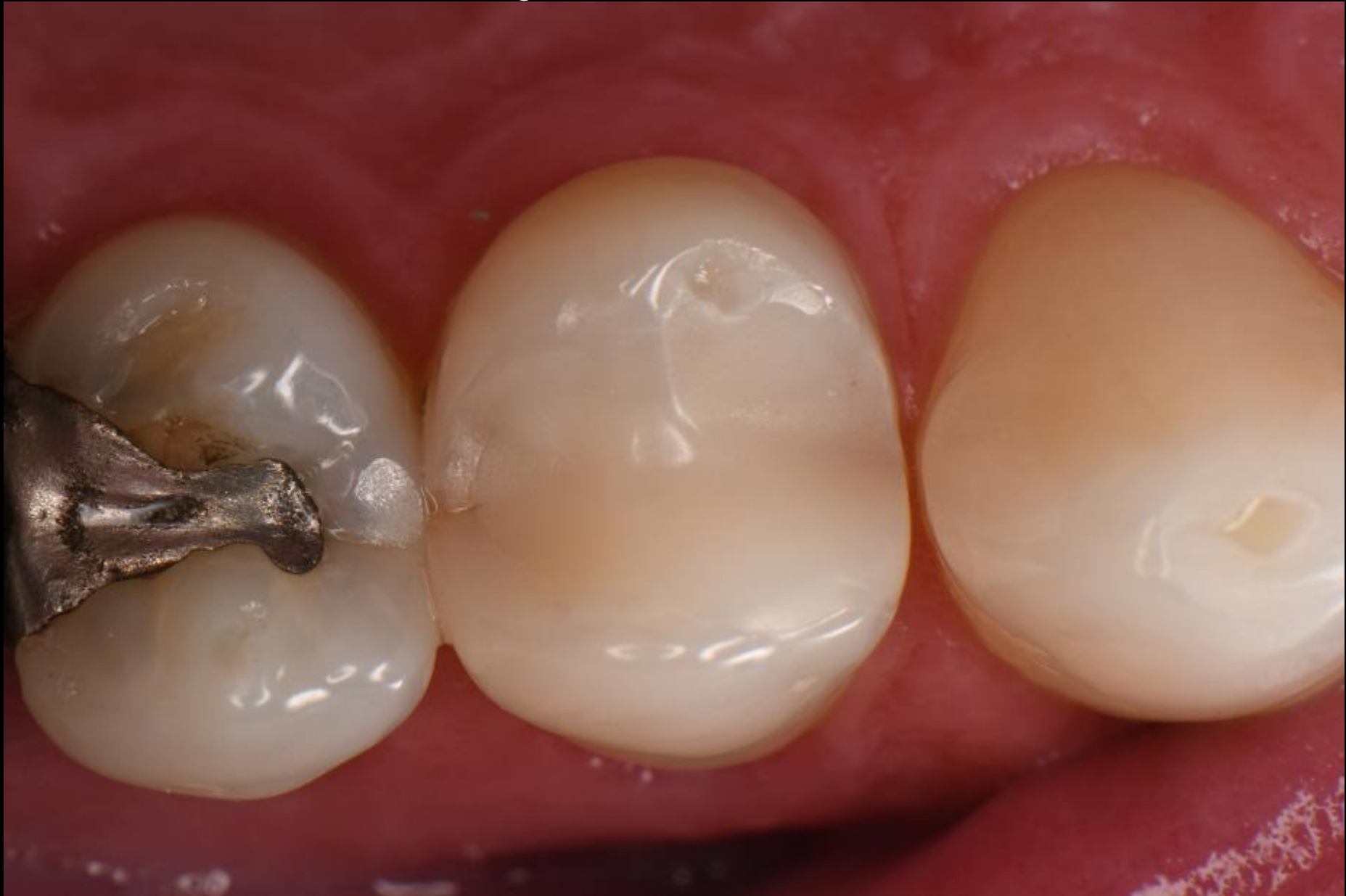9 year follow up



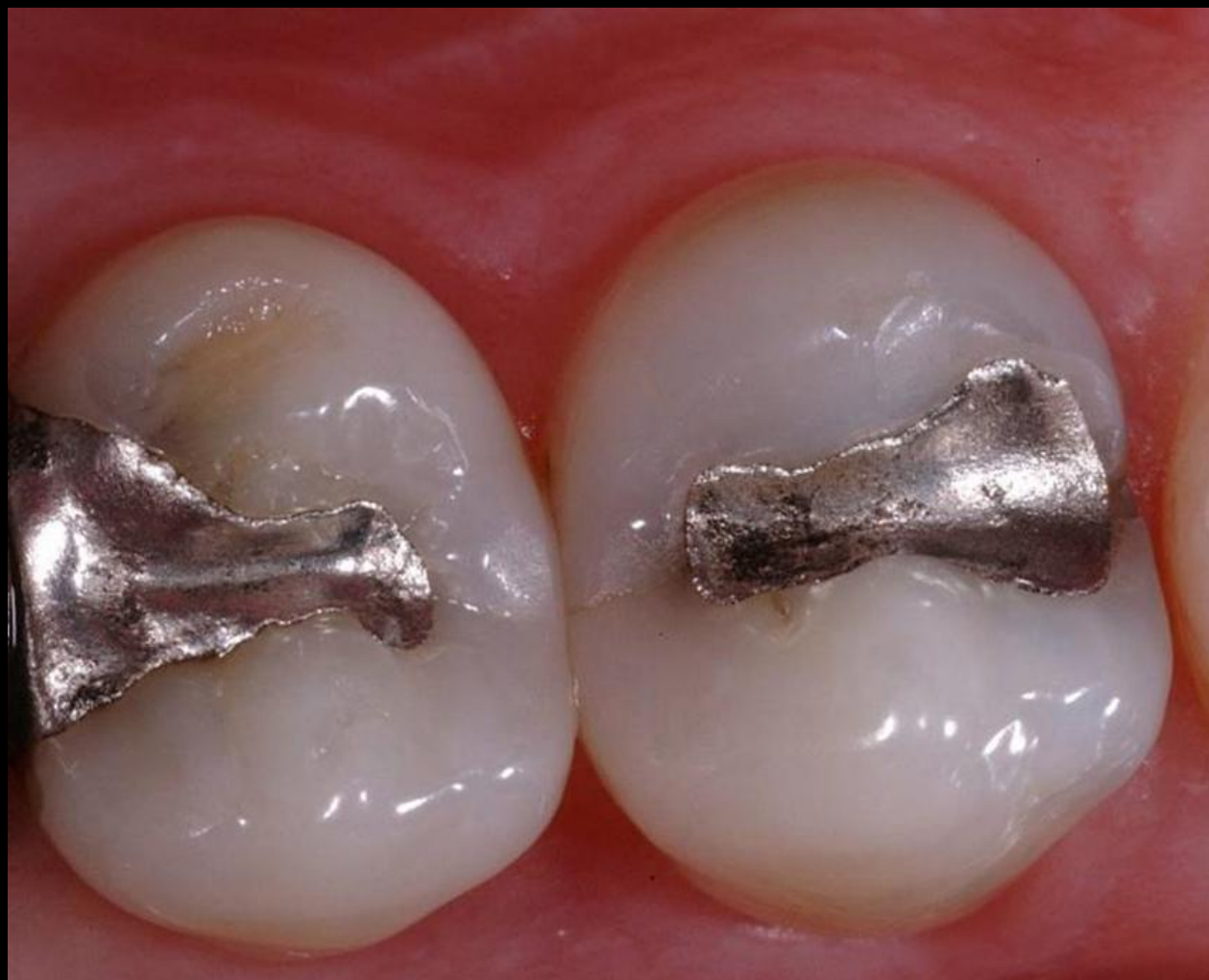9 year follow up



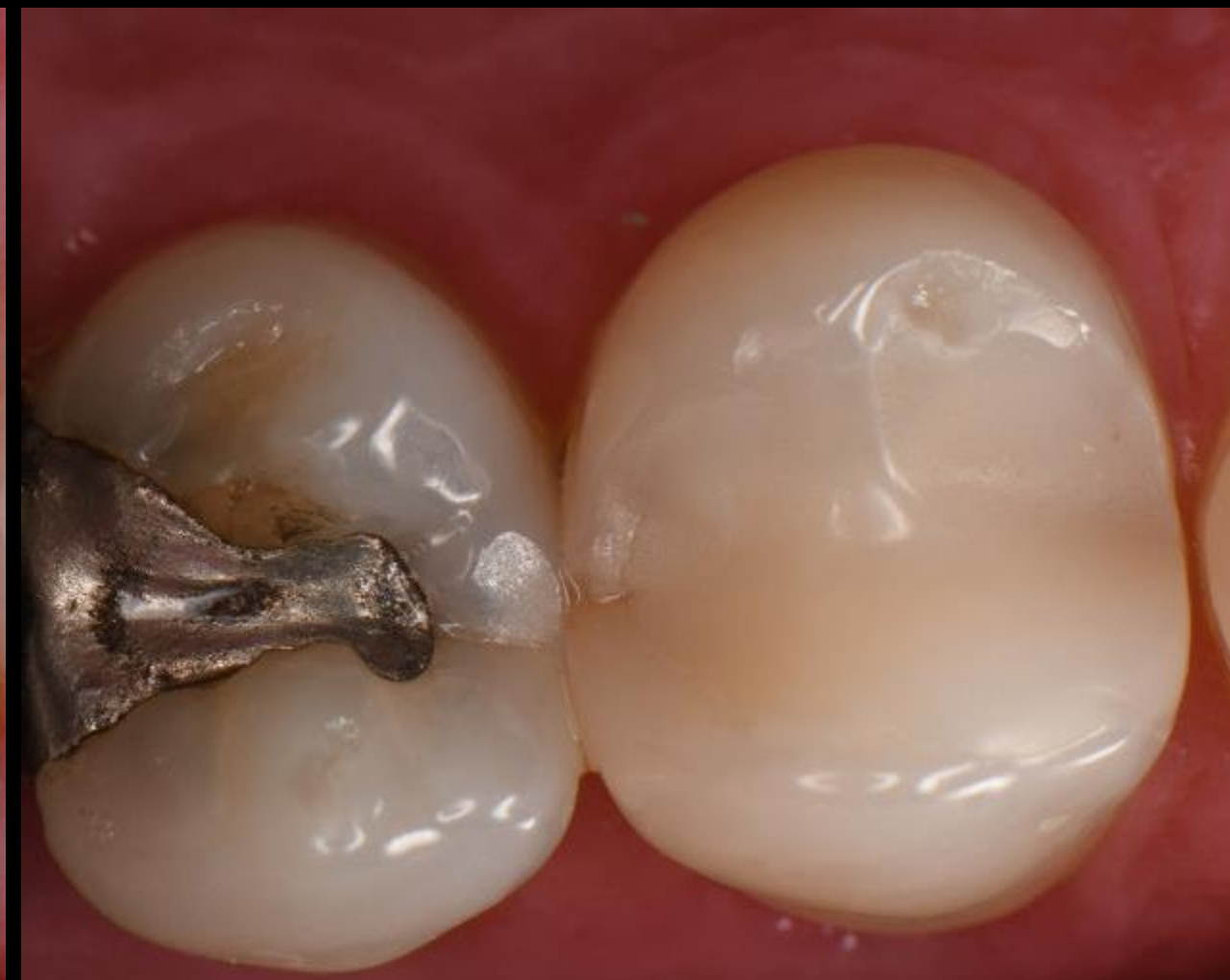12 year follow up



Pre-op

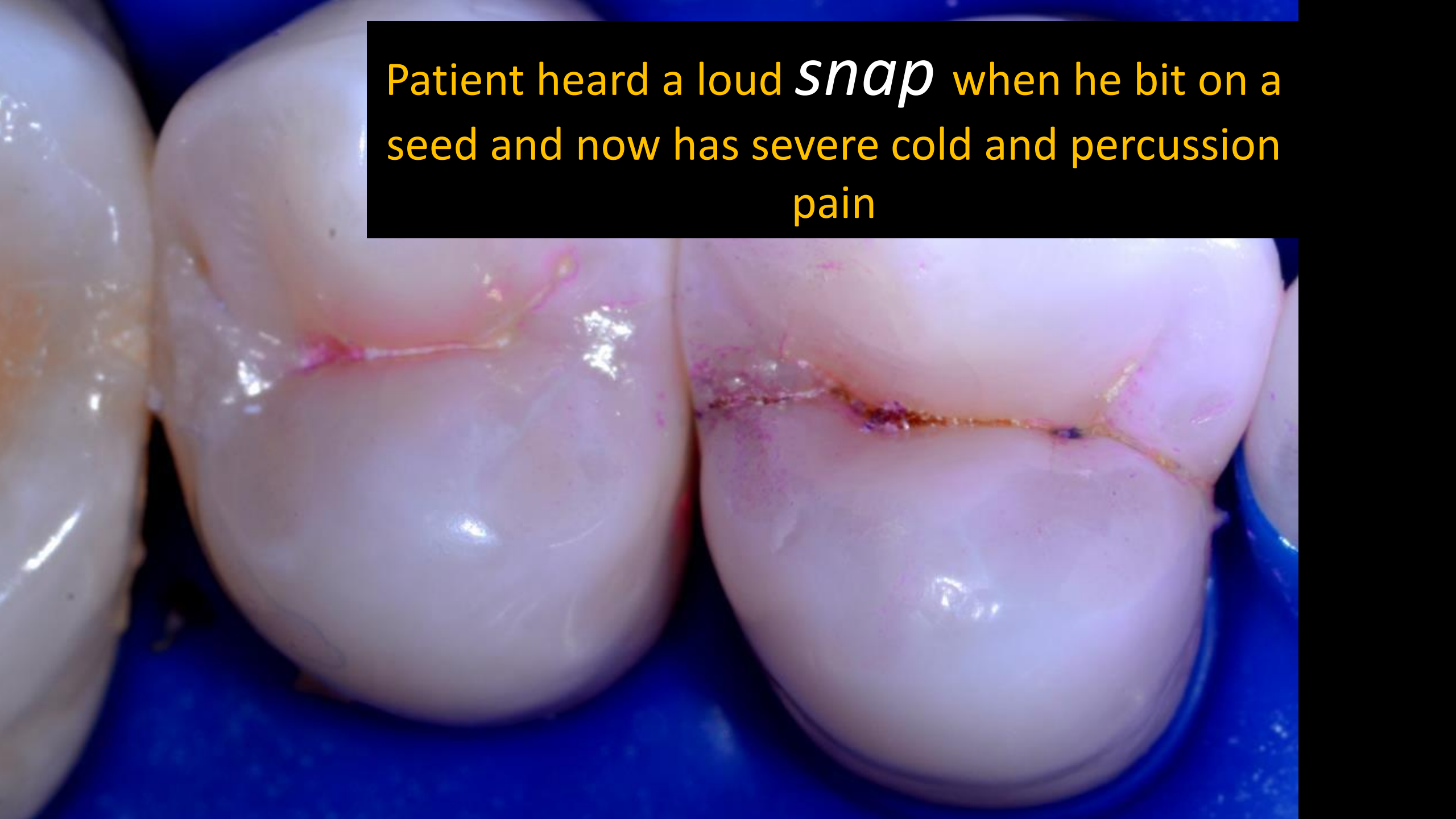

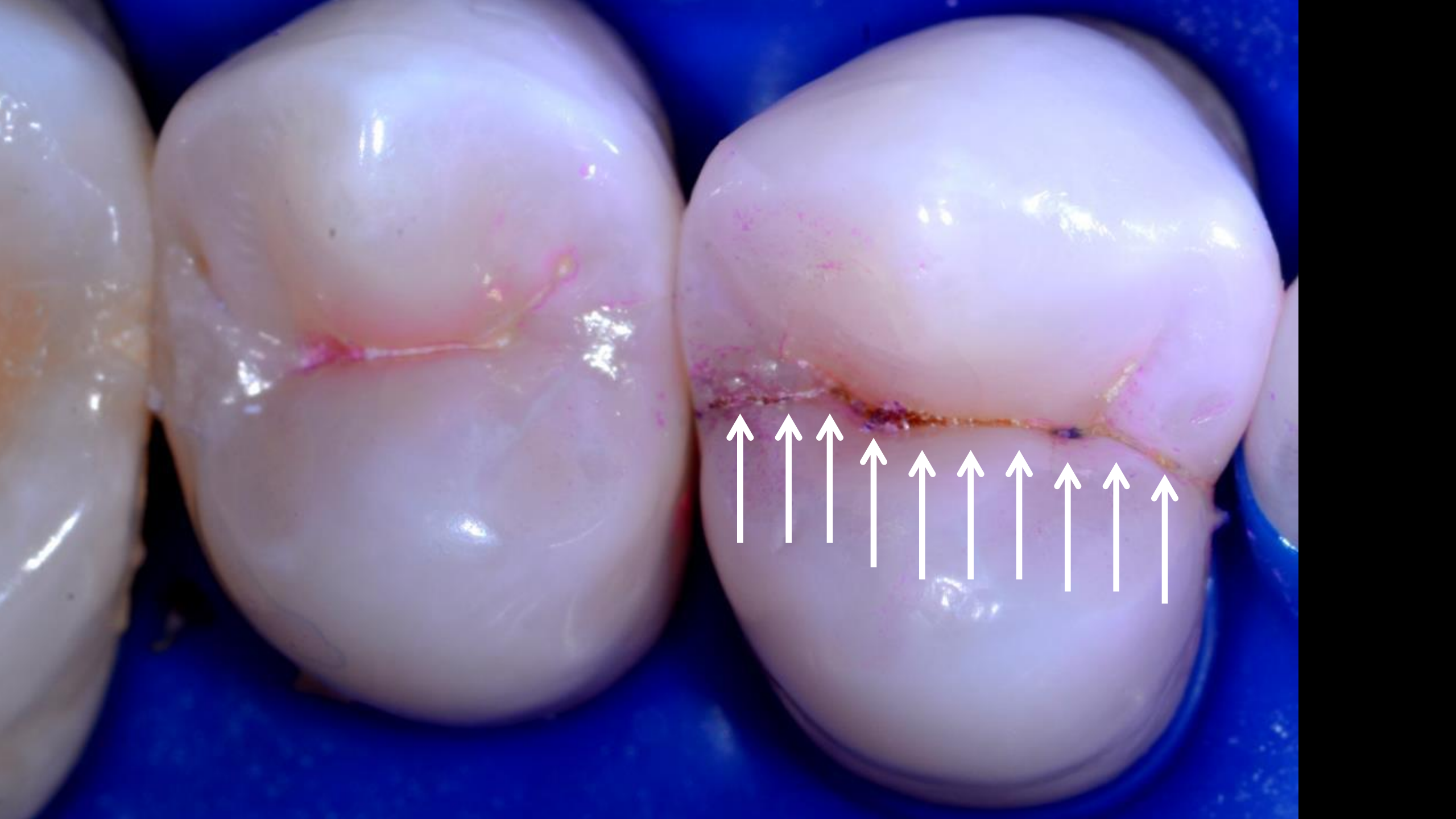
12 year follow up



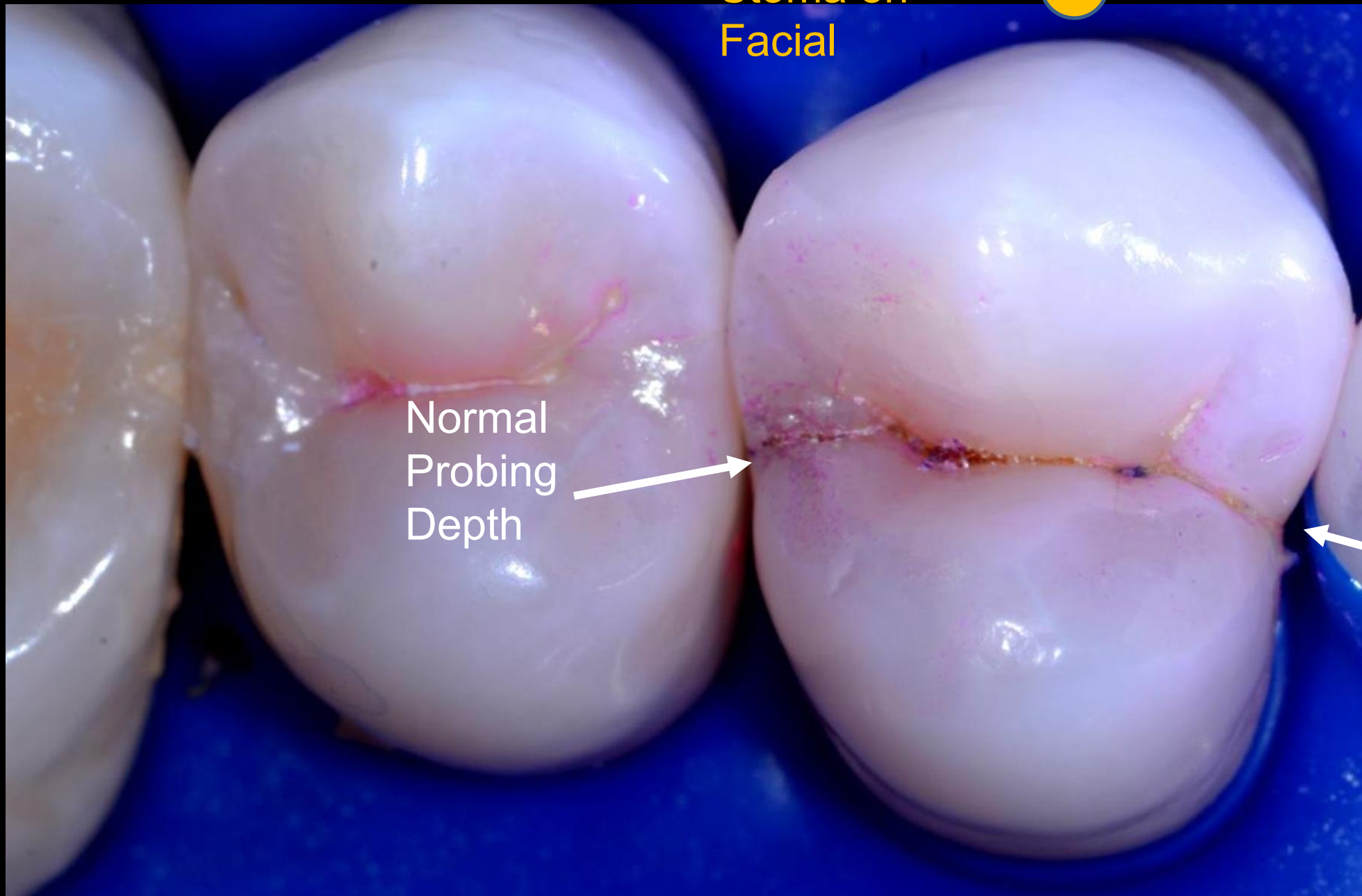
An Extreme Calla Lily Clinical Case

Patient heard a loud *snap* when he bit on a seed and now has severe cold and percussion pain





Stoma on
Facial

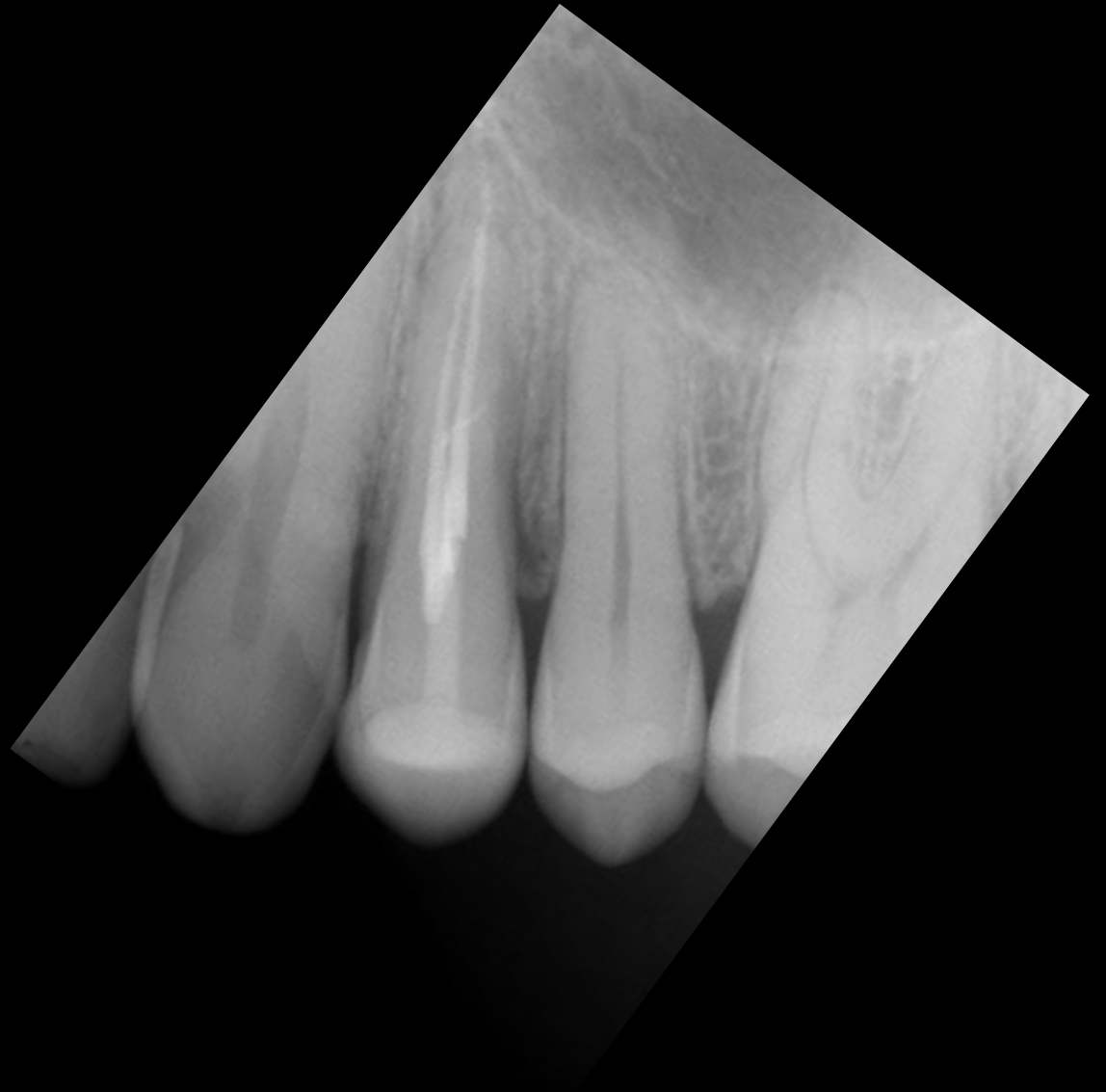
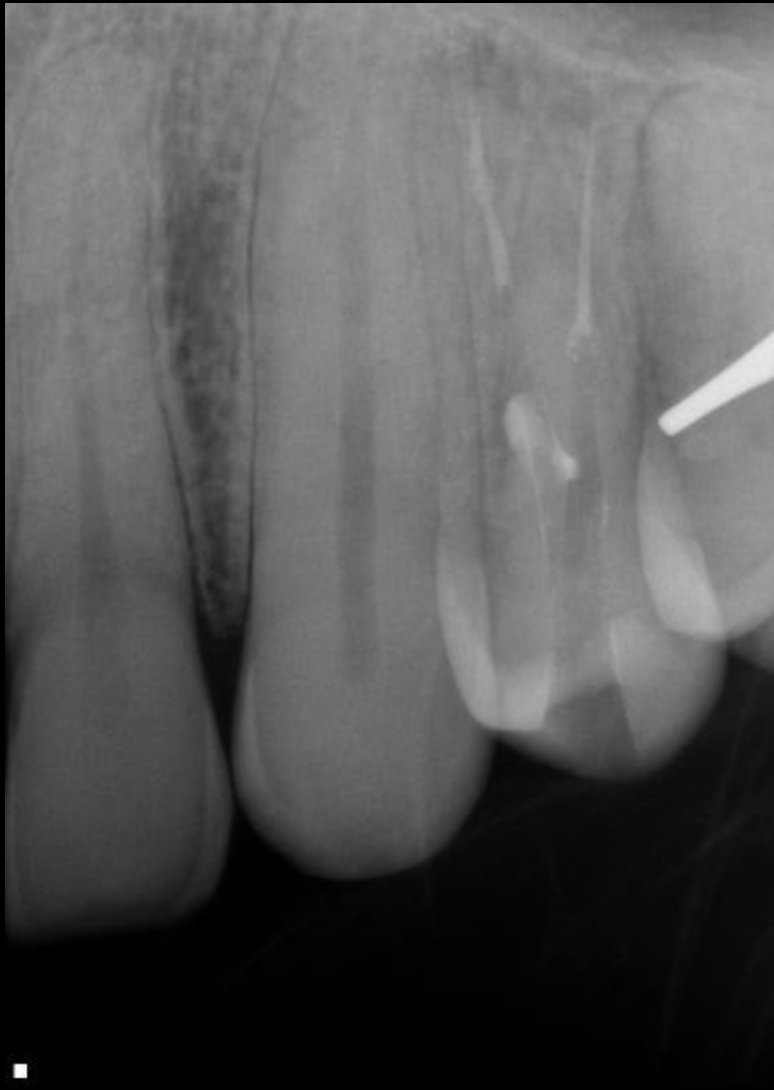

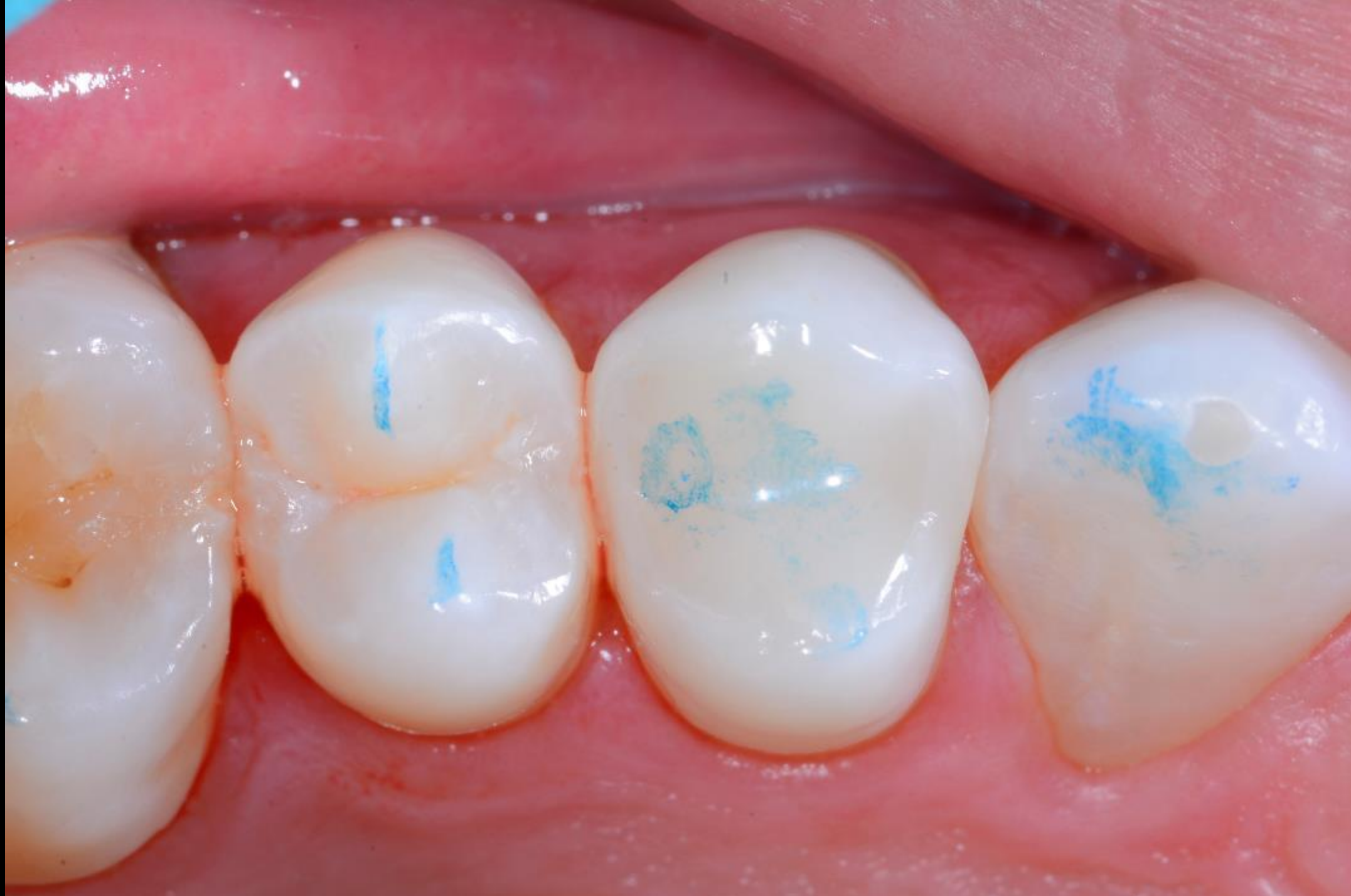Normal
Probing
Depth

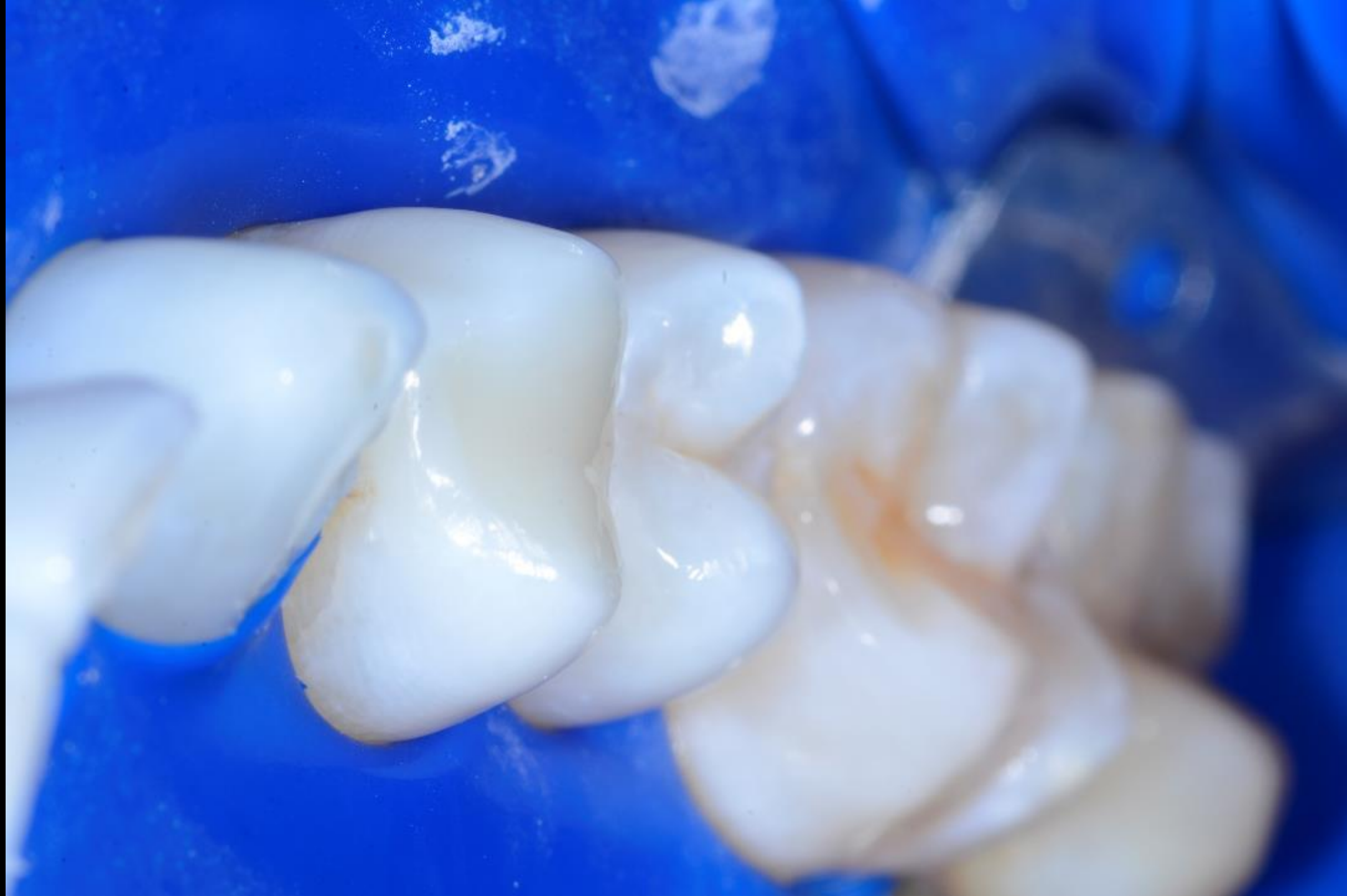


Normal
Probing
Depth



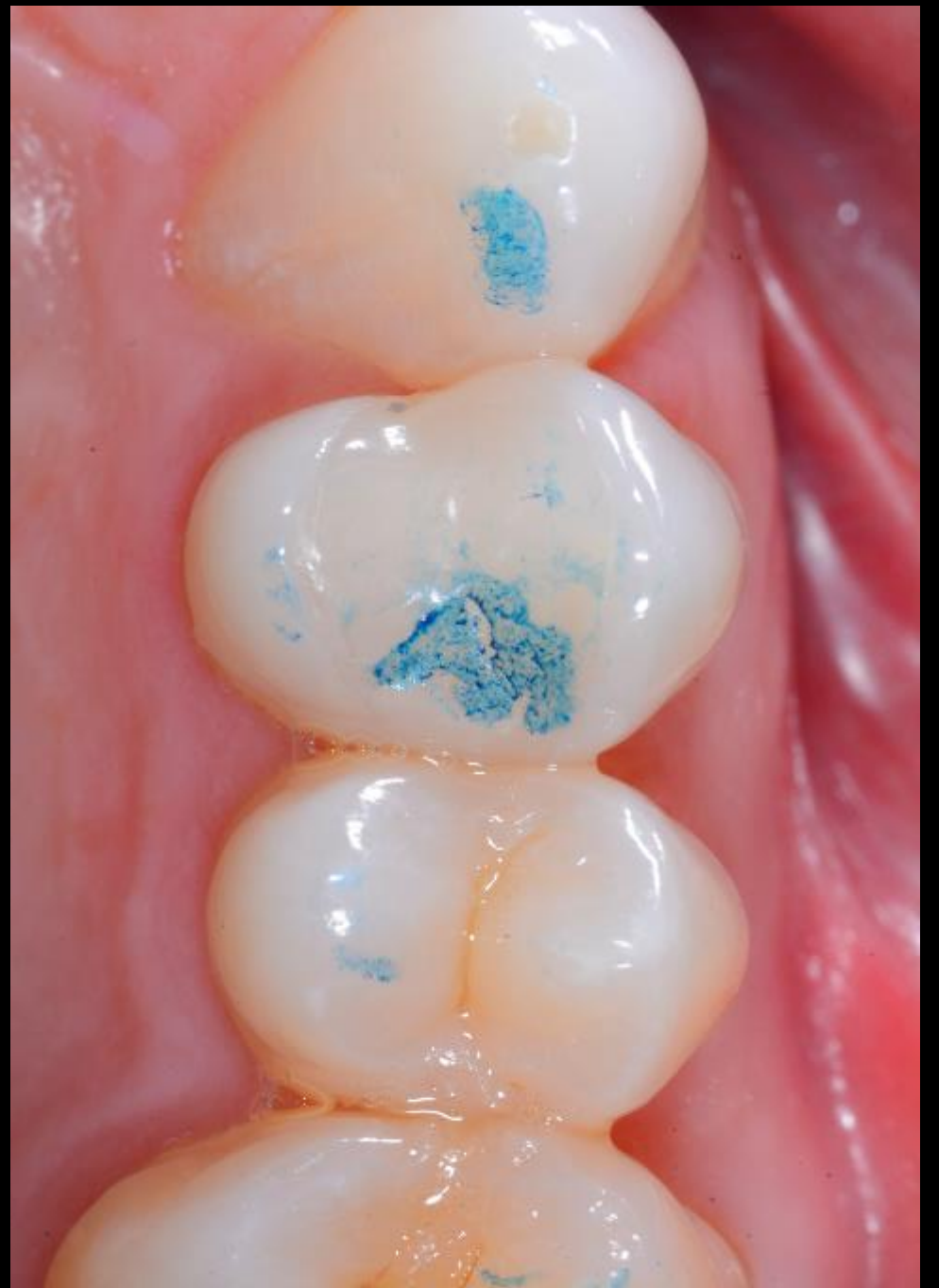
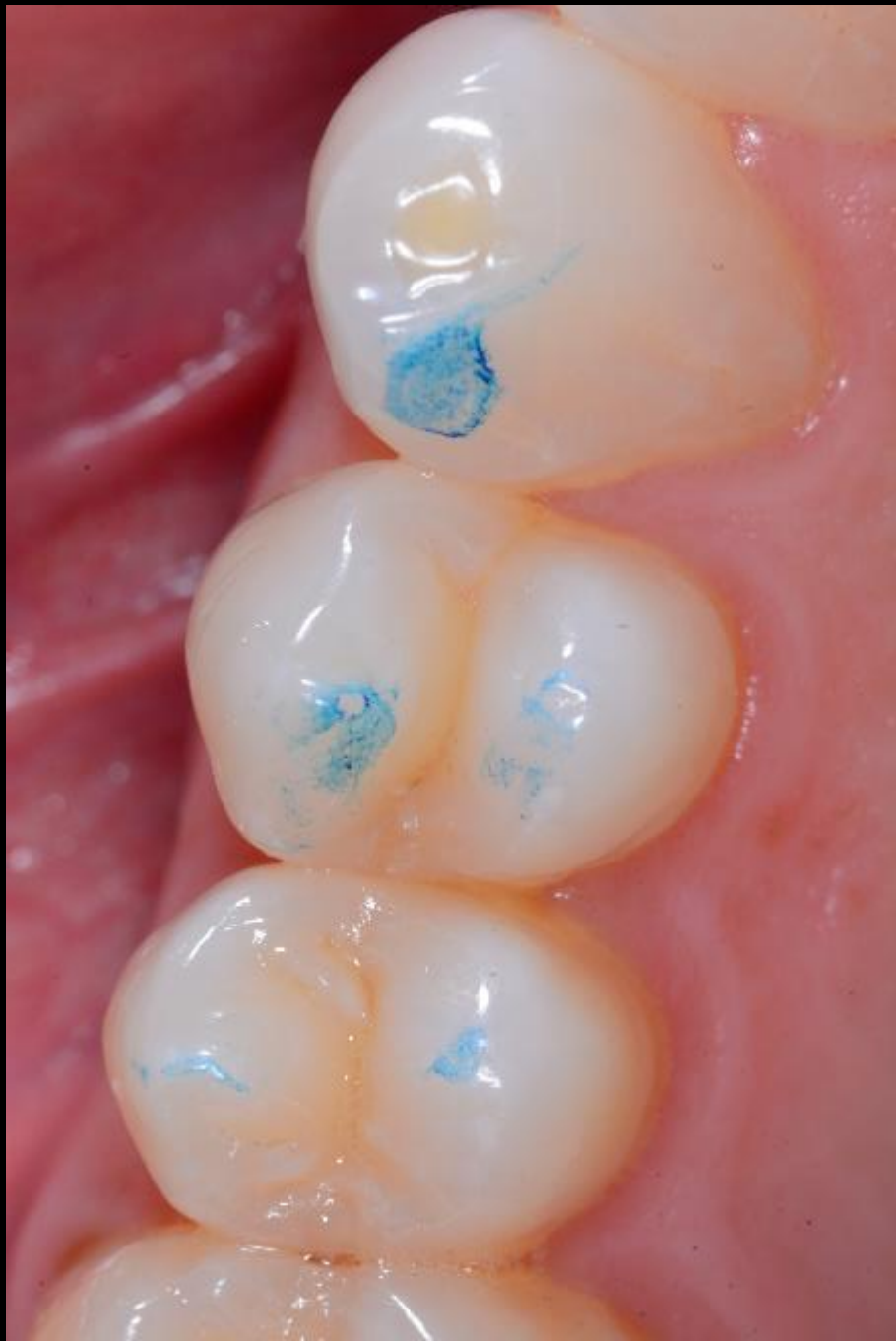


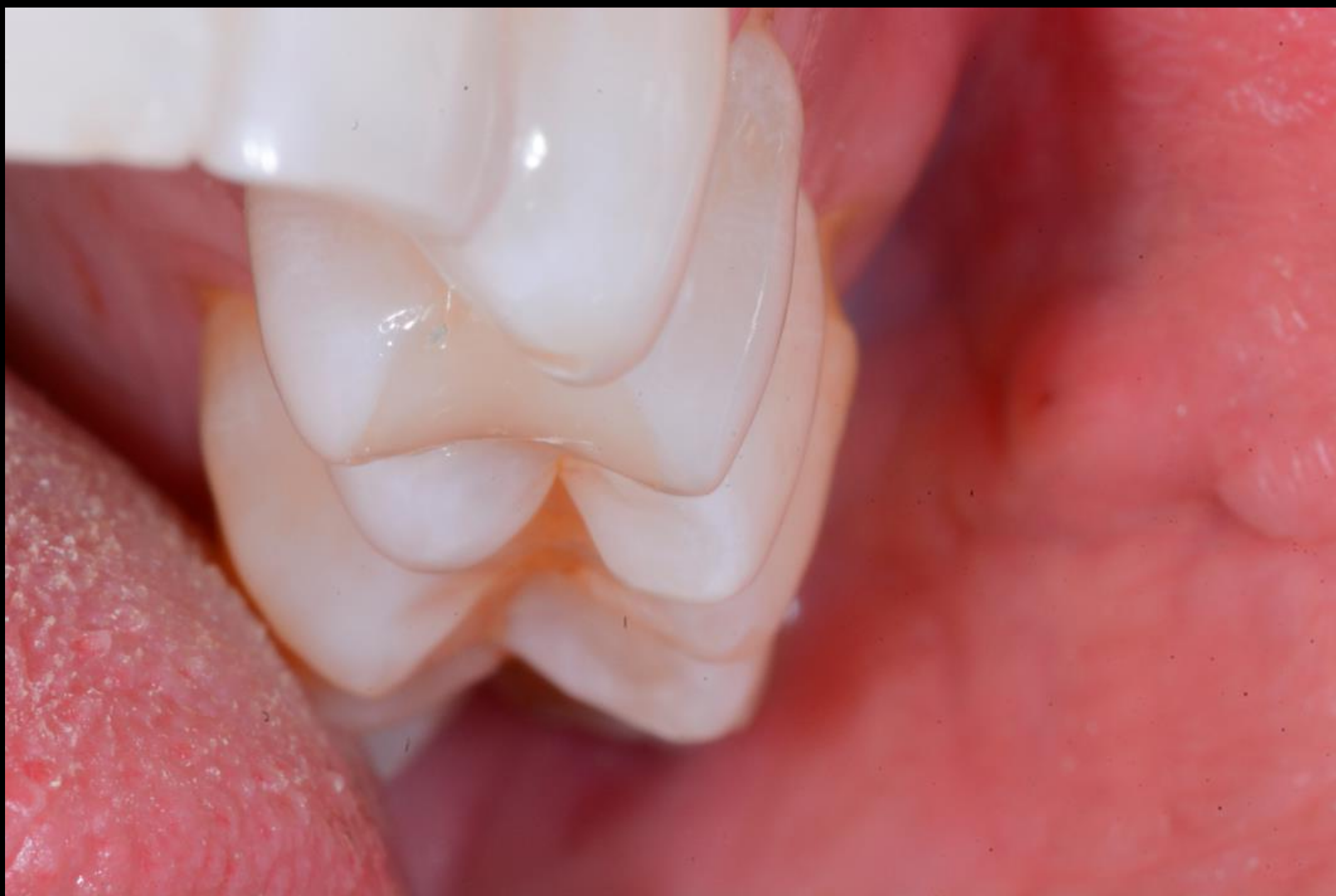


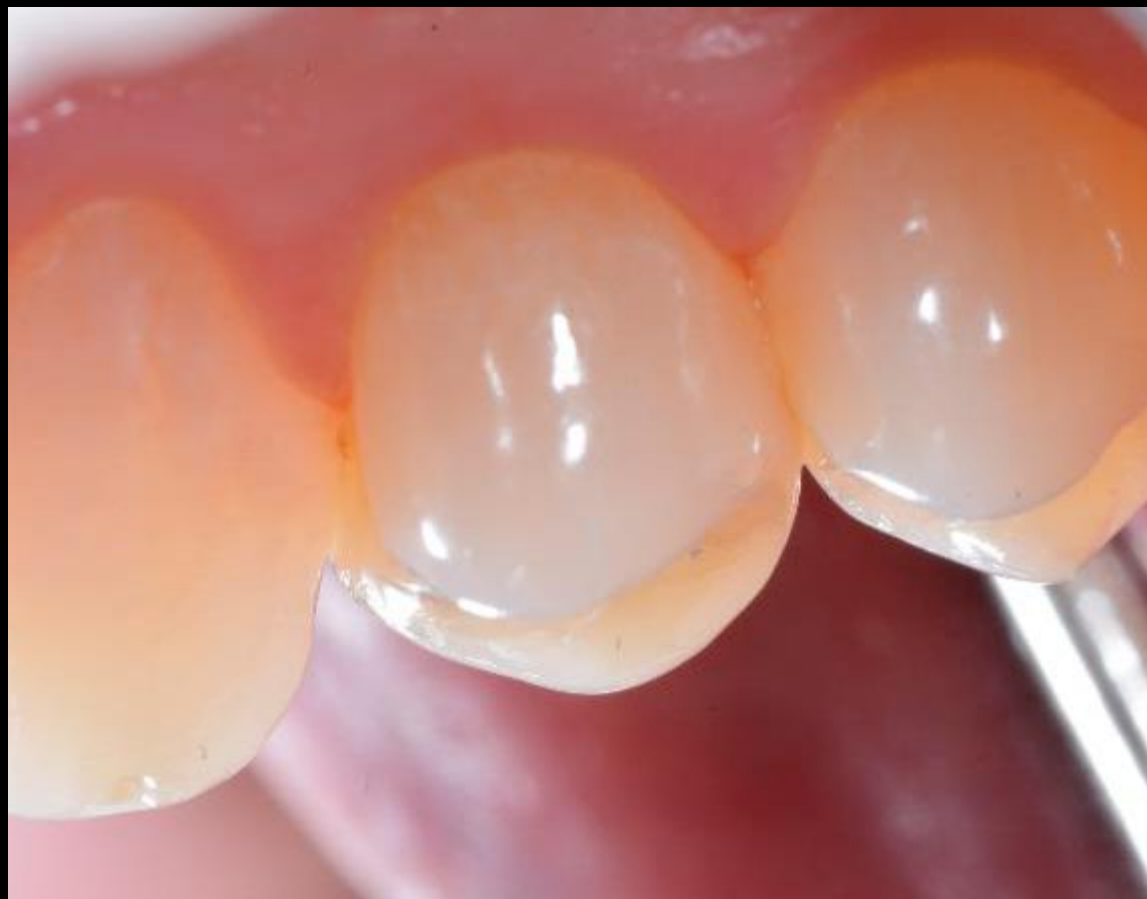
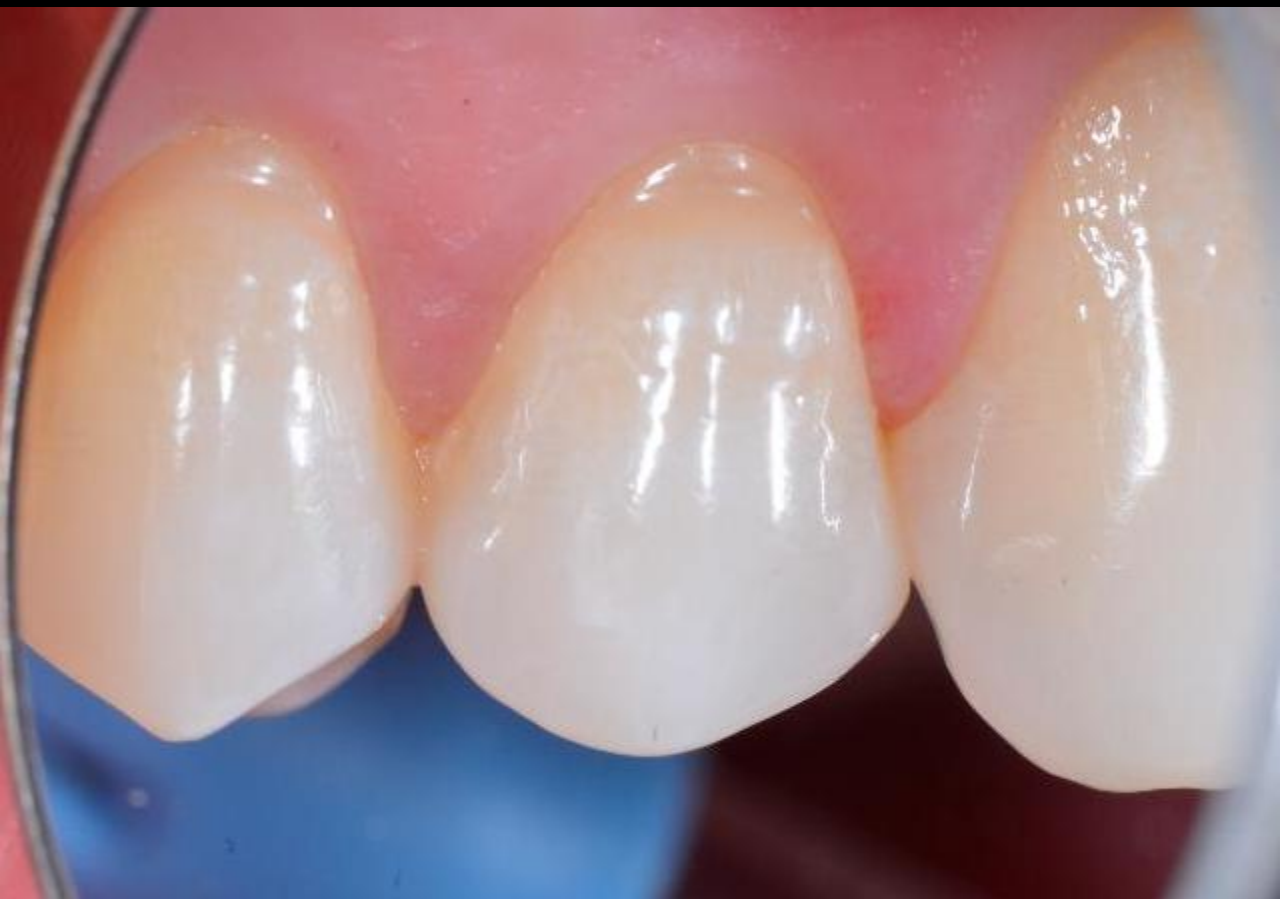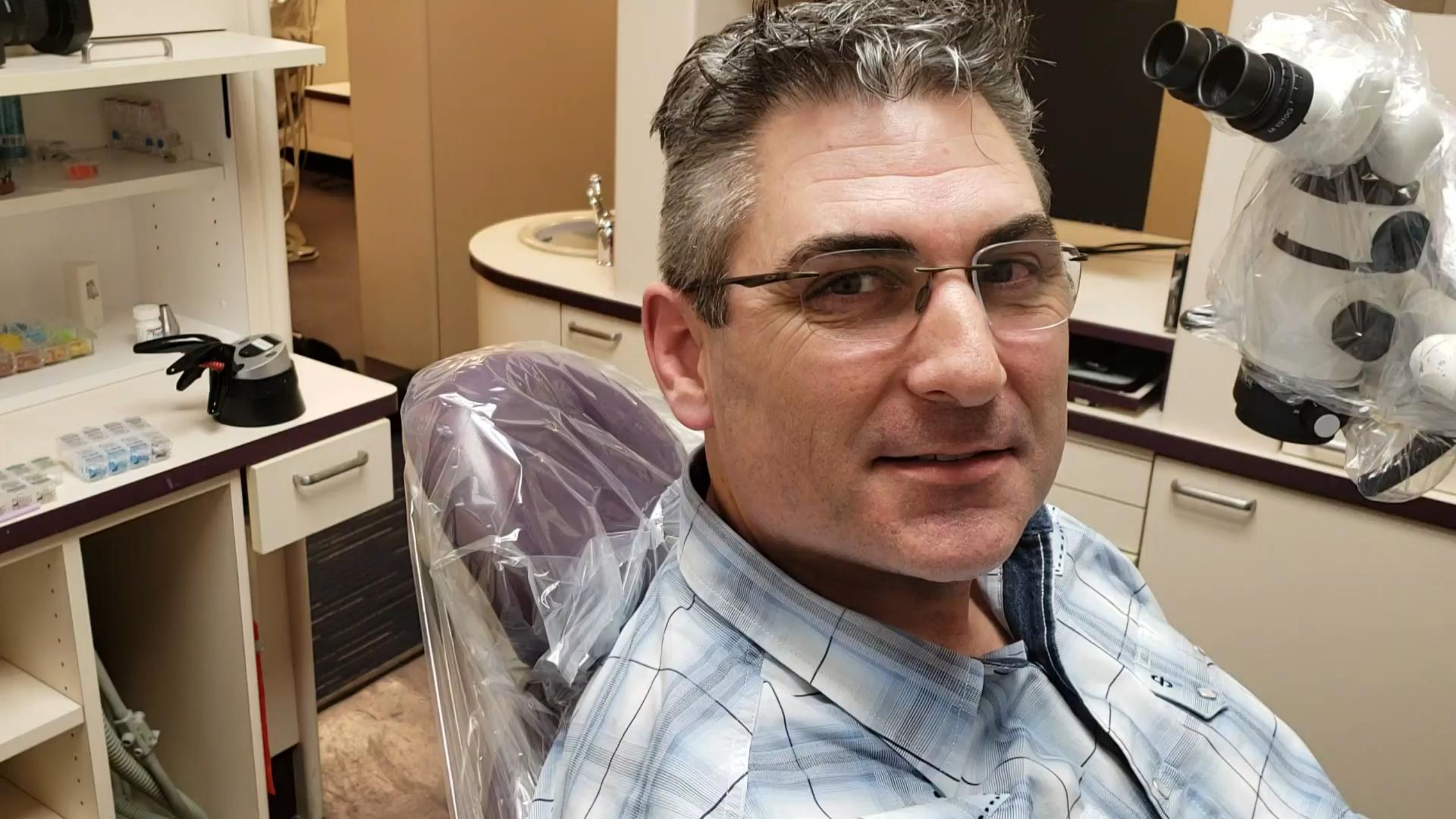18 month follow up

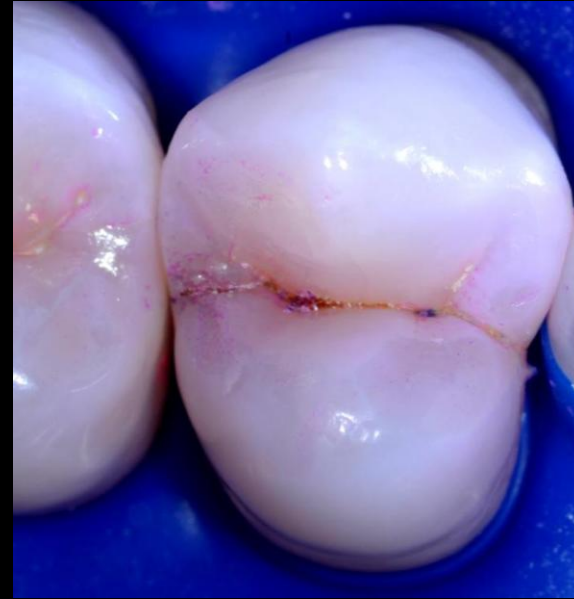




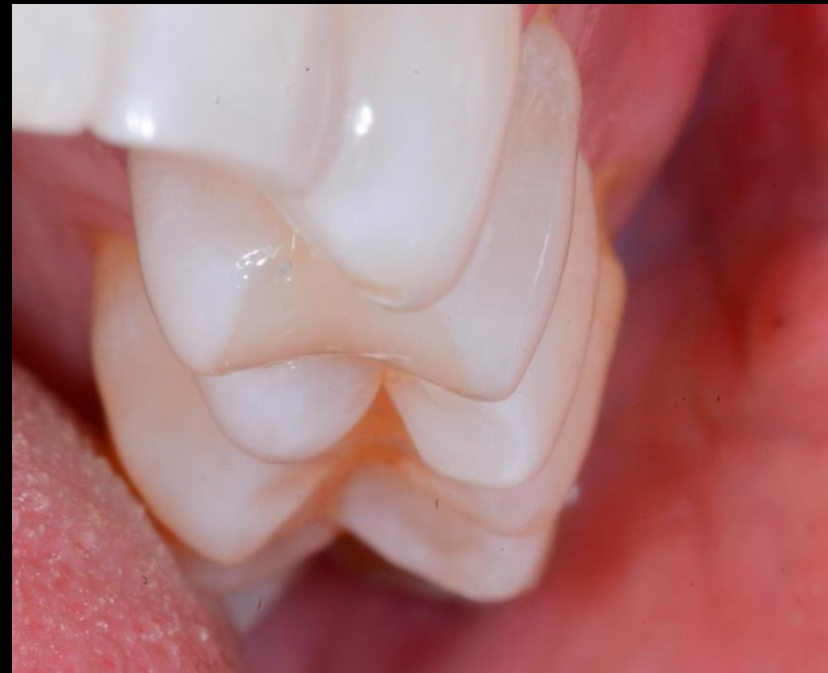


“Build a bridge from buccal to lingual, and the crack(s) becomes dormant.”



Before



Before

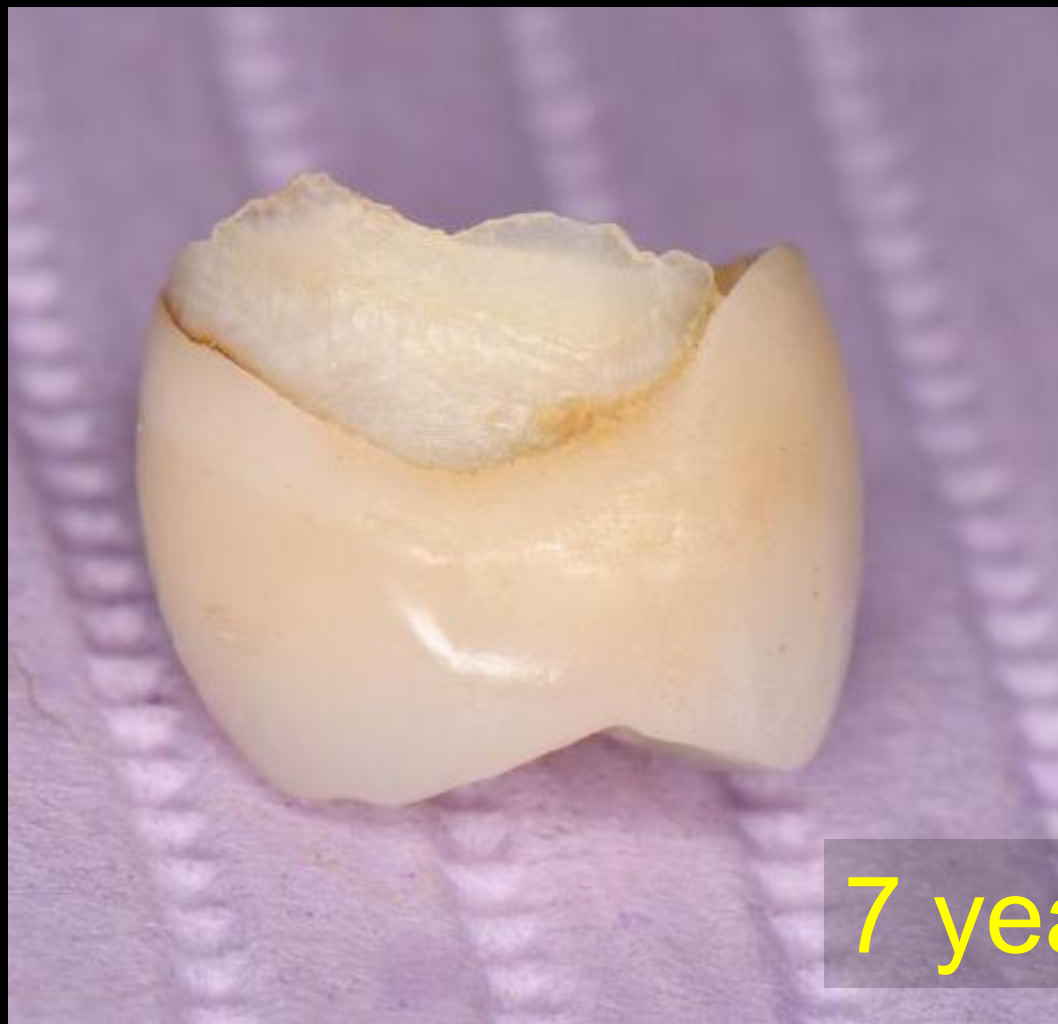“That’s it”



DR. ALEX FOK




“David that’s not going to work, do a crown.”



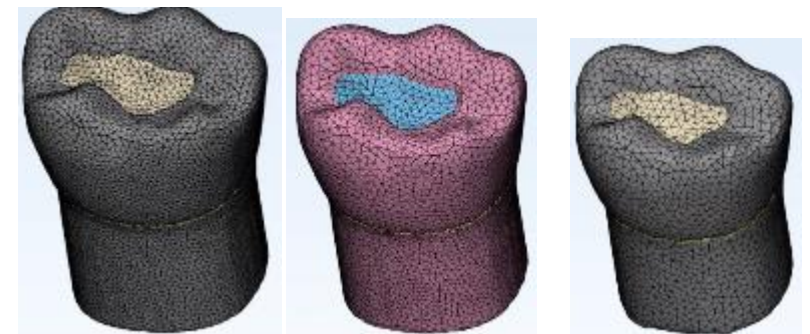
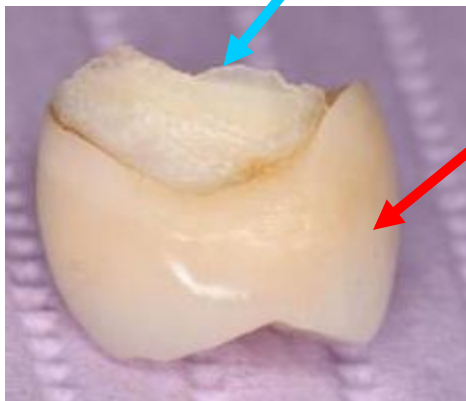
7 years post-op

Stress/Strain Concentration

- Abrupt changes in geometry
- Mismatches in mechanical properties
- Concentrated loads



	Elastic Modulus (GPa)	Poisson's Ratio	Effective Shrinkage Strain*
Composite	10	0.3	0.34%
Dentin	18	0.2	NA
Enamel	48-80	0.23	NA
Gold	79		
Zirconia	200		



[1] Alex SL Fok, Dent Mater, 2013

- Why things break...
- Modern cavity preparations
- Injection Molding of composite
- FEA of both load and shrinkage
- Long term outcomes & case studies
- The Bioclear Method as a “3rd option”

■ When to do endo, when to extract

- Why things break...
- Modern cavity preparations
- Injection Molding of composite
- FEA of both load and shrinkage
- Long term outcomes & case studies
- The Bioclear Method as a “3rd option”

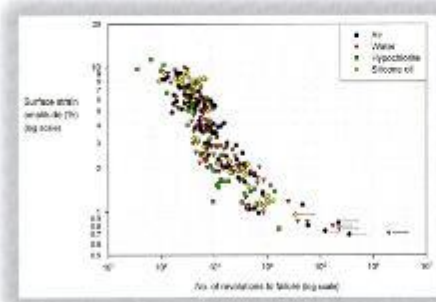
■ When to do endo, when to extract

JOE

Journal of Endodontics

December 2007 Volume 33, Number 12

Dec
2007



Effect of Environment on Cyclic Fatigue
Page 1433

Clinical page 1405

Association of Pulpitis in a Cohort of 796 Cracked Teeth

Basic page 1430

Initial Evaluation of Ceramicrete as a Potential Root End Filling Material

Case Report page 1484

Nerve Damage Associated with Overextended Obturating Material



Official Journal of the American Association of Endodontists

A Six Year Evaluation of Cracked Teeth Diagnosed with Reversible Pulpitis: Treatment and Prognosis

Keith V. Krell, DDS, MS, MA,* and Eric M. Rivera, DDS, MS†

Abstract

The purpose of this investigation was to report on the clinical outcomes of cracked teeth diagnosed with reversible pulpitis (RP). Eight thousand one hundred seventy-five patients referred for evaluation and treatment during a 6-year period had medical and dental histories, radiographs, pulpal and periapical diagnosis, periodontal probings, direct identification of crack(s) with transillumination, and biting responses on various cusps recorded. All data were stored daily in a database. All cases were treatment planned according to the pulpal and periapical diagnosis. Cases with RP were treatment planned for crowns only, regardless of periapical diagnosis. All patients were recalled at 1 year unless root canal treatment was needed before the anniversary. Results indicated that cracks were identified in 9.7% (796 of 8175) of all teeth evaluated during this time period. Of 127 patients specifically diagnosed with RP, 27 converted to irreversible pulpitis (N = 21) in 58 days or to necrotic pulp (N = 6) in 149 days. To date, none of the original remaining 100 cases of RP have required root canal treatment. The outcomes of this study suggest that if a marginal ridge crack is identified early enough in teeth with a diagnosis of RP and a crown is placed, root canal treatment will be necessary in about 20% of these cases within a 6-month period. (*J Endod* 2007;33:1405–1407)

Key Words

Cracked teeth, reversible pulpitis

From the *Department of Endodontics, College of Dentistry, University of Iowa, Iowa City, Iowa; and †Department of Endodontics, School of Dentistry, University of North Carolina, Chapel Hill, North Carolina.

Address requests for reprints to Keith V. Krell, DDS, MS, MA, 1450 28th St, West Des Moines, IA 50266. E-mail address: krekth@iwoi.com.

0099-2595/07 - see front matter

Copyright © 2007 by the American Association of Endodontists.

doi:10.1016/j.joen.2007.08.015

The Fall/Winter 1997 AAE Colleagues for Excellence article entitled "Cracking the Cracked Tooth Code" (<http://www.aae.org/NR/rdonlyres/7D73B05C-FEE4-4B00-AB57-086056F163BC/0/bw97ecfc.pdf>) defined 5 types of tooth cracks. Four of the 5 cracks are associated with coronal defects generated from chewing and biting events (1). Teeth with craze lines have no pain, show lines in the enamel, but no "shadows" in the dentin with transillumination. Teeth with fractured cusps have mild pain to biting on a specific cusp, usually a marginal ridge and buccal or lingual groove crack in the dentin, seen as a shadow with transillumination and a Class II restoration. Removal of the restoration might result in the cusp breaking off. Cracked teeth might or might not have a restoration, will exhibit acute pain on mastication, early brief pain to cold, centrally located mesial-to-distal marginal ridge crack(s) seen in the dentin as a shadow(s) with transillumination, normal-to-deep periodontal probings associated with the crack, no detectable movement of cusps with an explorer, and might require removal of existing restorations to definitively diagnose. The pulpal and periapical diagnoses are dependent on the extent of the crack and duration of the symptoms. Split teeth usually have marked pain to chewing, can be considered an extension of the cracked tooth, have mesiodistal cracks extending across both marginal ridges with detectable buccal and lingual cusp separation with an explorer, and deep probings with both marginal ridges. Vertical root fractures begin in the roots of teeth that usually have had endodontic treatment, extend in the buccal-to-lingual plane, usually have minimal signs or symptoms, might have normal probings, and require surgical assessment to complete the diagnosis.

The treatment of teeth diagnosed as a cracked tooth has largely been variable and empirical. The Fall/Winter 1997 AAE Colleagues for Excellence article entitled "Cracking the Cracked Tooth Code" suggested "the treatment plan will vary depending on the location and extent of the crack" and noted that "any thermal sensitivity probably indicates the crack extends near or into the pulp, and root canal treatment will be necessary prior to restoring the tooth with a crown" (1). The juxtaposition to assuming the tooth will need root canal treatment before the crown is to place the crown first, see whether symptoms subside, and only perform root canal treatment when the pulpal and periradicular status dictates treatment. Ailor (2) presented a "flow chart" that took into consideration the pulp status at the time of discovery of the crack. He suggested temporizing the tooth with a temporary crown and monitoring it for symptoms.

Incidence data from Hiatt (3) and Cameron (4) found that the most frequently involved teeth were mandibular molars followed by maxillary premolars and then by maxillary first molars. Weine et al (5) found that the most frequently involved teeth were mandibular molars followed by maxillary molars and then by maxillary premolars.

To date there have been no studies that have looked at teeth diagnosed with cracks (cracked teeth) that have a pulpal diagnosis of reversible pulpitis (RP) and are subsequently crowned without initial root canal treatment. The purpose of this investigation was to report on the clinical outcomes of cracked teeth that were initially diagnosed with RP that were crowned during a 6-year period. Specific questions to be answered were the following: (1) what are the locations of these cracked teeth in the mouth? (2) What is the periodontal status of these cracked teeth? (3) Where are the cracks located on the teeth? (4) How many teeth required root canal therapy? (5) What clinical changes occurred in or around the teeth requiring root canal therapy?

Dec 2007



A Six Year Evaluation of Cracked Teeth Diagnosed with Reversible Pulpitis: Treatment and Prognosis

Keith V. Krell, DDS, MS, MA,* and Eric M. Rivera, DDS, MS†

Abstract

The purpose of this investigation was to report on the clinical outcomes of cracked teeth diagnosed with reversible pulpitis (RP). Eight thousand one hundred seventy-five patients referred for evaluation and treatment during a 6-year period had medical and dental histories, radiographs, pulpal and periapical diagnosis, periodontal probings, direct identification of crack(s) with transillumination, and biting responses on various cusps recorded. All data were stored daily in a database. All cases were treatment planned according to the pulpal and periapical diagnosis. Cases with RP were treatment planned for crowns only, regardless of periapical diagnosis. All patients were recalled at 1 year unless root canal treatment was needed before the anniversary. Results indicated that cracks were identified in 9.7% (796 of 8175) of all teeth evaluated during this time period. Of 127 patients specifically diagnosed with RP, 27 converted to irreversible pulpitis (N = 21) in 58 days or to necrotic pulp (N = 6) in 149 days. To date, none of the original remaining 100 cases of RP have required root canal treatment. The outcomes of this study suggest that if a marginal ridge crack is identified early enough in teeth with a diagnosis of RP and a crown is placed, root canal treatment will be necessary in about 20% of these cases within a 6-month period. (*J Endod* 2007;33:1405-1407)

Key Words

Cracked teeth, reversible pulpitis

From the *Department of Endodontics, College of Dentistry, University of Iowa, Iowa City, Iowa; and †Department of Endodontics, School of Dentistry, University of North Carolina, Chapel Hill, North Carolina.

Address requests for reprints to Keith V. Krell, DDS, MS, MA, 1450 28th St, West Des Moines, IA 50266. E-mail address: krekth@iow.uiowa.edu

0099-2595/07 - see front matter

Copyright © 2007 by the American Association of Endodontists

doi:10.1016/j.joen.2007.08.015

The Fall/Winter 1997 AAE Colleagues for Excellence article entitled "Cracking the Cracked Tooth Code" (<http://www.aae.org/NR/rdonlyres/7D73B05C-FEE4-4B00-AB57-086056F163BC/0/bw97ecfe.pdf>) defined 5 types of tooth cracks. Four of the 5 cracks are associated with coronal defects generated from chewing and biting events (1). Teeth with craze lines have no pain, show lines in the enamel, but no "shadows" in the dentin with transillumination. Teeth with fractured cusps have mild pain to biting on a specific cusp, usually a marginal ridge and buccal or lingual groove crack in the dentin, seen as a shadow with transillumination and a Class II restoration. Removal of the restoration might result in the cusp breaking off. Cracked teeth might or might not have a restoration, will exhibit acute pain on mastication, early brief pain to cold, centrally located mesial-to-distal marginal ridge crack(s) seen in the dentin as a shadow(s) with transillumination, normal-to-deep periodontal probings associated with the crack, no detectable movement of cusps with an explorer, and might require removal of existing restorations to definitively diagnose. The pulpal and periapical diagnoses are dependent on the extent of the crack and duration of the symptoms. Split teeth usually have marked pain to chewing, can be considered an extension of the cracked tooth, have mesiodistal cracks extending across both marginal ridges with detectable buccal and lingual cusp separation with an explorer, and deep probings with both marginal ridges. Vertical root fractures begin in the roots of teeth that usually have had endodontic treatment, extend in the buccal-to-lingual plane, usually have minimal signs or symptoms, might have normal probings, and require surgical assessment to complete the diagnosis.

The treatment of teeth diagnosed as a cracked tooth has largely been variable and empirical. The Fall/Winter 1997 AAE Colleagues for Excellence article entitled "Cracking the Cracked Tooth Code" suggested "the treatment plan will vary depending on the location and extent of the crack" and noted that "any thermal sensitivity probably indicates the crack extends near or into the pulp, and root canal treatment will be necessary prior to restoring the tooth with a crown" (1). The juxtaposition to assuming the tooth will need root canal treatment before the crown is to place the crown first, see whether symptoms subside, and only perform root canal treatment when the pulpal and periradicular status dictates treatment. Ailor (2) presented a "flow chart" that took into consideration the pulp status at the time of discovery of the crack. He suggested temporizing the tooth with a temporary crown and monitoring it for symptoms.

Incidence data from Hiatt (3) and Cameron (4) found that the most frequently involved teeth were mandibular molars followed by maxillary premolars and then by maxillary first molars. Weine et al (5) found that the most frequently involved teeth were mandibular molars followed by maxillary molars and then by maxillary premolars.

To date there have been no studies that have looked at teeth diagnosed with cracks (cracked teeth) that have a pulpal diagnosis of reversible pulpitis (RP) and are subsequently crowned without initial root canal treatment. The purpose of this investigation was to report on the clinical outcomes of cracked teeth that were initially diagnosed with RP that were crowned during a 6-year period. Specific questions to be answered were the following: (1) what are the locations of these cracked teeth in the mouth? (2) What is the periodontal status of these cracked teeth? (3) Where are the cracks located on the teeth? (4) How many teeth required root canal therapy? (5) What clinical changes occurred in or around the teeth requiring root canal therapy?

6 year
evaluation
.....the first
study of
its kind



A Six Year Evaluation of Cracked Teeth Diagnosed with Reversible Pulpitis: Treatment and Prognosis

Keith V. Krell, DDS, MS, MA,* and Eric M. Rivera, DDS, MS†

Abstract

The purpose of this investigation was to report on the clinical outcomes of cracked teeth diagnosed with reversible pulpitis (RP). Eight thousand one hundred seventy-five patients referred for evaluation and treatment during a 6-year period had medical and dental histories, radiographs, pulpal and periapical diagnosis, periodontal probings, direct identification of crack(s) with transillumination, and biting responses on various cusps recorded. All data were stored daily in a database. All cases were treatment planned according to the pulpal and periapical diagnosis. Cases with RP were treatment planned for crowns only, regardless of periapical diagnosis. All patients were recalled at 1 year unless root canal treatment was needed before the anniversary. Results indicated that cracks were identified in 9.7% (796 of 8175) of all teeth evaluated during this time period. Of 127 patients specifically diagnosed with RP, 27 converted to irreversible pulpitis (N = 21) in 58 days or to necrotic pulp (N = 6) in 149 days. To date, none of the original remaining 100 cases of RP have required root canal treatment. The outcomes of this study suggest that if a marginal ridge crack is identified early enough in teeth with a diagnosis of RP and a crown is placed, root canal treatment will be necessary in about 20% of these cases within a 6-month period. (*J Endod* 2007;33:1405–1407)

Key Words

Cracked teeth, reversible pulpitis

From the *Department of Endodontics, College of Dentistry, University of Iowa, Iowa City, Iowa; and †Department of Endodontics, School of Dentistry, University of North Carolina, Chapel Hill, North Carolina.

Address requests for reprints to Keith V. Krell, DDS, MS, MA, 1450, 19th St, 2nd Floor, Durham, NC 27705. E-mail address: krellk@dent.unc.edu
0099-2398
Copyright © 2007 by Lippincott Williams & Wilkins
DOI: 10.1097/00006583-200712000-00005



The Fall/Winter 1997 AAE Colleagues for Excellence article entitled "Cracking the Cracked Tooth Code" (<http://www.aae.org/NR/rdonlyres/7D73B05C-FEE4-4B00-AB57-086056F163BC/0/w97ecfc.pdf>) defined 5 types of tooth cracks. Four of the 5 cracks are associated with coronal defects generated from chewing and biting events (1). Teeth with craze lines have no pain, show lines in the enamel, but no "shadows" in the dentin with transillumination. Teeth with fractured cusps have mild pain to biting on a specific cusp, usually a marginal ridge and buccal or lingual groove crack in the dentin, seen as a shadow with transillumination and a Class II restoration. Removal of the restoration might result in the cusp breaking off. Cracked teeth might or might not have a restoration, will exhibit acute pain on mastication, early brief pain to cold, centrally located mesial-to-distal marginal ridge crack(s) seen in the dentin as a shadow(s) with transillumination, normal-to-deep periodontal probings associated with the crack, no detectable movement of cusps with an explorer, and might require removal of existing restorations to definitively diagnose. The pulpal and periapical diagnoses are dependent on the extent of the crack and duration of the symptoms. Split teeth usually have marked pain to chewing, can be considered an extension of the cracked tooth, have mesiodistal cracks extending across both marginal ridges with detectable buccal and lingual cusp separation with an explorer, and deep probings with both marginal ridges. Vertical root fractures begin in the roots of teeth that usually have had endodontic treatment, extend in the buccal-to-lingual plane, usually have minimal signs or symptoms, might have normal probings, and require surgical assessment to complete the diagnosis.

The treatment of teeth diagnosed as a cracked tooth has largely been variable and empirical. The Fall/Winter 1997 AAE Colleagues for Excellence article entitled "Cracking the Cracked Tooth Code" suggested "the treatment plan will vary depending on the location and extent of the crack" and noted that "any thermal sensitivity probably indicates the crack extends near or into the pulp, and root canal treatment will be necessary prior to restoring the tooth with a crown" (1). The juxtaposition to assuming the tooth will need root canal treatment before the crown is to place the crown first, see whether symptoms subside, and only perform root canal treatment when the pulpal and periradicular status dictates treatment. Ailor (2) presented a "flow chart" that took into consideration the pulp status at the time of discovery of the crack. He suggested temporizing the tooth with a temporary crown and monitoring it for symptoms.

Incidence data from Hiatt (3) and Cameron (4) found that the most frequently involved teeth were mandibular molars followed by maxillary premolars and then by maxillary first molars. Weine et al (5) found that the most frequently involved teeth were mandibular molars followed by maxillary molars and then by maxillary premolars.

To date there have been no studies that have looked at teeth diagnosed with cracks (cracked teeth) that have a pulpal diagnosis of reversible pulpitis (RP) and are subsequently crowned without initial root canal treatment. The purpose of this investigation was to report on the clinical outcomes of cracked teeth that were initially diagnosed with RP that were crowned during a 6-year period. Specific questions to be answered were the following: (1) what are the locations of these cracked teeth in the mouth? (2) What is the periodontal status of these cracked teeth? (3) Where are the cracks located on the teeth? (4) How many teeth required root canal therapy? (5) What clinical changes occurred in or around the teeth requiring root canal therapy?

127 teeth
with R.P.
were
restored
with crowns
and NO
ENDO

TABLE 1. The Number and Percentage of Cracked Teeth by Tooth Position in the Mouth

	Maxillary Second Molar	Maxillary First Molar	Maxillary Second Premolar	Maxillary First Premolar	Mandibular Second Molar	Mandibular First Molar	Mandibular Second Premolar	Mandibular First Premolar	Totals
Cracked	71	167	46	25	243	231	12	1	796
Total	835	1879	754	549	1380	2100	456	222	8175
%	8.50	8.89	6.10	4.55	17.61	11.00	2.63	0.45	9.74

Materials and Methods

There were 8175 patients included in this study from a private endodontic practice population during a 6-year period. The patients were recorded consecutively as they were referred to the endodontist for evaluation and appropriate treatment during the 6-year period. Besides the standard medical history and subjective history, the endodontist was responsible for the diagnosis of all teeth and recorded the following information for all teeth:

- (1) Pulpal response to cold or hot.
- (2) Periapical response to pressure, palpation, and percussion.
- (3) Buccal and lingual periodontal probings were recorded in the mesial and distal interproximal spaces and furca. These interproximal probings would be directed precisely where marginal ridge cracks were identified to indicate the deepest probing of the crack. A total of 6 probing points were recorded for each tooth.
- (4) Identification of a crack(s) with direct transillumination and visualization with and without magnification. The identified crack had to block light transmission and show a definite shadow with both the buccal and lingual coronal light placement. Teeth not exhibiting a shadow were considered to have "crazings" and were not included in this study.
- (5) Responses to biting on various cusps of the diagnosed tooth, with at least 1 cusp exhibiting pain to biting on either a burlew wheel or Tooth Slooth (Professional Results, Inc, Laguna Hills, Calif).

Teeth were diagnosed with RP if (1) there was no history of spontaneous pain; (2) the response to cold went away in less than 3–5 seconds; (3) there was no radiographic pathology.

No teeth were included in this part of the study that could not be confirmed by visualization as having an identifiable crack even if biting sensitivity was present. Restorations were removed only for patients with pulpal diagnoses that required root canal treatment. Teeth diagnosed as cusp fractures, split teeth, and vertical root fractures were also excluded from this study (6). All patients were recalled at 1 year unless root canal treatment was needed before the anniversary, then recall was 1 year later after treatment. The recall therefore extended into a seventh year of the data collection.

All cases were treatment planned according to the pulpal and periapical diagnosis. Cases with RP were treatment planned for crowns only, regardless of periapical diagnosis.

TABLE 2. The Number and Percentage of Cracked Teeth by Tooth Position with RP Eventually Requiring Root Canal Treatment

	Maxillary Second Molar	Maxillary First Molar	Maxillary Second Premolar	Maxillary First Premolar	Mandibular Second Molar	Mandibular First Molar	Mandibular Second Premolar	Mandibular First Premolar	Totals
Cracked	12	33	8	4	29	41	0	0	127
REV. > IP or NEC.	3	9	0	0	8	7	0	0	27
%	25	27	0	0	28	17	0	0	21

REV, reversible pulpitis; IP, irreversible pulpitis; NEC, necrosis.

Results

Of the 8175 cases seen during the 6-year period, 796 cases were diagnosed as cracked teeth (9.7%). Mandibular second molars (243/796, 30%) had the largest incidence followed by mandibular first molars (231/796, 29%) and maxillary first molars (167/796, 21%). All teeth are included in Table 1.

Cases with RP had the following distribution: mandibular first molars (41/127, 32%), maxillary first molars (33/127, 25%), and mandibular second molars (29/127, 23%). All teeth are included in Table 2.

Of 127 patients specifically diagnosed with RP, 27 converted to irreversible pulpitis (N = 21) in 58 days or to necrotic pulp (N = 6) in 149 days. The distribution of teeth requiring root canal therapy was as follows: maxillary first molars (9/27, 33%), mandibular second molars (8/27, 29%), mandibular first molars (7/27, 26%), and maxillary second molars (3/27, 11%).

All teeth had initial interproximal probings less than 3 mm in the space associated with the identified crack. Increased interproximal probings were associated with the fractured marginal ridge for only 5 of the 27 teeth requiring root canal treatment. The greatest increase in probing depth was 2 mm for 2 of 5 teeth.

The teeth requiring root canal treatment had the crack located on the distal marginal ridge in 15 of the 27 cases (56%). The distribution was mandibular second molars (6/27, 27%), mandibular first molars (3/27, 11%), maxillary first molars (3/27, 11%), maxillary second premolars (2/27, 7%), and maxillary second molars (1/27, 4%). The crack was located only on the mesial marginal ridge in 4 of the 27 cases (15%). The distribution was the maxillary first molars (3/27, 11%) and maxillary first premolars (1/27, 4%). Both marginal ridges were involved in 8 of the 27 cases (29%). The distribution was mandibular first molars (5/27, 19%), maxillary first molars (2/27, 7%), and maxillary second molars (1/27, 4%). None of the teeth had fractures that extended into the floor of the chamber or rendered them "non-restorable".

None of the original remaining 100 cases of RP required root canal treatment.

Discussion

The patients who composed this database were all patients referred to a private practice endodontist. Our incidence data are in agreement with the findings of Weine et al (5), which were also derived from an endodontist's practice. The difference in percentages from

What are the 5 questions you ask to distinguish R.P. ?



Journal of Organometallic Chemistry

Volume 689, Issues 1–3, November 2012

Editorial Board

Chairman	Editor	Editorial Board	Editorial Board	Editorial Board	Editorial Board	Editorial Board	Editorial Board	Editorial Board	Editorial Board
John A. Cowie	John A. Cowie	John A. Cowie	John A. Cowie	John A. Cowie	John A. Cowie	John A. Cowie	John A. Cowie	John A. Cowie	John A. Cowie

Editorial Board

Chairman	Editor	Editorial Board	Editorial Board	Editorial Board	Editorial Board	Editorial Board	Editorial Board	Editorial Board	Editorial Board
John A. Cowie	John A. Cowie	John A. Cowie	John A. Cowie	John A. Cowie	John A. Cowie	John A. Cowie	John A. Cowie	John A. Cowie	John A. Cowie

Editorial Board

Chairman	Editor	Editorial Board	Editorial Board	Editorial Board	Editorial Board	Editorial Board	Editorial Board	Editorial Board	Editorial Board
John A. Cowie	John A. Cowie	John A. Cowie	John A. Cowie	John A. Cowie	John A. Cowie	John A. Cowie	John A. Cowie	John A. Cowie	John A. Cowie



1) Is the pain spontaneous?

Discussion

Table 1. Mean values of the variables of the study (n = 100).

Variable	Mean	SD	Min	Max
Age (years)	23.5	2.1	18	30
Gender (male/female)	50/50	-	-	-
Duration of disease (years)	1.2	0.8	0	5
Number of attacks per year	2.5	1.5	0	10
Number of attacks per month	0.8	0.5	0	3
Number of attacks per week	0.3	0.2	0	1
Number of attacks per day	0.1	0.1	0	1
Number of attacks per hour	0.05	0.05	0	1
Number of attacks per minute	0.01	0.01	0	1
Number of attacks per second	0.001	0.001	0	1



2) Does the pain to cold and biting linger? (past 5 seconds)

3) Has the pain ever woken
you?

4) Lingering pain to heat?

Table 1 Comparison of the performance of the different methods for the detection of the different types of defects.

Defect	Visual	RT	UT	ET	MT	PT	DT	CT	MR
Cracks	Low	High	High	High	High	High	High	High	High
Corrosion	High	Low	Low	Low	Low	Low	Low	Low	Low
Delamination	Low	Low	Low	Low	Low	Low	Low	Low	Low
Disbonding	Low	Low	Low	Low	Low	Low	Low	Low	Low
Foreign material	High	Low	Low	Low	Low	Low	Low	Low	Low
Inclusions	Low	Low	Low	Low	Low	Low	Low	Low	Low
Porosity	Low	Low	Low	Low	Low	Low	Low	Low	Low
Surface defects	High	Low	Low	Low	Low	Low	Low	Low	Low
Volume defects	Low	High	High	High	High	High	High	High	High



5) Is there “radiographic pathosis”? (Krell’s lexicon)

TABLE 1. The Number and Percentage of Cracked Teeth by Tooth Position in the Mouth

	Maxillary Second Molar	Maxillary First Molar	Maxillary Second Premolar	Maxillary First Premolar	Mandibular Second Molar	Mandibular First Molar	Mandibular Second Premolar	Mandibular First Premolar	Totals
Cracked	71	167	46	25	243	231	12	1	796
Total	835	1879	754	549	1380	2100	456	222	8175
%	8.50	8.89	6.10	4.55	17.61	11.00	2.63	0.45	9.74

Materials and Methods

There were 8175 patients included in this study from a private endodontic practice population during a 6-year period. The patients were recorded consecutively as they were referred to the endodontist for evaluation and appropriate treatment during the 6-year period. Besides the standard medical history and subjective history, the endodontist was responsible for the diagnosis of all teeth and recorded the following information for all teeth:

- (1) Pulpal response to cold or hot.
- (2) Periapical response to pressure, palpation, and percussion.
- (3) Buccal and lingual periodontal probings were recorded in the mesial and distal interproximal spaces and furca. These interproximal probings would be directed precisely where marginal ridge cracks were identified to indicate the deepest probing of the crack. A total of 6 probing points were recorded for each tooth.
- (4) Identification of a crack(s) with direct transillumination and visualization with and without magnification. The identified crack had to block light transmission and show a definite shadow with both the buccal and lingual coronal light placement. Teeth not exhibiting a shadow were considered to have "crazings" and were not included in this study.
- (5) Responses to biting on various cusps of the diagnosed tooth, with at least 1 cusp exhibiting pain to biting on either a burlew wheel or Tooth Slooth (Professional Results, Inc, Laguna Niguel, CA).

Teeth were diagnosed with RP if (1) there was no history of spontaneous pain; (2) the response to cold went away in less than 3–5 seconds; (3) there was no radiographic pathology.

No teeth were included in this part of the study that could not be confirmed by visualization as having an identifiable crack even if biting sensitivity was present. Restorations were removed only for patients with pulpal diagnoses that required root canal treatment. Teeth diagnosed as cusp fractures, split teeth, and vertical root fractures were also excluded from this study (6). All patients were recalled at 1 year unless root canal treatment was needed before the anniversary, then recall was 1 year later after treatment. The recall therefore extended into a seventh year of the data collection.

All cases were treatment planned according to the pulpal and periapical diagnosis. Cases with RP were treatment planned for crowns only, regardless of periapical diagnosis.

TABLE 2. The Number and Percentage of Cracked Teeth by Tooth Position with RP Eventually Requiring Root Canal Treatment

	Maxillary Second Molar	Maxillary First Molar	Maxillary Second Premolar	Maxillary First Premolar	Mandibular Second Molar	Mandibular First Molar	Mandibular Second Premolar	Mandibular First Premolar	Totals
Cracked	12	33	8	4	29	41	0	0	127
REV. >IP or NEC.	3	9			8	7			27
%	25	27	0	0	28	17			21

REV, reversible pulpitis; IP, irreversible pulpitis; NEC, necrosis.

Results

Of the 8175 cases seen during the 6-year period, 796 cases were diagnosed as cracked teeth (9.7%). Mandibular second molars (243/796, 30%) had the largest incidence followed by mandibular first molars (231/796, 29%) and maxillary first molars (167/796, 21%). All teeth are included in Table 1.

Cases with RP had the following distribution: mandibular first molars (41/127, 32%), maxillary first molars (33/127, 25%), and mandibular second molars (29/127, 23%). All teeth are included in Table 2.

Of 127 patients specifically diagnosed with RP, 27 converted to irreversible pulpitis (N = 21) in 58 days or to necrotic pulp (N = 6) in 149 days. The distribution of teeth requiring root canal therapy was as follows: maxillary first molars (9/27, 33%), mandibular second molars (8/27, 29%), mandibular first molars (7/27, 26%), and maxillary second molars (3/27, 11%).

All teeth had initial interproximal probings less than 3 mm in the space associated with the identified crack. Increased interproximal probings were associated with the fractured marginal ridge for only 5 of the 27 teeth requiring root canal treatment. The greatest increase in probing depth was 2 mm for 2 of 5 teeth.

The teeth requiring root canal treatment had the crack located on the distal marginal ridge in 15 of the 27 cases (56%). The distribution was mandibular second molars (6/27, 27%), mandibular first molars (3/27, 11%), maxillary first molars (3/27, 11%), maxillary second premolars (2/27, 7%), and maxillary second molars (1/27, 4%). The crack was located only on the mesial marginal ridge in 4 of the 27 cases (15%). The distribution was the maxillary first molars (3/27, 11%) and maxillary first premolars (1/27, 4%). Both marginal ridges were involved in 8 of the 27 cases (29%). The distribution was mandibular first molars (5/27, 19%), maxillary first molars (2/27, 7%), and maxillary second molars (1/27, 4%). None of the teeth had fractures that extended into the floor of the chamber or rendered them "non-restorable".

None of the original remaining 100 cases of RP required root canal treatment.

Discussion

The patients who composed this database were all patients referred to a private practice endodontist. Our incidence data are in agreement with the findings of Weine et al (5), which were also derived from an endodontist's practice. The difference in percentages from

How many pulps eventually died?



TABLE 1. The Number and Percentage of Cracked Teeth by Tooth Position in the Mouth

	Maxillary Second Molar	Maxillary First Molar	Maxillary Second Premolar	Maxillary First Premolar	Mandibular Second Molar	Mandibular First Molar	Mandibular Second Premolar	Mandibular First Premolar	Totals
Cracked	71	167	46	25	243	231	12	1	796
Total	835	1879	754	549	1380	2100	456	222	8175
%	8.50	8.89	6.10	4.55	17.61	11.00	2.63	0.45	9.74

Materials and Methods

There were 8175 patients included in this study from a private endodontic practice population during a 6-year period. The patients were recorded consecutively as they were referred to the endodontist for evaluation and appropriate treatment during the 6-year period. Besides the standard medical history and subjective history, the endodontist was responsible for the diagnosis of all teeth and recorded the following information for all teeth:

- (1) Pulpal response to cold or hot.
- (2) Periapical response to pressure, palpation, and percussion.
- (3) Buccal and lingual periodontal probings were recorded in the mesial and distal interproximal spaces and furca. These interproximal probings would be directed precisely where marginal ridge cracks were identified to indicate the deepest probing of the crack. A total of 6 probing points were recorded for each tooth.
- (4) Identification of a crack(s) with direct transillumination and visualization with and without magnification. The identified crack had to block light transmission and show a definite shadow with both the buccal and lingual coronal light placement. Teeth not exhibiting a shadow were considered to have "crazings" and were not included in this study.
- (5) Responses to biting on various cusps of the diagnosed tooth, with at least 1 cusp exhibiting pain to biting on either a burlew wheel or Tooth Slooth (Professional Results, Inc, Laguna Niguel, CA).

Teeth were diagnosed with RP if (1) there was no history of spontaneous pain; (2) the response to cold went away in less than 3–5 seconds; (3) there was no radiographic pathology.

No teeth were included in this part of the study that could not be confirmed by visualization as having an identifiable crack even if biting sensitivity was present. Restorations were removed only for patients with pulpal diagnoses that required root canal treatment. Teeth diagnosed as cusp fractures, split teeth, and vertical root fractures were also excluded from this study (6). All patients were recalled at 1 year unless root canal treatment was needed before the anniversary, then recall was 1 year later after treatment. The recall therefore extended into a seventh year of the data collection.

All cases were treatment planned according to the pulpal and peritapical diagnosis. Cases with RP were treatment planned for crowns only, regardless of peritapical diagnosis.

TABLE 2. The Number and Percentage of Cracked Teeth by Tooth Position with RP Eventually Requiring Root Canal Treatment

	Maxillary Second Molar	Maxillary First Molar	Maxillary Second Premolar	Maxillary First Premolar	Mandibular Second Molar	Mandibular First Molar	Mandibular Second Premolar	Mandibular First Premolar	Totals
Cracked	12	33	8	4	29	41	0	0	127
REV. >IP or NEC.	3	9	0	0	8	7	0	0	27
%	25	27	0	0	28	17	0	0	21

REV, reversible pulpitis; IP, irreversible pulpitis; NEC, necrosis

Results

Of the 8175 cases seen during the 6-year period, 796 cases were diagnosed as cracked teeth (9.7%). Mandibular second molars (243/796, 30%) had the largest incidence followed by mandibular first molars (231/796, 29%) and maxillary first molars (167/796, 21%). All teeth are included in Table 1.

Cases with RP had the following distribution: mandibular first molars (41/127, 32%), maxillary first molars (33/127, 25%), and mandibular second molars (29/127, 23%). All teeth are included in Table 2.

Of 127 patients specifically diagnosed with RP, 27 converted to irreversible pulpitis (N = 21) in 58 days or to necrotic pulp (N = 6) in 149 days. The distribution of teeth requiring root canal therapy was as follows: maxillary first molars (9/27, 33%), mandibular second molars (8/27, 29%), mandibular first molars (7/27, 26%), and maxillary second molars (3/27, 11%).

All teeth had initial interproximal probings less than 3 mm in the space associated with the identified crack. Increased interproximal probings were associated with the fractured marginal ridge for only 5 of the 27 teeth requiring root canal treatment. The greatest increase in probing depth was 2 mm for 2 of 5 teeth.

The teeth requiring root canal treatment had the crack located on the distal marginal ridge in 15 of the 27 cases (56%). The distribution was mandibular second molars (6/27, 27%), mandibular first molars (3/27, 11%), maxillary first molars (3/27, 11%), maxillary second premolars (2/27, 7%), and maxillary second molars (1/27, 4%). The crack was located only on the mesial marginal ridge in 4 of the 27 cases (15%). The distribution was the maxillary first molars (3/27, 11%) and maxillary first premolars (1/27, 4%). Both marginal ridges were involved in 8 of the 27 cases (29%). The distribution was mandibular first molars (5/27, 19%), maxillary first molars (2/27, 7%), and maxillary second molars (1/27, 4%). None of the teeth had fractures that extended into the floor of the chamber or rendered them "non-restorable".

None of the original remaining 100 cases of RP required root canal treatment.

Discussion

The patients who composed this database were all patients referred to a private practice endodontist. Our incidence data are in agreement with the findings of Weine et al (5), which were also derived from an endodontist's practice. The difference in percentages from

How many pulps eventually died? 20%



other studies might be largely due to the nature of general dental populations versus an endodontic specialty population. Hiat (5) and Cameron (4) reported maxillary premolars having the second highest incidence of cracks, which represents a periodontist and general dental practice. Therefore, this study's population might be under-represented with respect to premolars and the actual incidence of cracked teeth in the population at large.

This study found that 21% of the cases diagnosed with RP and a crack eventually required root canal treatment. Although no other studies have reported this finding, there have been studies examining the necessity for root canal treatment on teeth restored with crowns. Saunders and Saunders (7) reported that 19% of crowned teeth in a Scottish dental school population had root canal treatment after crown placement. This study was unable to report whether cracks were present before the crown was placed.

Cheung et al (8) found that 15% (19/122) of teeth restored with a ceramo-metallic crown required root canal treatment after crown placement in a population in Asia. They also found that of those serving as an abutment of a fixed-fixed bridge (25/77), 32% required root canal treatment after final cementation of the bridge.

Although the populations in these 2 studies are quite diverse, the similar percentages for teeth requiring root canal treatment after crown placement suggest that 15%–19% of their patients are to be expected for all crowns. The 21% of the cases in this study with RP and cracks that were crowned and subsequently required root canal treatment is only slightly higher than the 15%–19% and suggests similar incidence data.

When examining a tooth with both mesial and distal marginal ridge fractures, the natural assumption would be that more of these teeth

would eventually require root canal treatment. Our data showed more teeth with a single marginal ridge crack, either mesial or distal, eventually required root canal treatment. This underlines the difficulty in predicting the eventual need for root canal treatment in teeth with RP and a cracked marginal ridge.

Conclusions

The outcomes of this study suggest that if a crack is identified early enough in cases with a diagnosis of RP and a crown is placed, root canal treatment will be necessary in about 20% of these cases within a 6-month period. Progression of interproximal periodontal defects associated with the crack(s) will occur in a very small percentage of the cases (5/127, 4%).

References

1. Cracking the cracked tooth code. Endodontics: Colleagues for Excellence 1997 (Fall/Winter):1–15.
2. Aizer JJ Jr. Margging incomplete tooth fractures. J Am Dent Assoc 2000;131:1168–74.
3. Hiat NH. Incomplete crown root fracture in pulpal periodontal disease. J Periodontol 1973;44:369–79.
4. Cameron GE. The cracked tooth syndrome: additional findings. J Am Dent Assoc 1976;93:971–5.
5. Wene FS, Detharry Jr, James A. Cracked tooth syndrome: vertical fractures of posterior teeth. In: Wene FS, ed. Endodontic therapy, 3rd ed. St Louis: Mosby, 1982:8–15.
6. Rivera EM, Walton BE. Longitudinal fractures. In: Torabinejad M, Walton BE, eds. Principles and practice of endodontics, 4th ed. Philadelphia: Saunders, in press.
7. Saunders WP, Saunders EM. Prevalence of periradicular periodontitis associated with crowned teeth in an adult Scottish subpopulation. Br Dent J 1998;185:137–40.
8. Cheung GS, Lee SC, Ng RP. Fate of vital pulps beneath a metal-ceramic crown or a bridge retainer. Int Endod J 2005;38:521–30.

What is the
pulpal death
rate for any
tooth w/ a
crown? 15-
19%



other studies might be largely due to the nature of general dental populations versus an endodontic specialty population. Blatt (3) and Cameron (4) reported mandibular premolars having the second highest incidence of cracks, which represents a periodontist and general dental practice. Therefore, this study's population might be under-represented with respect to premolars and the actual incidence of cracked teeth in the population at large.

This study found that 21% of the cases diagnosed with RP and a crack eventually required root canal treatment. Although no other studies have reported this finding, there have been studies examining the necessity for root canal treatment on teeth restored with crowns. Saunders and Saunders (7) reported that 19% of crowned teeth in a Scottish dental school population had root canal treatment after crown placement. This study was unable to report whether cracks were present before the crown was placed.

Cheong et al (8) found that 15% (19/122) of teeth restored with a ceramo-metallic crown required root canal treatment after crown placement in a population in Asia. They also found that of those serving as an abutment of a fixed-fixed bridge (25/77), 32% required root canal treatment after final cementation of the bridge.

Although the populations in these 2 studies are quite diverse, the similar percentages for teeth requiring root canal treatment after crown placement suggest that 15%–19% of their patients are to be expected for all crowns. The 21% of the cases in this study with RP and cracks that were crowned and subsequently required root canal treatment is only slightly higher than the 15%–19% and suggests similar incidence data.

When examining a tooth with both mesial and distal marginal ridge fractures, the natural assumption would be that more of these teeth

would eventually require root canal treatment. Our data showed more teeth with a single marginal ridge crack, either mesial or distal, eventually required root canal treatment. This underlines the difficulty in predicting the eventual need for root canal treatment in teeth with RP and a cracked marginal ridge.

Conclusions

The outcomes of this study suggest that if a crack is identified early enough in cases with a diagnosis of RP and a crown is placed, root canal treatment will be necessary in about 20% of these cases within a 6-month period. Progression of interproximal periodontal defects associated with the crack(s) will occur in a very small percentage of the cases (5/127, 4%).

References

1. Cracking the cracked tooth code. Endodontics: Guidelines for Excellence 1997 (Fall/Winter):1–13.
2. Aher JE Jr. Managing incomplete tooth fractures. J Am Dent Assoc 2000;131:1168–74.
3. Blatt W. Incomplete crown construction in pulpal periodontal disease. J Periodontol 1973;44:269–70.
4. Cameron CE. The cracked tooth syndrome: additional findings. J Am Dent Assoc 1976;83:971–5.
5. Wetse FS, Desberry Jr, James A. Cracked-tooth syndrome: vertical fractures of posterior teeth. In: Wetse FS, ed. Endodontic therapy. 5th ed. St Louis: Mosby, 1982:6–15.
6. Rivera EM, Wilson RE. Longitudinal fractures. In: Torabianaj H, Walton RE, eds. Principles and practice of endodontics, 4th ed. Philadelphia: Saunders, in press.
7. Saunders WP, Saunders EM. Prevalence of periodontal periodontitis associated with crowned teeth in an adult Scottish subpopulation. Br Dent J 1998;185:137–40.
8. Cheong GS, Lee SC, Ng RP. Fate of vital pulps beneath a metal-ceramic crown on a bridge abutment. Int Endod J 2005;38:521–30.

What is the pulpal death rate for bridge abutments? 32%



other studies might be largely due to the nature of general dental populations versus an endodontic specialty population. Iliatt (3) and Cameron (4) reported mandibular premolars having the second highest incidence of cracks, which represents a periodontist and general dental practice. Therefore, this study's population might be under-represented with respect to premolars and the actual incidence of cracked teeth in the population at large.

This study found that 21% of the cases diagnosed with RP and a crack eventually required root canal treatment. Although no other studies have reported this finding, there have been studies examining the necessity for root canal treatment on teeth restored with crowns. Saunders and Saunders (7) reported that 19% of crowned teeth in a Scottish dental school population had root canal treatment after crown placement. This study was unable to report whether cracks were present before the crown was placed.

Cheong et al (8) found that 15% (19/122) of teeth restored with a ceramo-metallic crown required root canal treatment after crown placement in a population in Asia. They also found that of those serving as an abutment of a fixed-fixed bridge (25/77), 32% required root canal treatment after final cementation of the bridge.

Although the populations in these 2 studies are quite diverse, the similar percentages for teeth requiring root canal treatment after crown placement suggest that 15%–19% of their patients are to be expected for all crowns. The 21% of the cases in this study with RP and cracks that were crowned and subsequently required root canal treatment is only slightly higher than the 15%–19% and suggests similar incidence data.

When examining a tooth with both mesial and distal marginal ridge fractures, the natural assumption would be that more of these teeth

would eventually require root canal treatment. Our data showed more teeth with a single marginal ridge crack, either mesial or distal, eventually required root canal treatment. This underlines the difficulty in predicting the eventual need for root canal treatment in teeth with RP and a cracked marginal ridge.

Conclusions

The outcomes of this study suggest that if a crack is identified early enough in cases with a diagnosis of RP and a crown is placed, root canal treatment will be necessary in about 20% of these cases within a 6-month period. Progression of interproximal periodontal defects associated with the crack(s) will occur in a very small percentage of the cases (5/127, 4%).

References

1. Cracking the cracked tooth code. Endodontics: Colquhoun for Excellence 1997 (Fall/Winter):1–13.
2. Aher JE Jr. Managing incomplete tooth fractures. J Am Dent Assoc 2000;131:1168–74.
3. Iliatt WJ. Incomplete crown construction in pulpal periodontal disease. J Periodontol 1973;44:269–70.
4. Cameron CE. The cracked tooth syndrome: additional findings. J Am Dent Assoc 1970;63:971–5.
5. Wetton PS, Desberry Jr, James A. Cracked-tooth syndrome: vertical fractures of posterior teeth. In: Wetton PS, ed. Endodontic therapy. 5th ed. St Louis: Mosby, 1982:6–15.
6. Rivera EM, Wilson RL. Longitudinal fractures. In: Torabinejad M, Walton RE, eds. Principles and practice of endodontics, 4th ed. Philadelphia: Saunders, in press.
7. Saunders GP, Saunders EM. Prevalence of periodontal periodontitis associated with crowned teeth in an adult Scottish subpopulation. Br Dent J 1998;185:137–40.
8. Cheong GS, Lee BK, Ng RP. Rate of vital pulps beneath a metal-ceramic crown on a bridge retainer. Int J Endod J 2005;38:521–30.

Big picture:
Cracked teeth
with R.P. don't
necessarily
need endo.



Big picture:
Prepare,
impress and
temporize
normally but
wait 6-8 weeks
to seat crown



Big picture:

For smaller ICF's
with mild symptoms,
a gold or porcelain
onlay may obviate
the wait period for
the crown seat.



Big picture:

Bioclear

Composite

Overlays have
shown immediate
elimination of
symptoms*



Big picture:

PROBE!

PROBE!

PROBE!

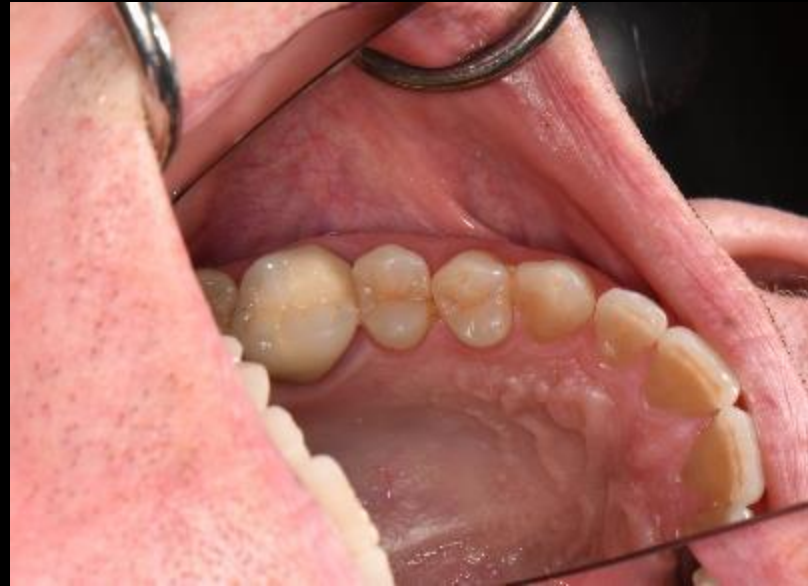

What is our most
reliable clinical test for
irreversible pulpitis?

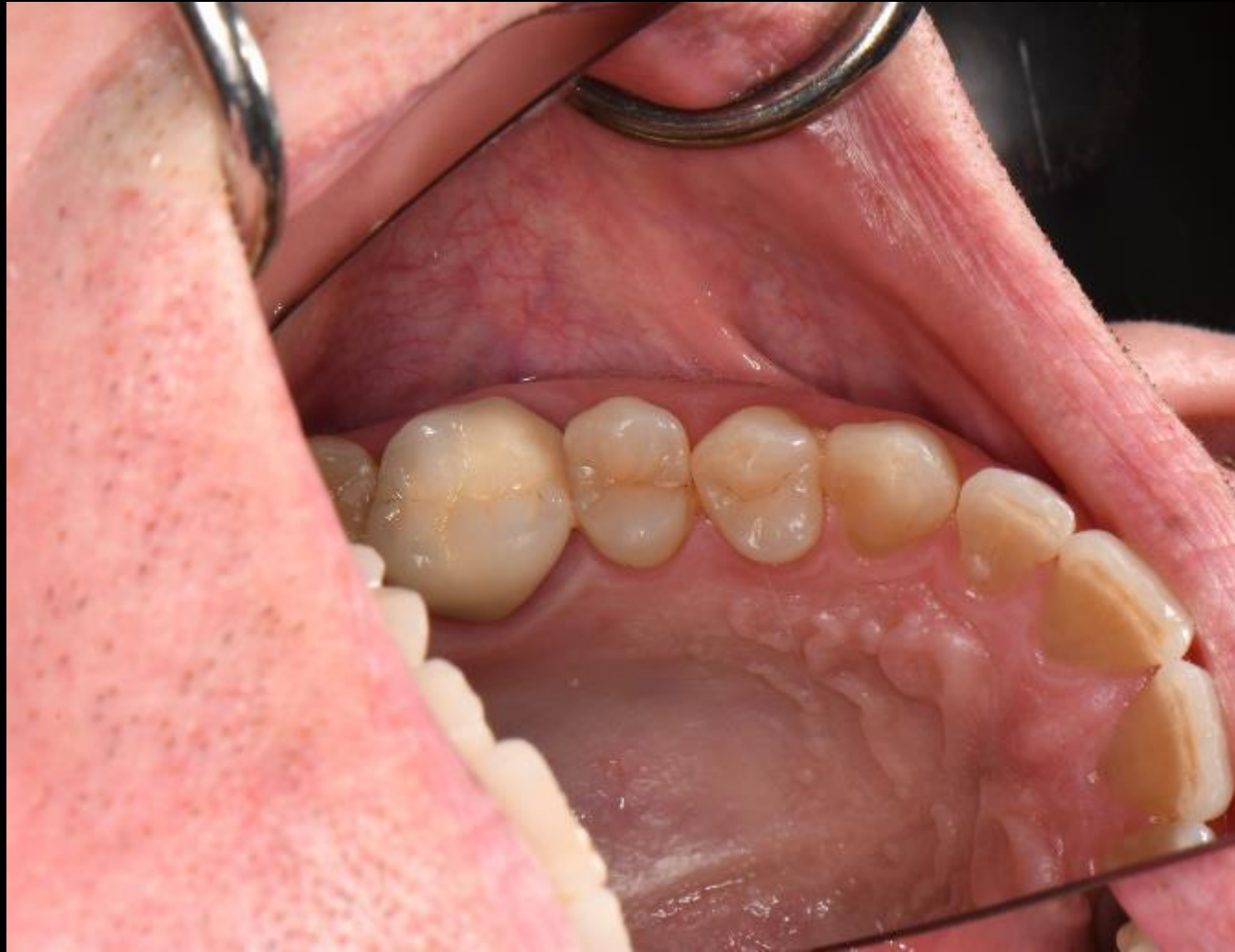**PERCUSSION TEST,
and REPEAT**



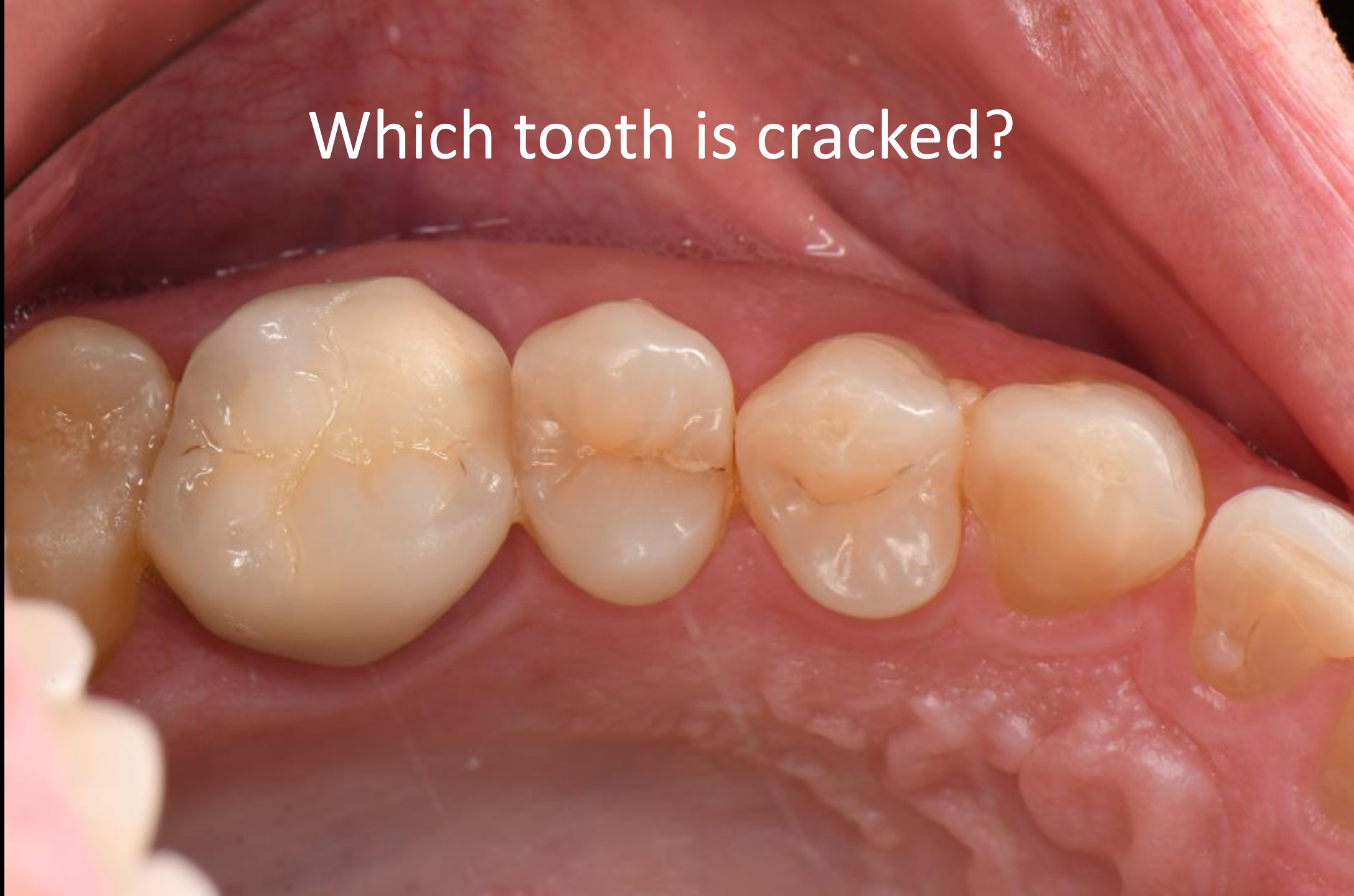Which tooth is cracked?



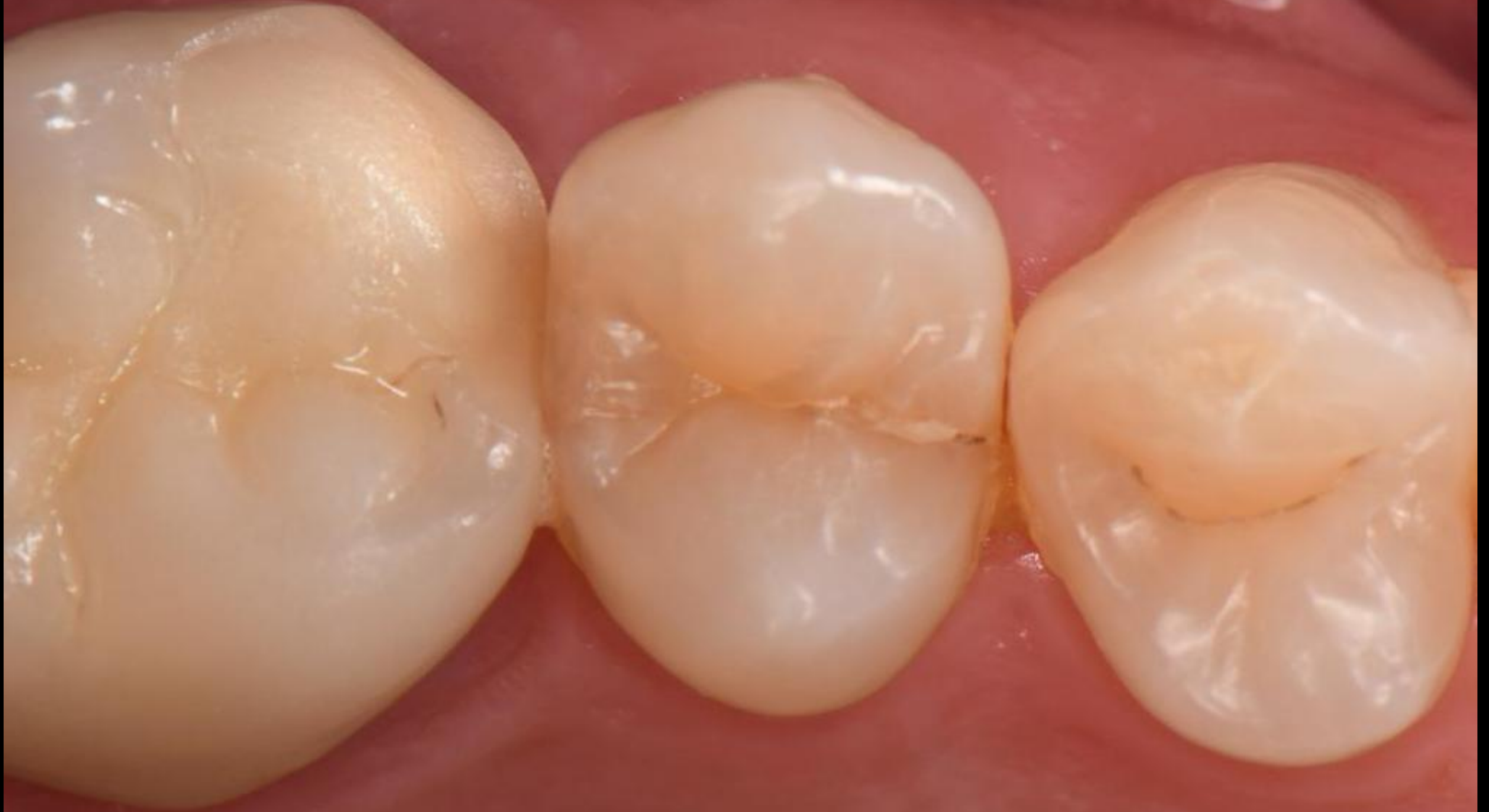Which tooth is cracked?



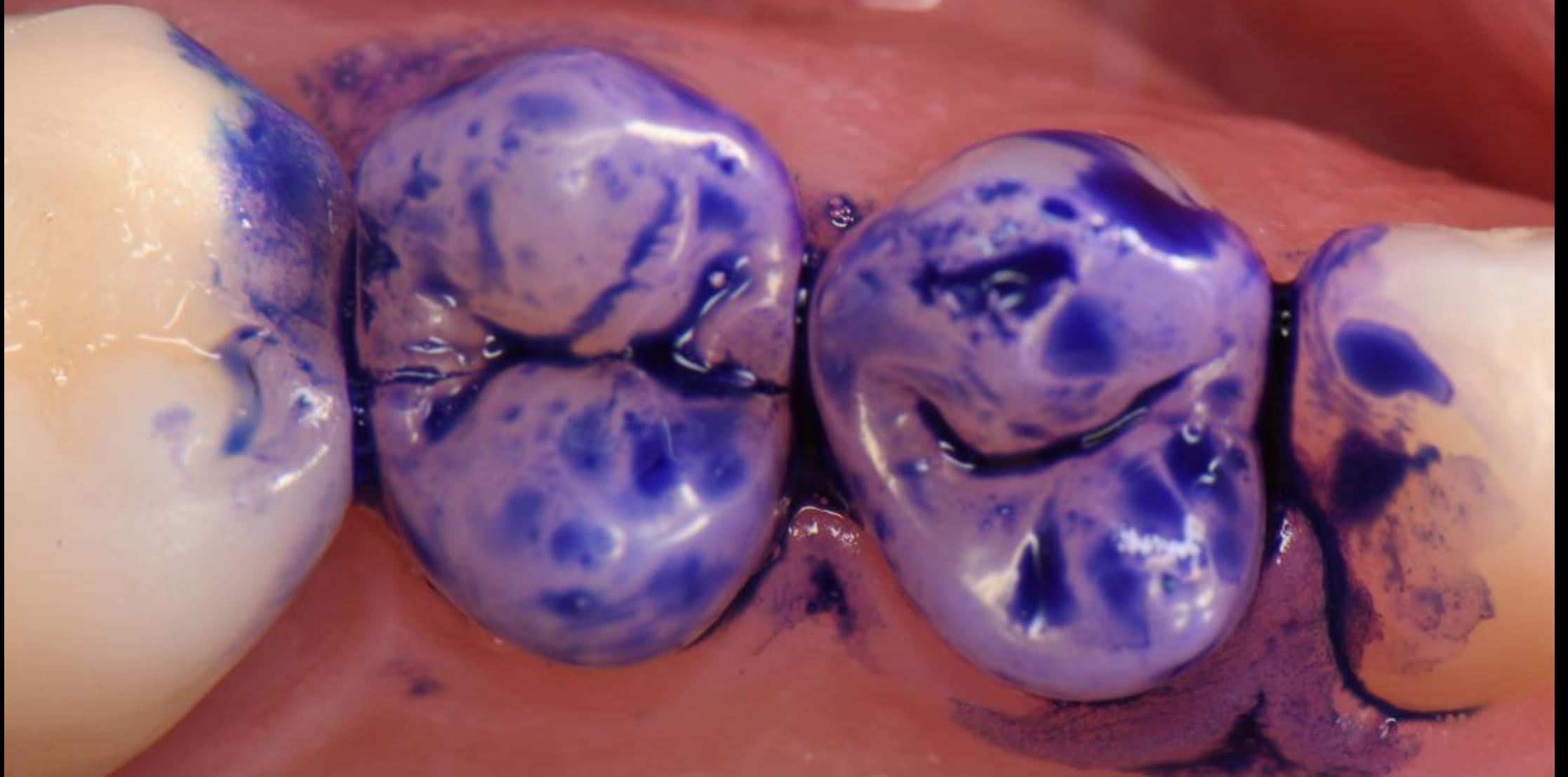Which tooth is cracked?

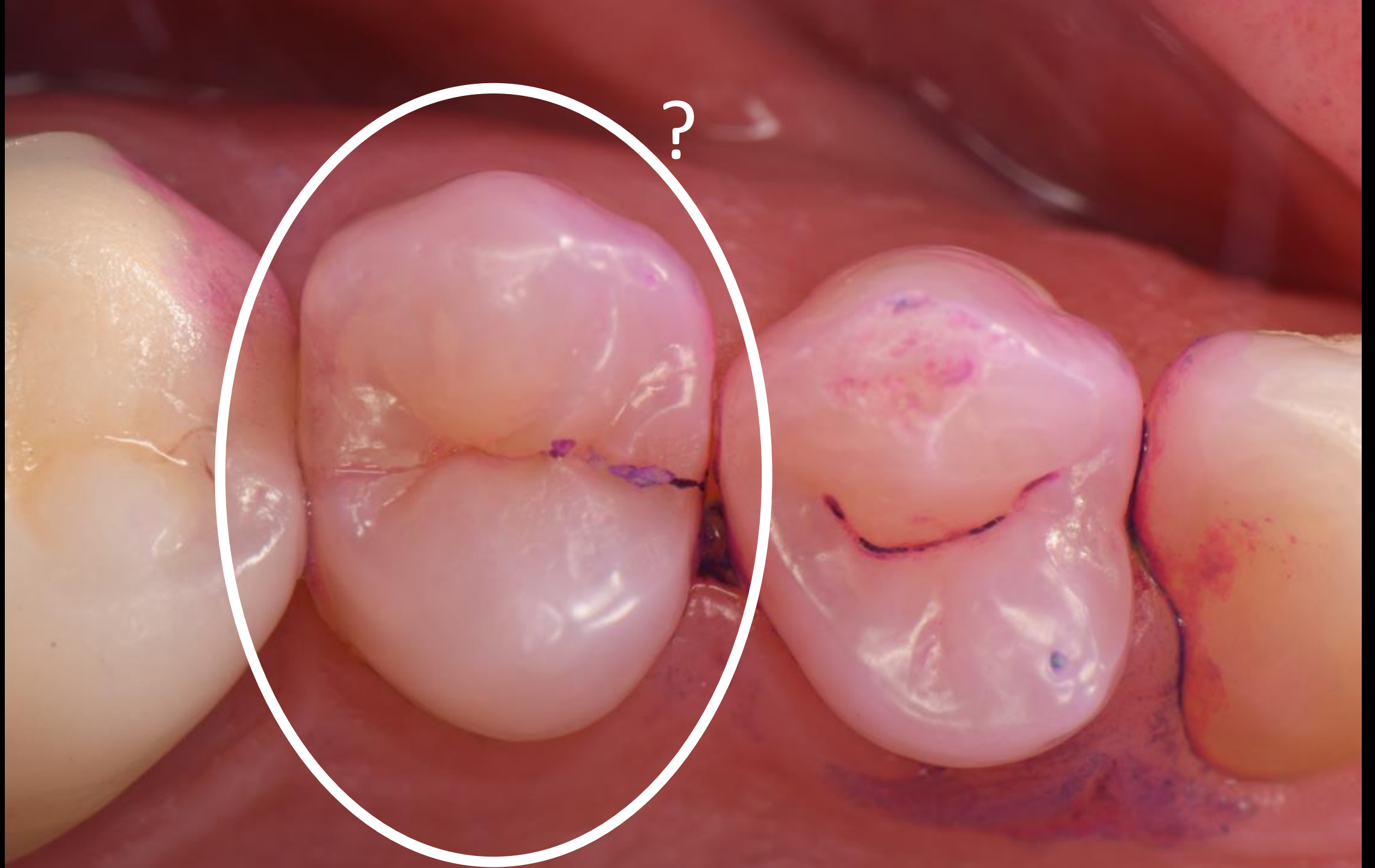


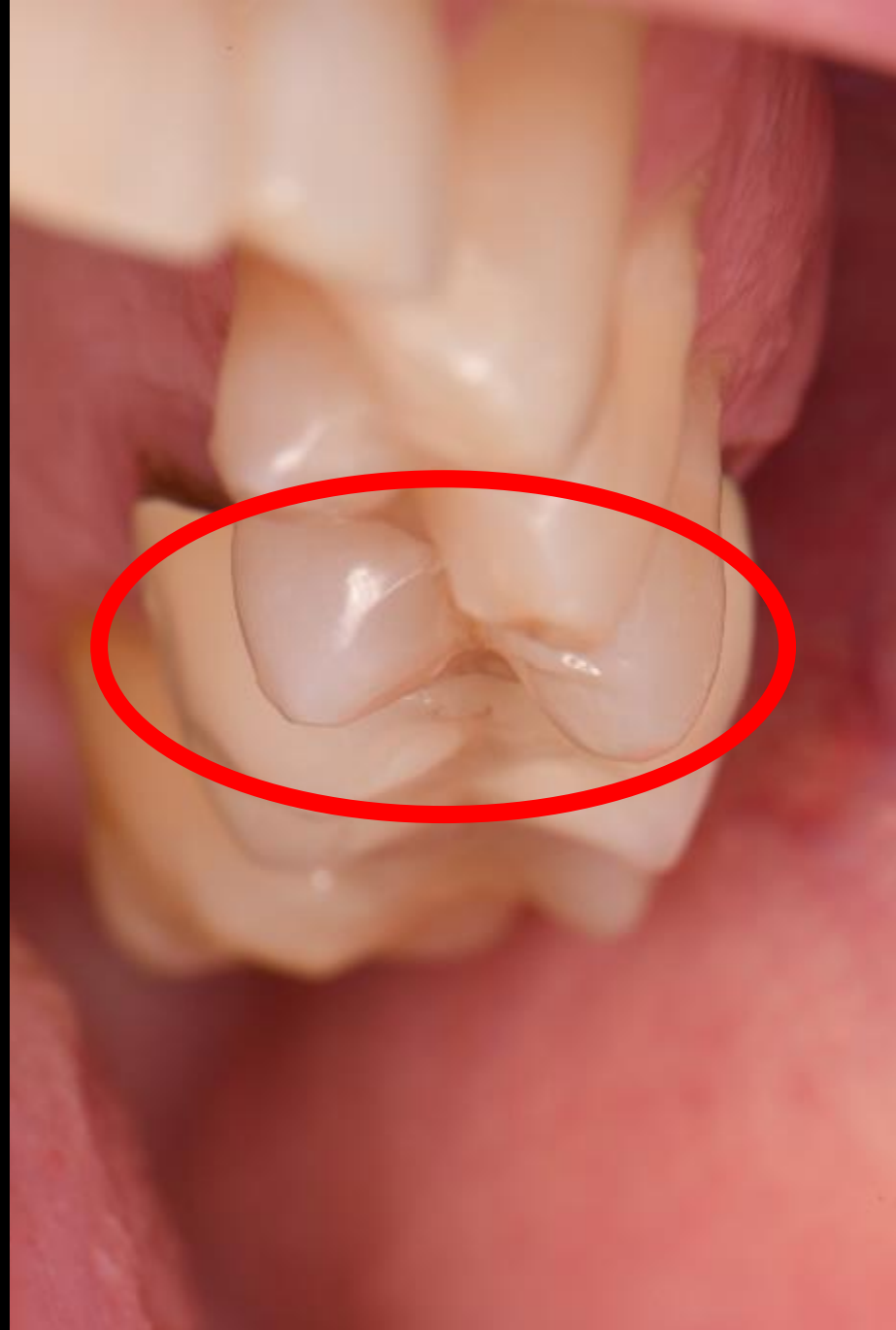Which tooth is cracked?

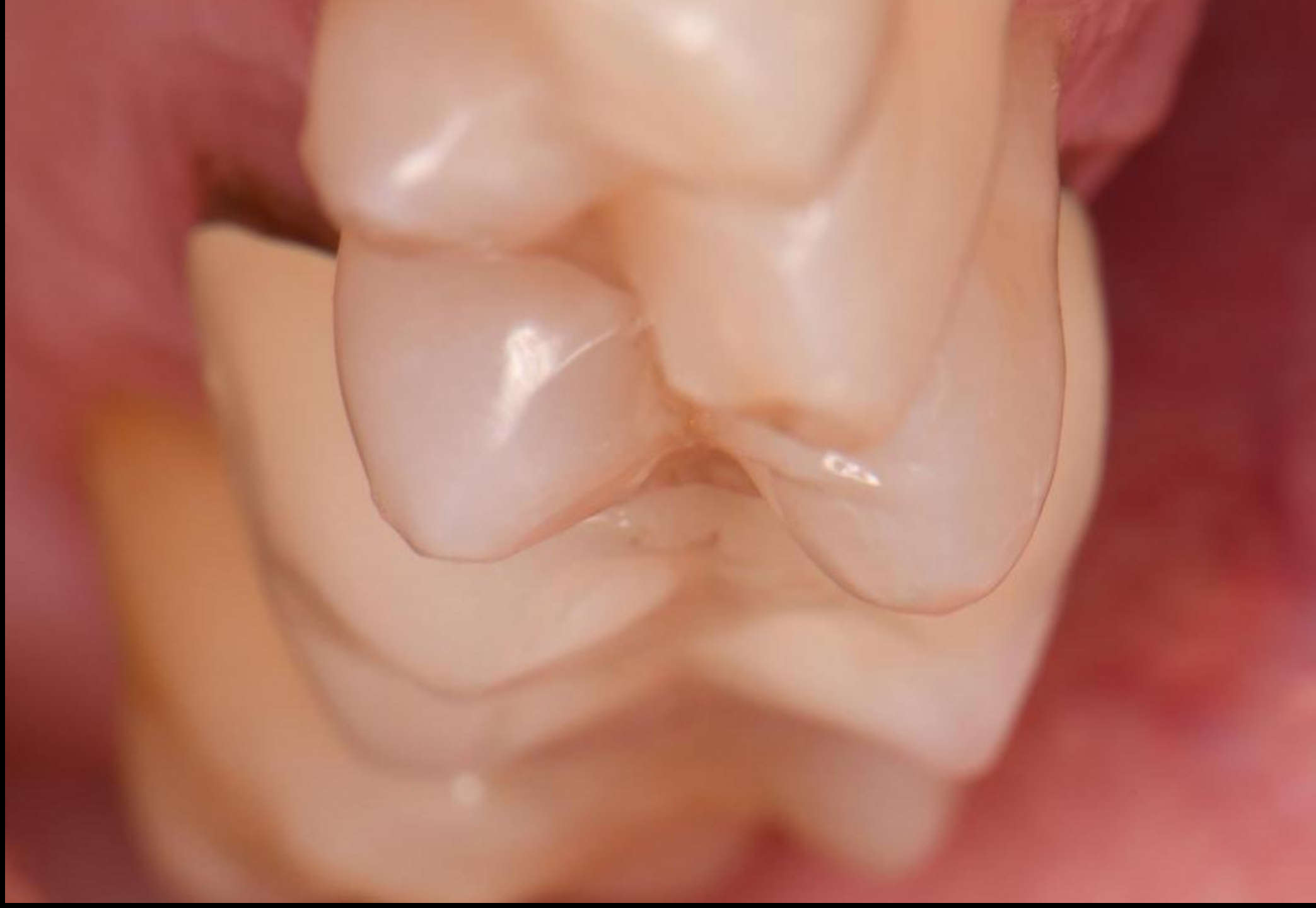

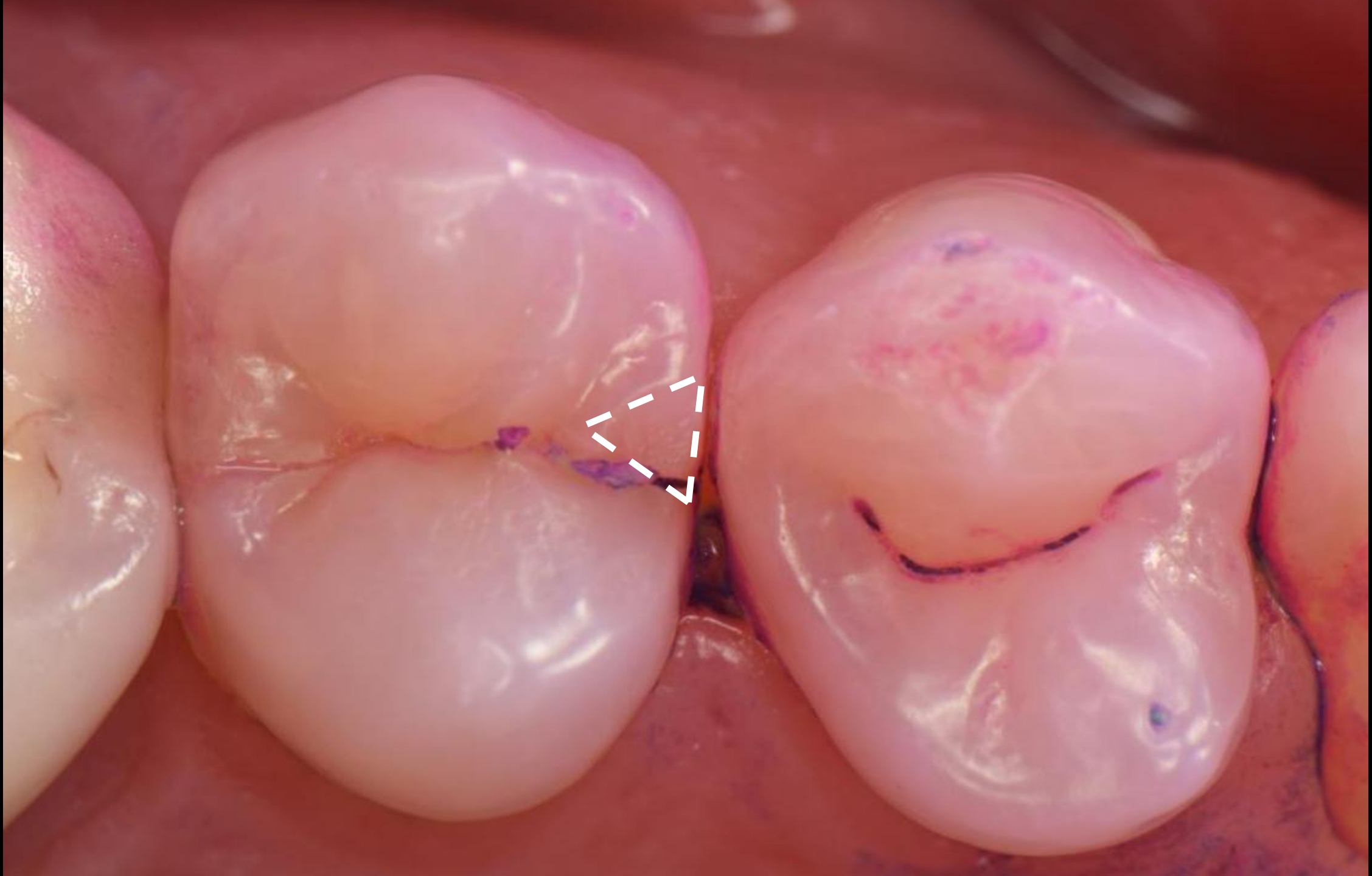?

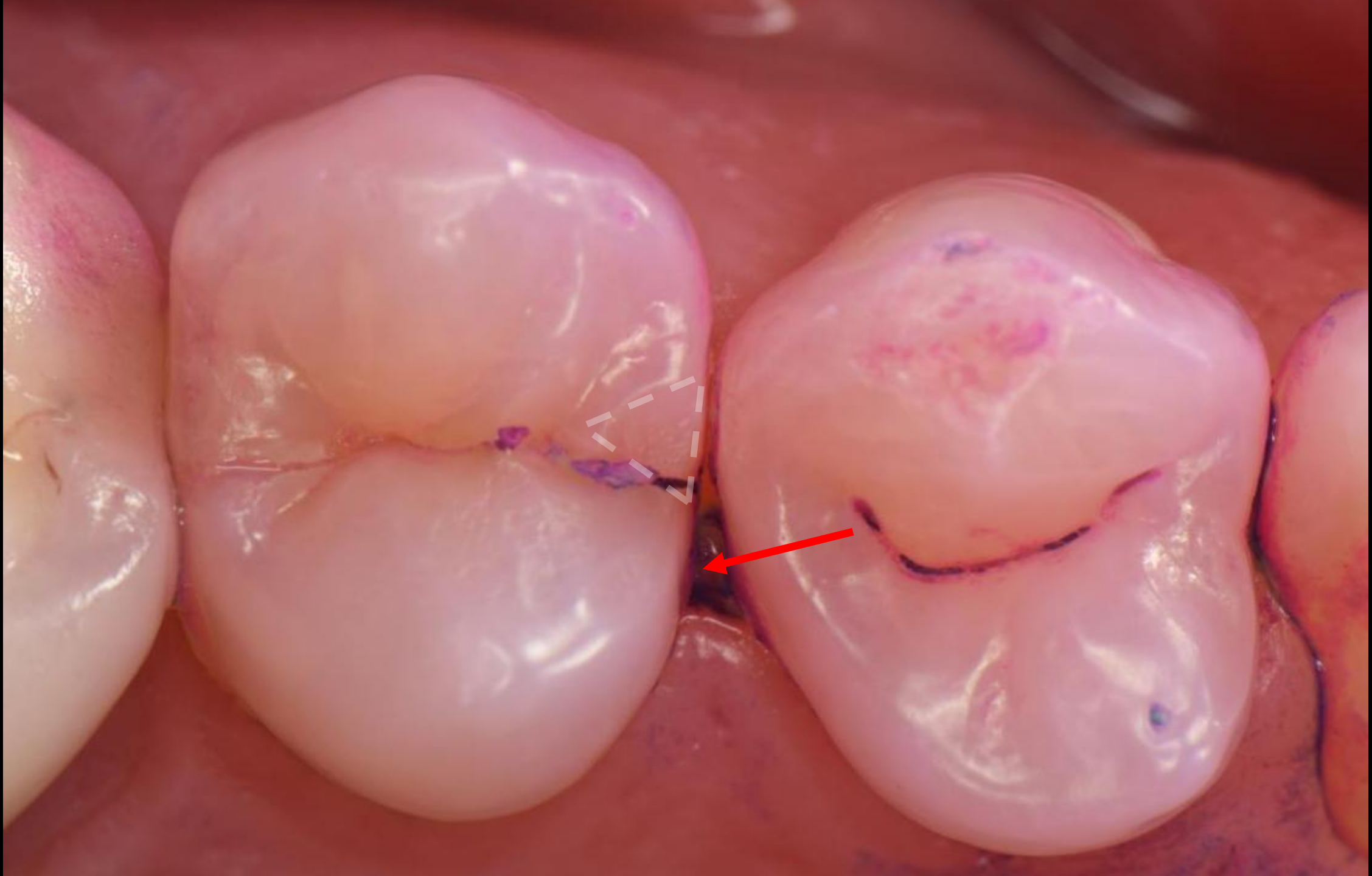


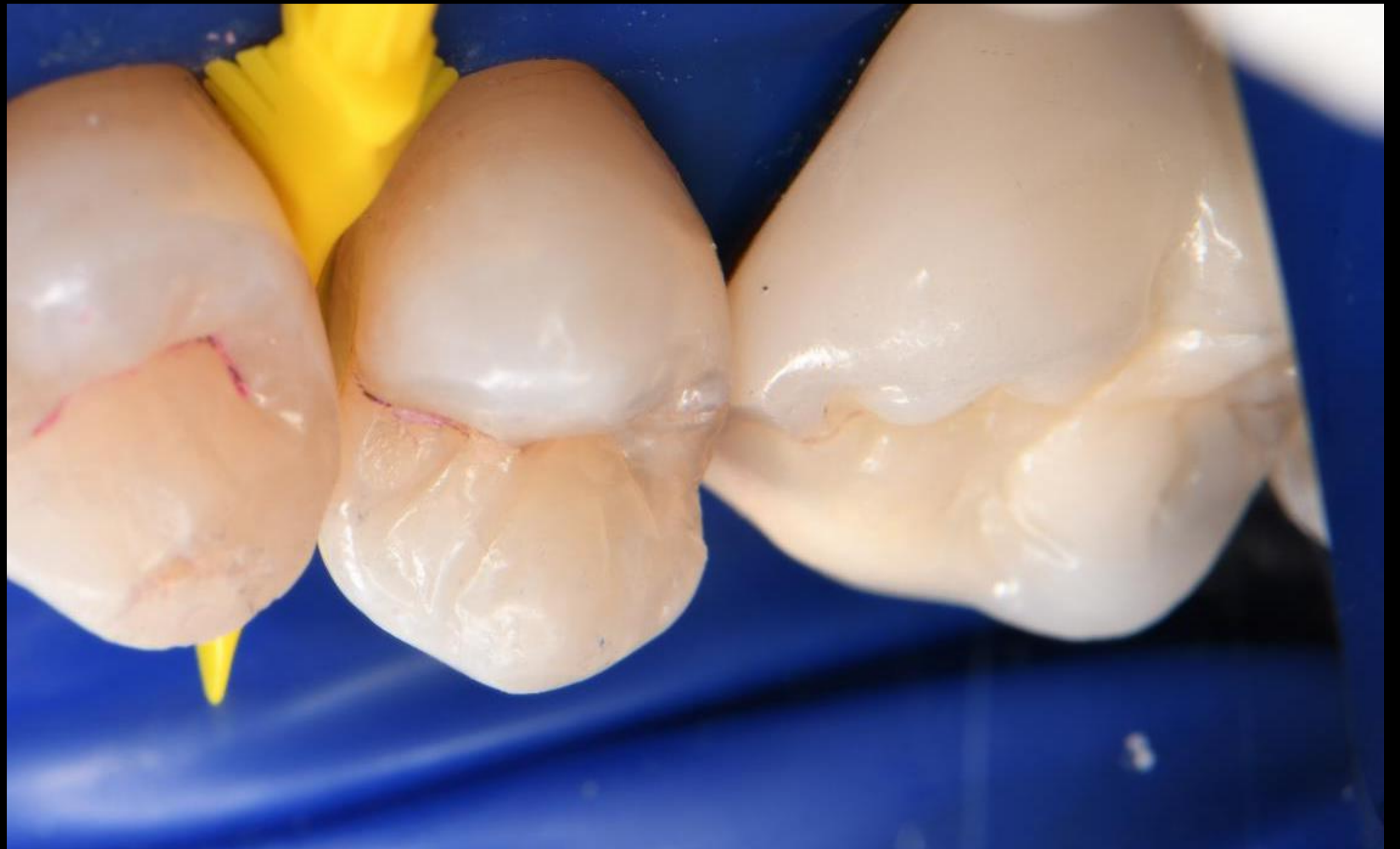


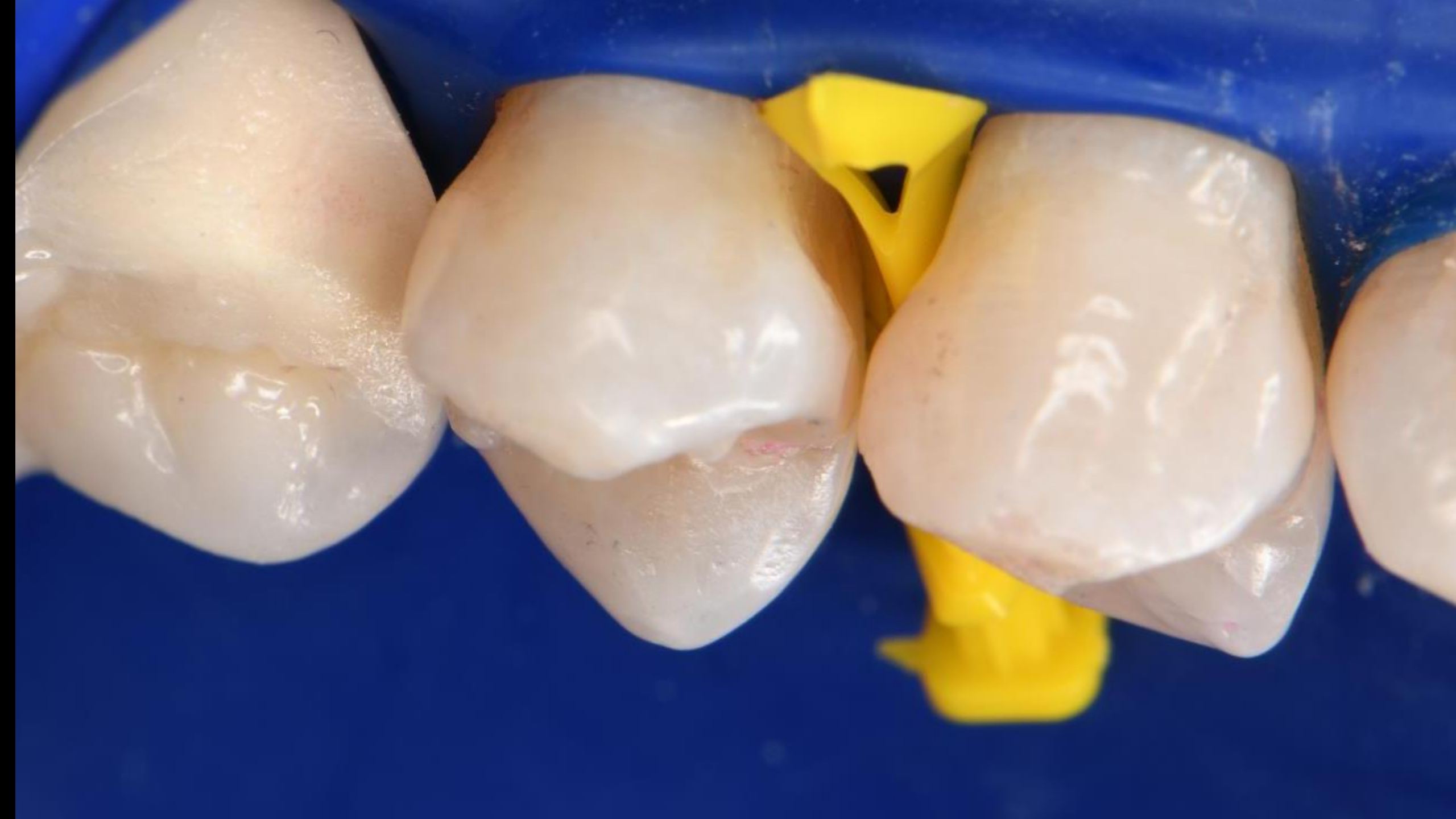


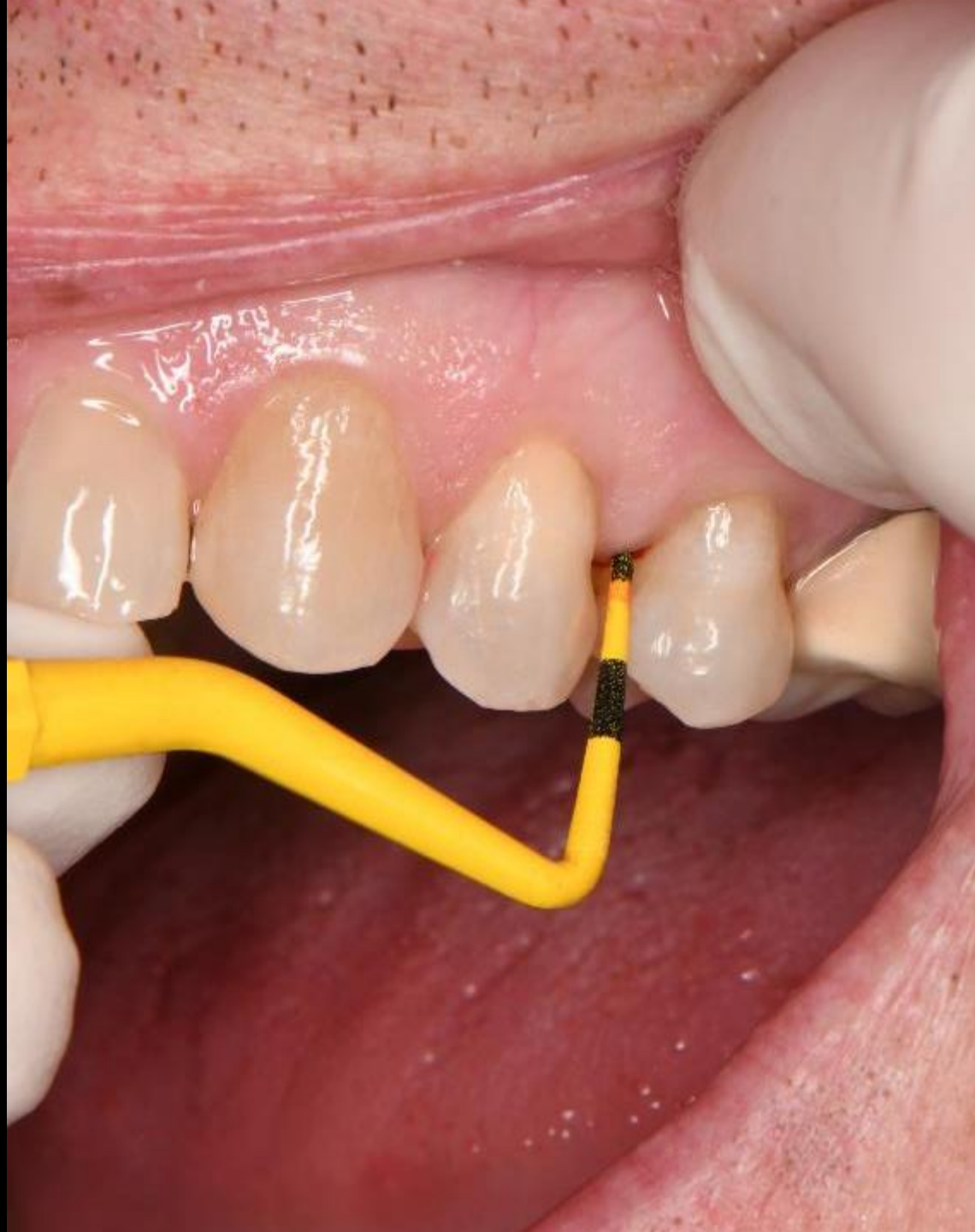

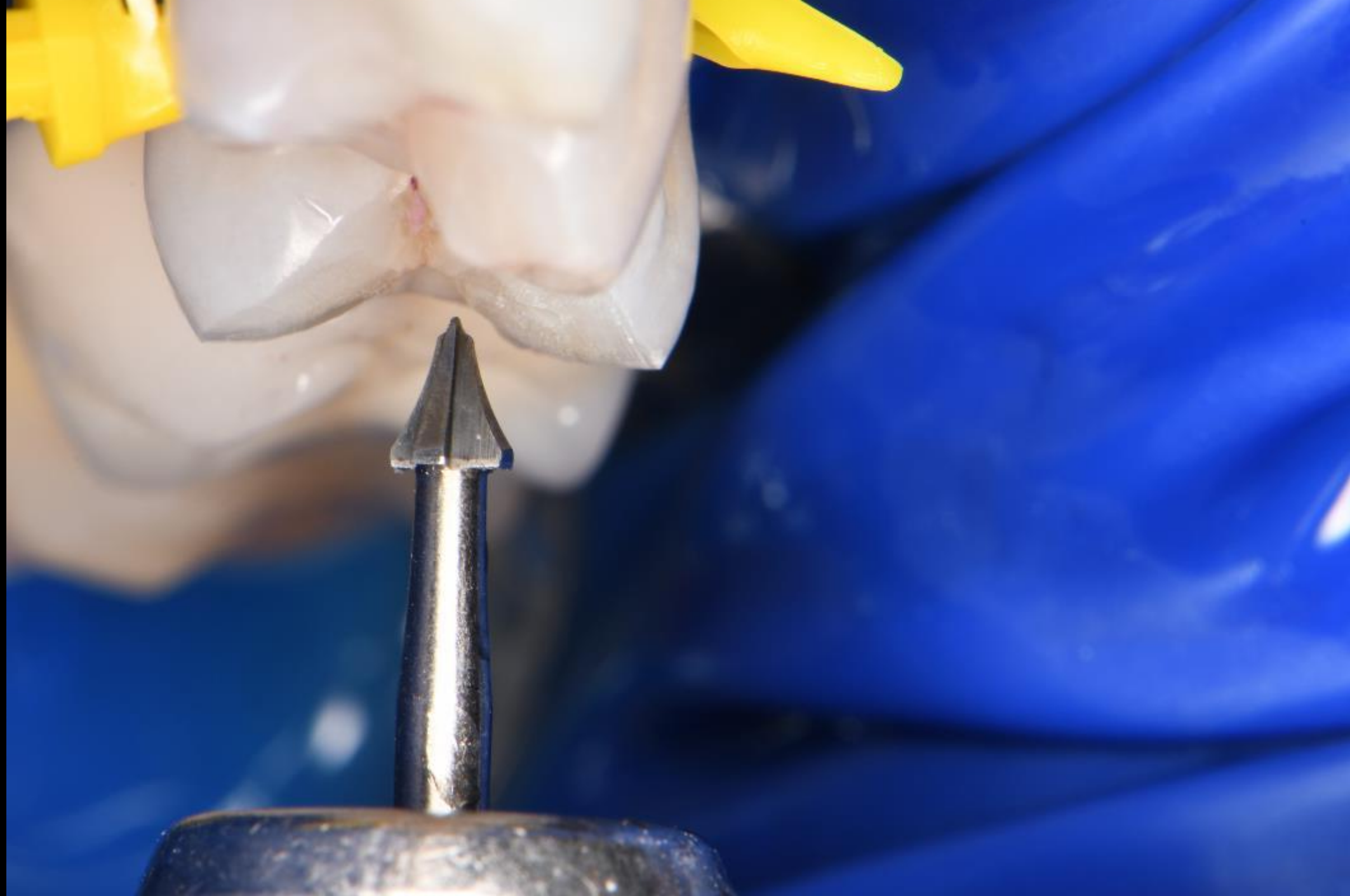







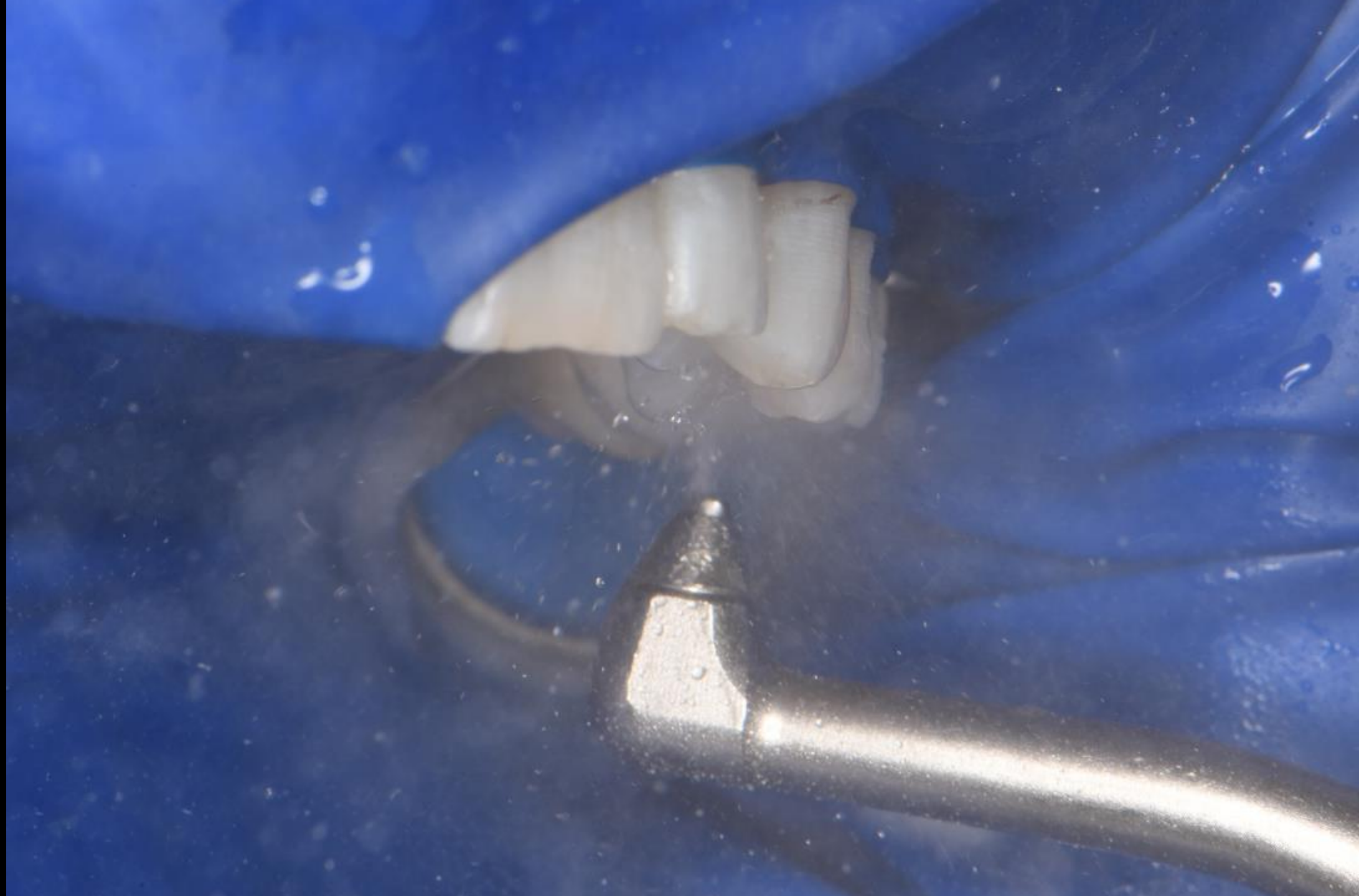


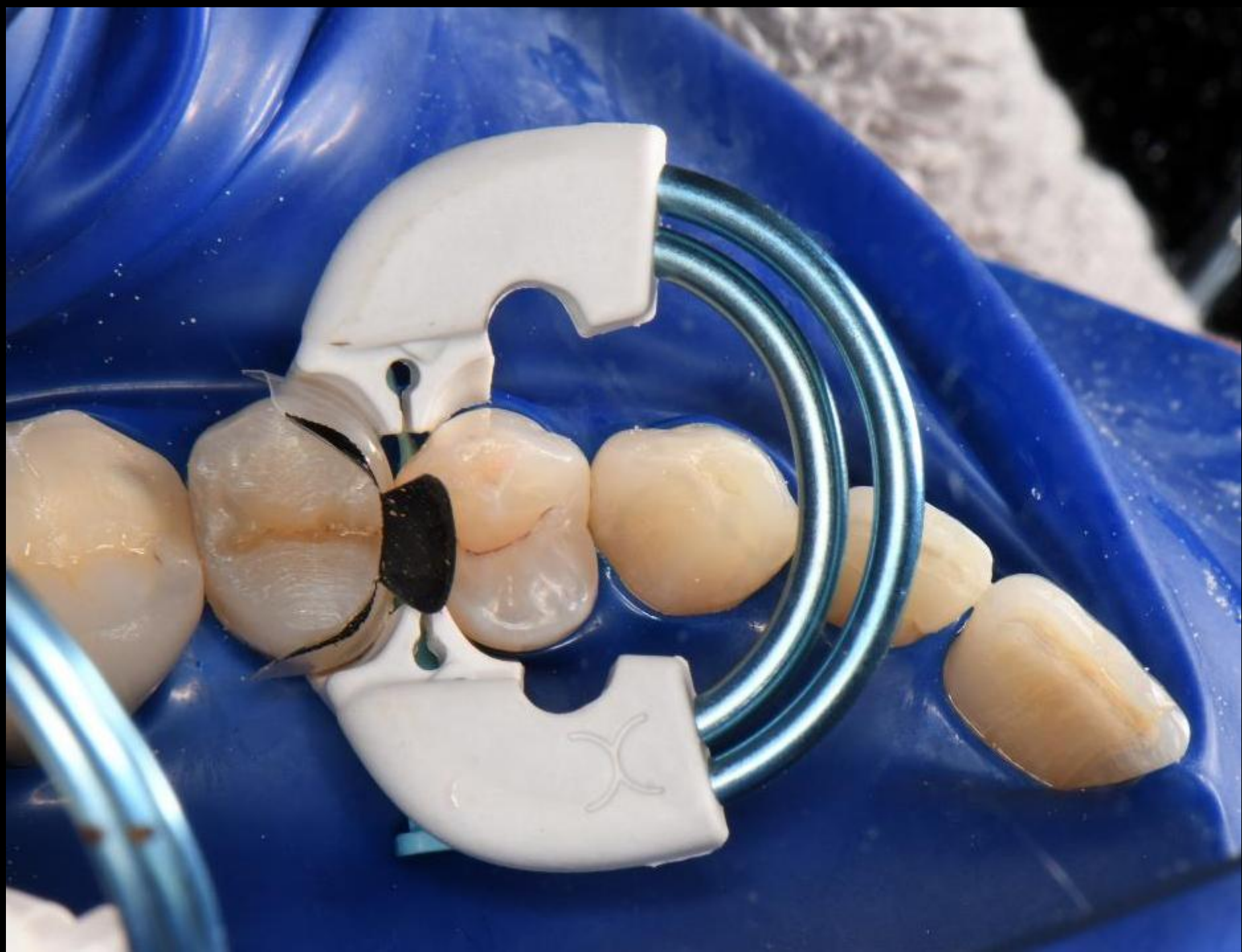


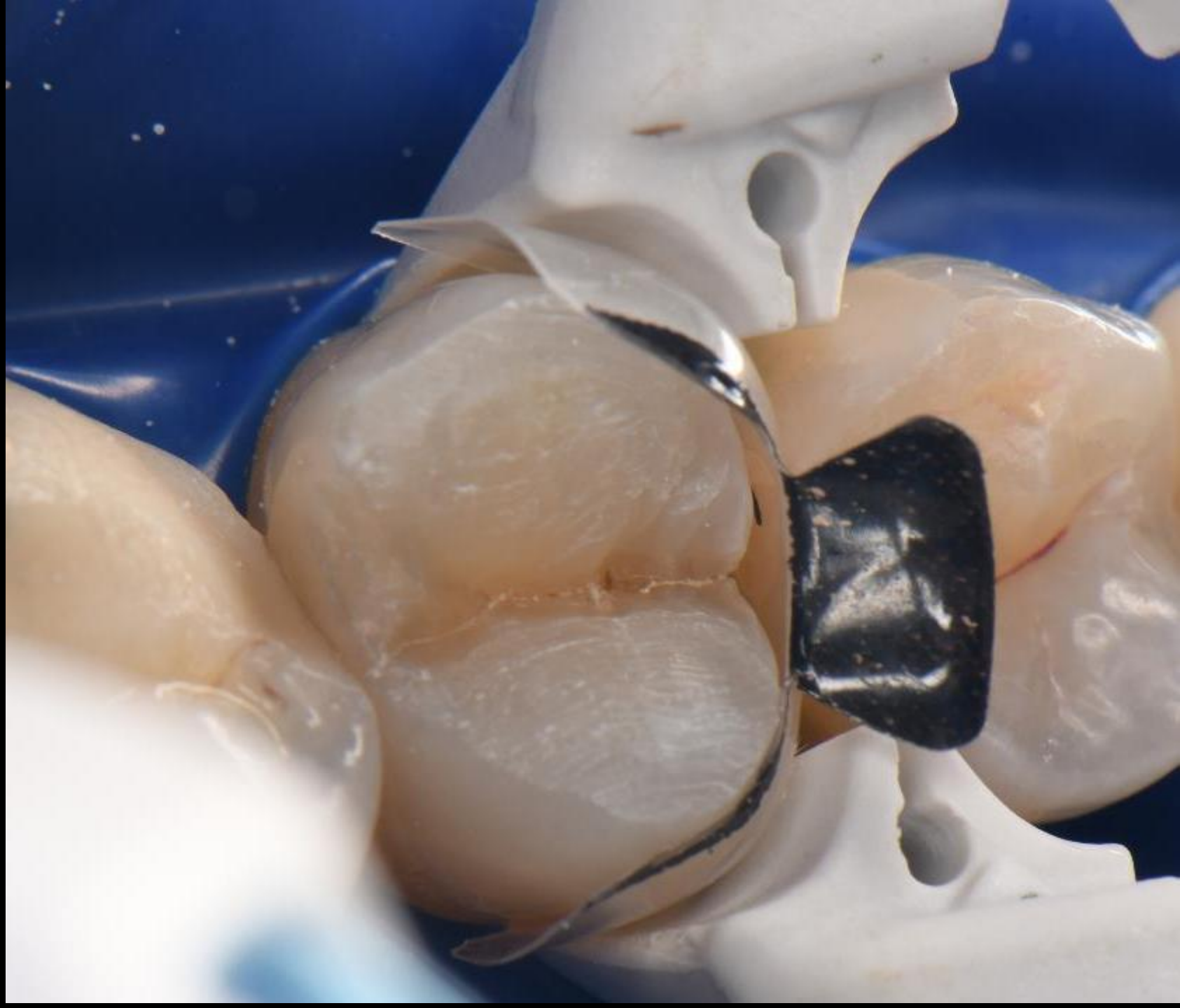


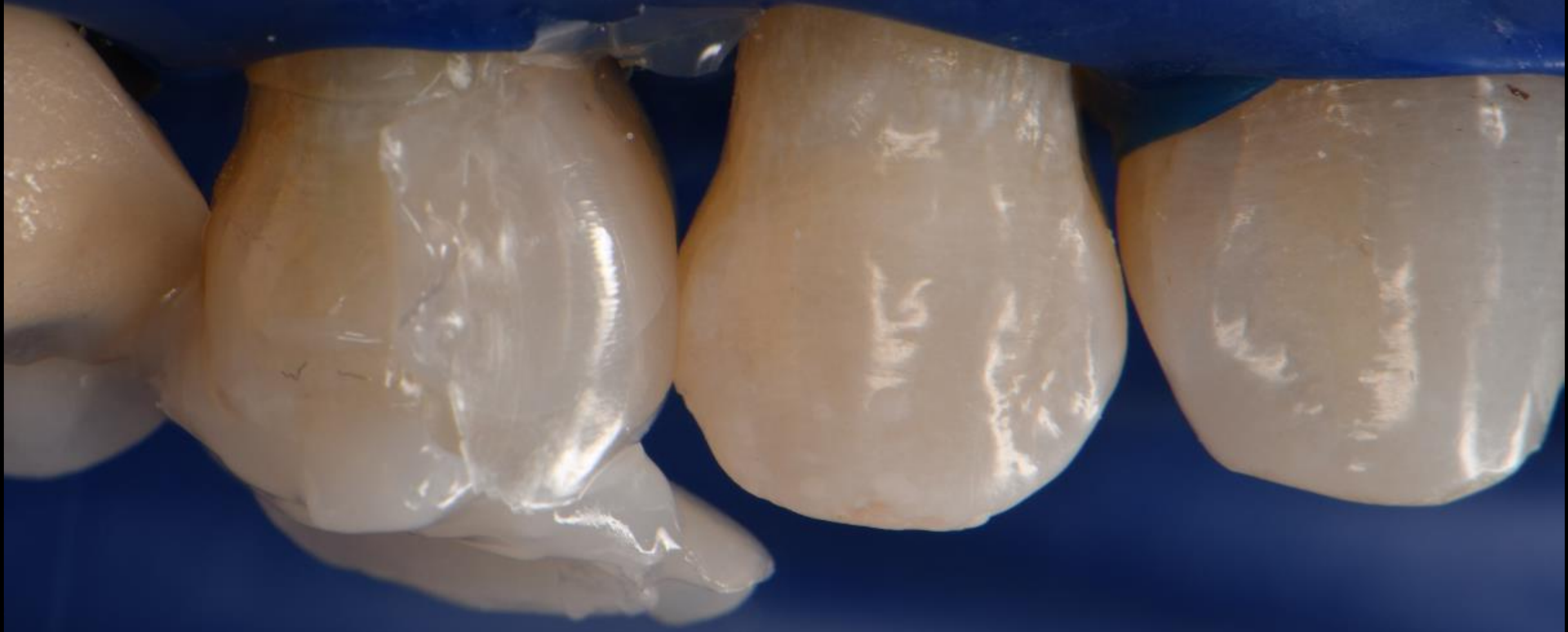


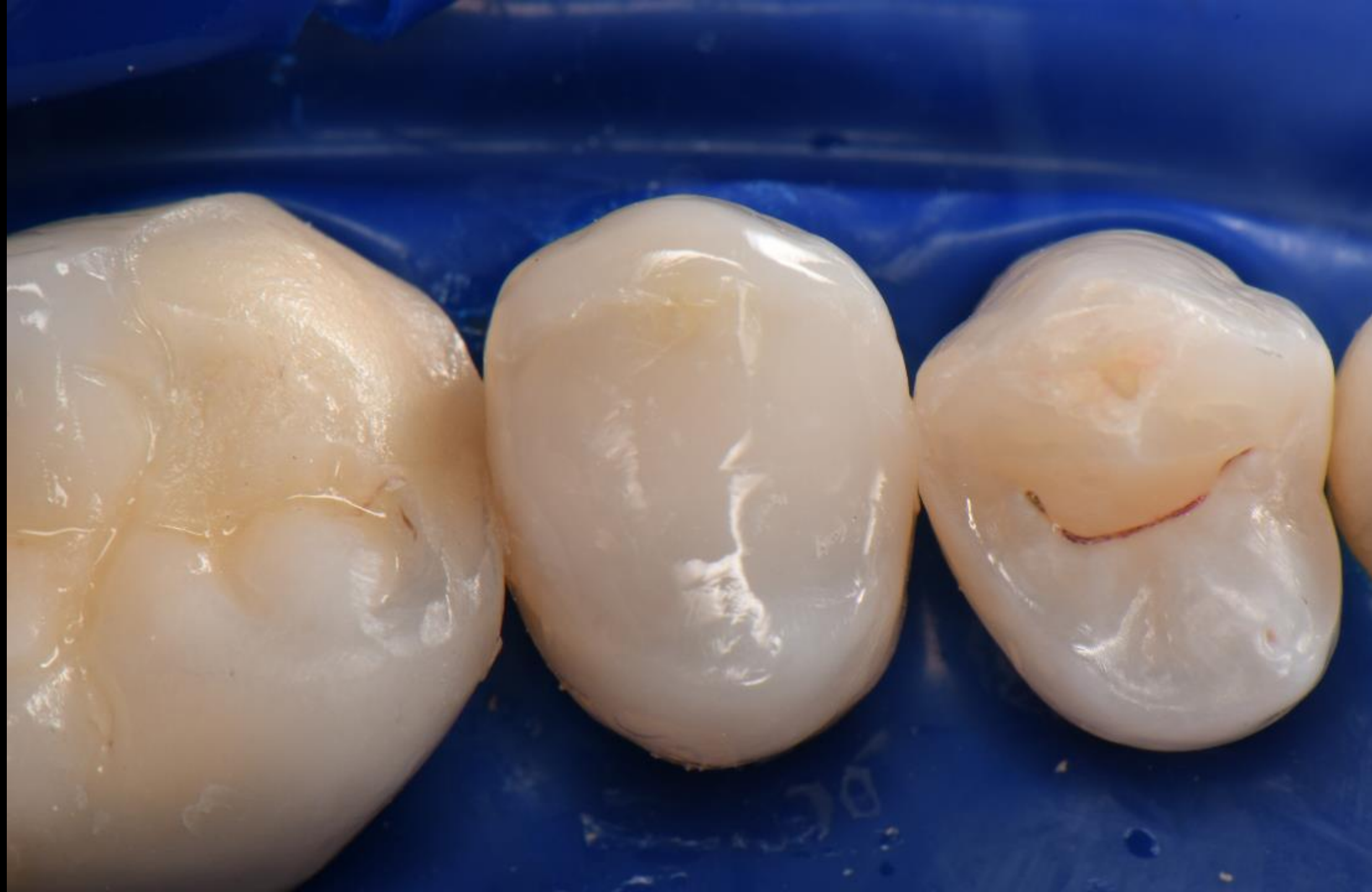


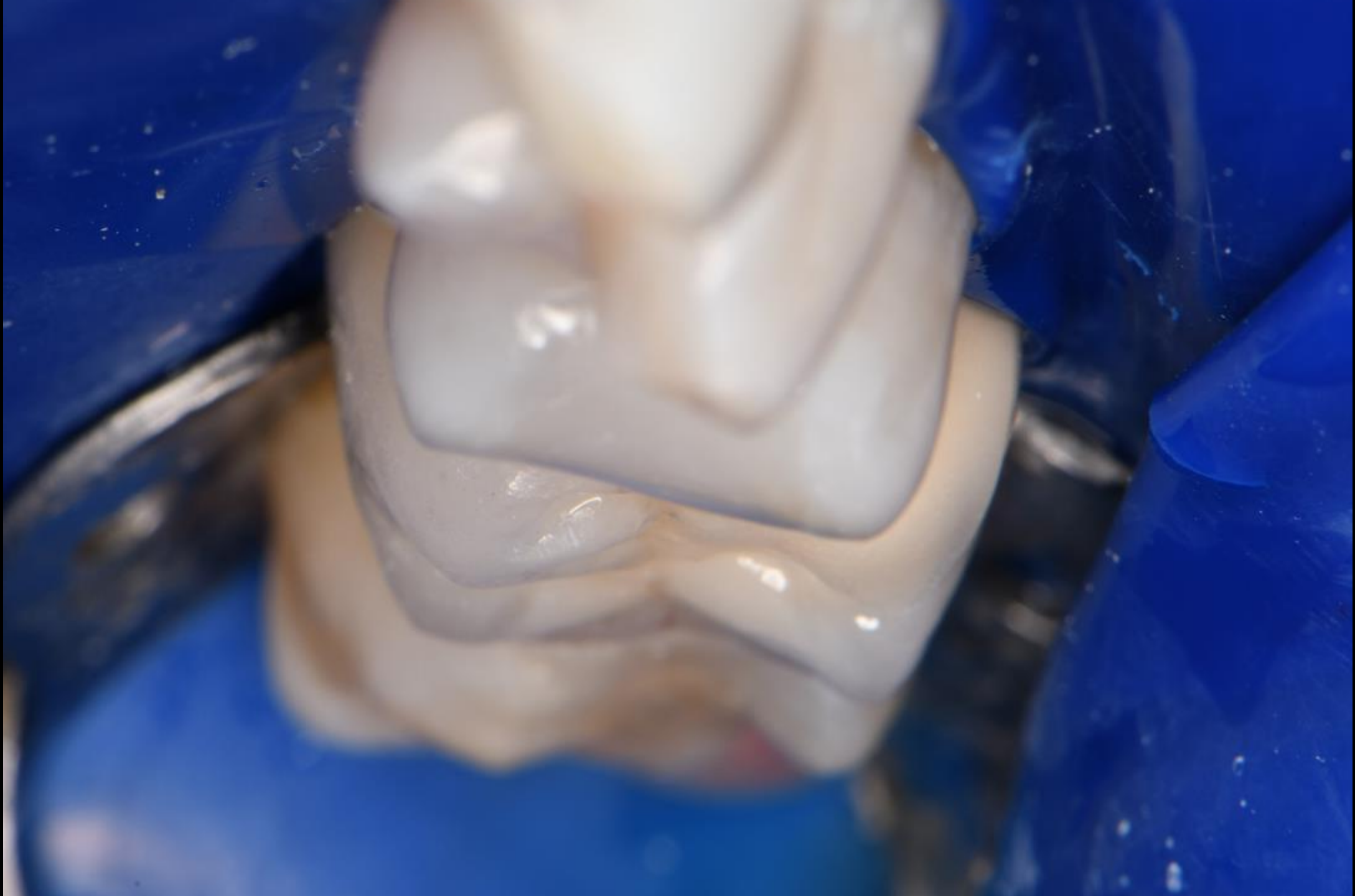


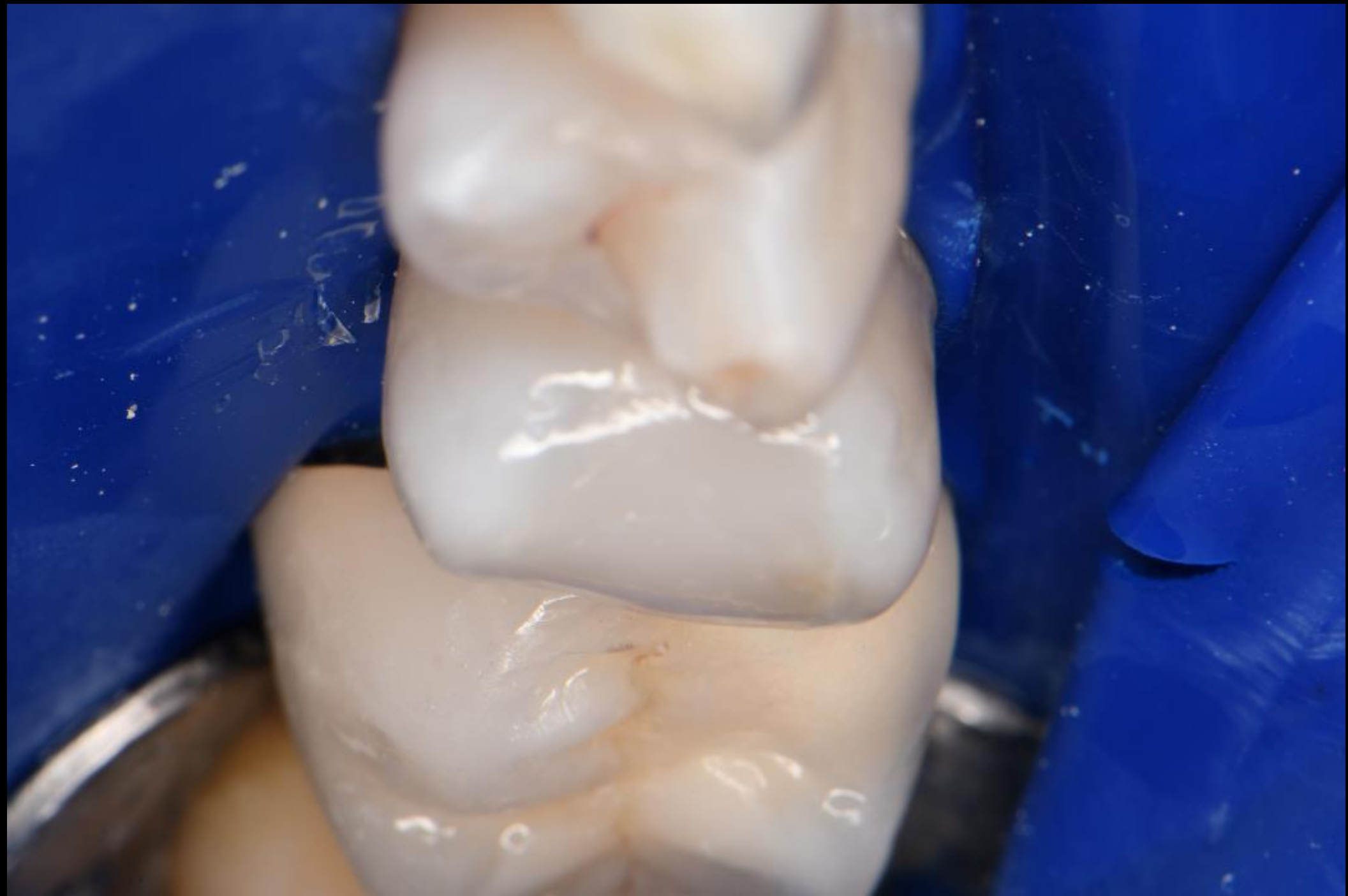


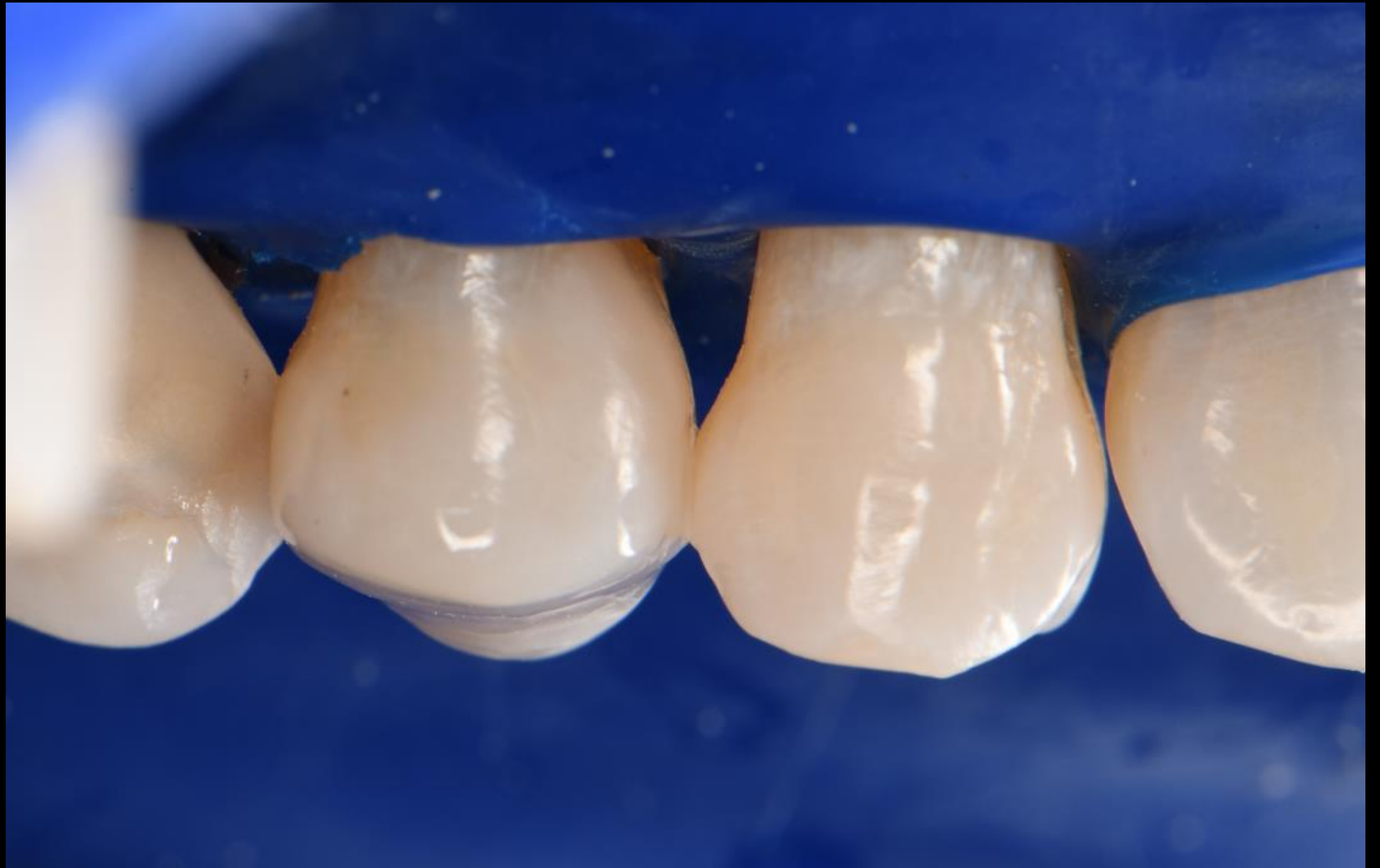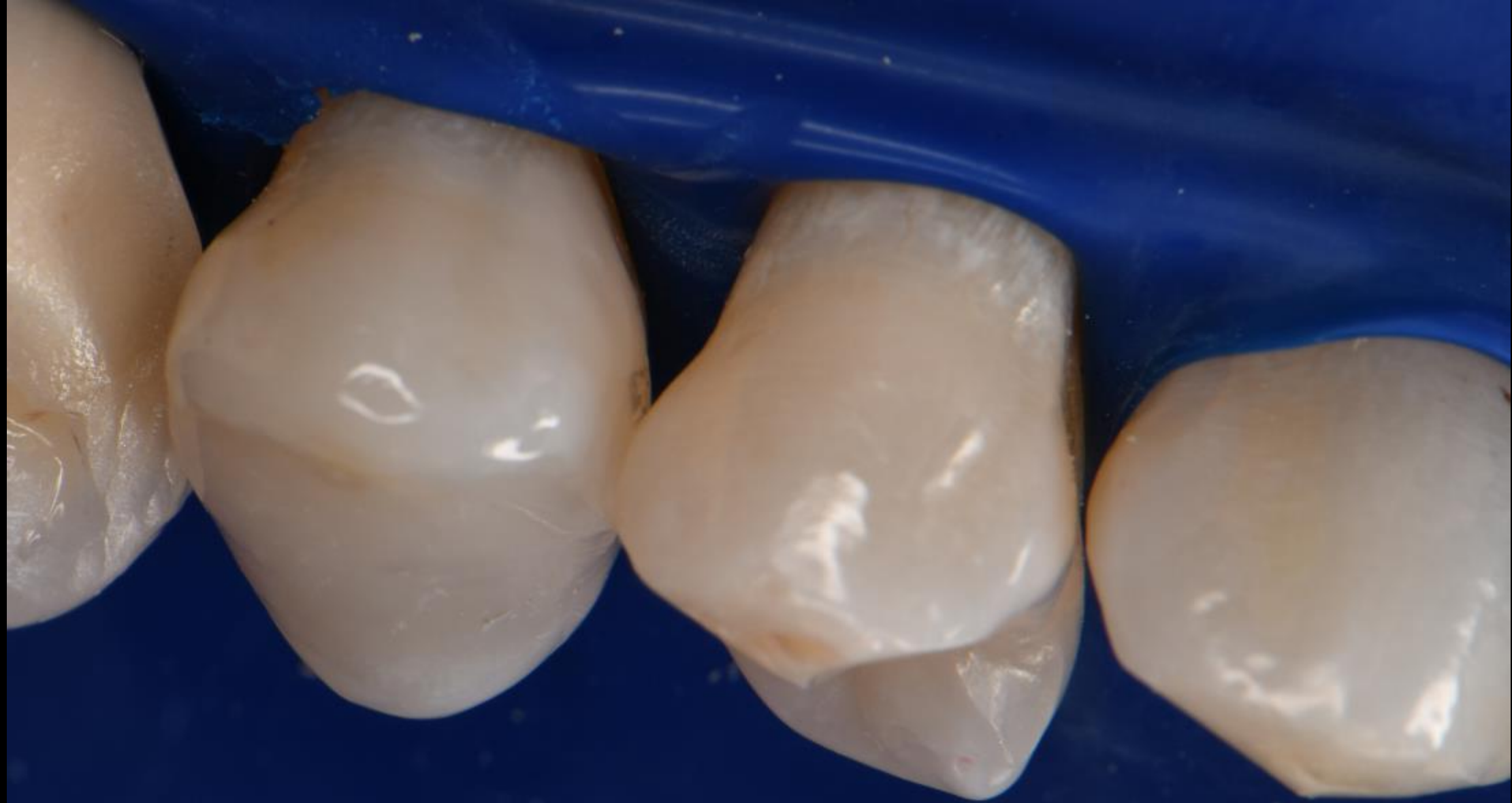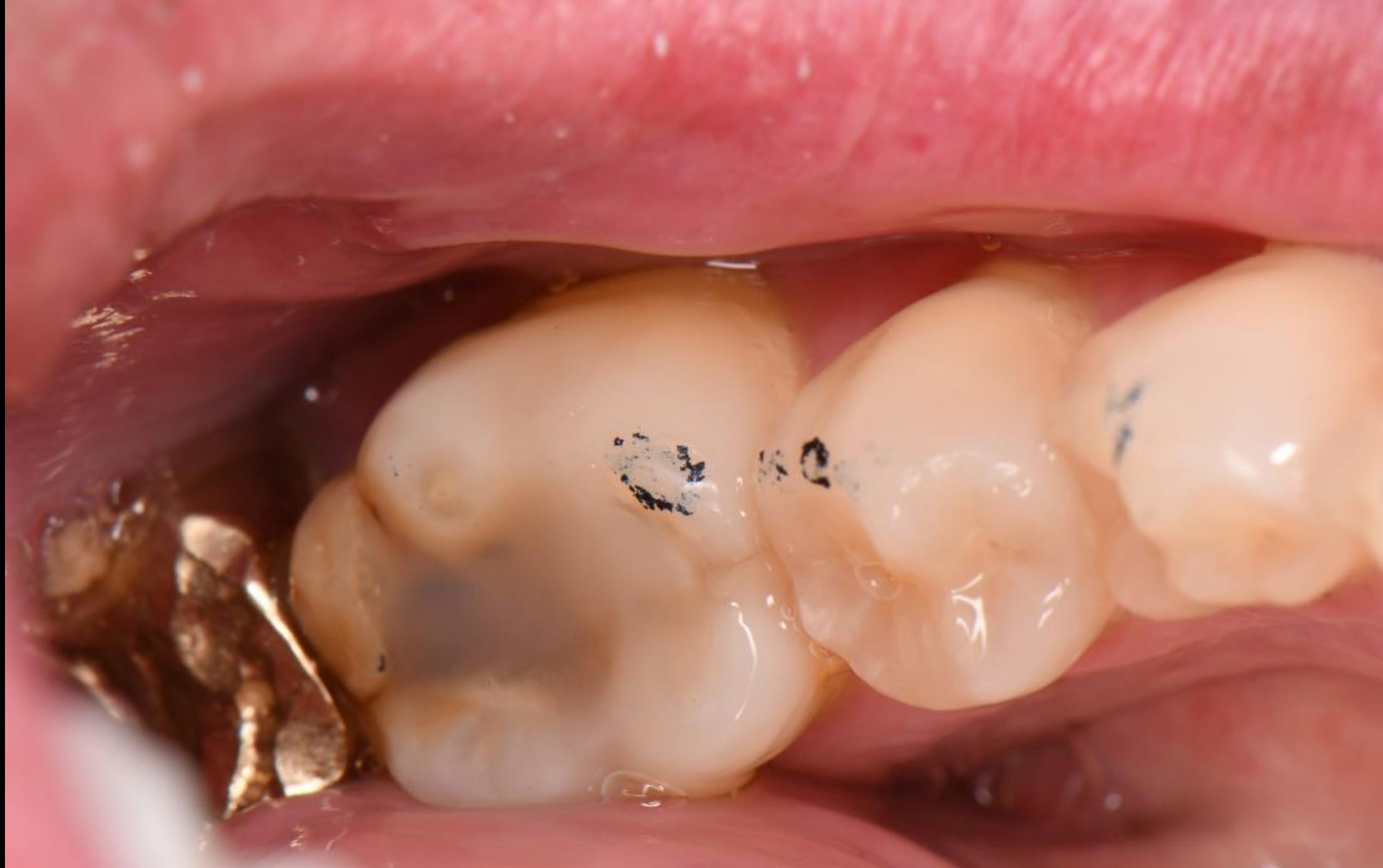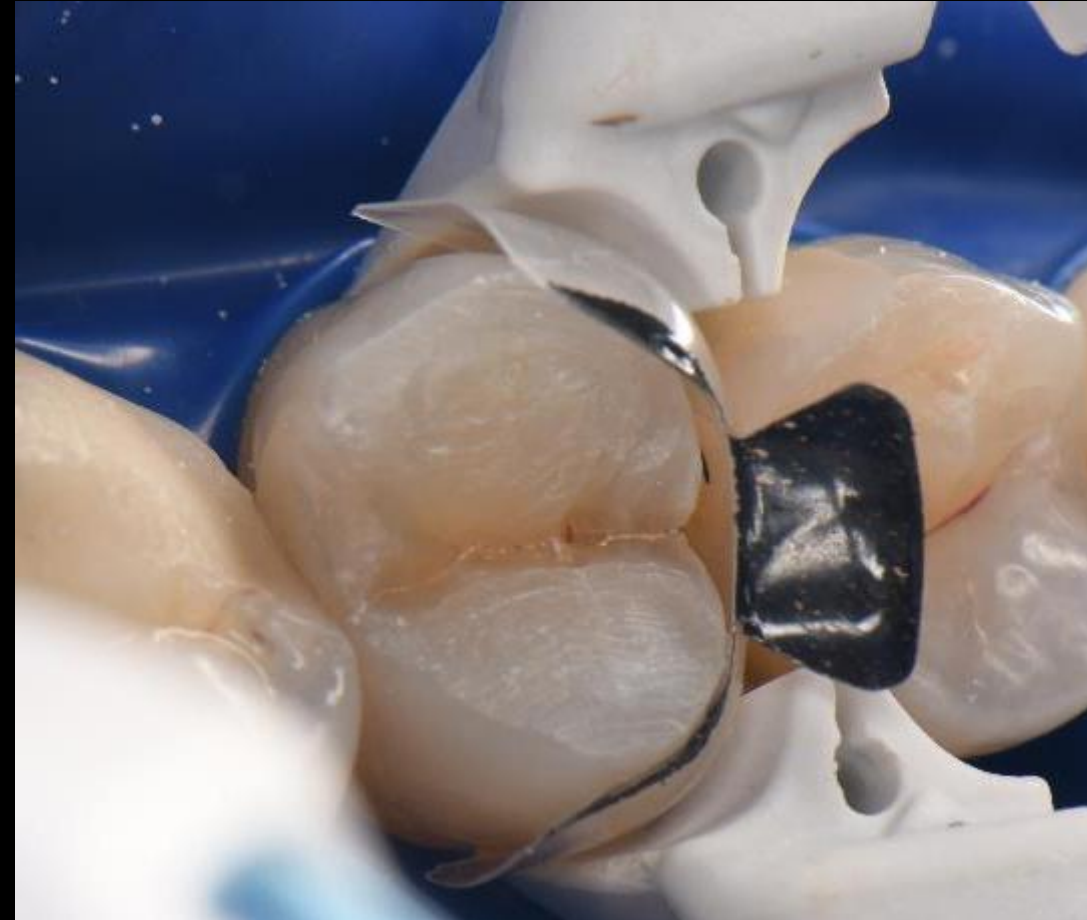






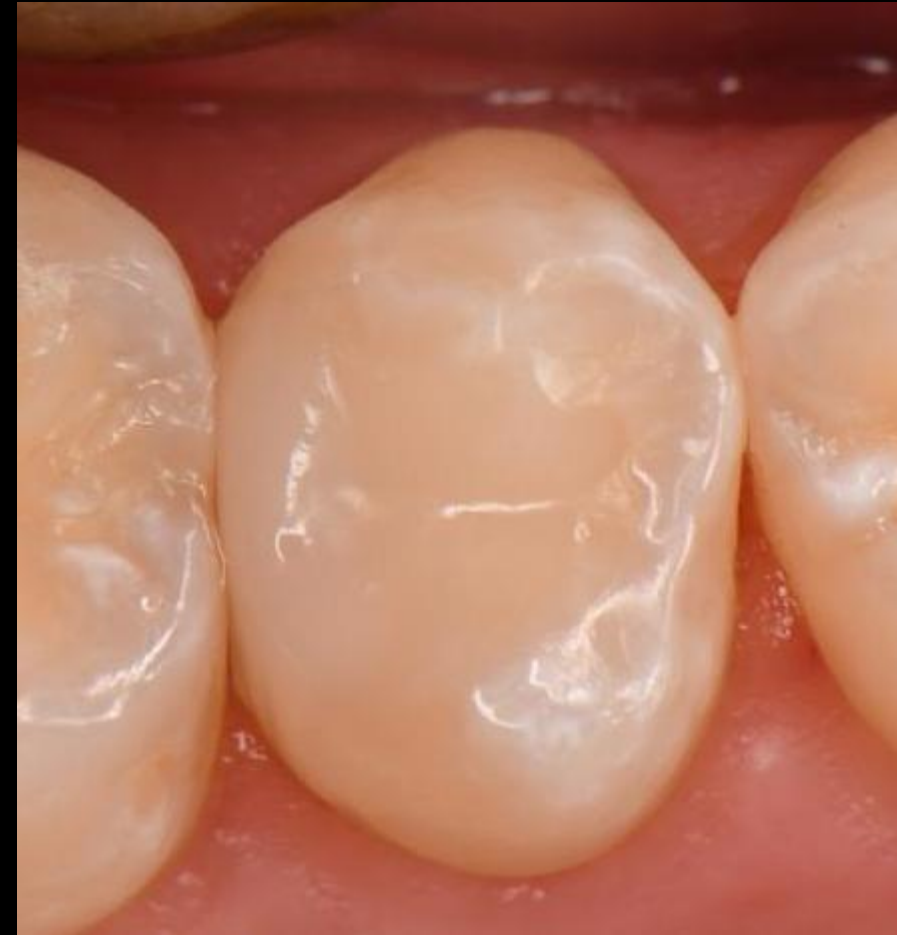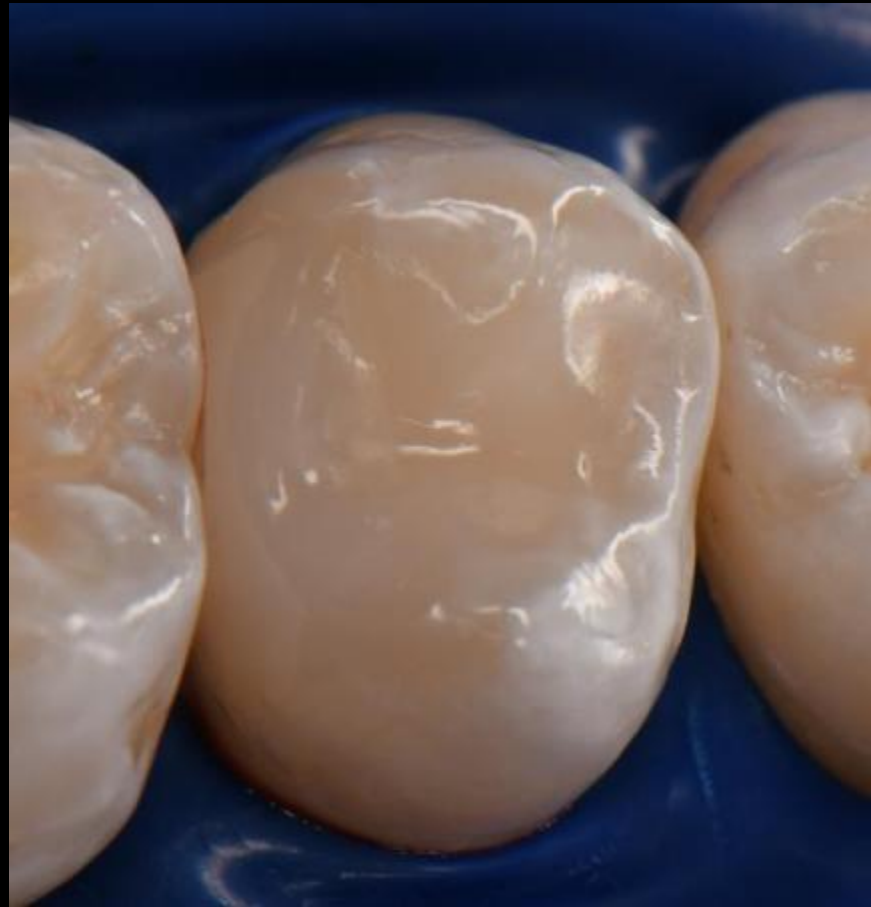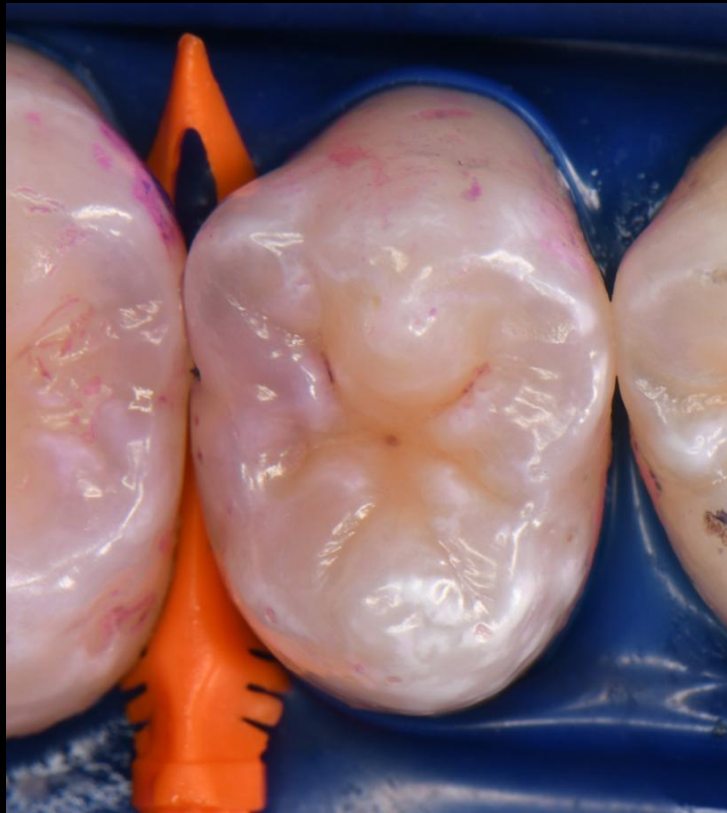Learning Objectives from the Case:

- Don't sweep the contacts*
- 3 mm thickness over the crack
- Build a bridge from buccal to lingual
- The crack becomes dormant
- "Harmonize" the opposing w/ consent
- If food impaction continues, so will pain and pocketing
- Contact technique works for other problems**
- We need a powerful separator



Pre-op, post op, and 3 year follow up

∞ BIOCLEAR



Are all
Separators
Equal?

NO!



Stretched to 20mm ONCE!!!





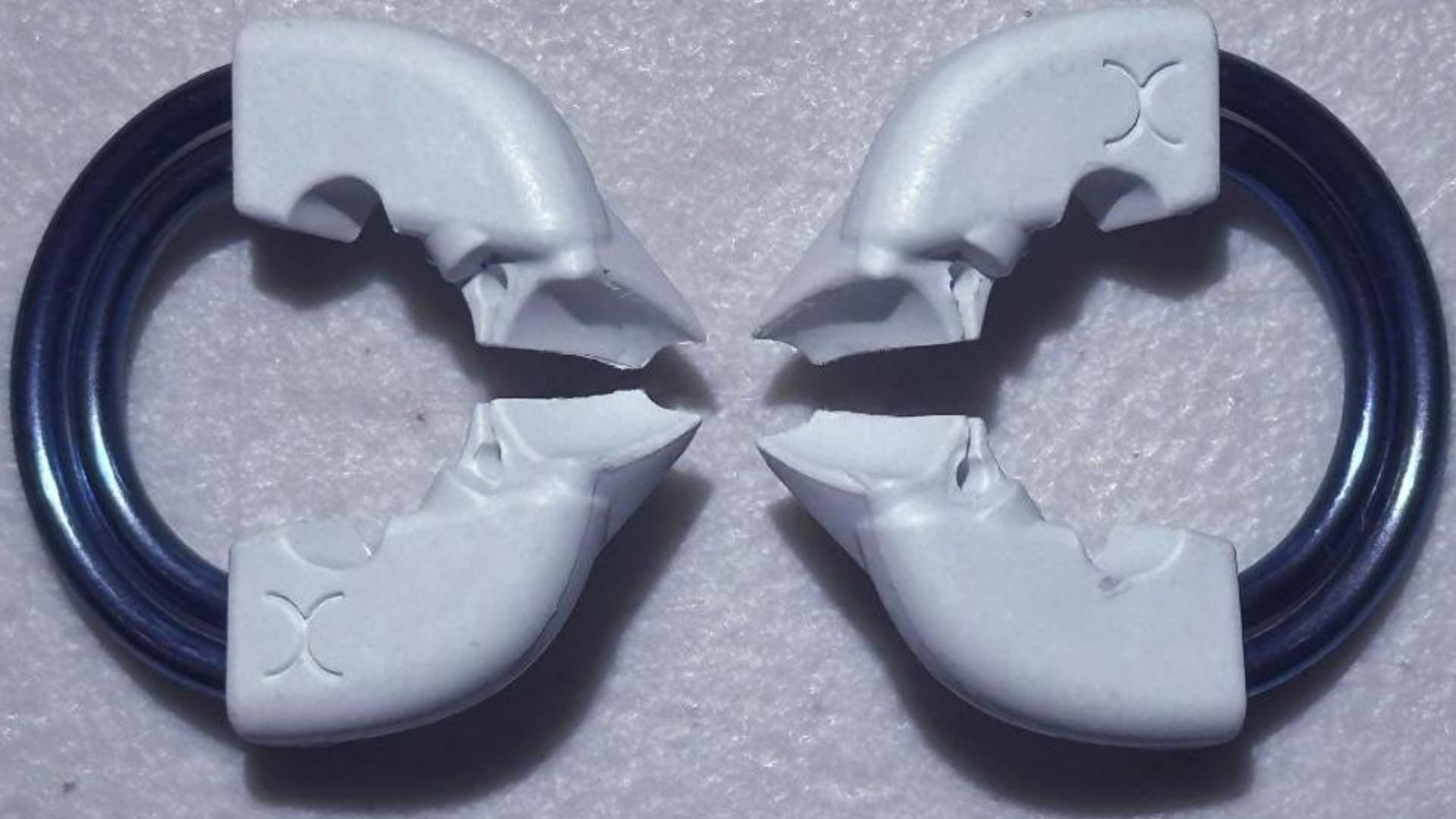And now most of
the power is
permanently lost

Once the yield of the metal/shape is reached, the
metal undergoes plastic deformation

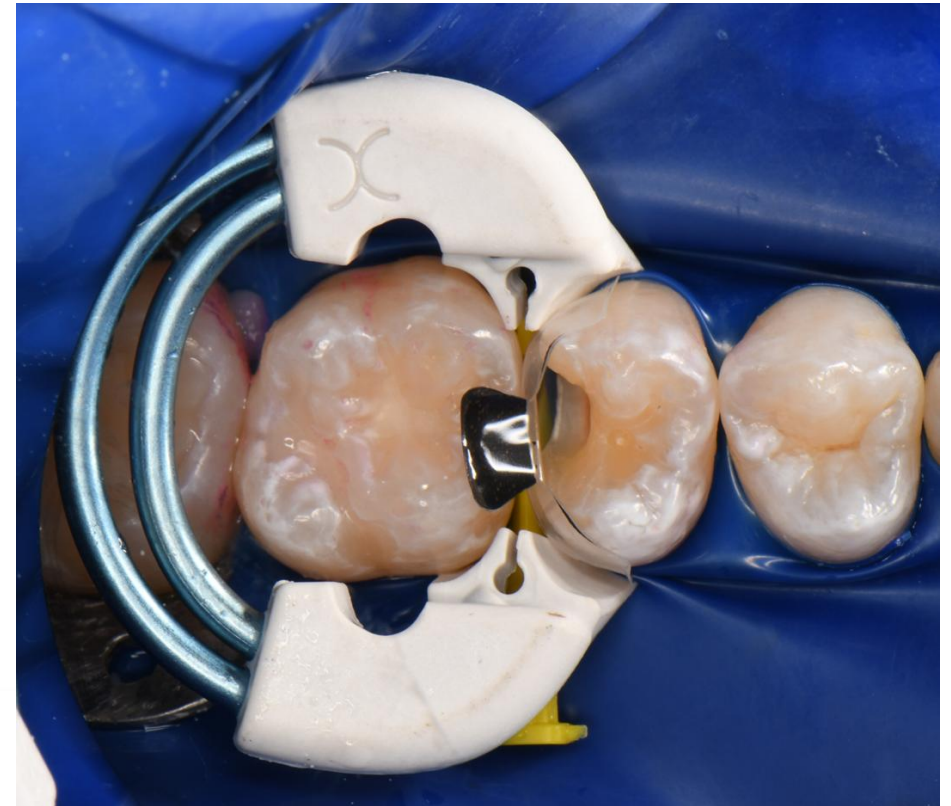
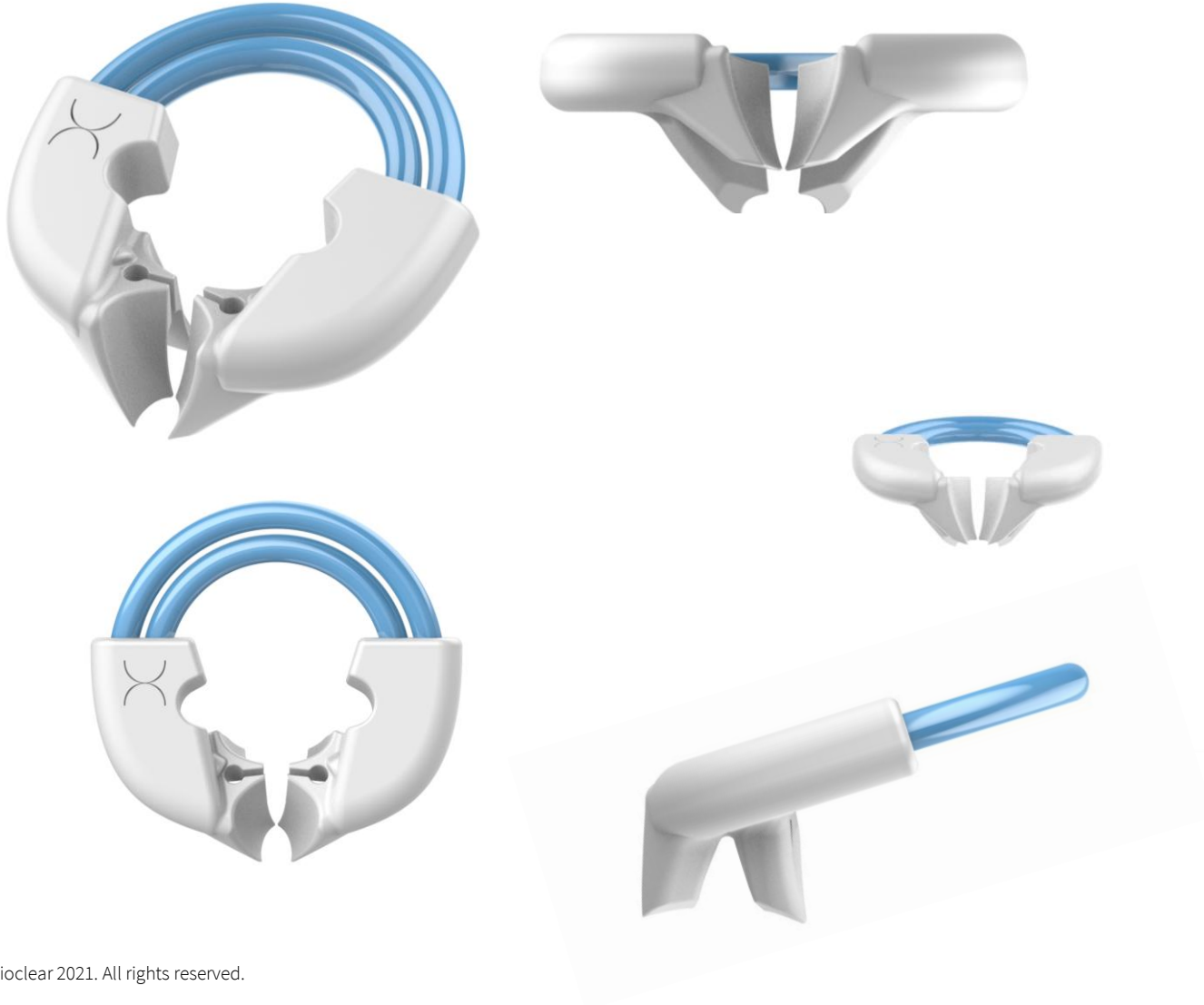
Stretched to 20mm Twenty Times

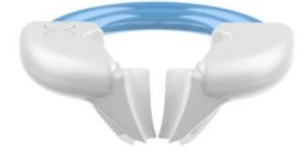


Stretched to 20mm Twenty Times



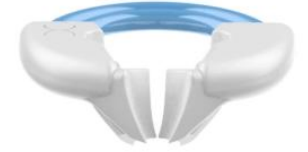
TwinRing Universal






How do we win the *Snug Contact Game?*

- Power
- Strategy
- Technique



How do we win the *Snug Contact Game?*

- Power
- Strategy
- Technique



Nate Lawson DMD PhD

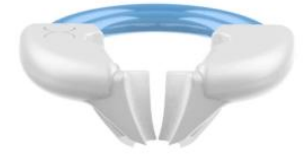
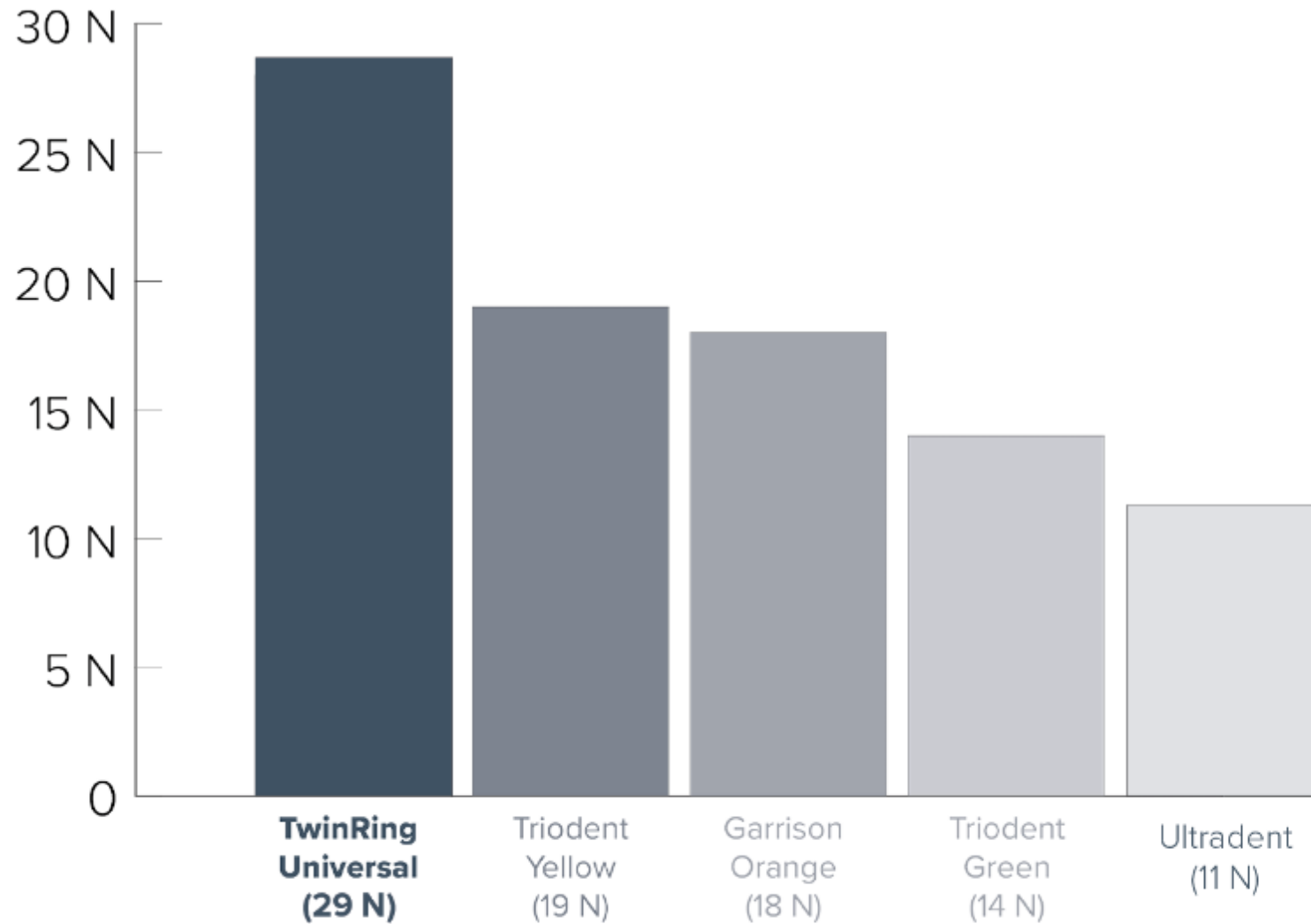
Director of the Division of Biomaterials and Pranit Bora. BDS, MDS.

Resident, Division of Biomaterials UAB School of Dentistry



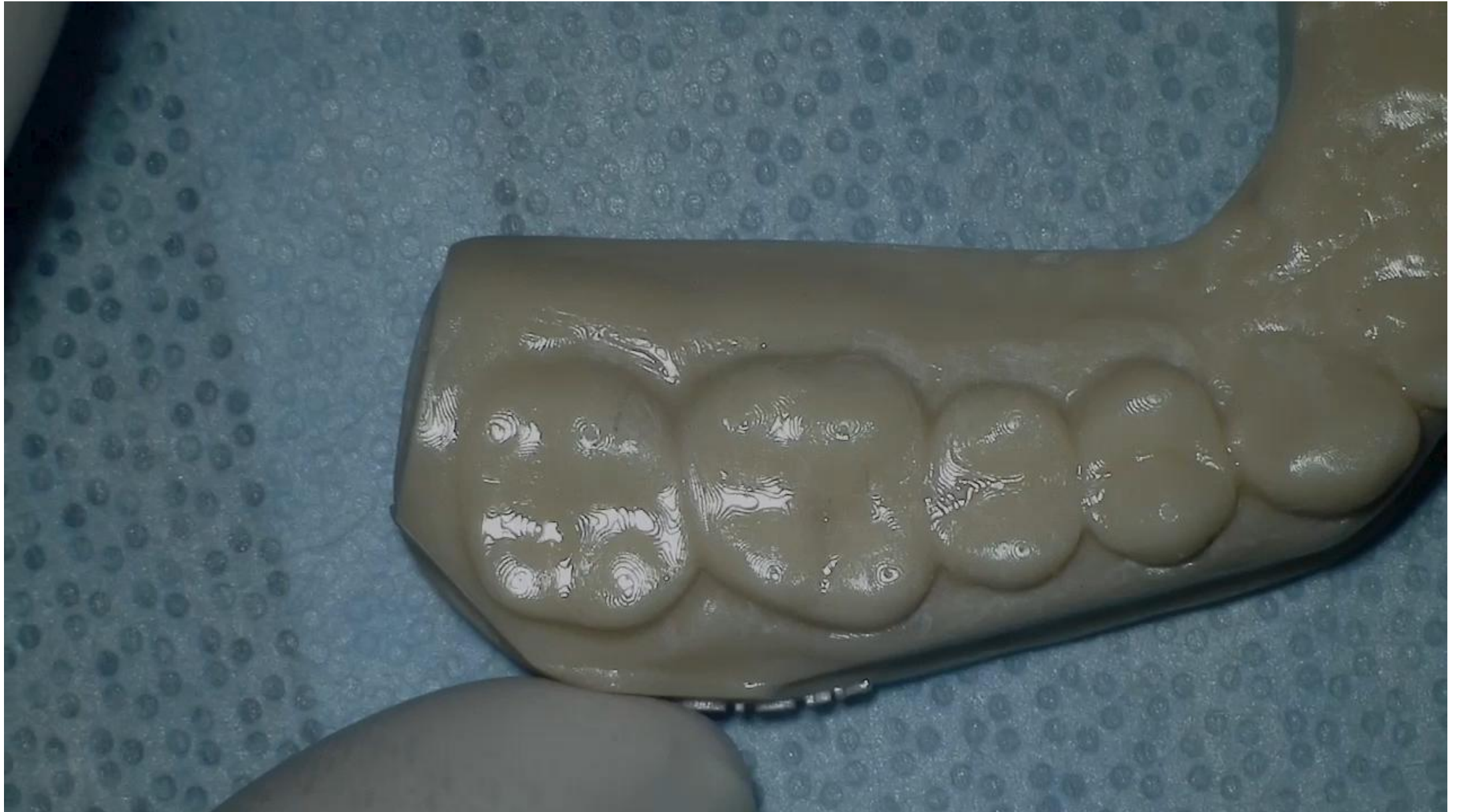TwinRing Universal
28 N

TwinRing Universal Instron Comparison



Note: Rings tested are not new and some rings stretch out quickly and lose up to half of their power after multiple uses. 1N = 1kg (m/s/s)

The slip-off test



 BIOCLEAR

Bioclear Matrices - Posterior





EVOLVE --- MATRIX

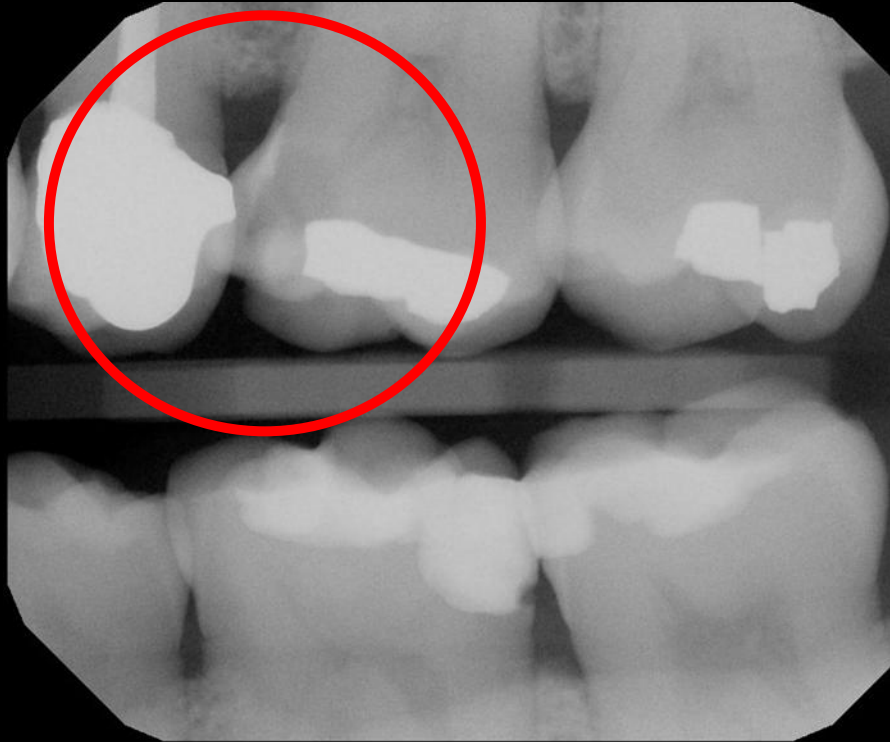
Premolar



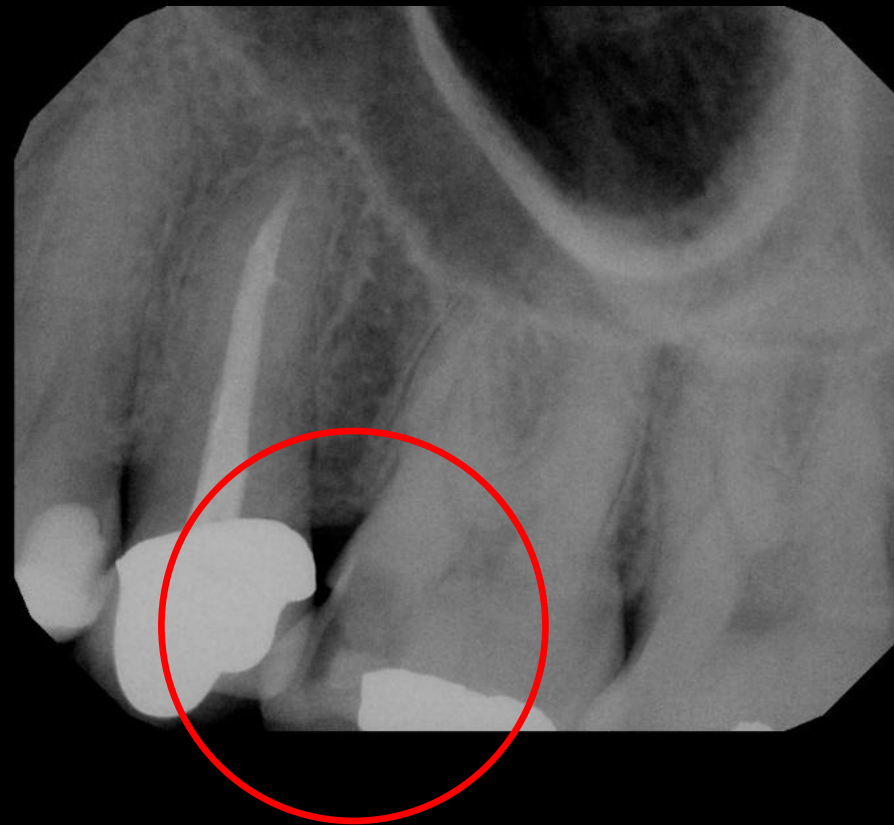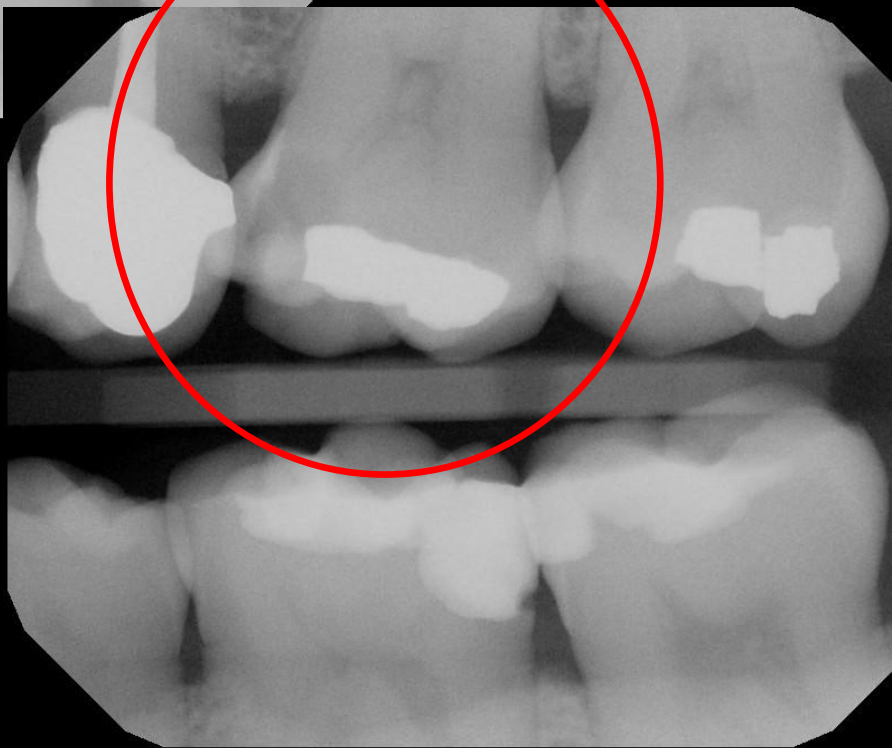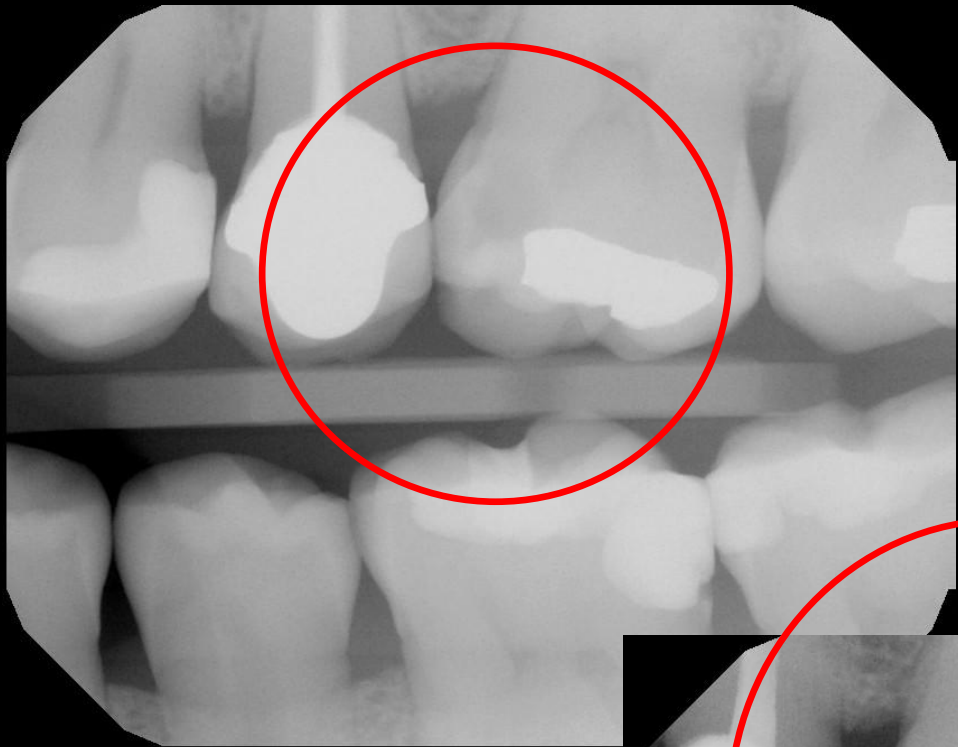Molar

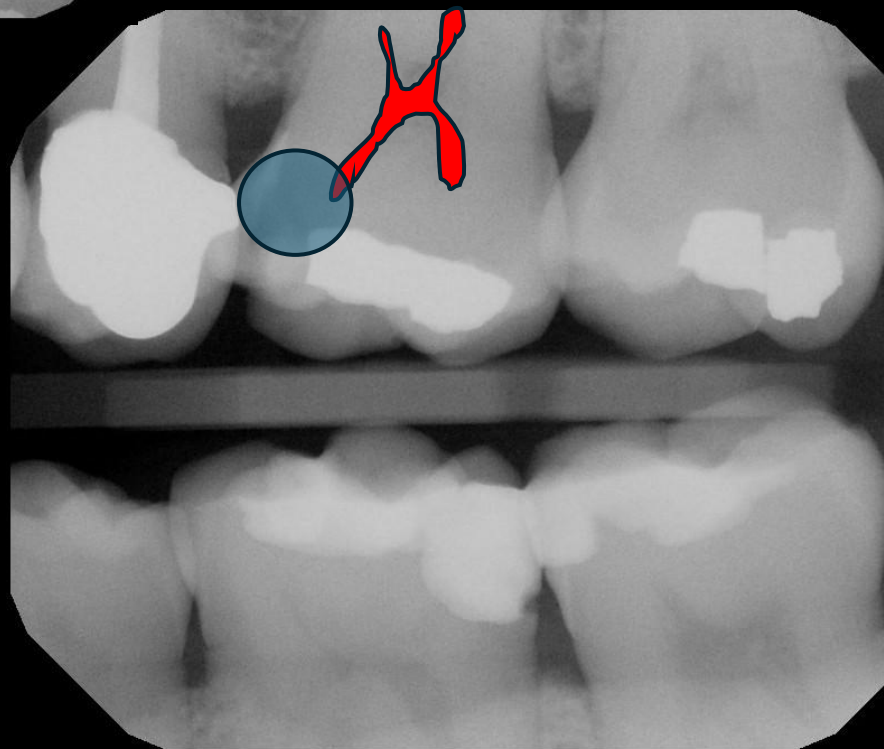
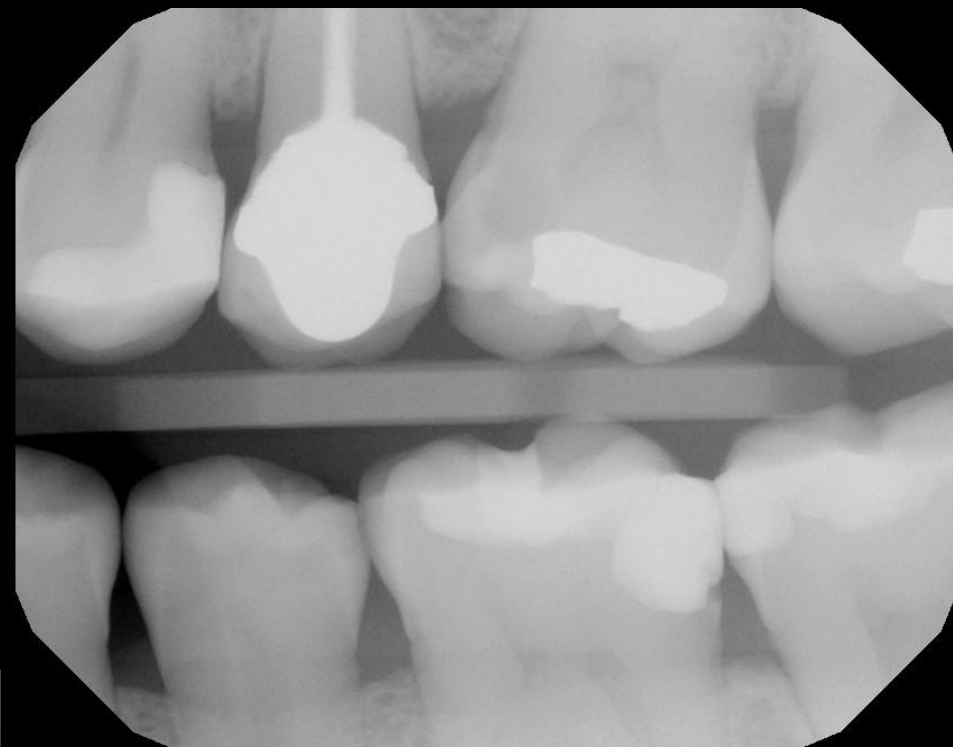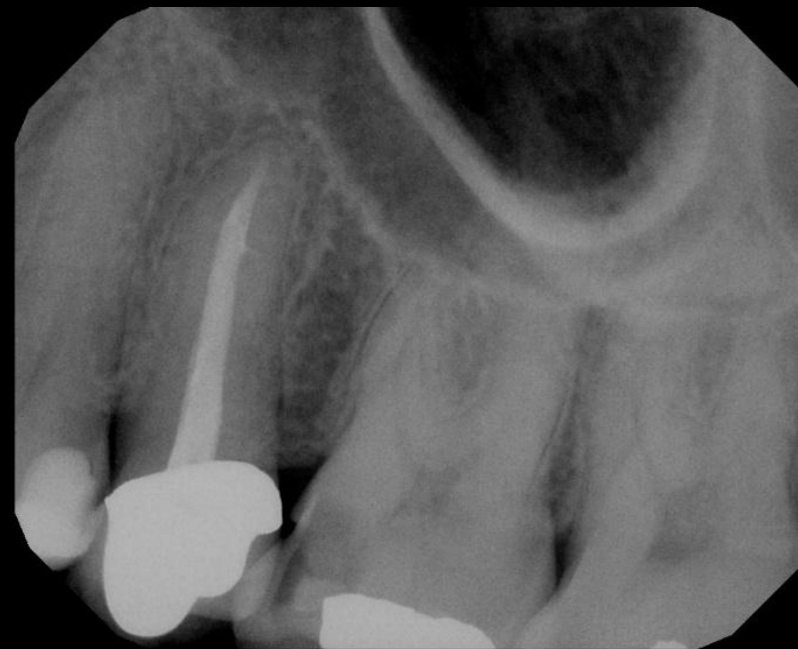


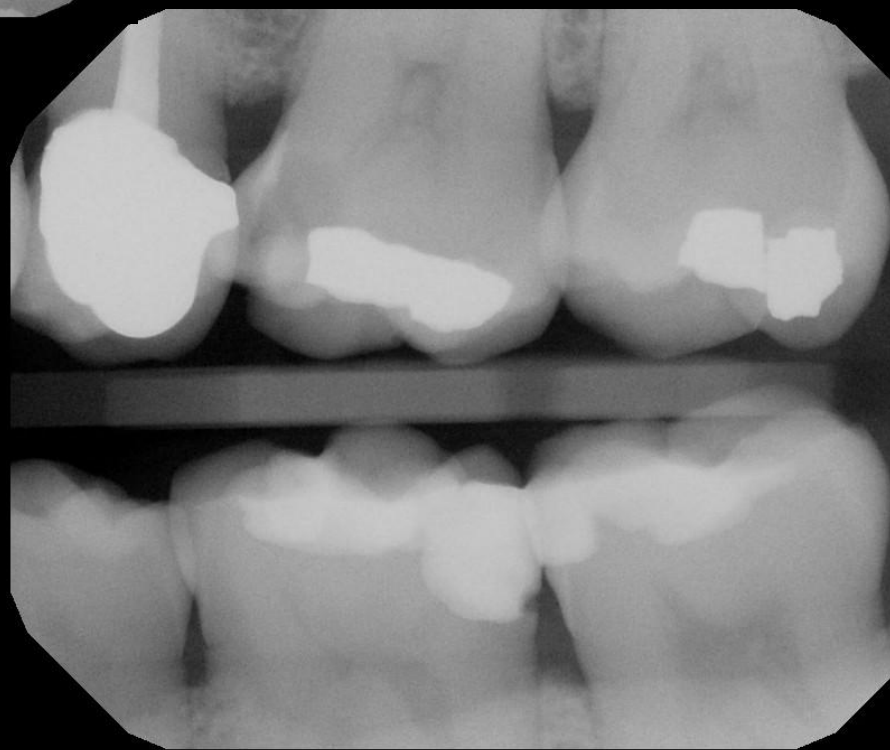
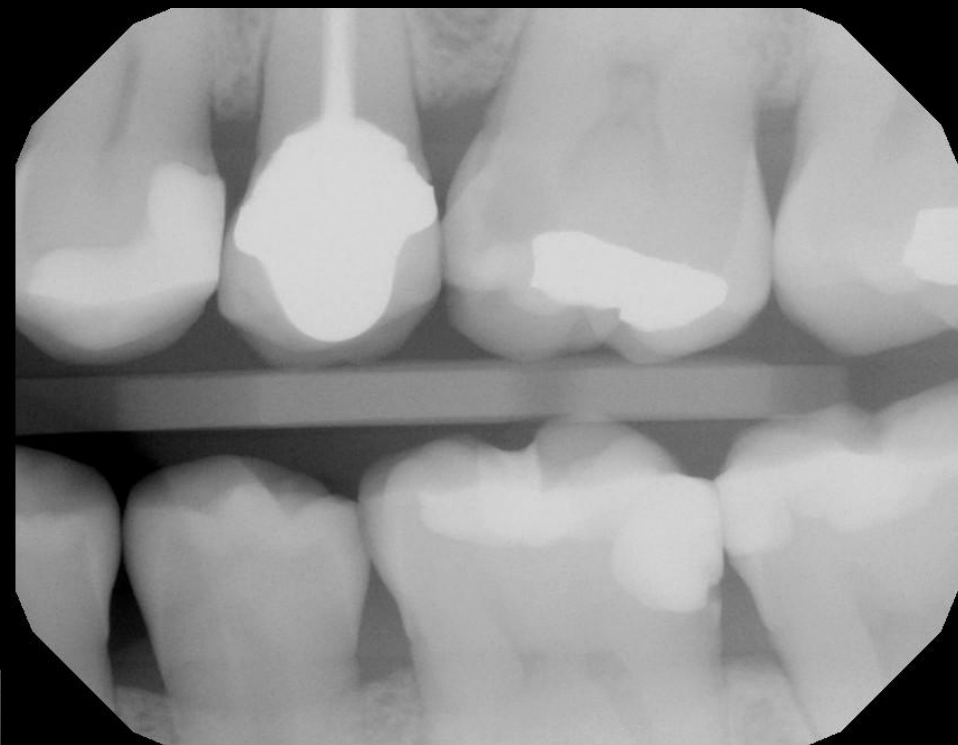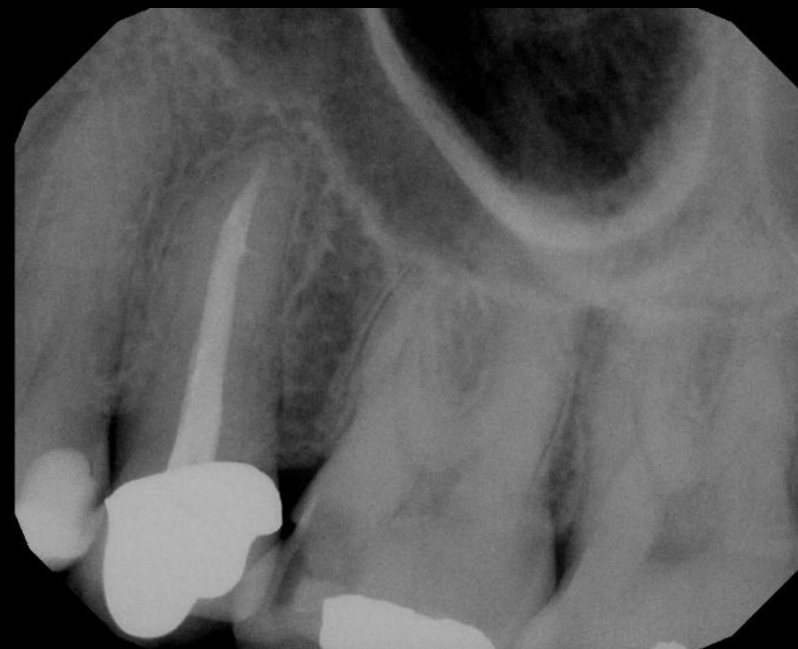
EVOLVE
MATRIX



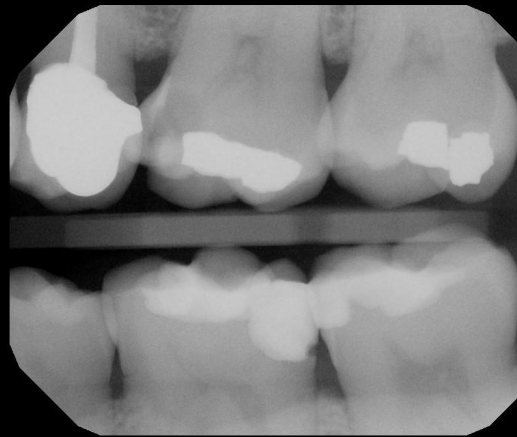
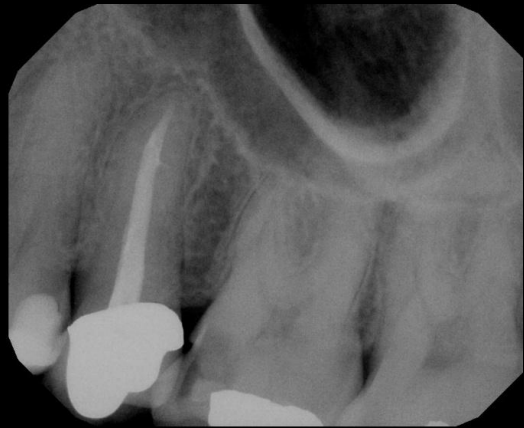
Dr. Rafael Bustamante
Full Faculty at the
Bioclear Learning center



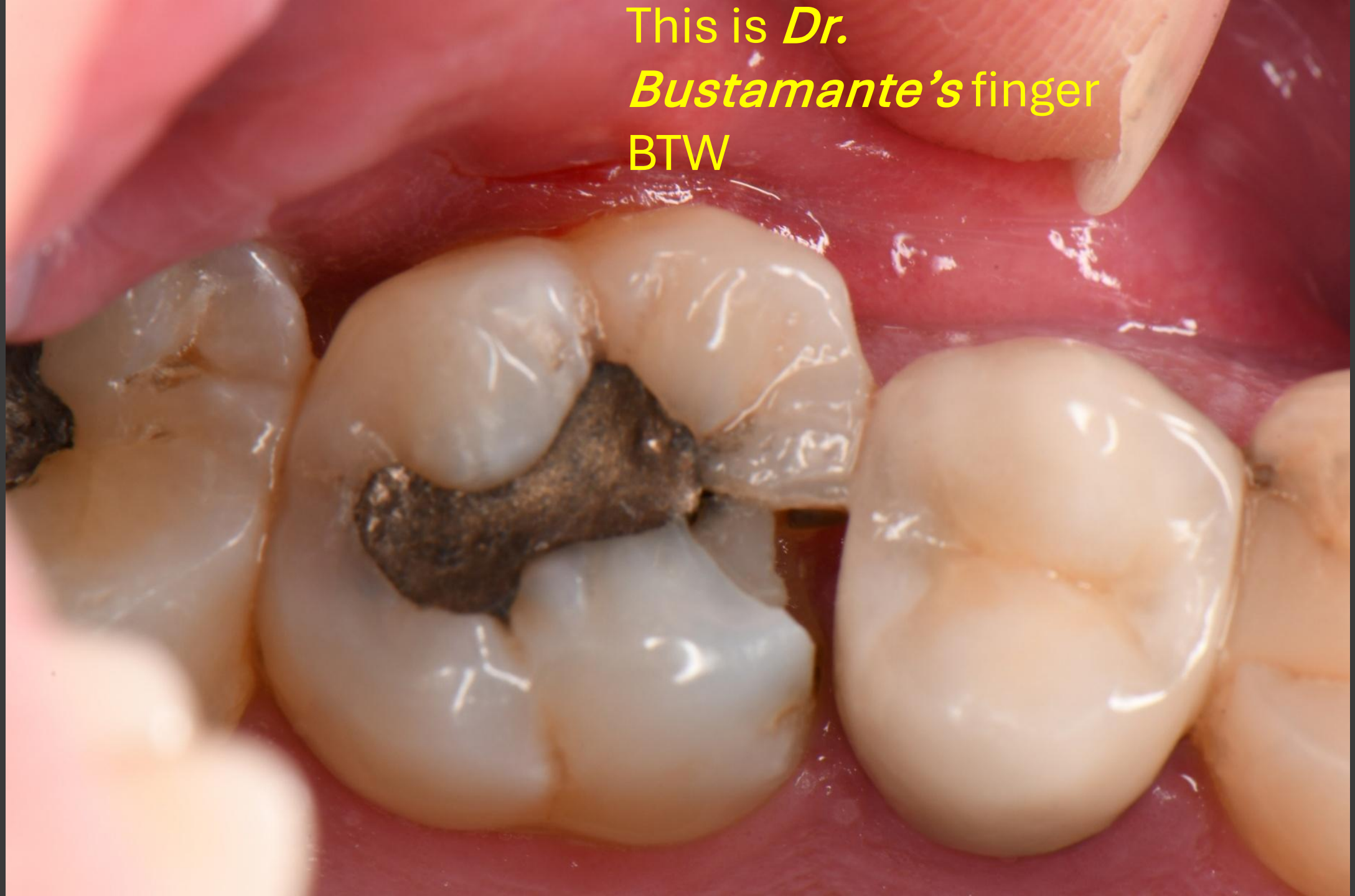


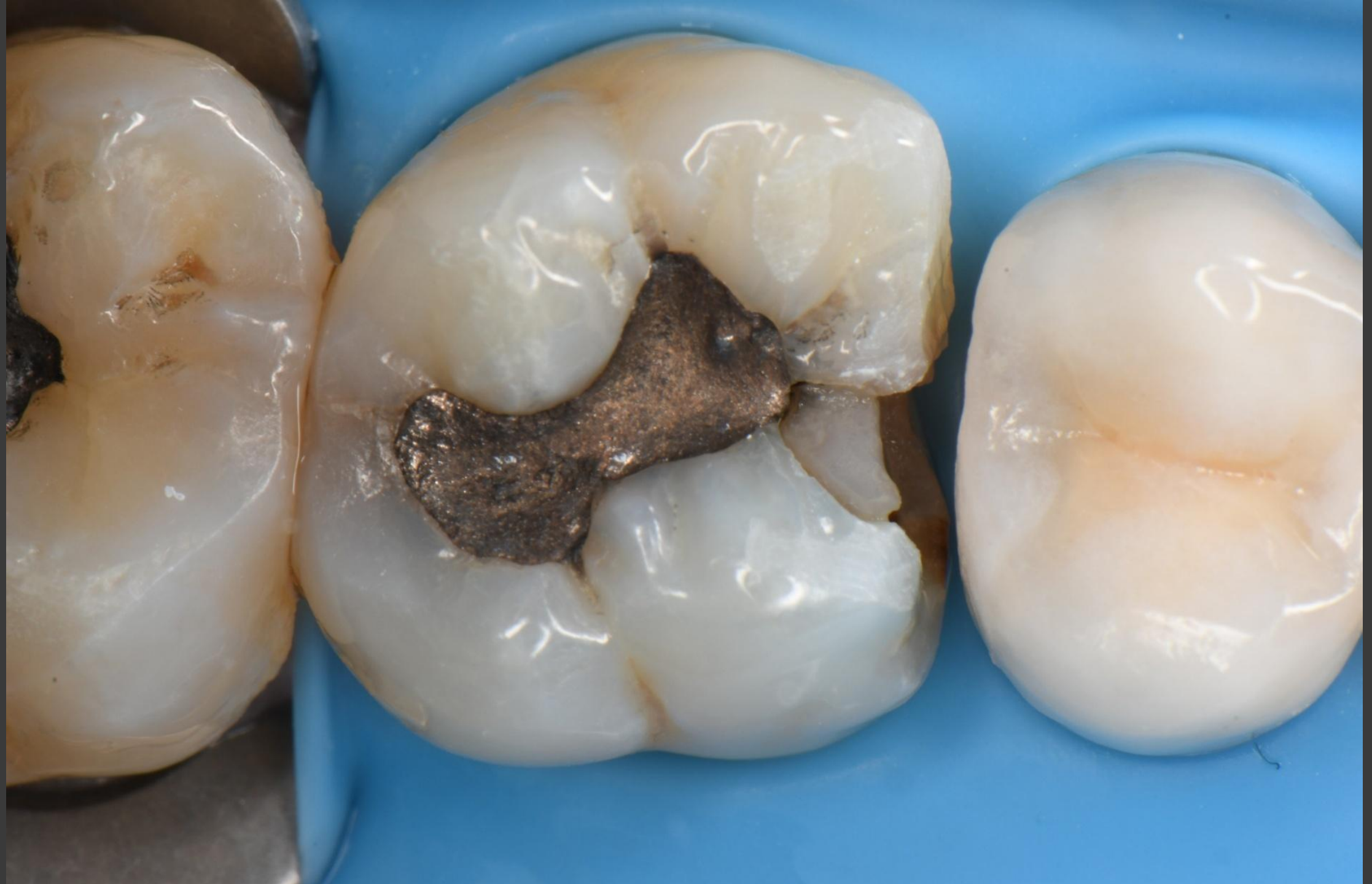
- Selective Caries Removal
- Calla Lilly Compression Based Cavity Preparation for a Cracked Tooth
- Deep Margin Acquisition
- Dealing with a Furcation

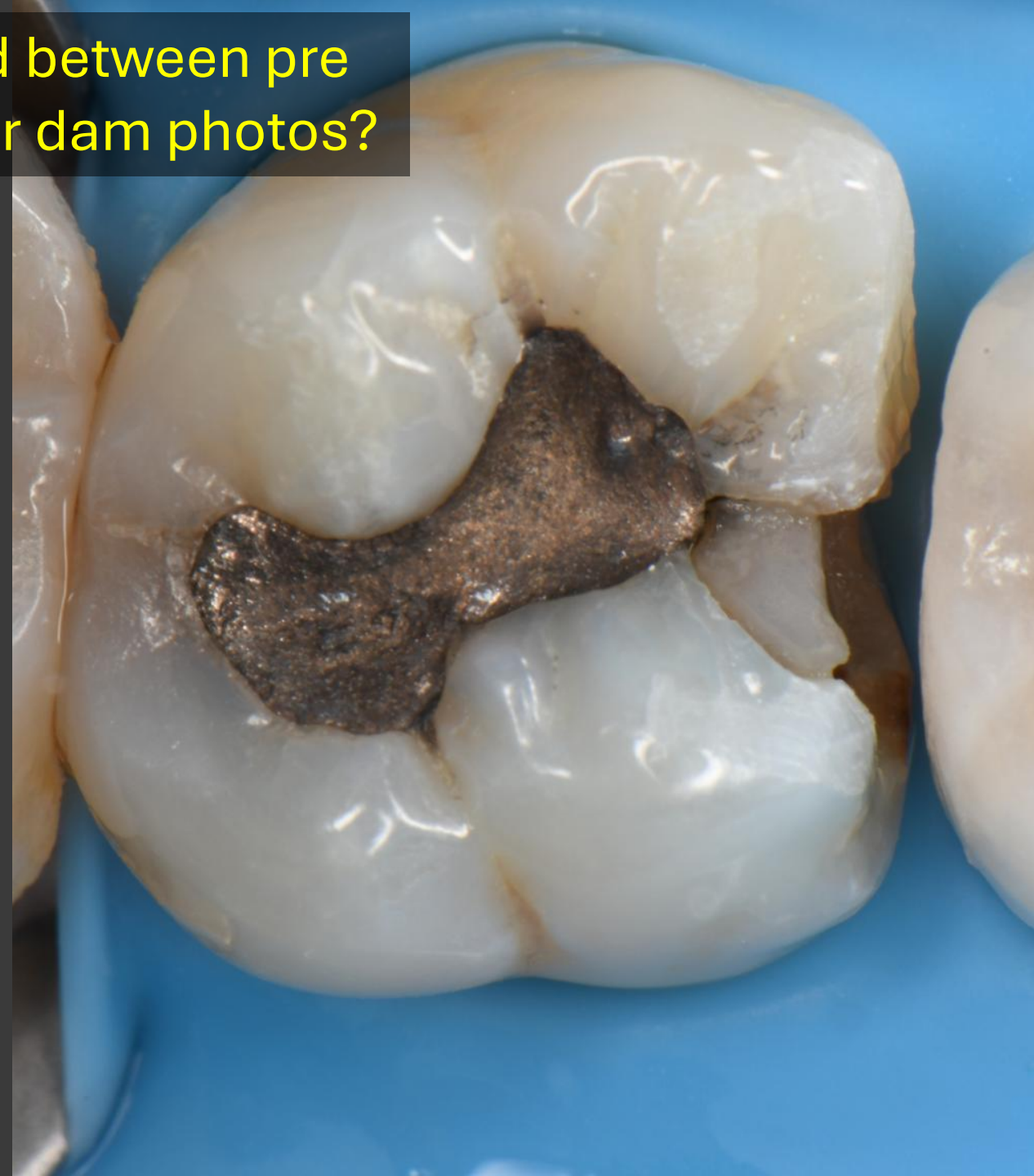
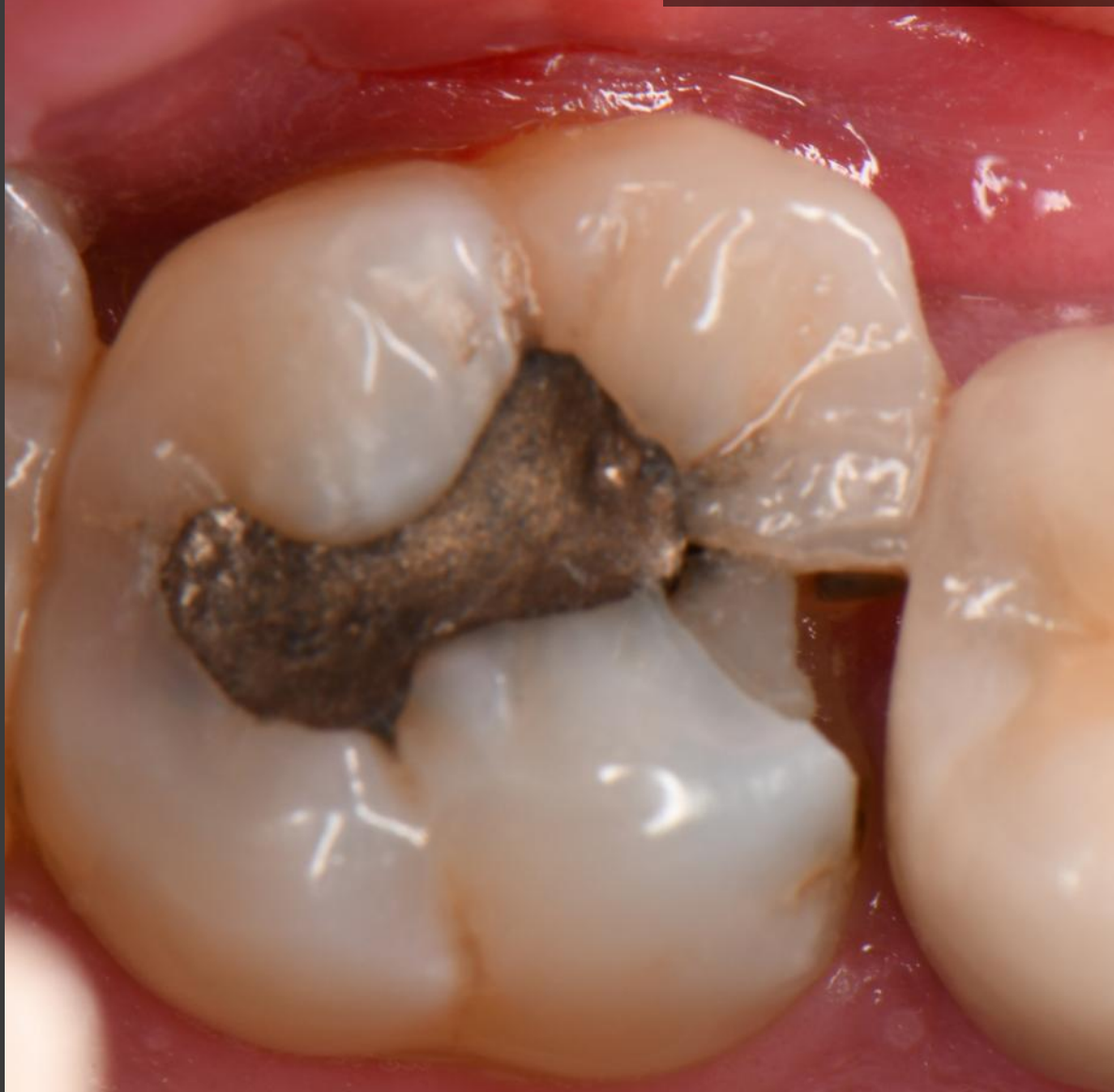
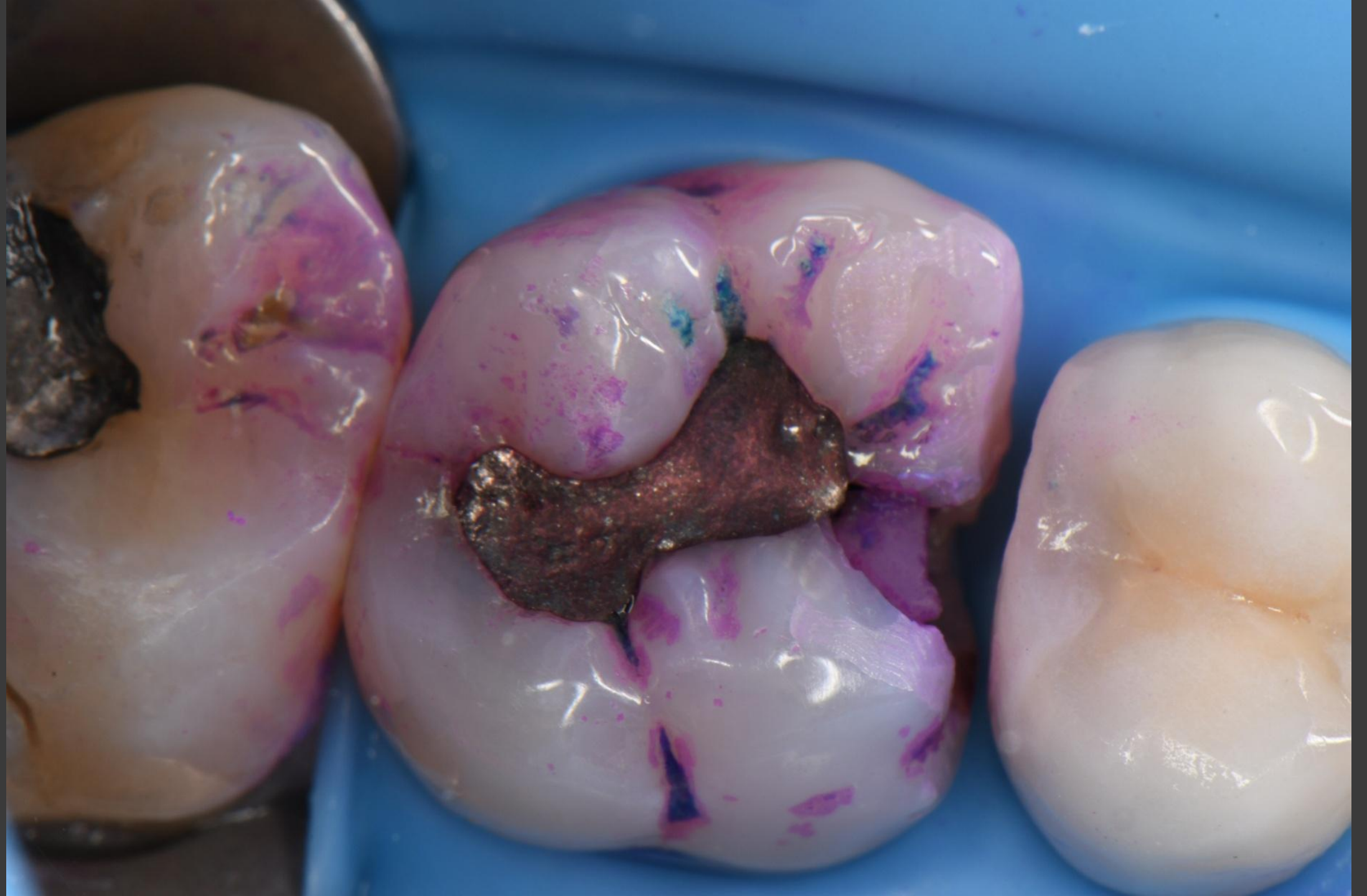
This is *Dr. Bustamante's* finger
BTW

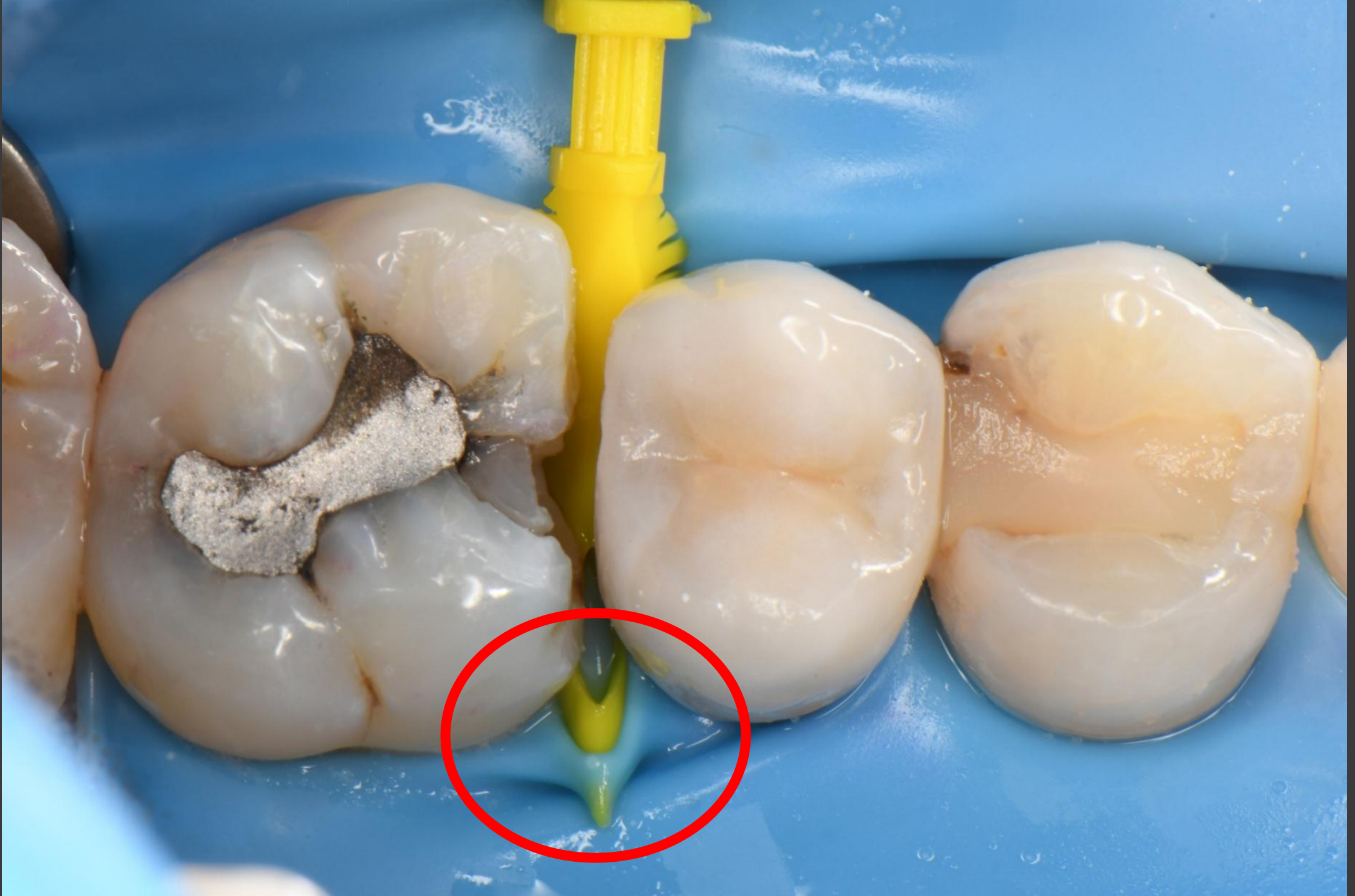


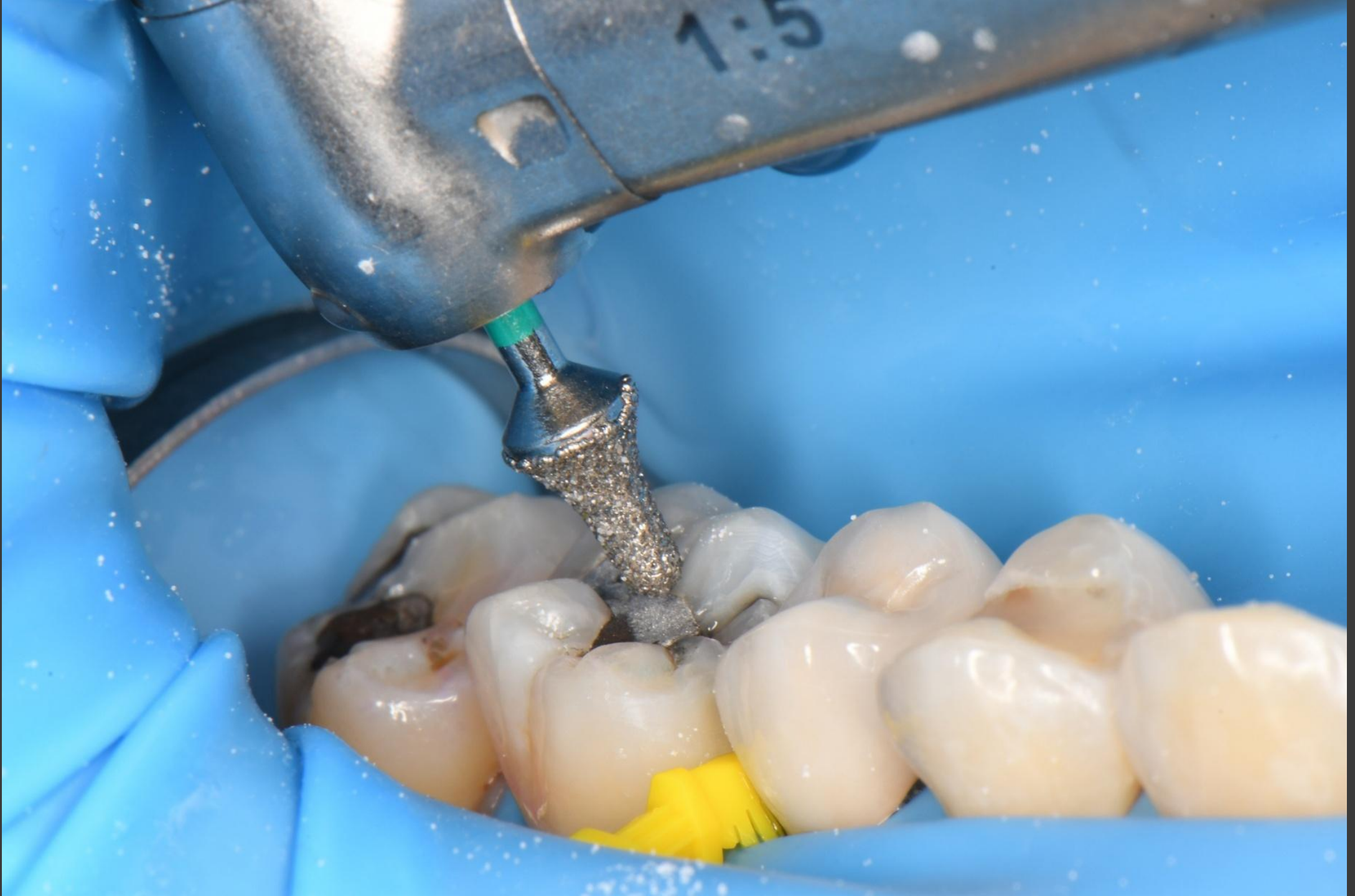
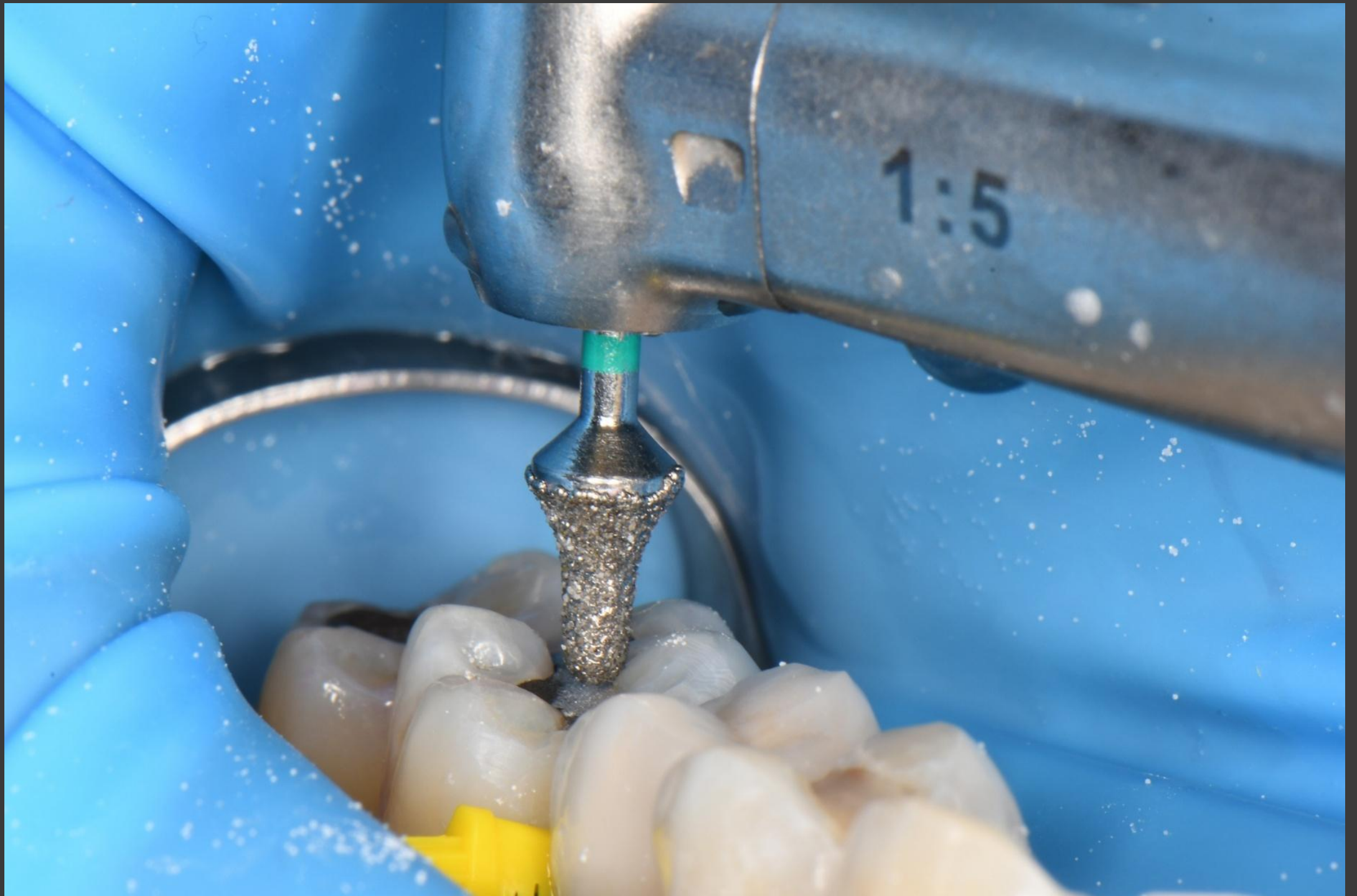What changed between pre and post rubber dam photos?

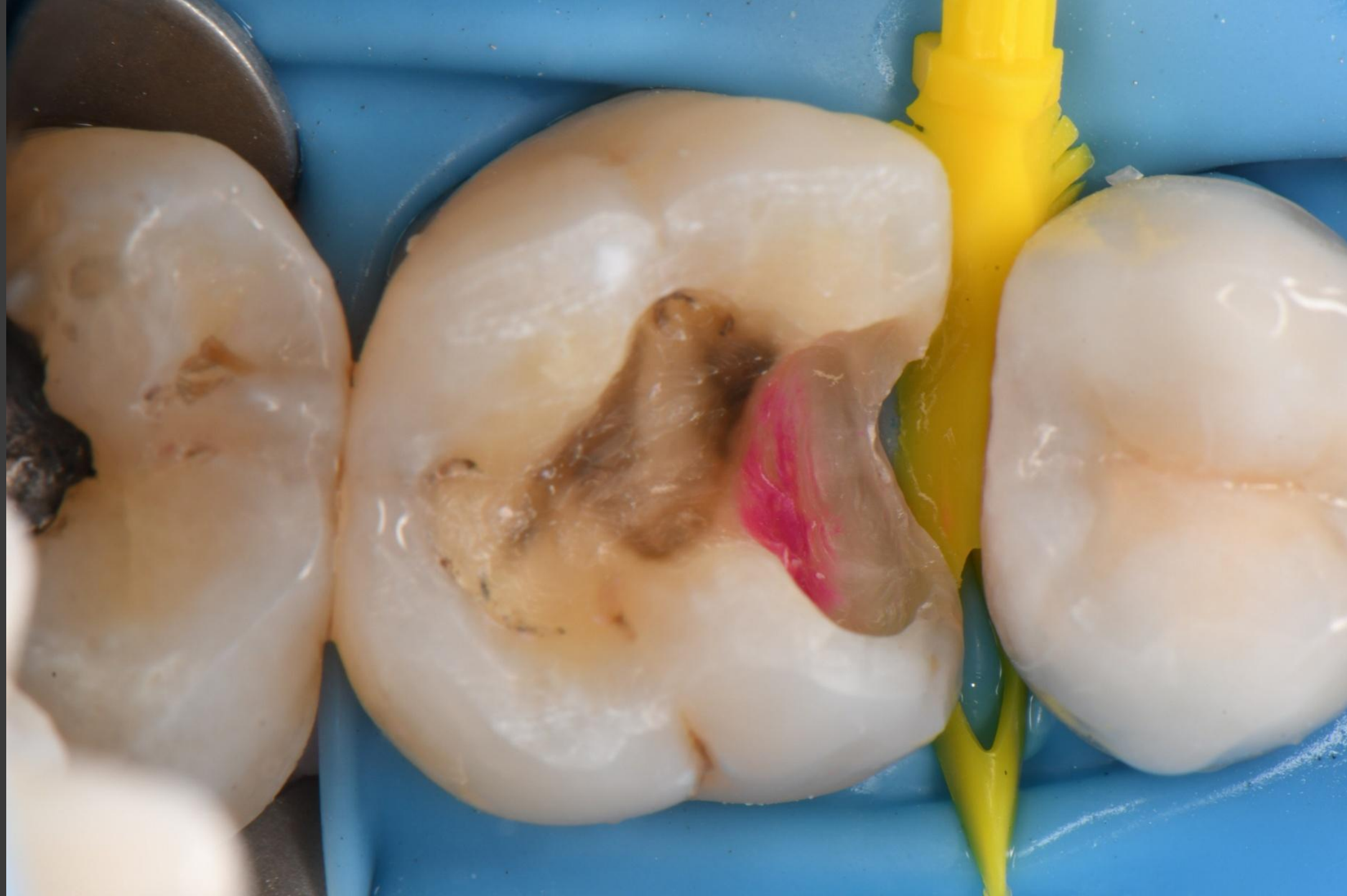


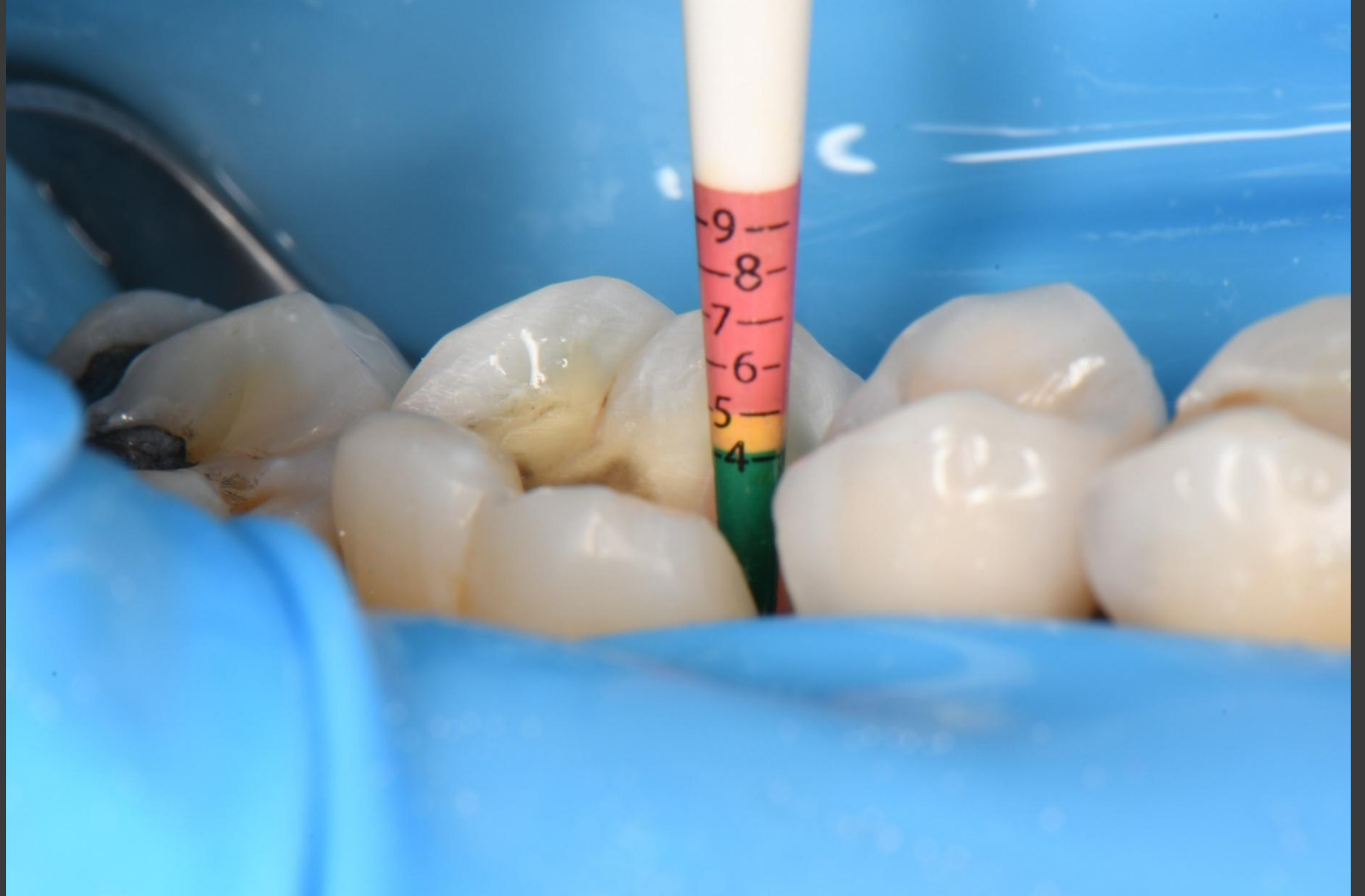


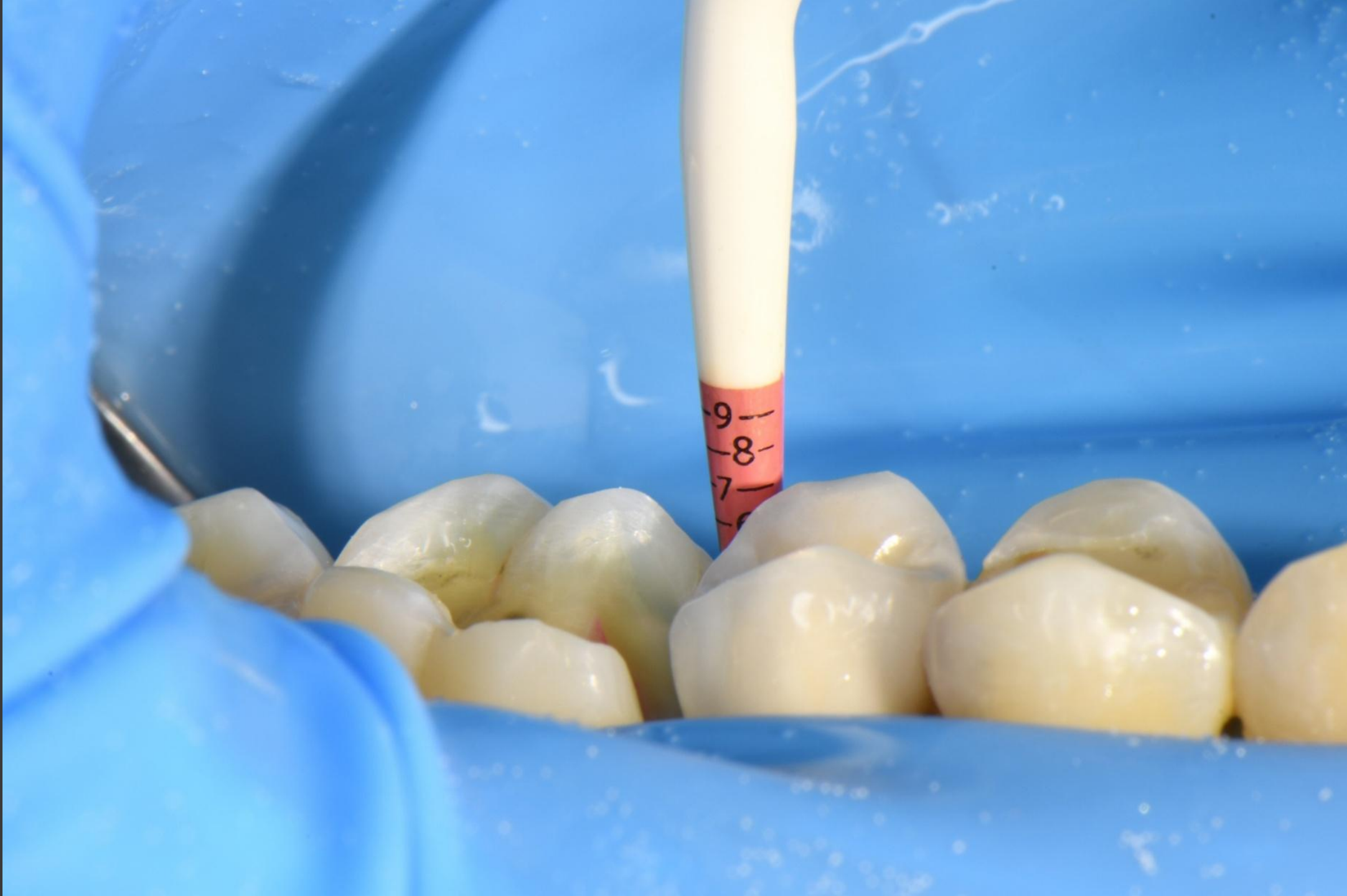


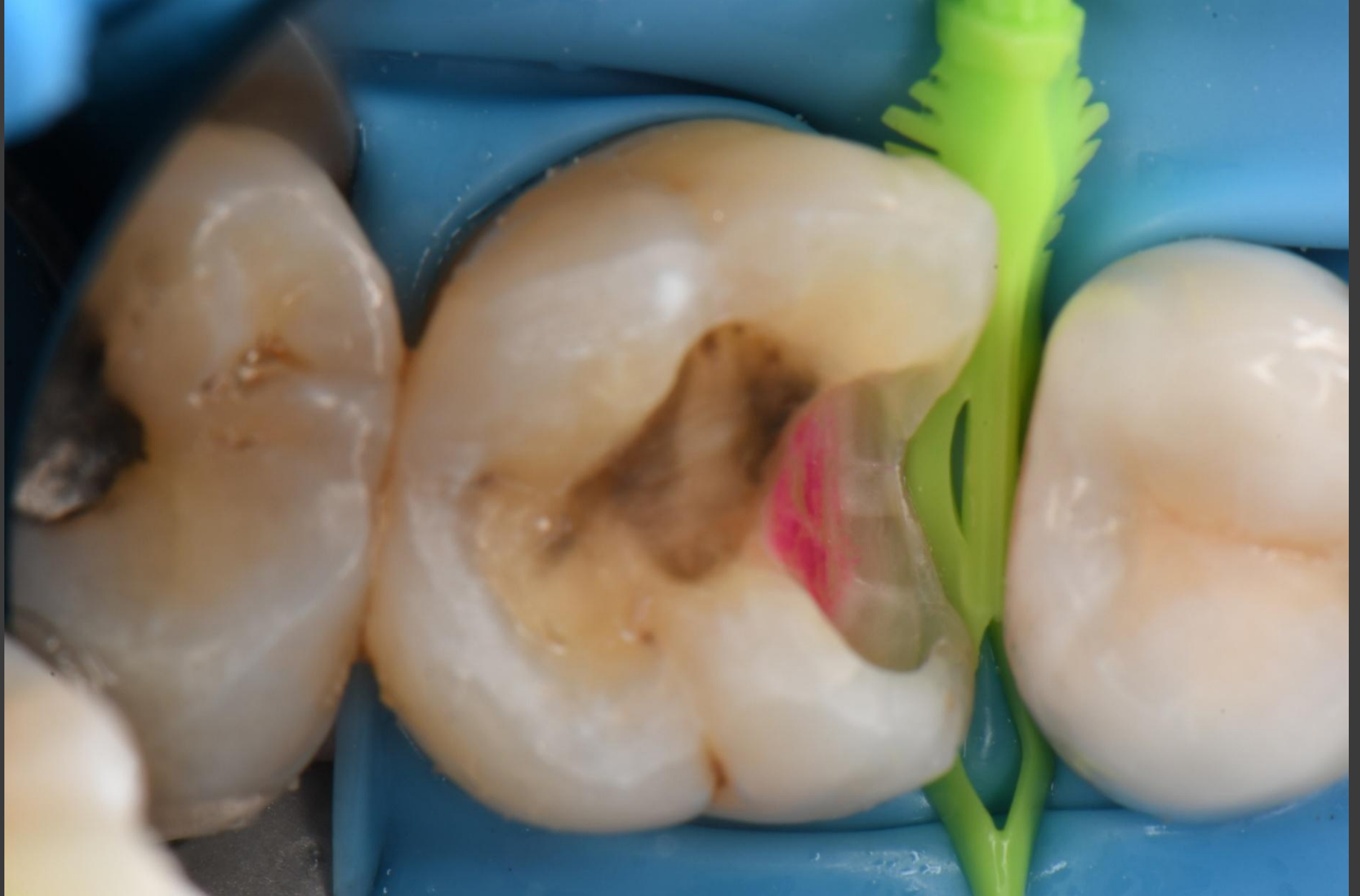








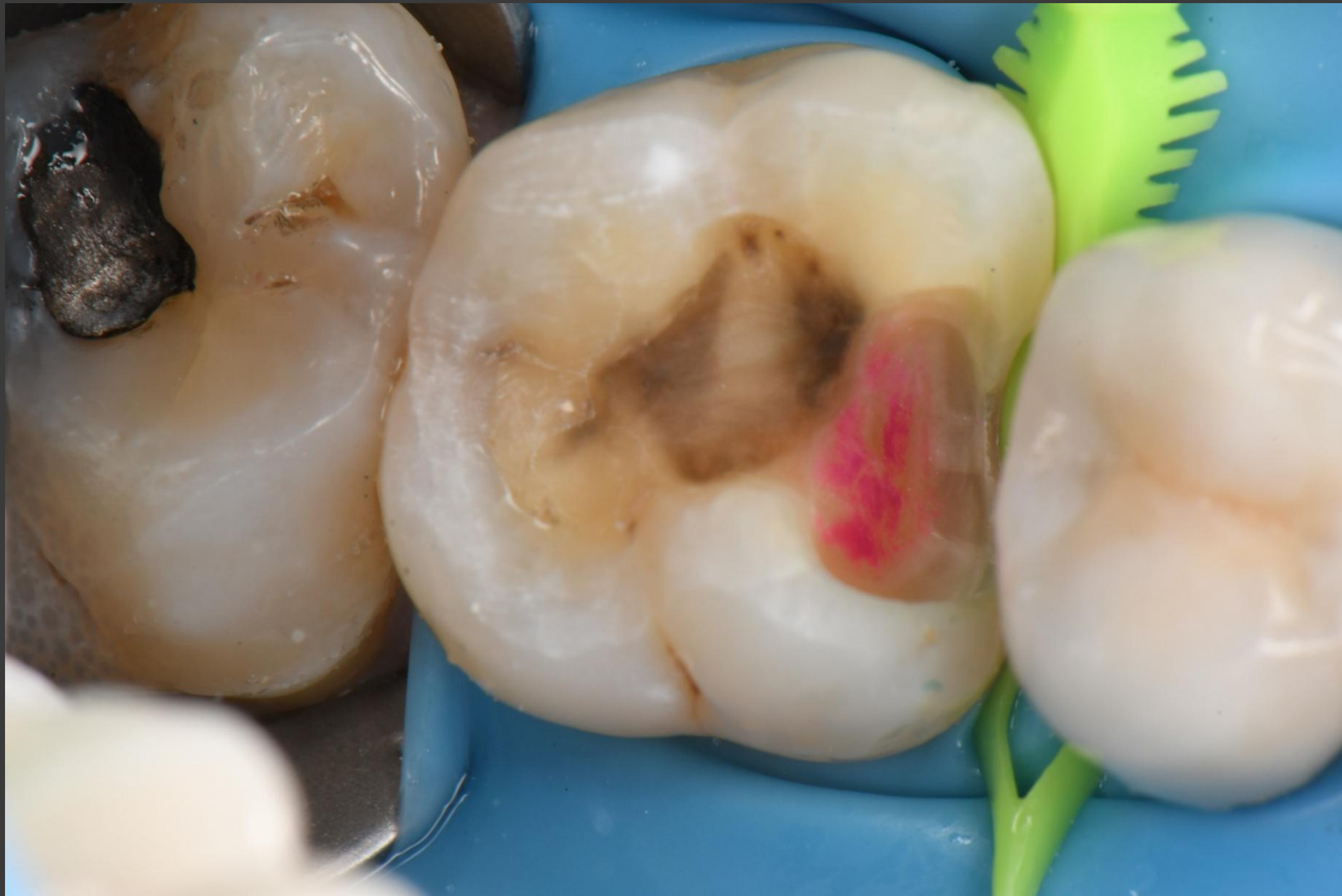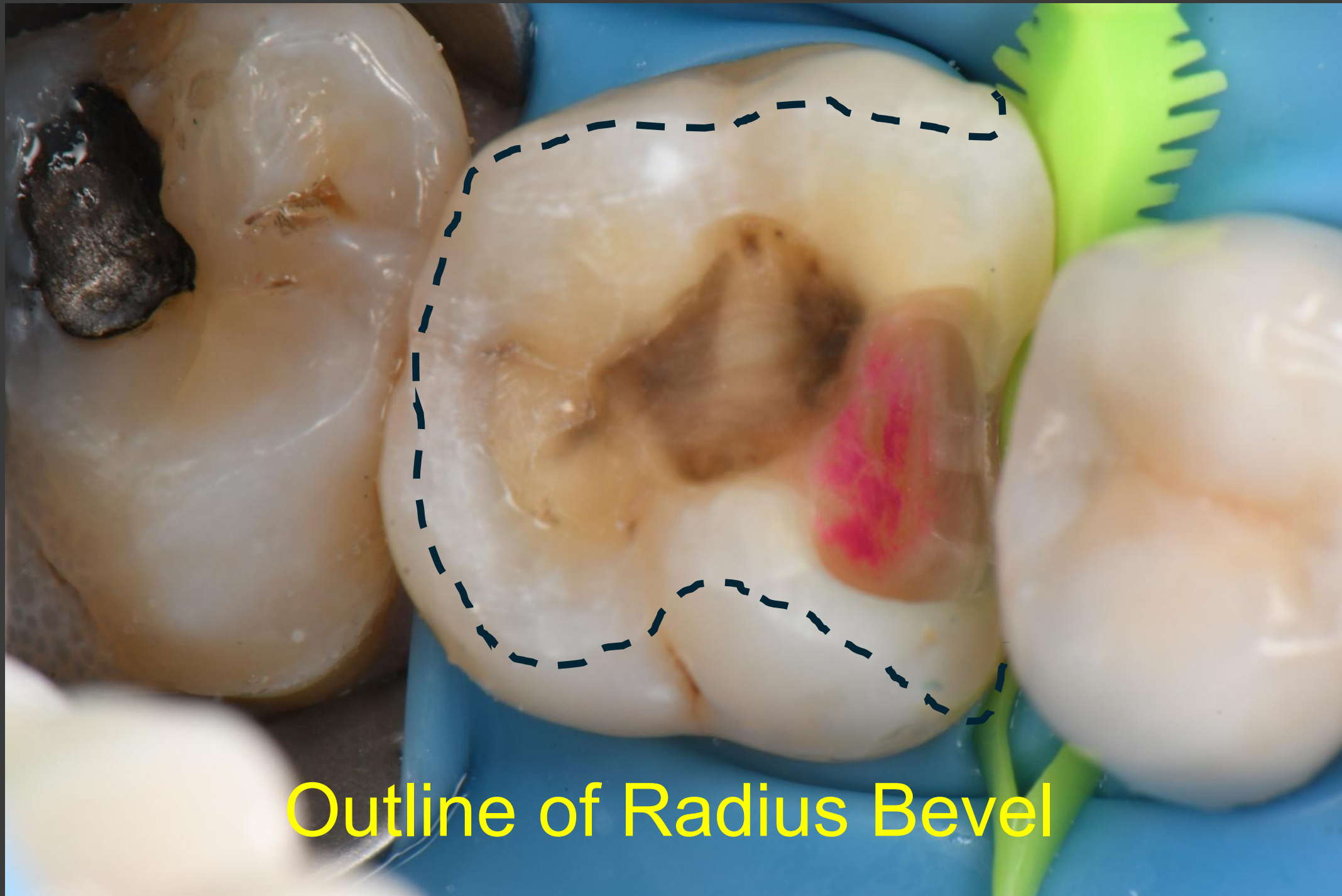
The new “Long Diamond Wedge” Available
in all five Diamond Wedge shapes



Long (Double-Hump) Furcal Wedge

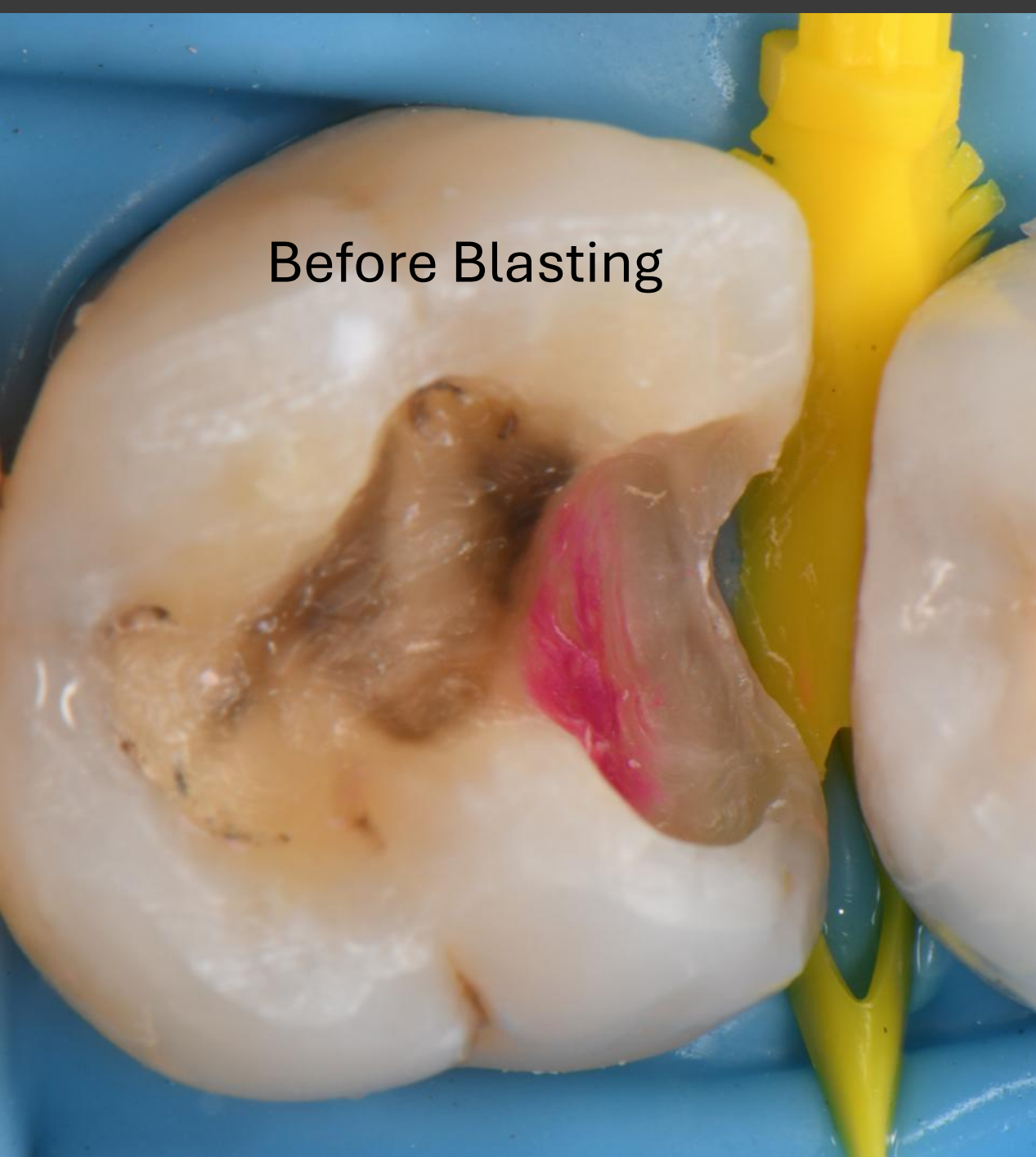




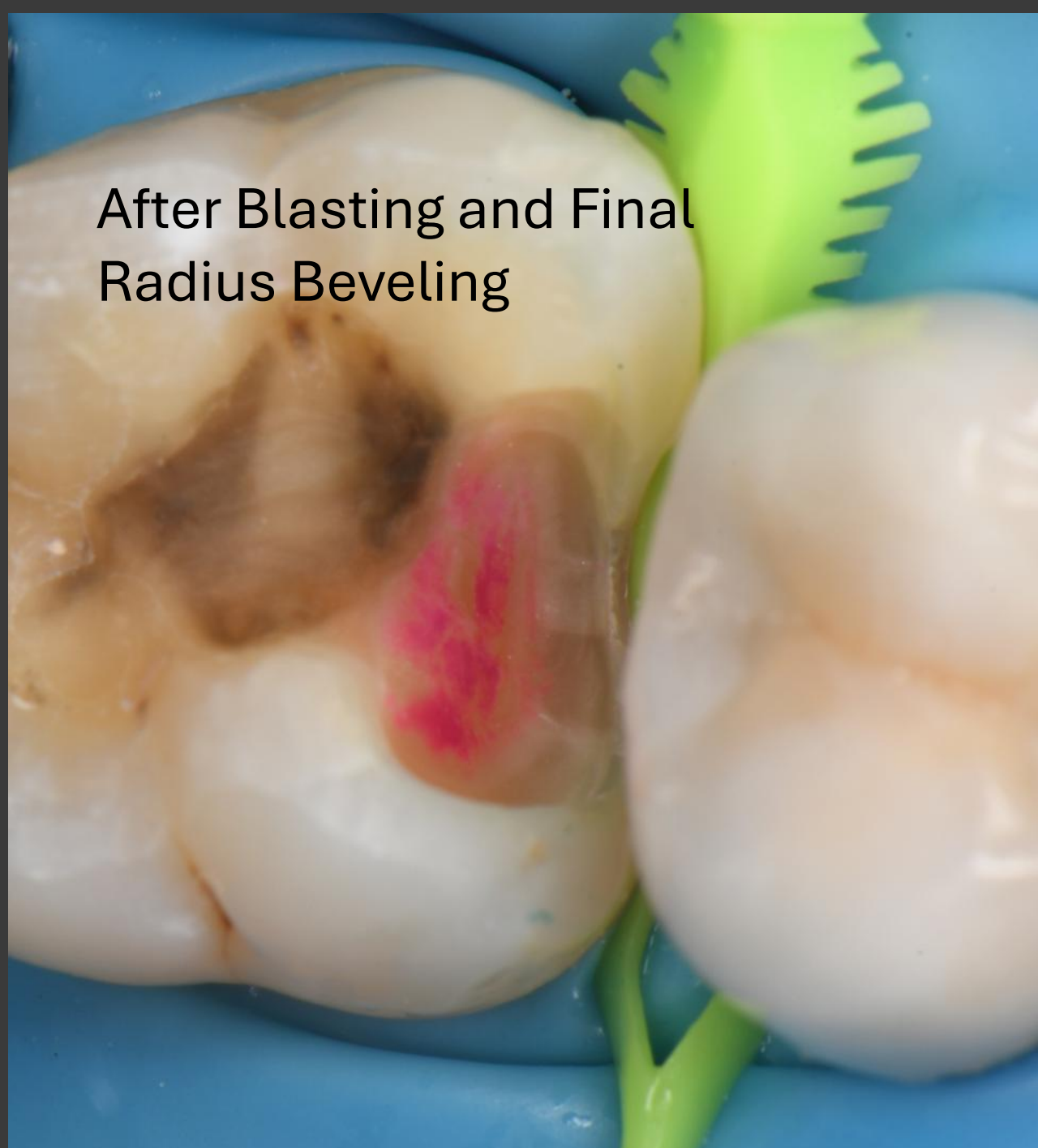
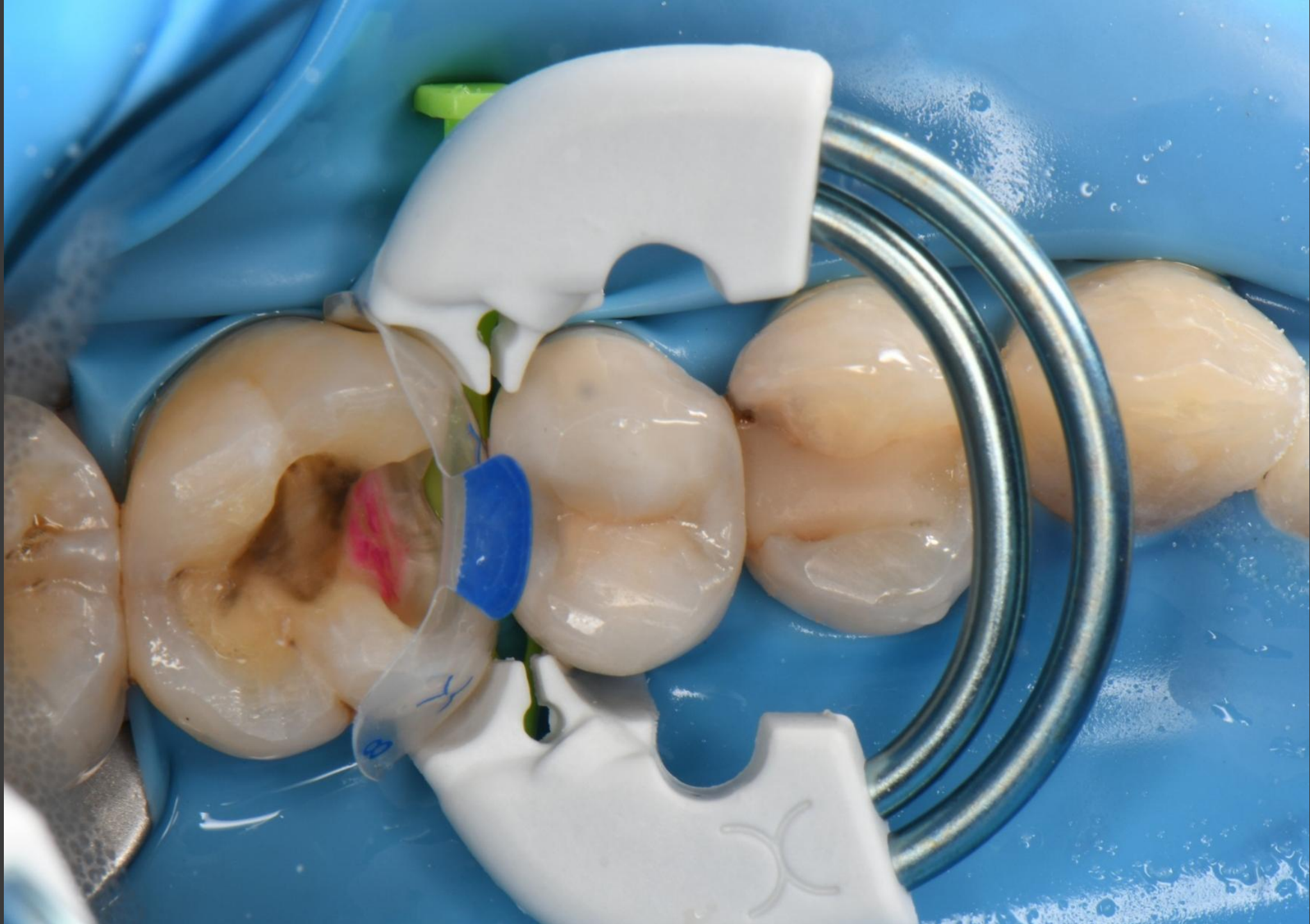Outline of Radius Bevel

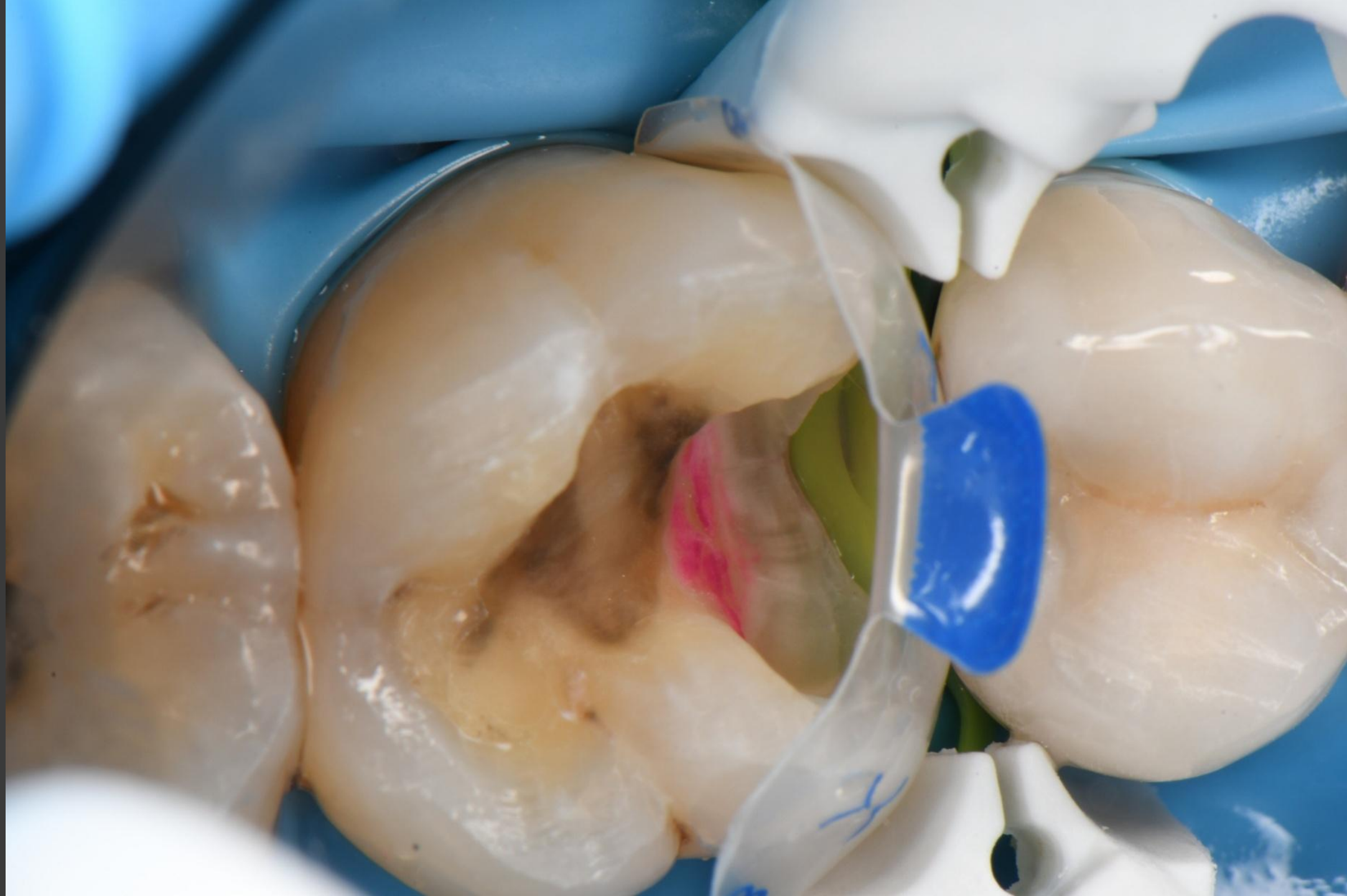Before Blasting

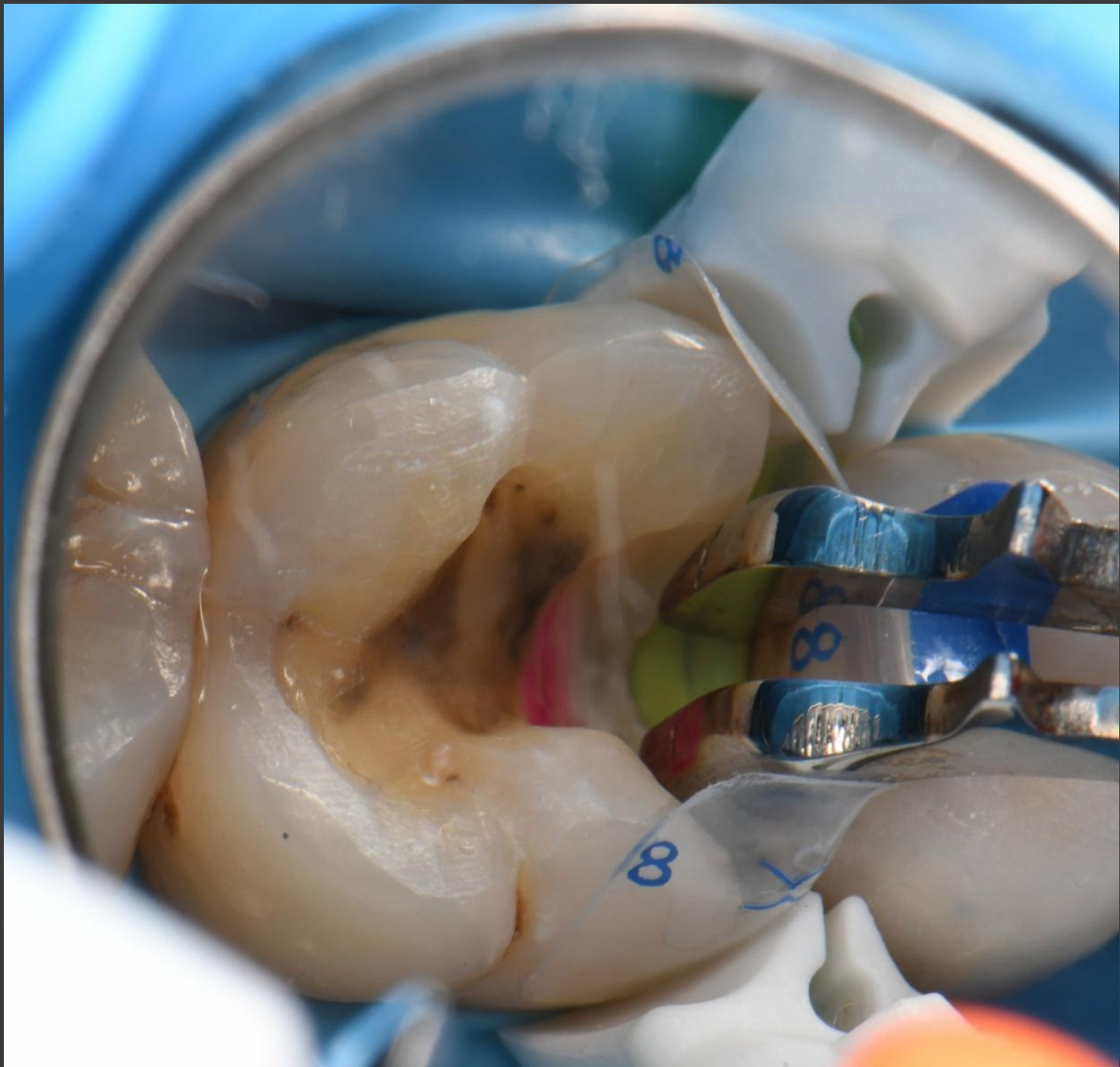


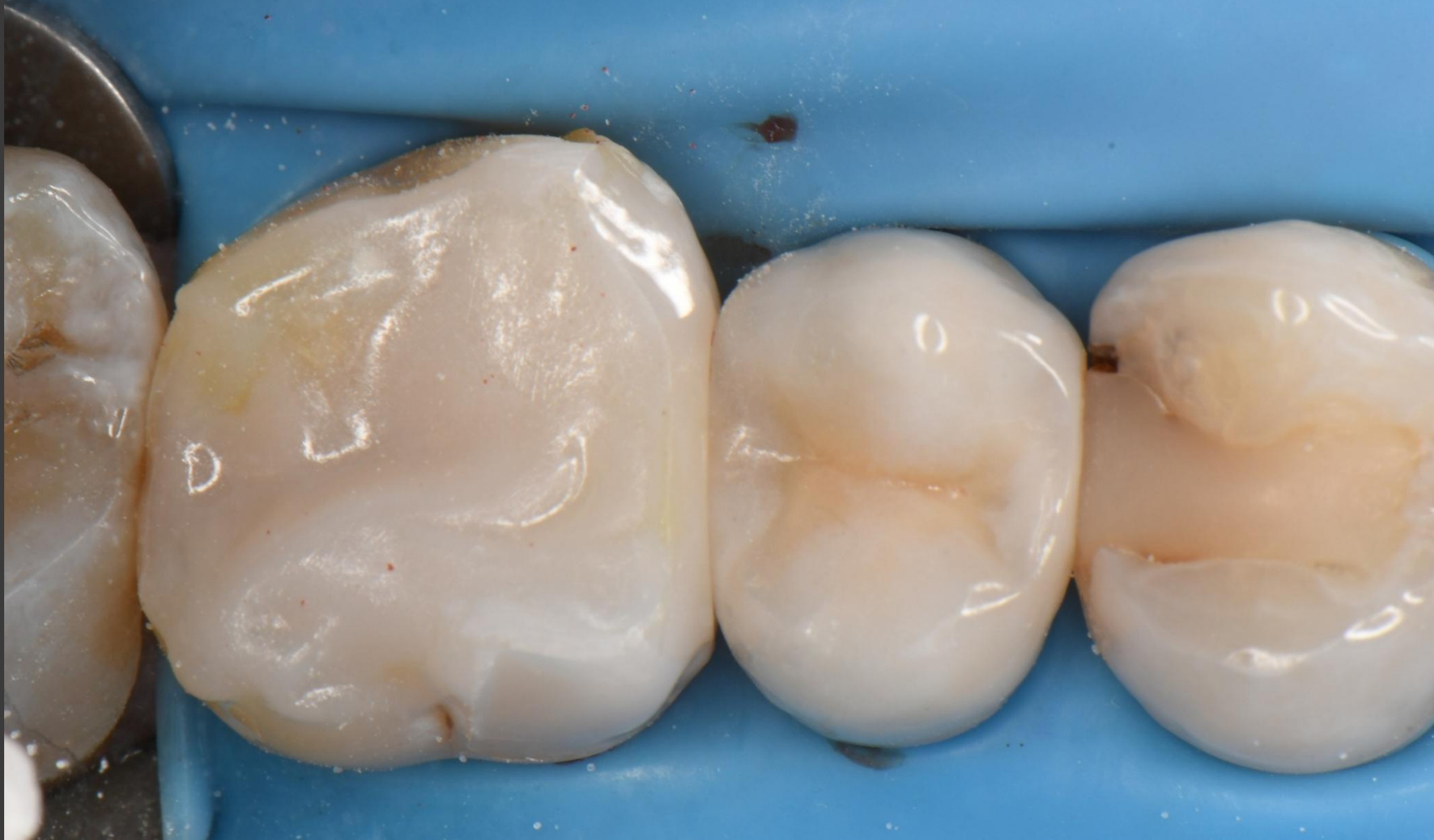
After Blasting and Final
Radius Beveling

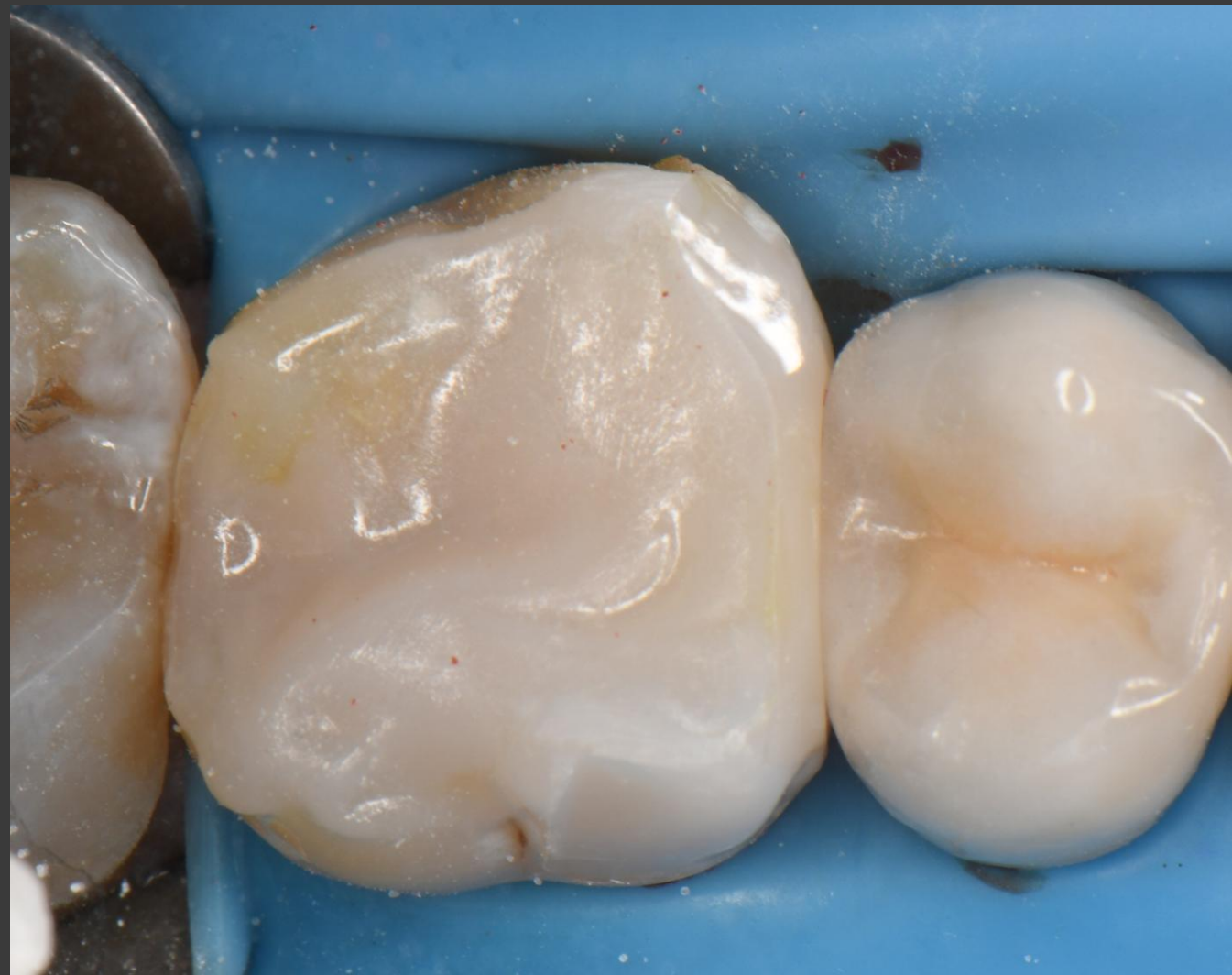
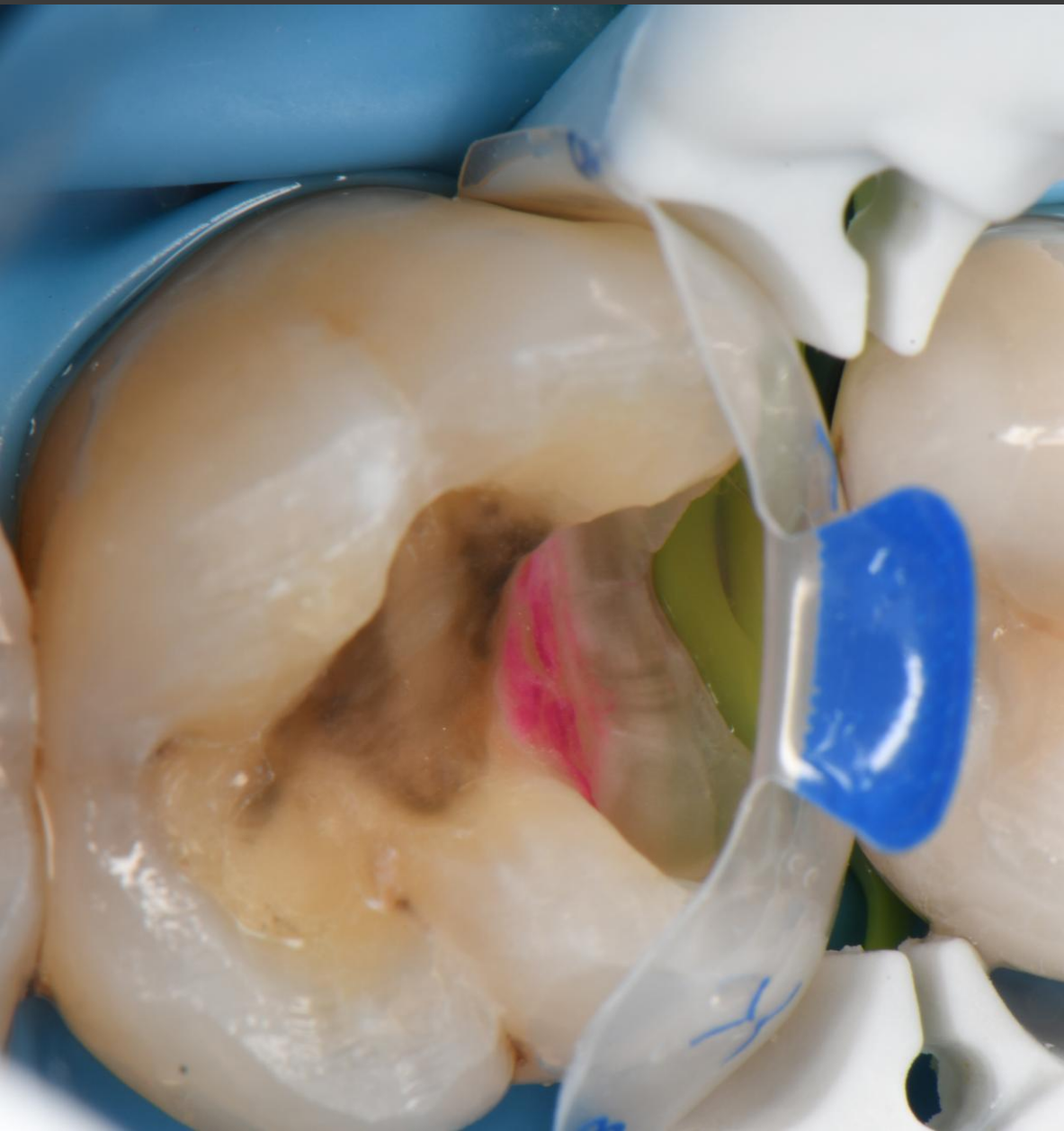


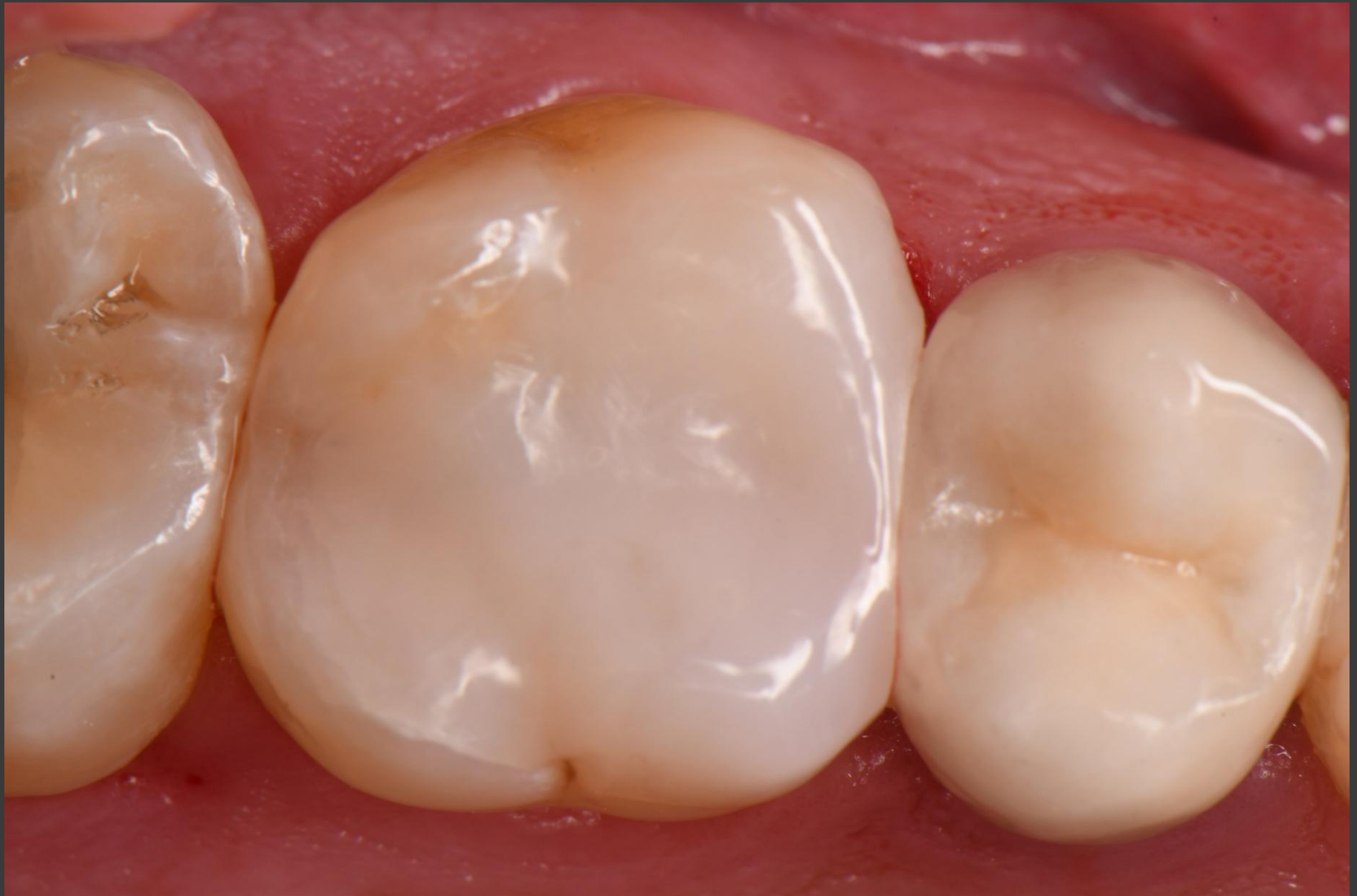


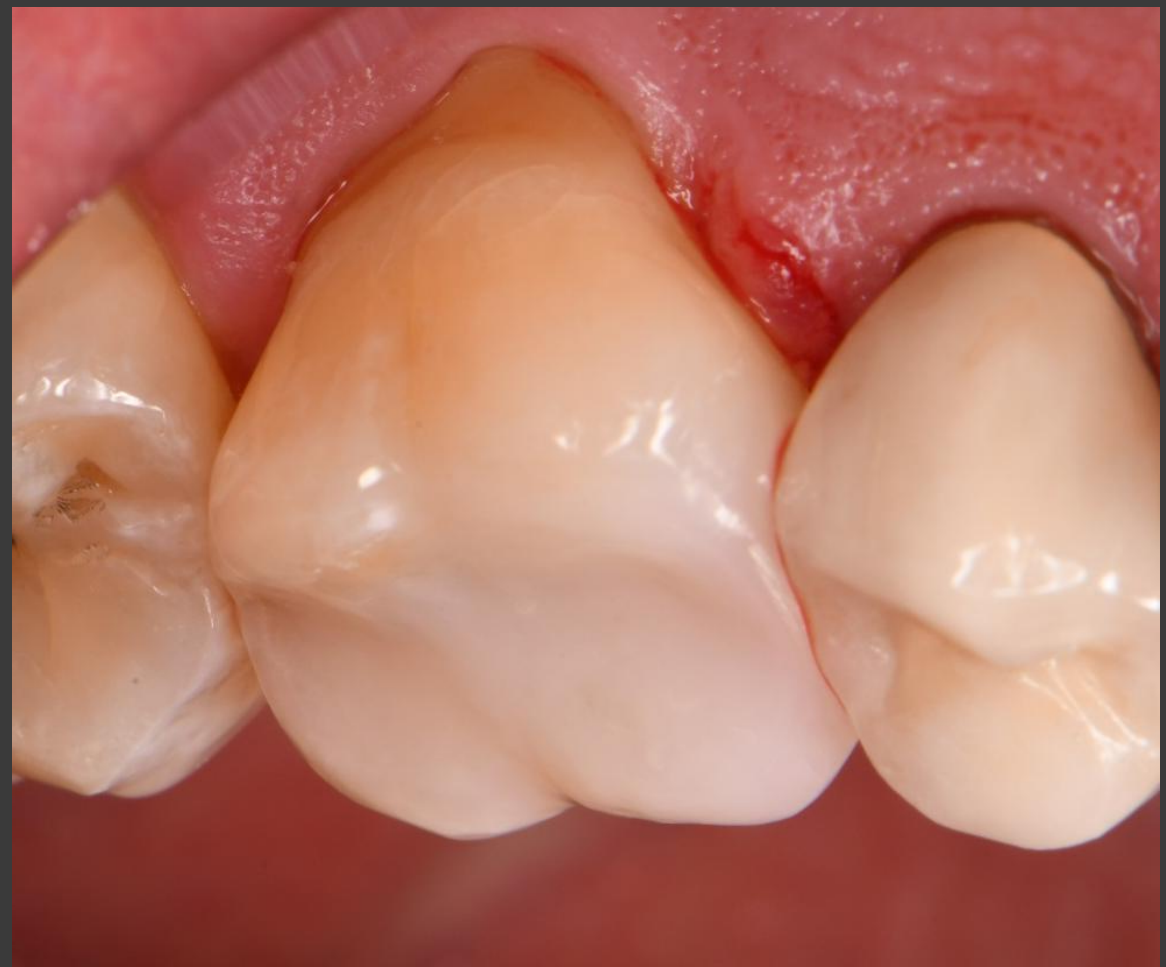
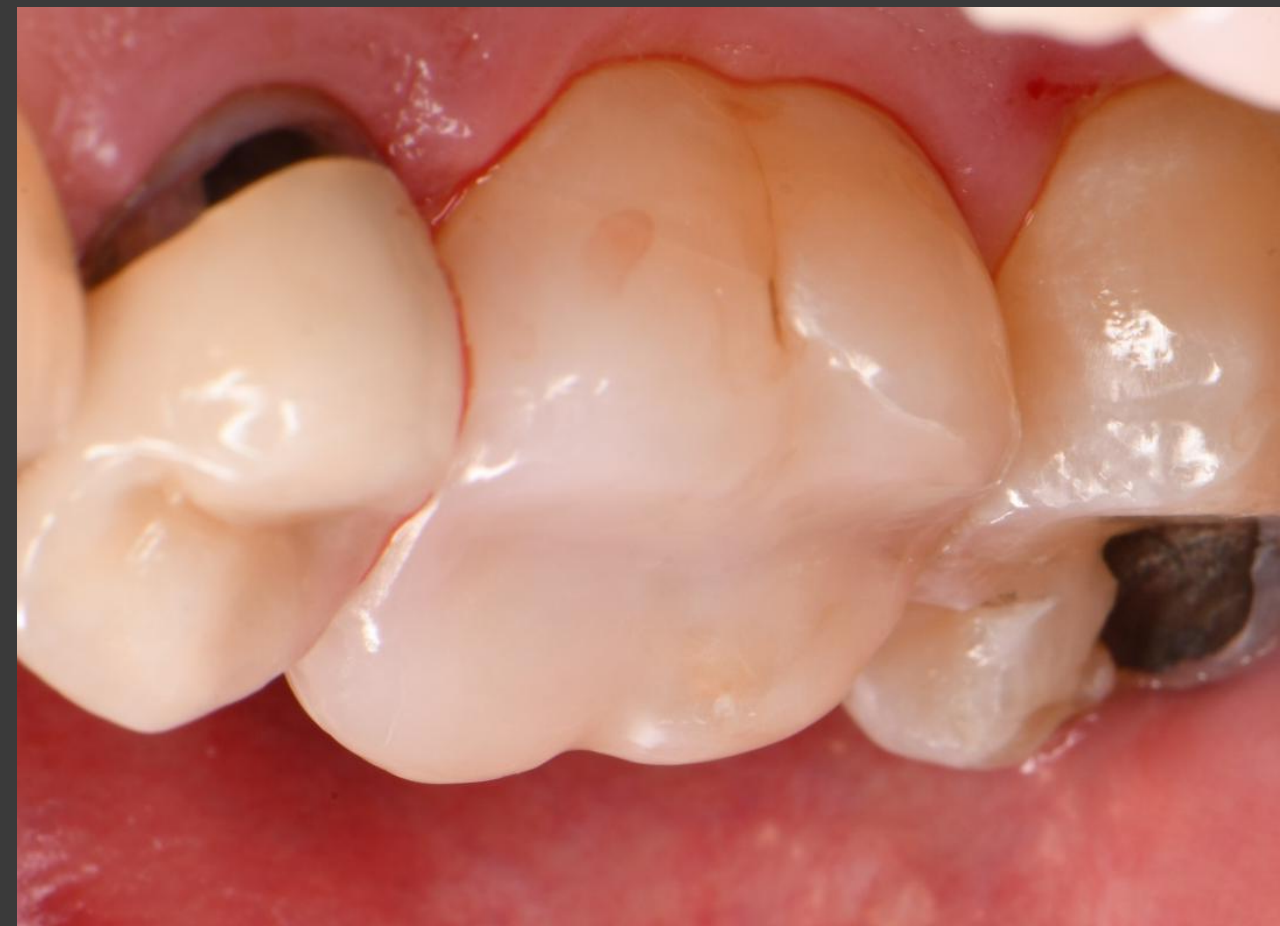


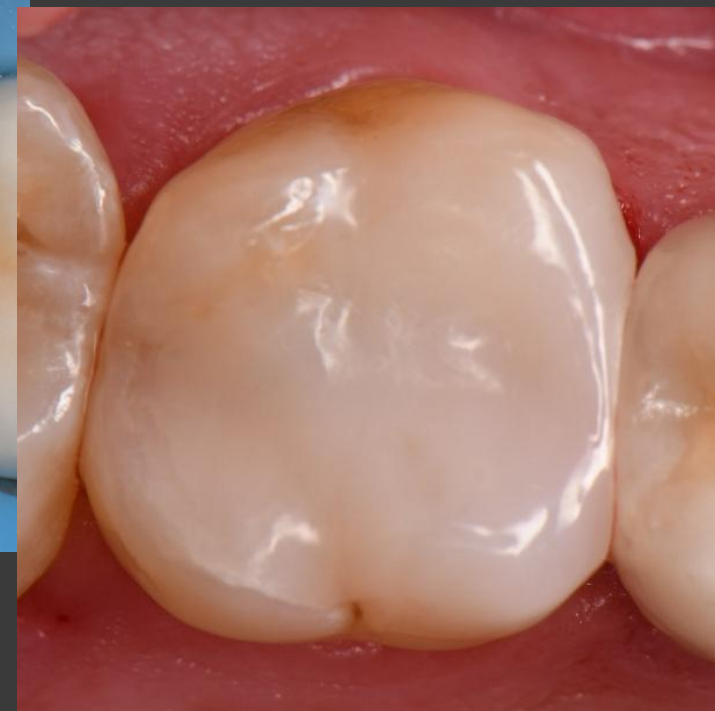
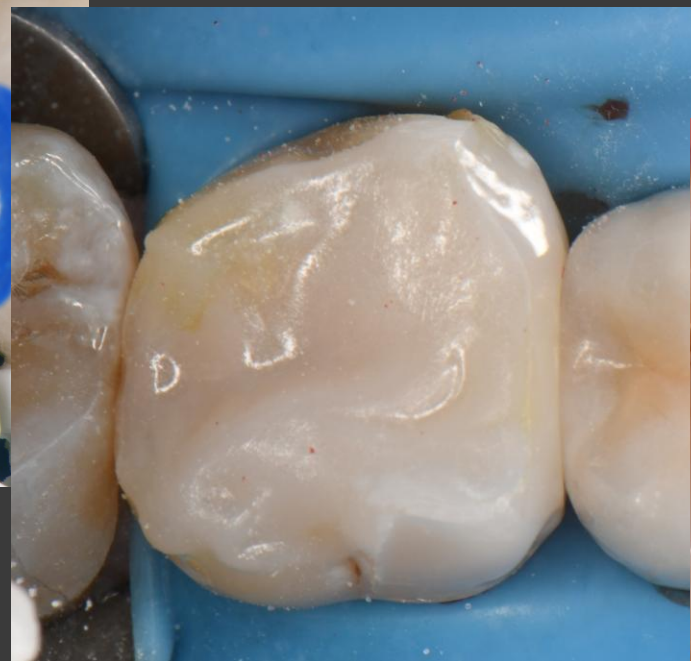
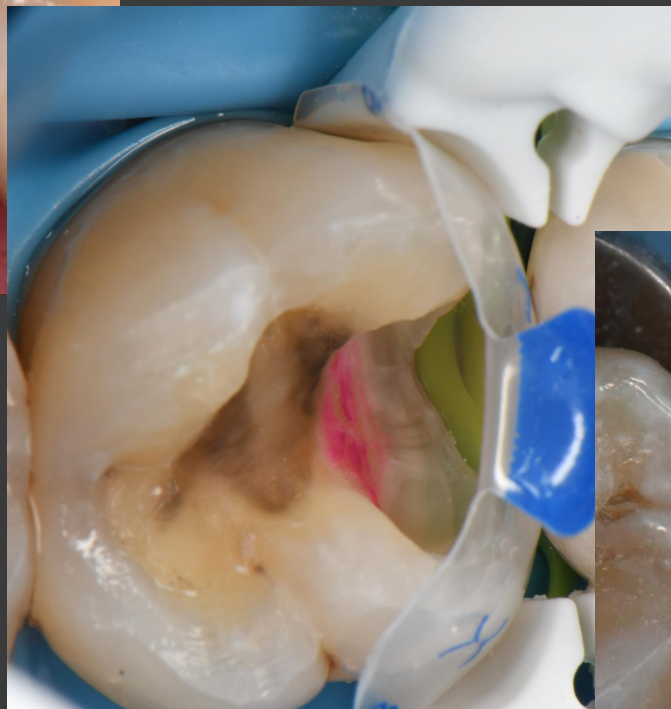
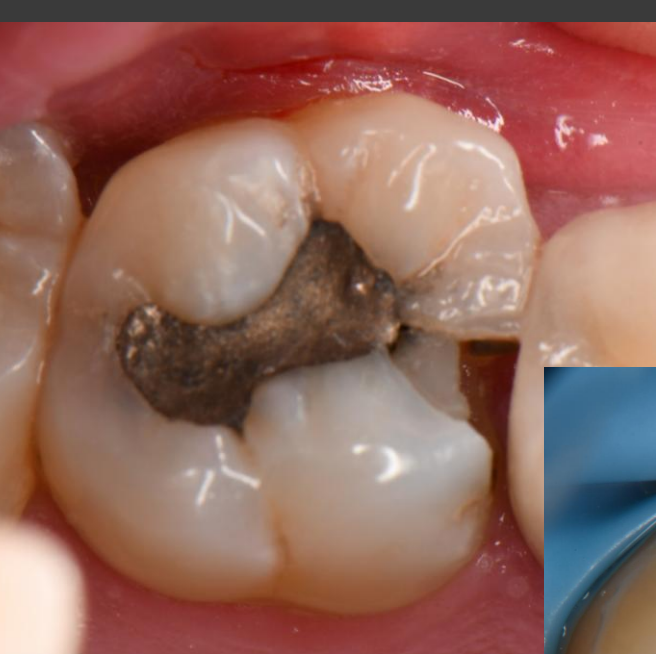



Miles ahead of everybody else for Bulk Fills

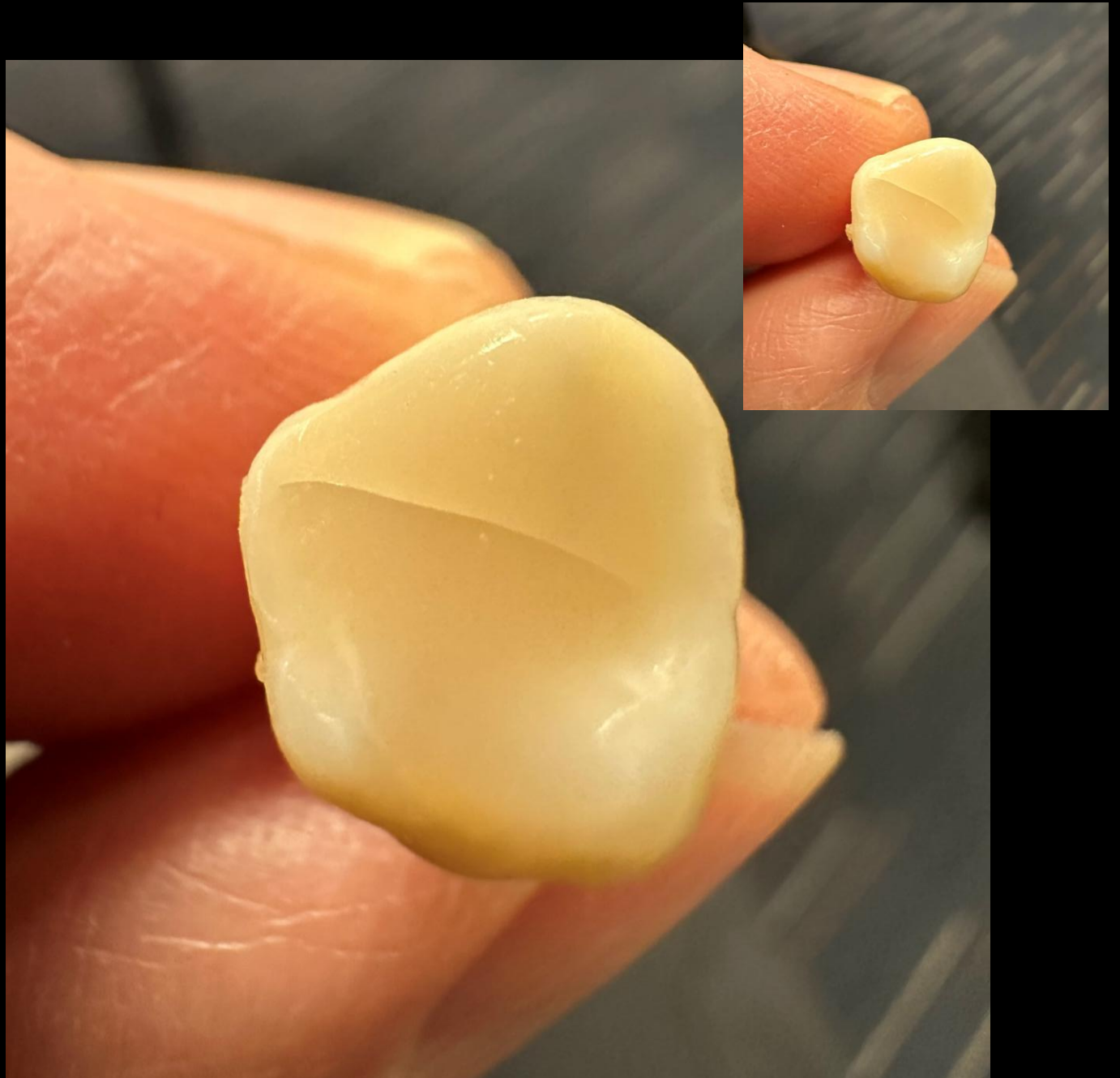




YIKES!!

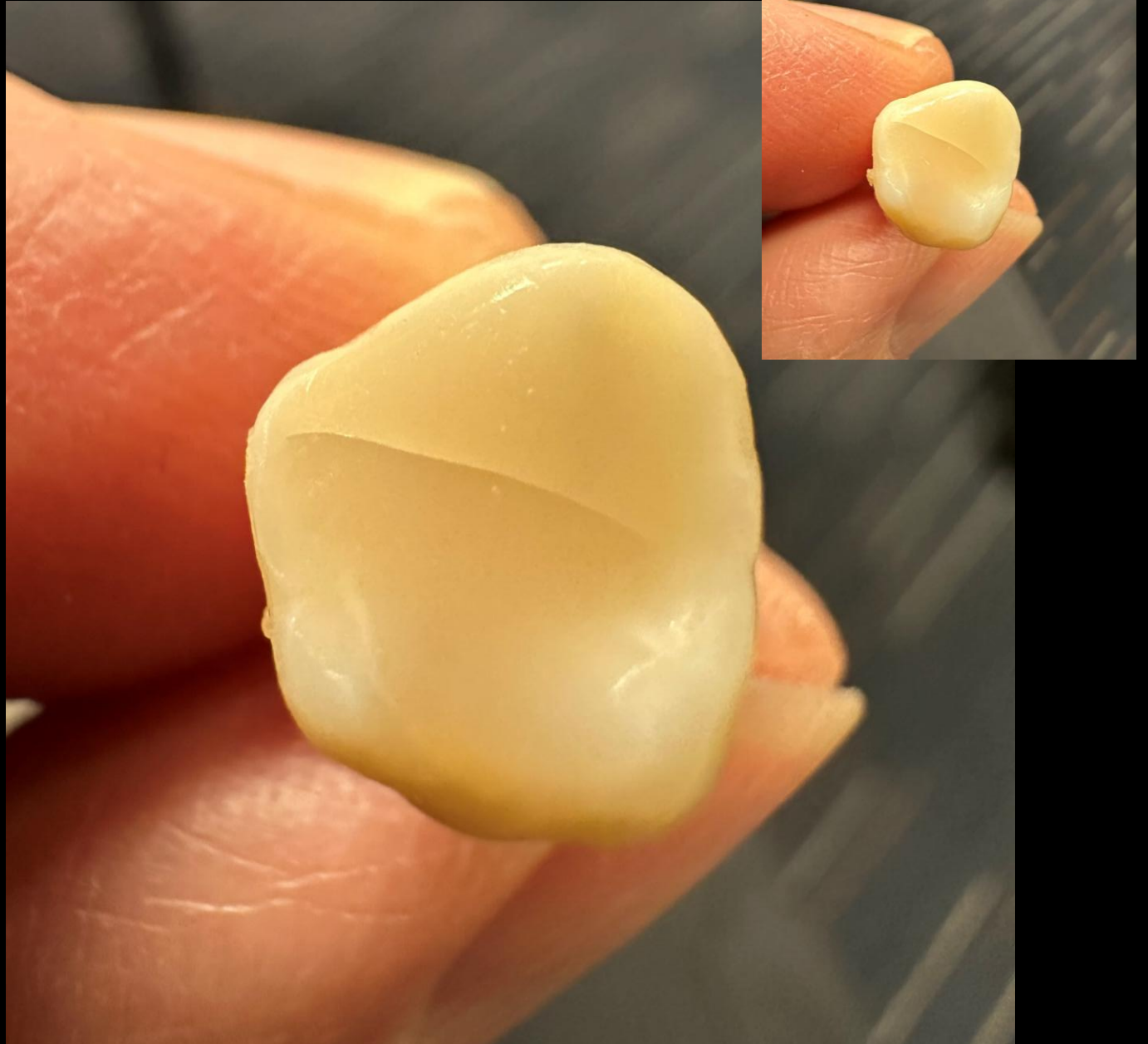
GC “Bulk Injectable”

Discussion:
Polymerization
shrinkage stress and
cuspal deflection is
very real but
challenging to
explain



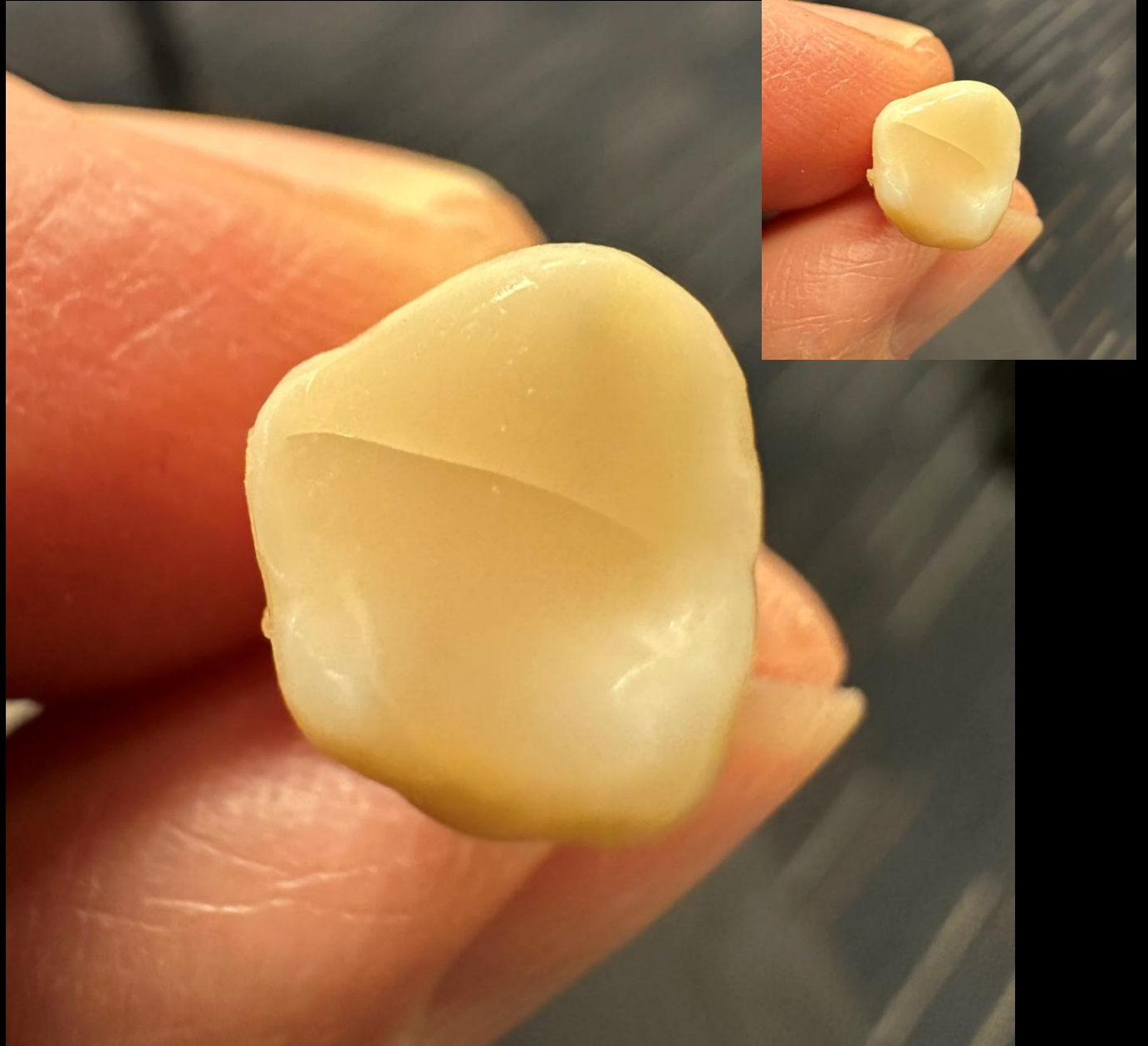
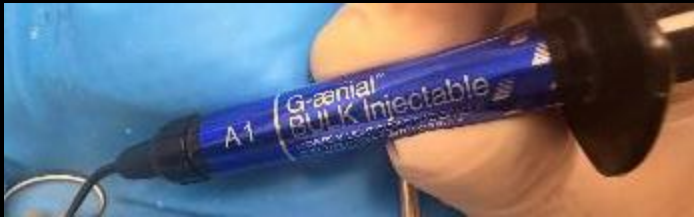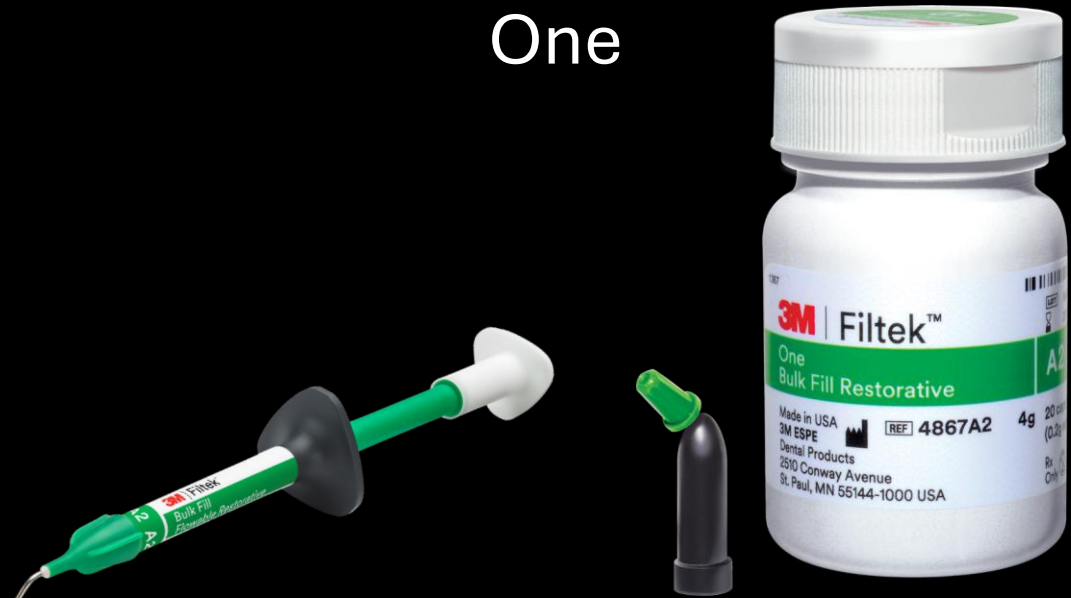Discussion:

The volume of composite, and residual strength of the tooth are key players. If half of tooth is missing, ie there is a good sized hole in the occlusal or interproximal, we are recommending Filtek One (bulk fill paste) plus GC bulk flow or Filtek bulk flow.



Discussion:

If you we have a fair amount of dentin removed, we need Filtek One

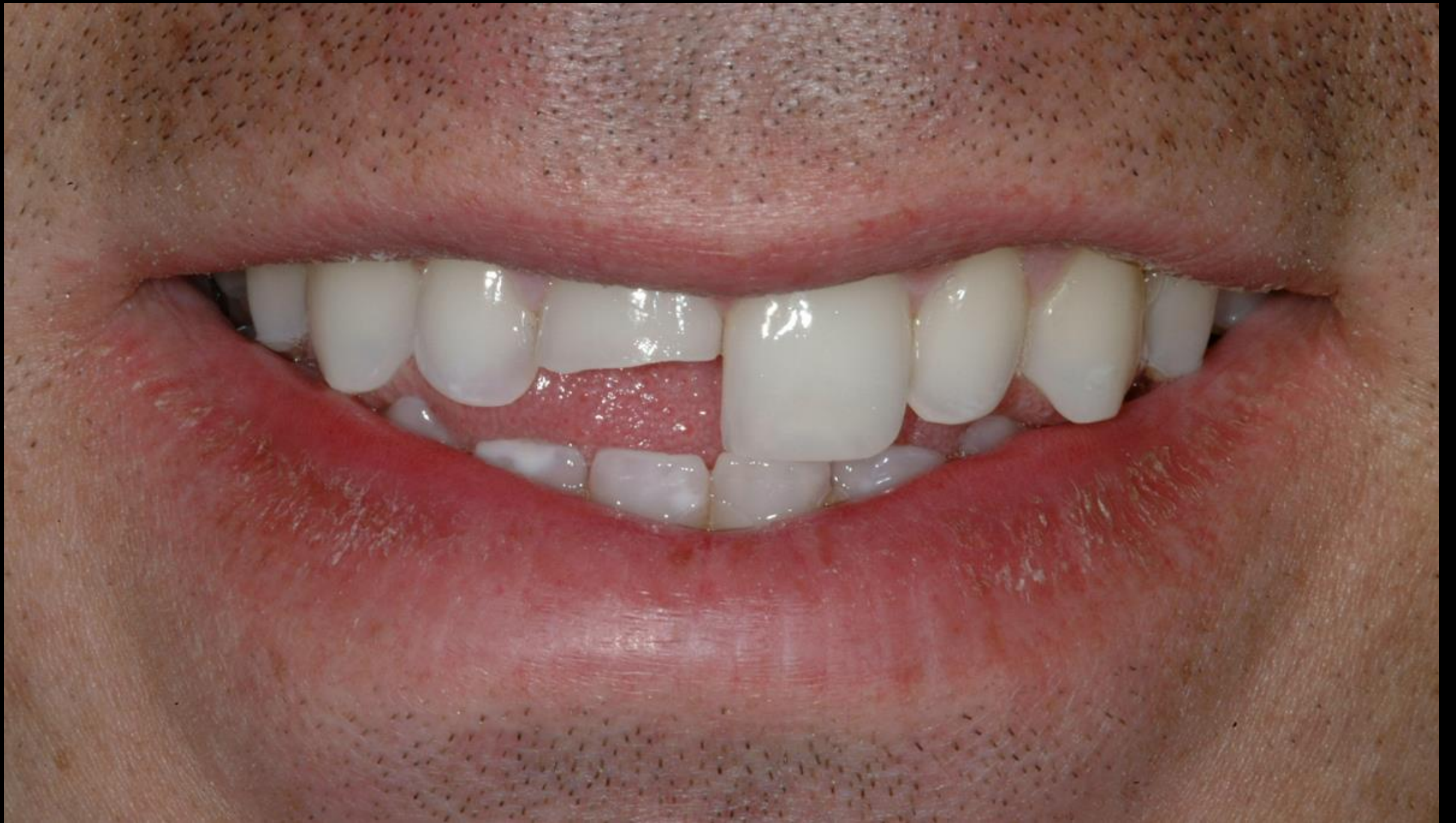

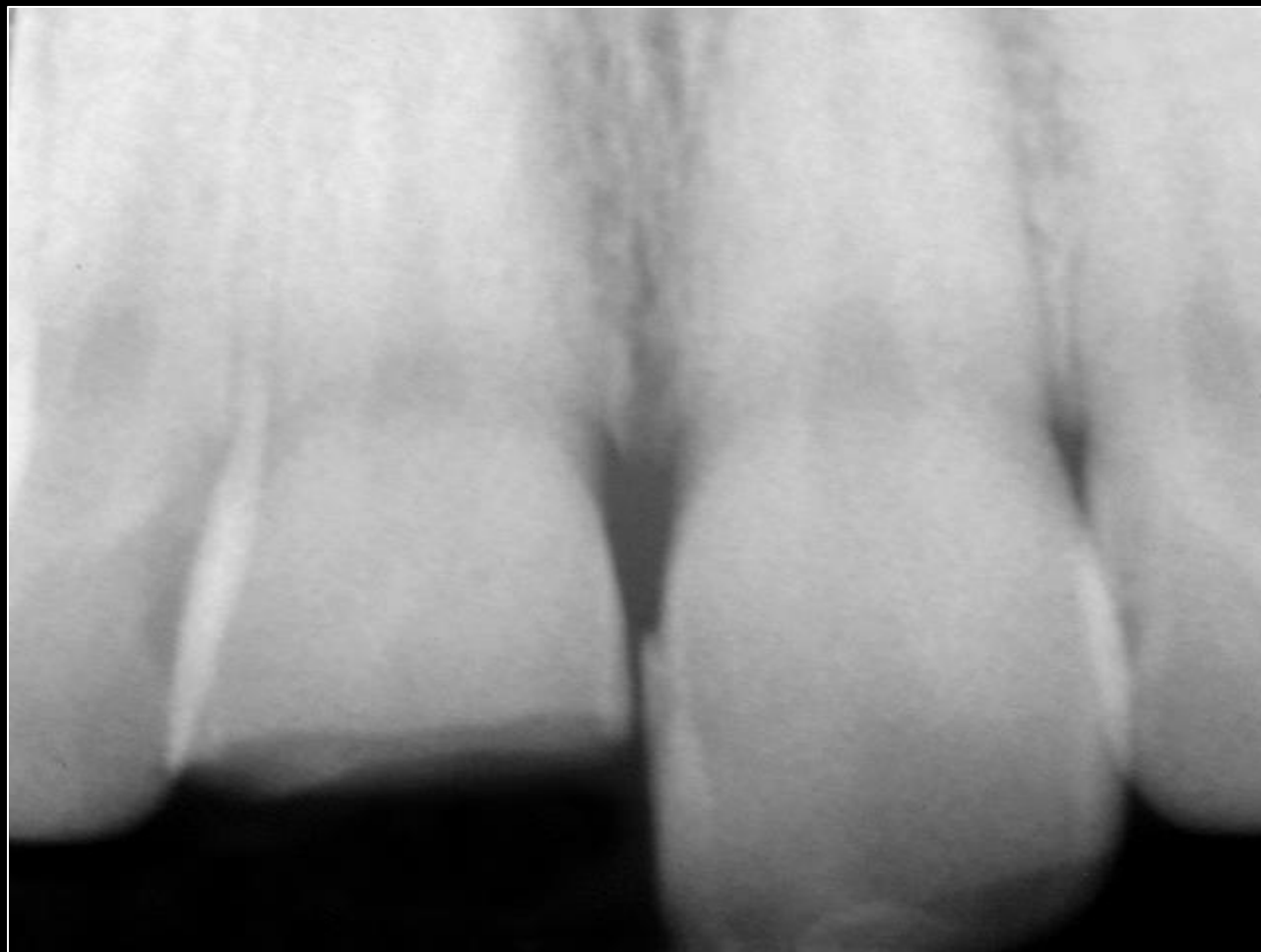
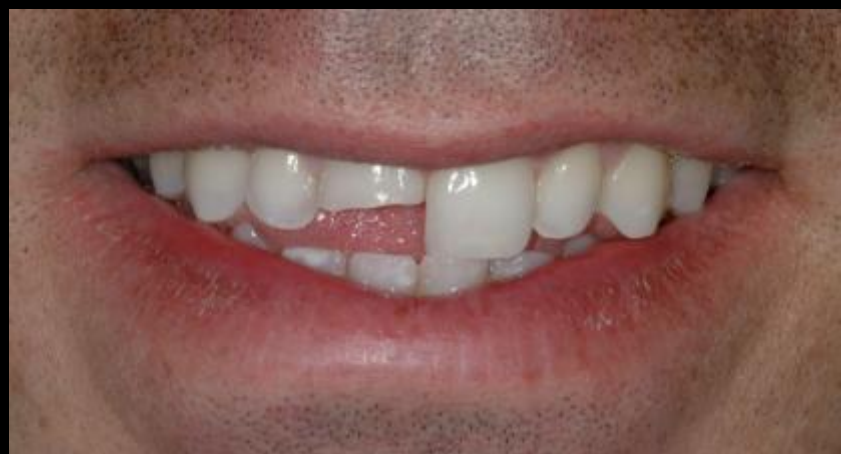Miles ahead of everybody else for Bulk Fills



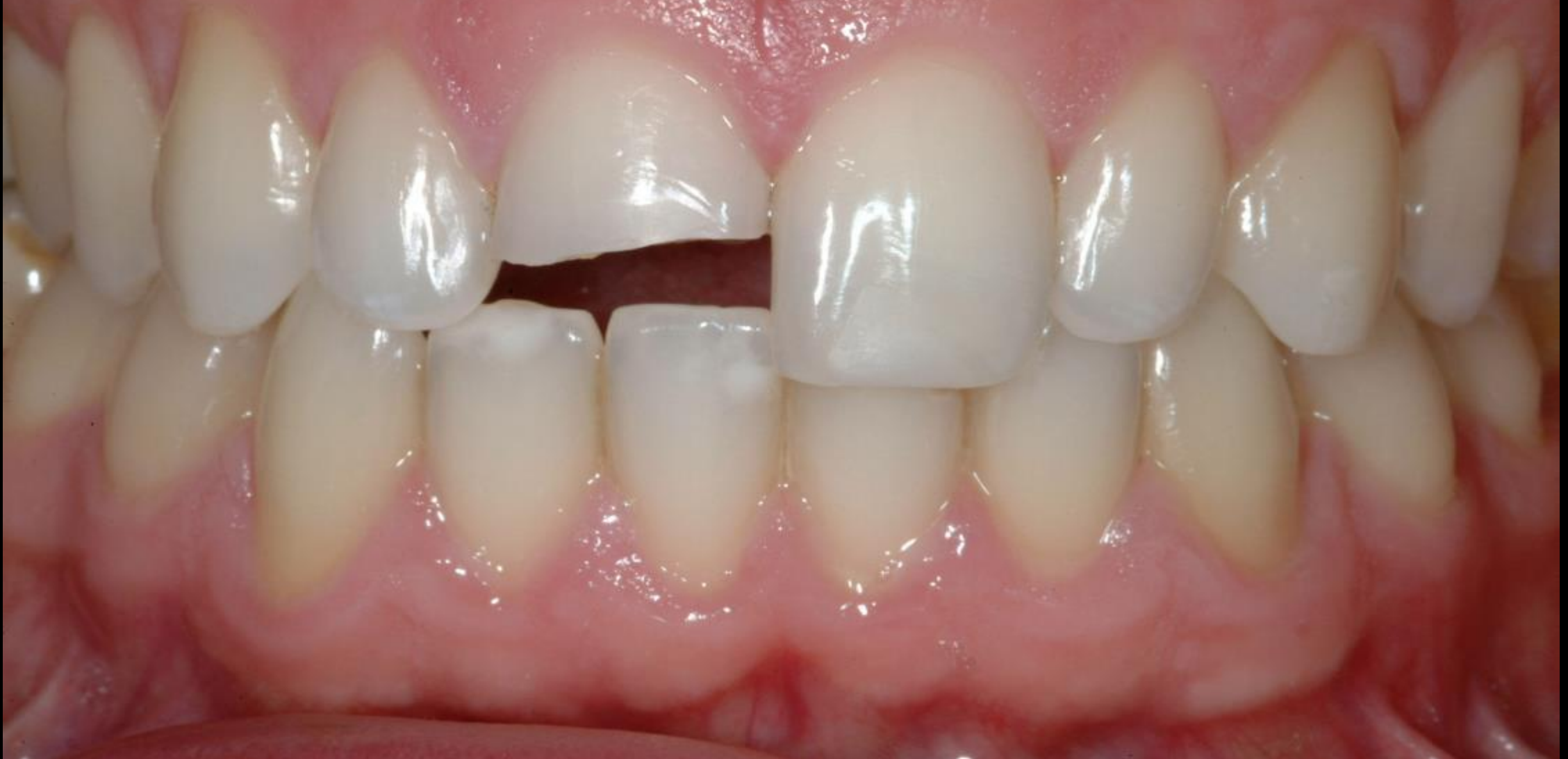In this case based lecture today we explore:

- Coronal (vertical and cuspal) Fracturing
- Snap-Off Fracturing

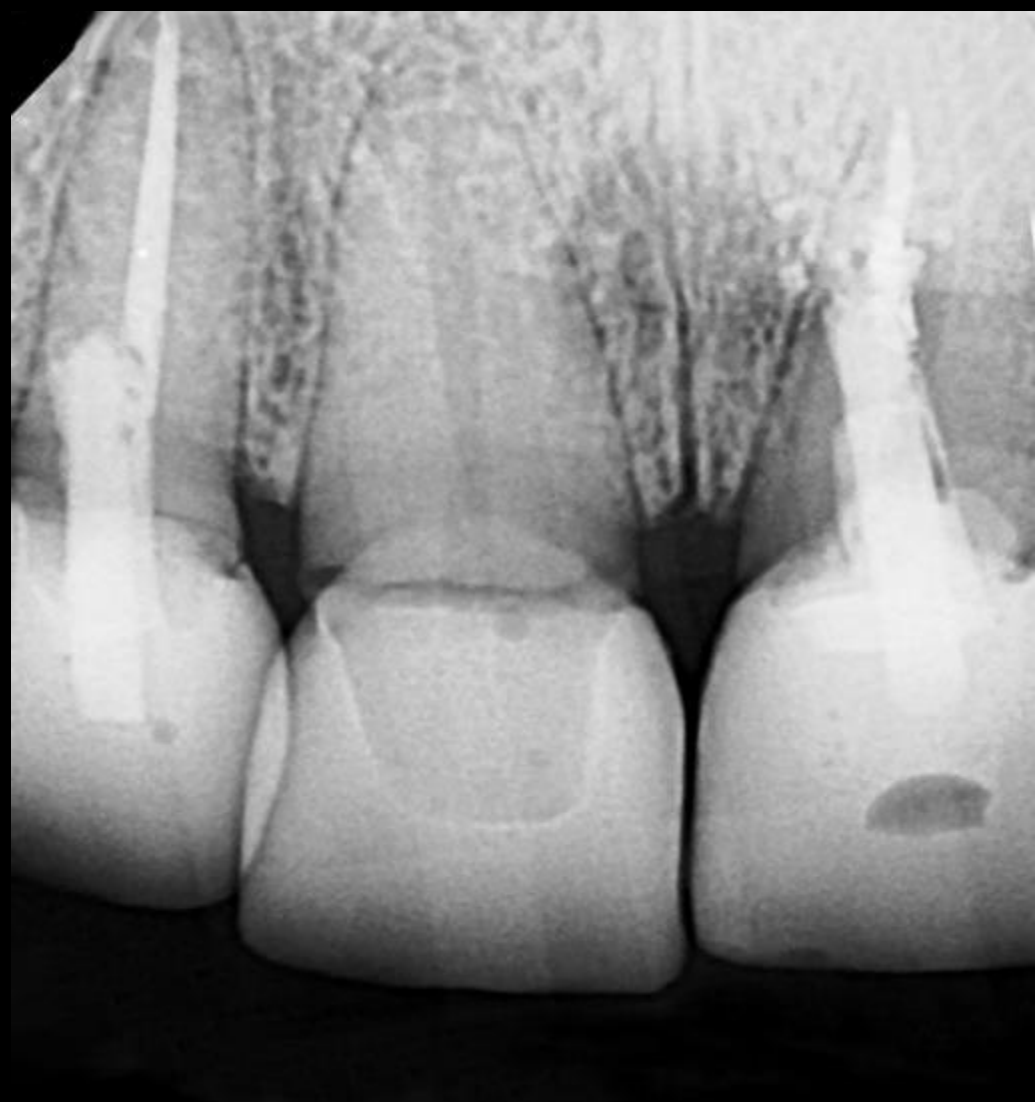


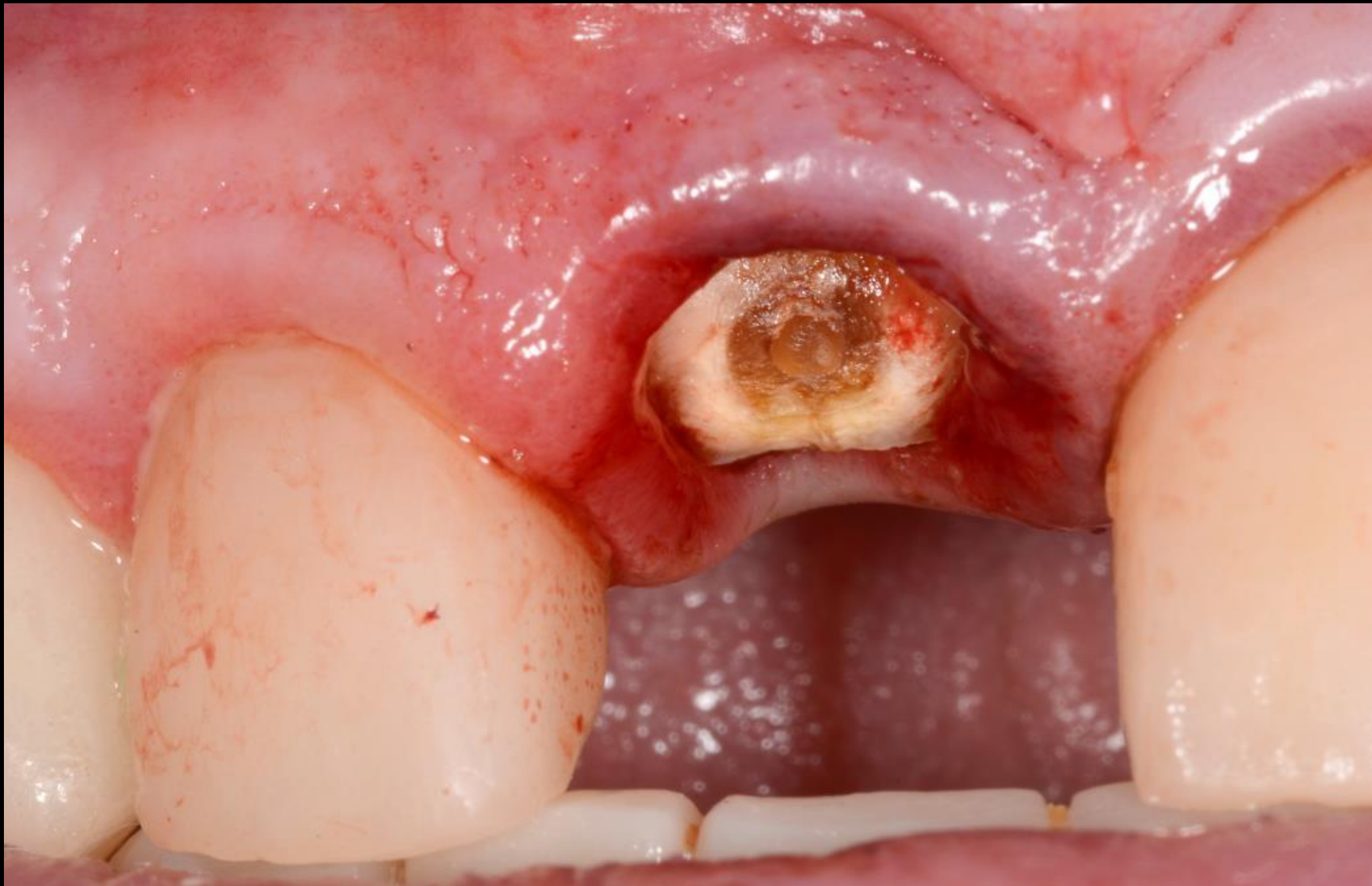
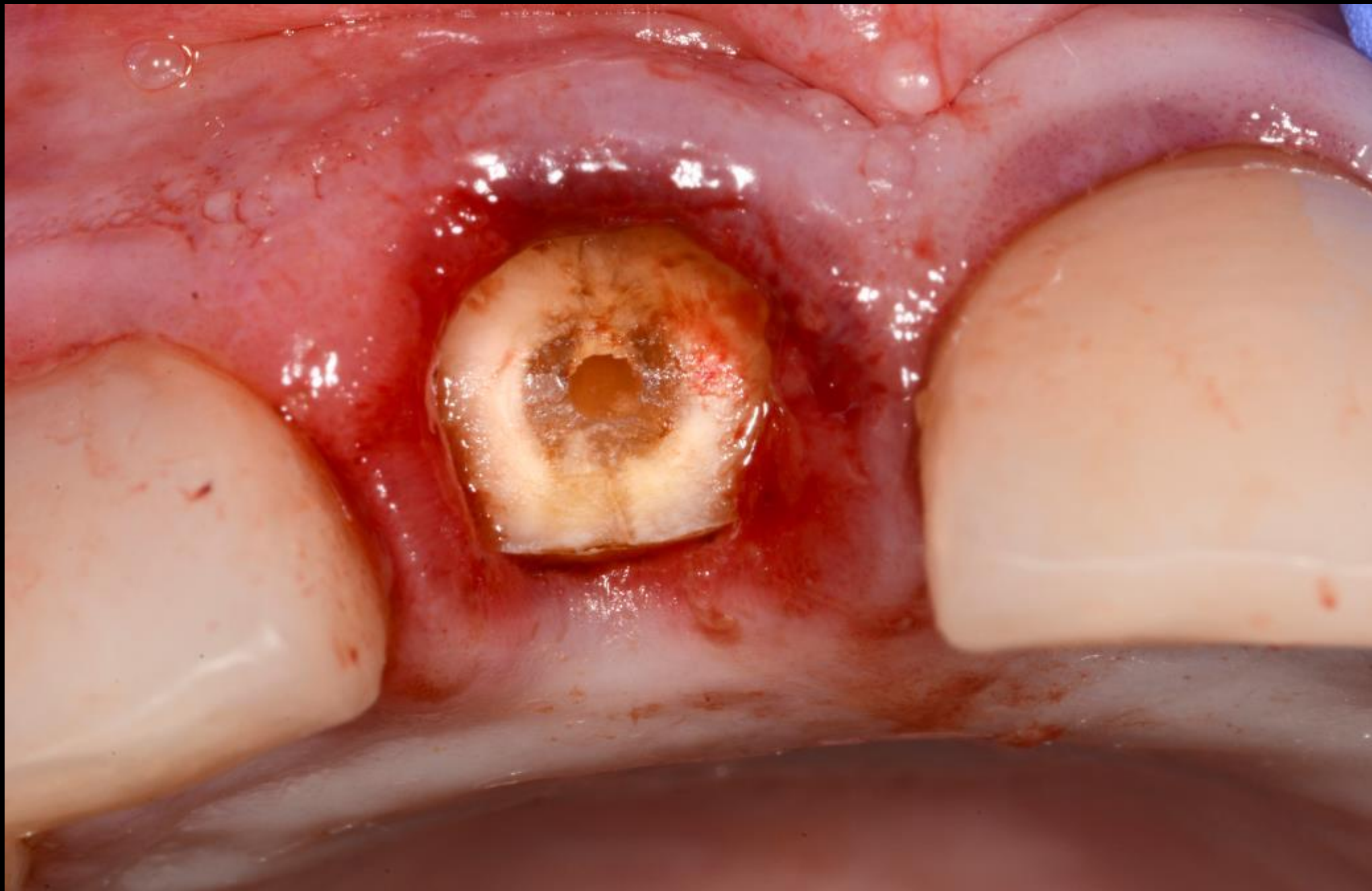What Would You Do?

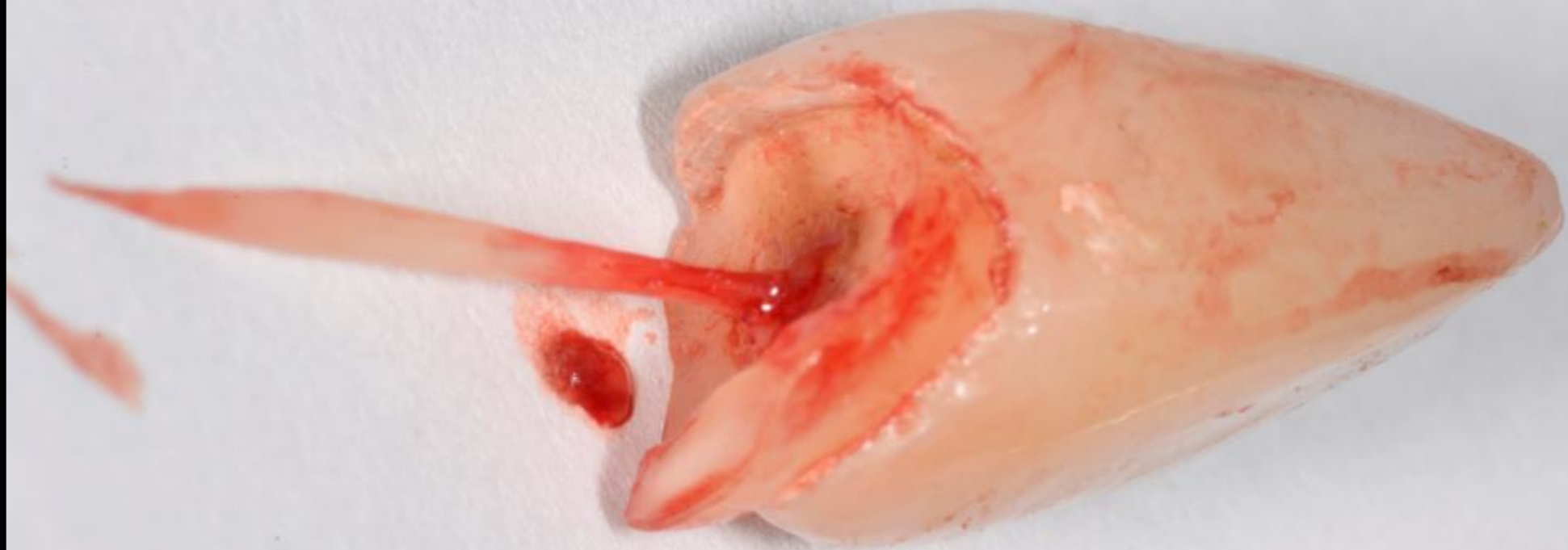


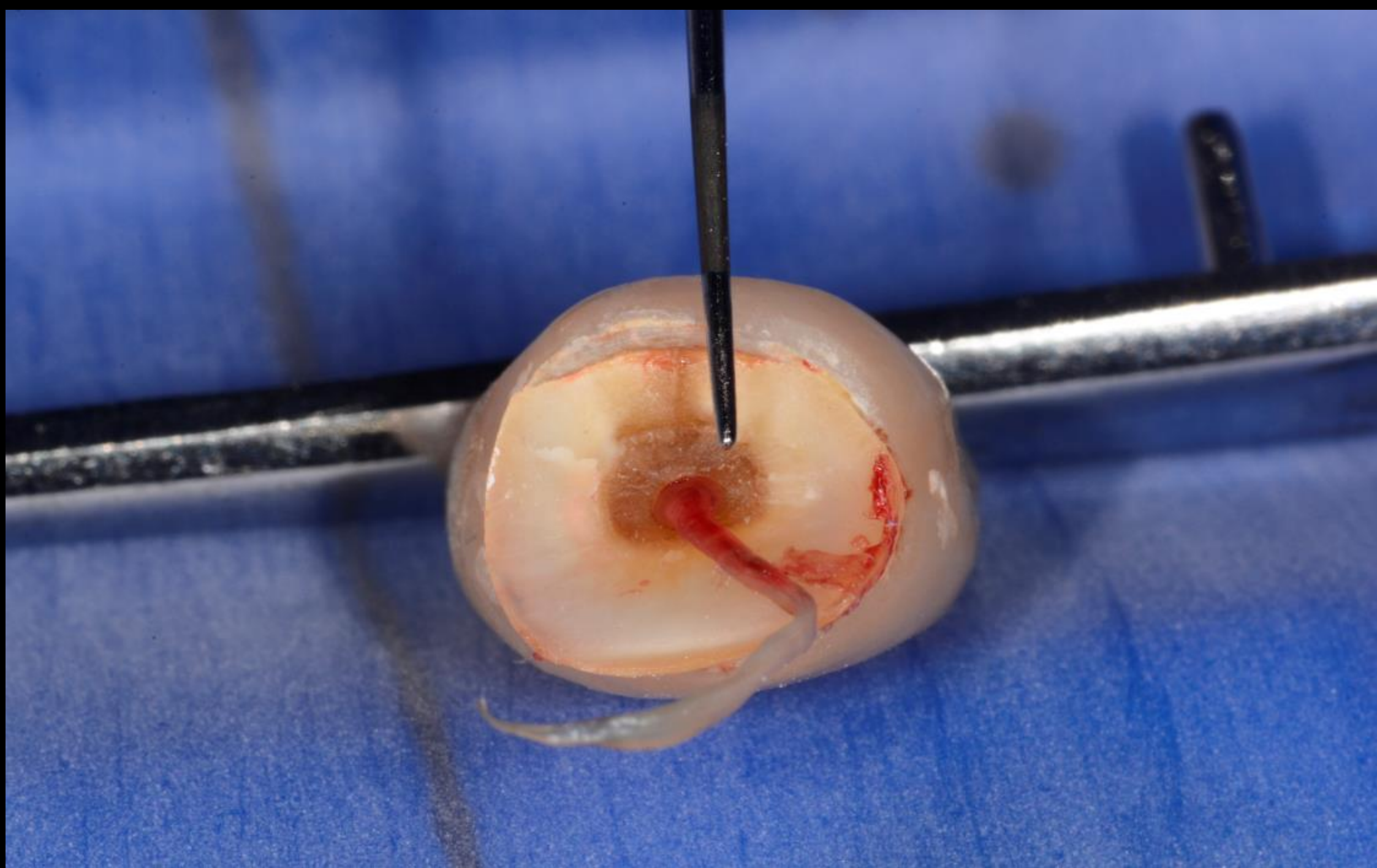
A different
toothache
patient we saw
recently...

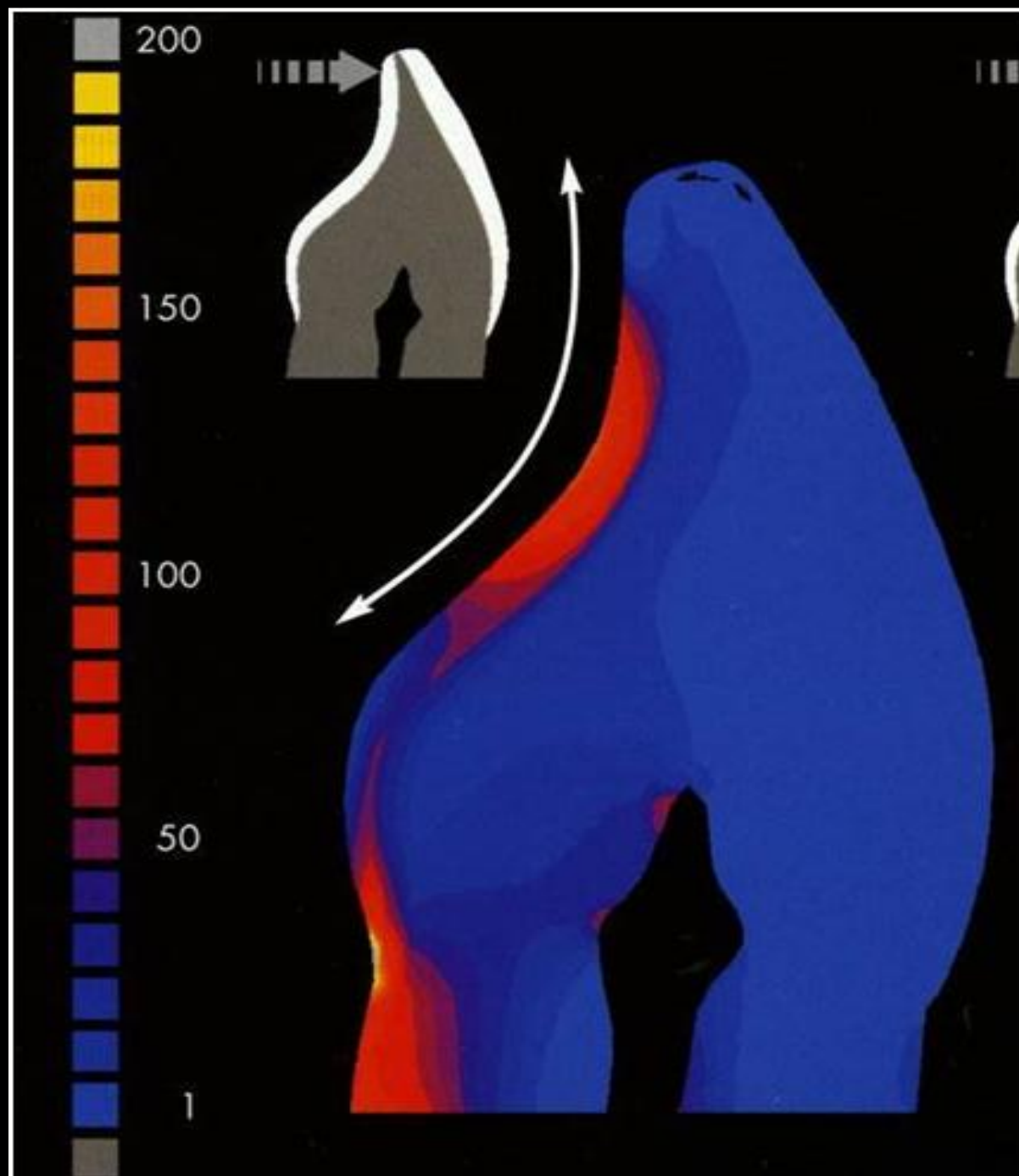


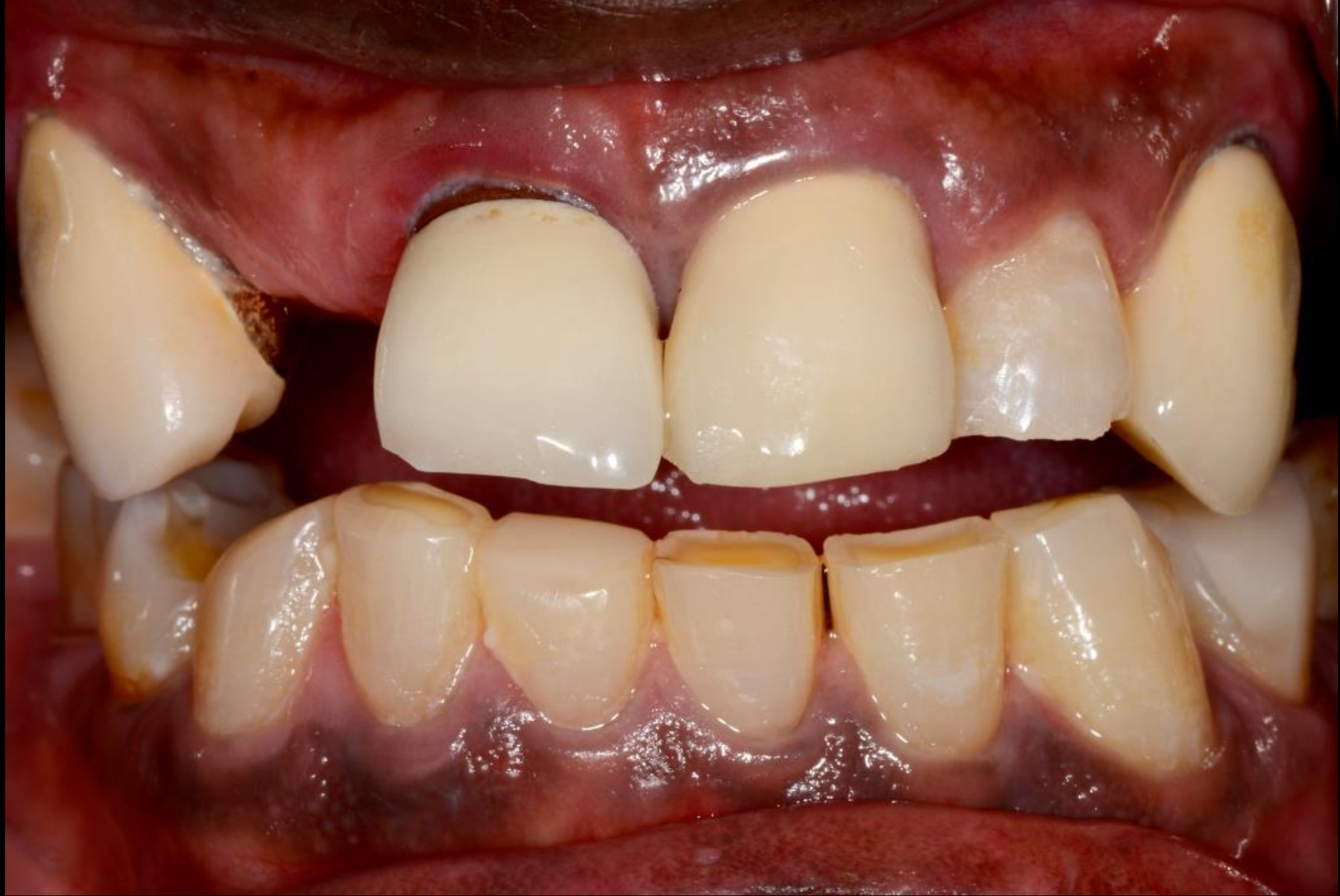


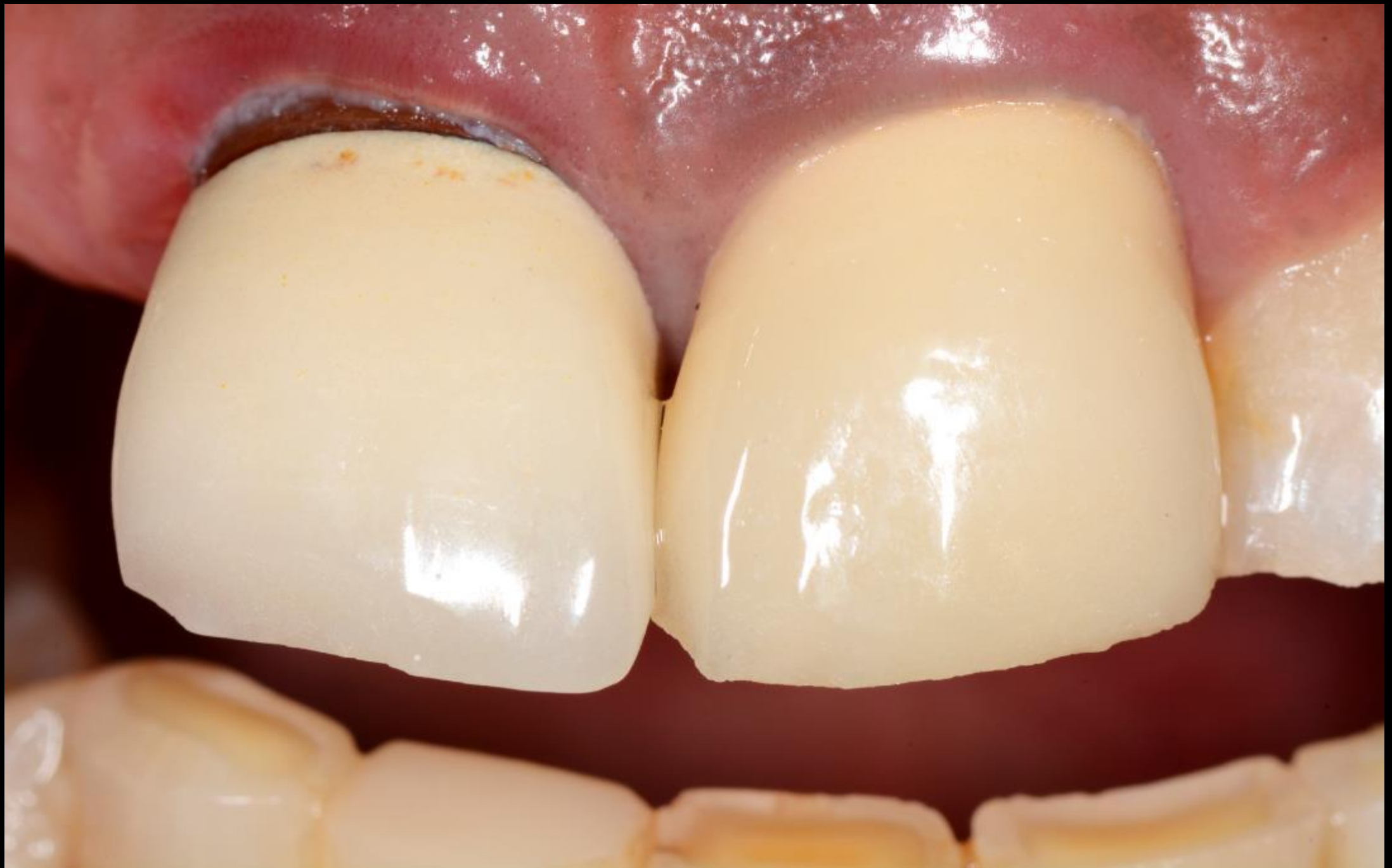
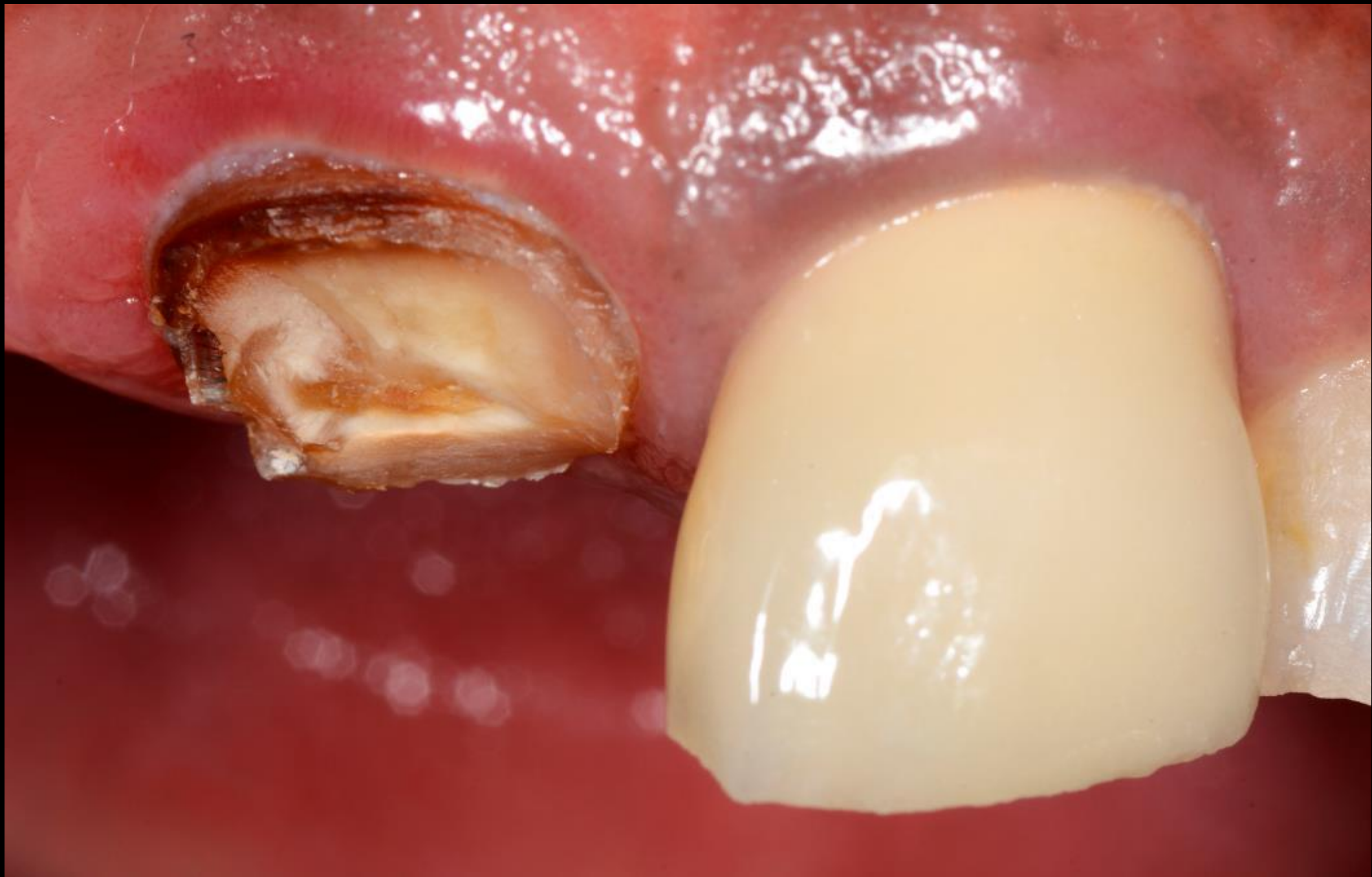




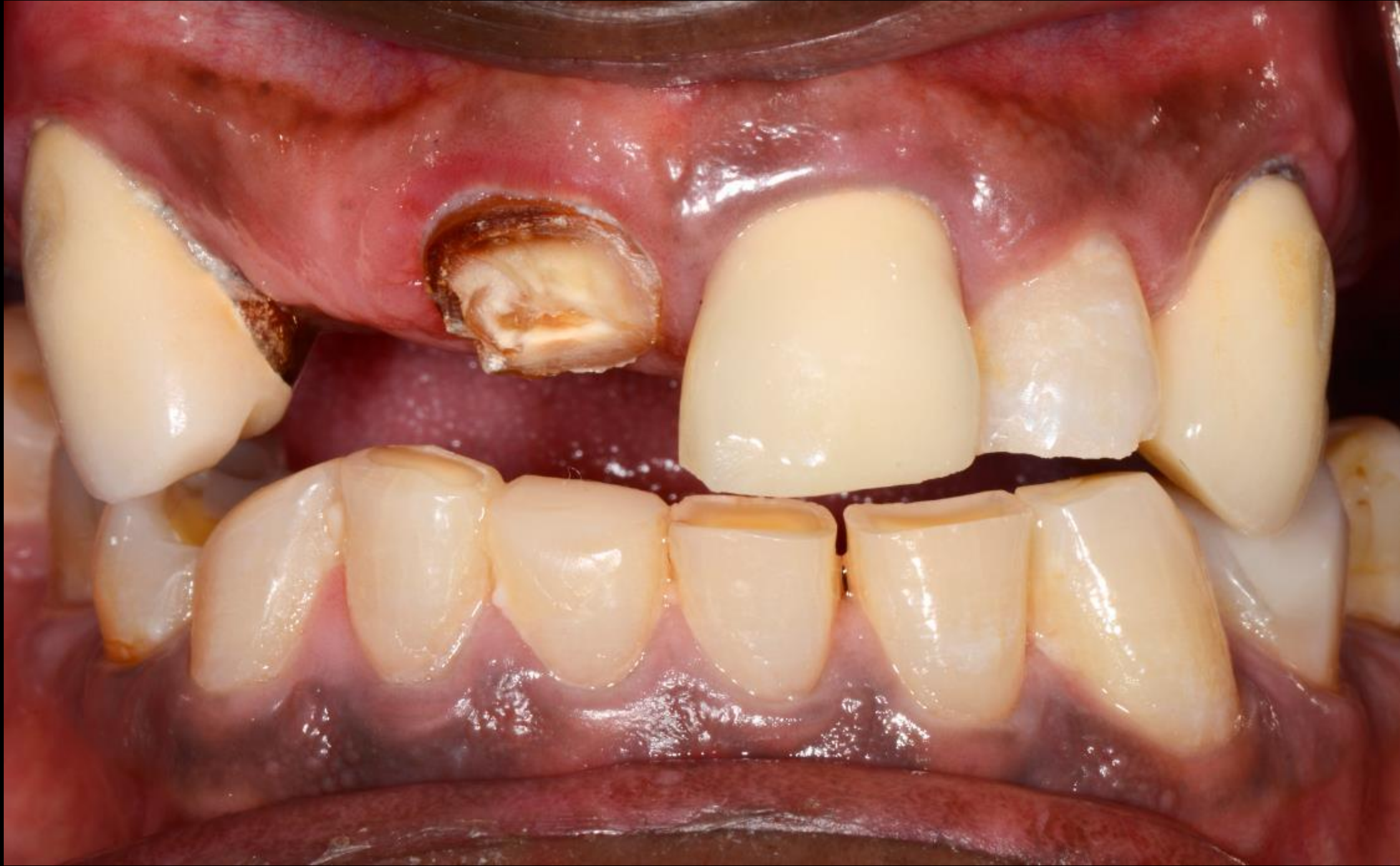





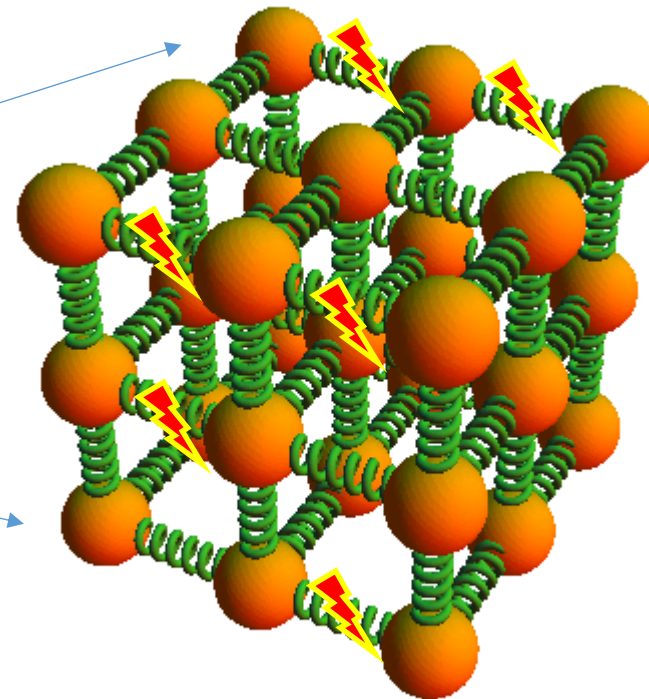
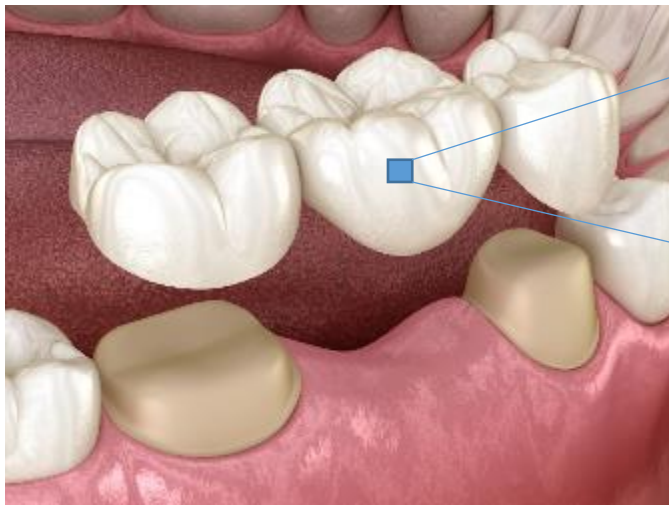




Basics of Solid Mechanics



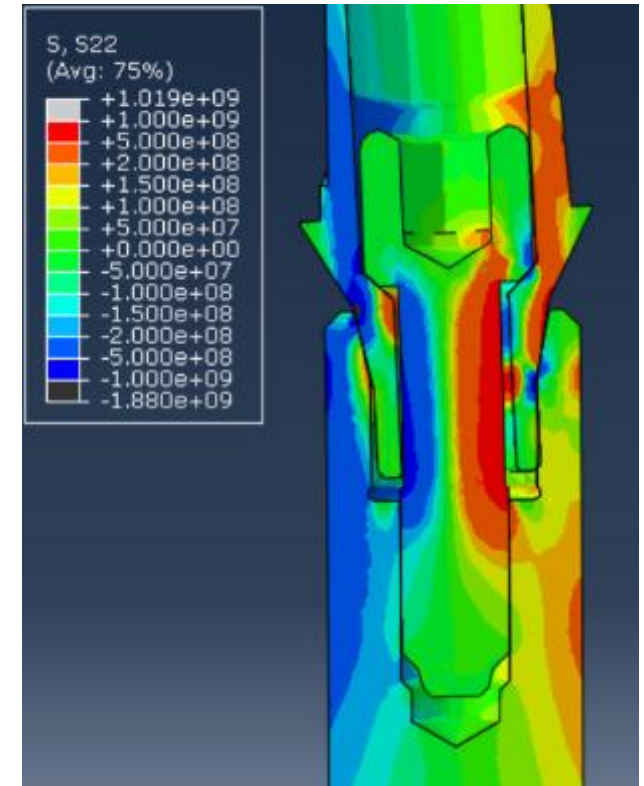
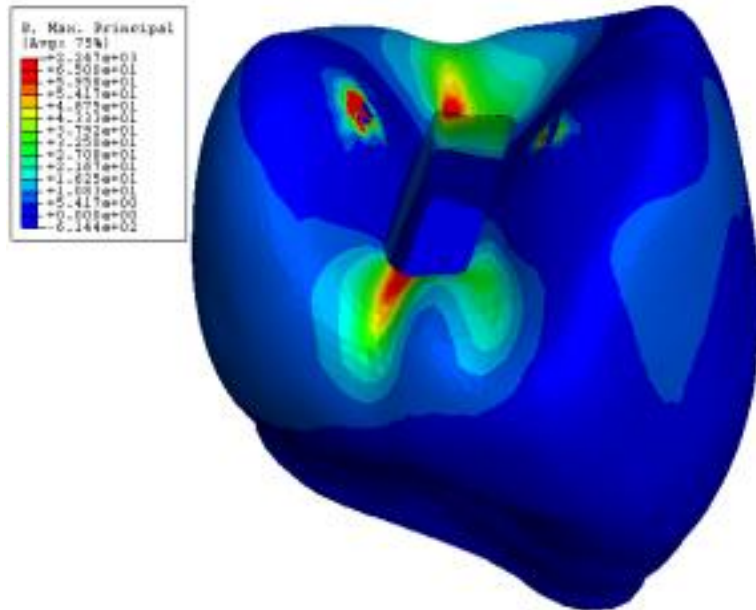
All solid structures can be considered as an assembly of many interconnected springs.



Stress/strain concentration

This occurs at

- Abrupt changes in geometry
- Mismatches in mechanical properties
- Concentrated loads



What is the percent of coronal volume removed in a conservative full porcelain crown preparation?

~3/4 Crown

All Ceramic
.8 Margin

All Ceramic
1 mm Margin

All Ceramic
1.4 mm Margin



53.0

70.4

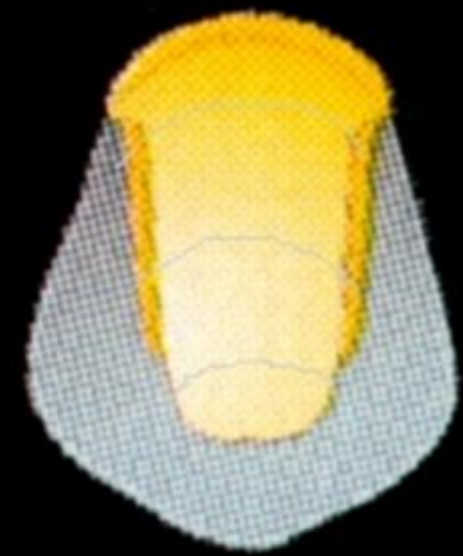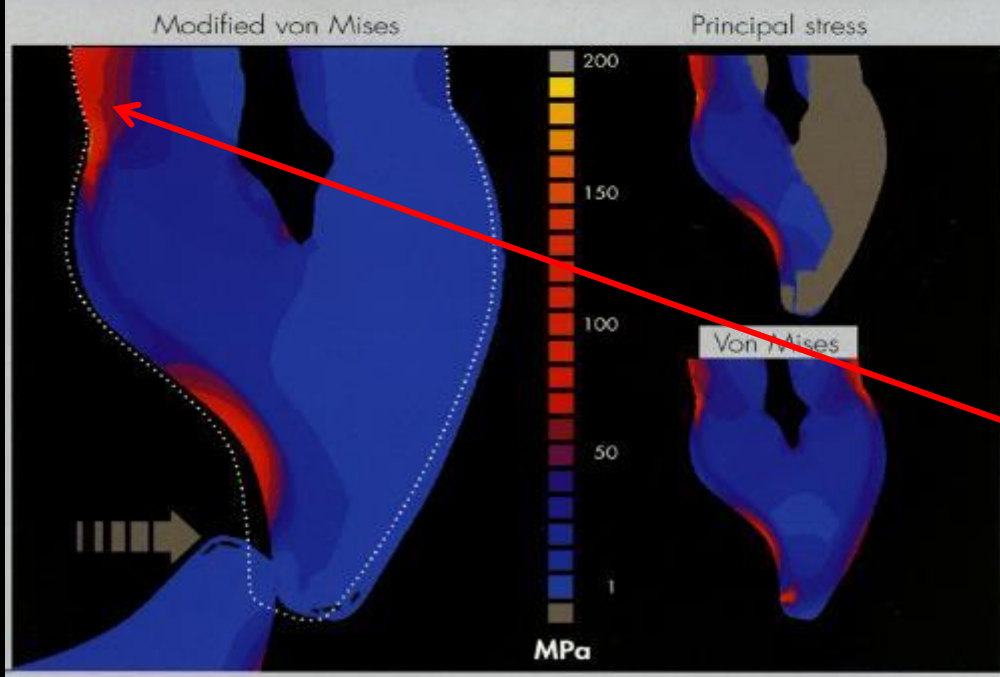
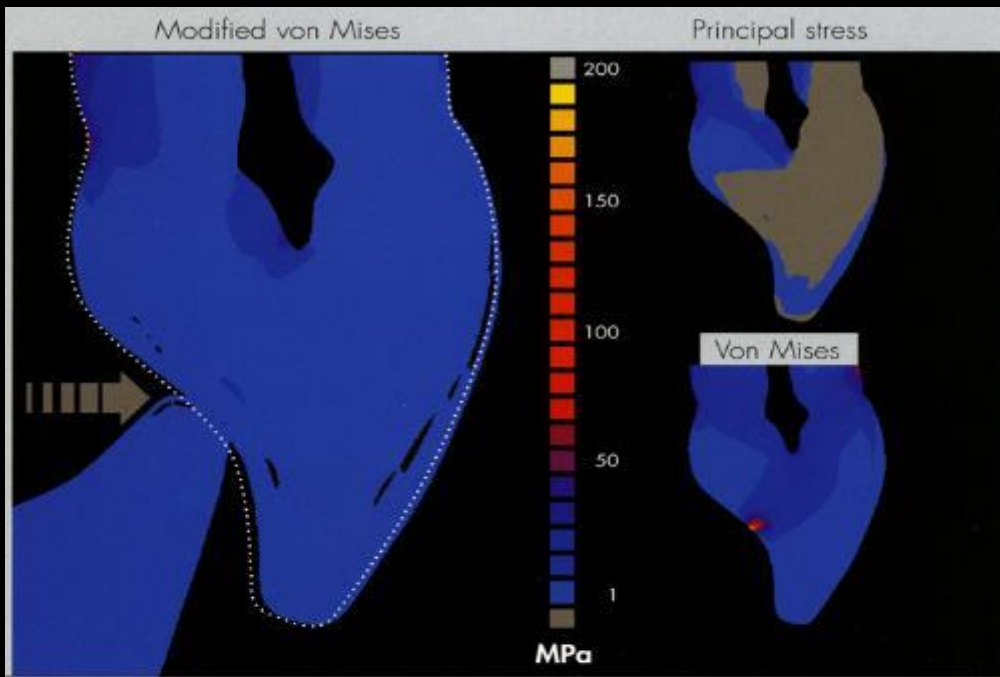
74.1

75.9

34 *

Edelhoff D, Sorensen JA.

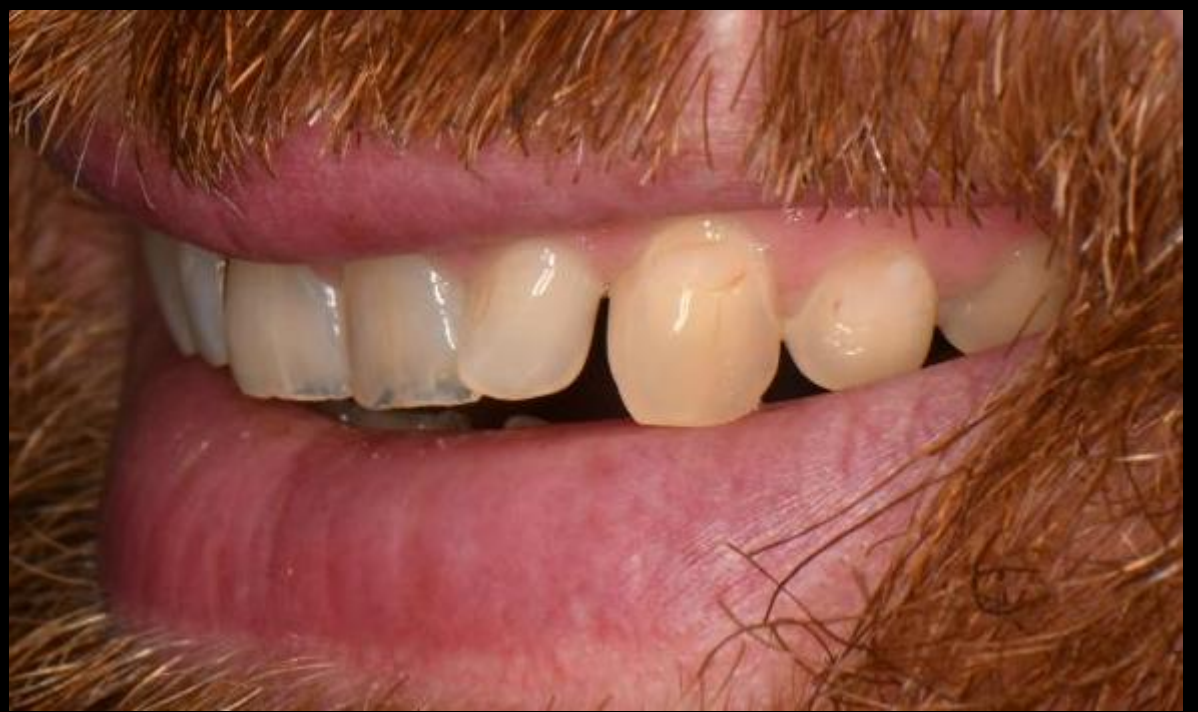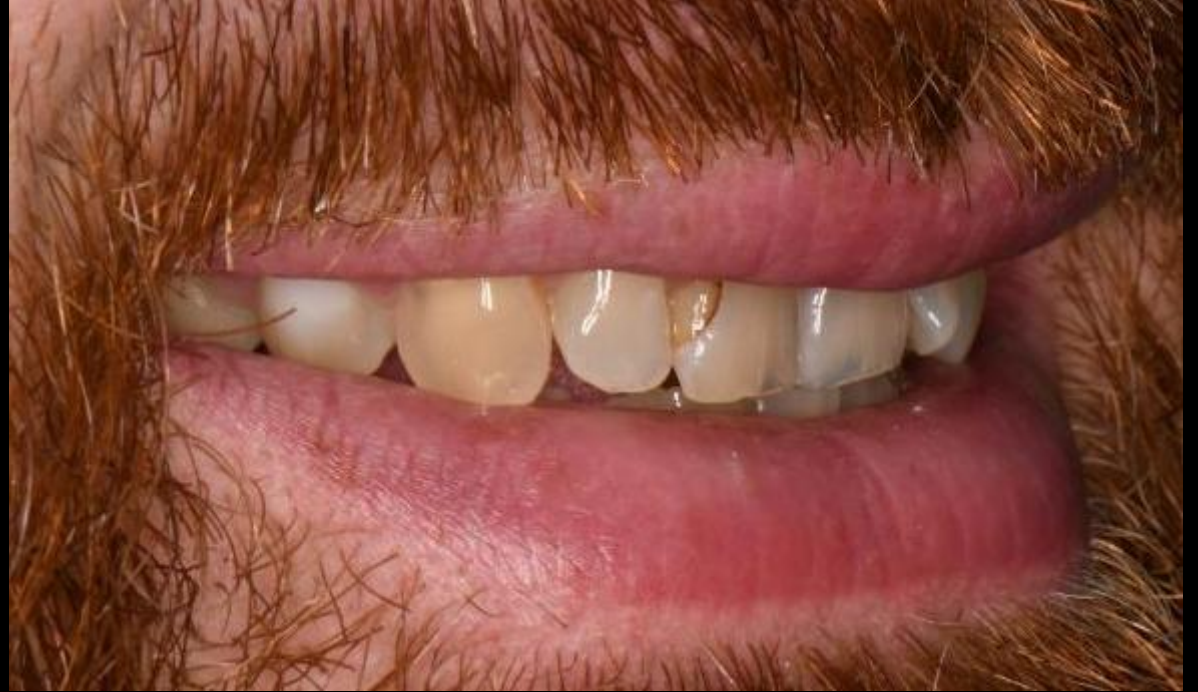1 Structure Removal Associated with Various Preparation Designs for Posterior Teeth.
Int J Periodontics Restorative Dent 2002; vol 22; 3: 240-249.

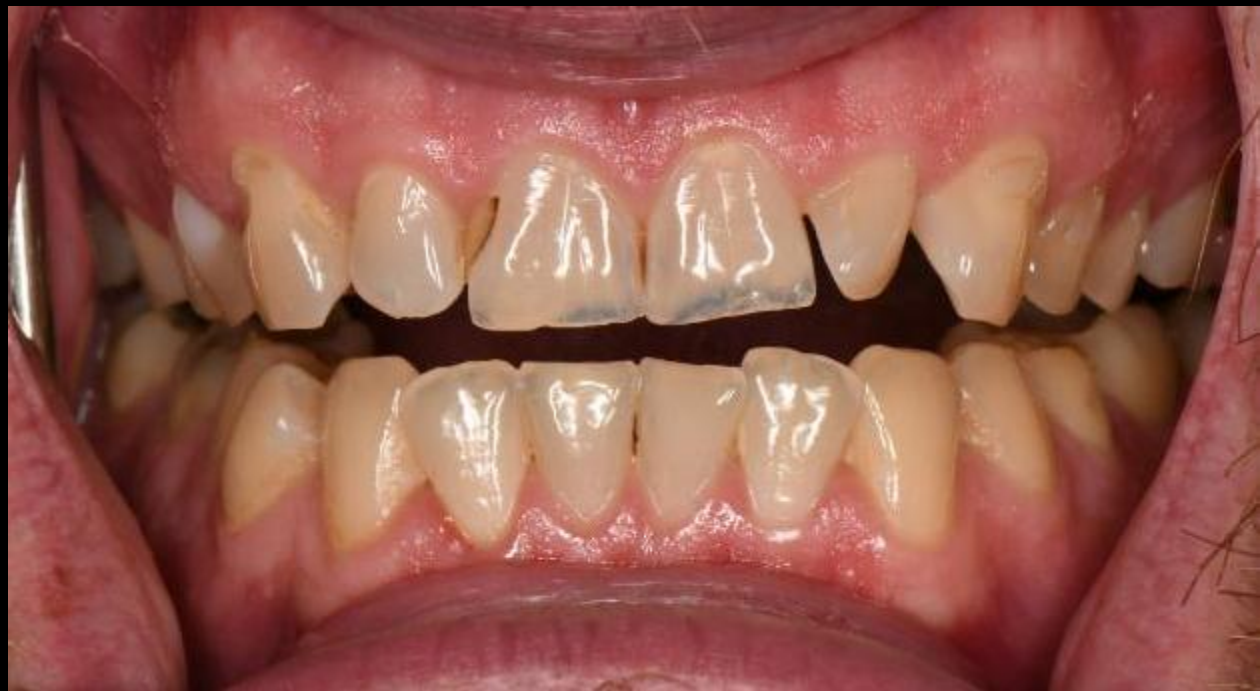
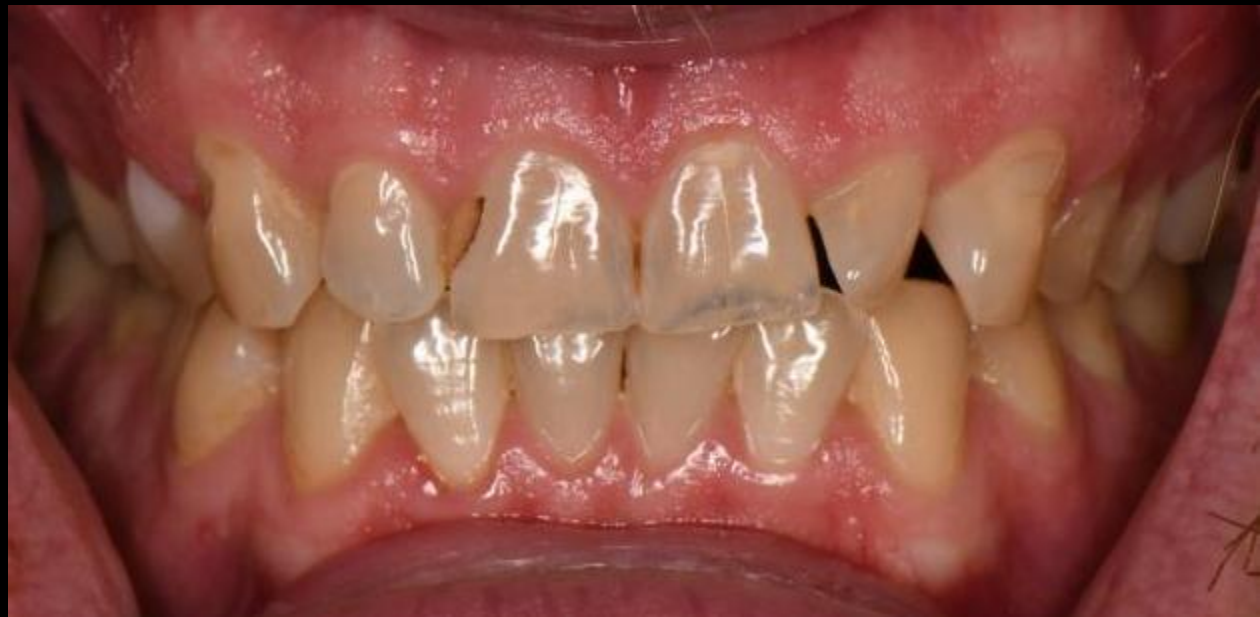
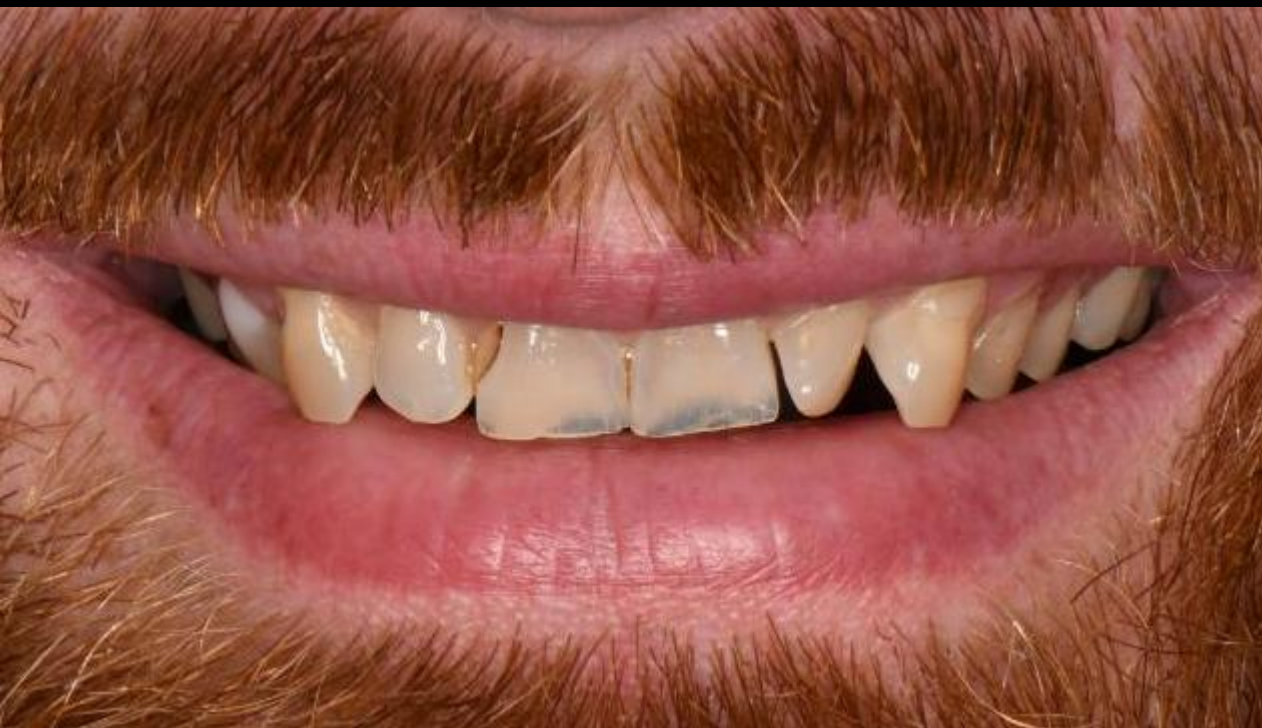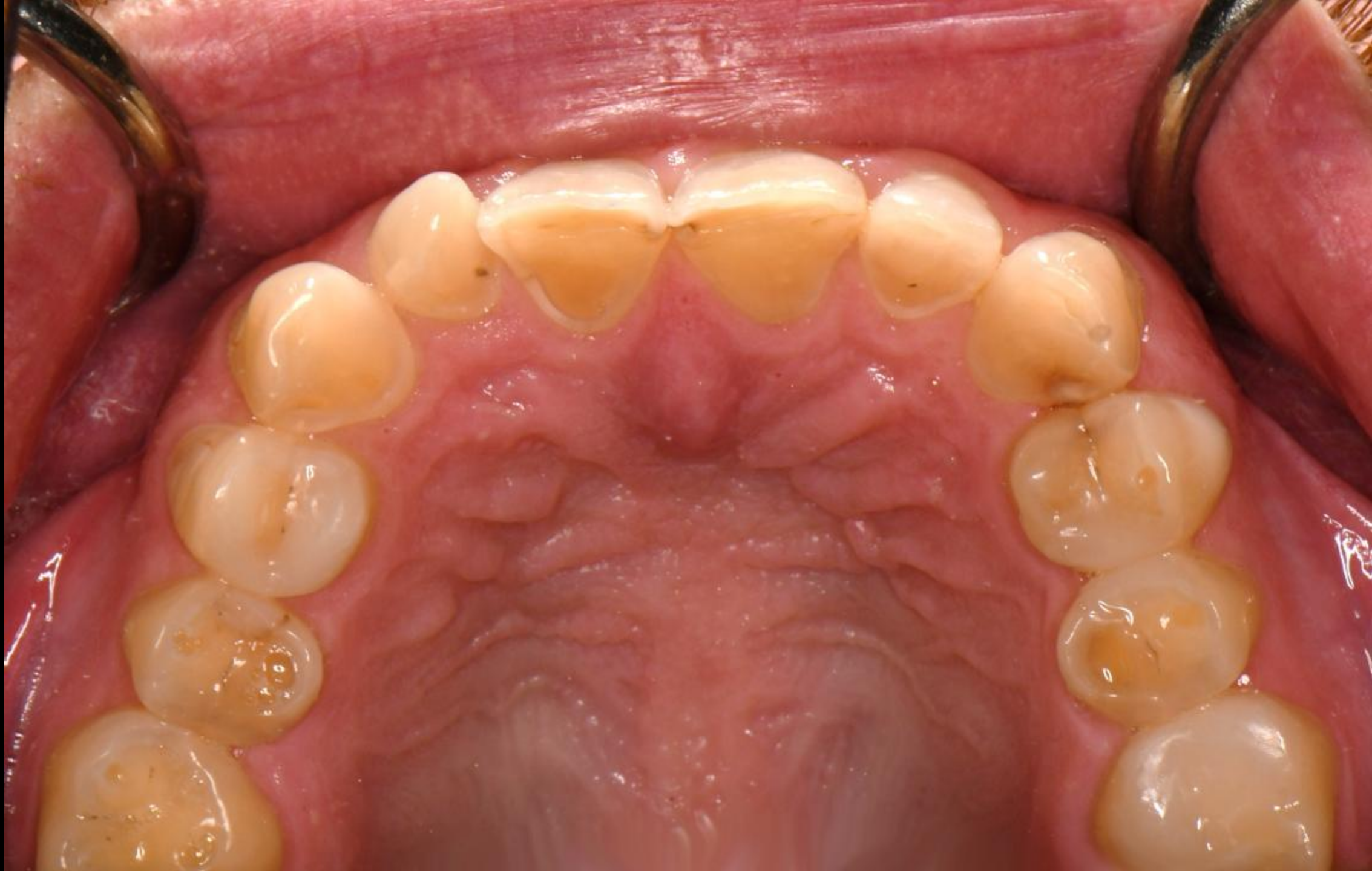75.9% volume gone + stress concentration

Is monolithic injection molded composite a viable alternative to full ceramic crowns in some cases?

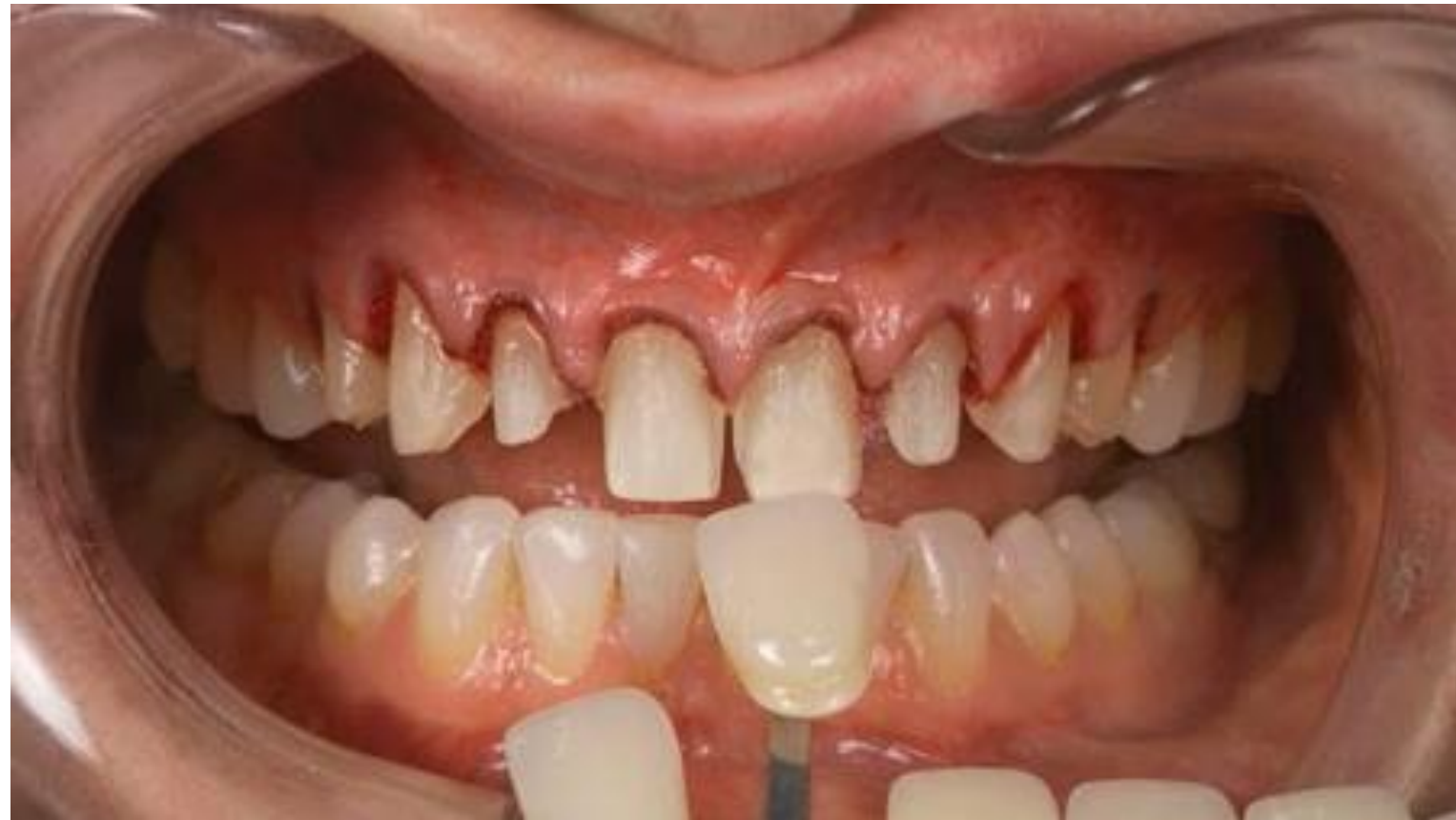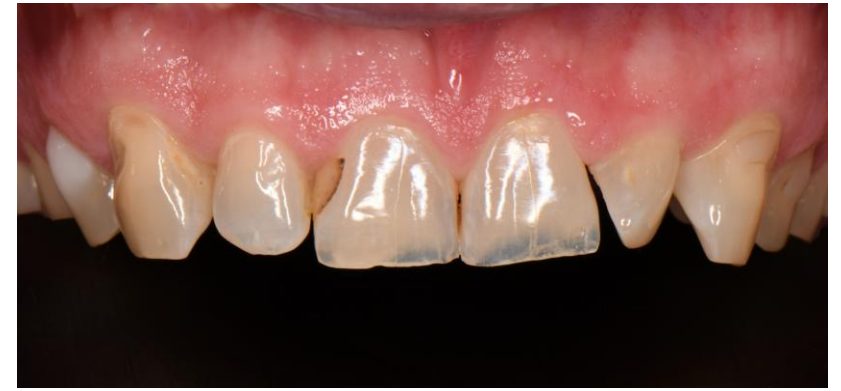You be the judge of that





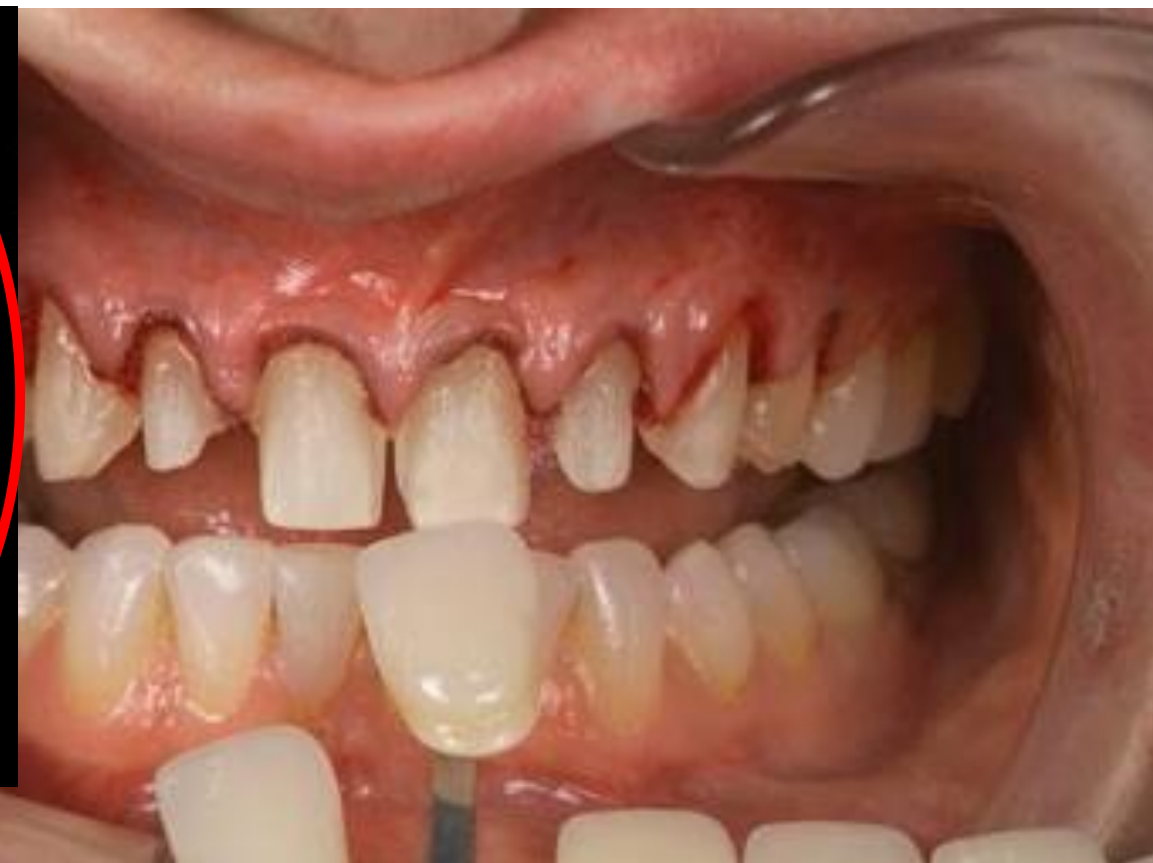
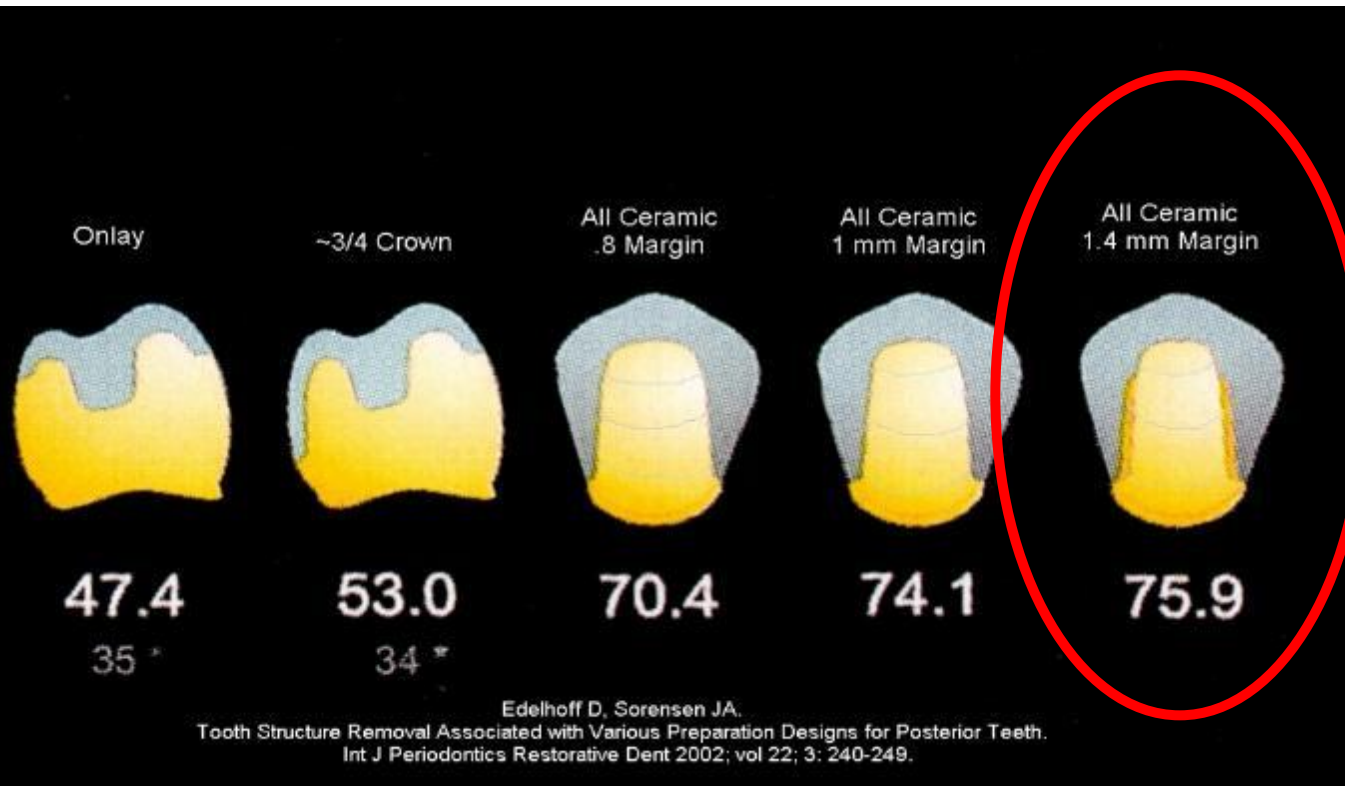
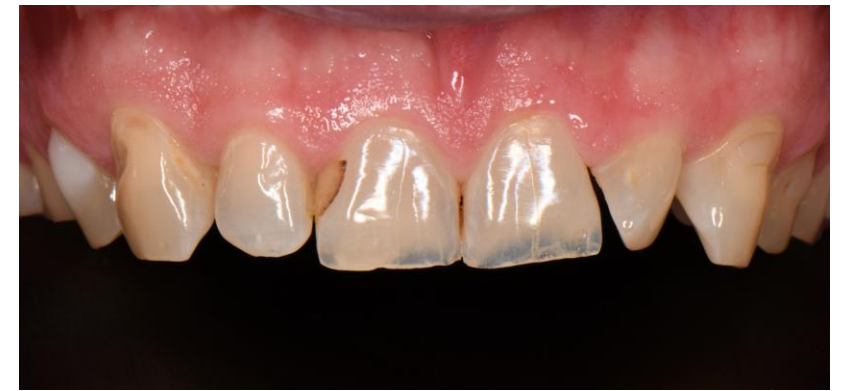What percentage of the tooth is removed for a conservative crown prep?

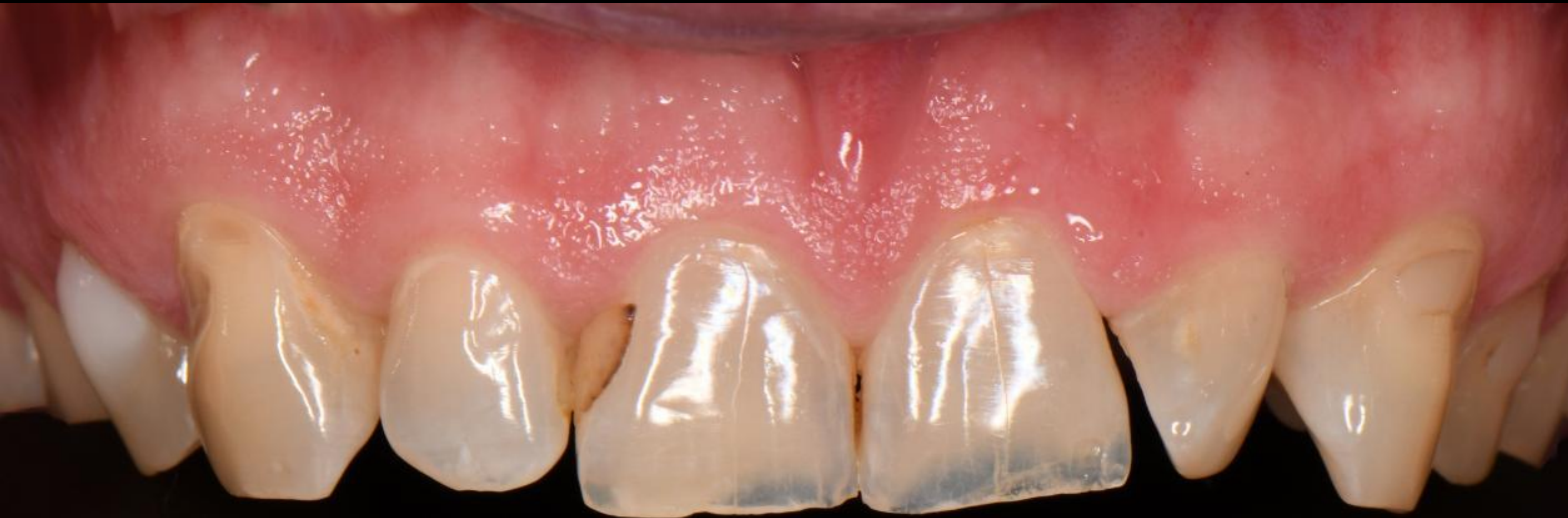

Source: Google Images

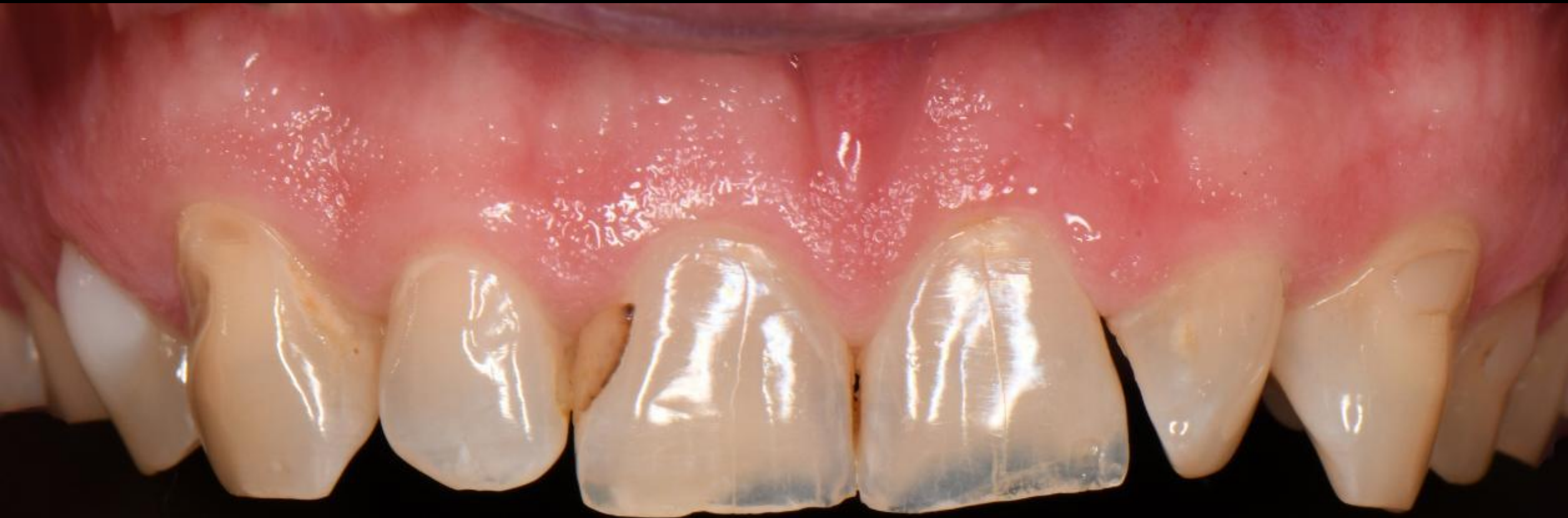What percentage of the tooth is removed for a conservative crown prep?



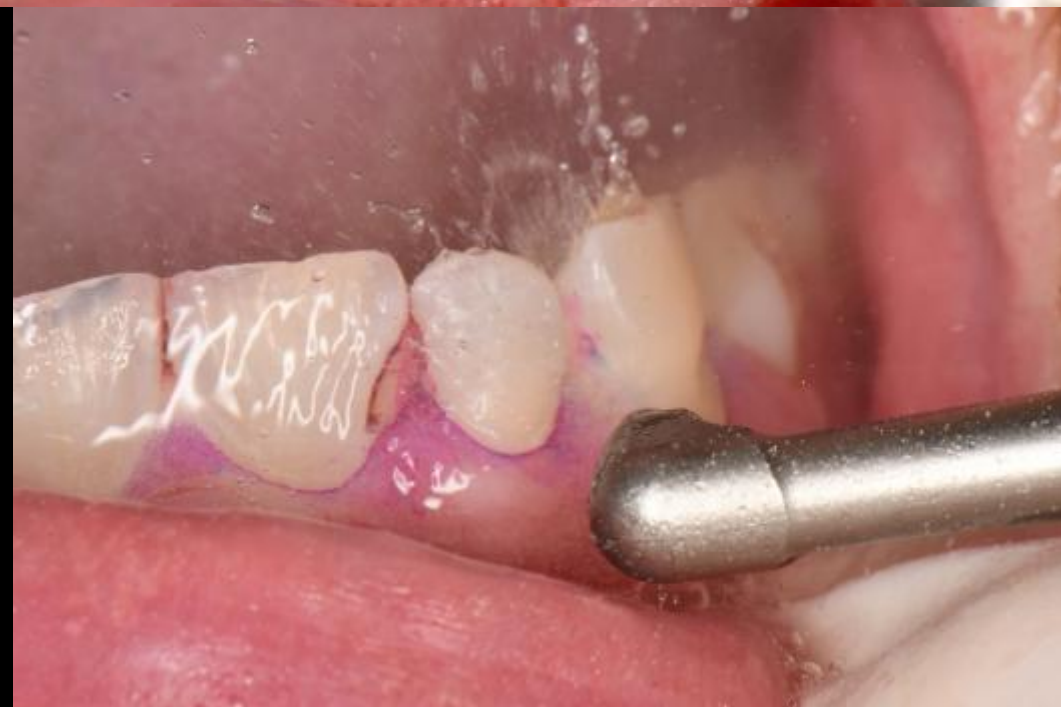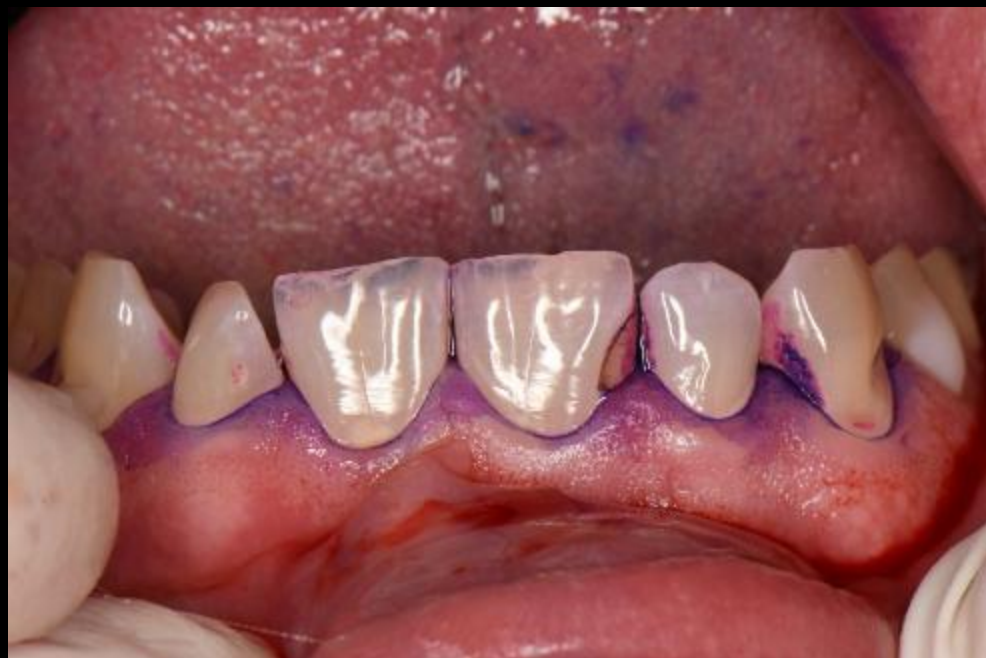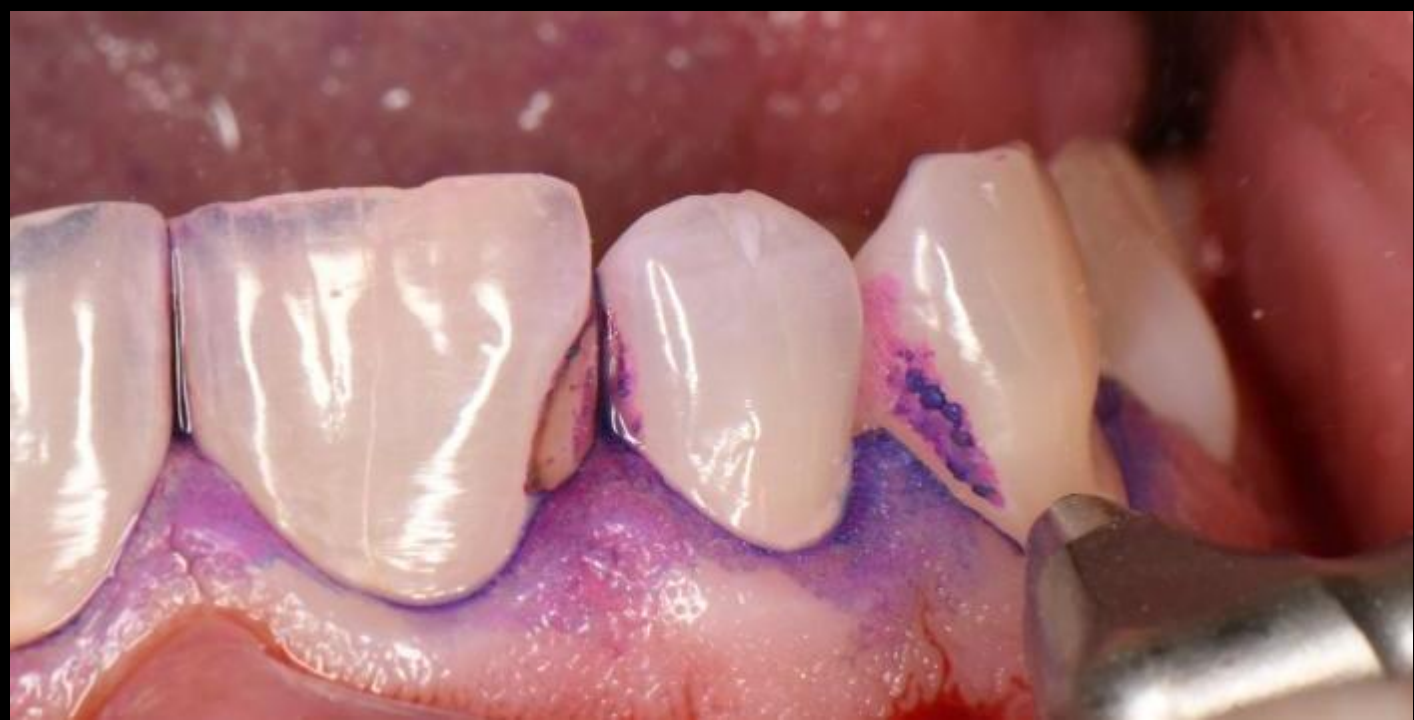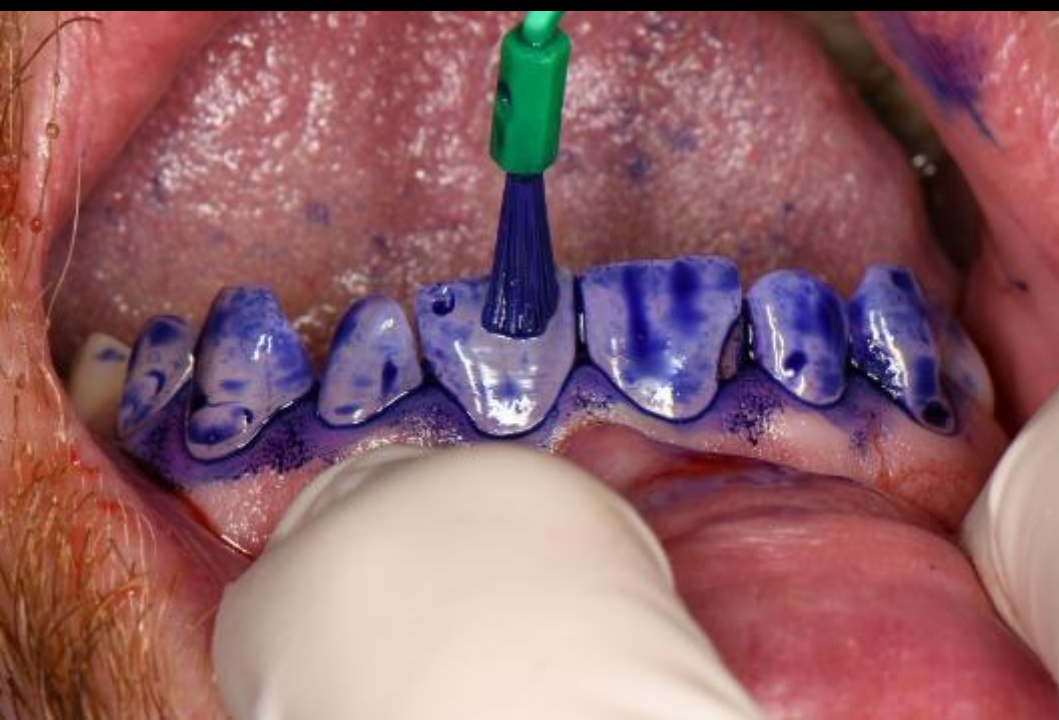Source: Google Images

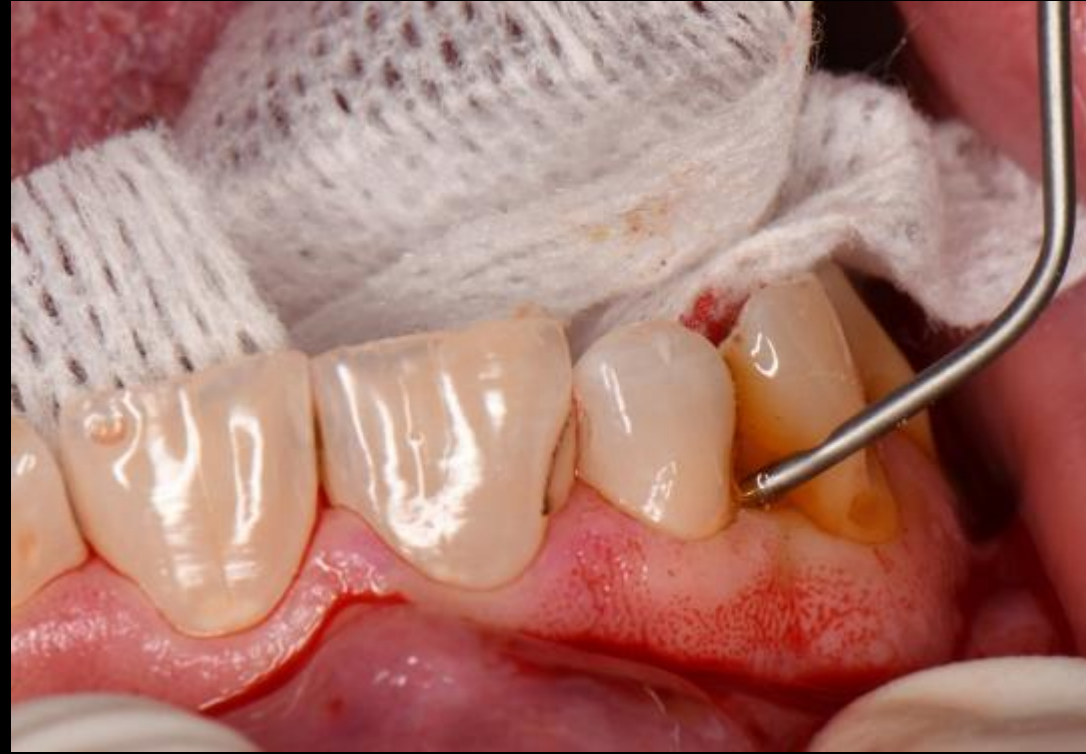
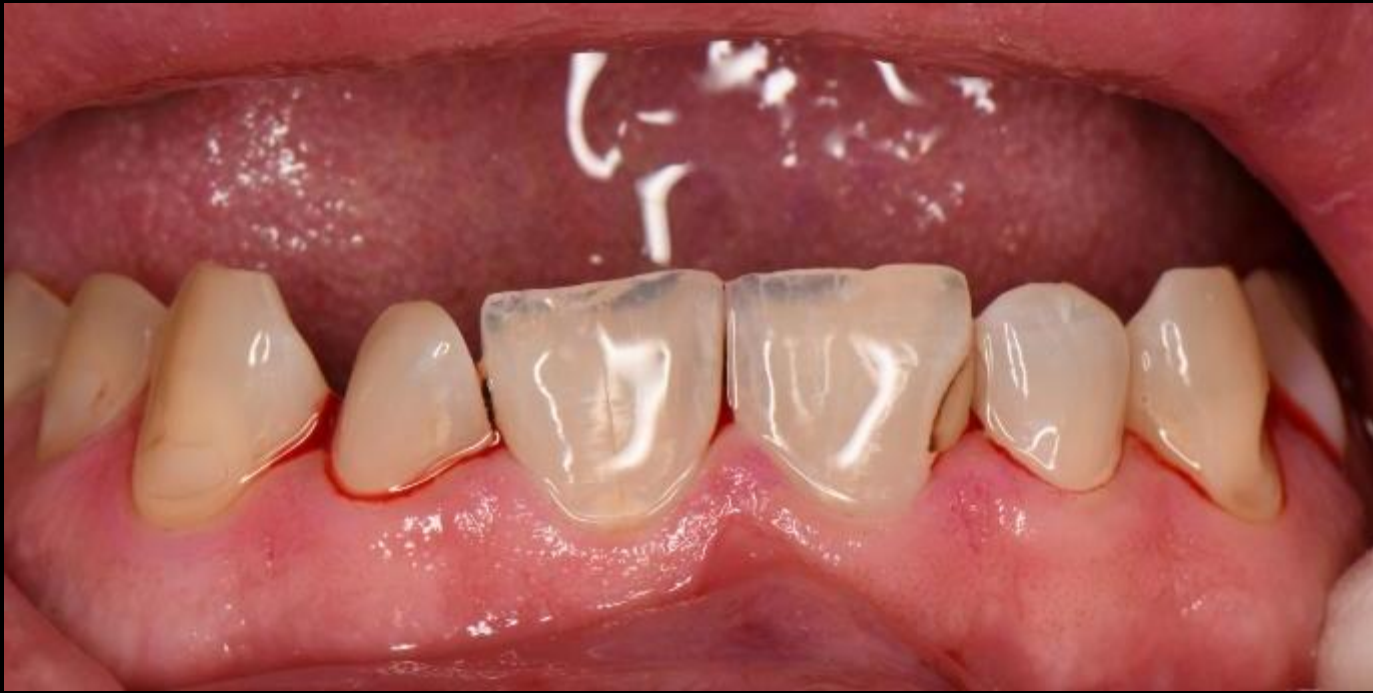
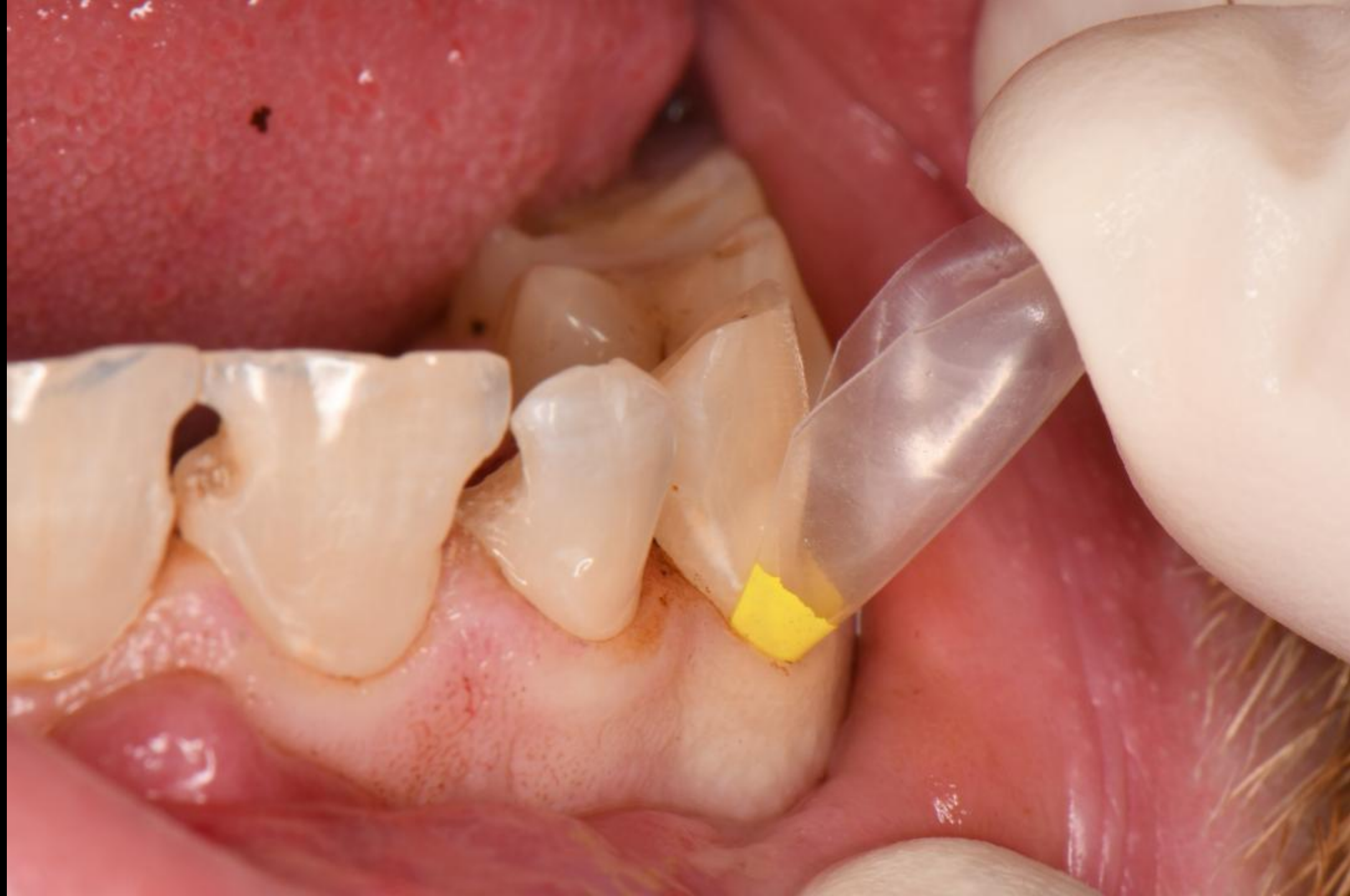Wouldn't it be nice to preserve nearly all the healthy tooth structure and at the same time completely rejuvenate this guy's smile?

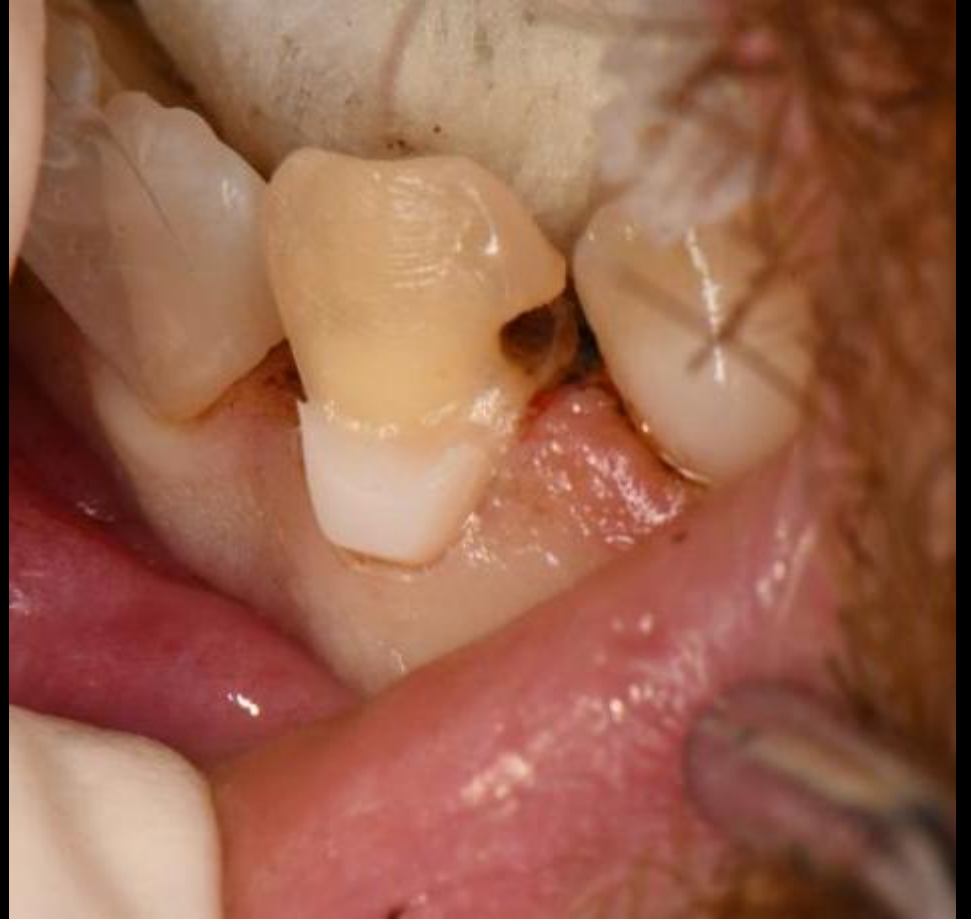
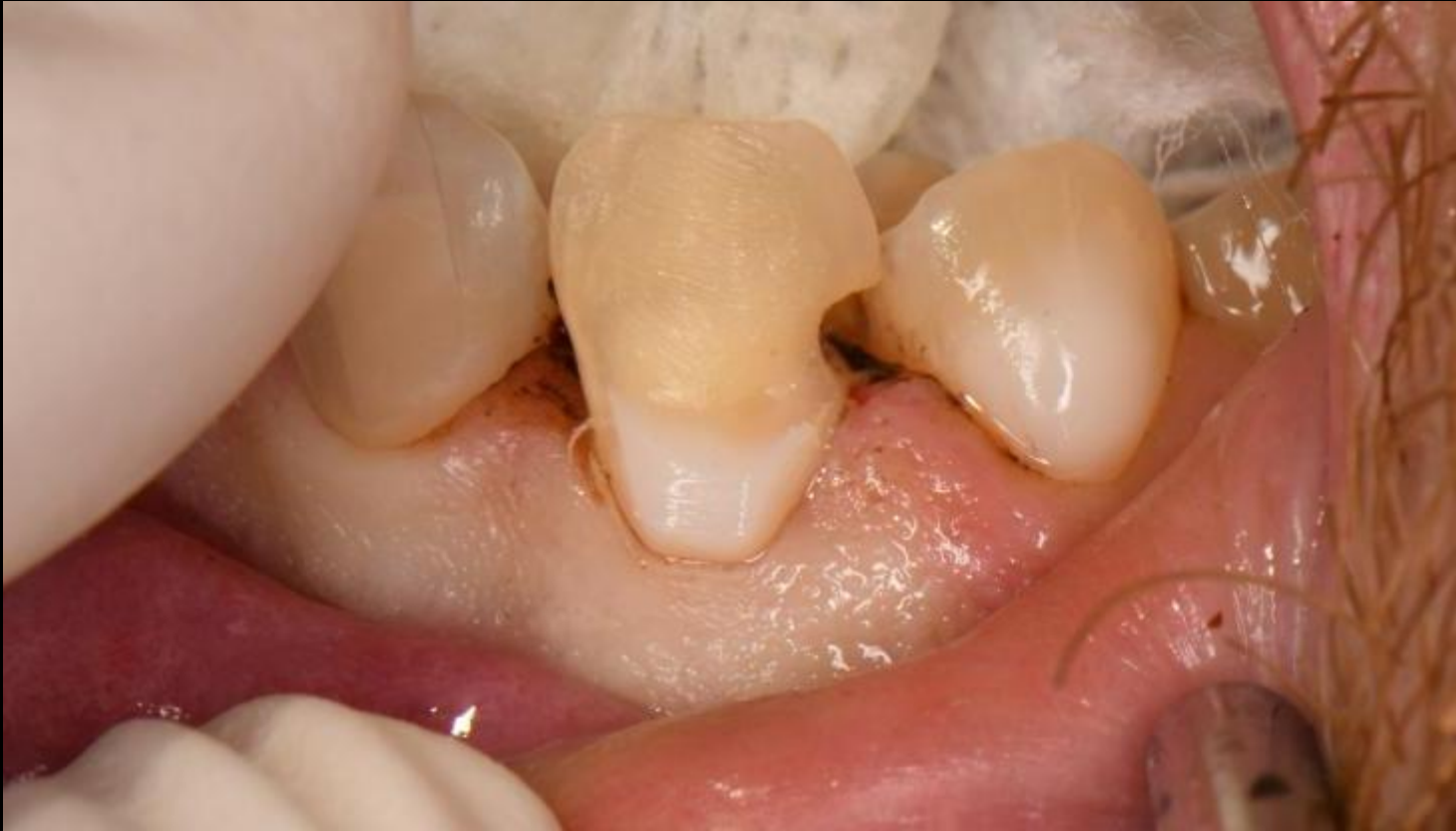
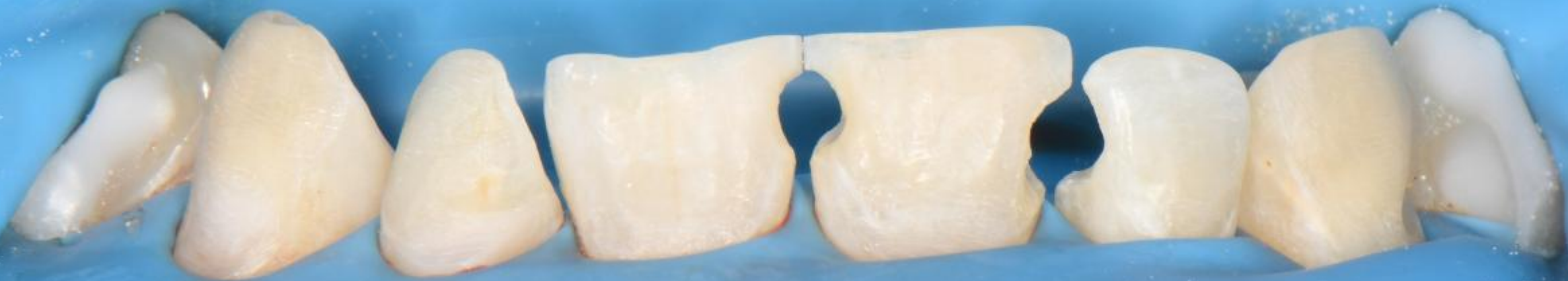Simplified Smile Design!

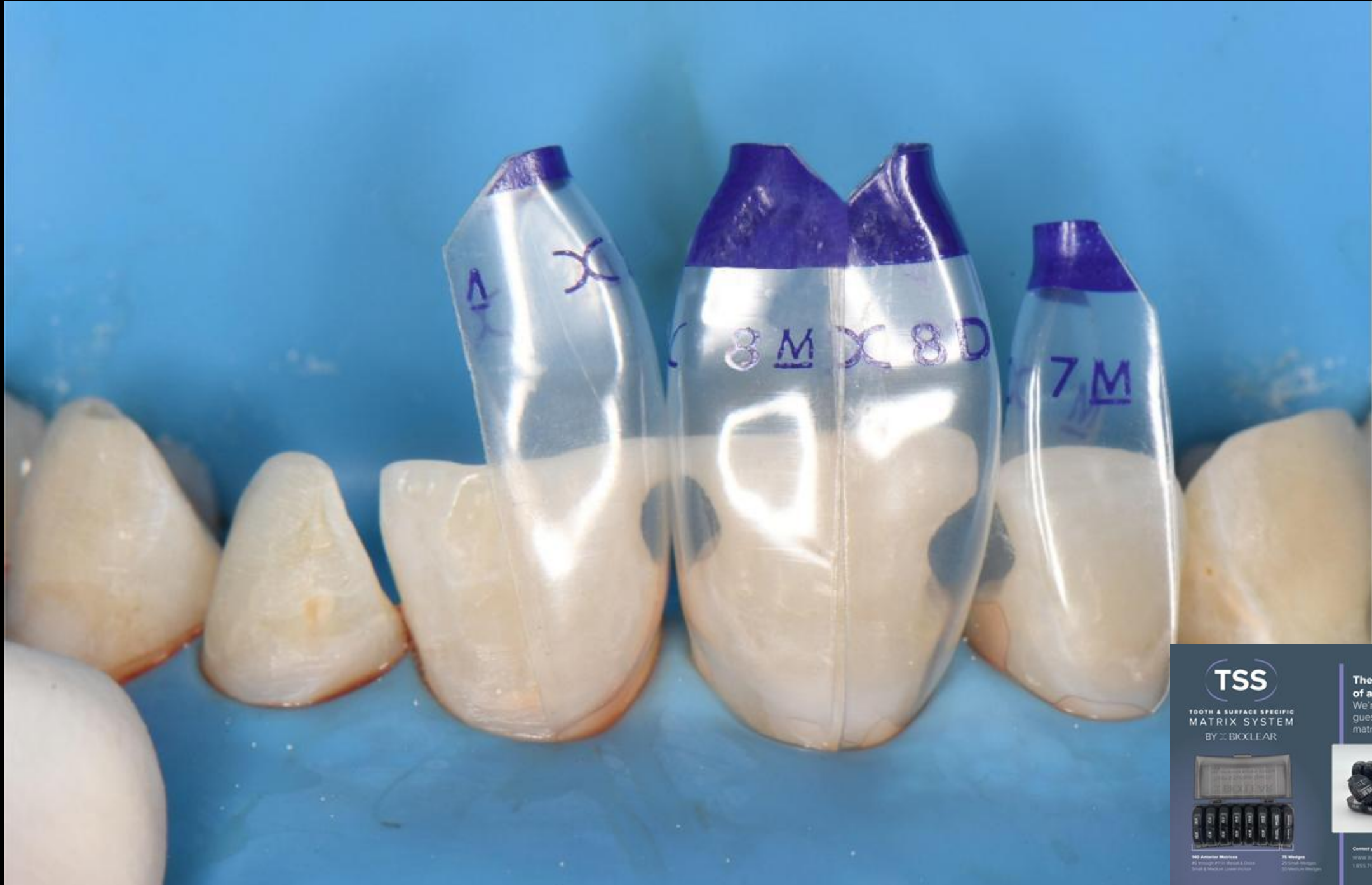











TSS

TOOTH & SURFACE SPECIFIC
MATRIX SYSTEM
BY  BIOCLEAR



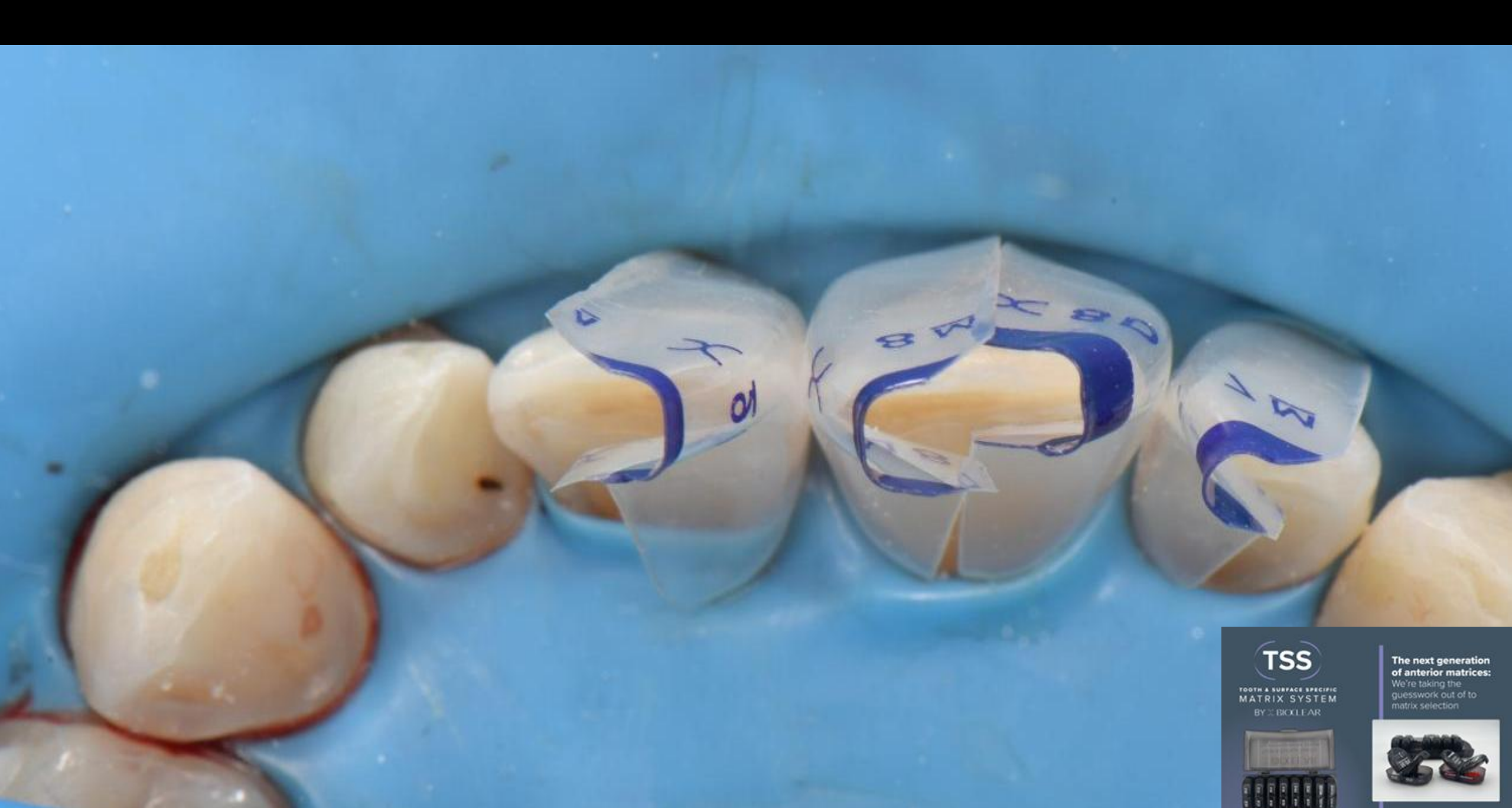140 Anterior Matrices
45 Smooth Anterior Matrix & Crown
Small & Medium Laser Notched

75 Wedges
25 Small Wedges
50 Medium Wedges

**The next generation
of anterior matrices:**
We're taking the
guesswork out of to
matrix selection



Contact your BioClear Sales Rep to Pre-Order
WWW.BIOCLEARMATRIX.COM
1.855.712.5427



TSS

TOOTH & SURFACE SPECIFIC
MATRIX SYSTEM
BY BIOCLEAR



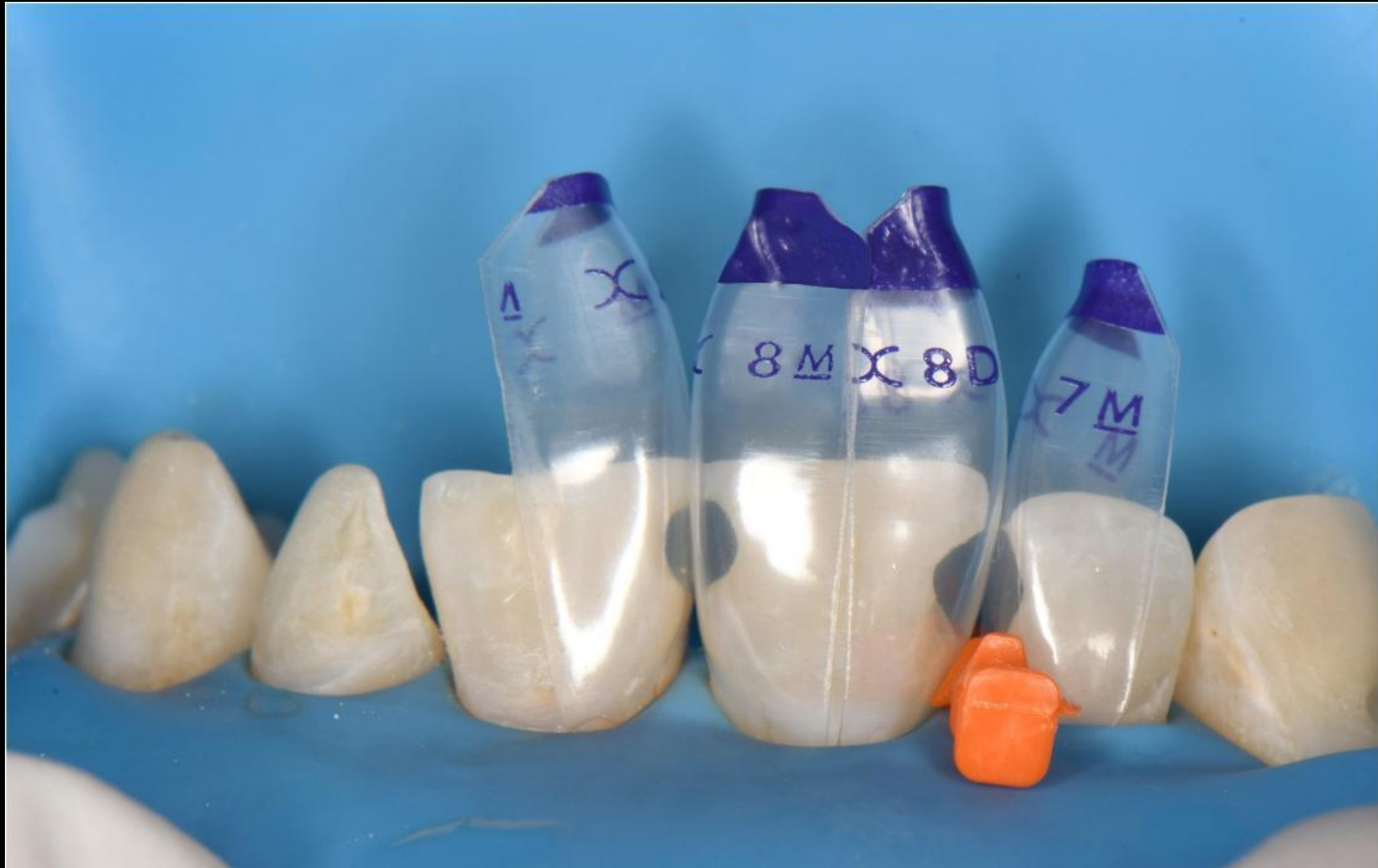100 American Matrices
100 Standard 1/2" Standard 2" Colors
Standard & Non-Standard Colors Available

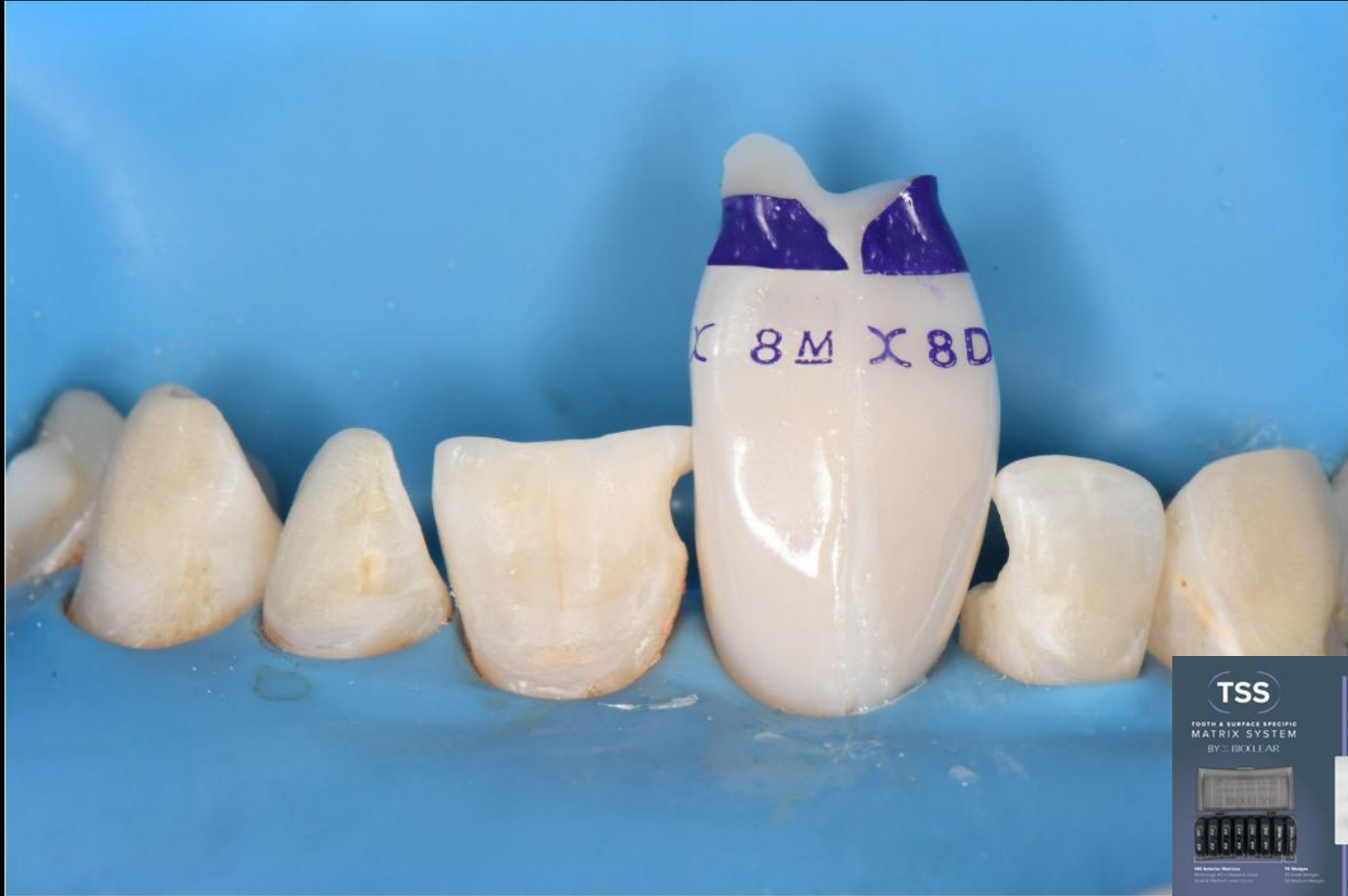1/4" Springs
1/4" Spring Springs
1/4" Standard Springs

**The next generation
of anterior matrices:**
We're taking the
guesswork out of
matrix selection



Contact your Bioclear Sales Rep to Pre-Order
WWW.BIOCLEARMATRIX.COM
1 800 770 5277





TSS

TOOTH & SURFACE SPECIFIC
MATRIX SYSTEM
BY BIOCLEAR



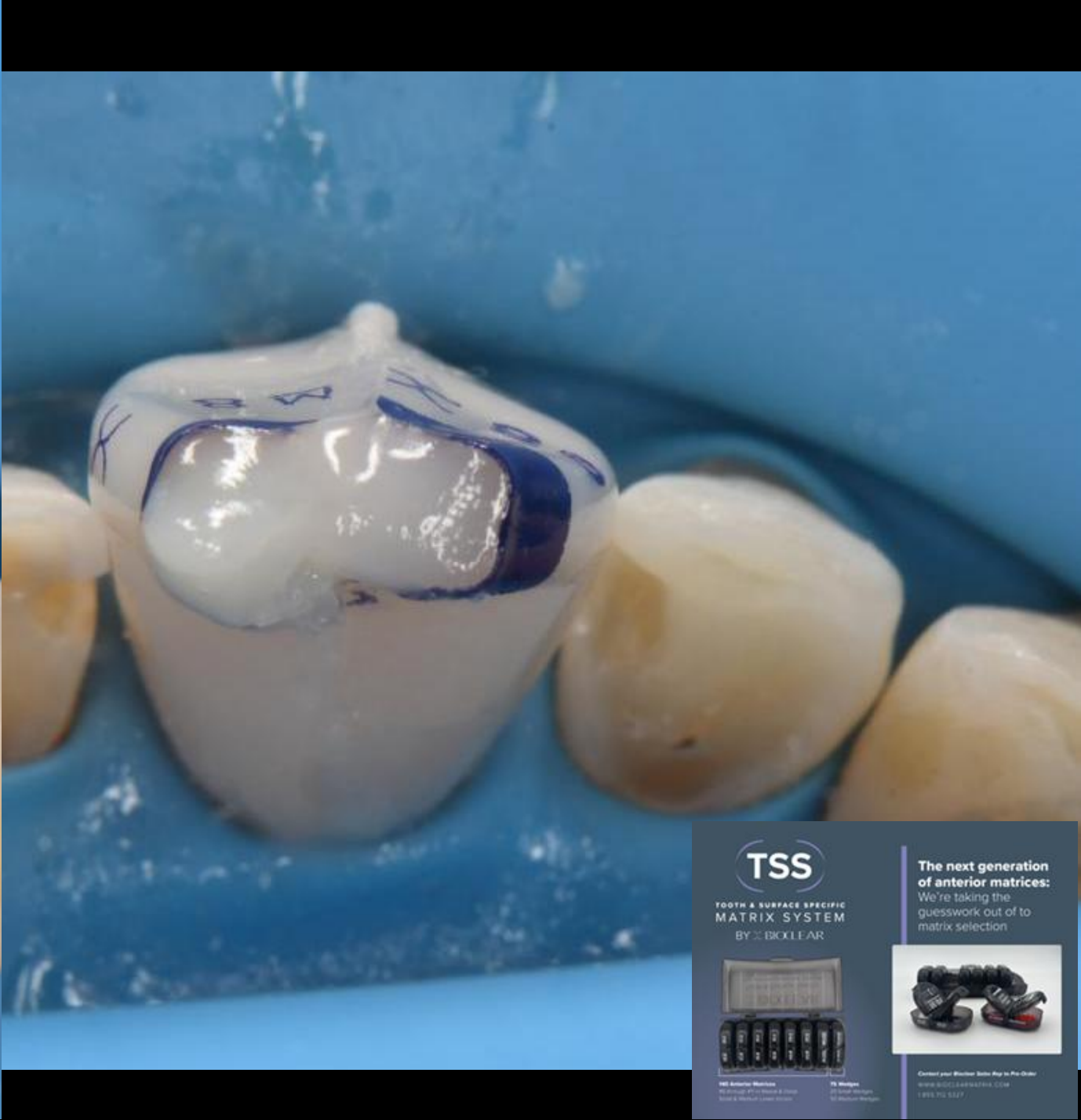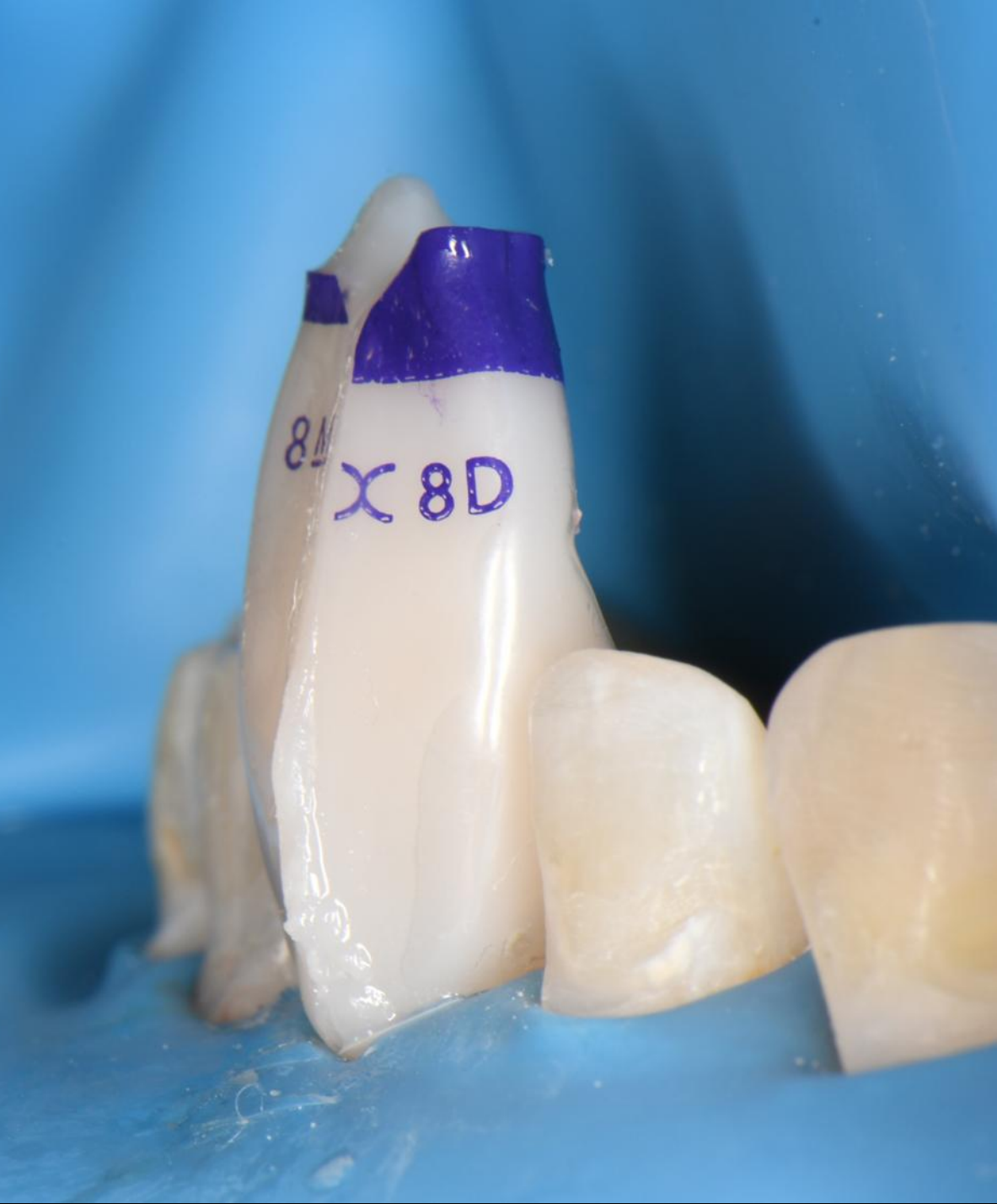100 Anterior Matrices
100 Anterior & Premolar & Canine
100 Anterior & Premolar & Canine

75 Molars
100 Molar & Premolar
100 Molar & Premolar

**The next generation
of anterior matrices:**
We're taking the
guesswork out of
matrix selection



Contact your Bioracer Sales Rep to Pre-Order
www.bioclearmatrix.com
1 800 750 5127



TSS

TOOTH & SURFACE SPECIFIC
MATRIX SYSTEM
BY BIOCLEAR

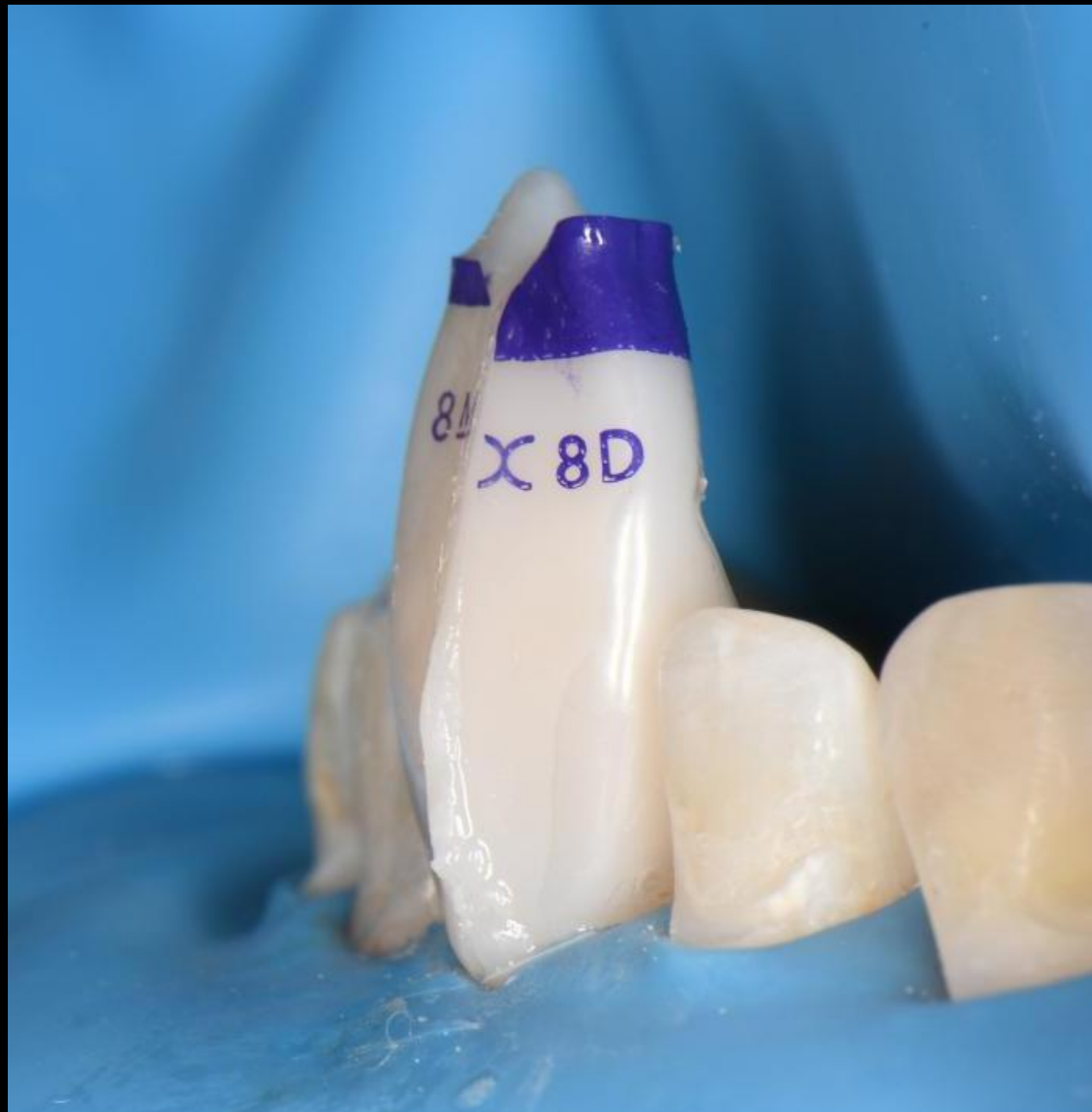

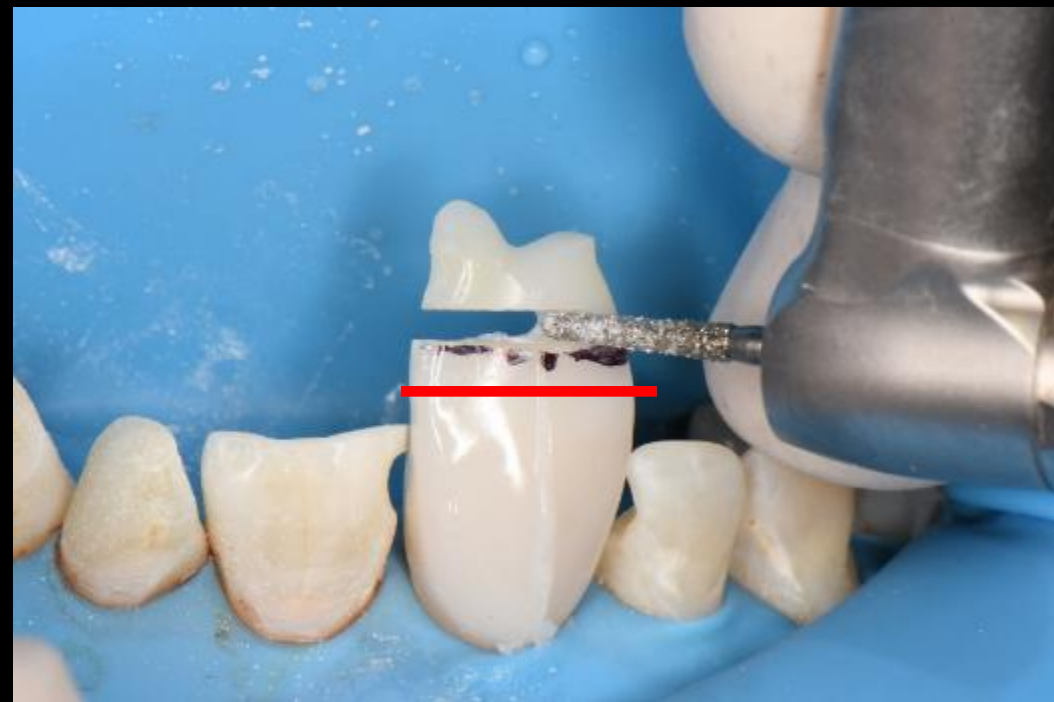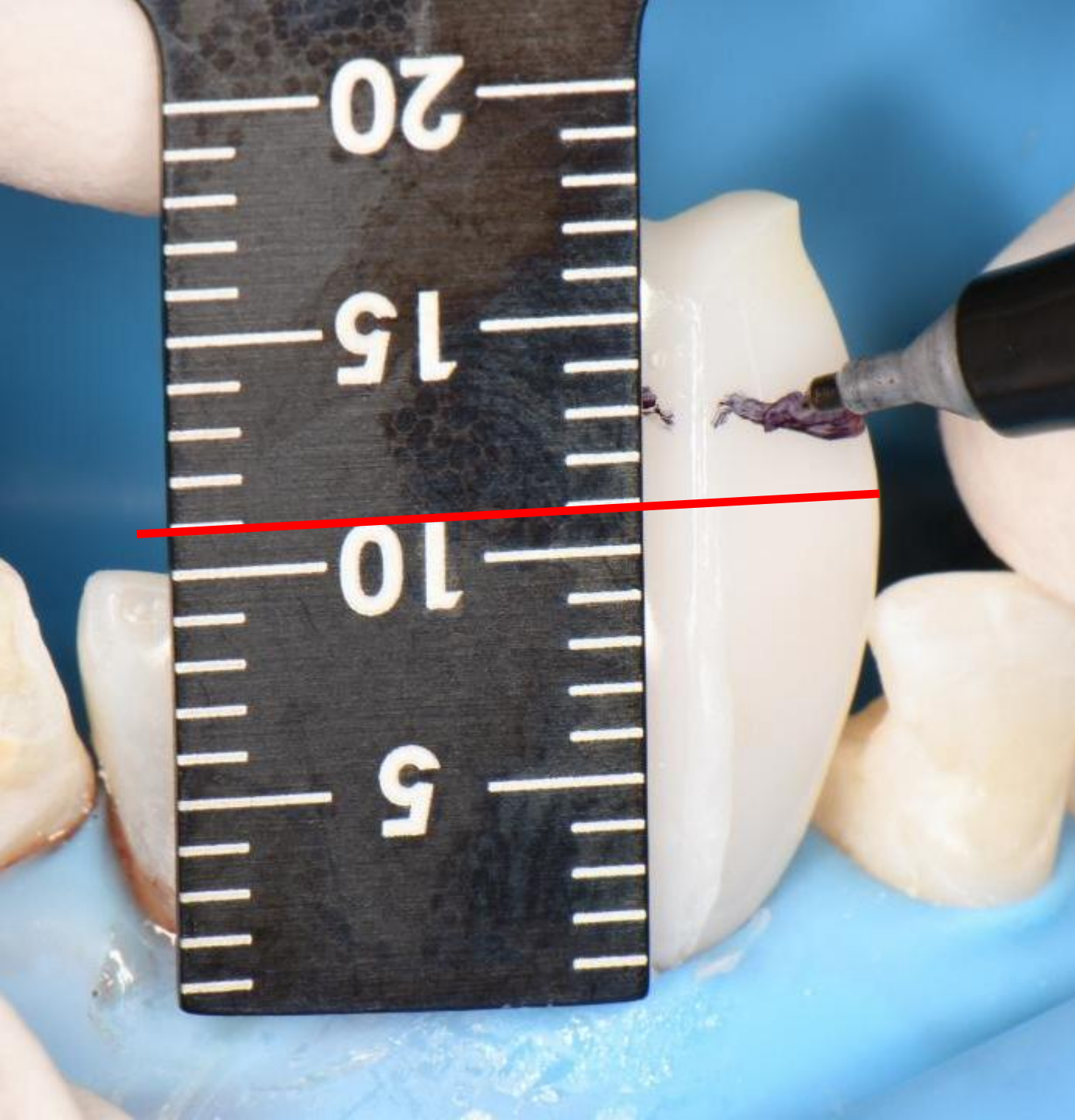
100 Anterior Matrices
100 Wedges
100 Anterior Matrices
100 Wedges

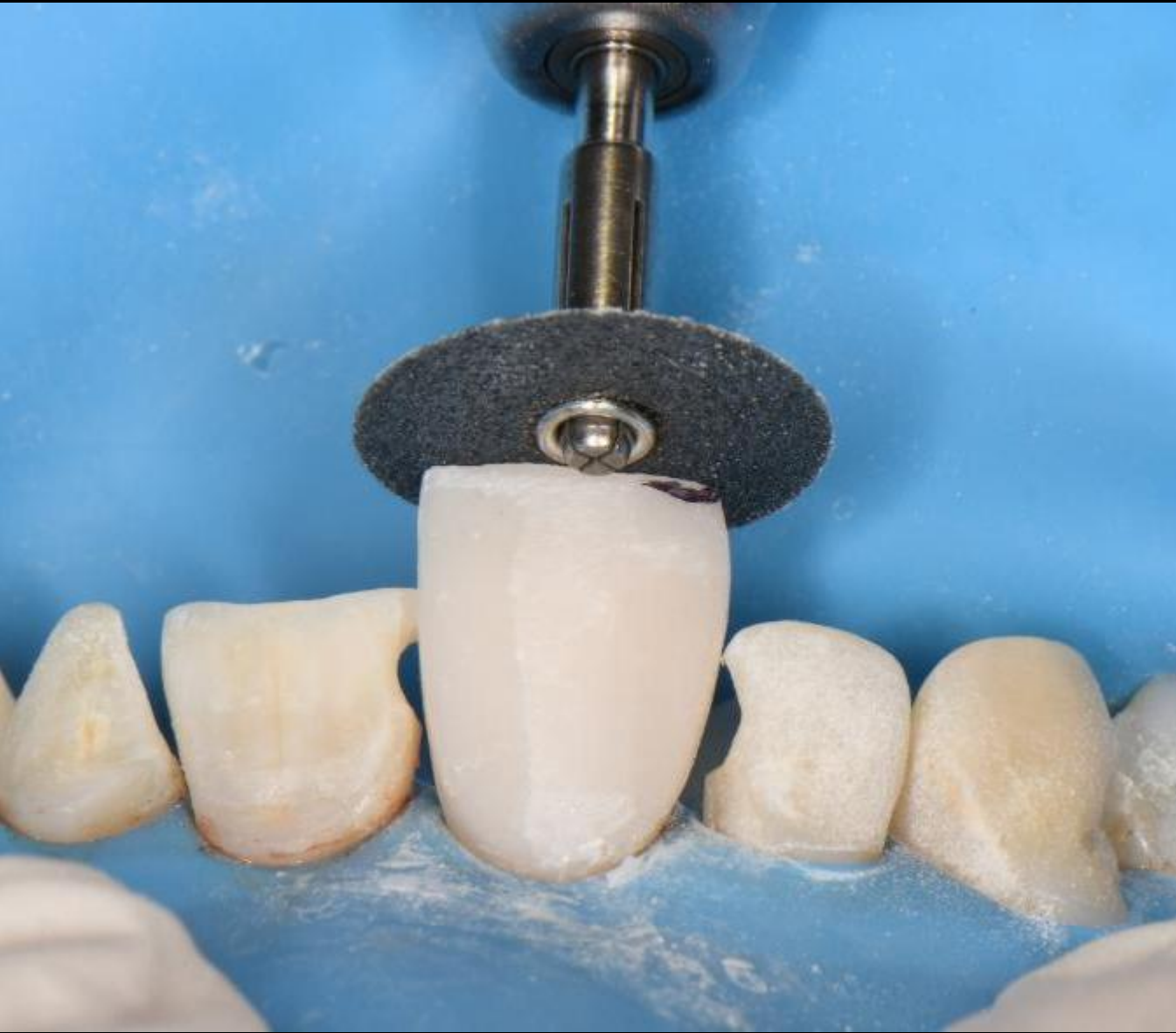**The next generation
of anterior matrices:**
We're taking the
guesswork out of to
matrix selection

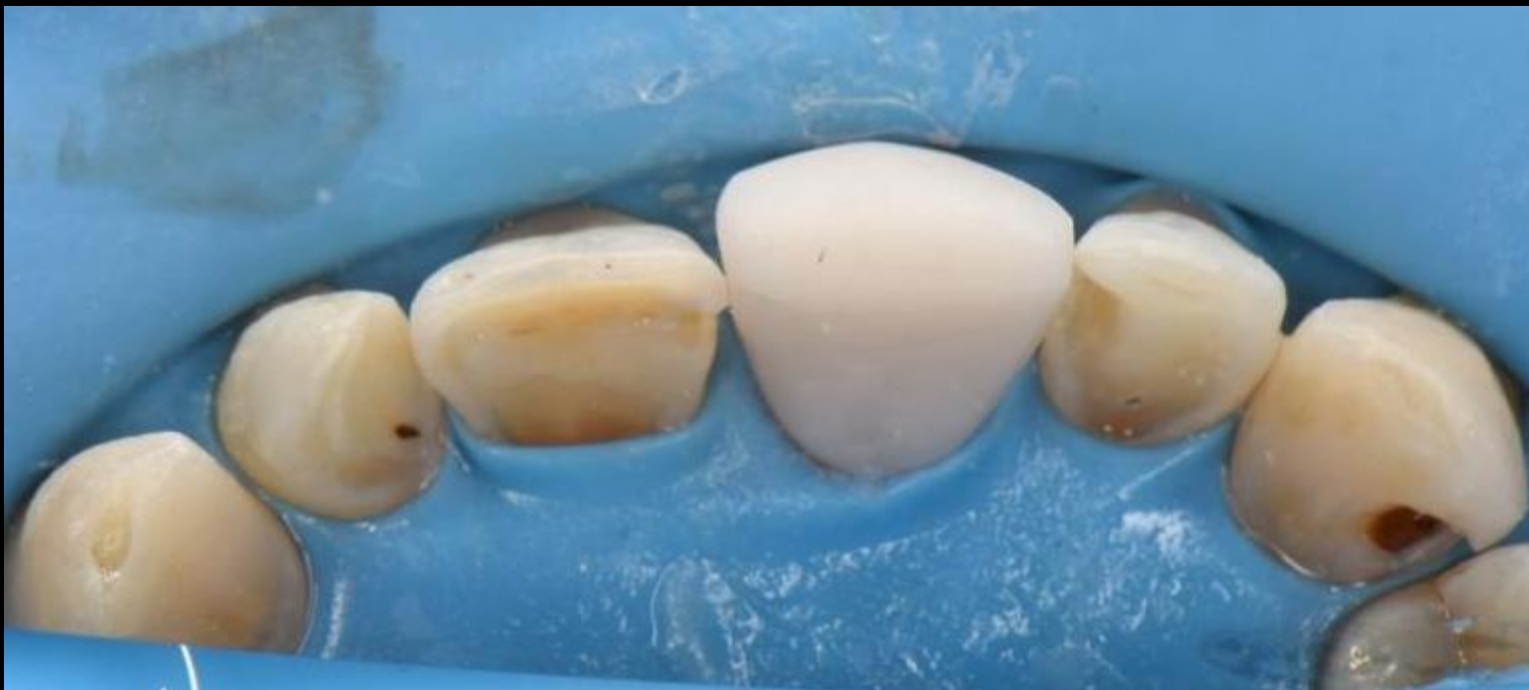
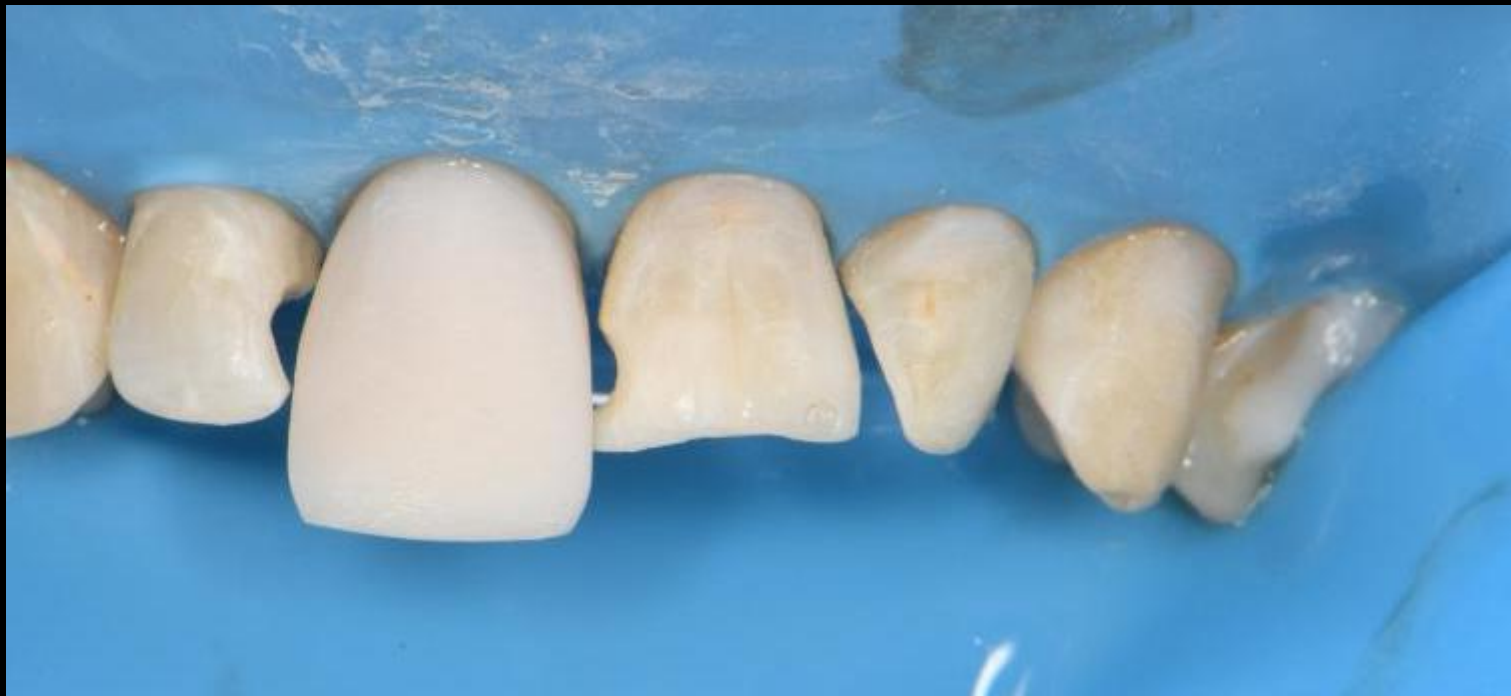
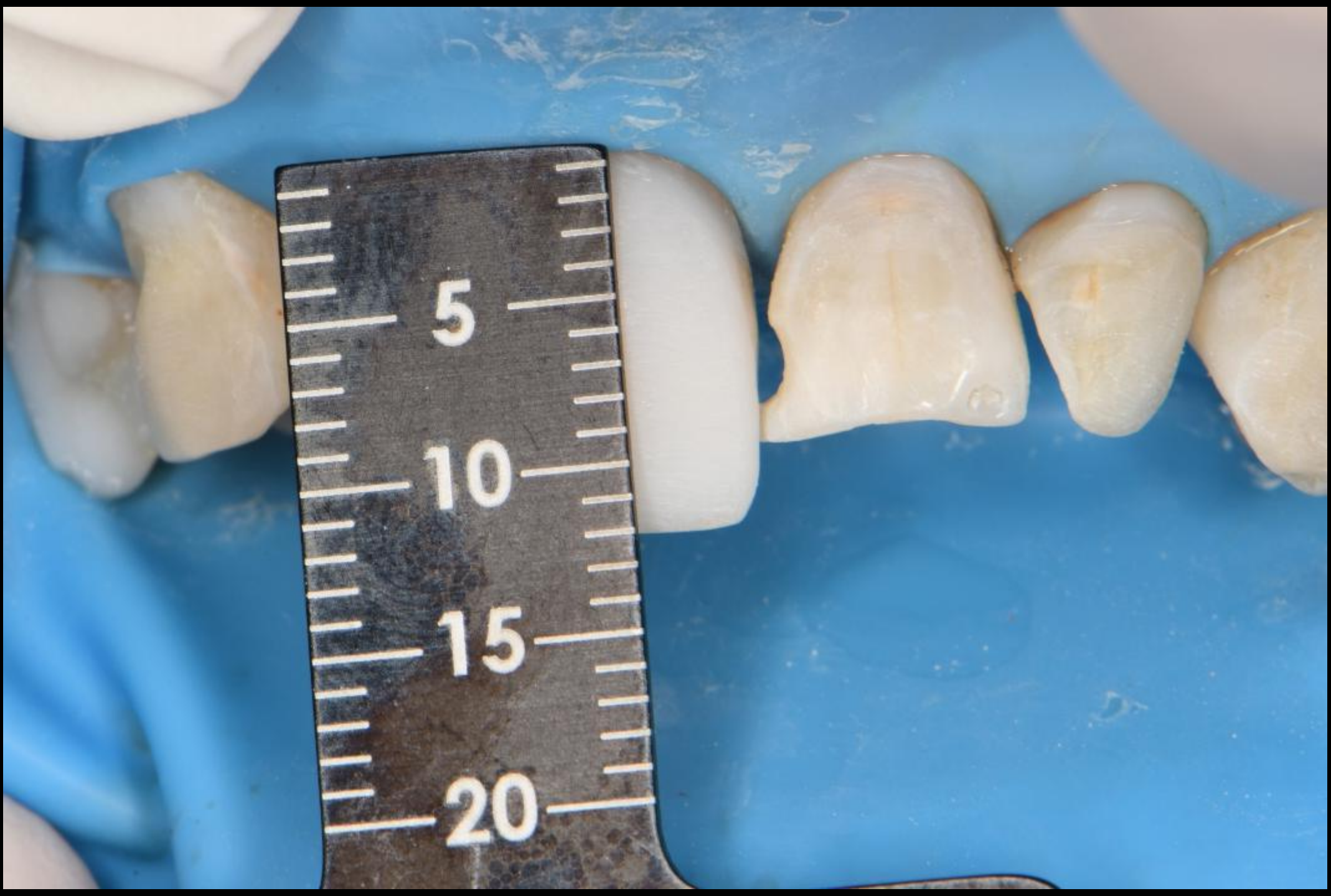Contact your Bioclear Sales Rep to Pre-Order
www.bioclearmatrix.com
1 855 712 5327

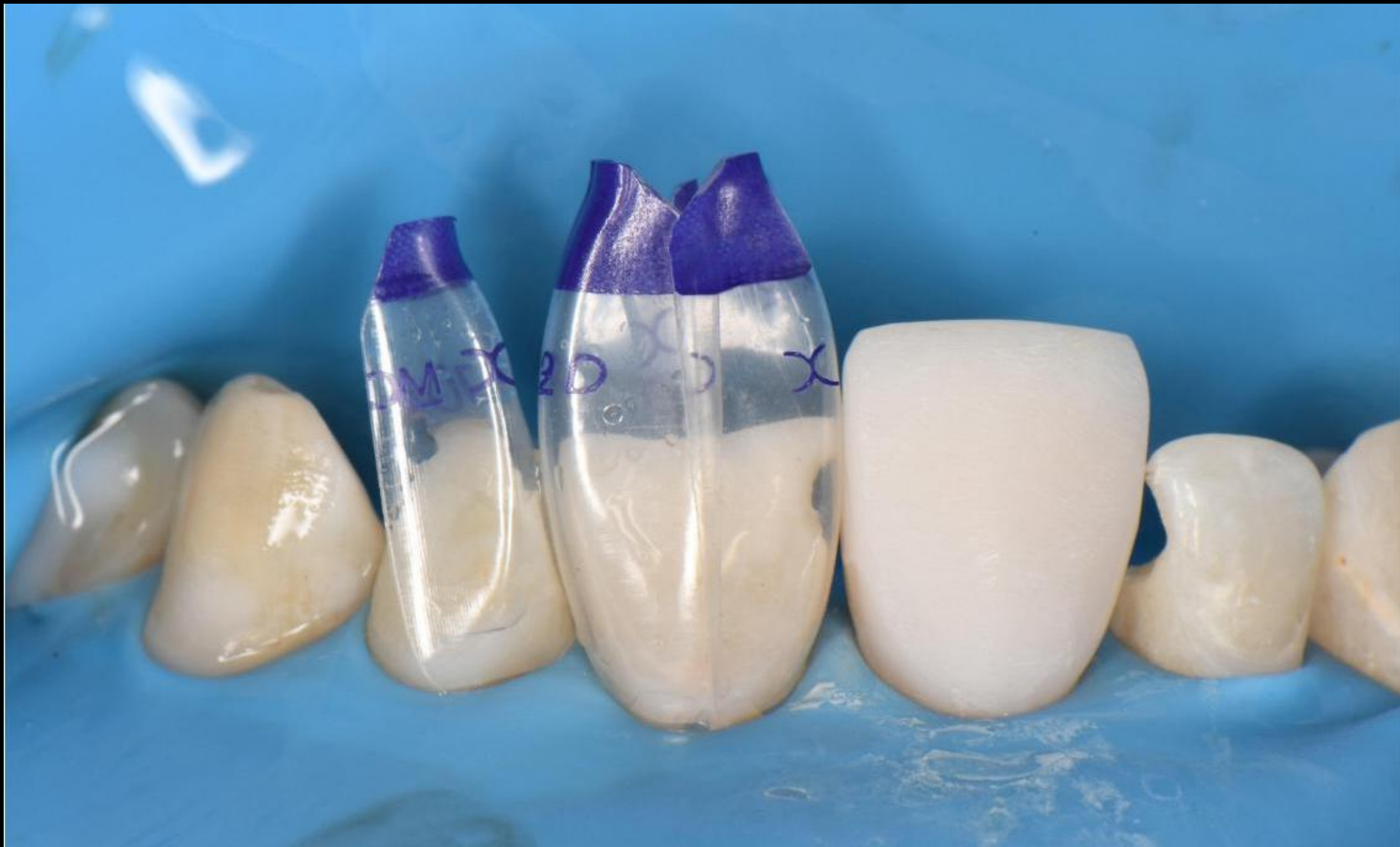


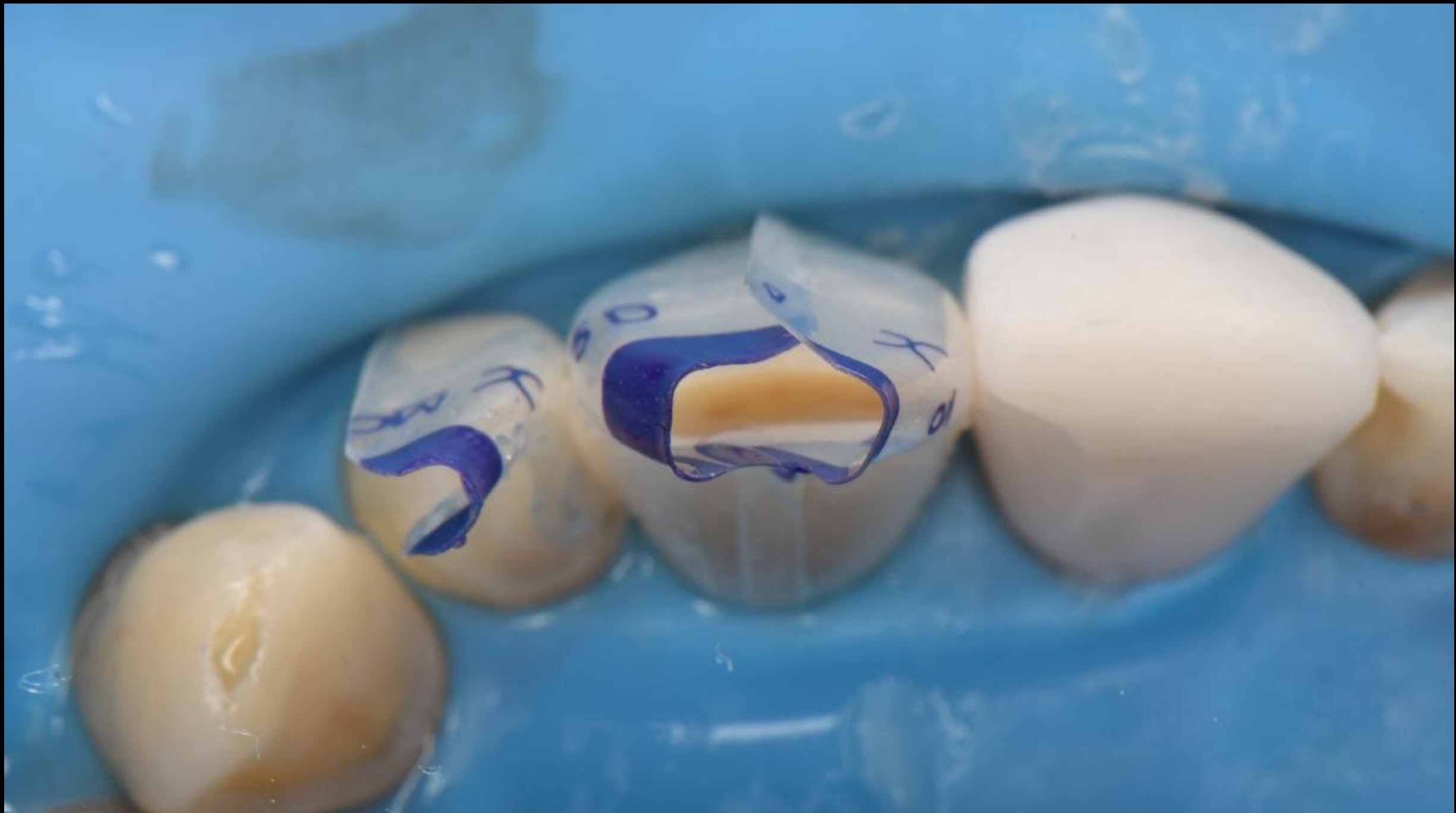


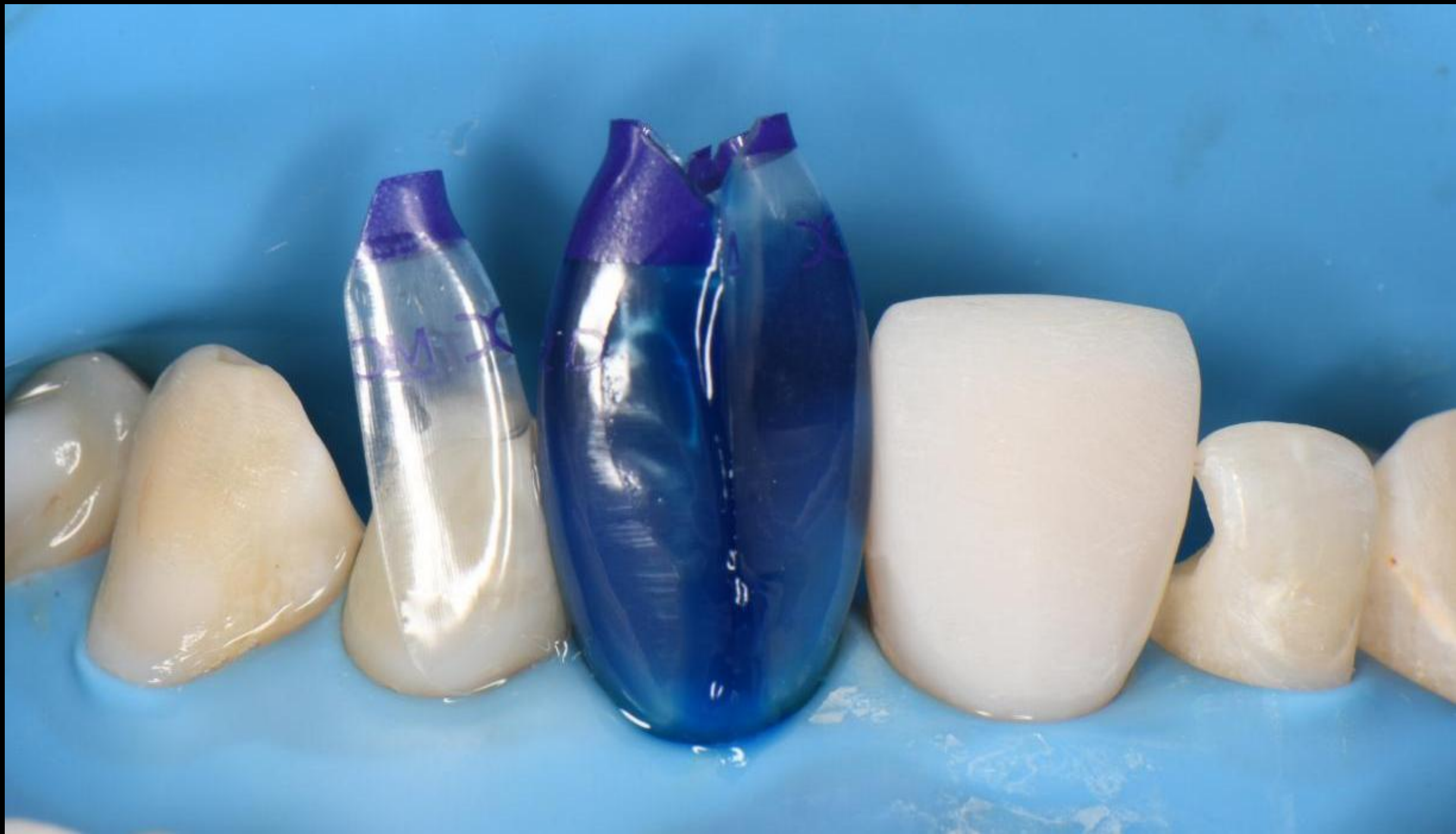


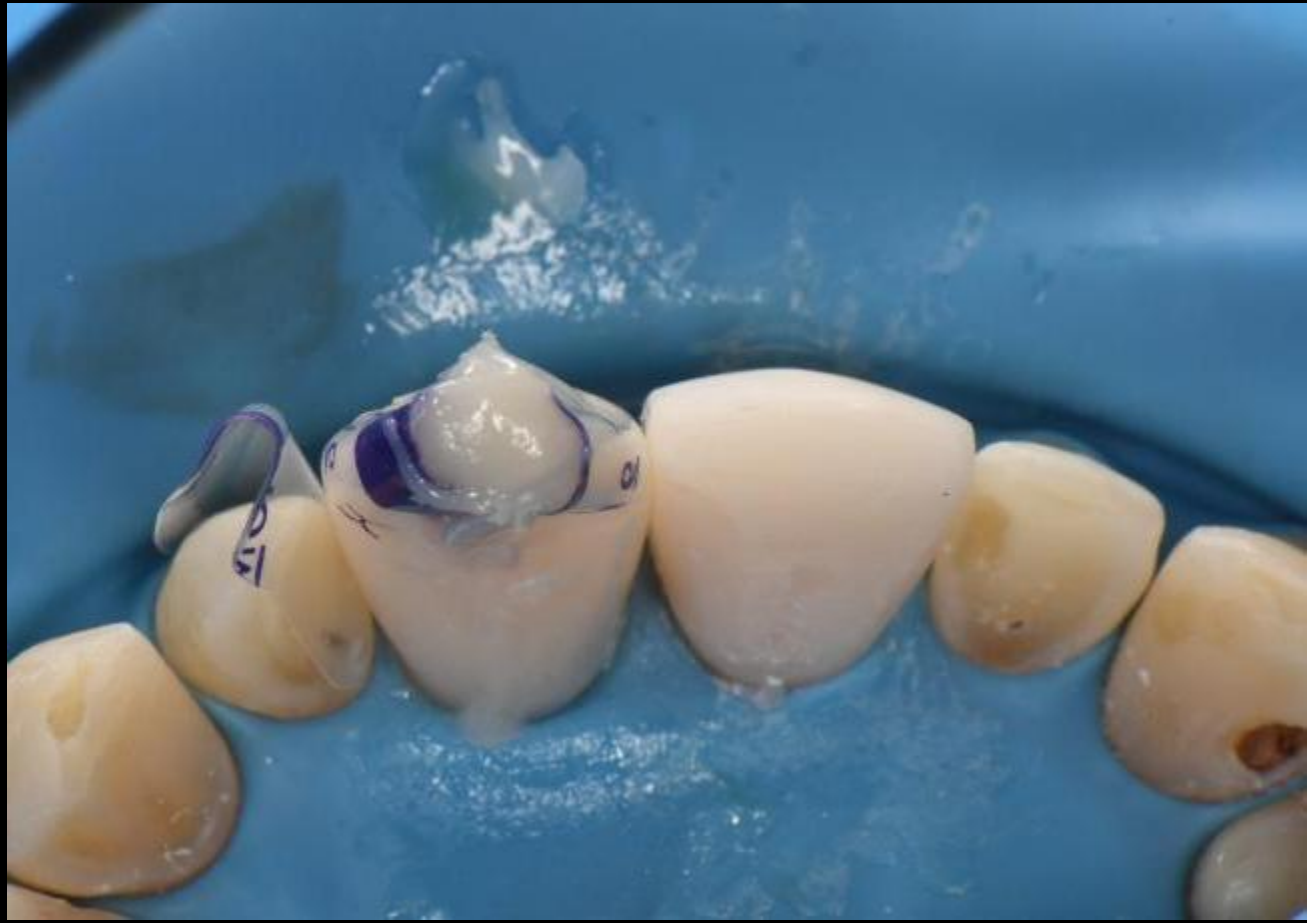
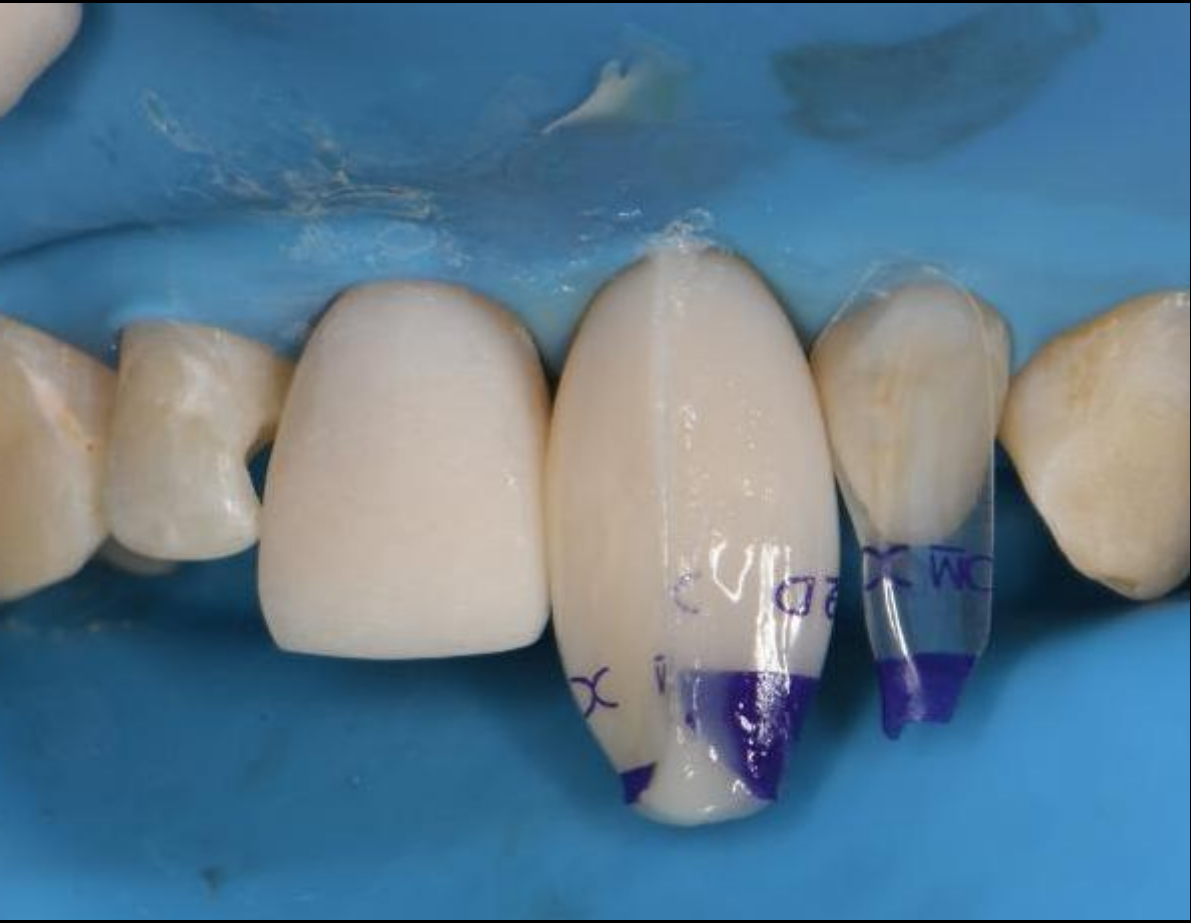


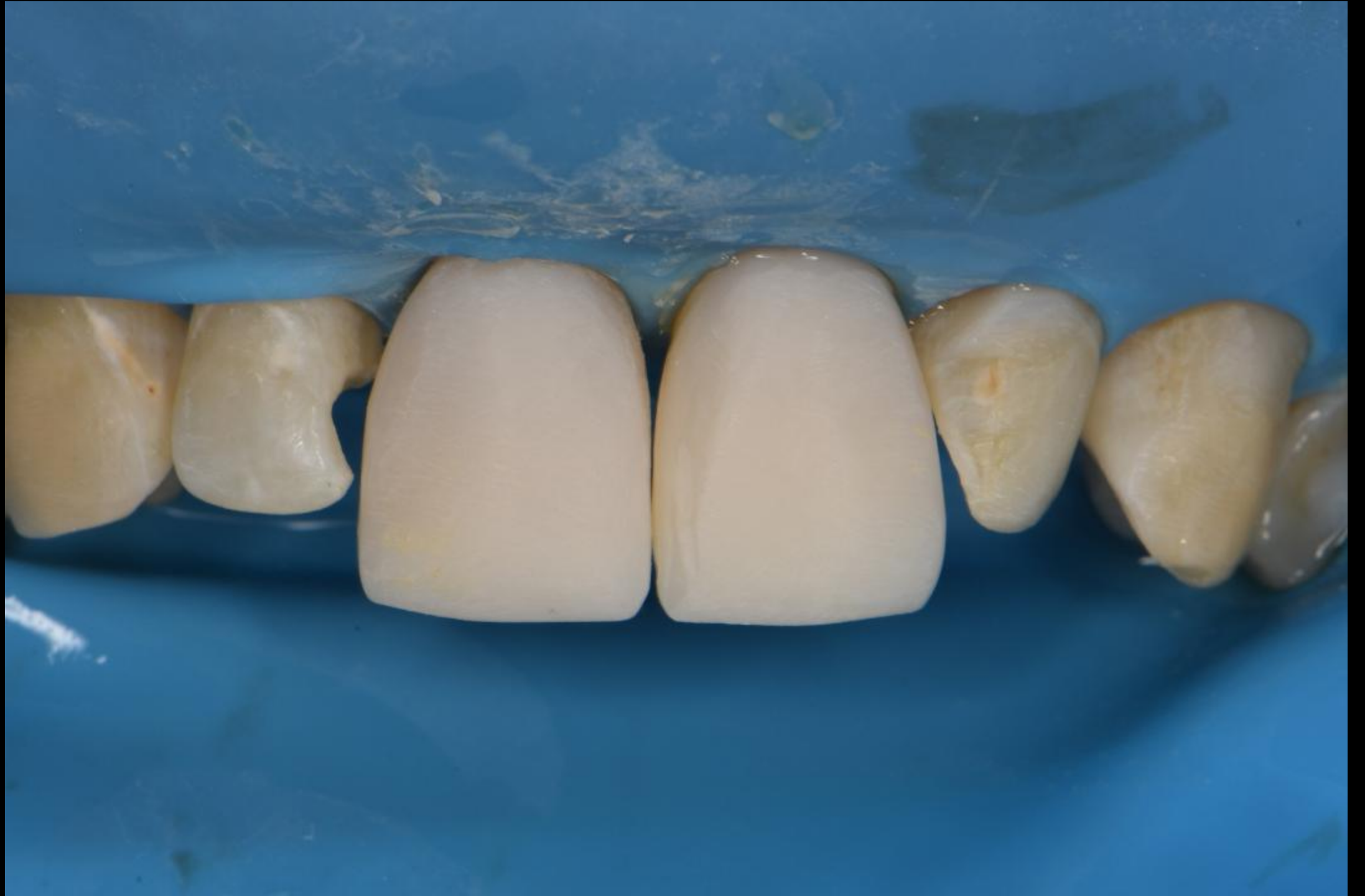


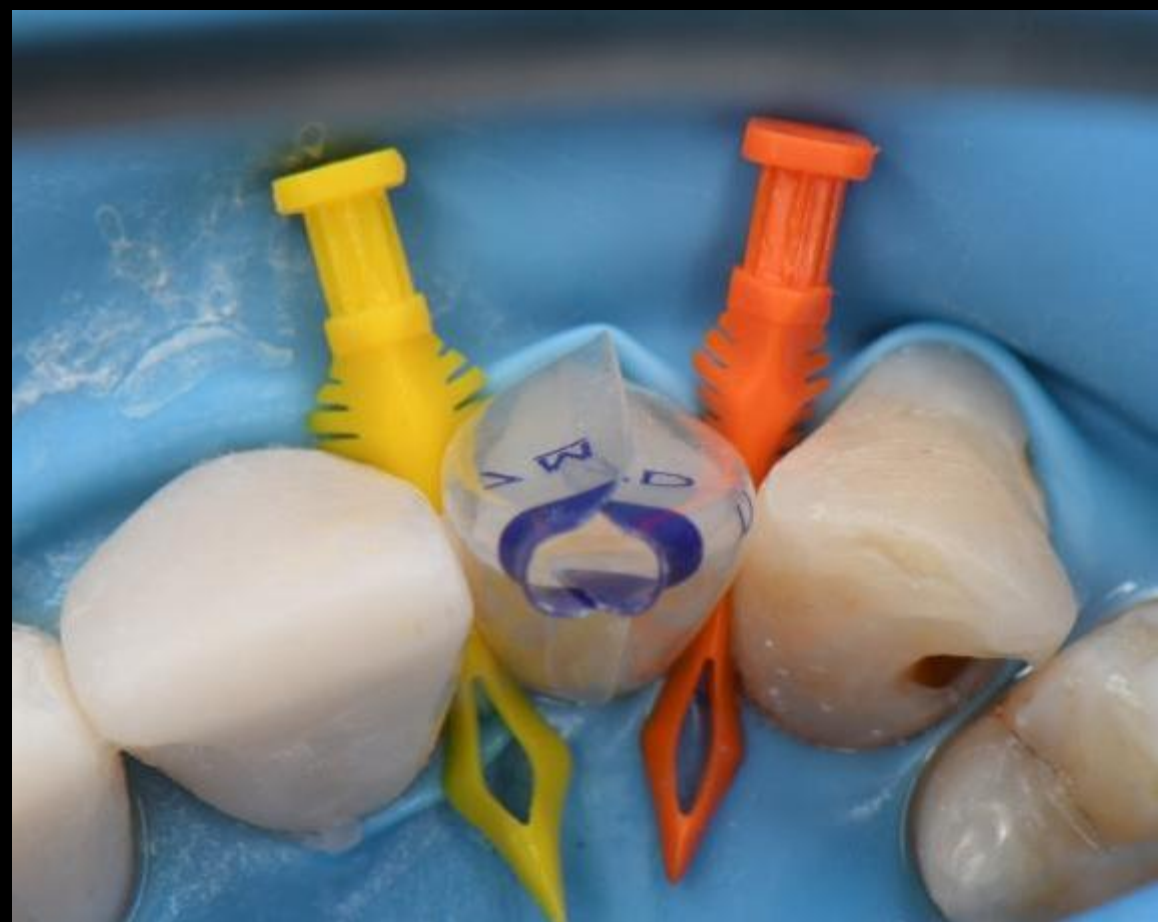
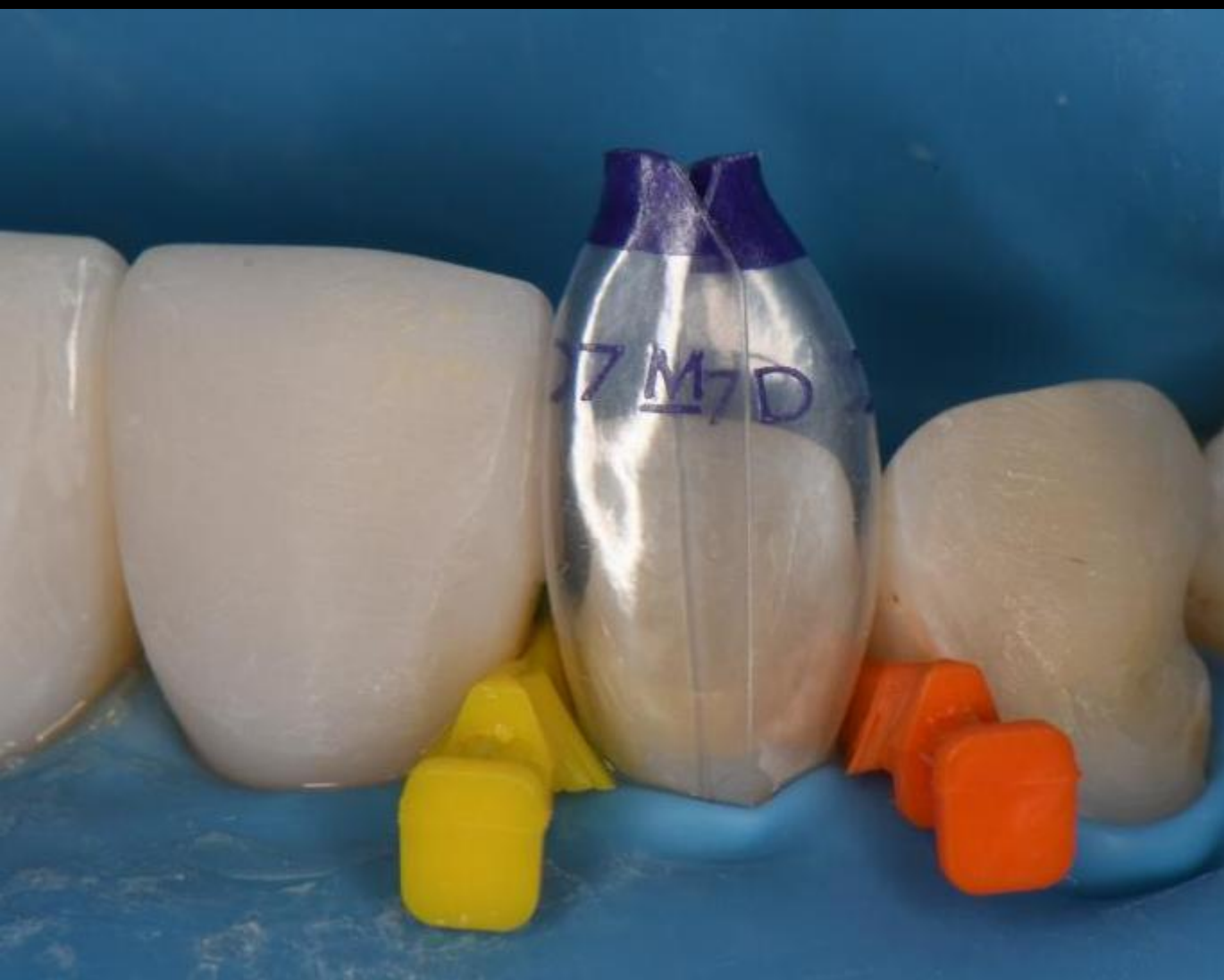


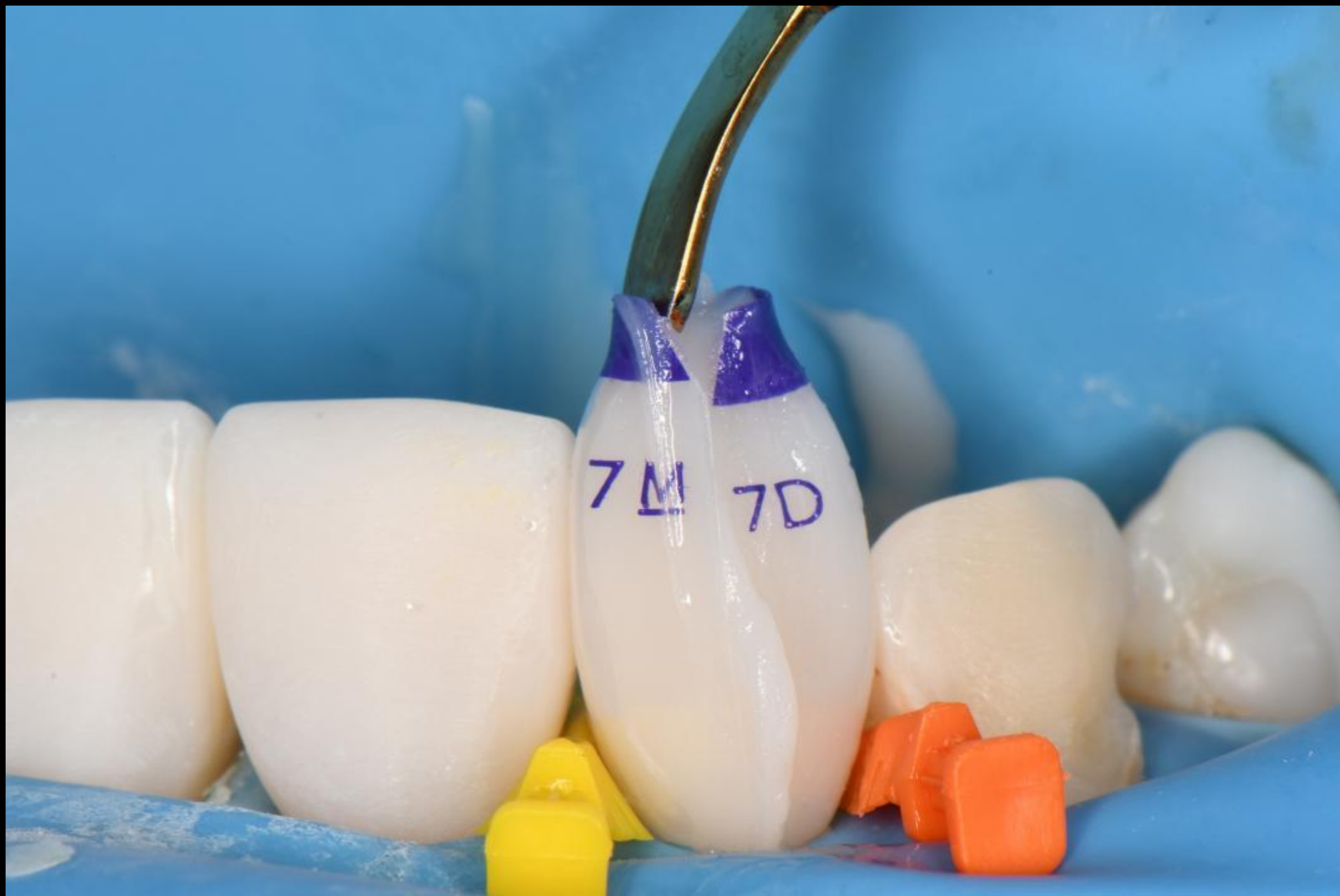


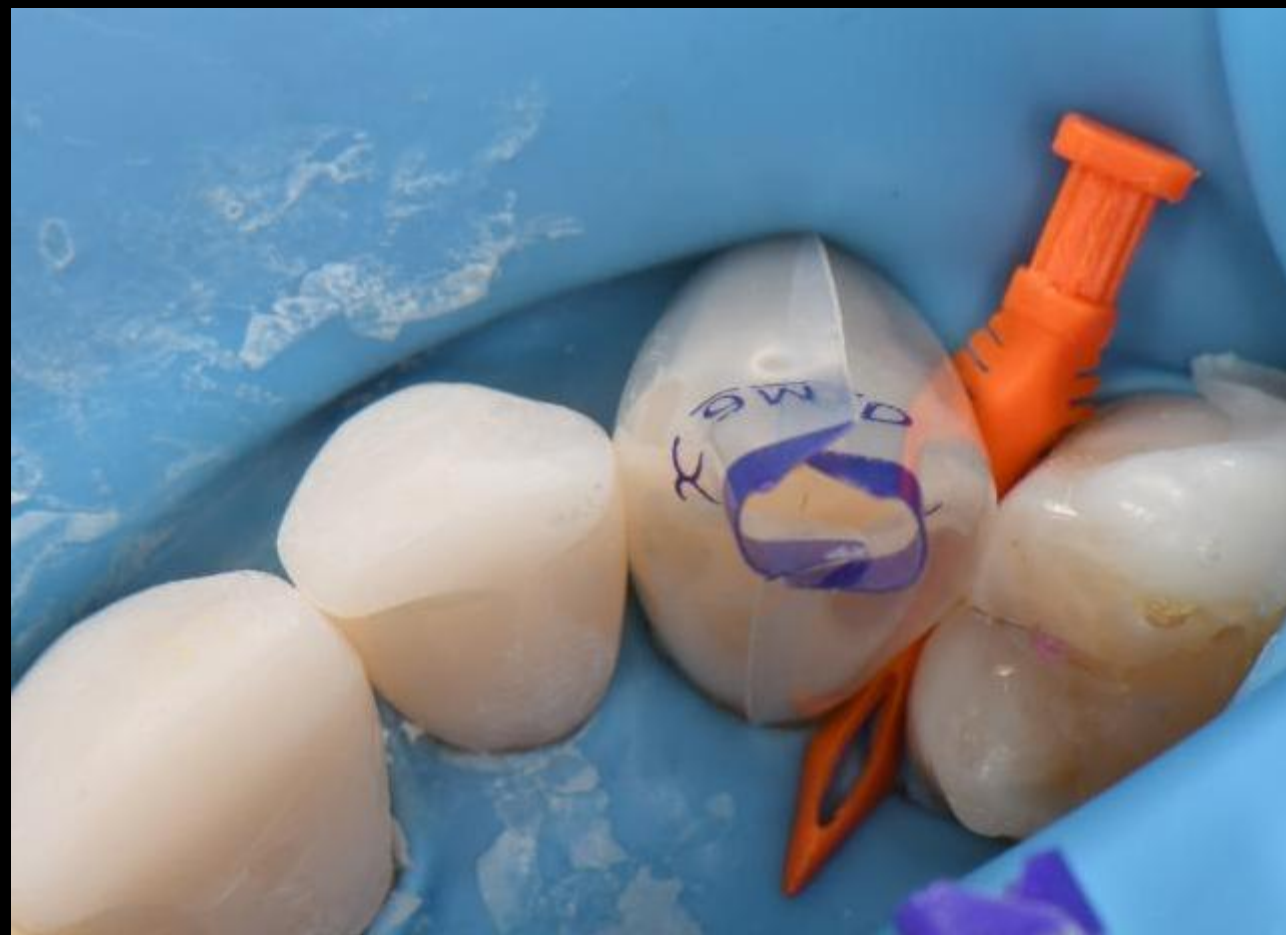
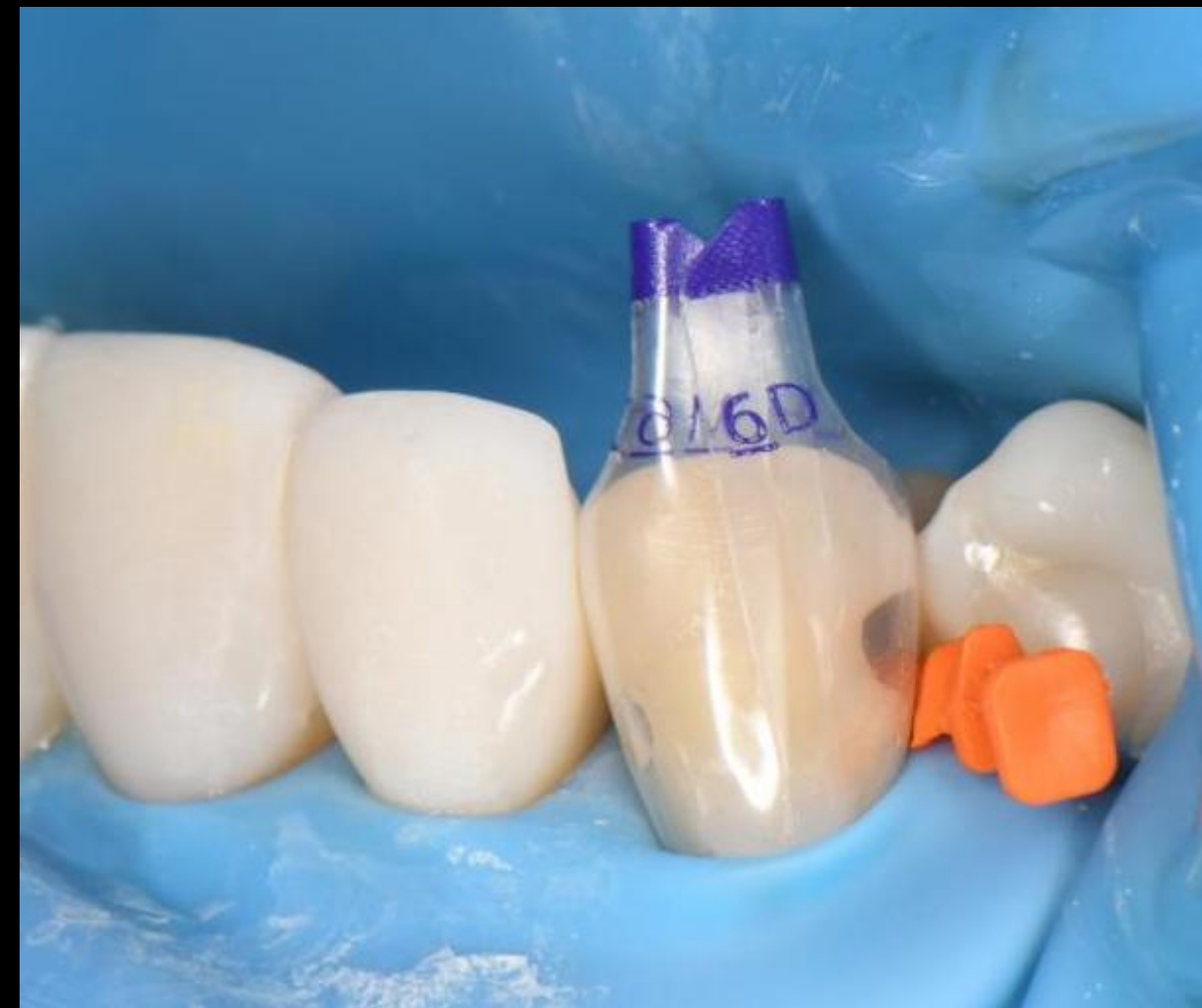


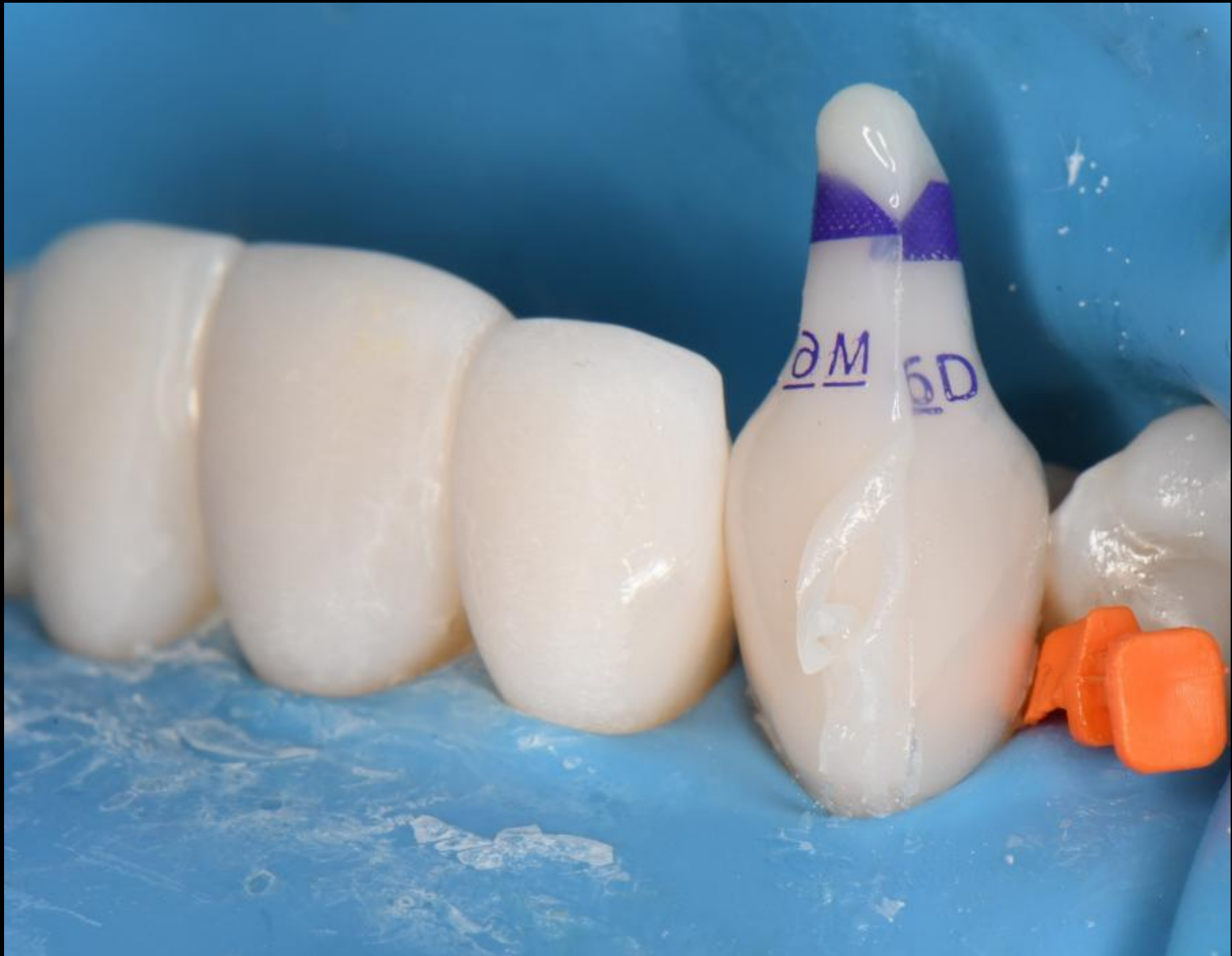


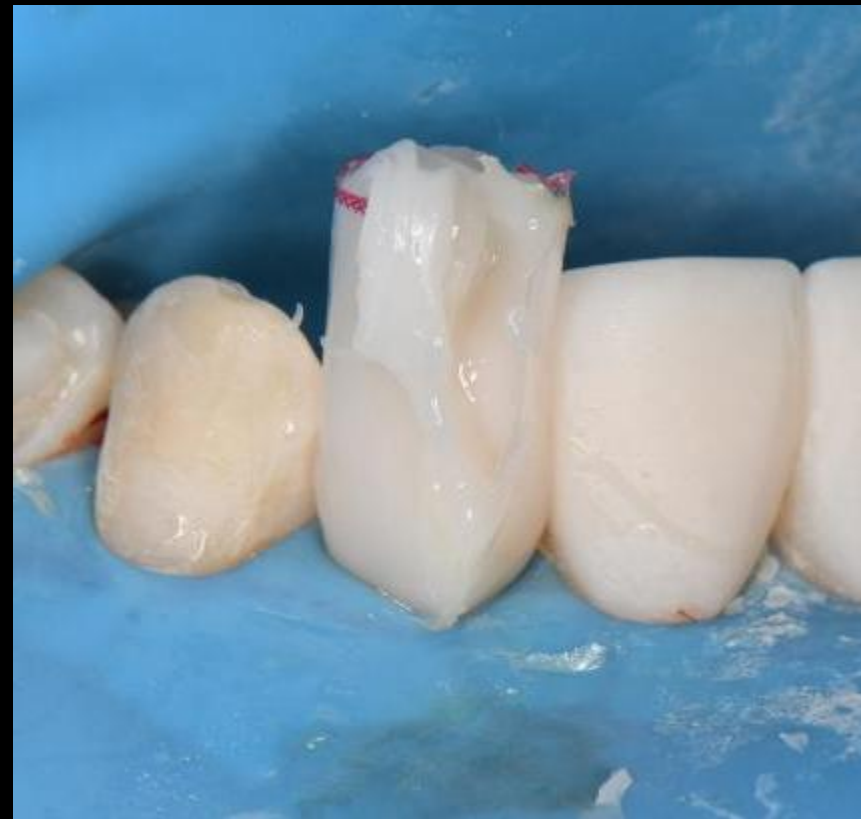
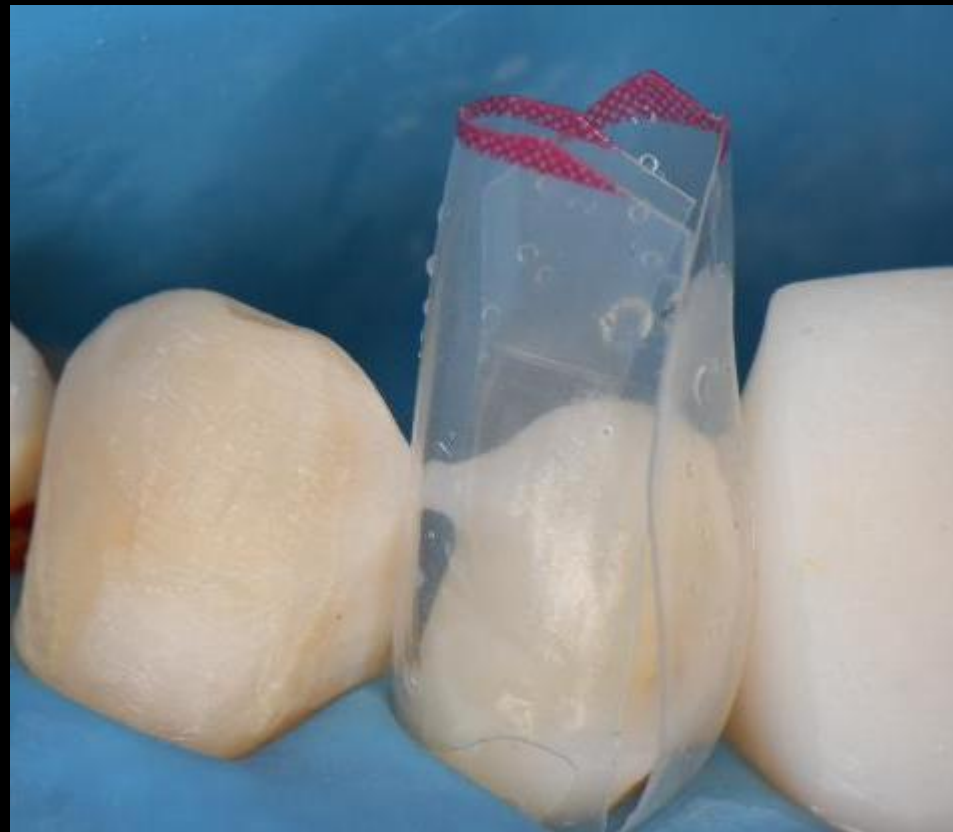
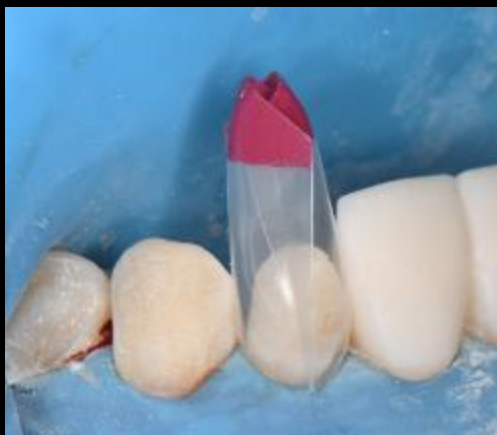
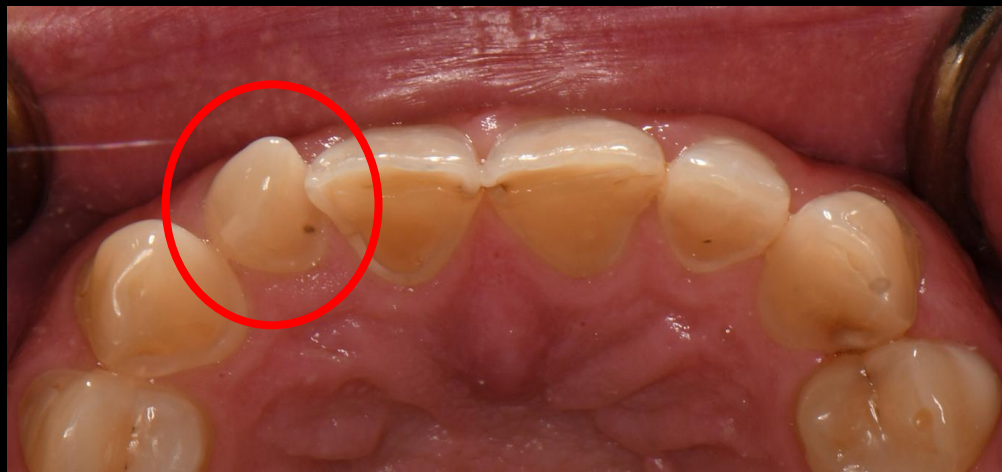
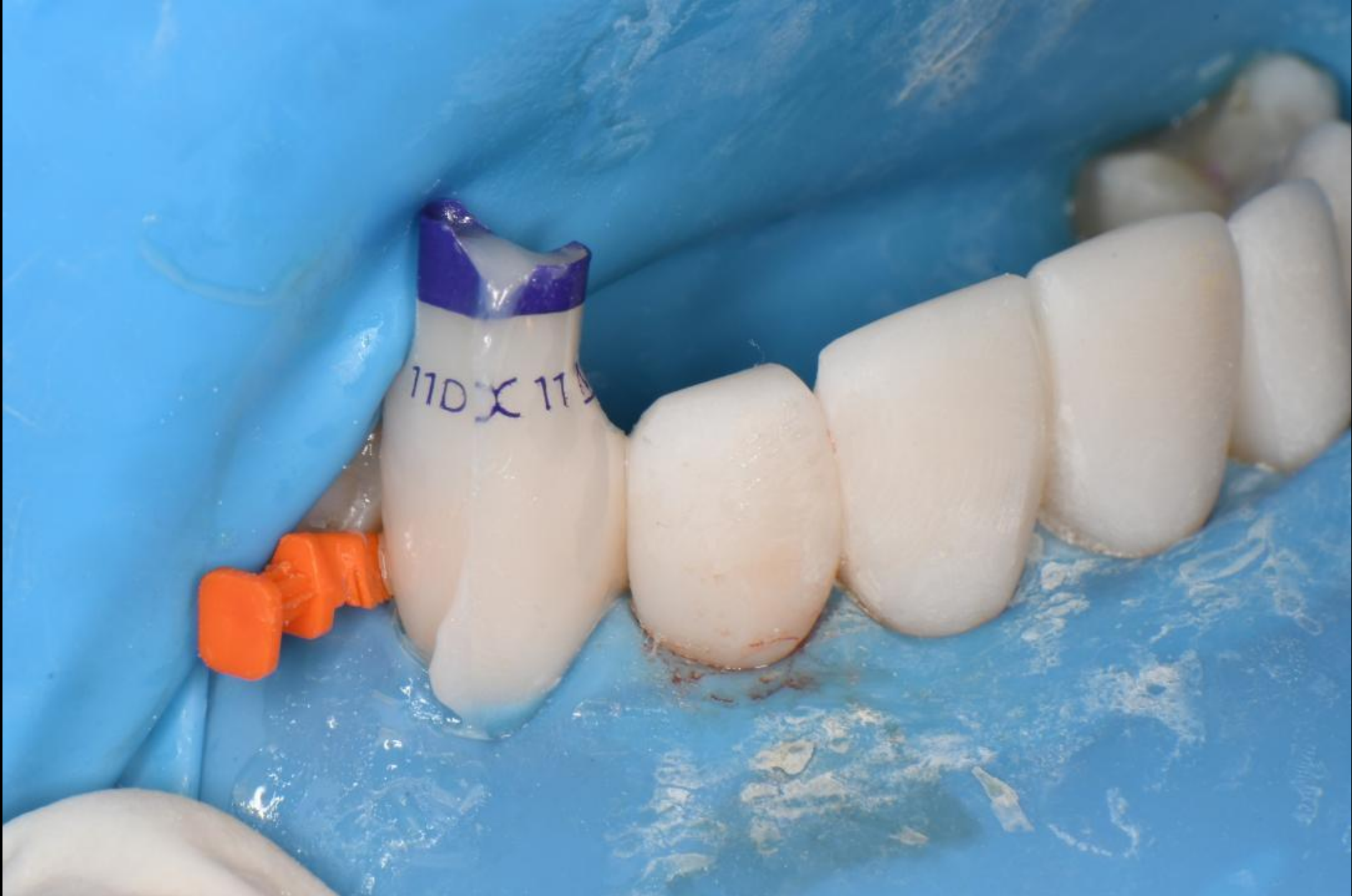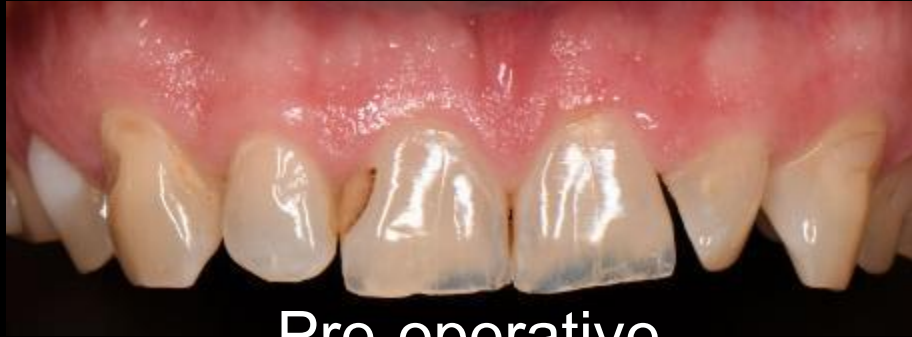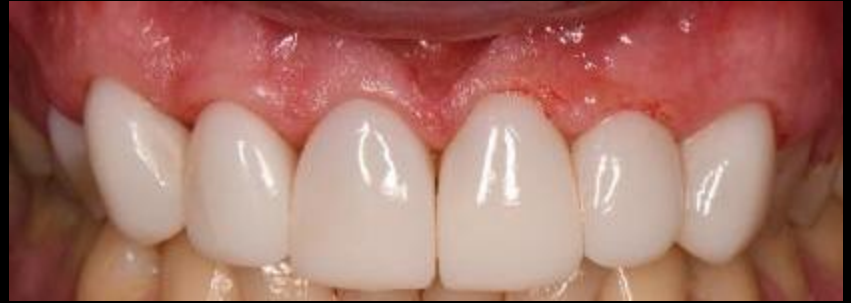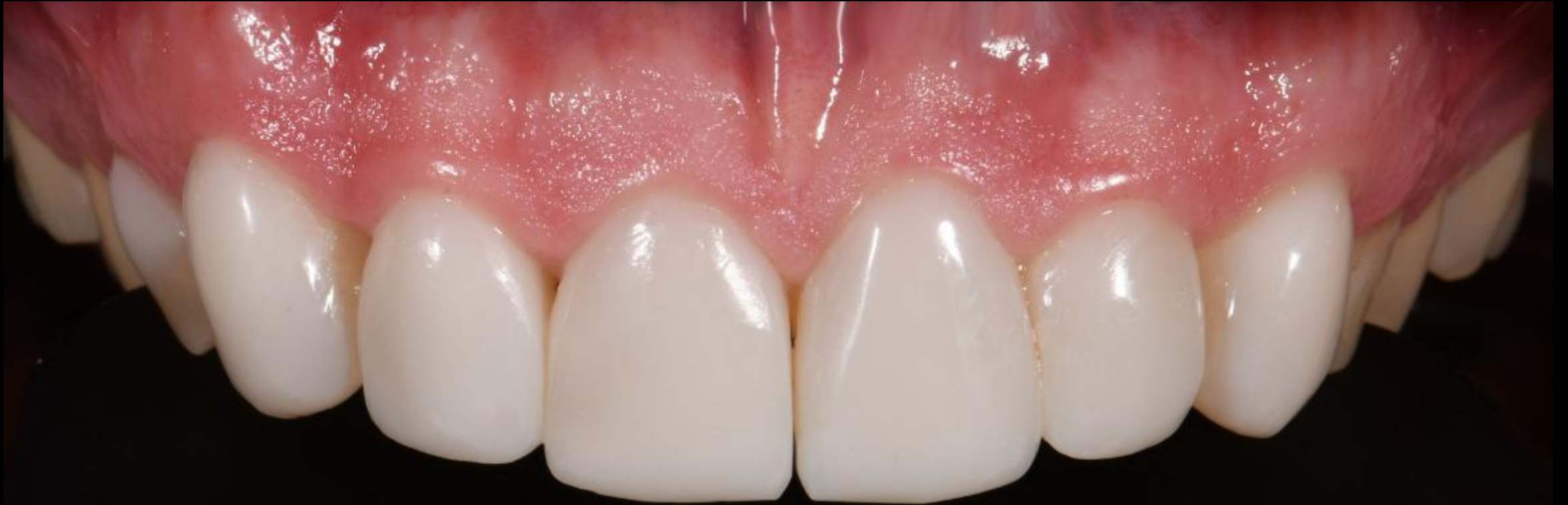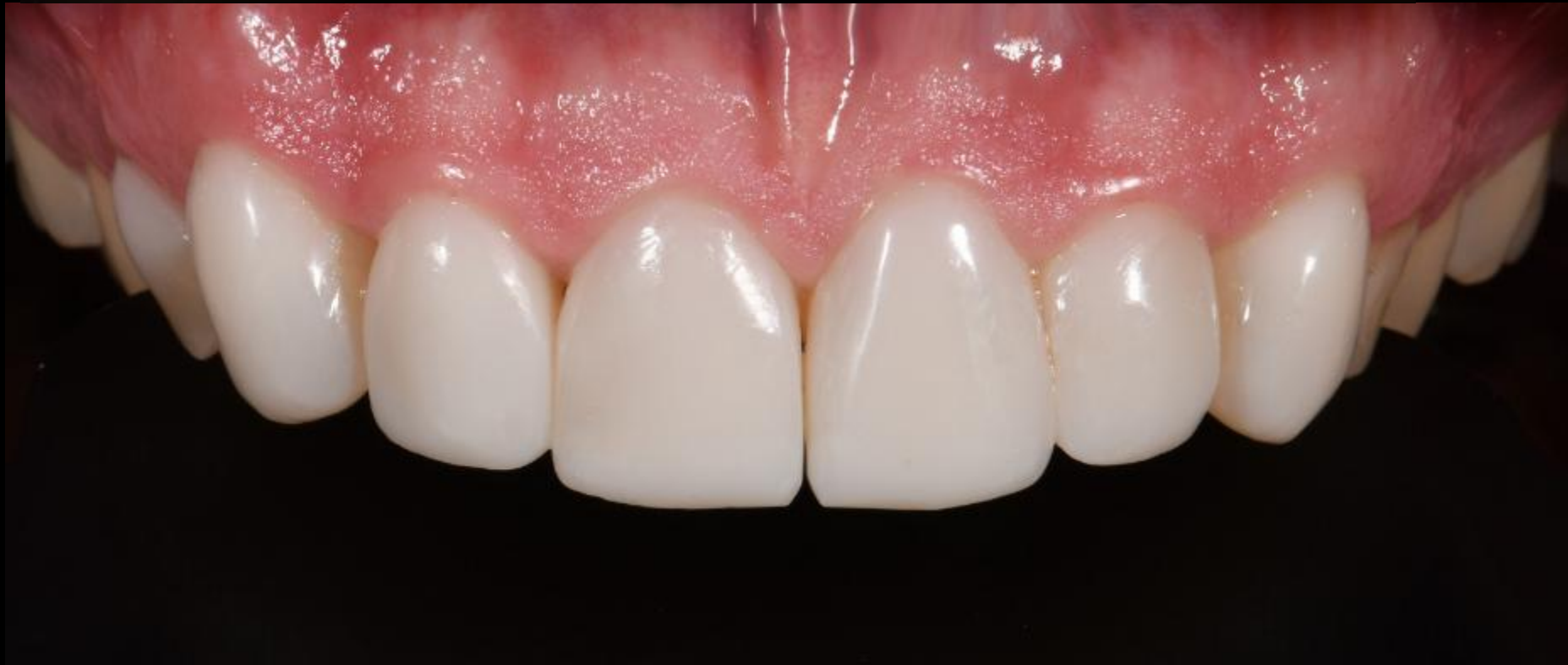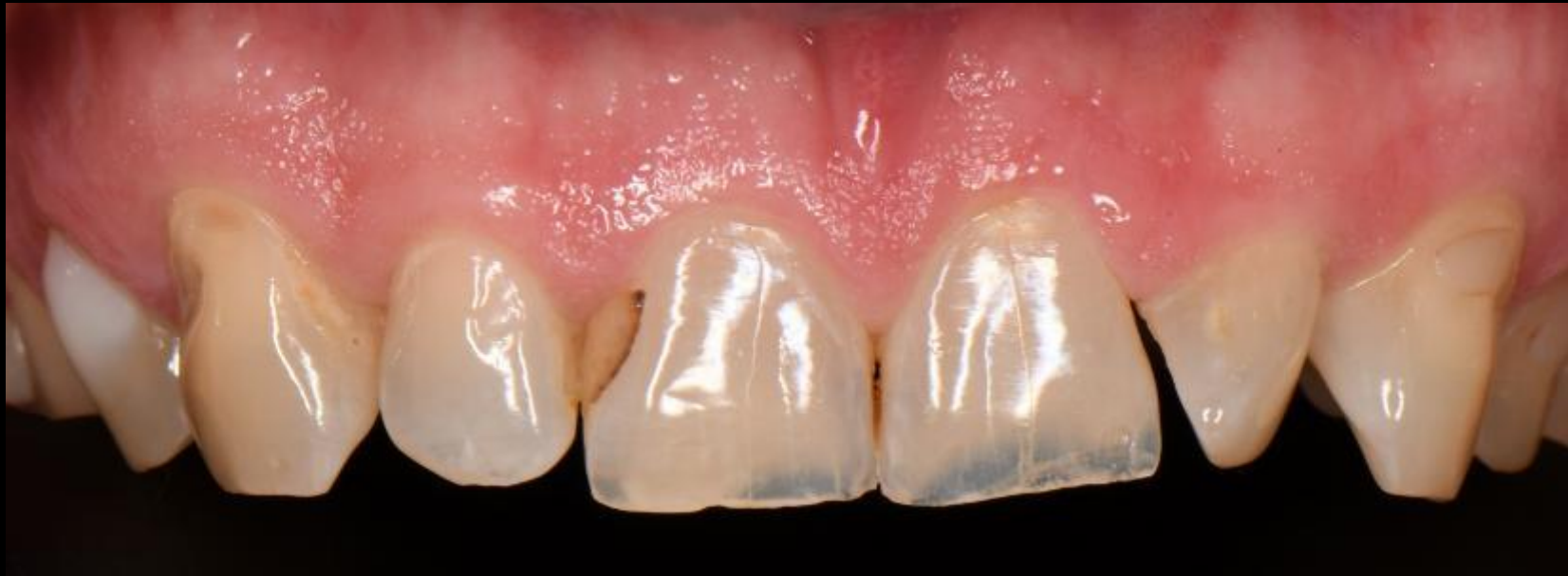Pre-operative

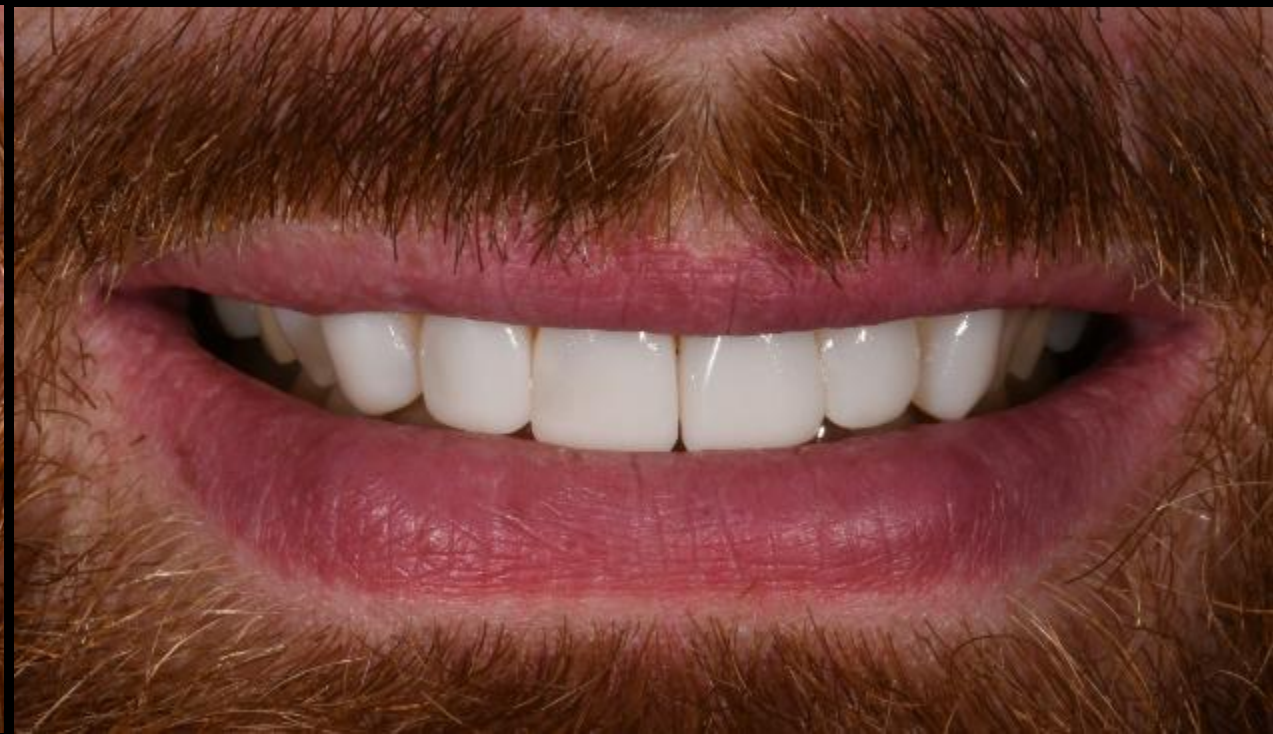
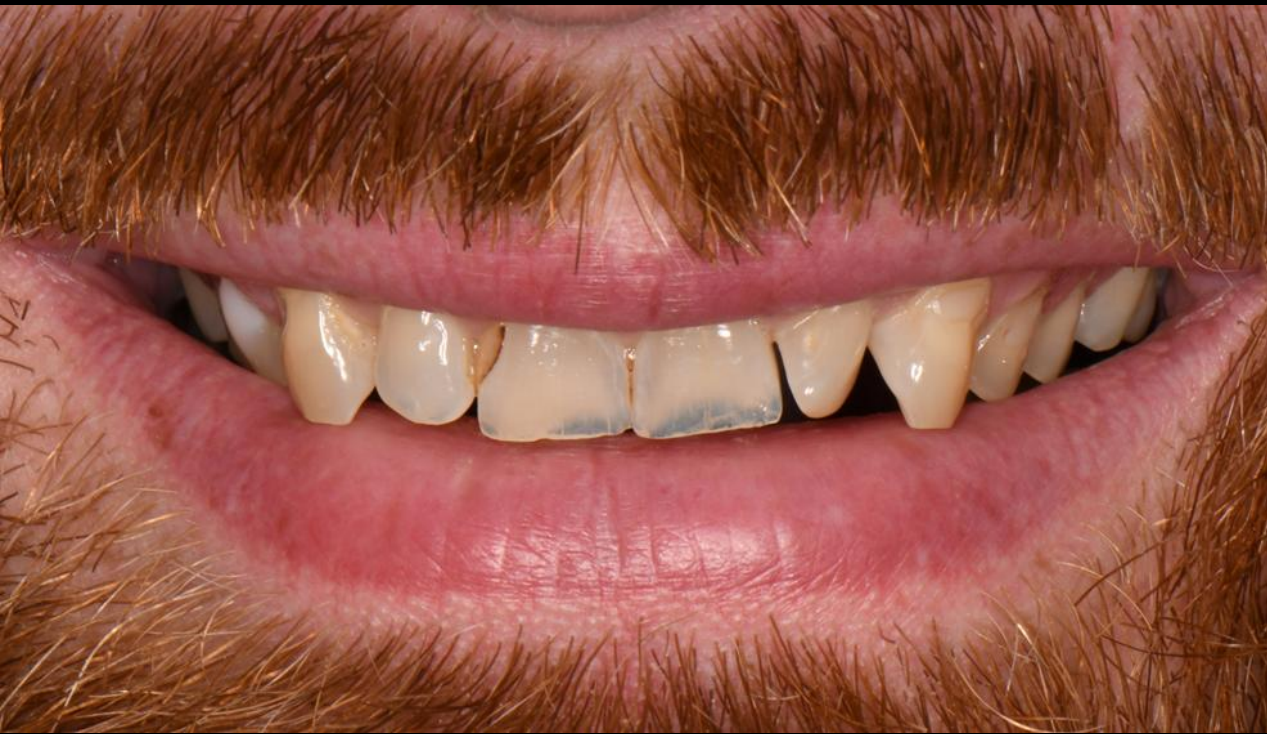
Immediate Post-Operative

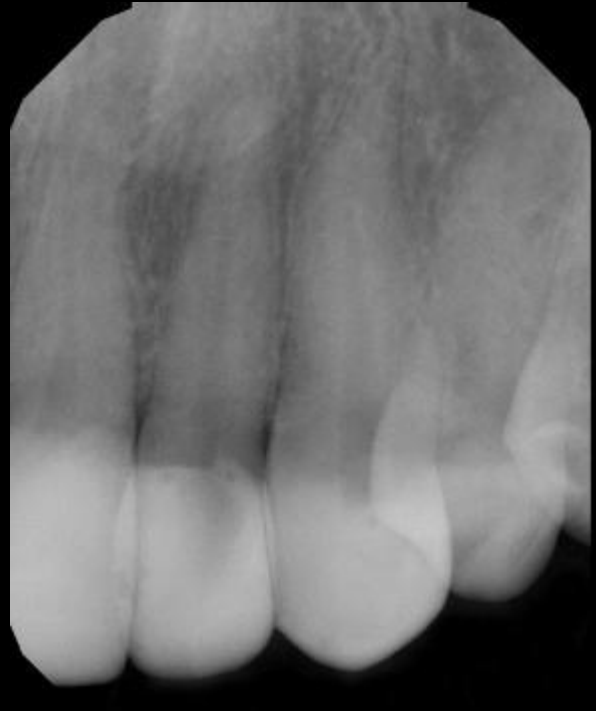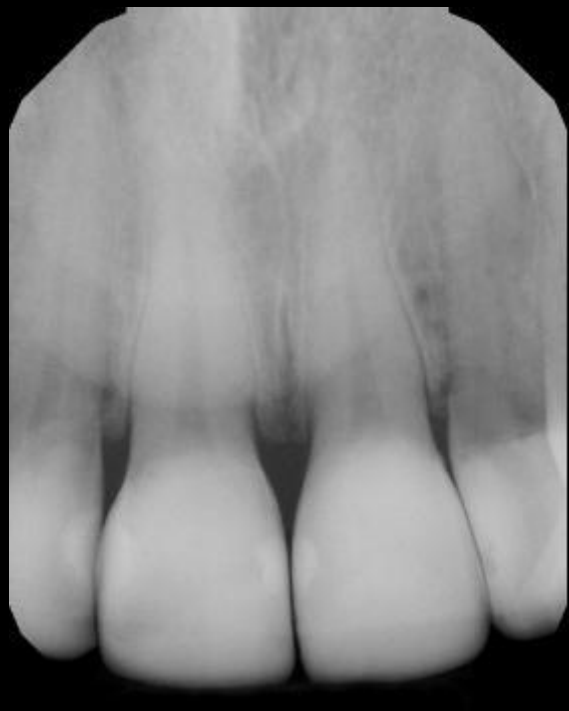

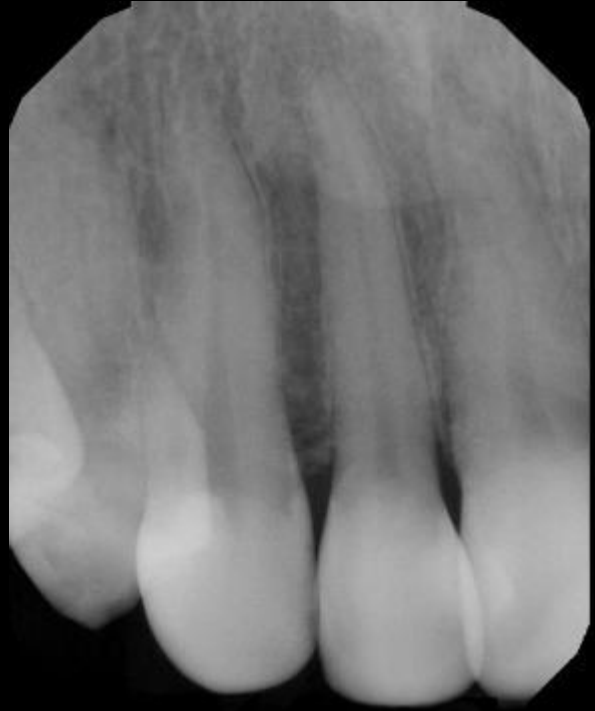
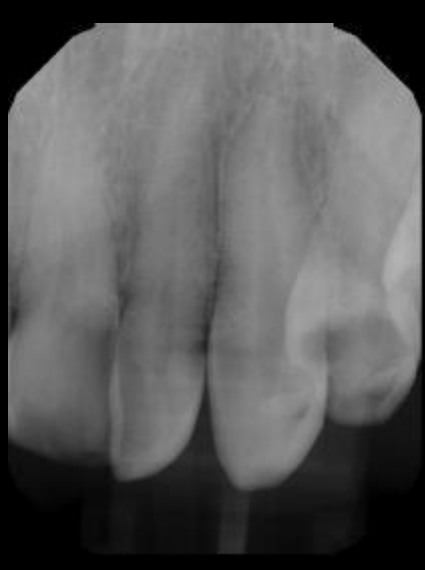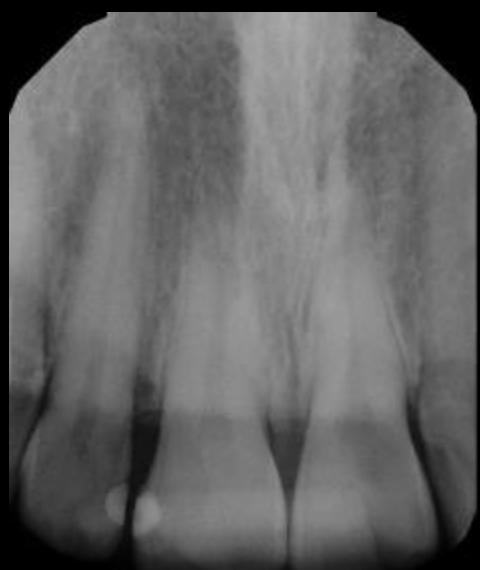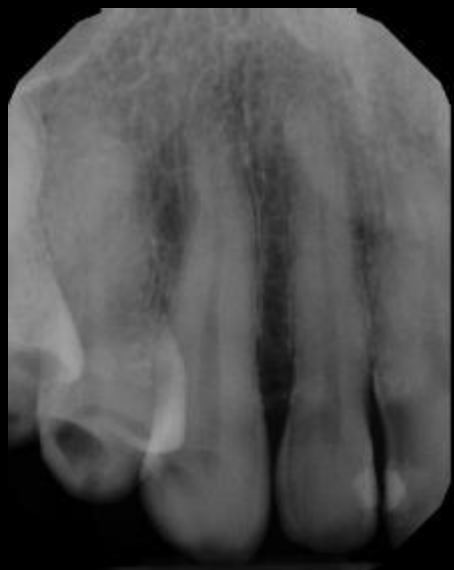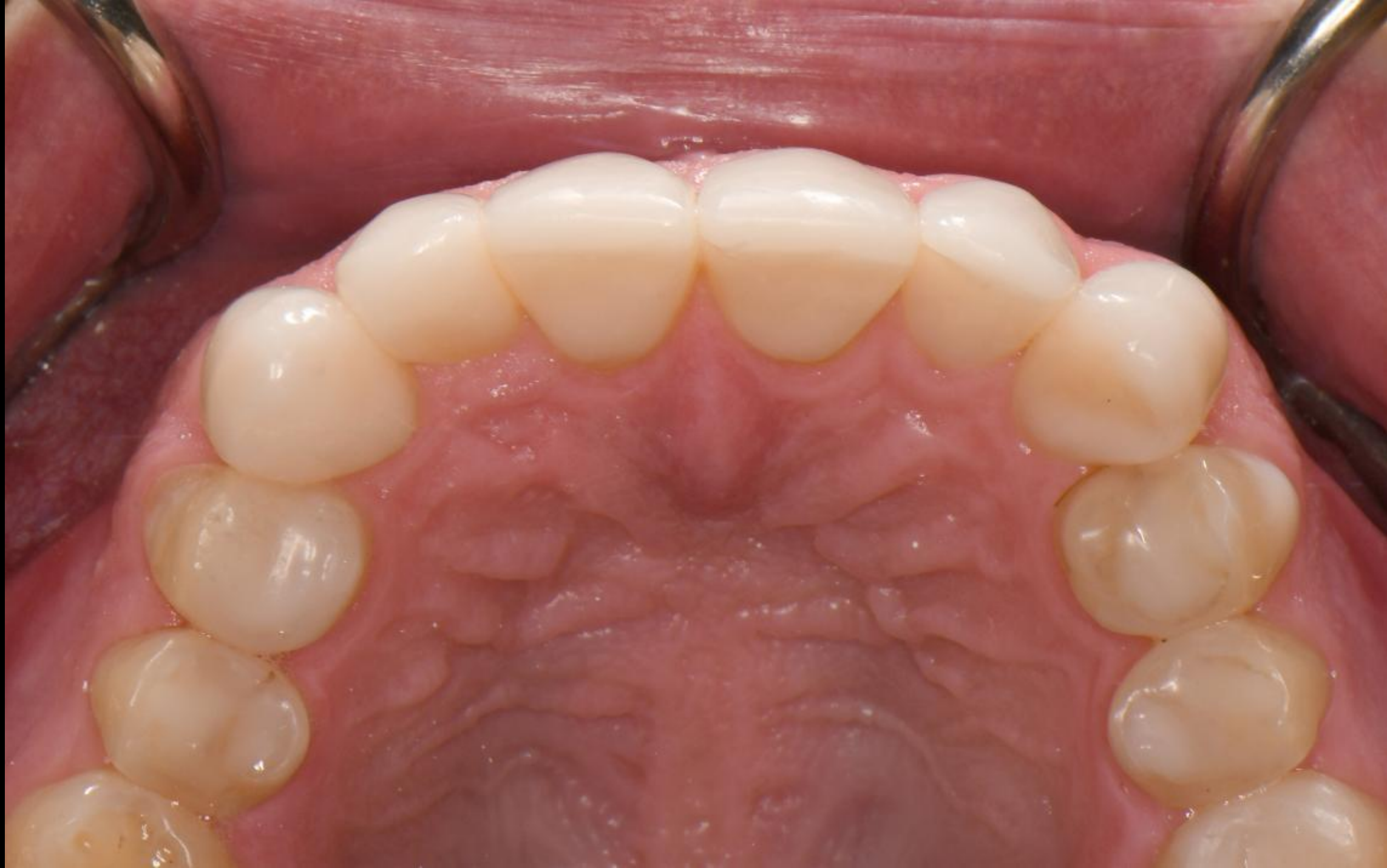One Week Post-Operative

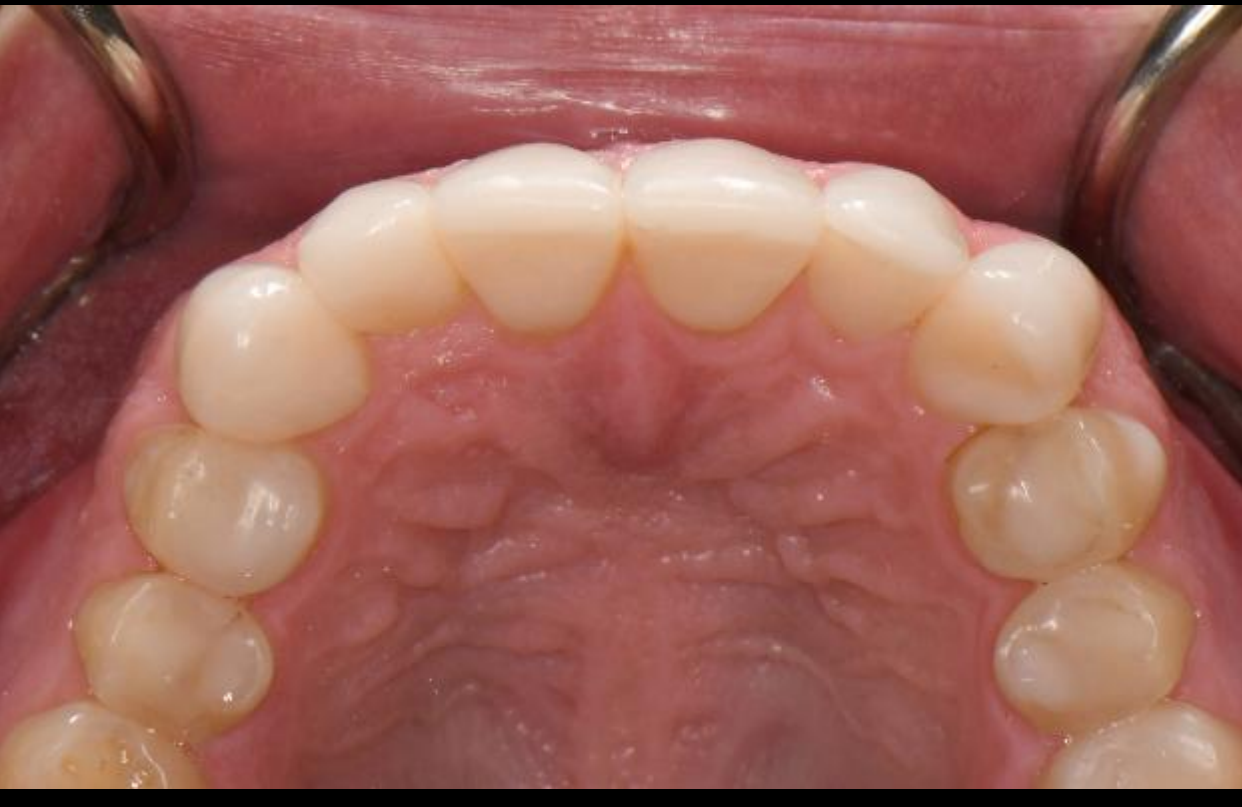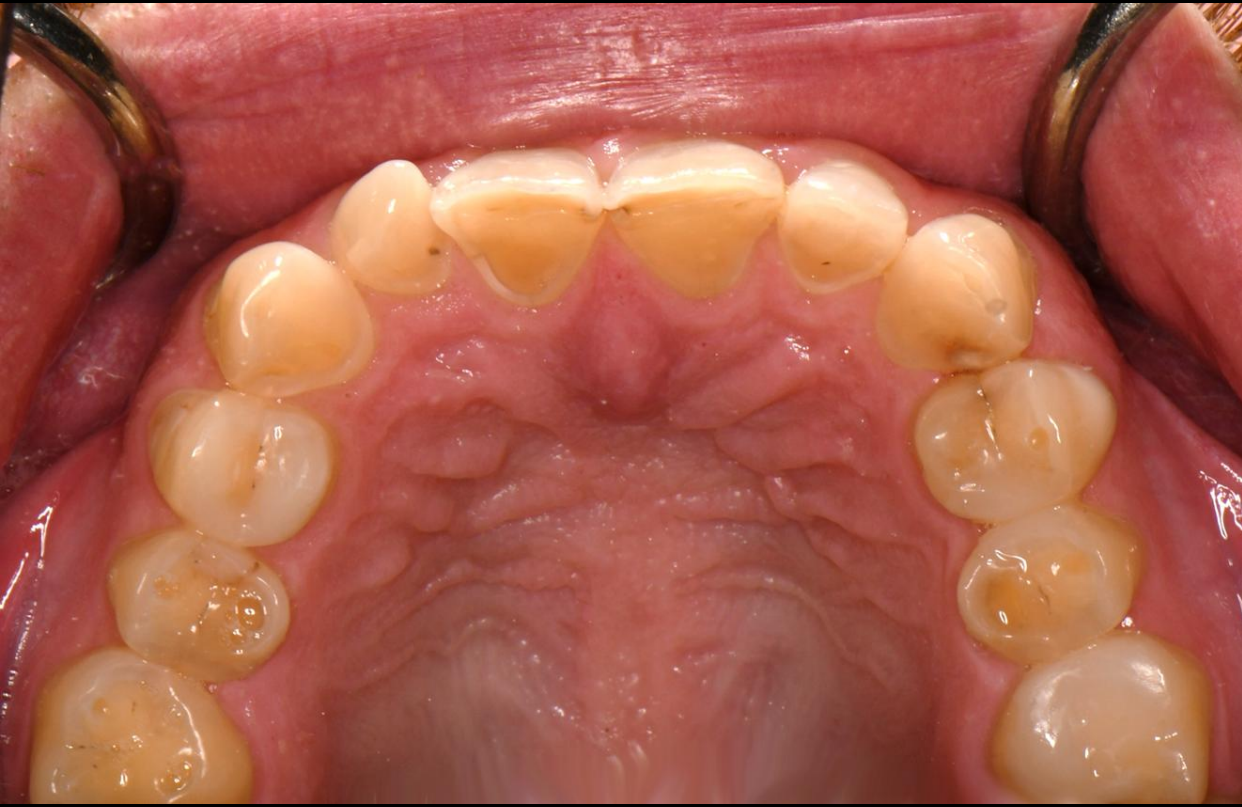










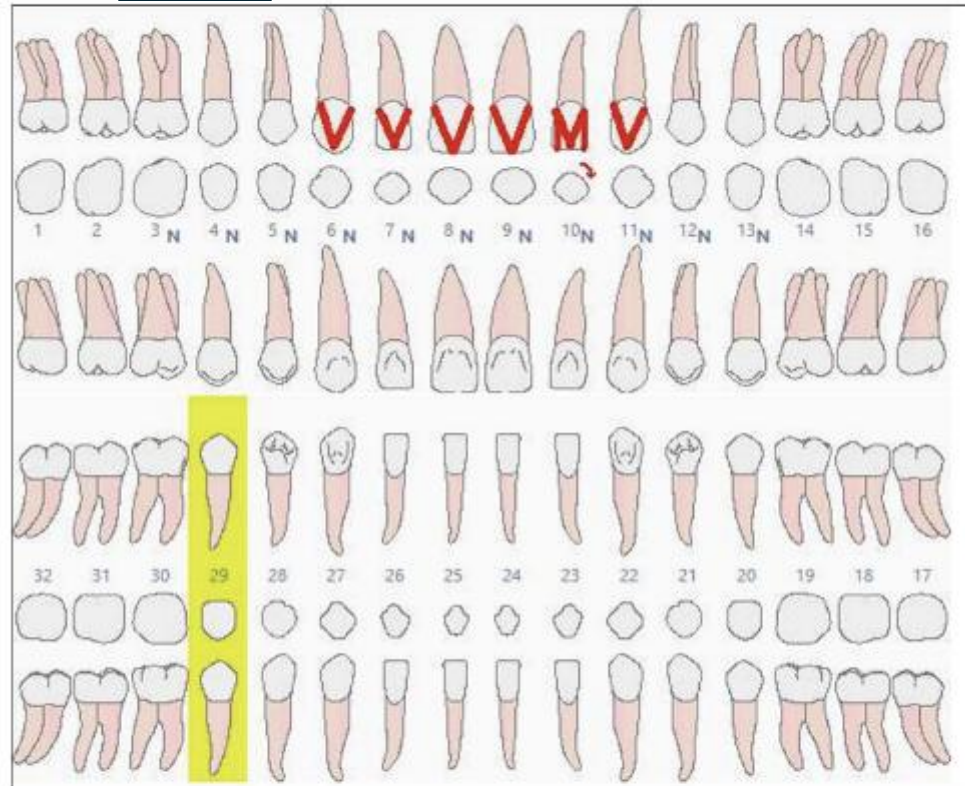


Patient Chart

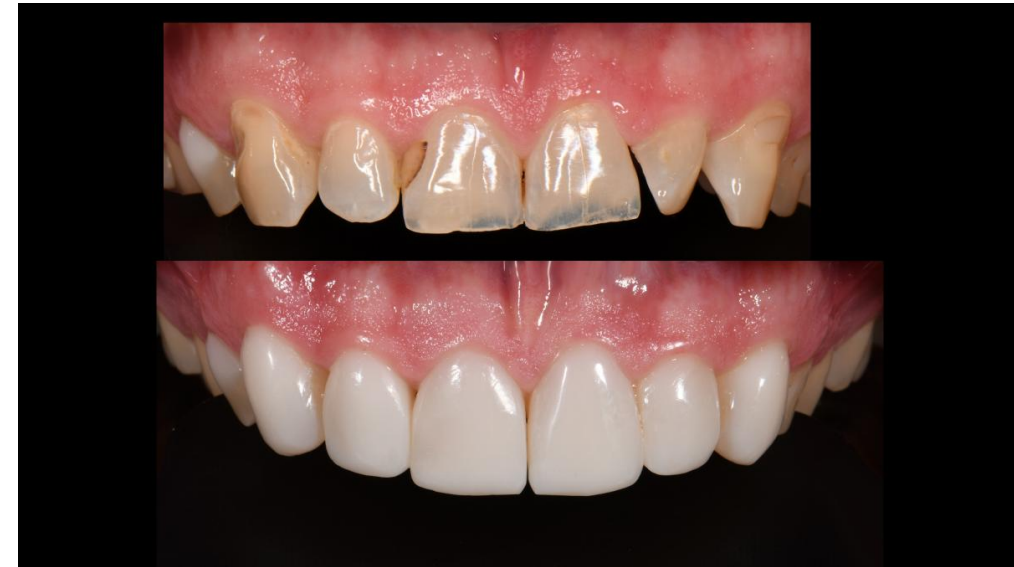Patient Name



Patient ID

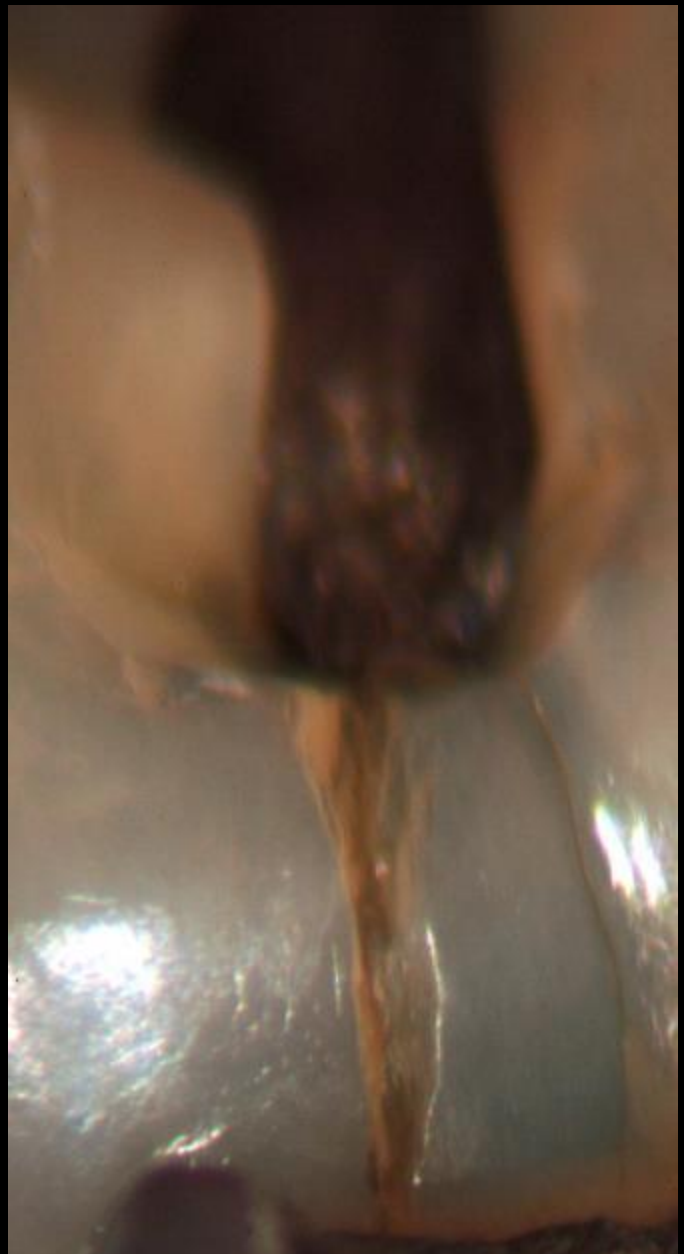
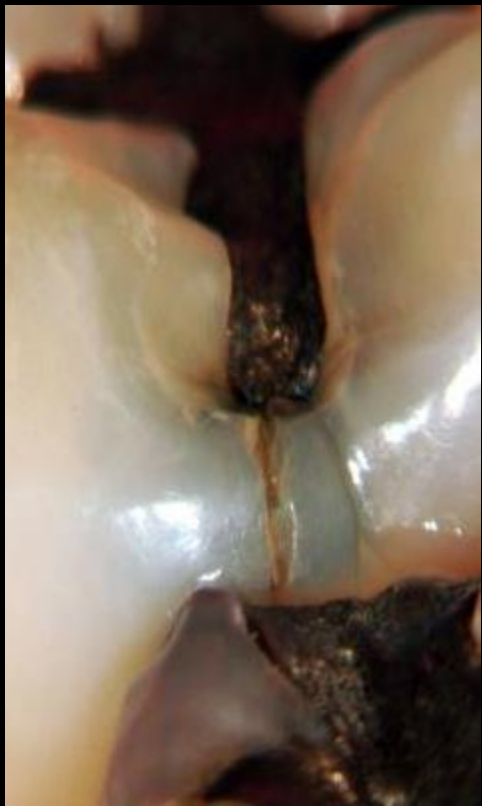
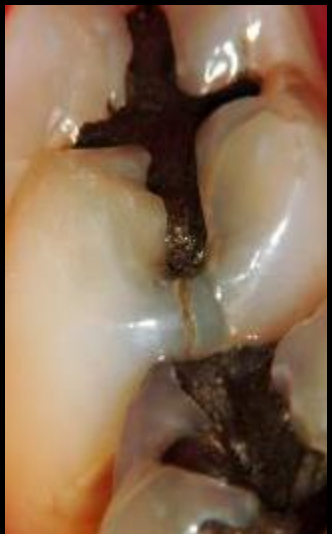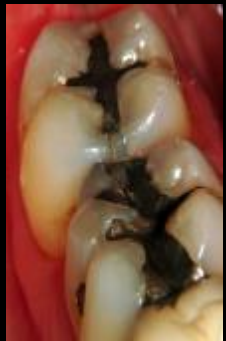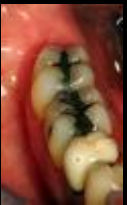Date	Description	Provider	Tit	Surf	Status	Fee
1/15/2026	2993A - BIOCLEAR 360 REJUVENATION COMPLEX	David J. Clark, D.D.S.	6		Proposed	\$1,840.00
1/15/2026	2993A - BIOCLEAR 360 REJUVENATION COMPLEX	David J. Clark, D.D.S.	7		Proposed	\$1,840.00
1/15/2026	2993A - BIOCLEAR 360 REJUVENATION COMPLEX	David J. Clark, D.D.S.	8		Proposed	\$1,840.00
1/15/2026	2993A - BIOCLEAR 360 REJUVENATION COMPLEX	David J. Clark, D.D.S.	9		Proposed	\$1,840.00
1/15/2026	2993A - BIOCLEAR 360 REJUVENATION COMPLEX	David J. Clark, D.D.S.	10		Proposed	\$1,840.00
1/15/2026	2993A - BIOCLEAR 360 REJUVENATION COMPLEX	David J. Clark, D.D.S.	11		Proposed	\$1,840.00
1/15/2026	199.2 - BIOCLEAR ORTHO CORRECTION PER TOOTH	David J. Clark, D.D.S.	10		Proposed	\$306.00
1/15/2026	299.5 - BIOCLEAR DIASTEMA CLOSURE	David J. Clark, D.D.S.	10	MD	Proposed	\$285.00



Total Bioclear Case Fee?

\$11,631

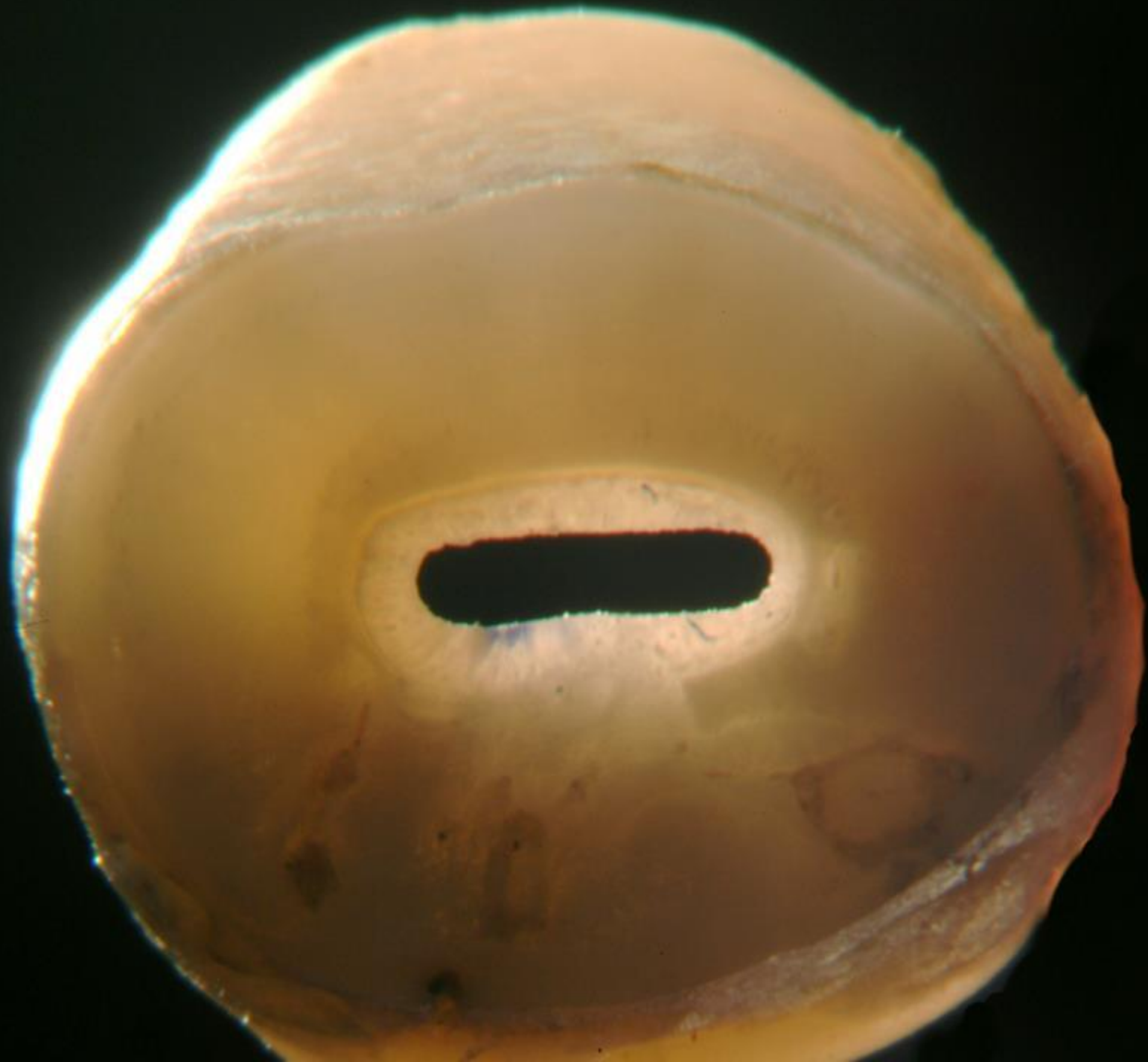


**ONE OF THE ENDURING
FIRST IMPRESSIONS OF
CLINICAL MICROSCOPE
DENTISTRY IS THE
STAGGERING ARRAY OF
CRACKS THAT ARE
SUDDENLY VISIBLE**

Clark, D.J., Paquette J., Sheets C., *Journal of Esthetic and Restorative
Dentistry*; Special Edition, 2004

Nature does
nothing
uselessly.

Aristotle 322 BC

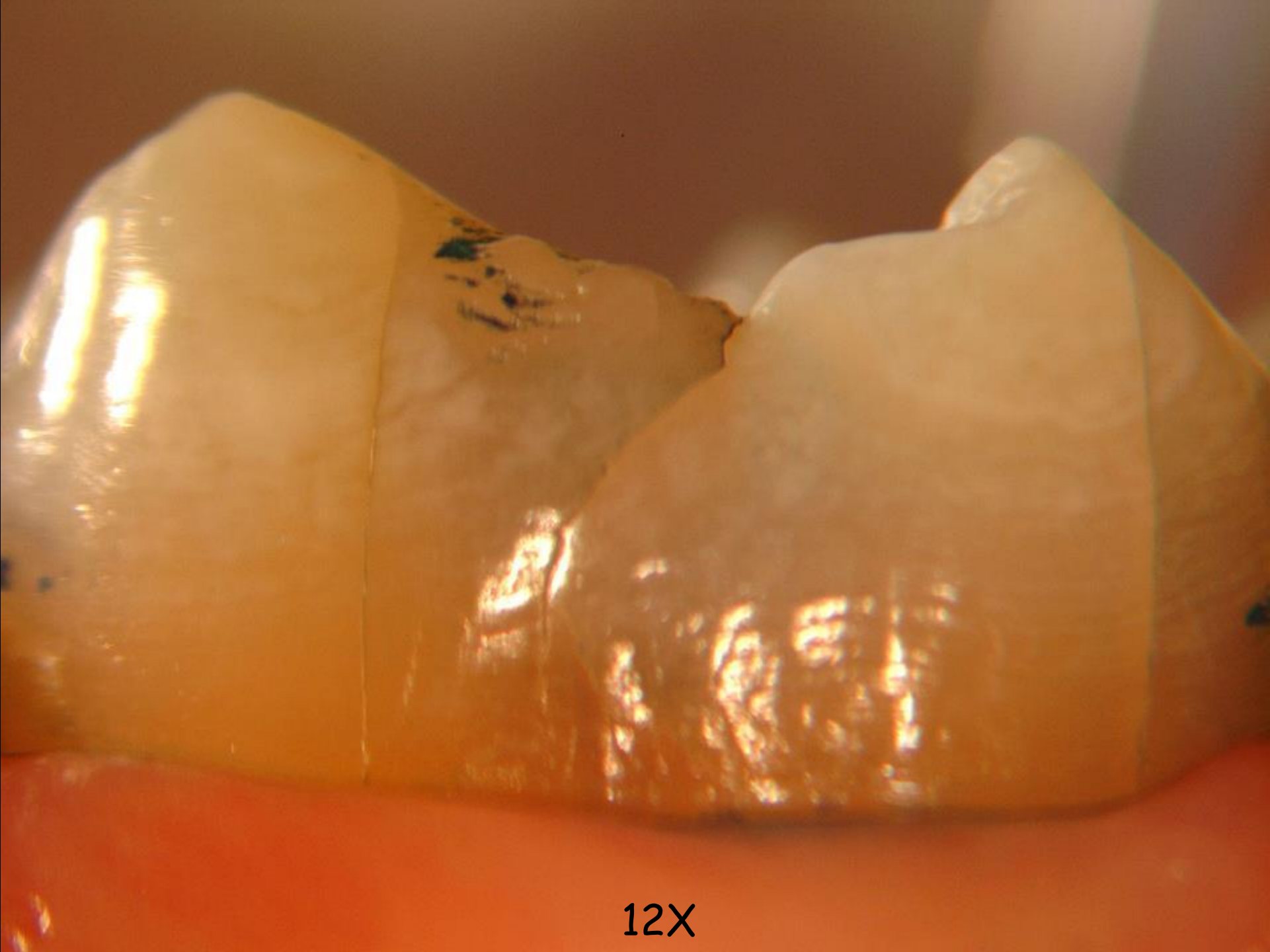


Enamel and dentin have radically different physical characteristics, as do their corresponding cracks.

A close-up photograph of a tooth, likely a maxillary premolar, showing a vertical crack that extends through the enamel and into the dentin. The crack is clearly visible as a dark line. The tooth is set against a dark background, and the lighting highlights the texture and color of the enamel and dentin. The text is overlaid on the upper portion of the image.

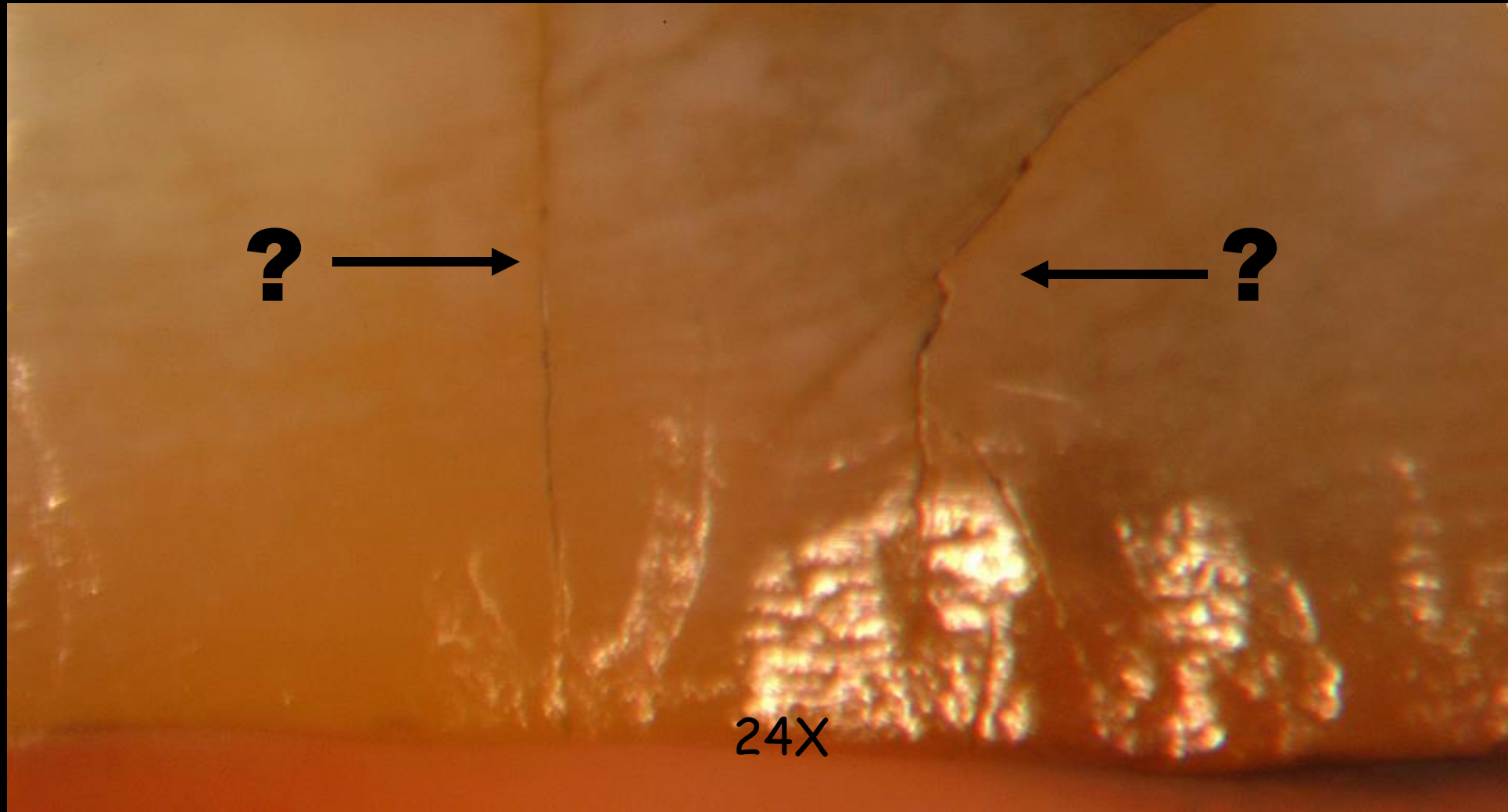
Enamel and dentin have radically different physical characteristics, as do their corresponding cracks.

12X



12X

Which enamel crack is "native", which crack is indicative of underlying pathology?



JOURNAL OF ESTHETIC AND RESTORATIVE DENTISTRY

Official Publication of the American Academy of Esthetic Dentistry,
Japan Academy of Esthetic Dentistry, International Federation of Esthetic Dentistry,
American Academy of Cosmetic and Adhesive Dentistry,
British Academy of Esthetic Dentistry, Dutch Academy of Esthetic Dentistry,
and the Scandinavian Academy of Esthetic Dentistry

www.bdecker.com

Definitive Diagnosis of Early Enamel and Dentinal Cracks Based on Microscopic Evaluation

DAVID J. CLARK, DDS,
DORLAND G. SMITH, DDS,
JACQUELINE BARTLEY, DDS

ABSTRACT

The diagnosis of cracked tooth and incomplete coronal fracture have historically been symptomatic. The dental operating microscope at 40× magnification can fundamentally change a clinician's ability to diagnose such conditions.

Clinicians have been observing cracks under extreme magnification to be merely cosmetic. Patients are becoming dentists who lack an appropriate treatment plan or symptoms or deterioration in tooth structure occur. Generally, many cracks are not structural and can locate microleakage and overextension. Methodologic microscopic examination, an understanding of crack progression, and an appreciation of the types of cracks will guide a clinician in making appropriate decisions.

Teeth can have structural cracks in various stages. To date, diagnosis and treatment are very subjective and range of crack descriptions.

CLINICAL SIGNIFICANCE

This article gives new guidelines for recognition, classification, and treatment of cracked teeth based on the routine use of 40× magnification. The significance of enamel cracks is they where no critical cracks is detailed.

J Esthet Restor Dent 16:XXX-XXX, 2004

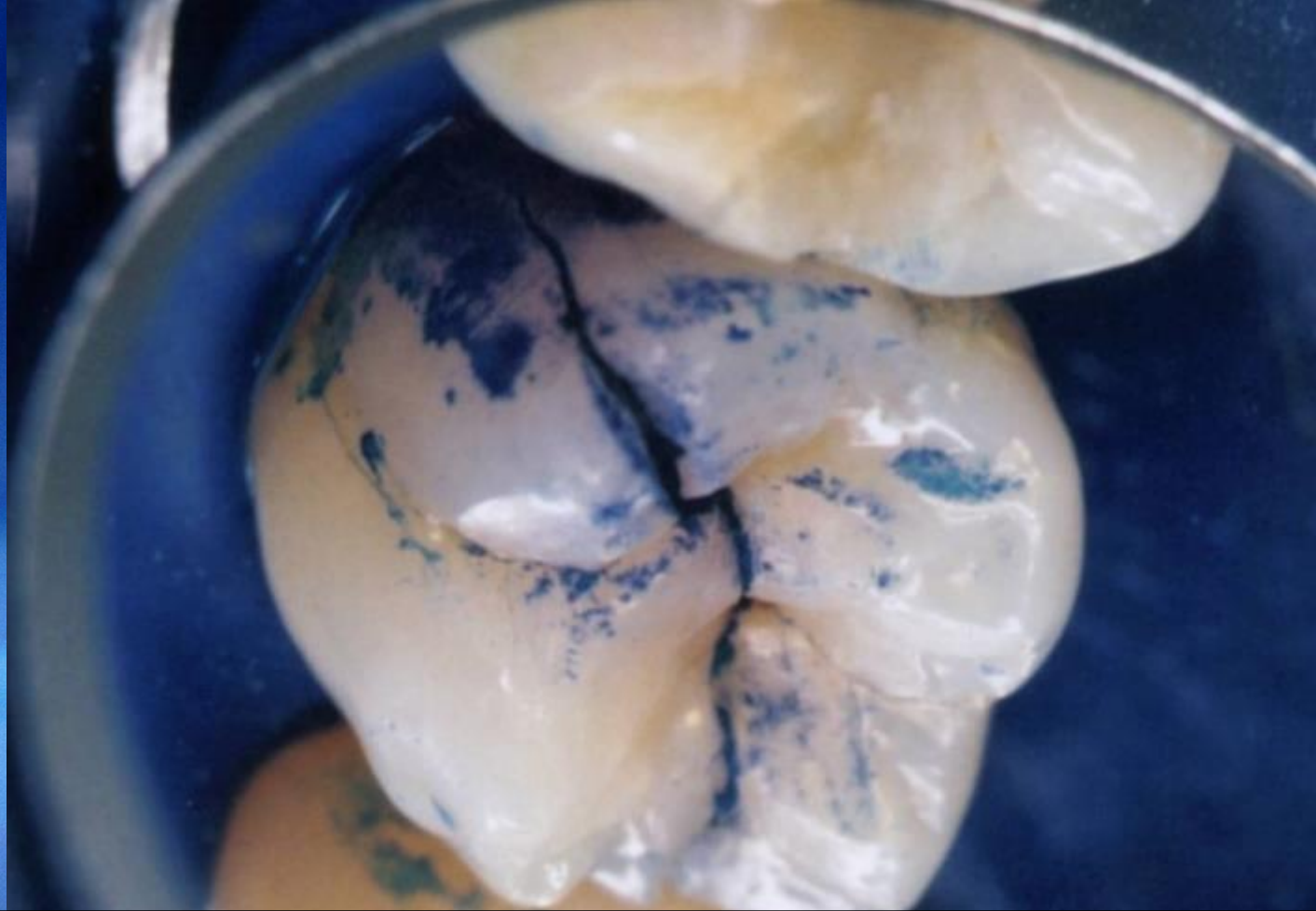
Microscopic and symptomatic diagnoses have been the accepted modalities for cracked teeth. The inherent limitations of the lack of visual confirmation result in therapies that often come out late in the treatment process. One limiting factor, irrespective of vision through a clinical microscope is the enlarging array of cracks that color visible tooth structures. Traditional visualization (unaided

or ocular) cannot reliably distinguish the presence or severity of the majority of these cracks (Figure 1A).

At extreme magnification levels (40× and greater), the translucent nature of enamel yields a wealth of information, such as color changes within the enamel may indicate early decay, microleakage, and a lack of structural integrity of dentin and

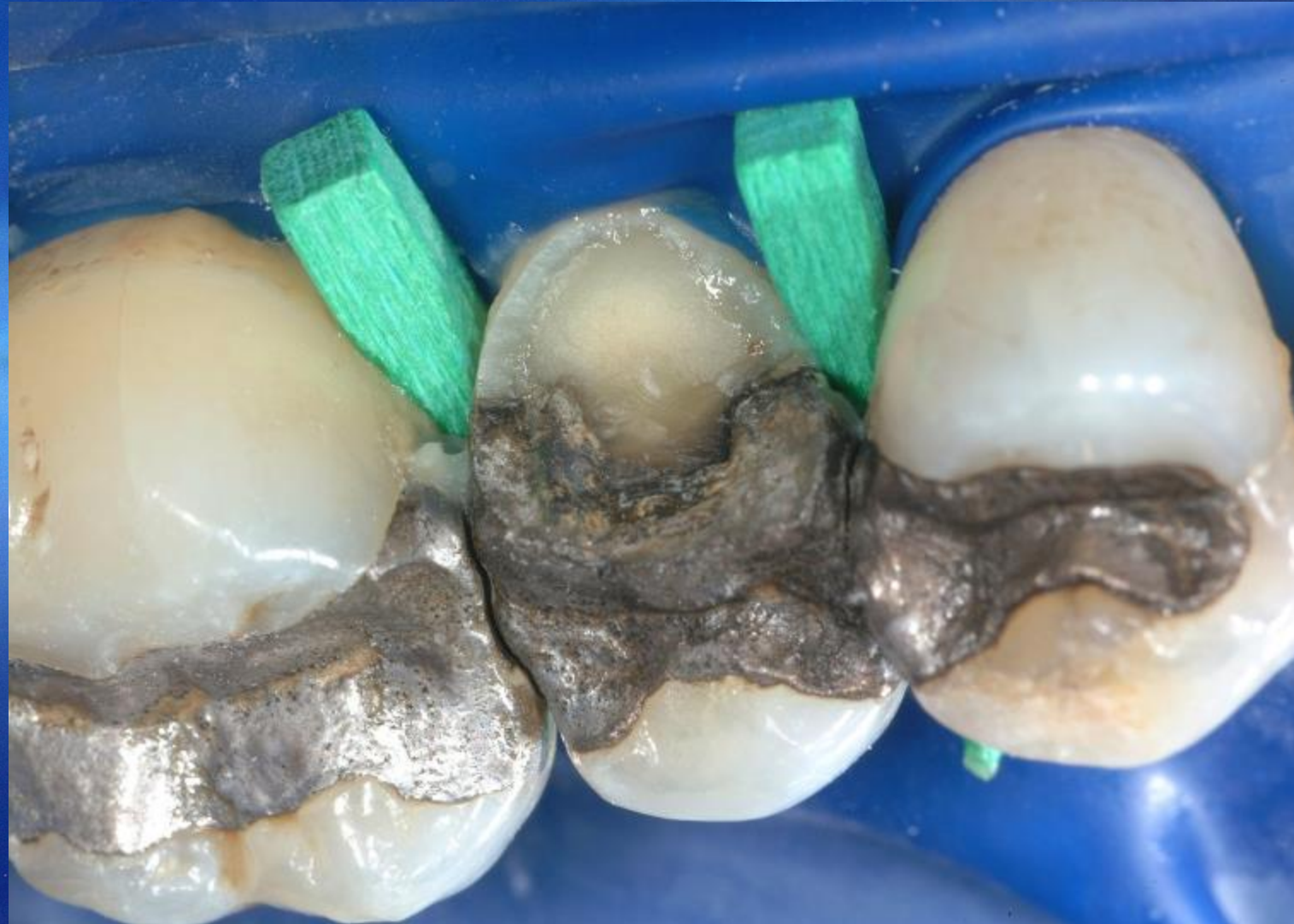enamel. Being able to see previously invisible decay can aid restorative decisions to more appropriate early treatment of compromised teeth before desiccating, traumatic, pulp involvement, and periodontal breakdown occur. The value of early diagnosis of the structural breakdown of teeth will become even more significant with our aging population coupled with increasing tooth retention in this population.

¹President, Academy of Microscopic Oral and Esthetic Dentistry
²Consultant, American Academy of Esthetic Dentistry, Newport Beach, CA; Clinical Professor of Restorative Dentistry, USC School of Dentistry, Los Angeles, CA, USA
³Consultant, American Academy of Esthetic Dentistry, Newport Beach, CA; Associate Professor, Restorative Dentistry, USC School of Dentistry, Los Angeles, CA, USA

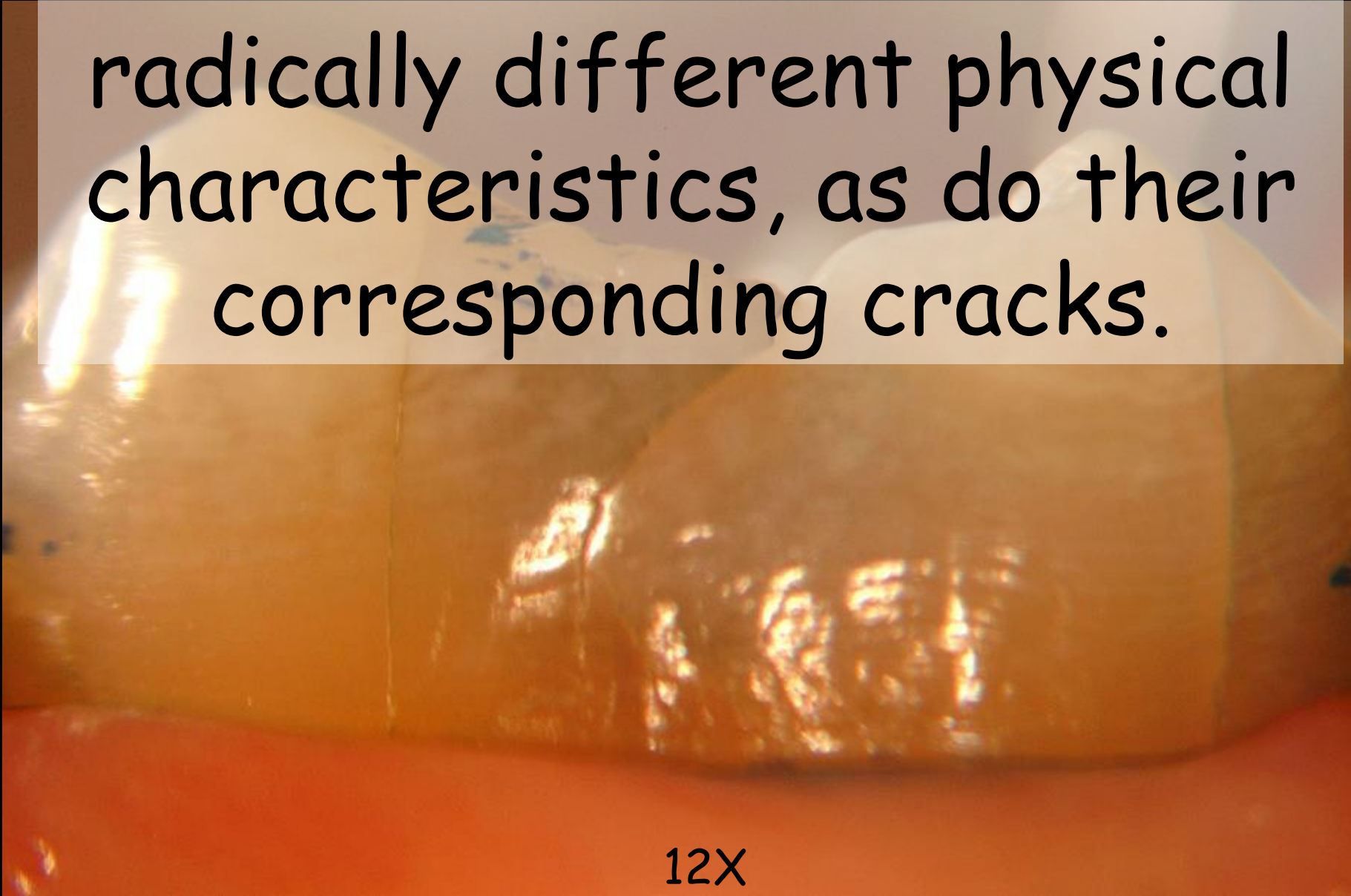


Vertical Crack End Stage:
Complete Tooth Fracture
(split tooth)

Endstage Oblique Fracture Cuspal Fracture

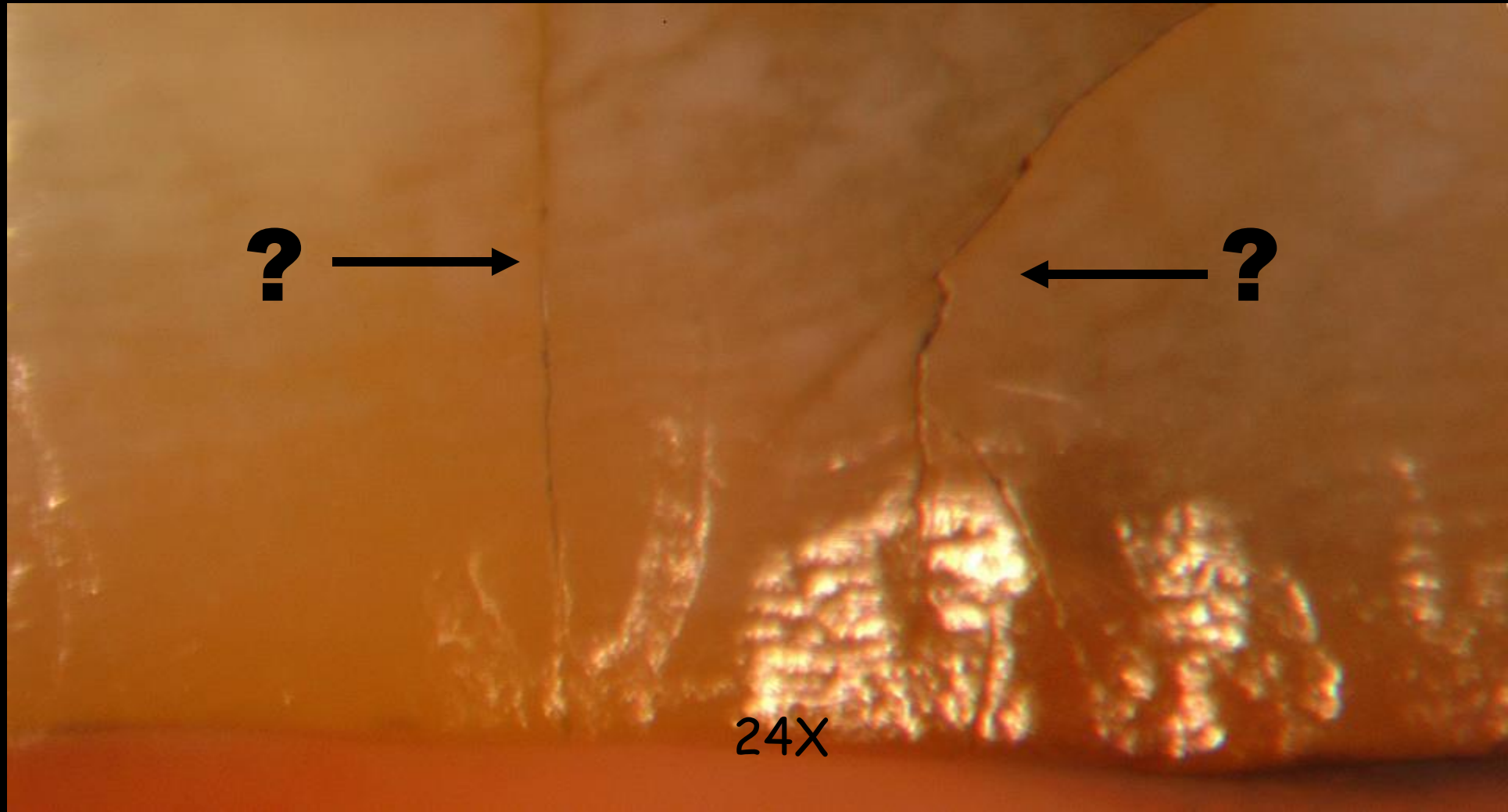


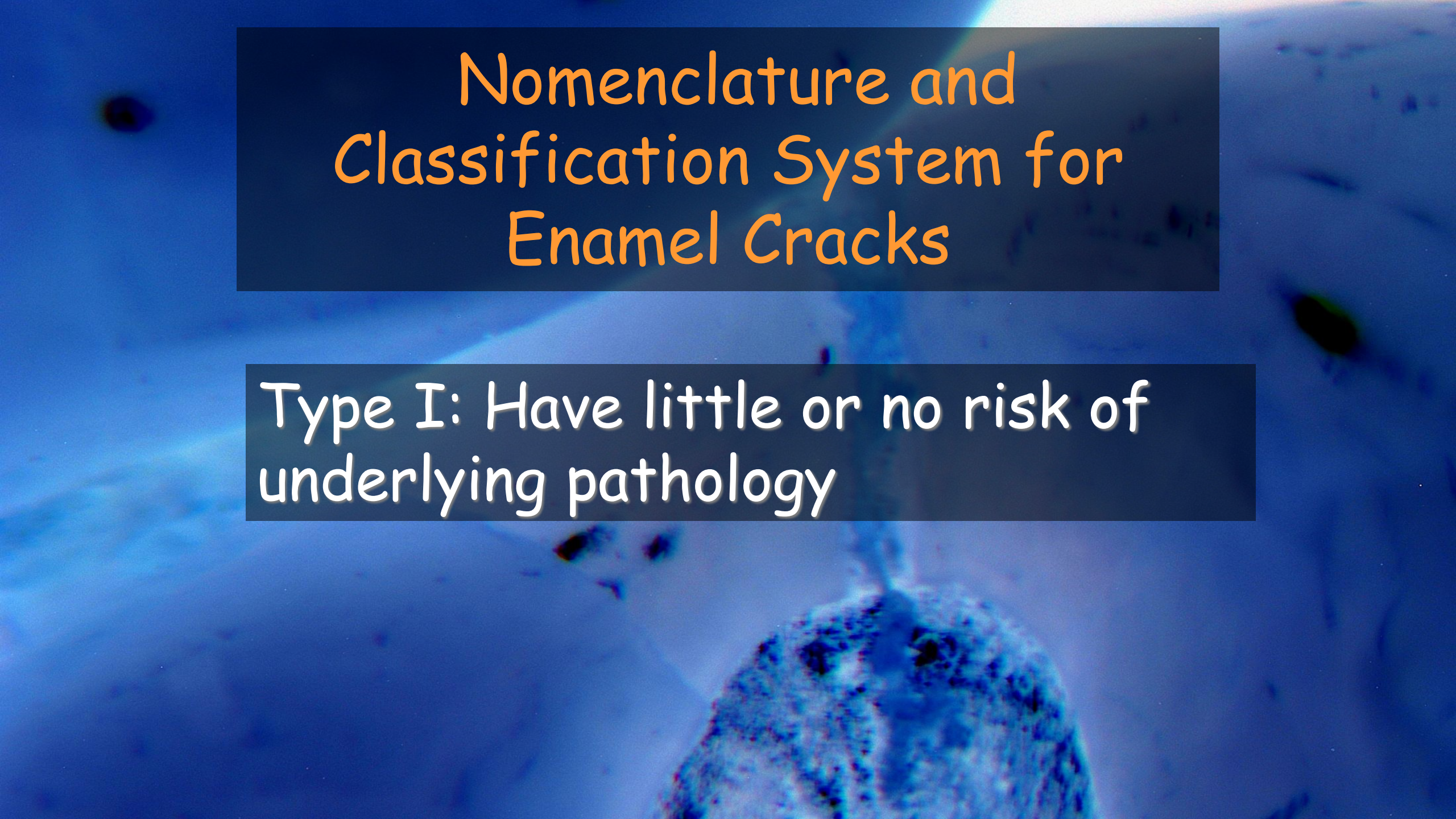
Enamel and dentin have radically different physical characteristics, as do their corresponding cracks.



12X

Which enamel crack is "native", which crack is indicative of underlying pathology?



A microscopic image of an enamel crack, showing a dark, irregularly shaped crack running through the enamel structure. The crack is surrounded by a lighter, more crystalline material. The overall image has a blueish tint.

Nomenclature and Classification System for Enamel Cracks

Type I: Have little or no risk of
underlying pathology

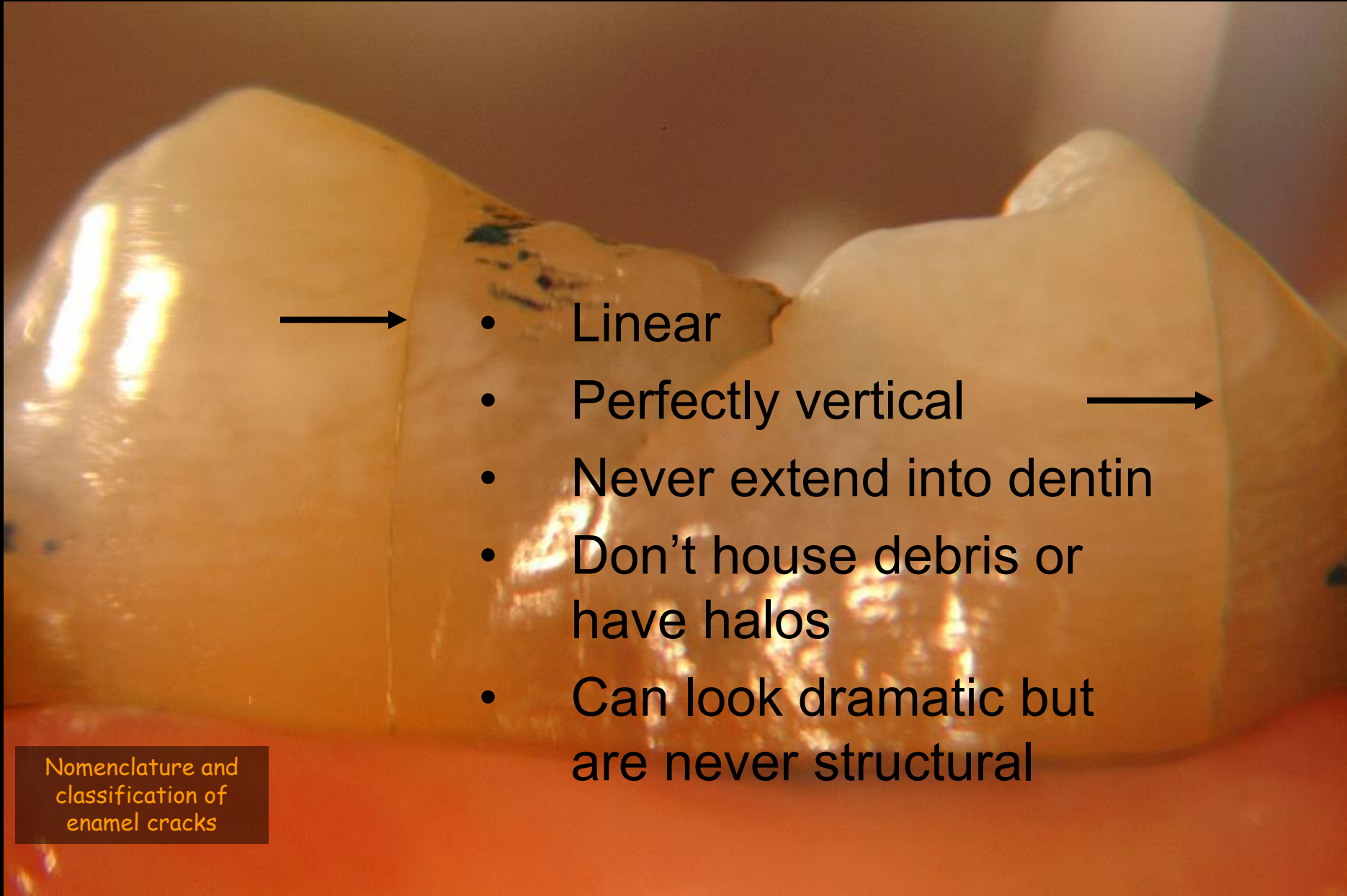
Type I: Have little or no risk of underlying pathology

- A) Craze lines
- B) Small vertical cracks
- C) Cracks that follow natural anatomic grooves
- D) Cracks with superficial stain penetration

Type I: Have little or no risk of underlying pathology

- F) Cracks Resulting from Polymerization Shrinkage of Composite
- G) Enamel Crackling in Aging, Thin, Cervical Enamel

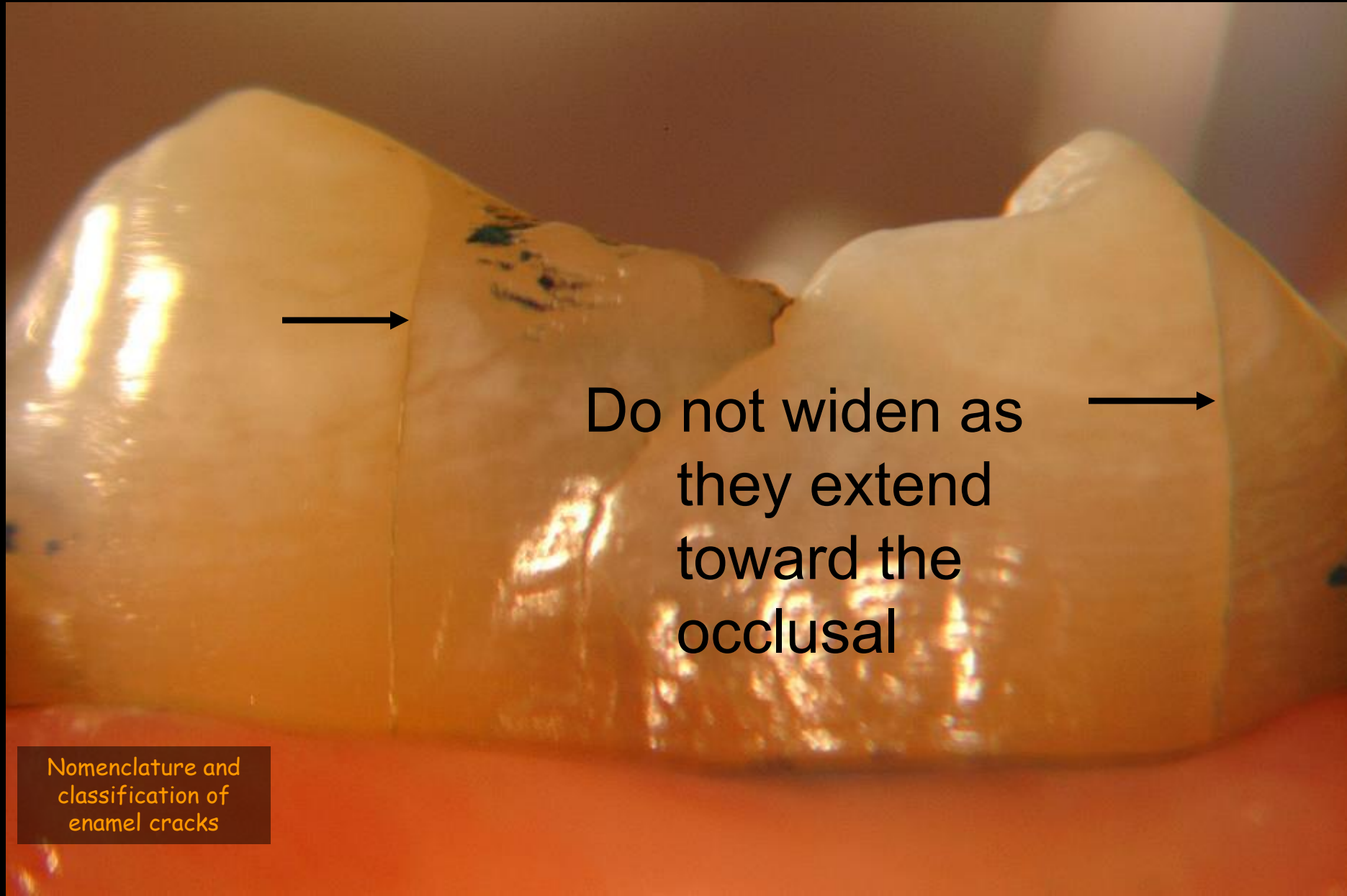
Craze Lines



- Linear
- Perfectly vertical
- Never extend into dentin
- Don't house debris or have halos
- Can look dramatic but are never structural

Nomenclature and
classification of
enamel cracks

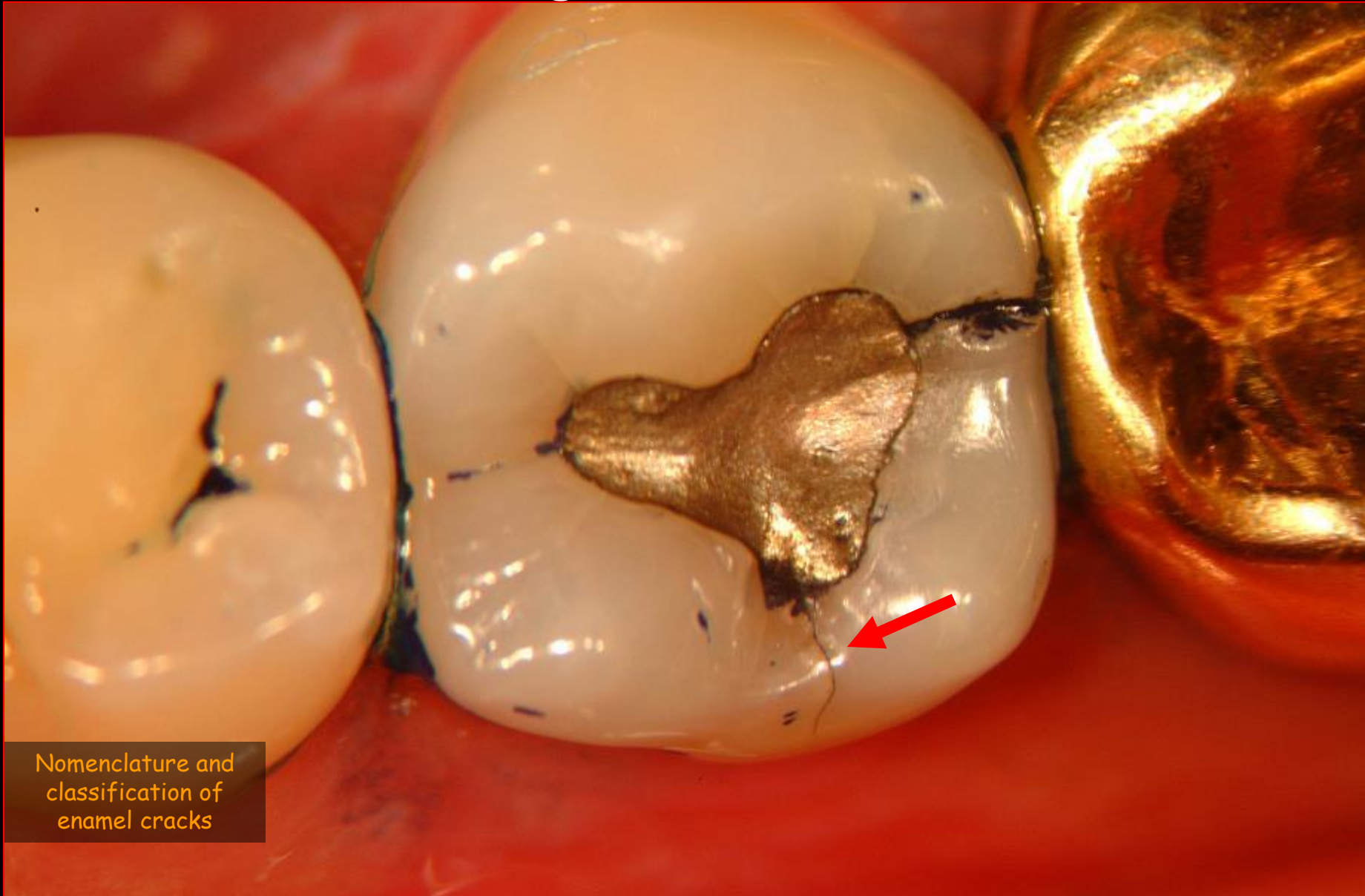
Craze Lines



Do not widen as
they extend
toward the
occlusal

Nomenclature and
classification of
enamel cracks

C. Cracks that follow anatomic grooves

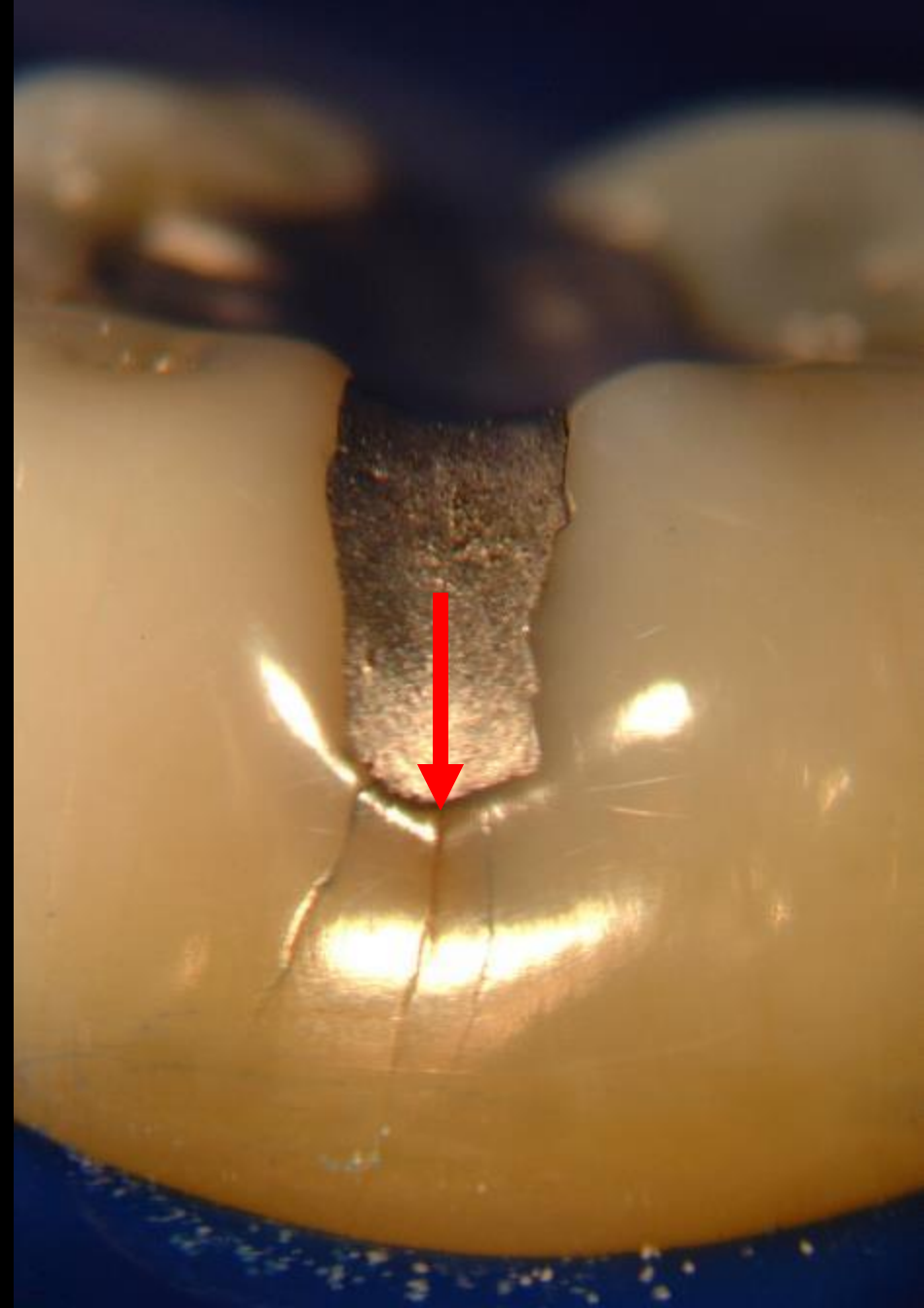


Nomenclature and
classification of
enamel cracks

C. Cracks that follow natural anatomic grooves

D Superficially Stained Cracks

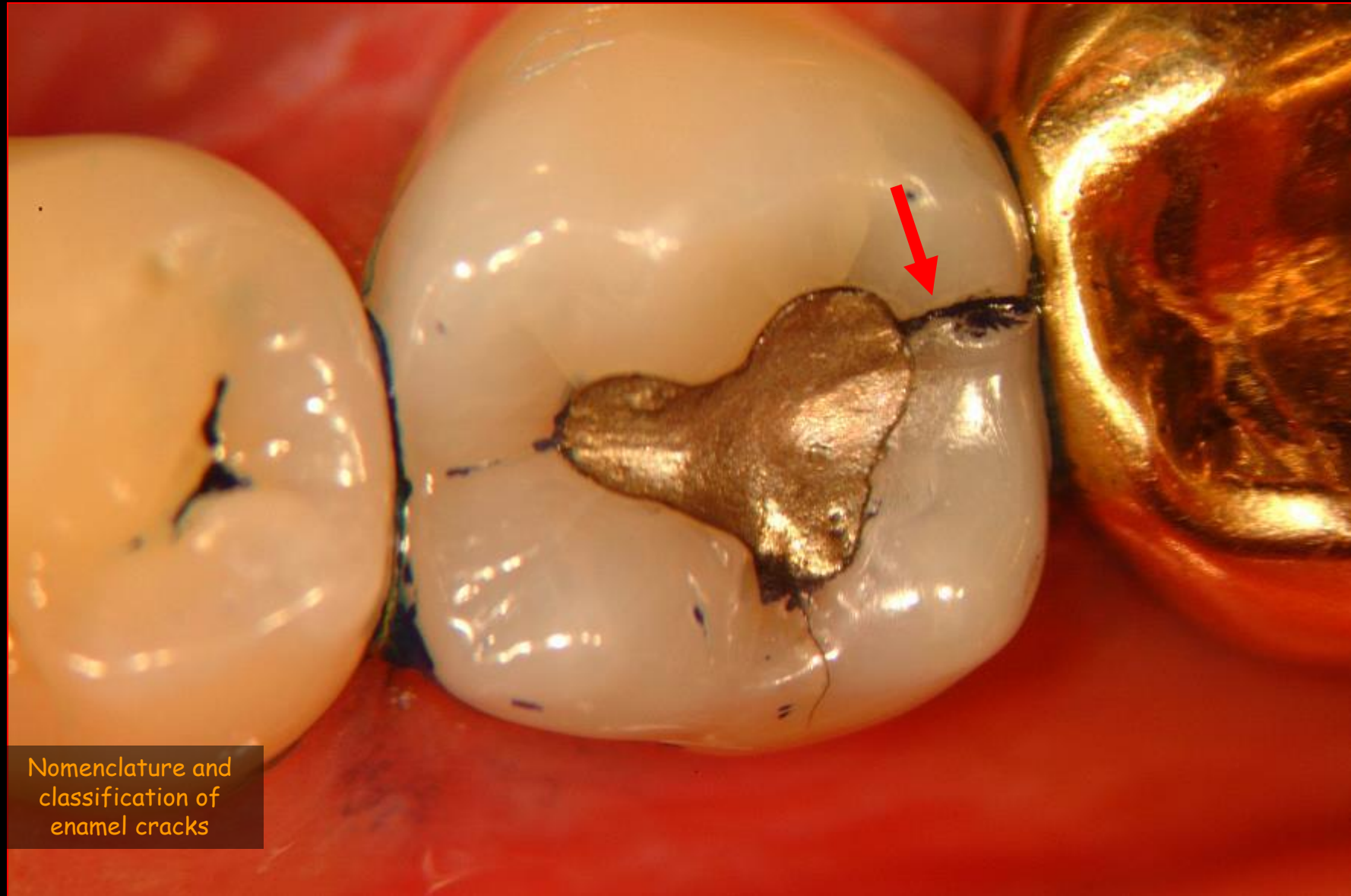
Nomenclature and
classification of
enamel cracks



Type II: Have moderate risk of underlying pathology

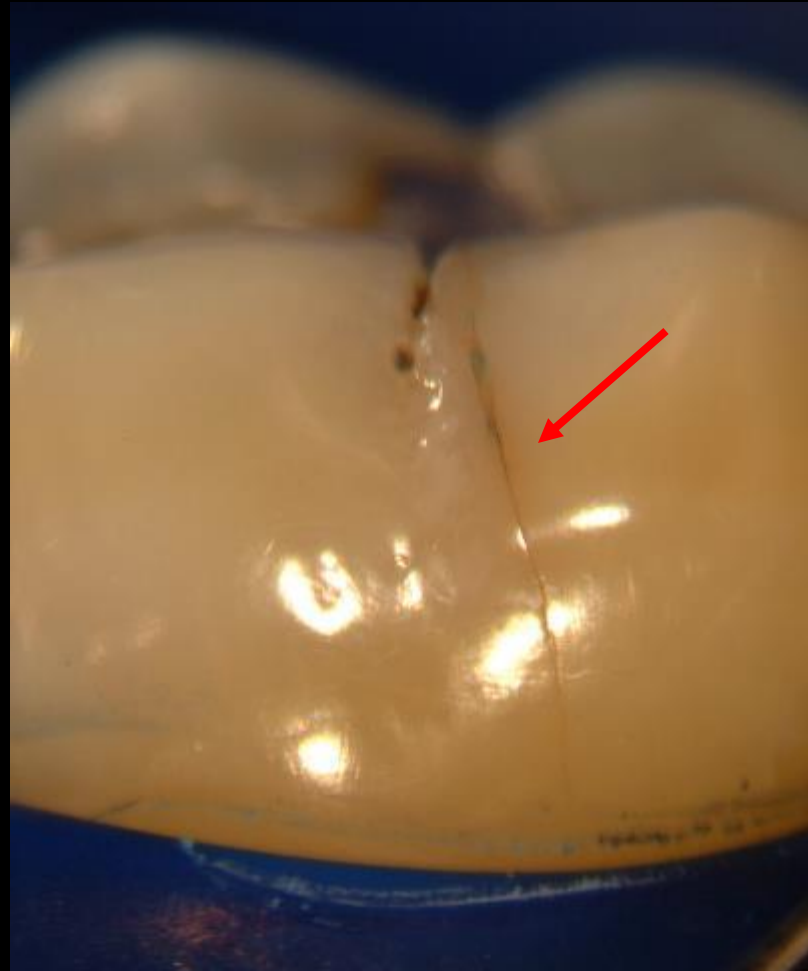- A) V-shaped enamel ditching with no adjoining restoration often associated with a wear facet centered over an otherwise benign crack
- B) V-shaped enamel ditching with a prior restoration often associated with a wear facet centered over an otherwise benign crack
- C) Cracks that detour from or do not follow natural anatomic grooves

B. V shaped ditching



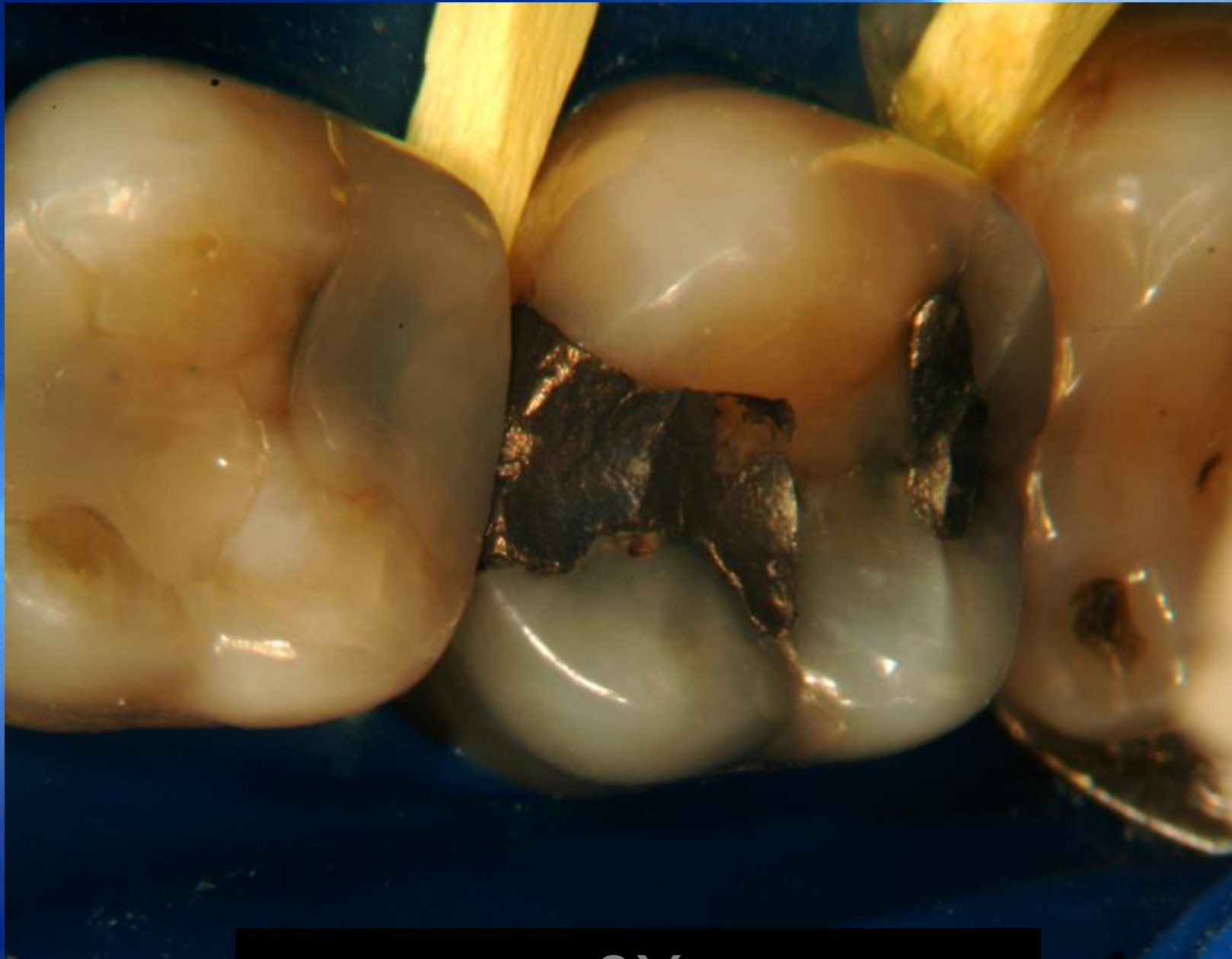Nomenclature and
classification of
enamel cracks

C. Non linear cracks that detour from or do not follow natural anatomic grooves



Type II: Have moderate risk of underlying pathology

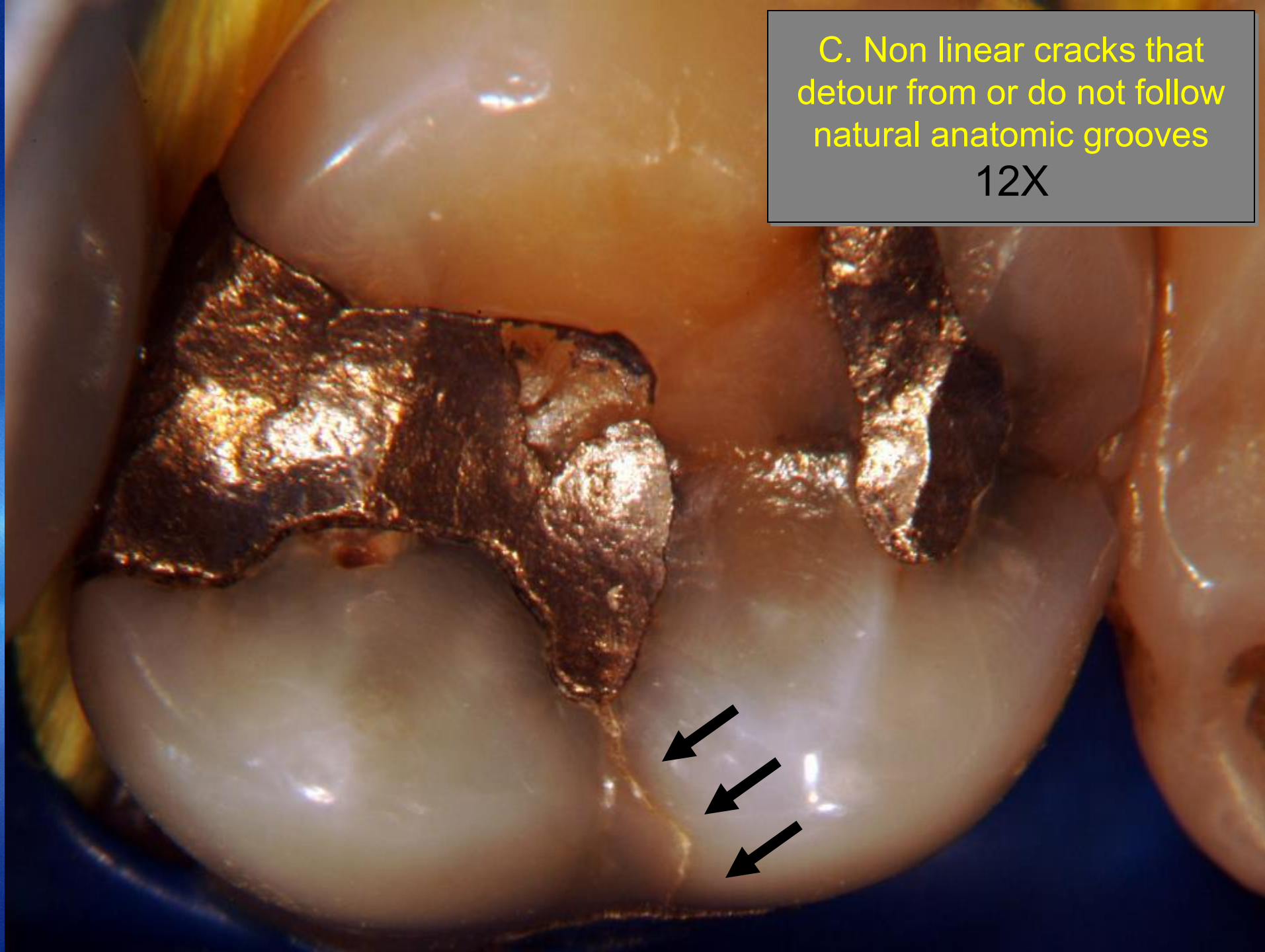
- A) V-shaped enamel ditching with or without an adjoining restoration often associated with a wear facet centered over an otherwise benign crack
- B) Cracks that detour from or do not follow natural anatomic grooves



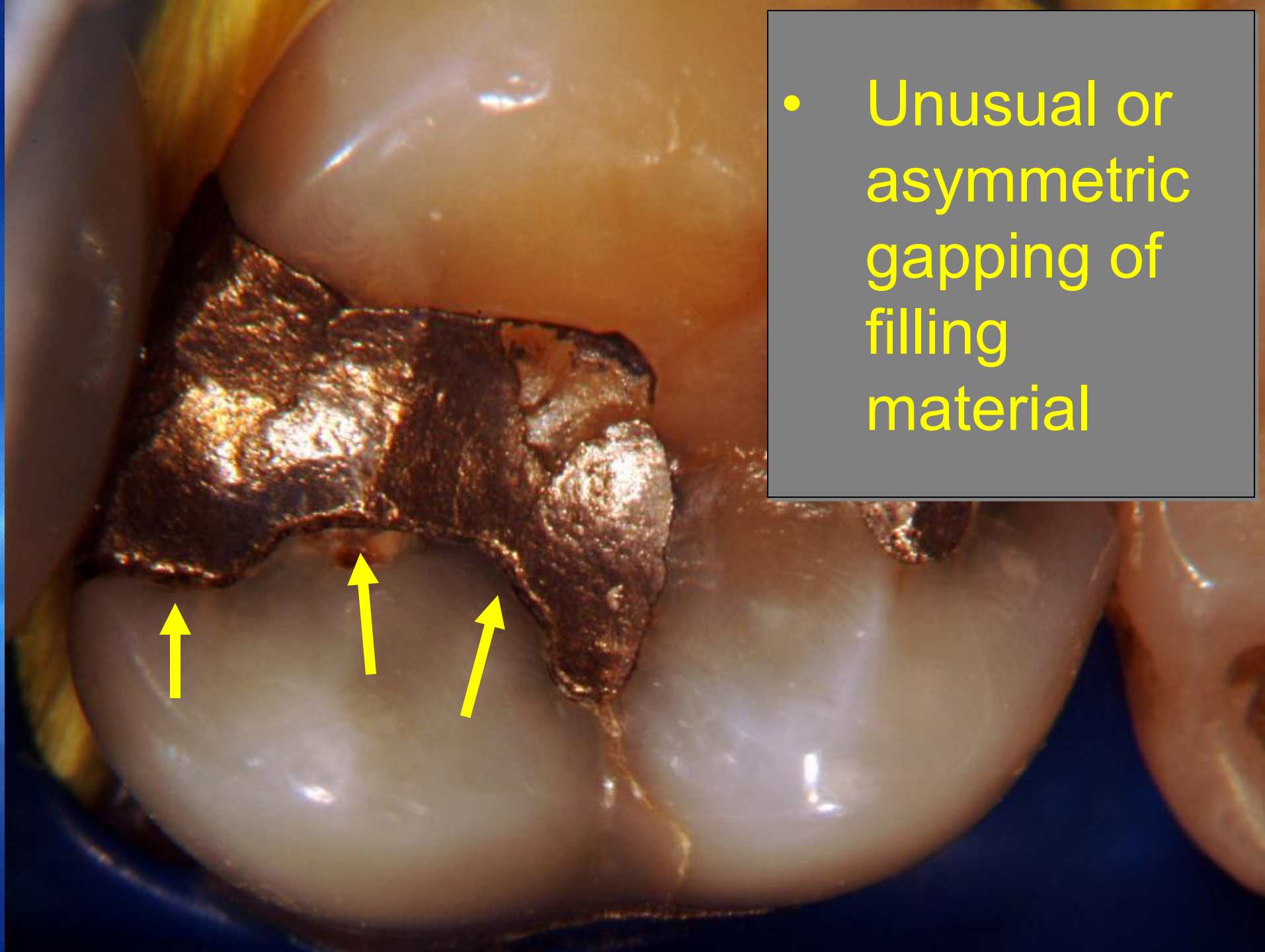
8X

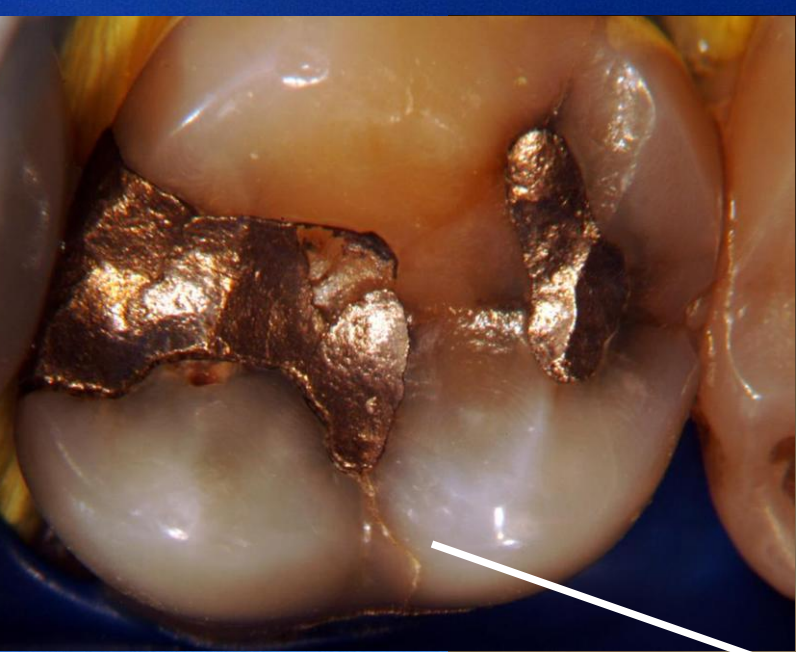C. Non linear cracks that
detour from or do not follow
natural anatomic grooves

12X

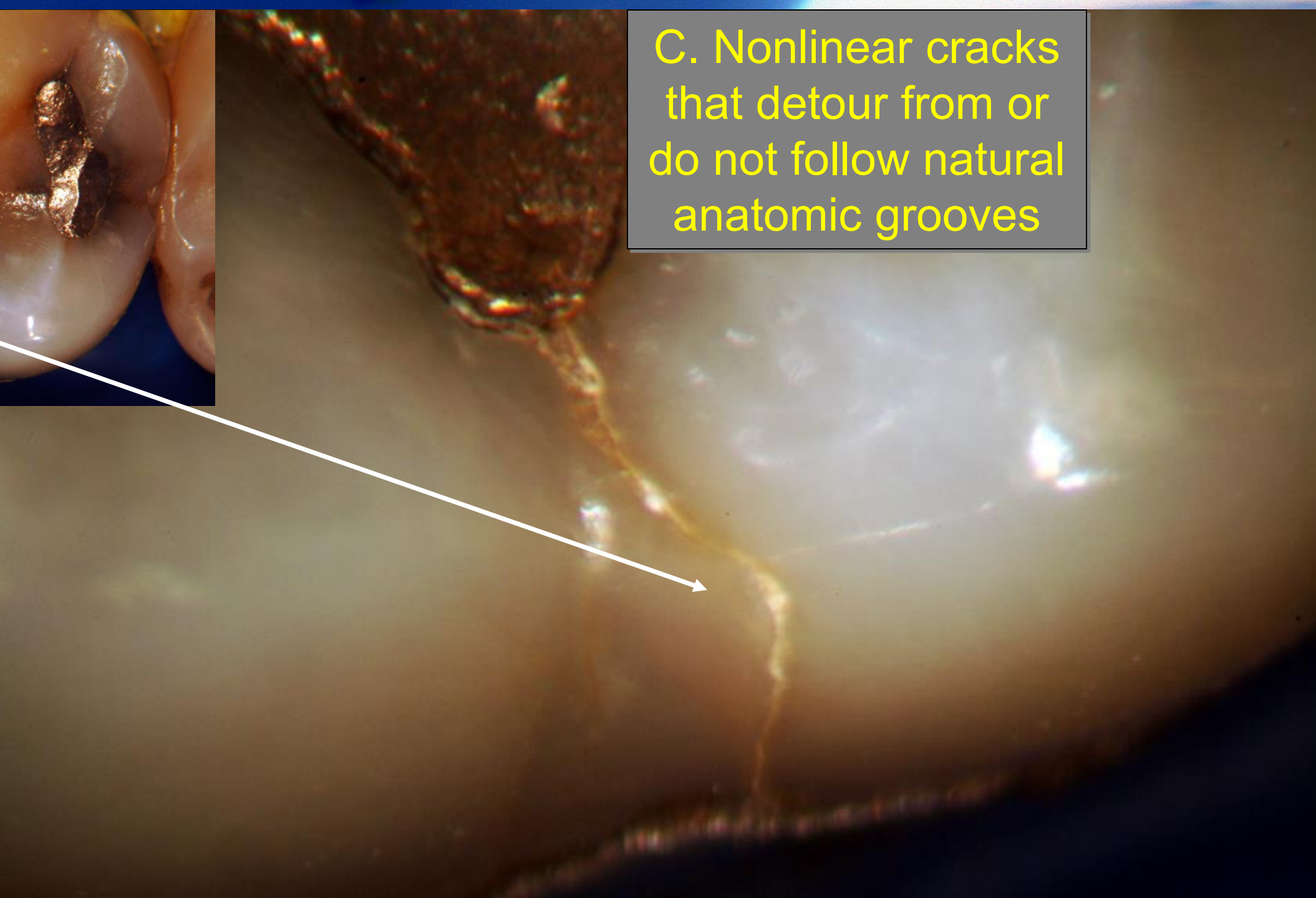


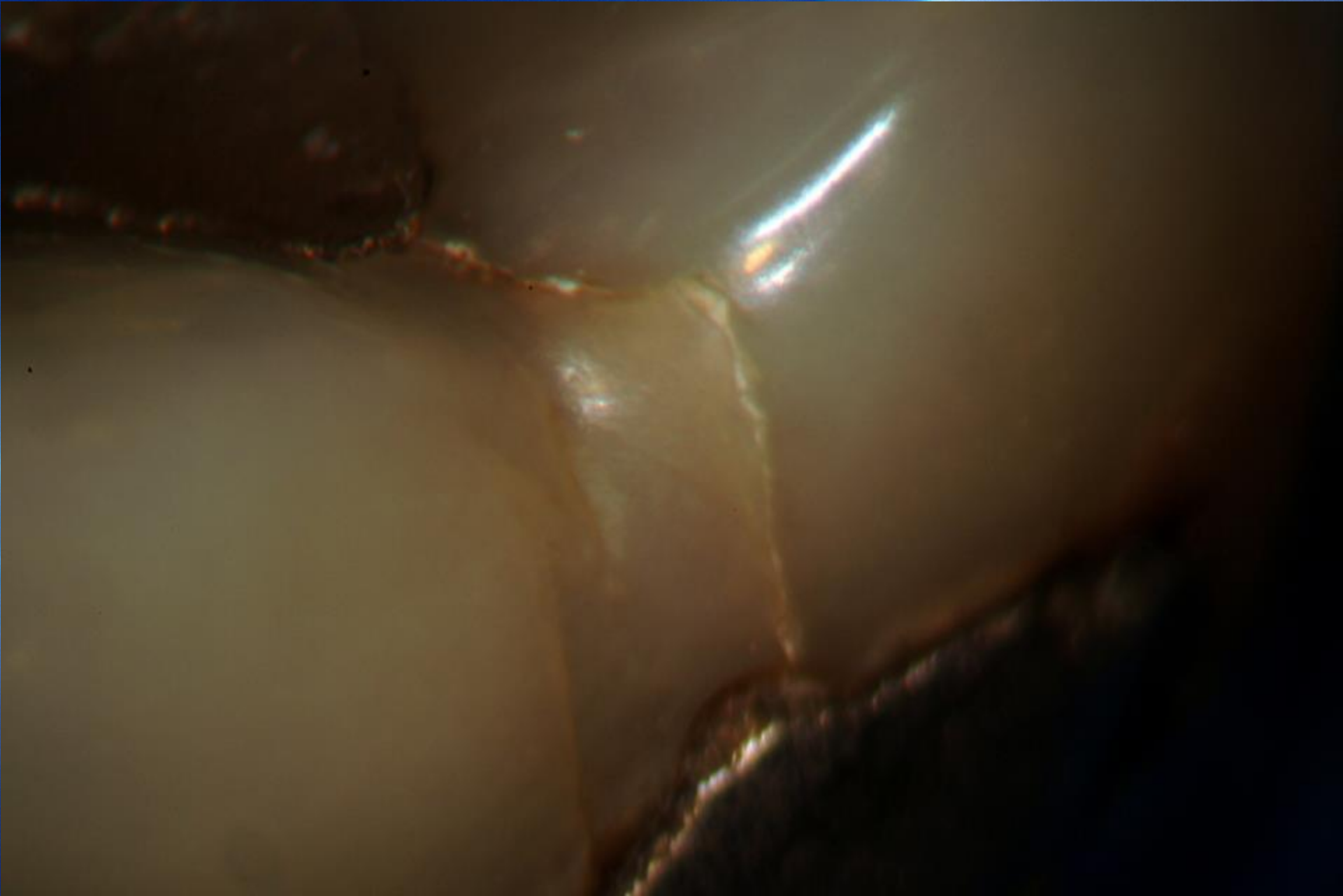
- Unusual or asymmetric gapping of filling material



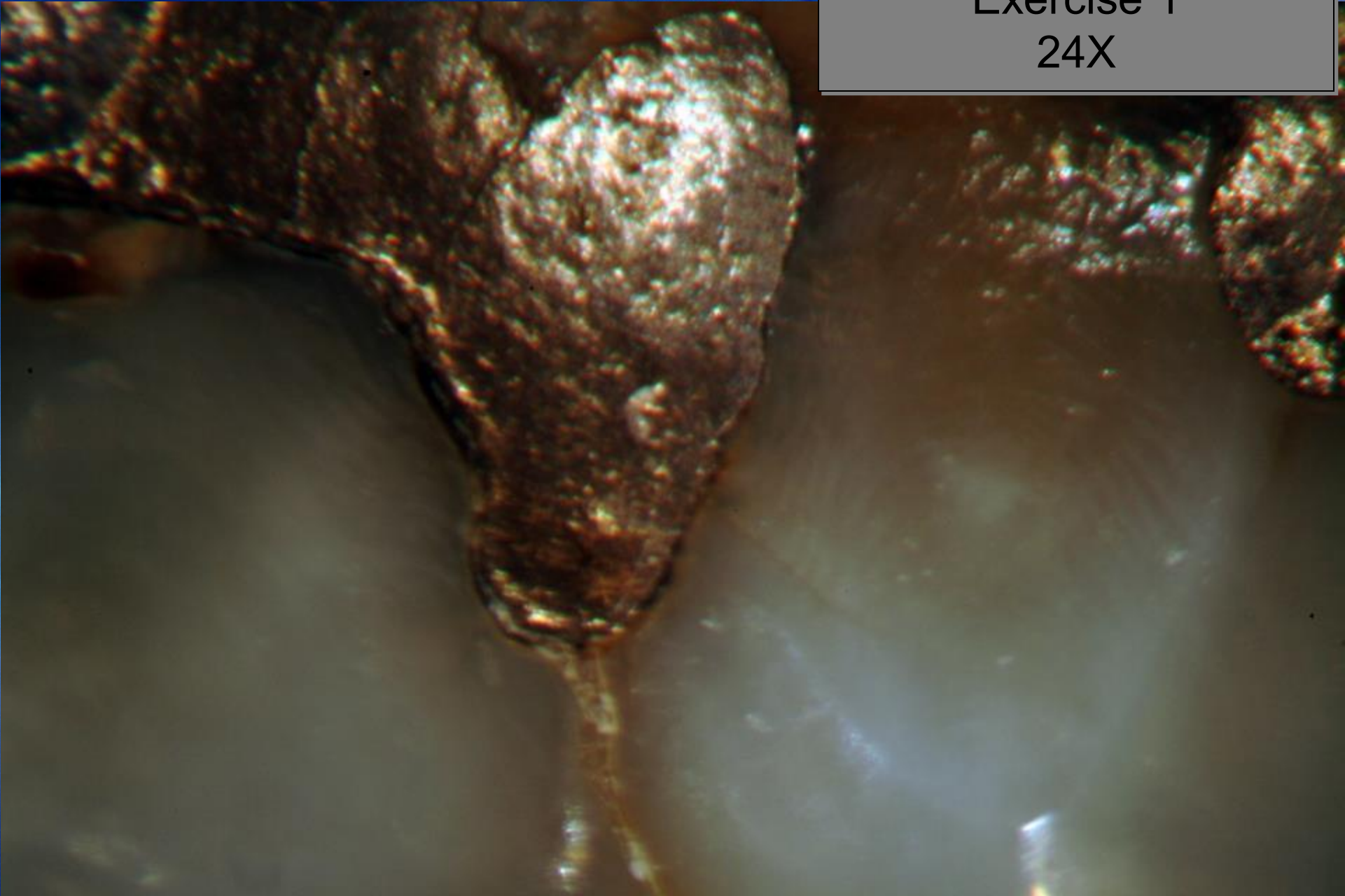


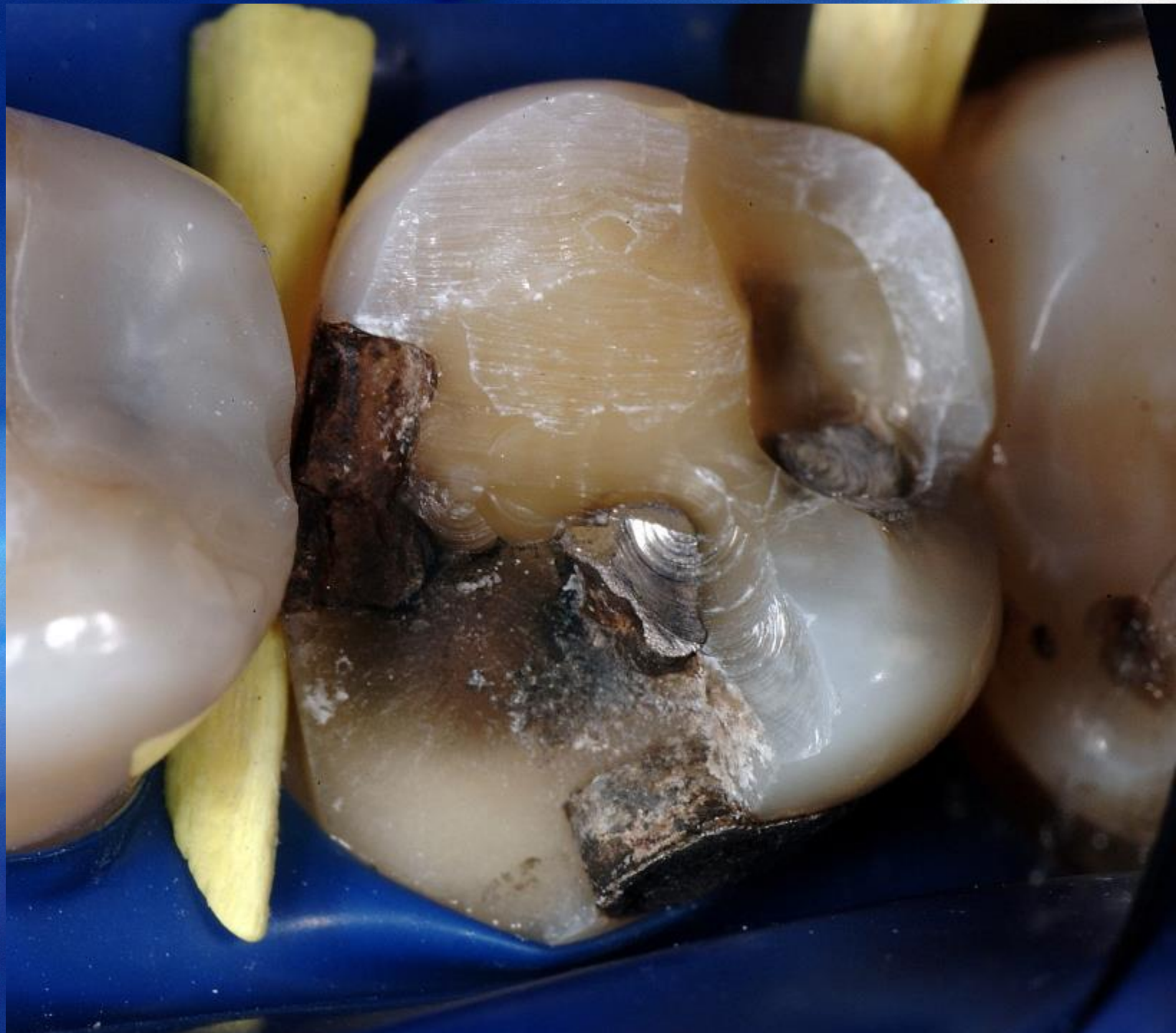C. Nonlinear cracks that detour from or do not follow natural anatomic grooves

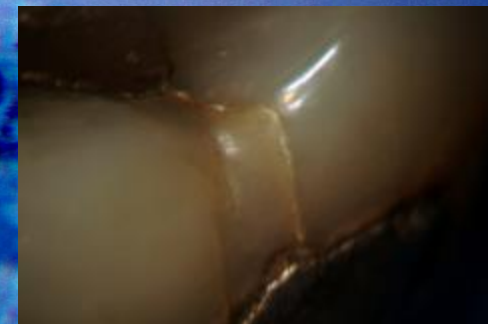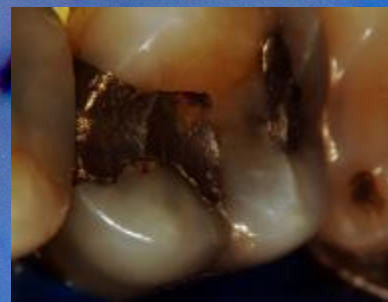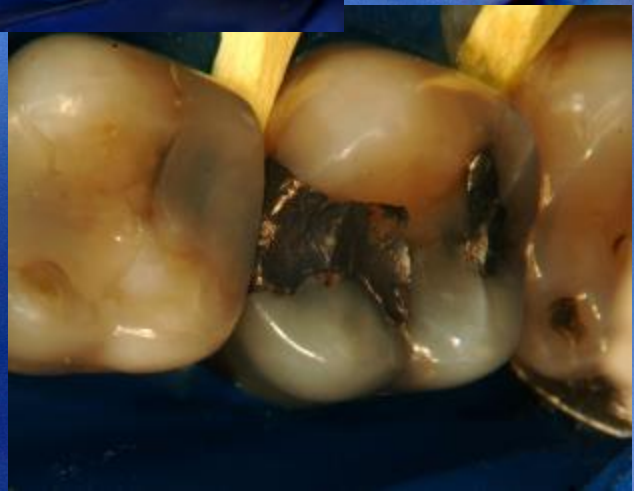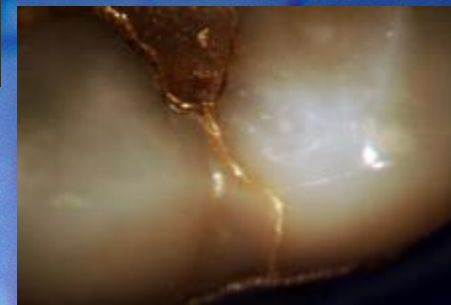
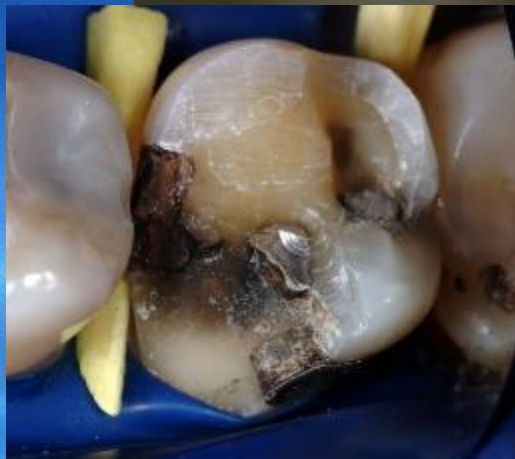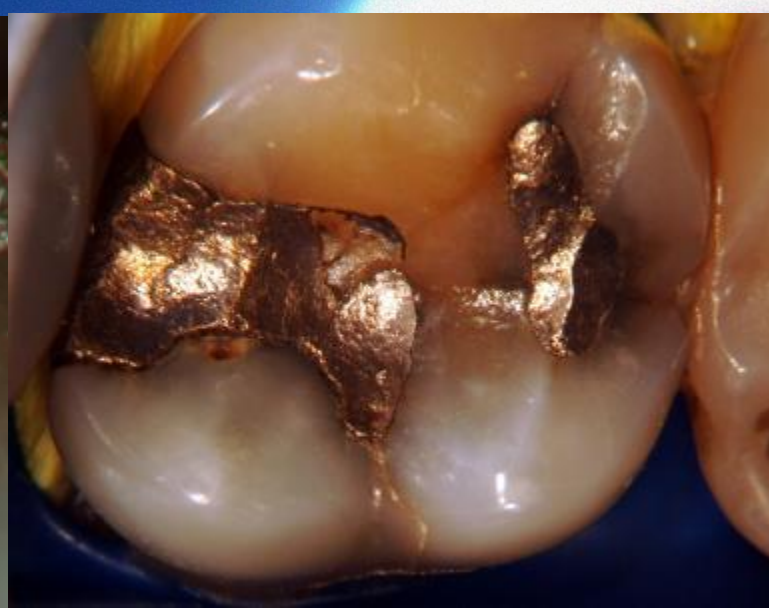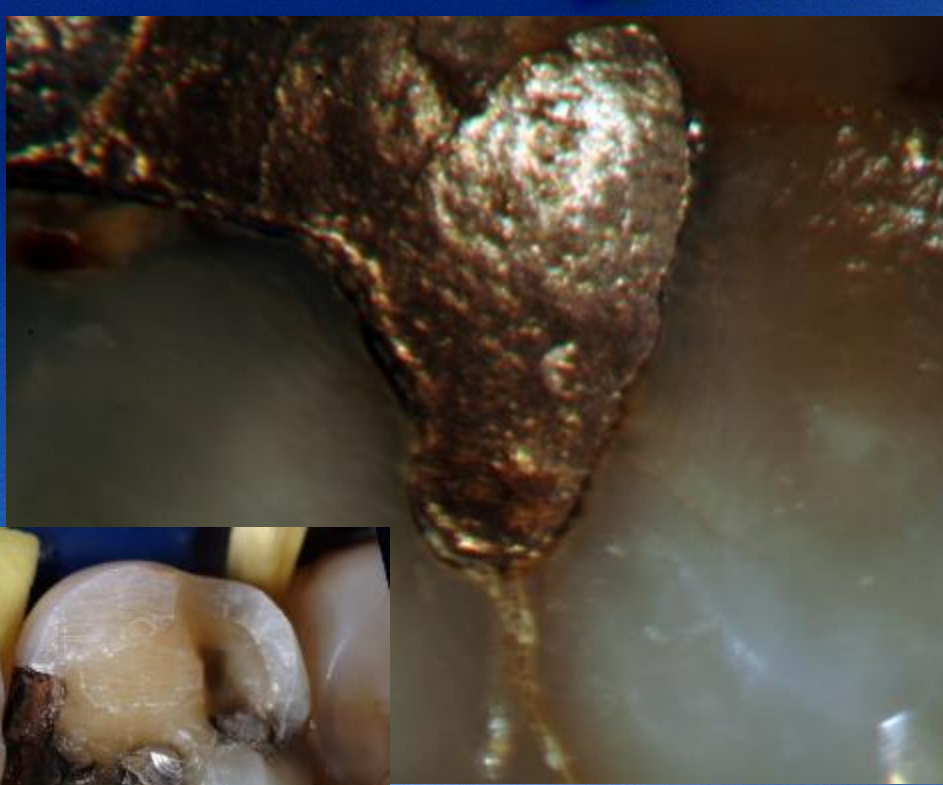




Exercise 1
24X



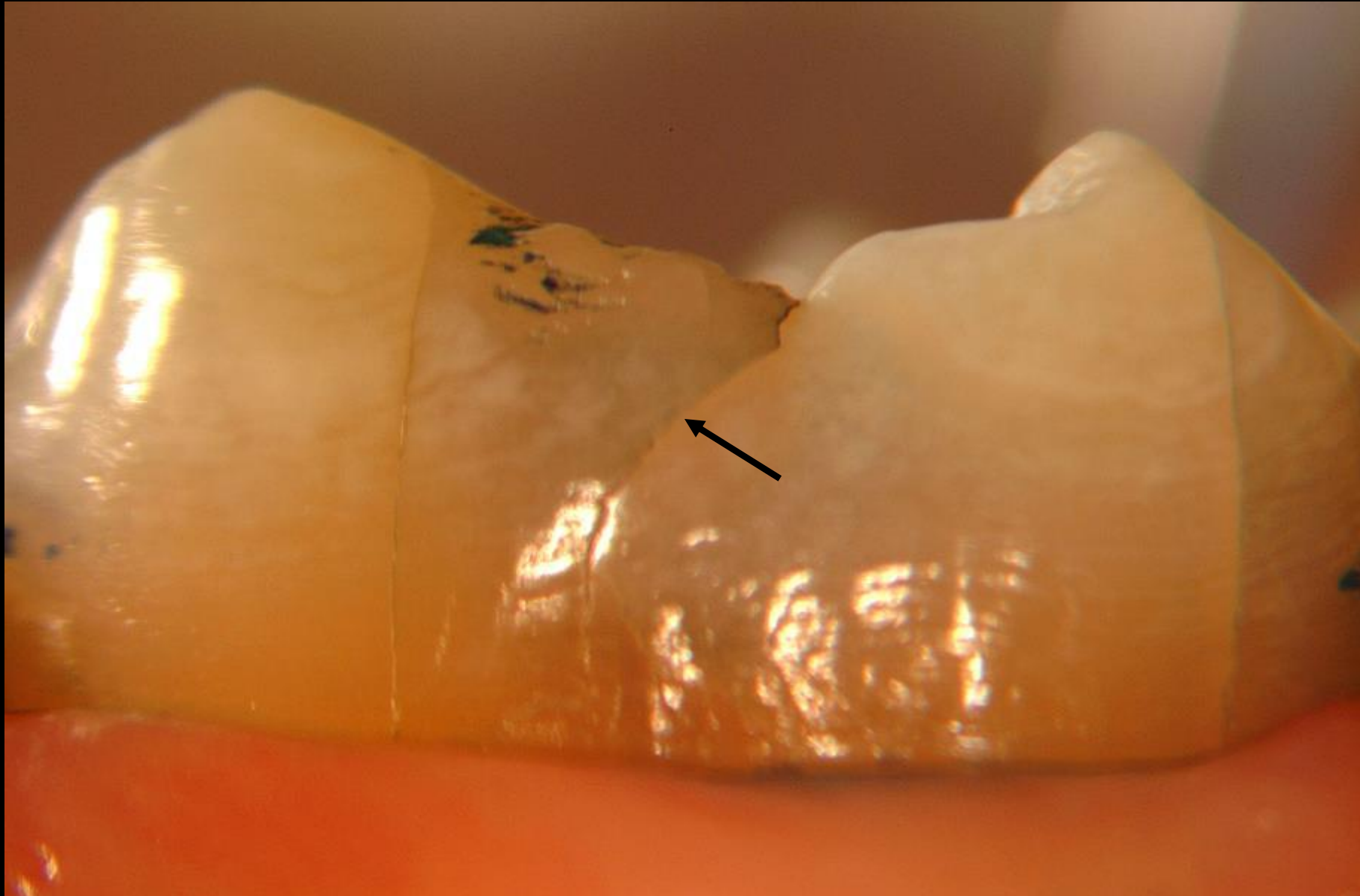




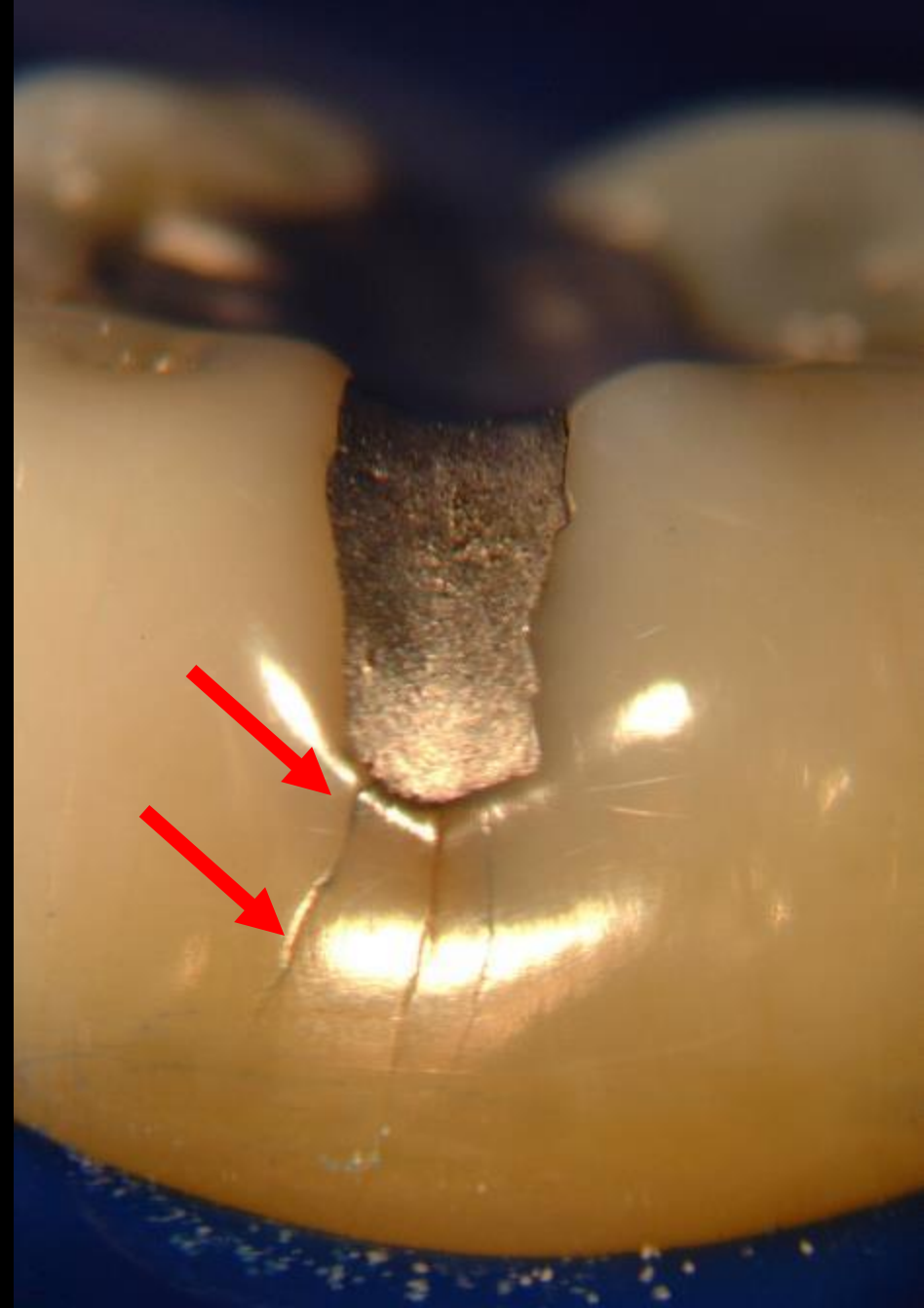
Type III: Have high risk of underlying pathology

- A) Diagonal cracks branching off a vertical crack
- B) Horizontal or diagonal cracks that emanate from the corner of a restoration
- C) Cracks that house debris
- **D) The tooth looks gray**

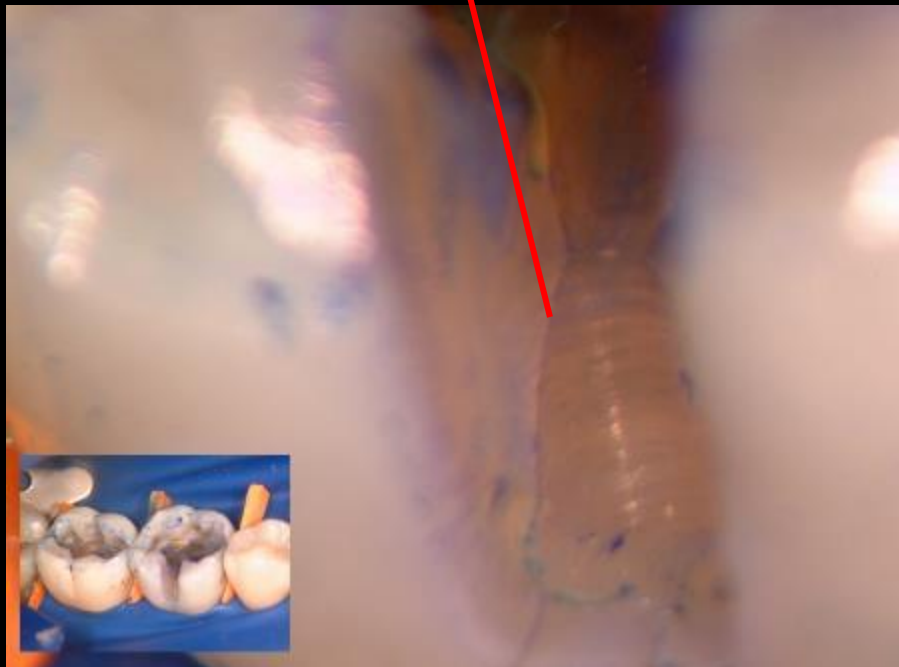
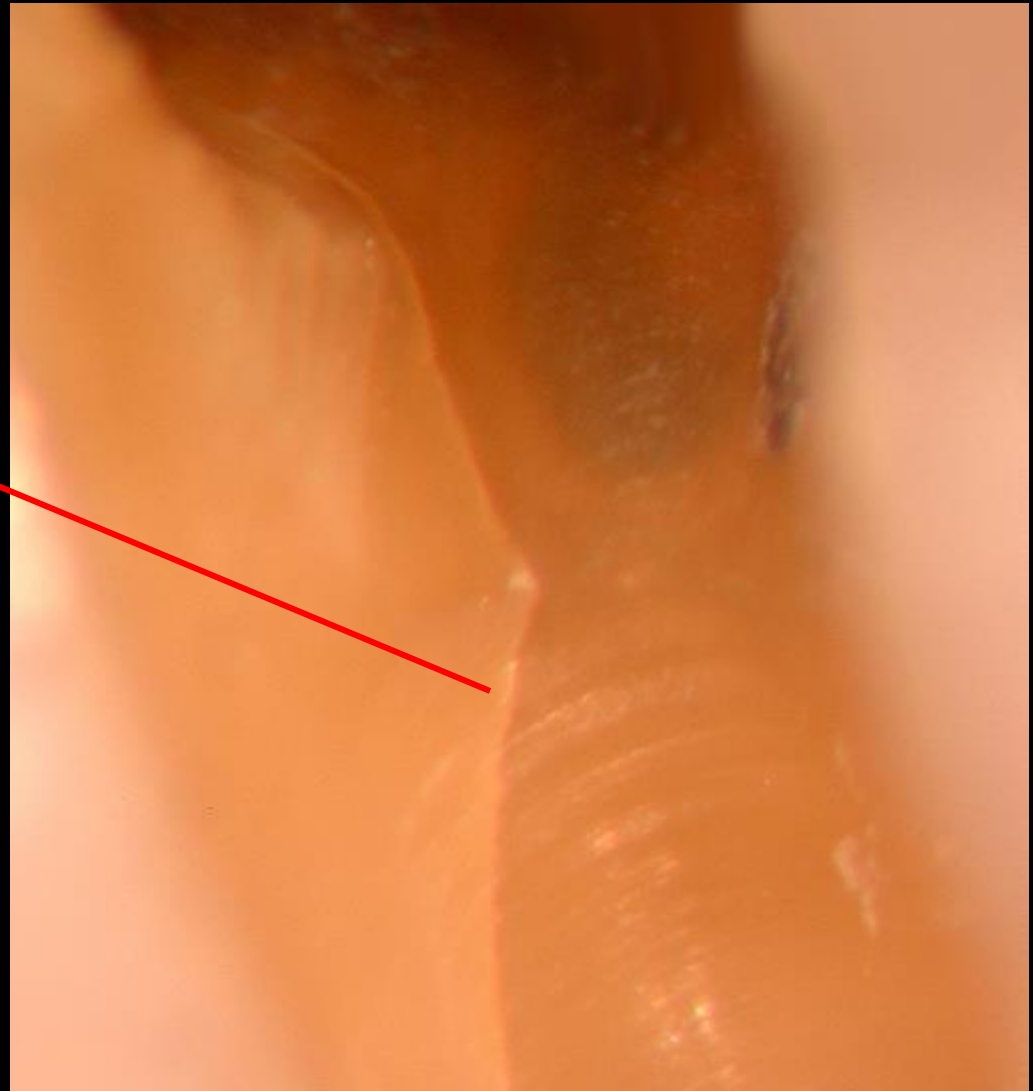
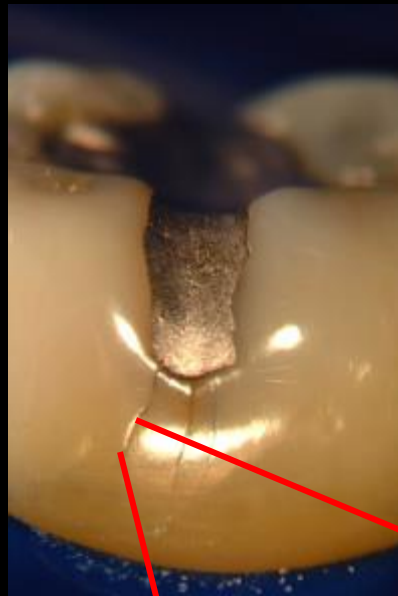A. Diagonal cracks



B. Diagonal cracks that emanate from the corner of a restoration

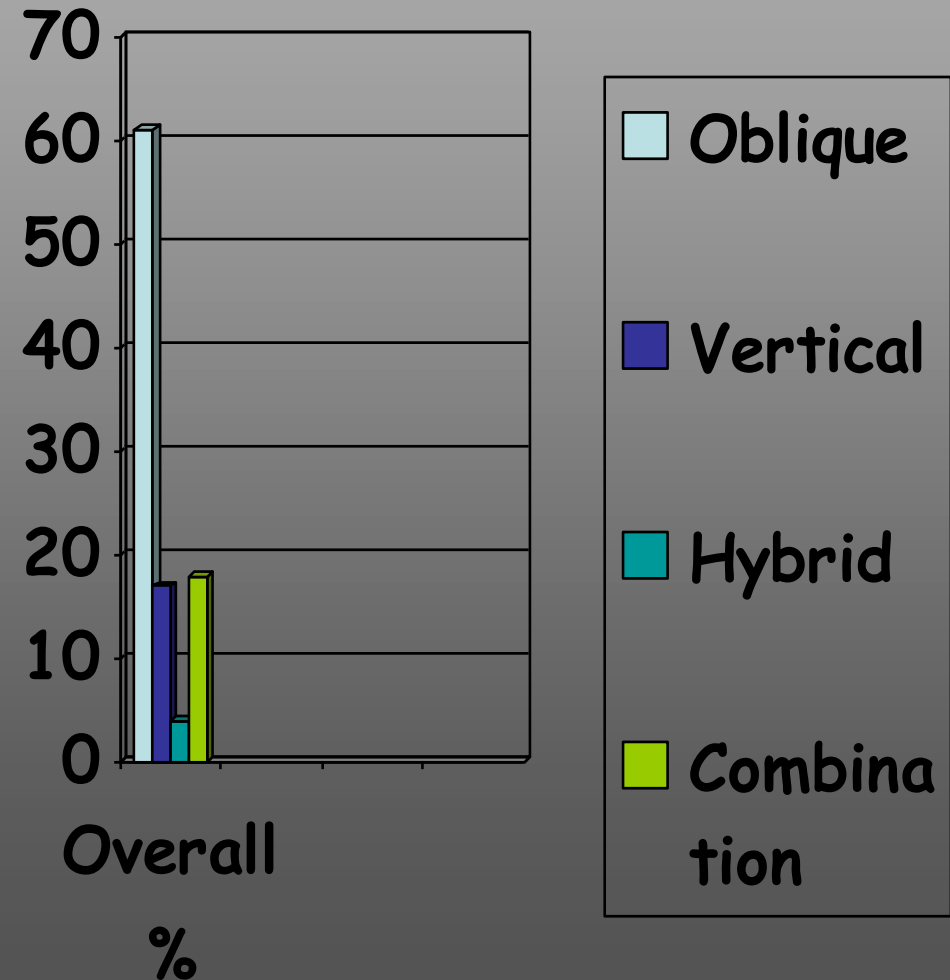


Nomenclature and
classification of
enamel cracks



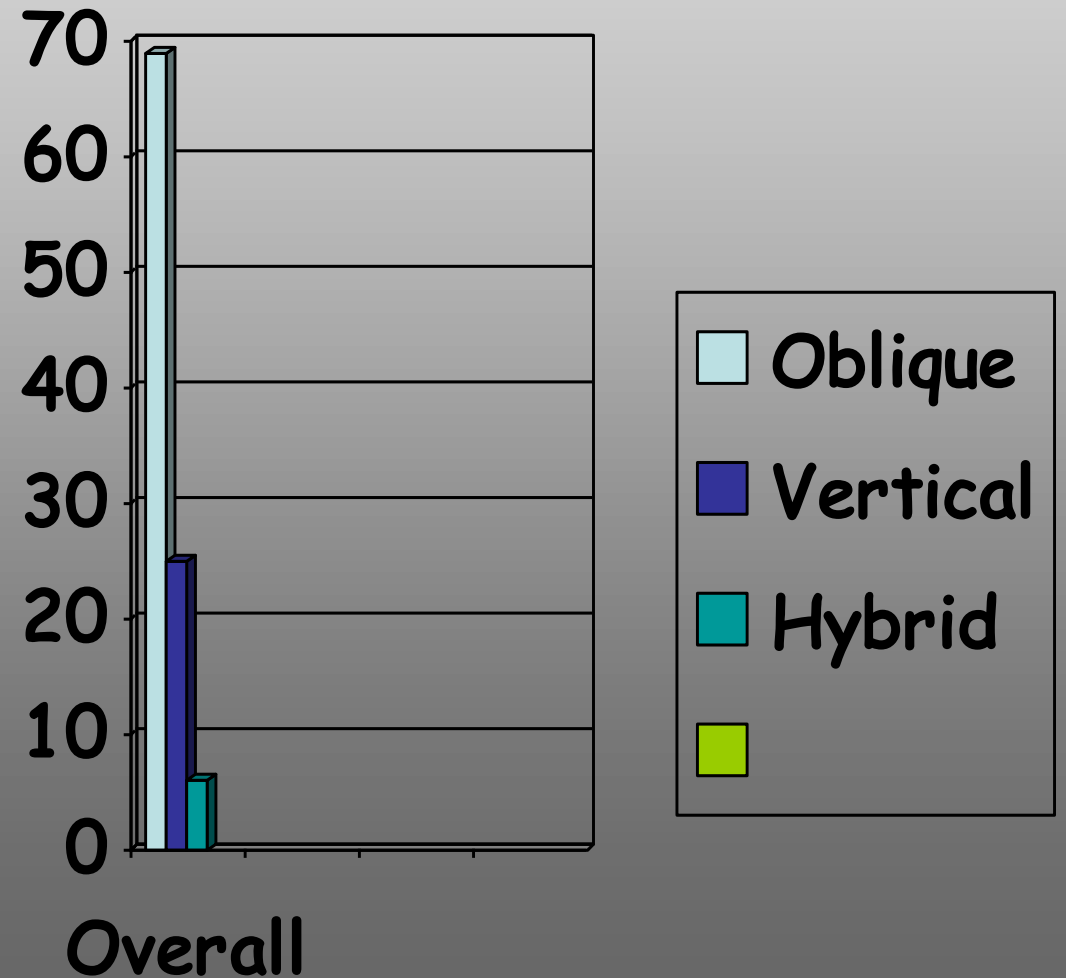
A Two Year Study 2001-2003

- 120 Teeth
- 24 months
- Every tooth treated restoratively examined at 16x after restorative material removed

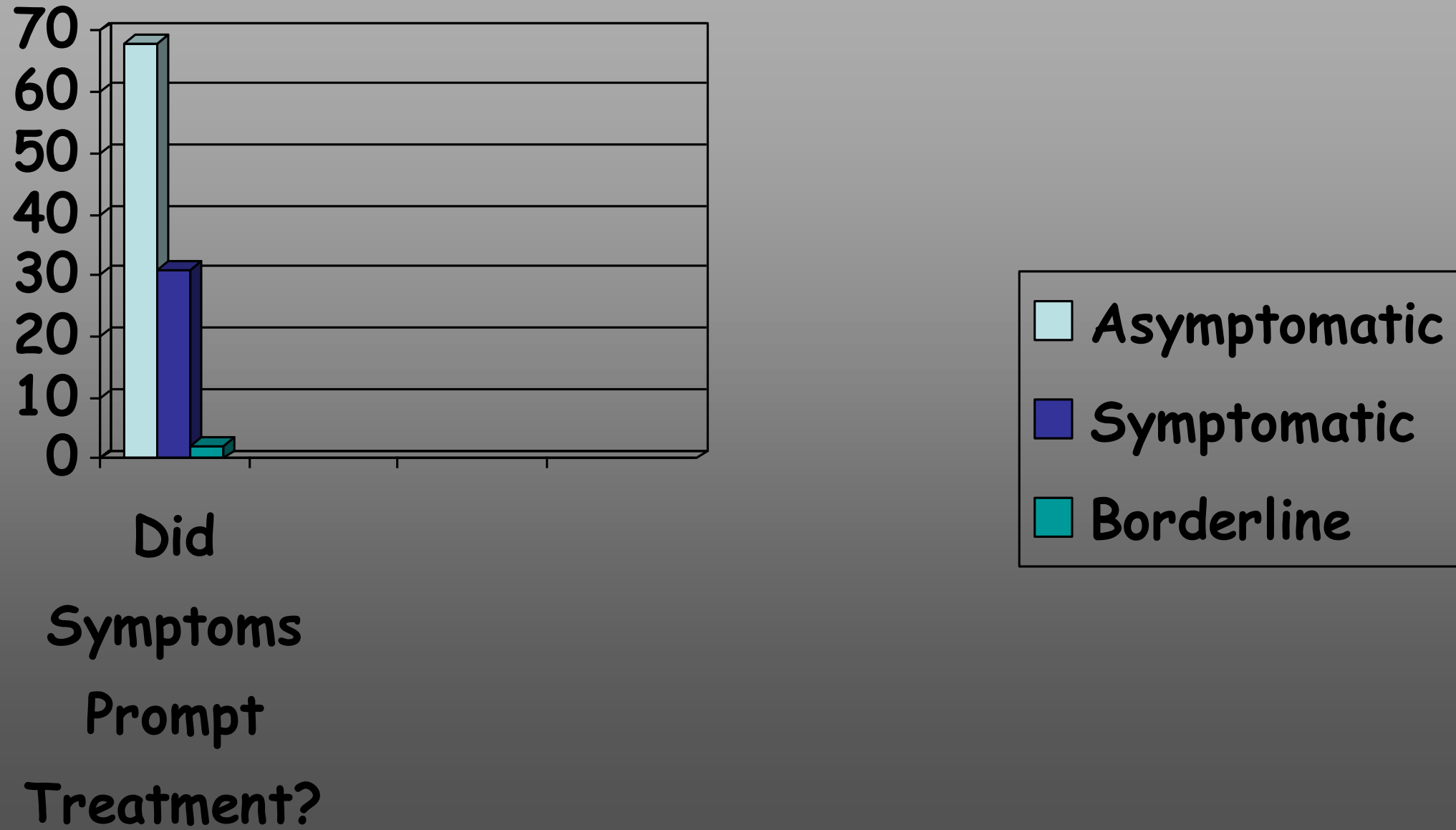


A Two Year Study

- 120 Teeth
- 188 Dentin Cracks
(Incomplete Fractures)

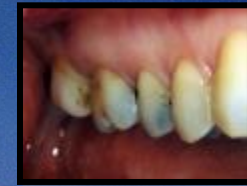

A Two Year Study



- The third leading cause of tooth loss today is from splits/fractures. (Lynch CD McCinnel RJ. The cracked tooth Syndrome. J Dent Assoc Sept 2002; 68(8):470-475)
- Crack initiation and progression should not be labeled a “syndrome”
- Diagnosis and treatment should be similar to approaches we utilize to address other pathologies (i.e. caries, periodontal disease)

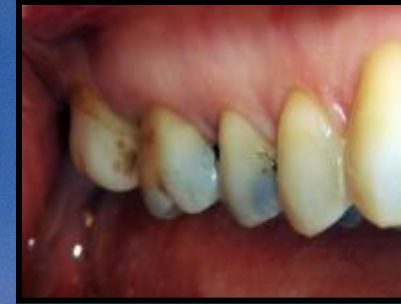B. Diagonal cracks that emanate from the corner of a restoration



2X

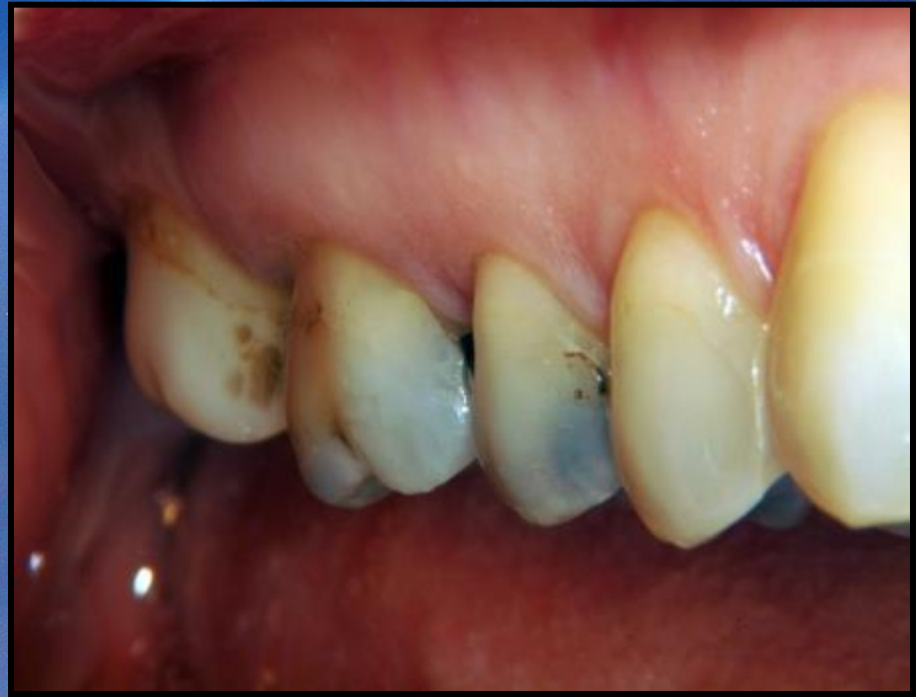Nomenclature and
classification of
enamel cracks

B. Diagonal cracks that emanate from the corner of a restoration



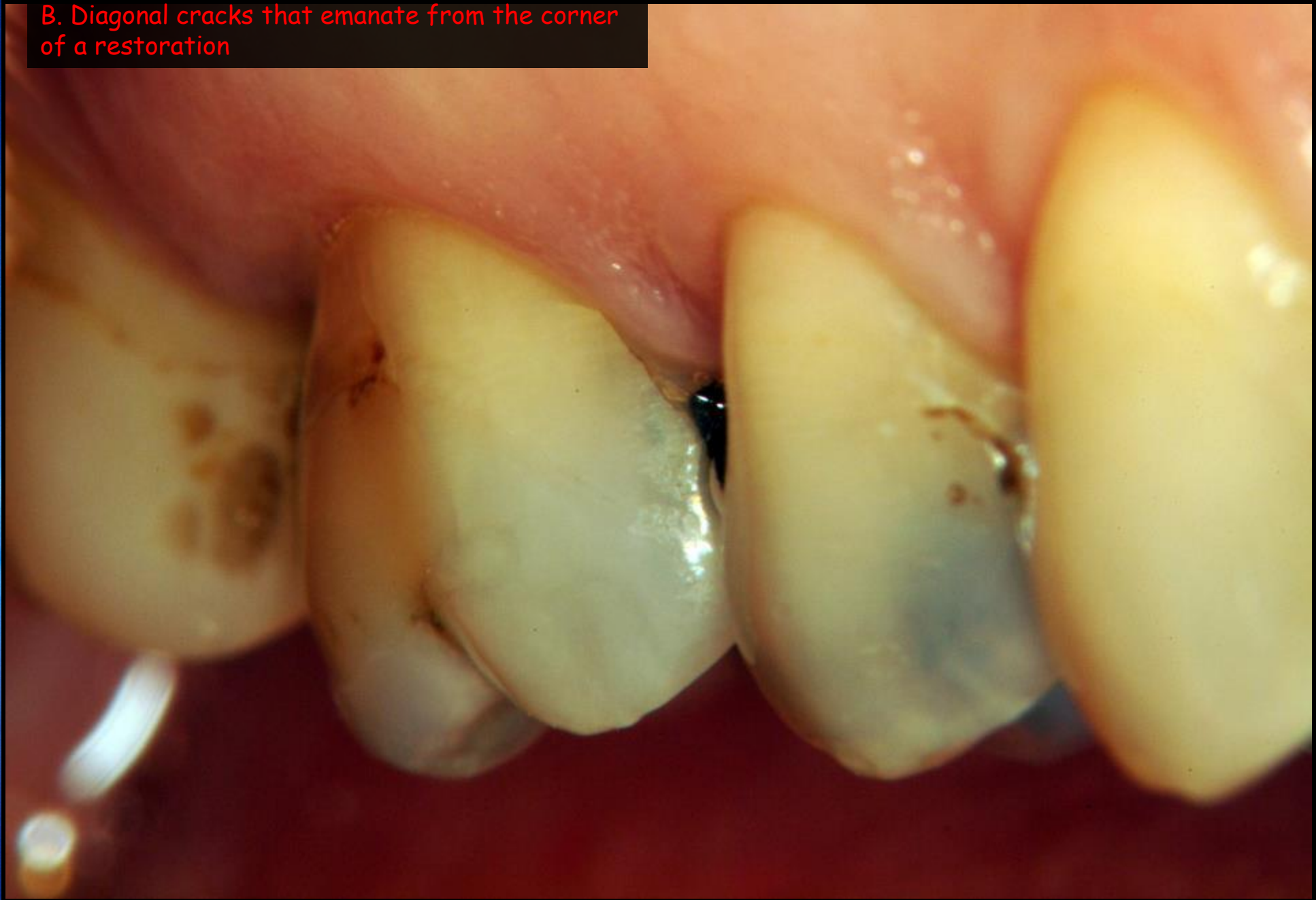4X

B. Diagonal cracks that emanate from the corner of a restoration

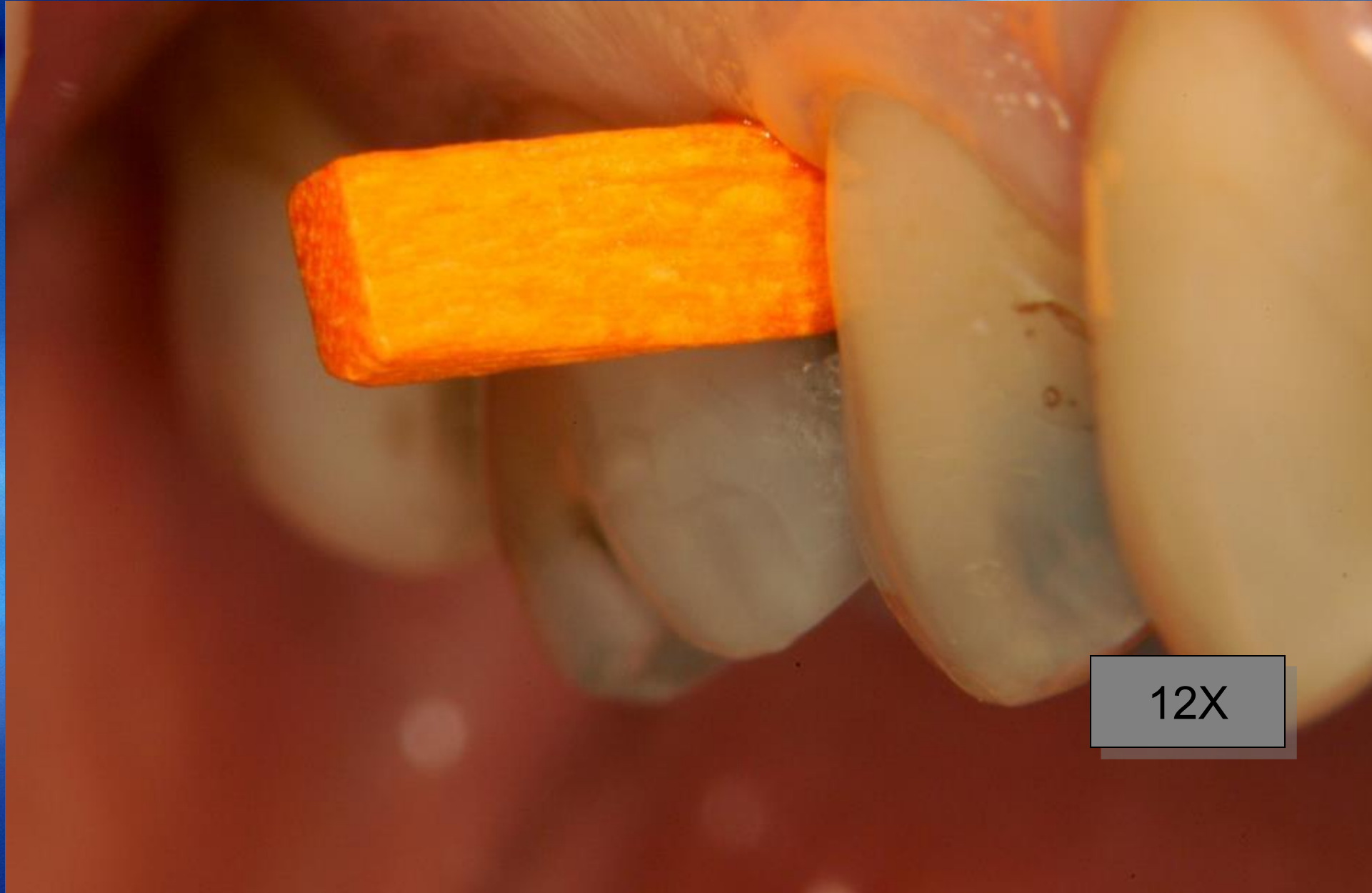

8X

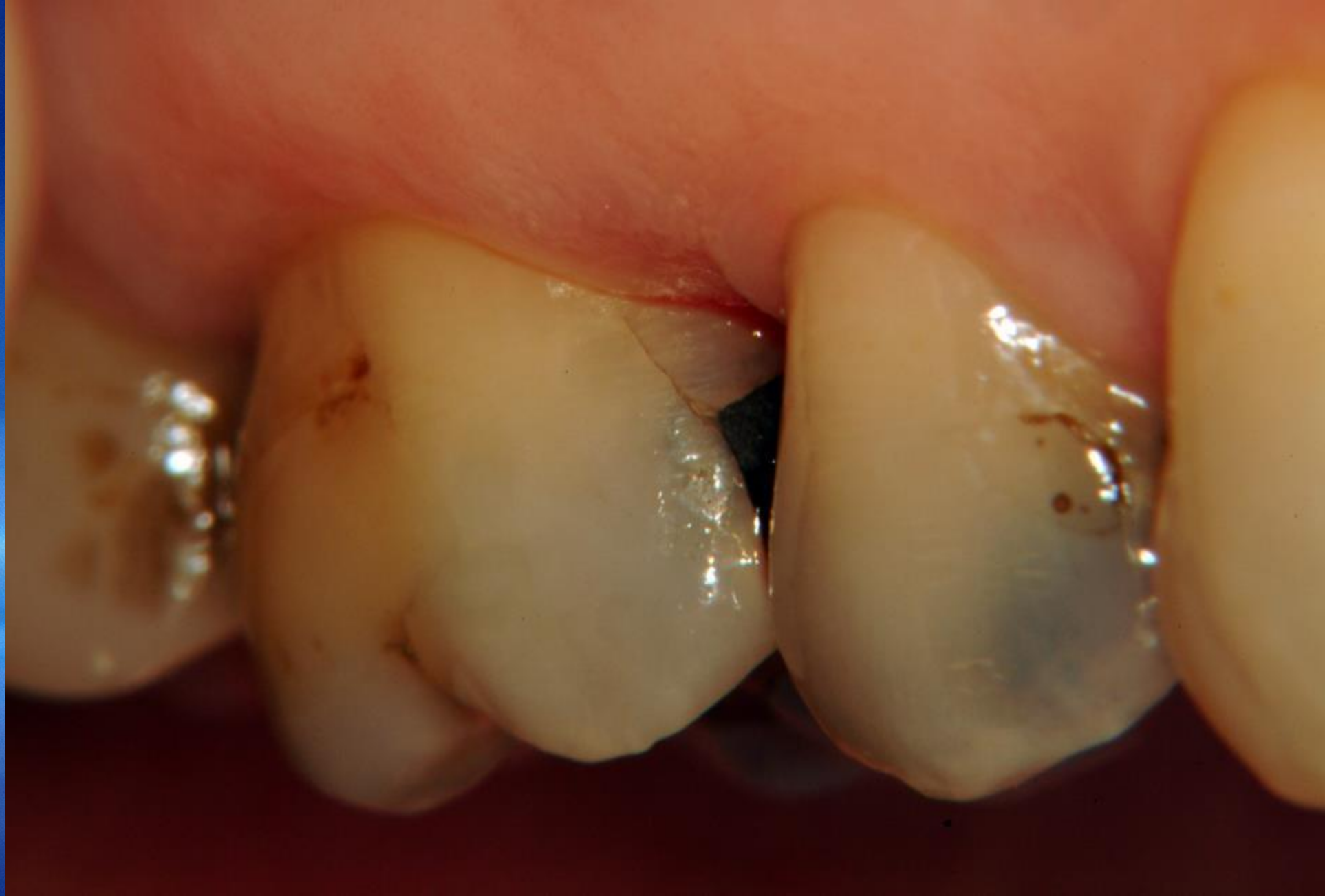B. Diagonal cracks that emanate from the corner of a restoration



B. Diagonal cracks that emanate from the corner of a restoration

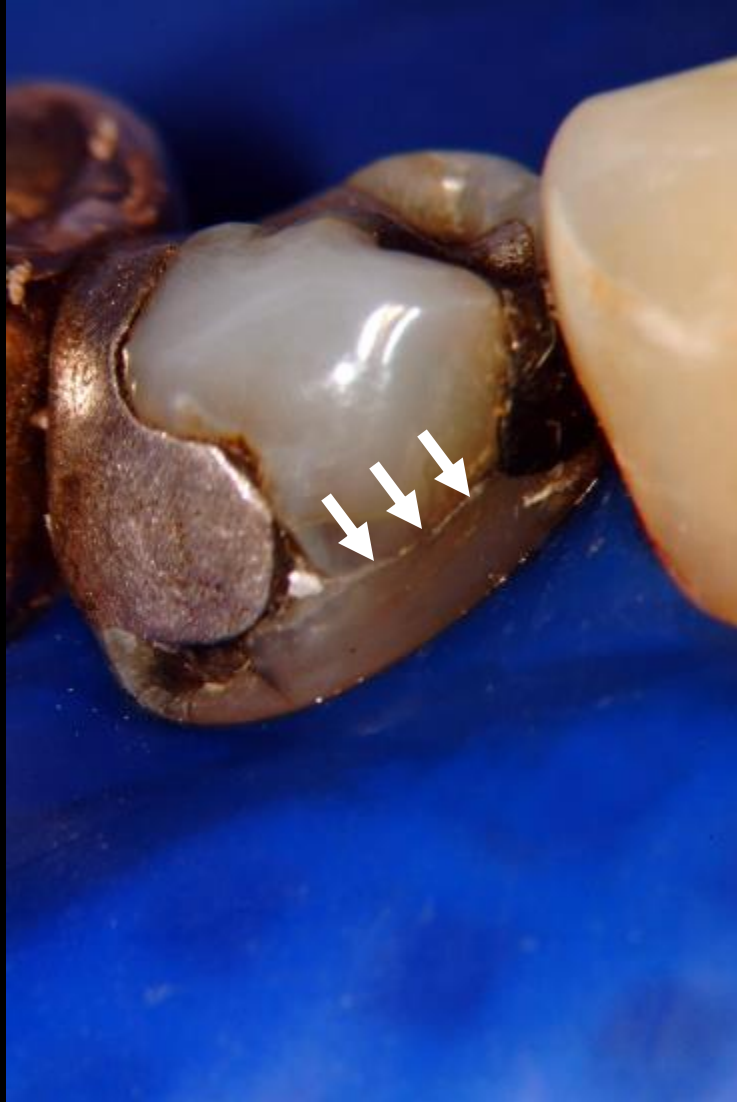

12X

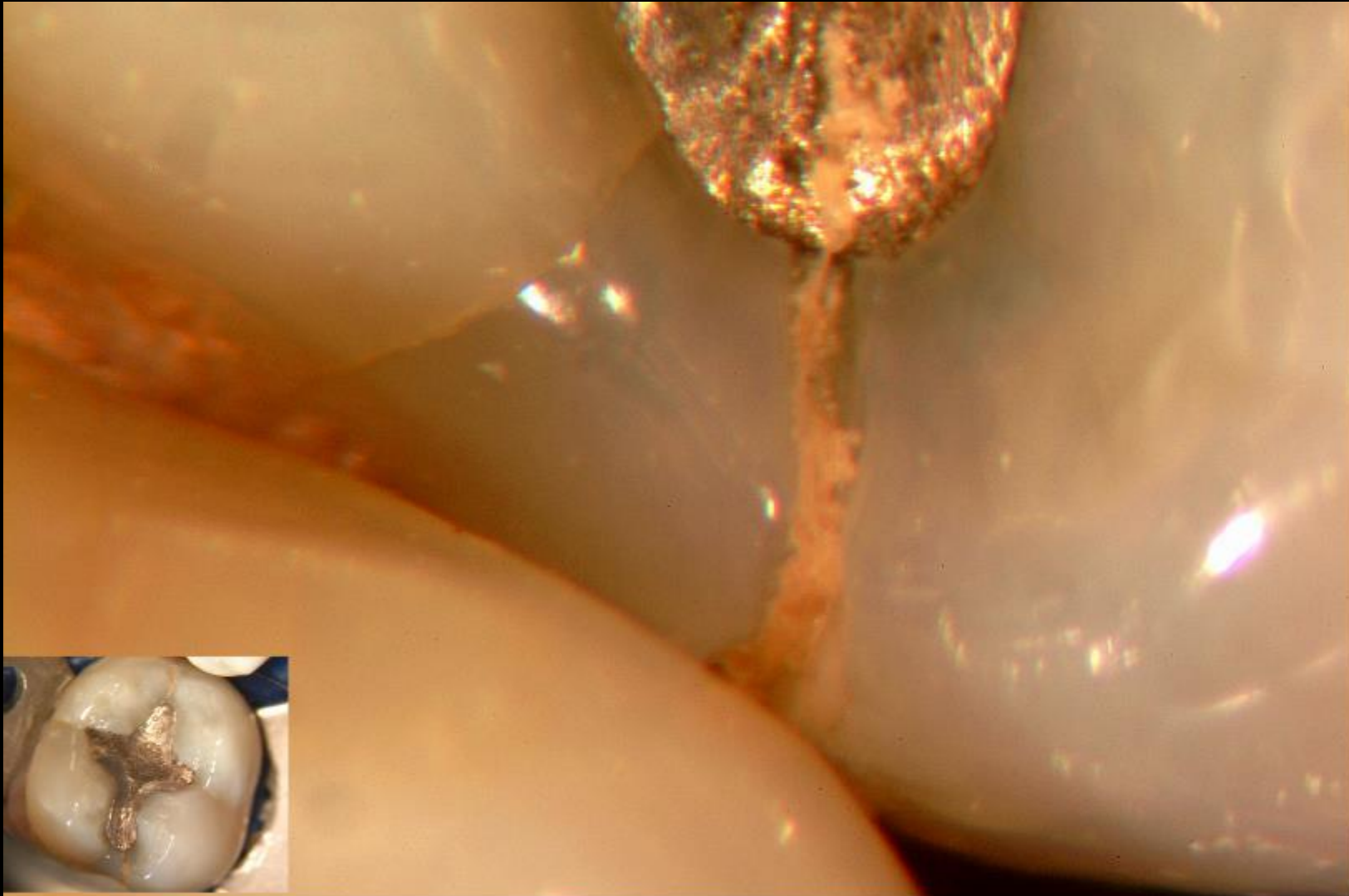



16X

B. Horizontal cracks



C. Crack that houses debris

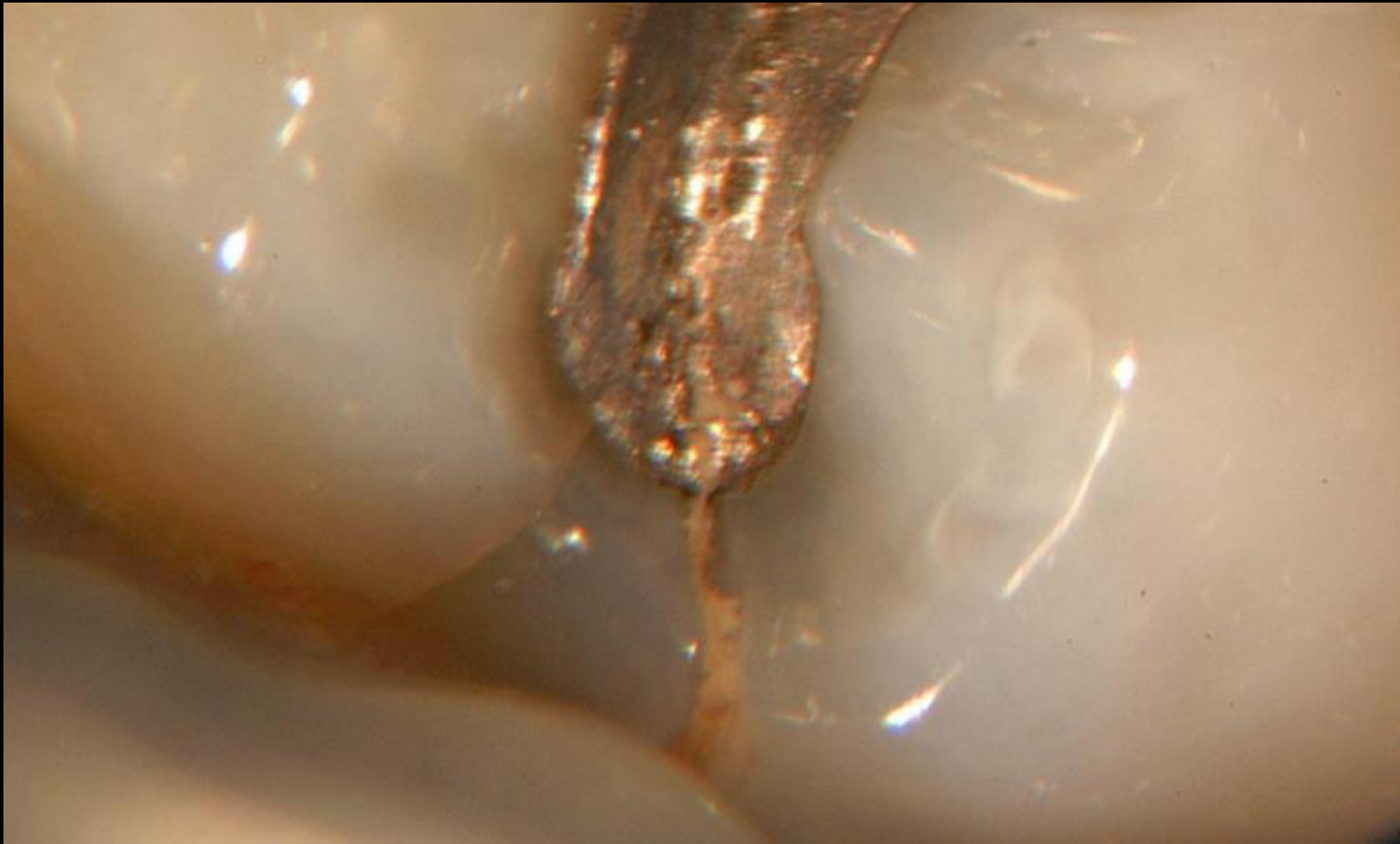



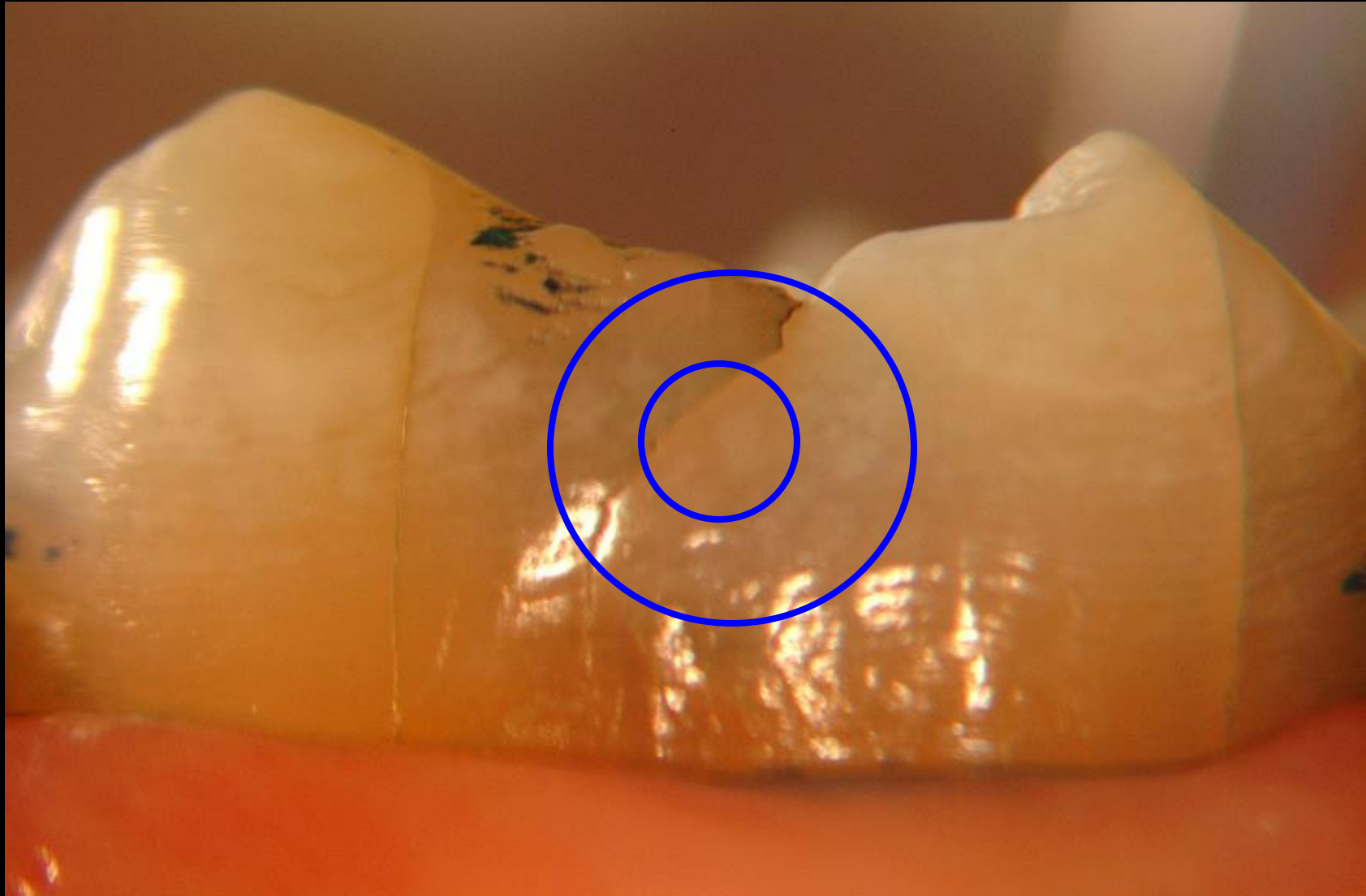
Type III: Have high risk of underlying pathology

- D. Pair of cracks that outline an area (cusp or marginal ridge) of discolored enamel
- E. Crack with corresponding halo of brown, grey or white centered on crack

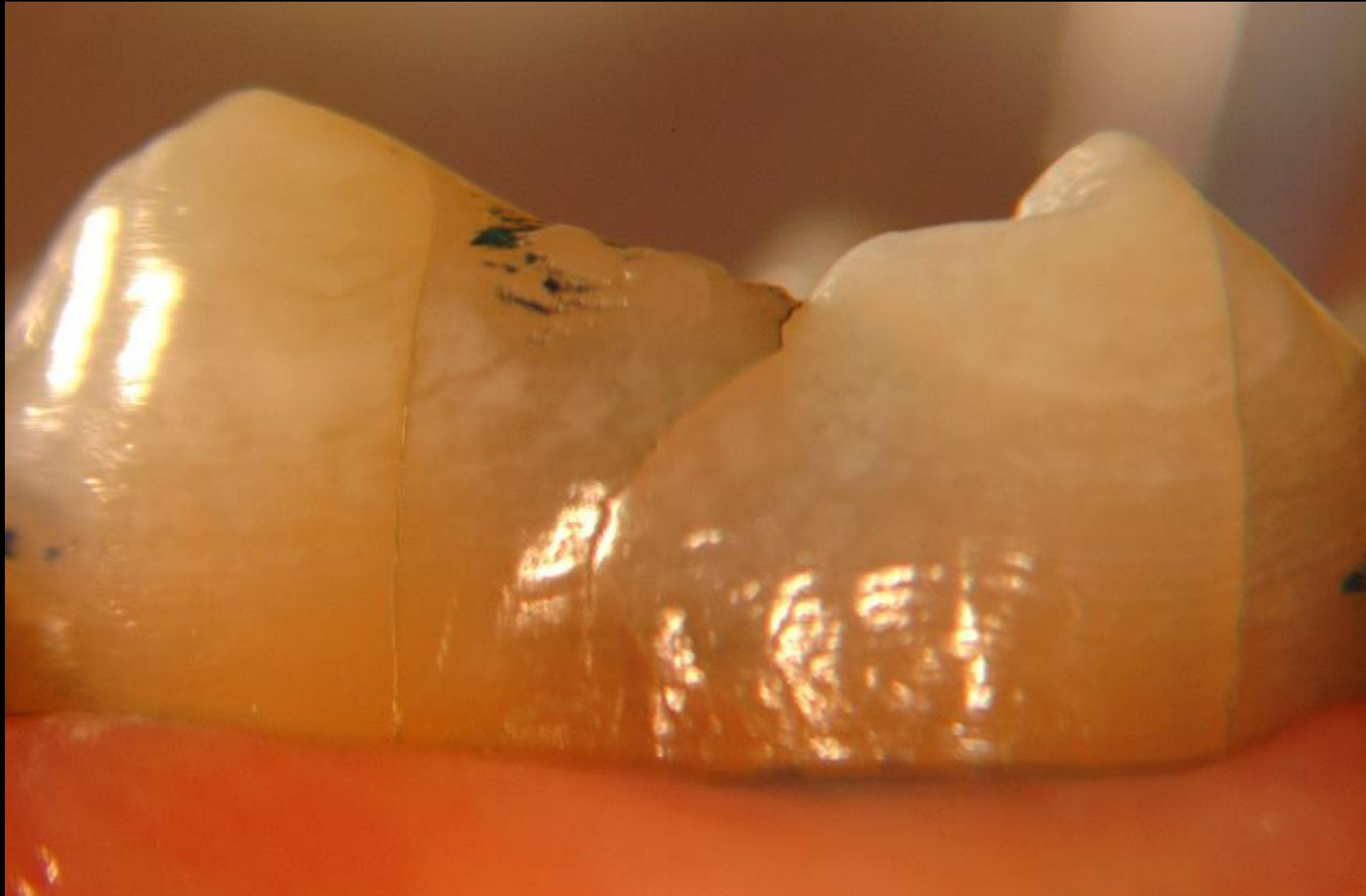D. Pair of cracks that outline an area (cusp or marginal ridge) of discolored enamel



E. Crack with corresponding halo of brown, grey or white centered on crack



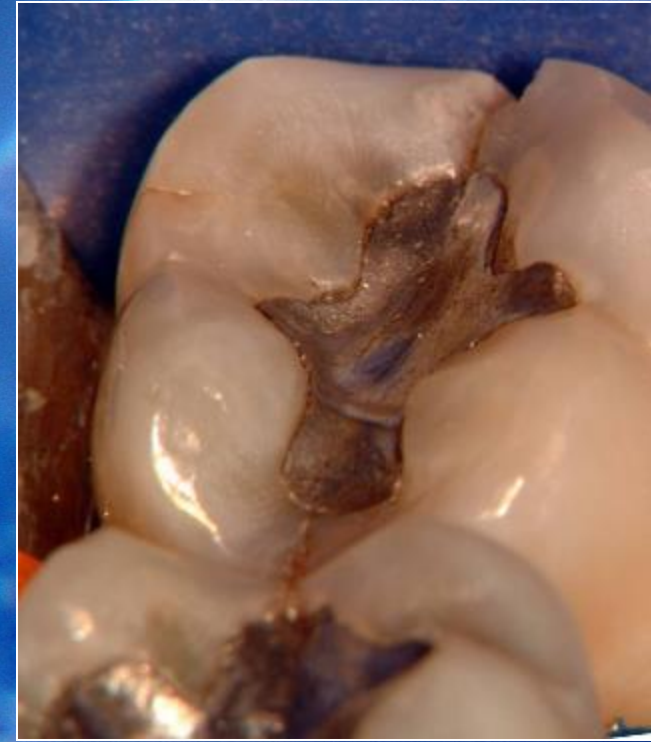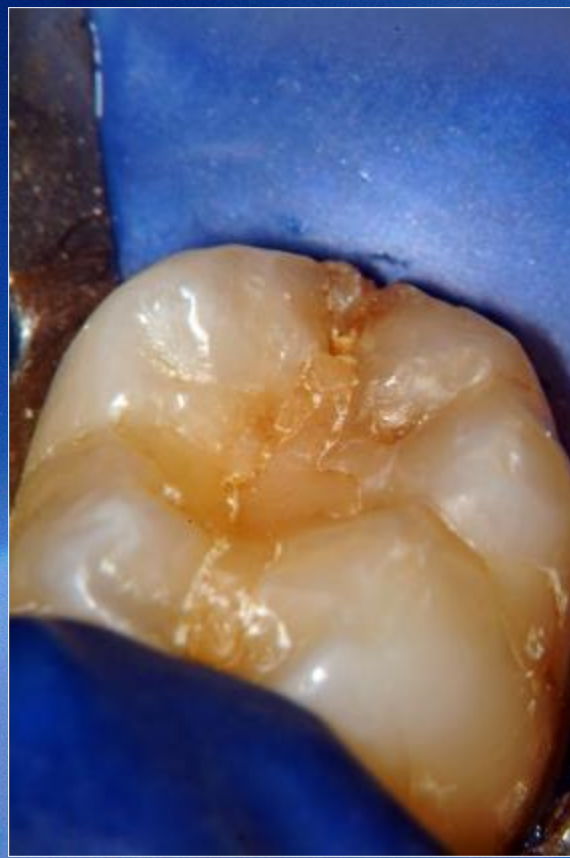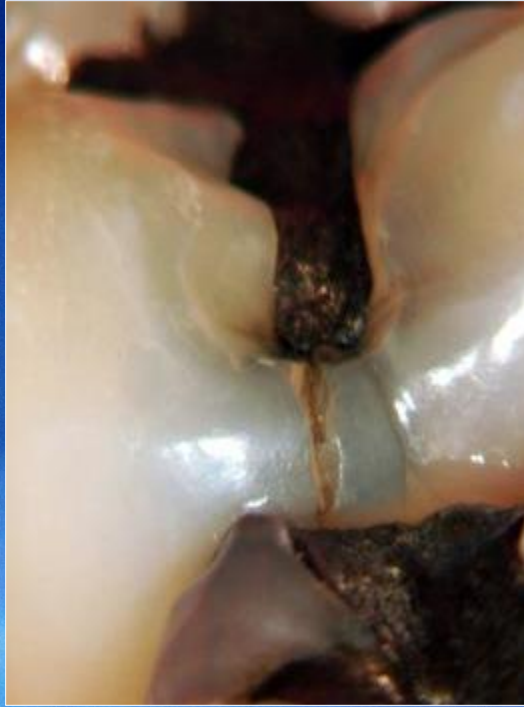E. Crack with corresponding halo of brown, grey or white centered on crack



Other Microscopic Findings That Can Indicate a Lack of Coronal Structural Integrity

- Unusual or asymmetric gapping of filling material
- Crack in Filling material
- Gray discoloration of a cusp or cusps

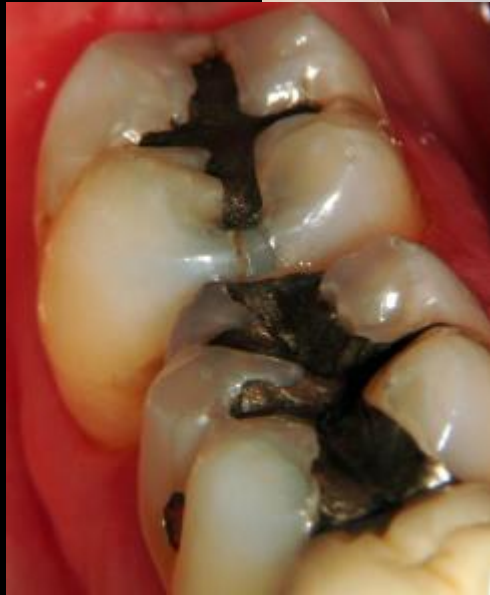
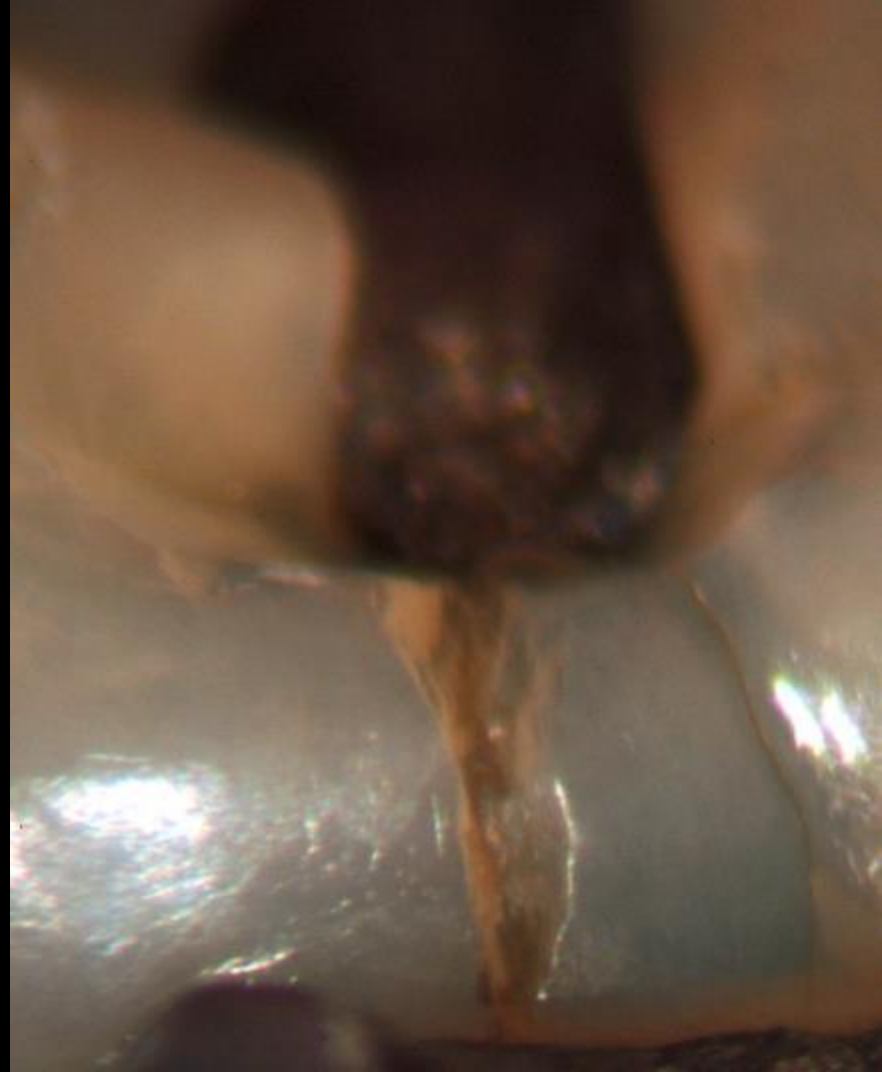
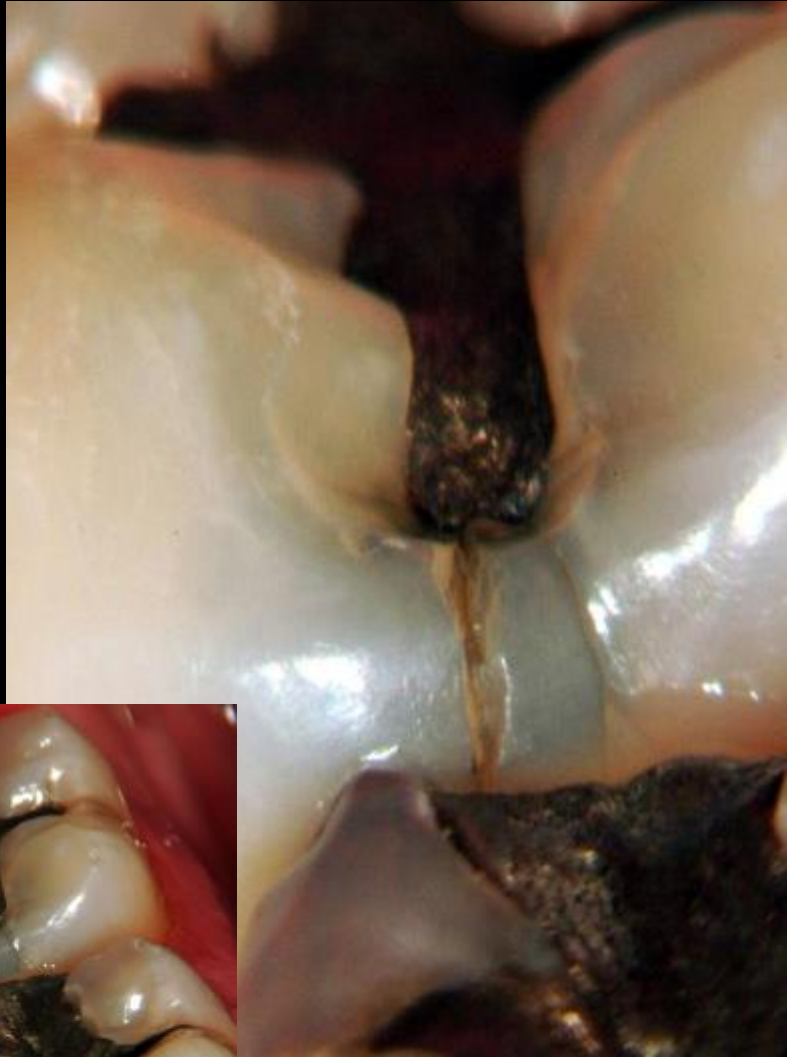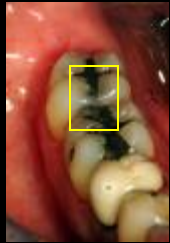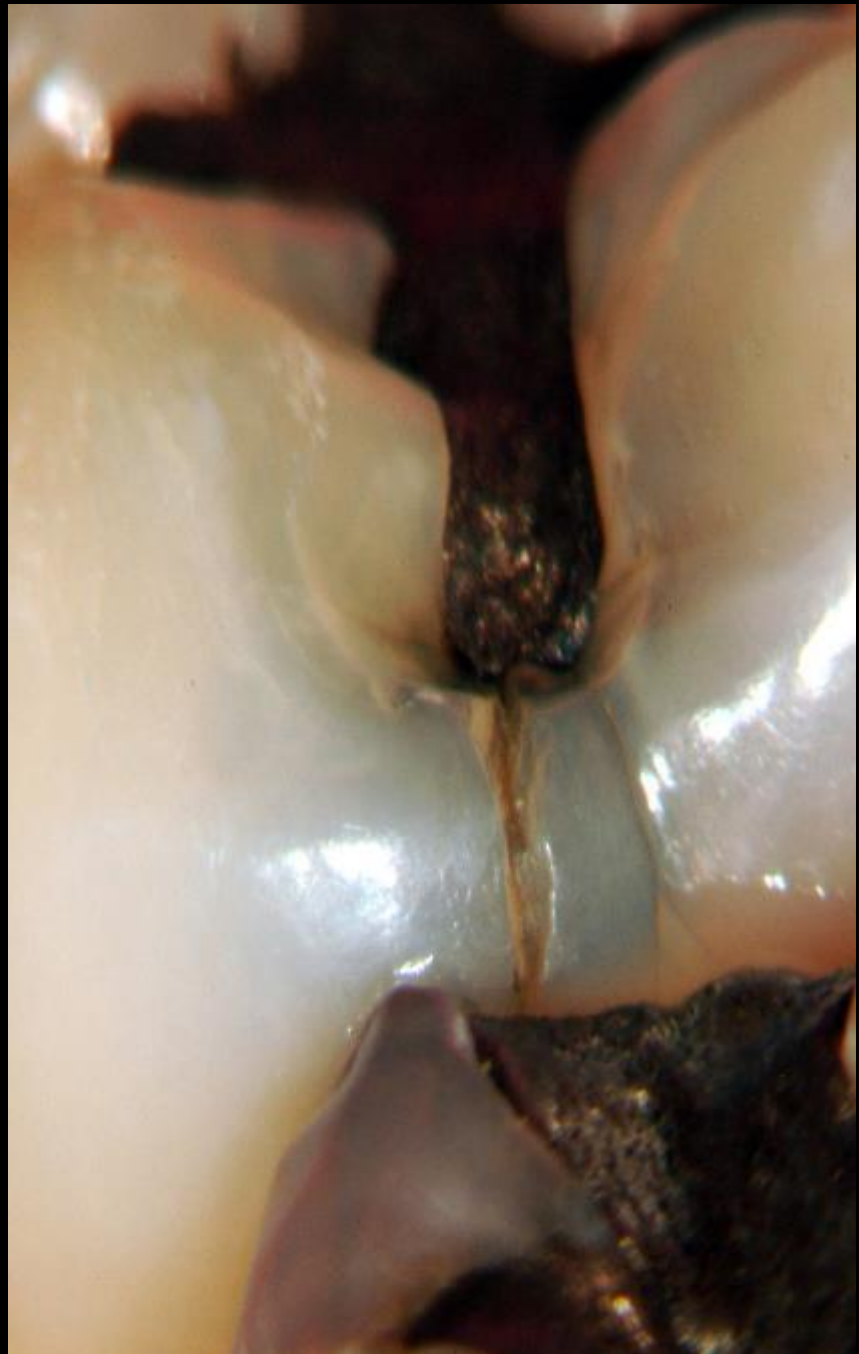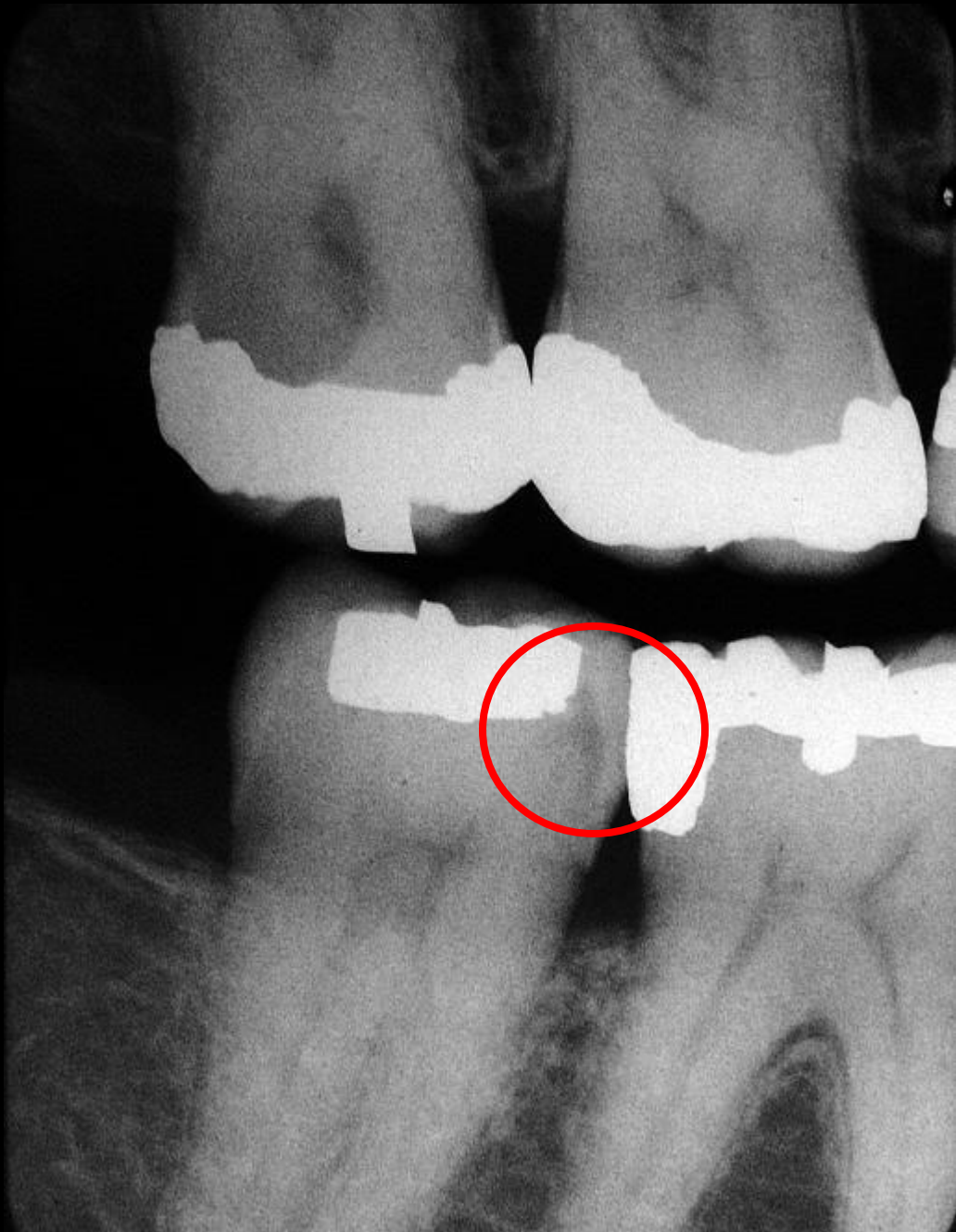


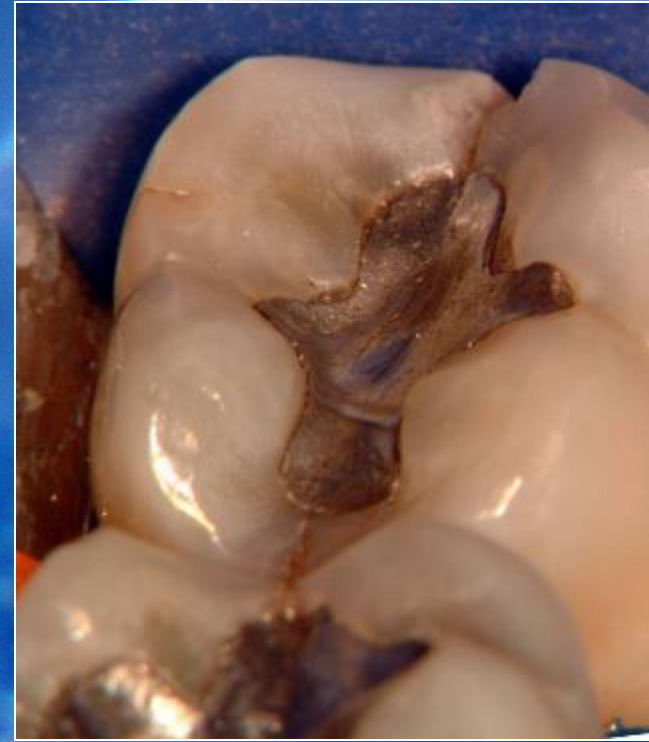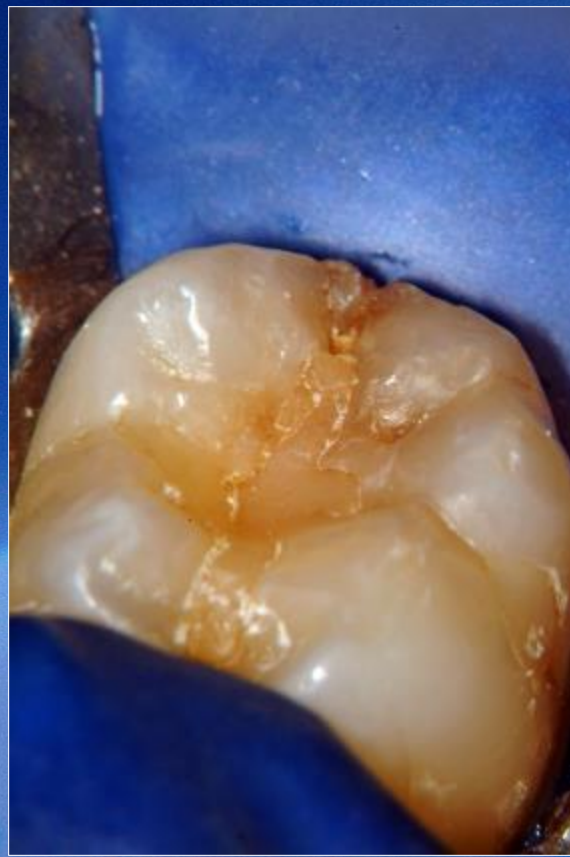A Tale of Three Marginal Ridges



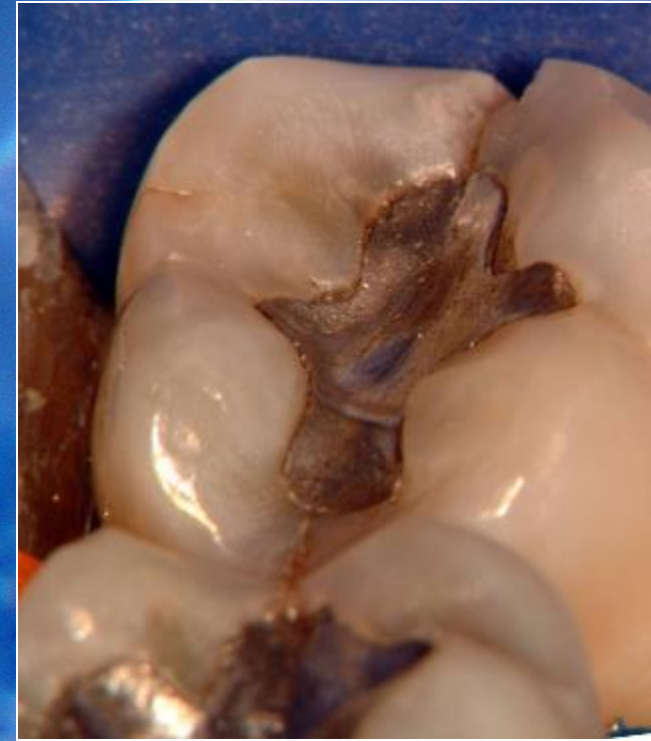A Tale of Three Marginal Ridges



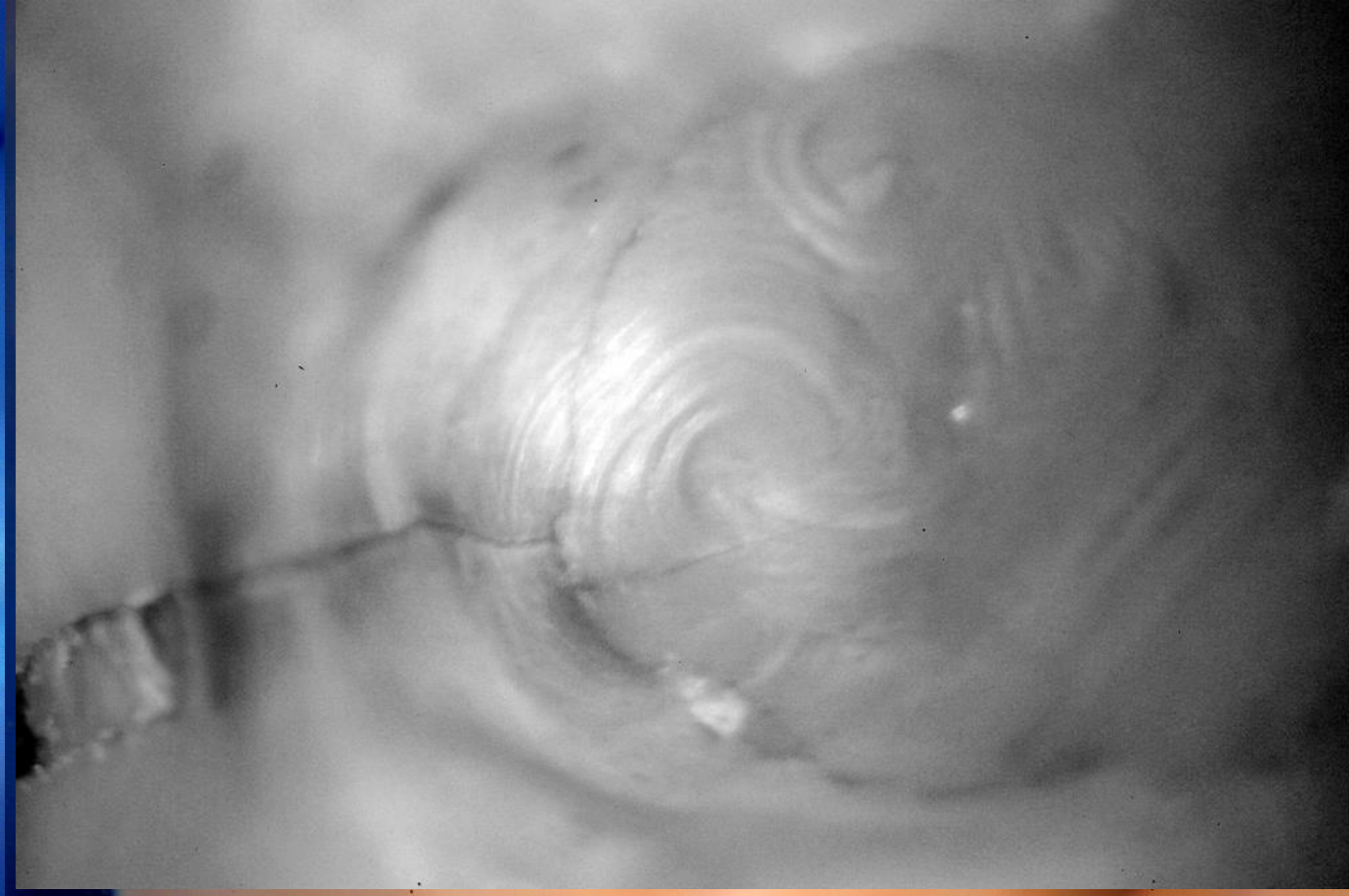


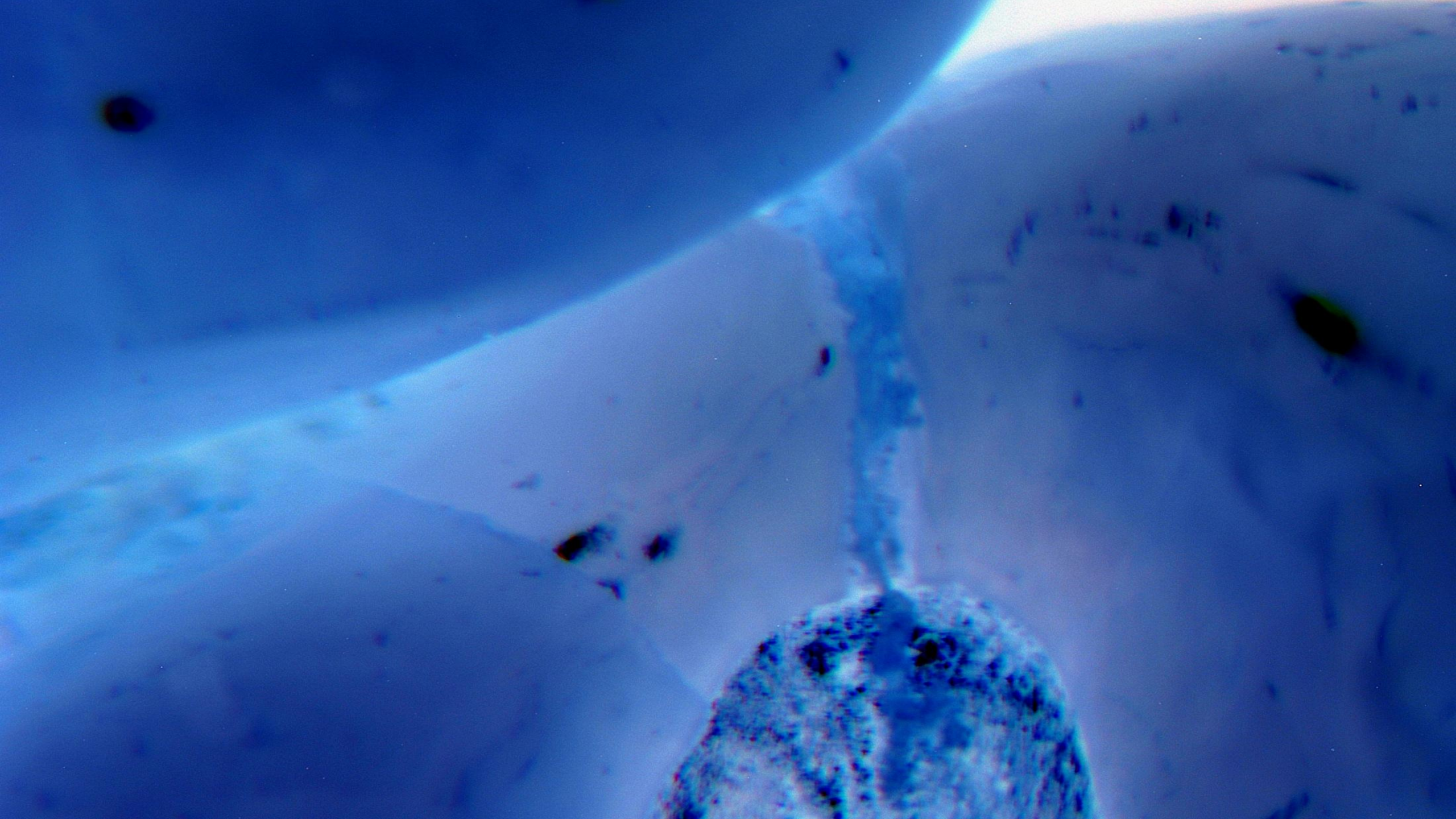


A Tale of Three Marginal Ridges



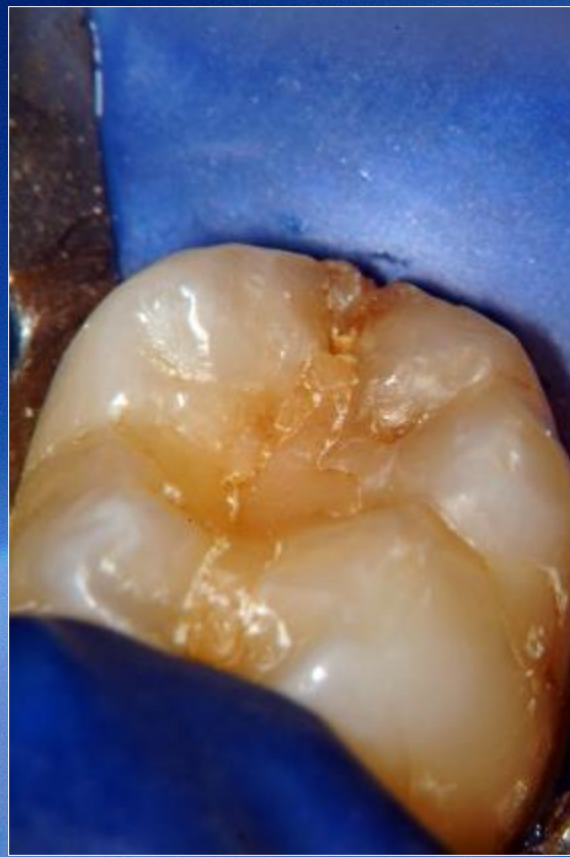
A Tale of Three Marginal Ridges



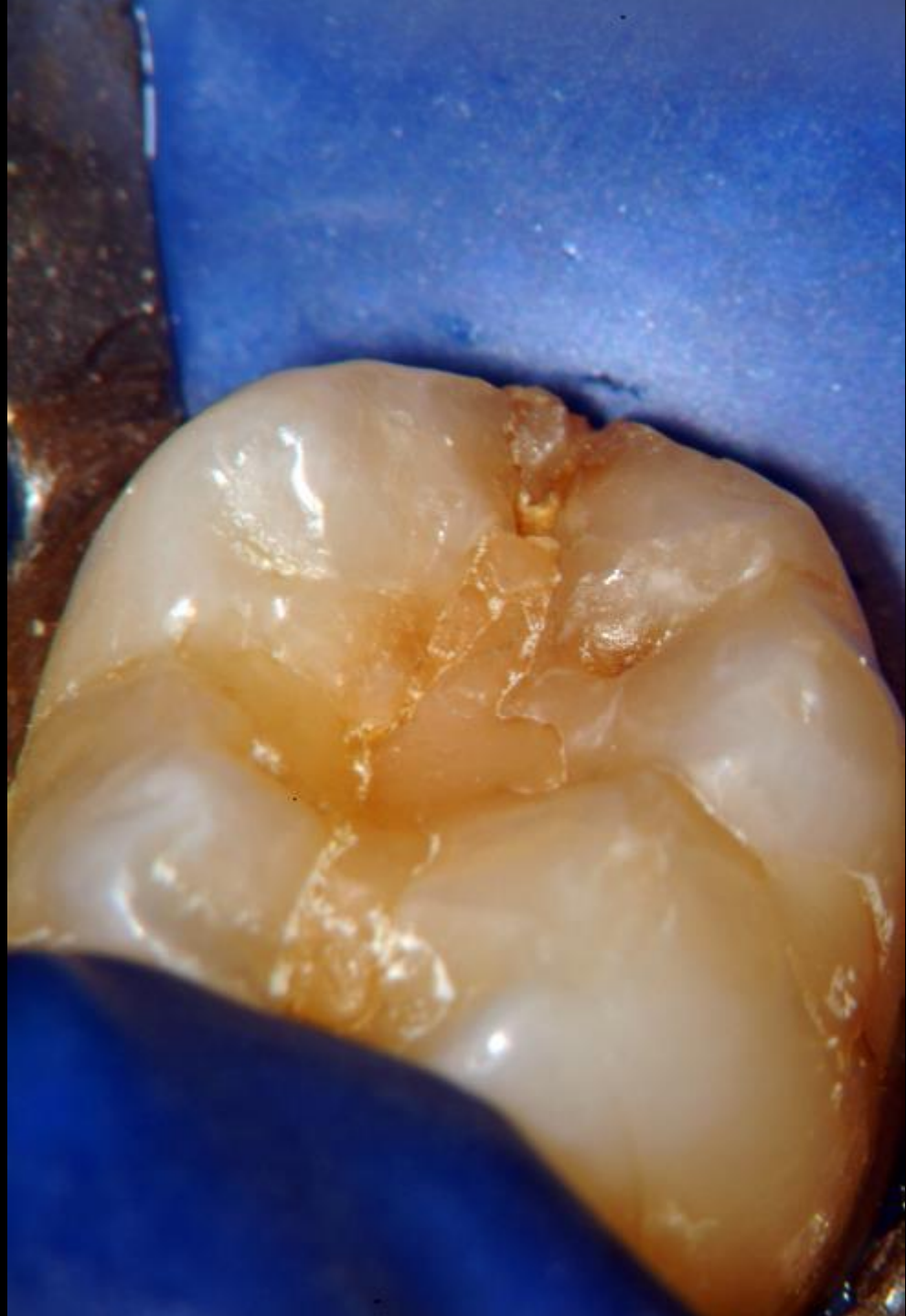

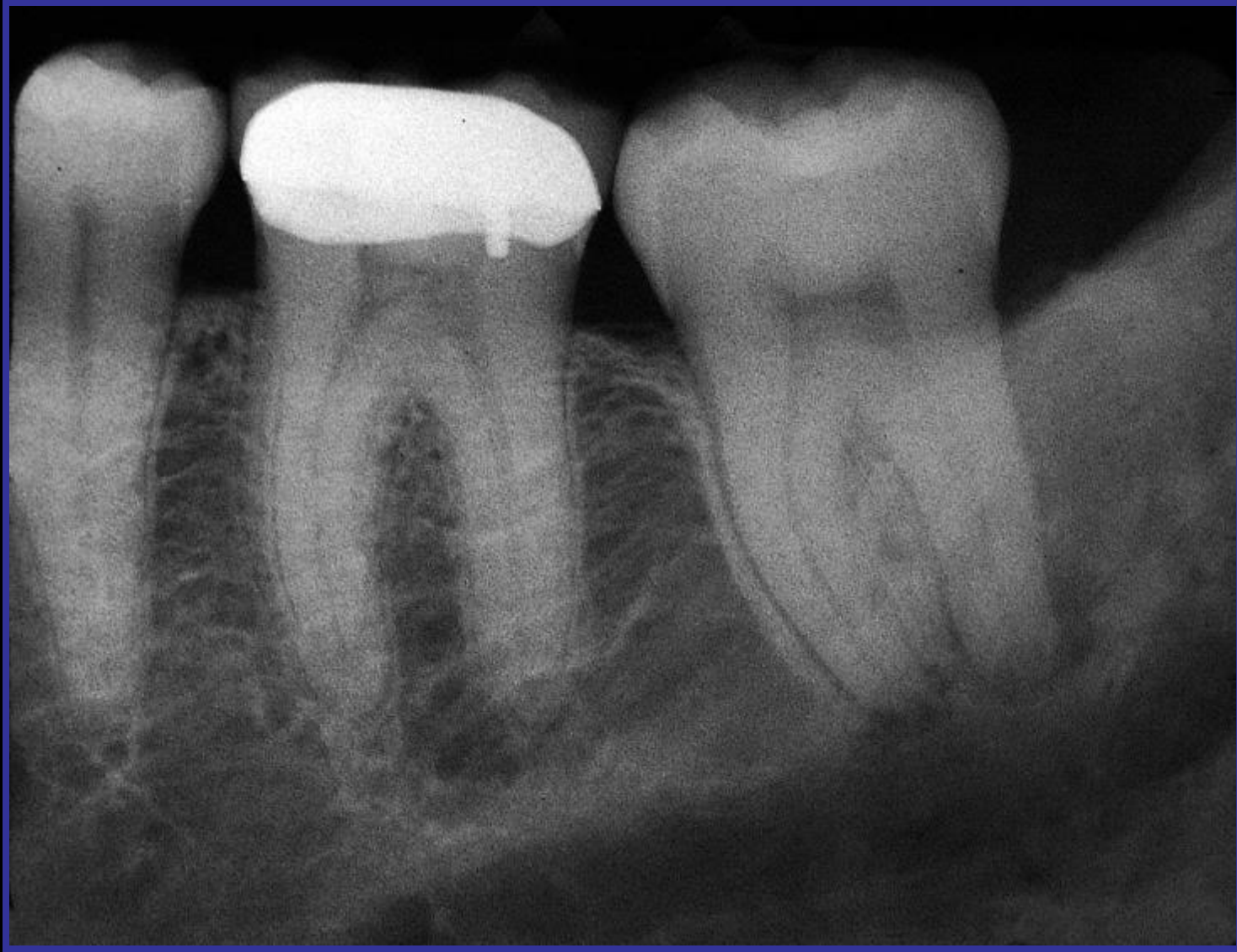


A Tale of Three Marginal Ridges

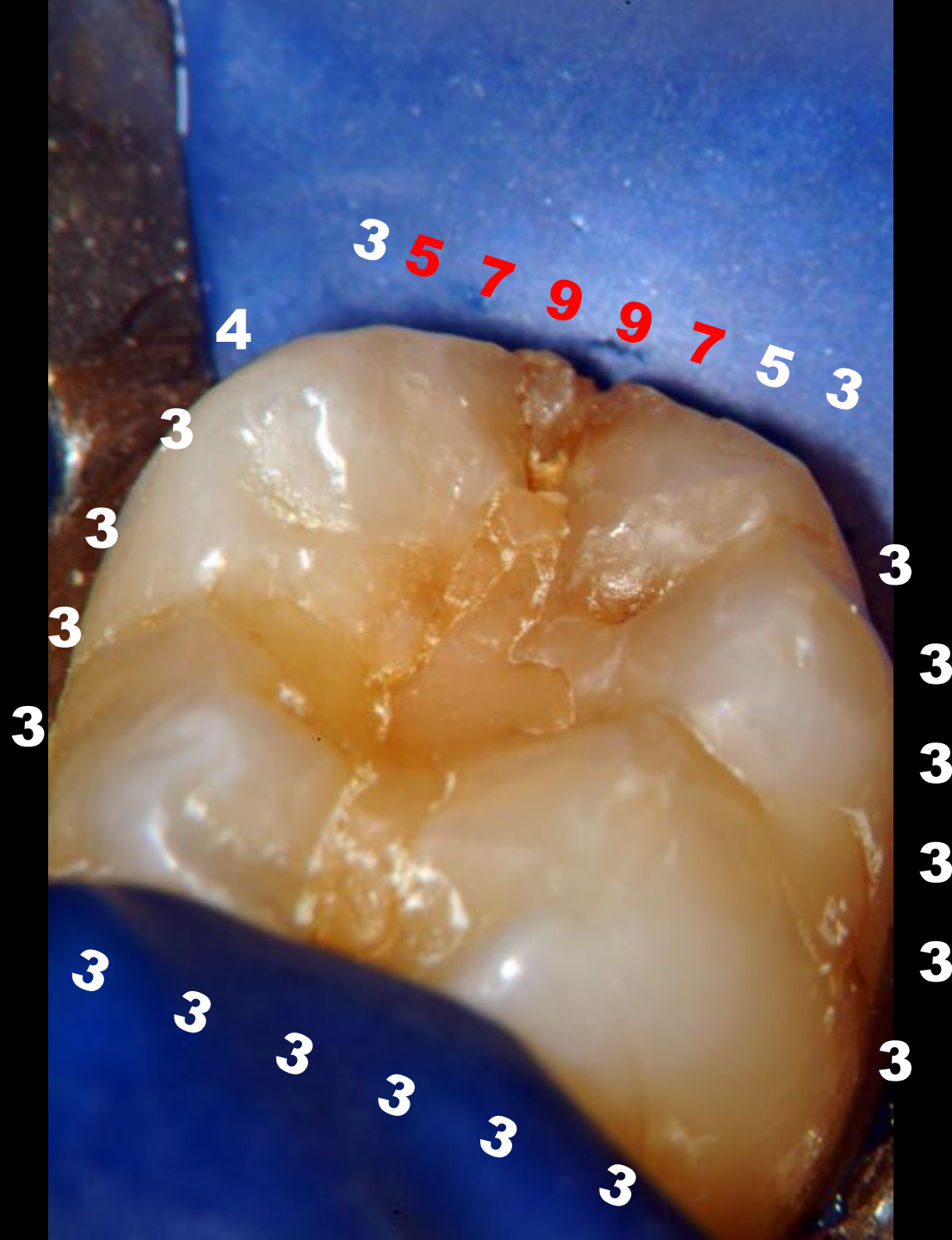


A Tale of Three Marginal Ridges

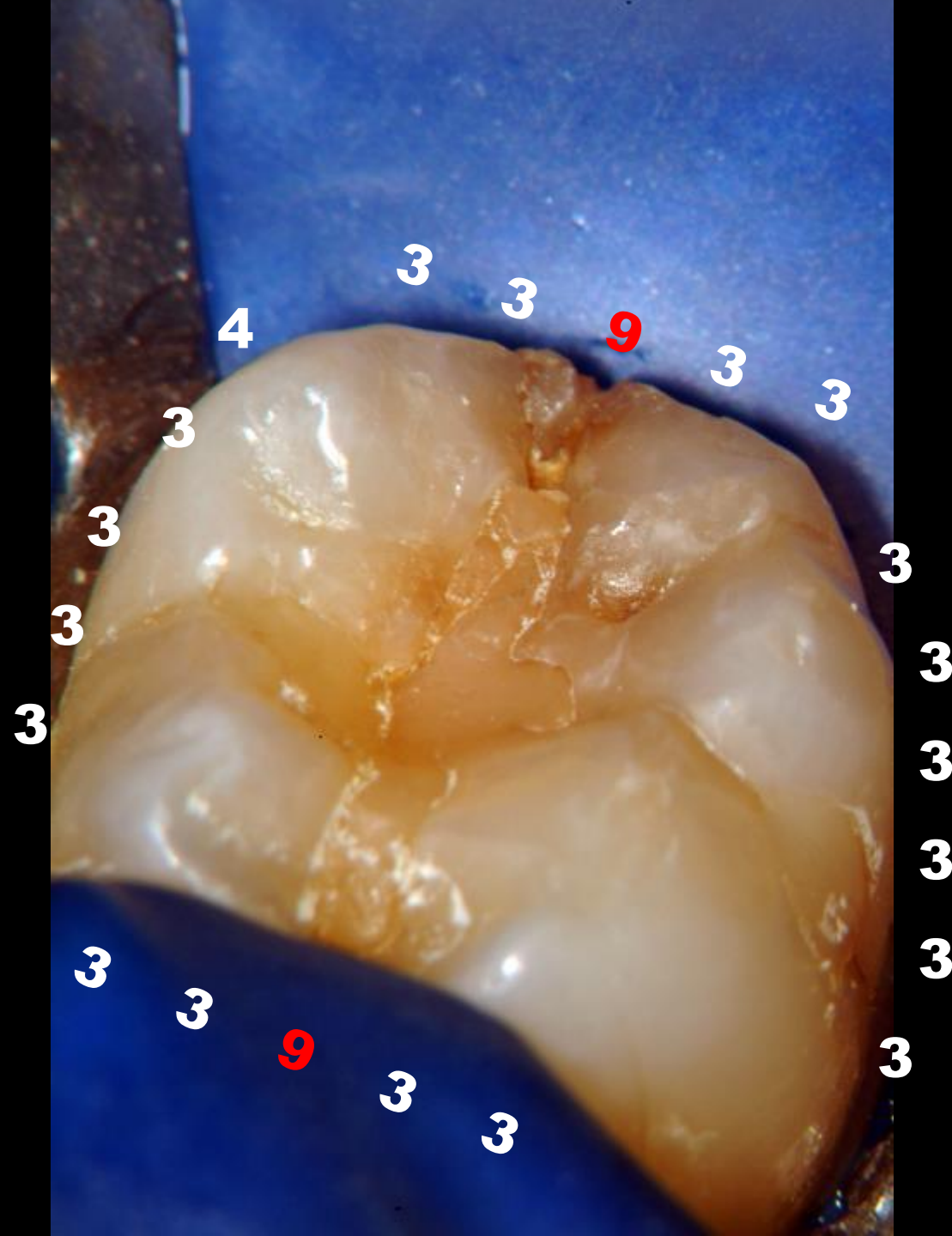




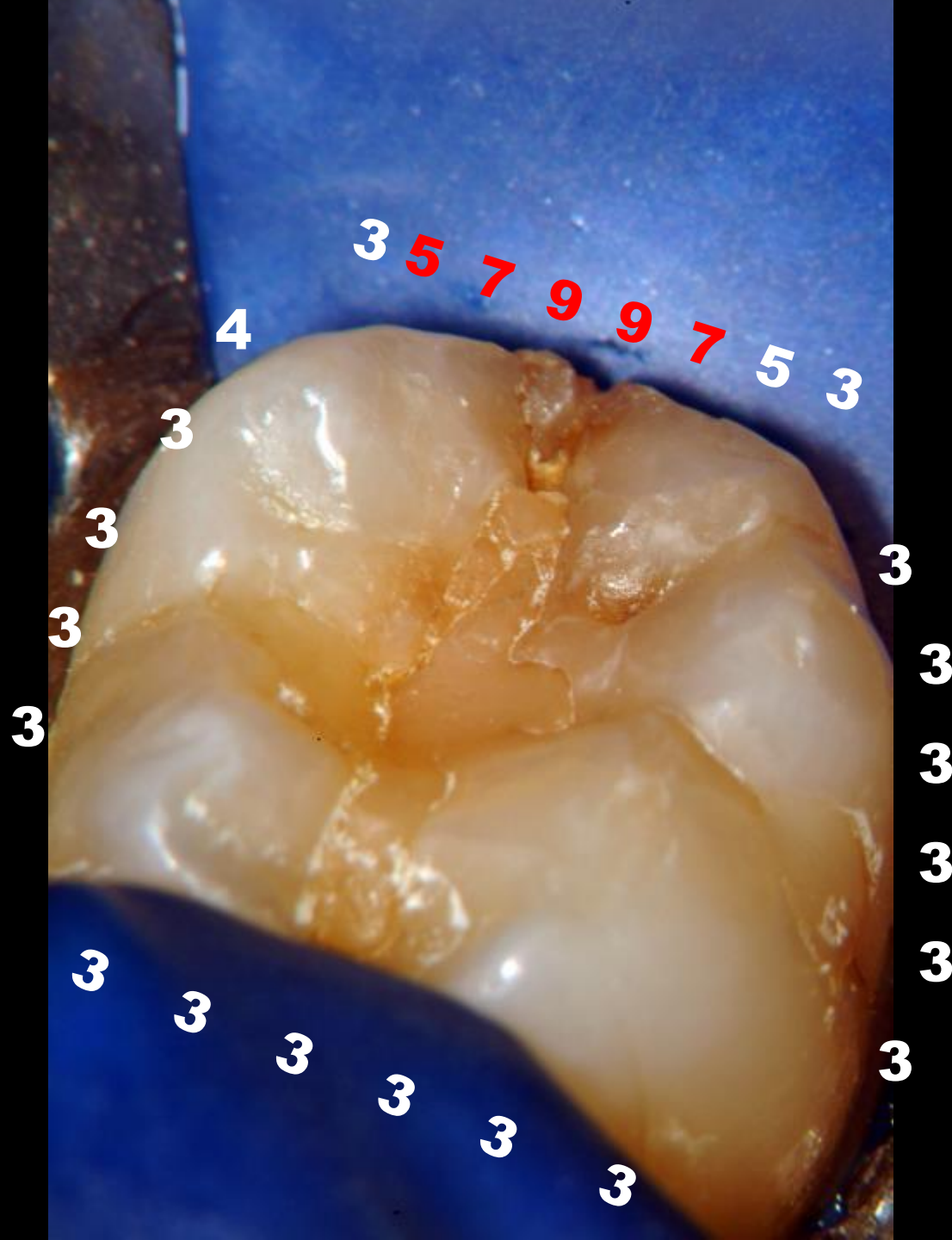
What
we
probed

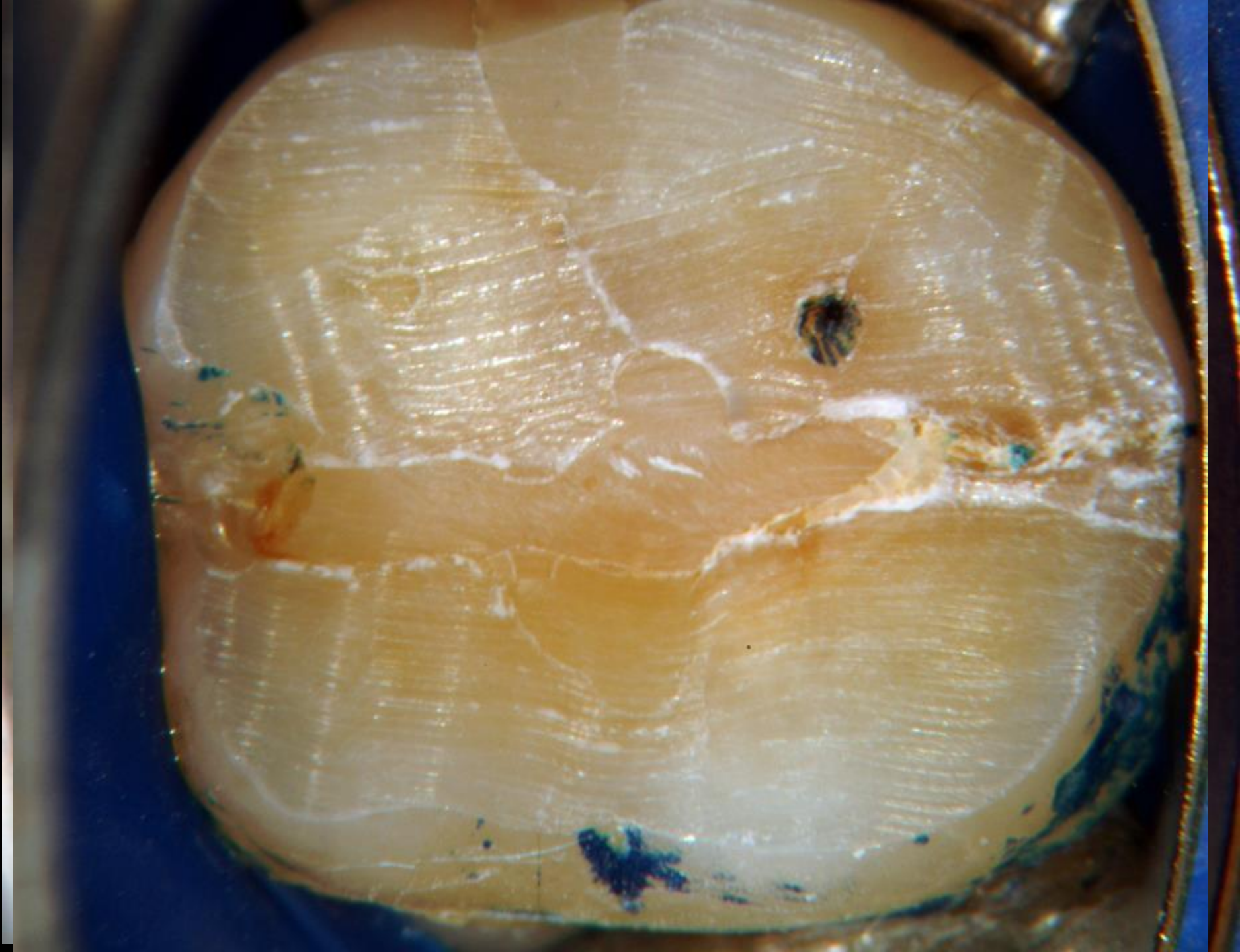


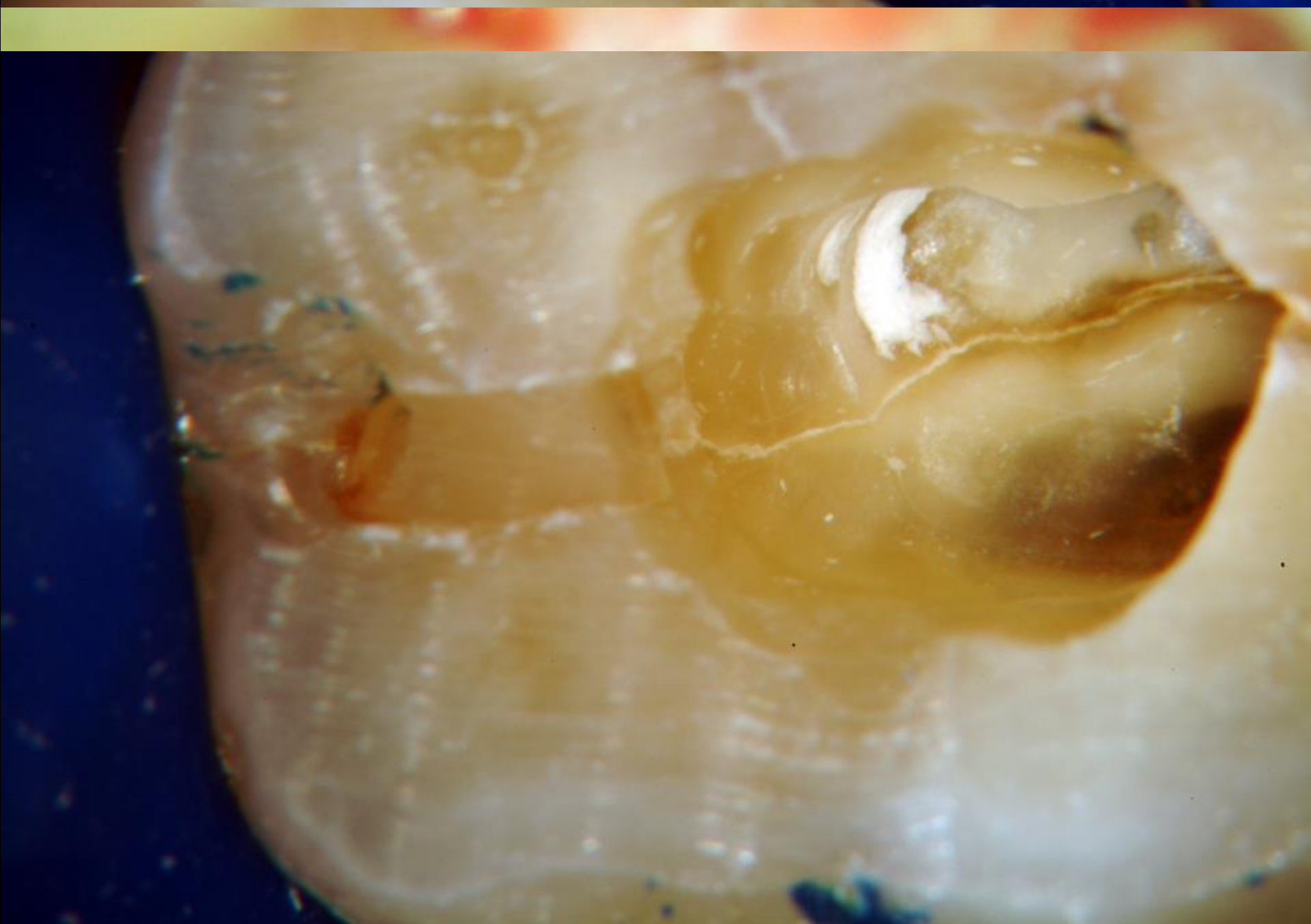*What
we
expected*

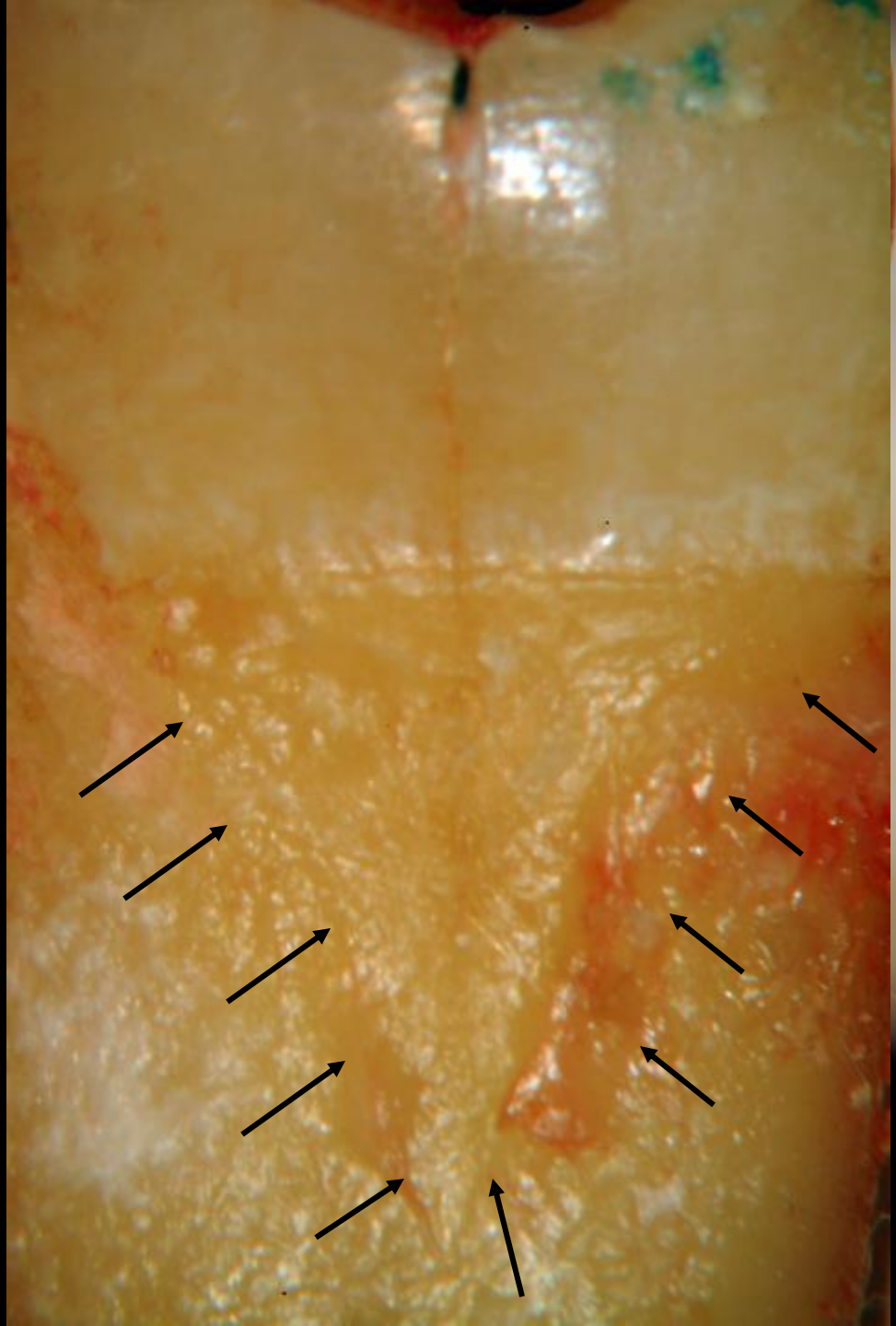


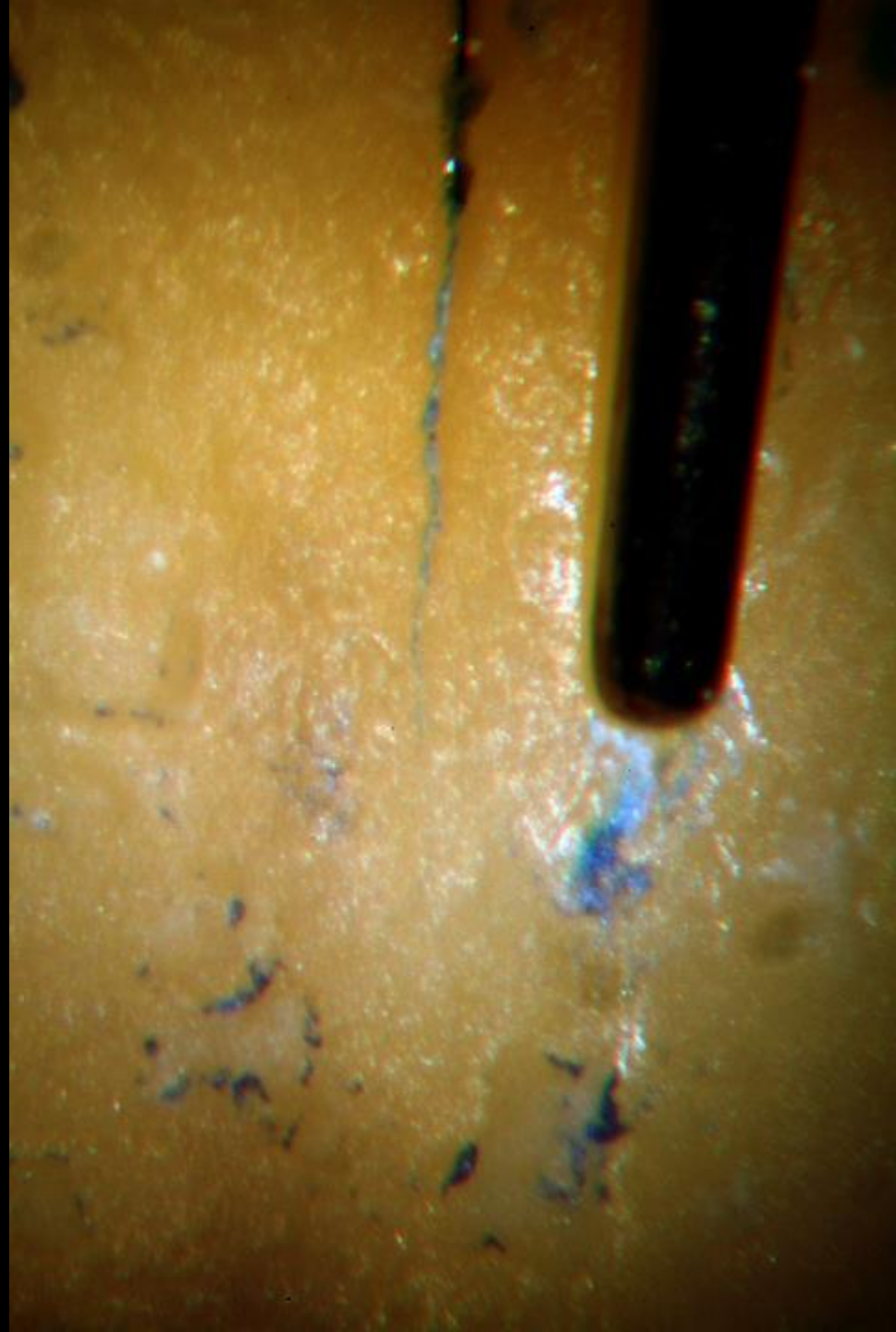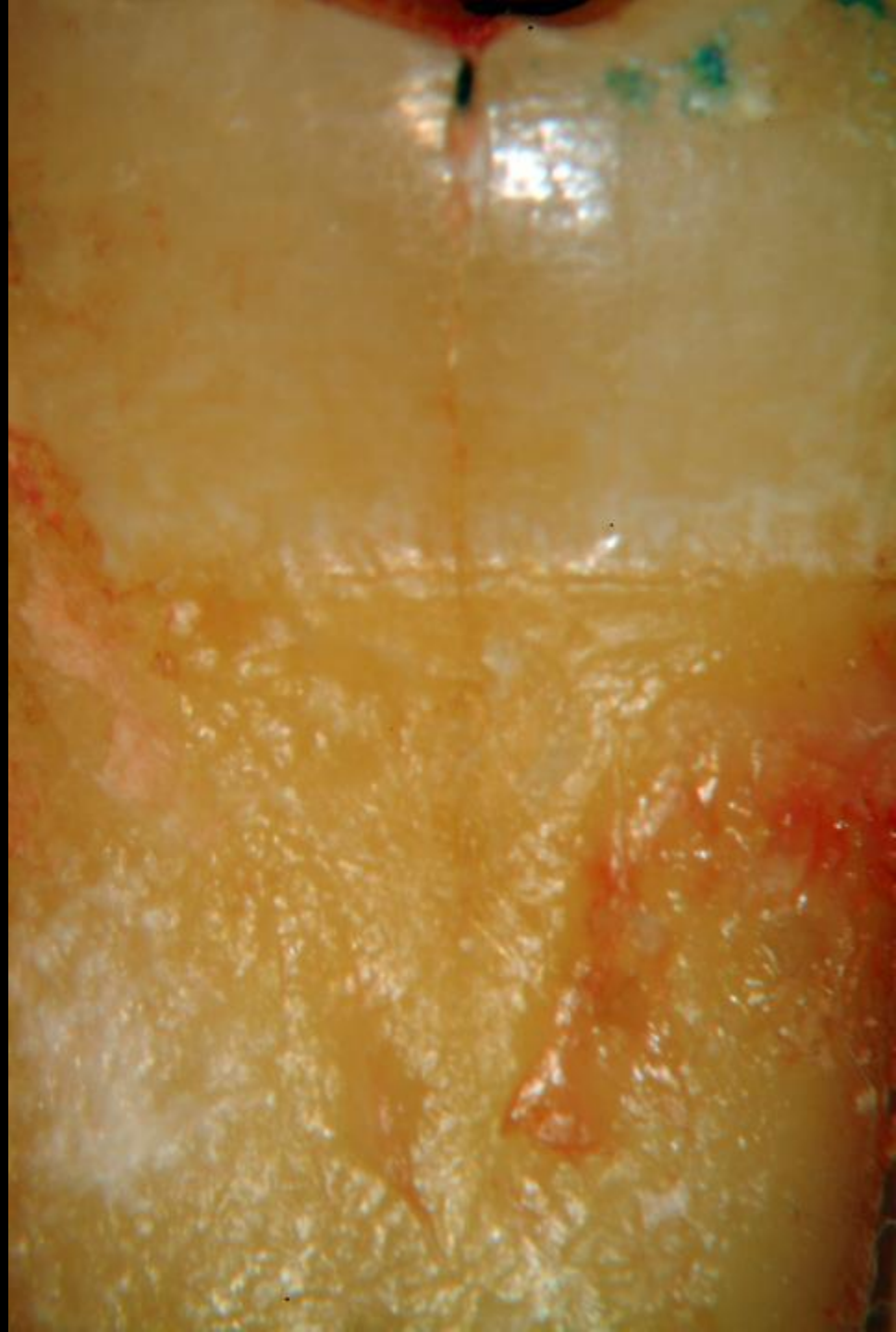
*What
we
probed*

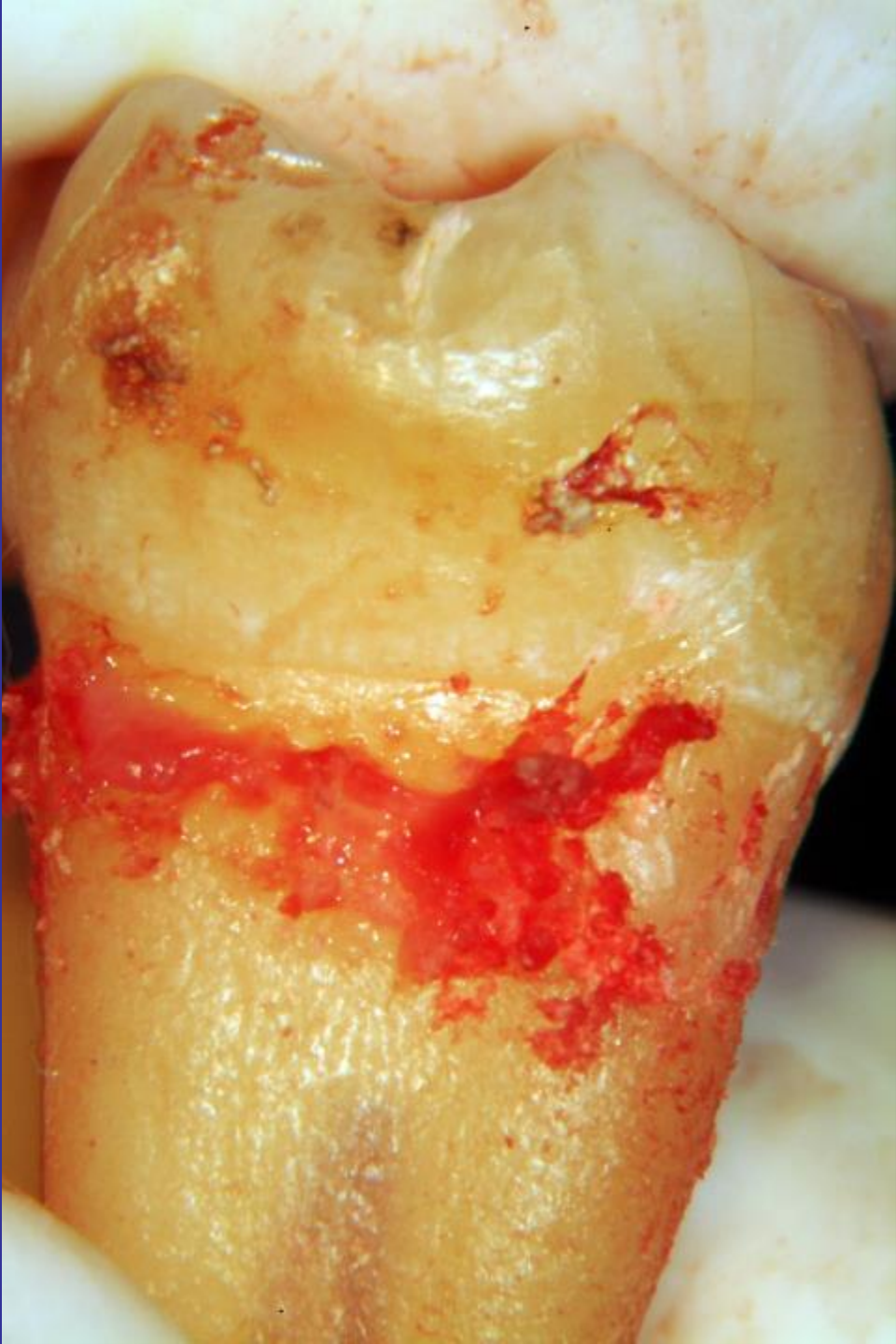
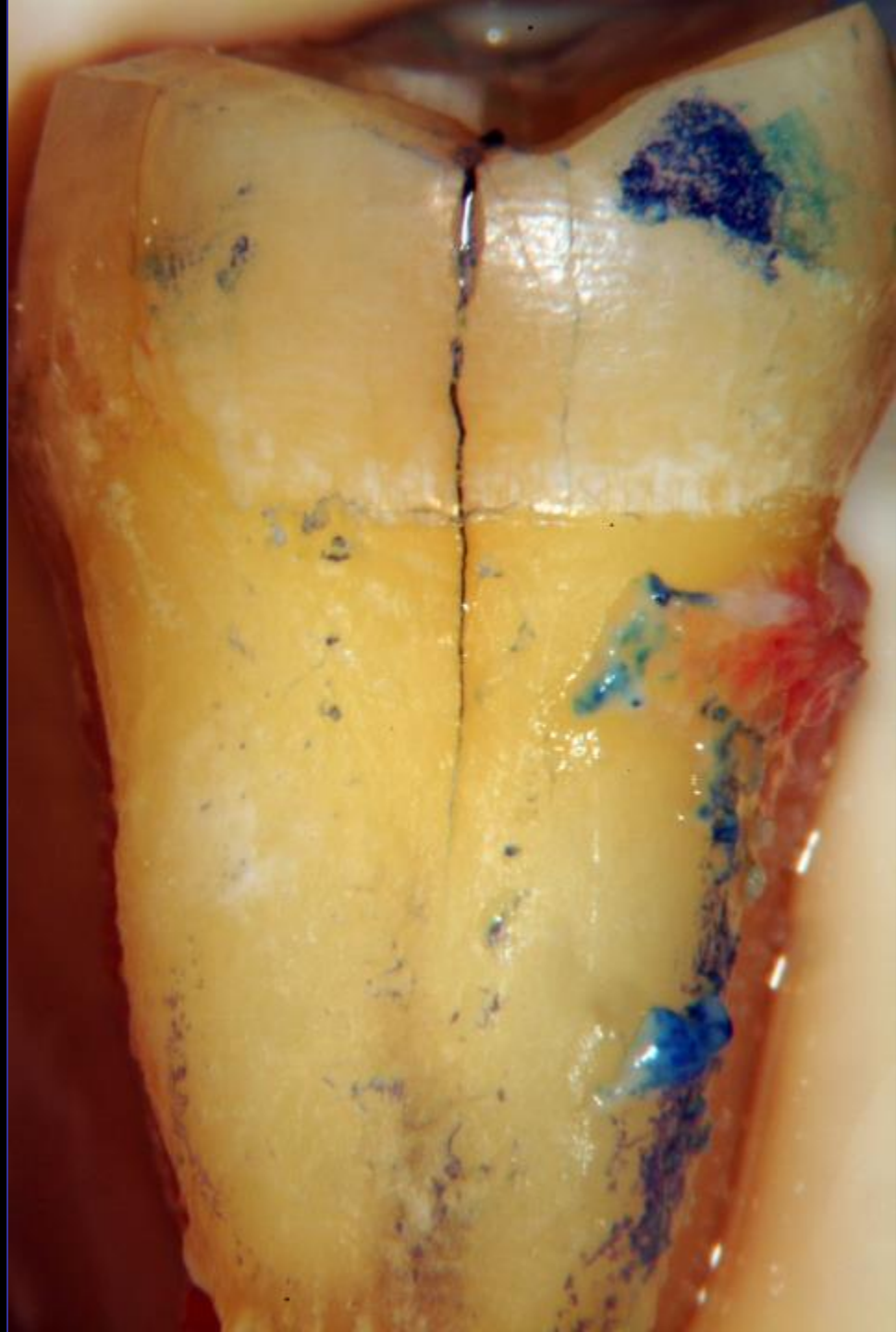
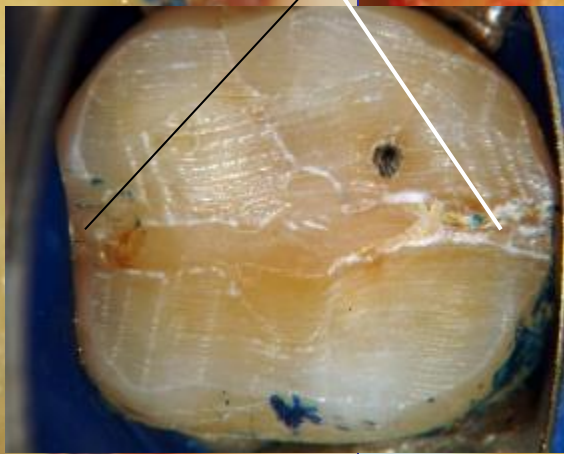
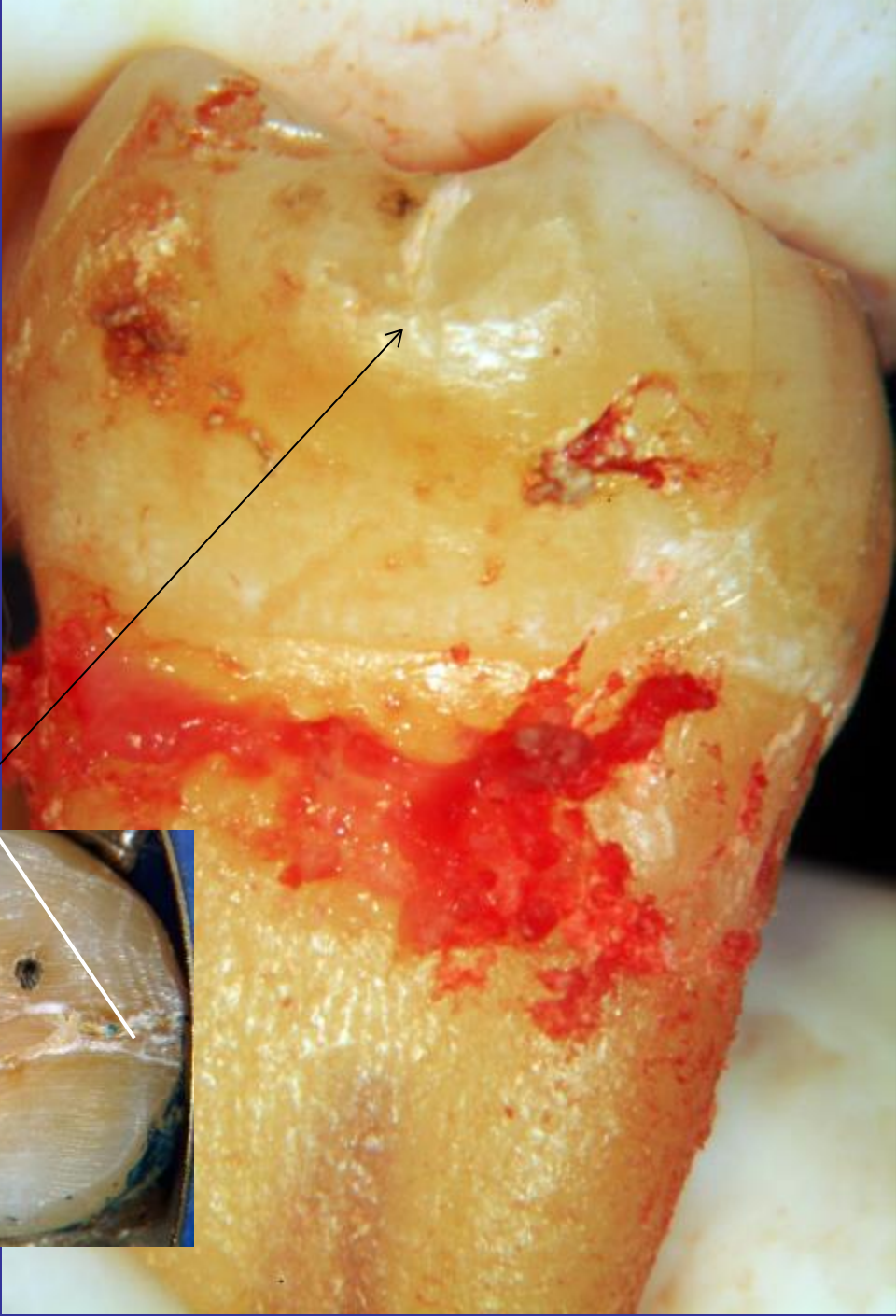
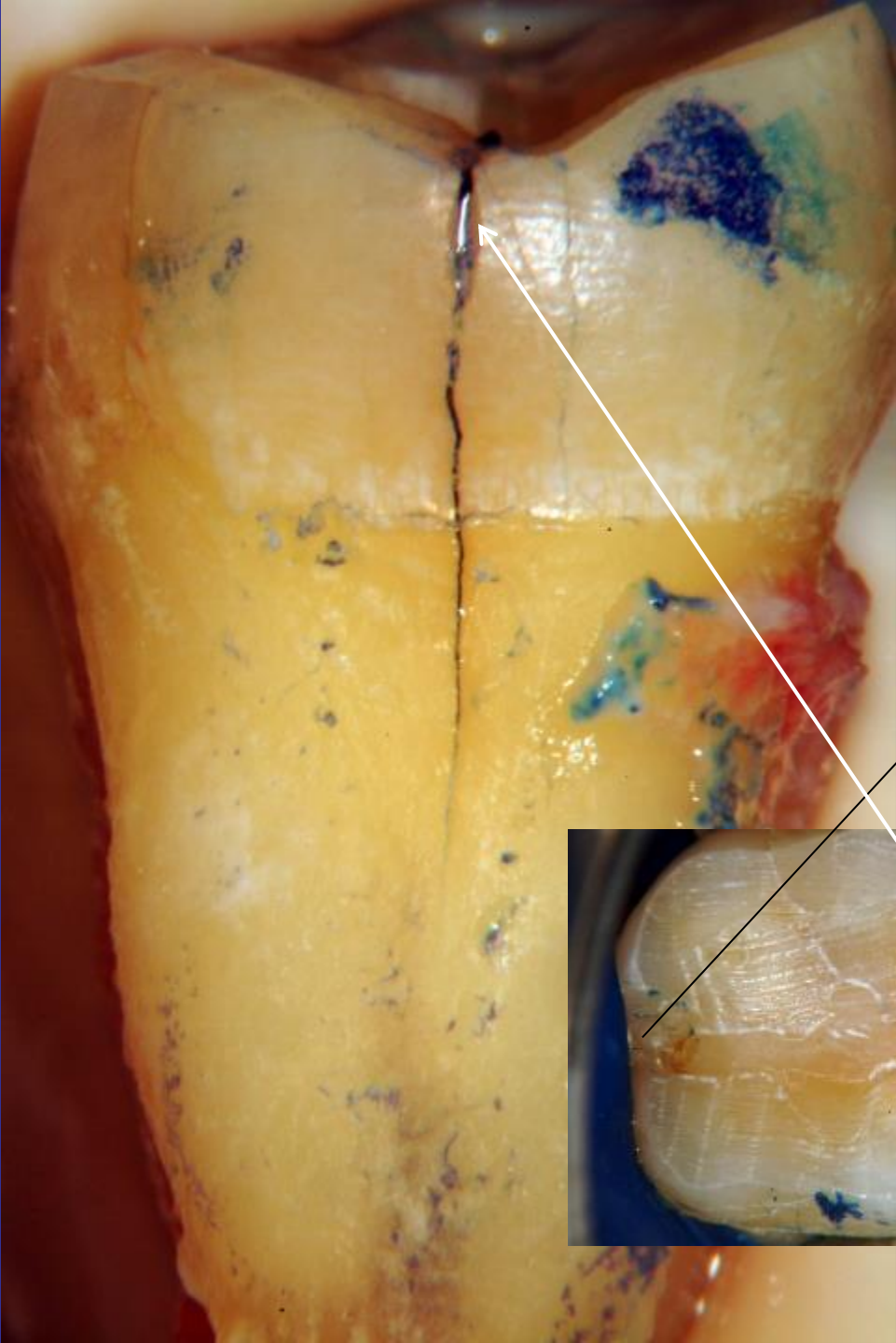






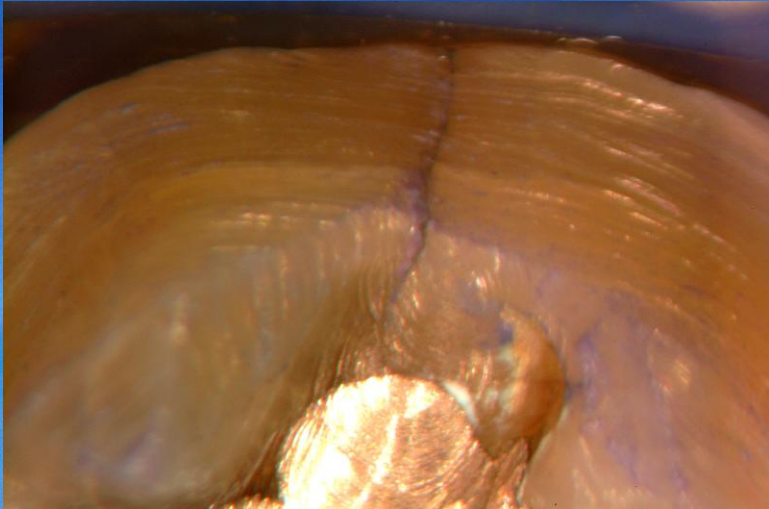




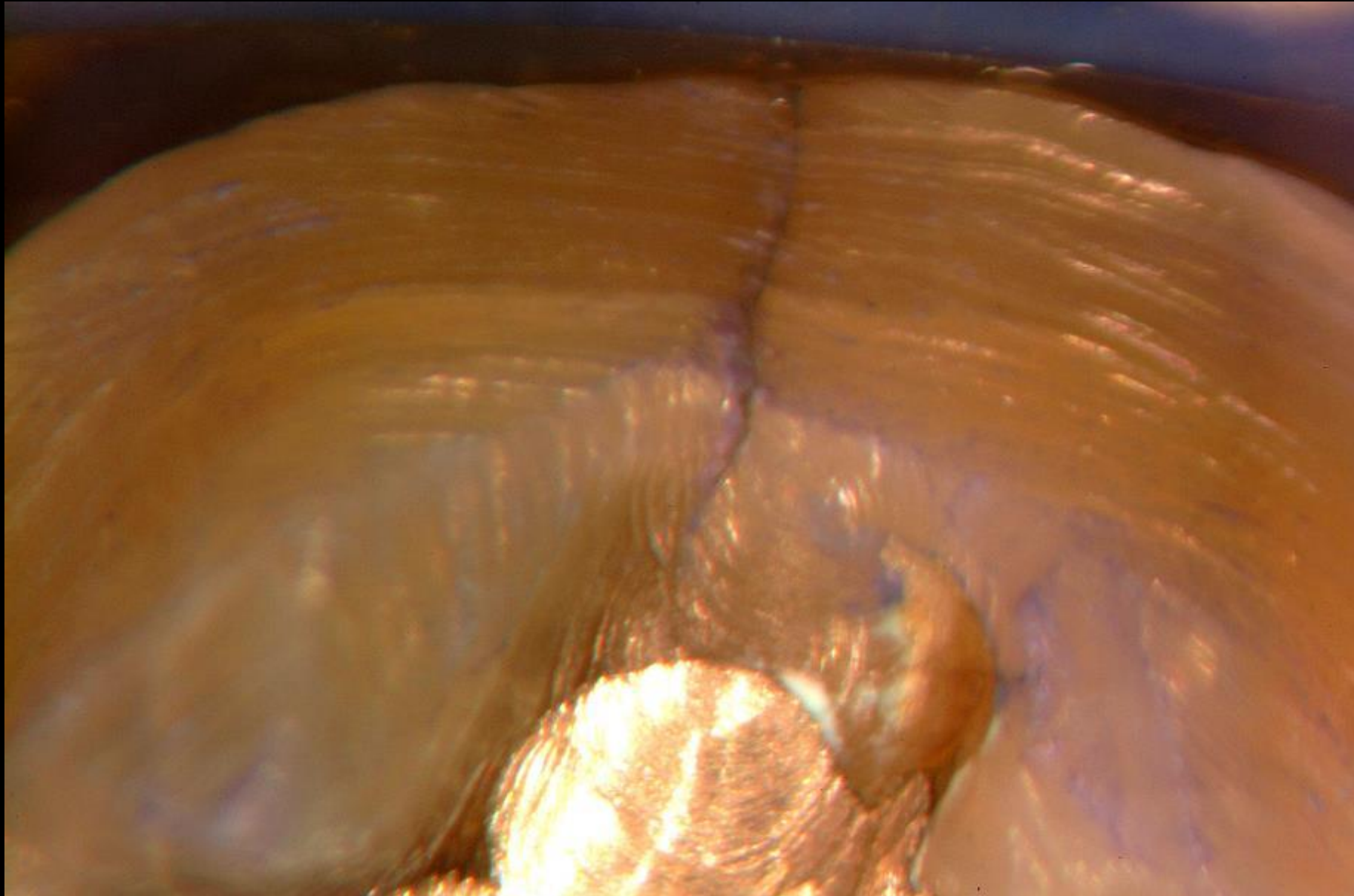


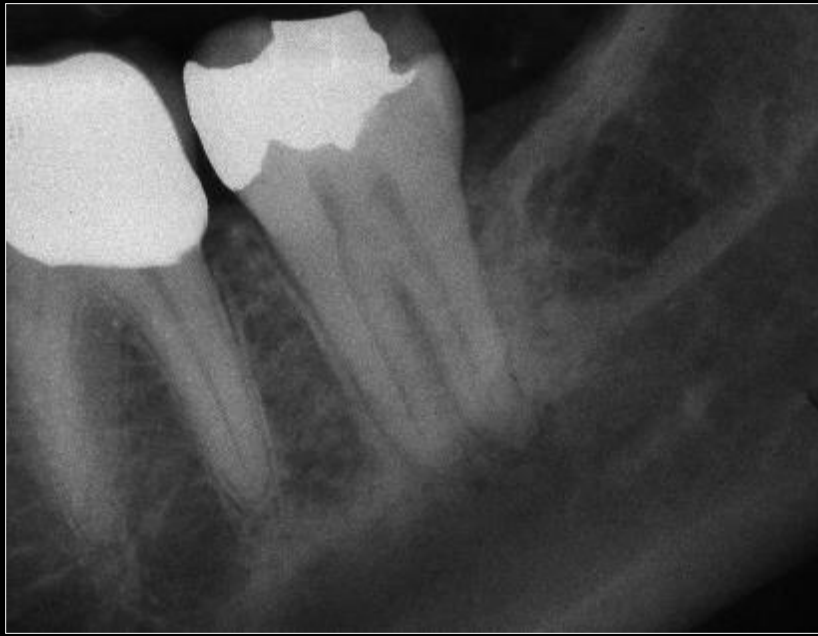
Incomplete and Complete Fractures

Case Study

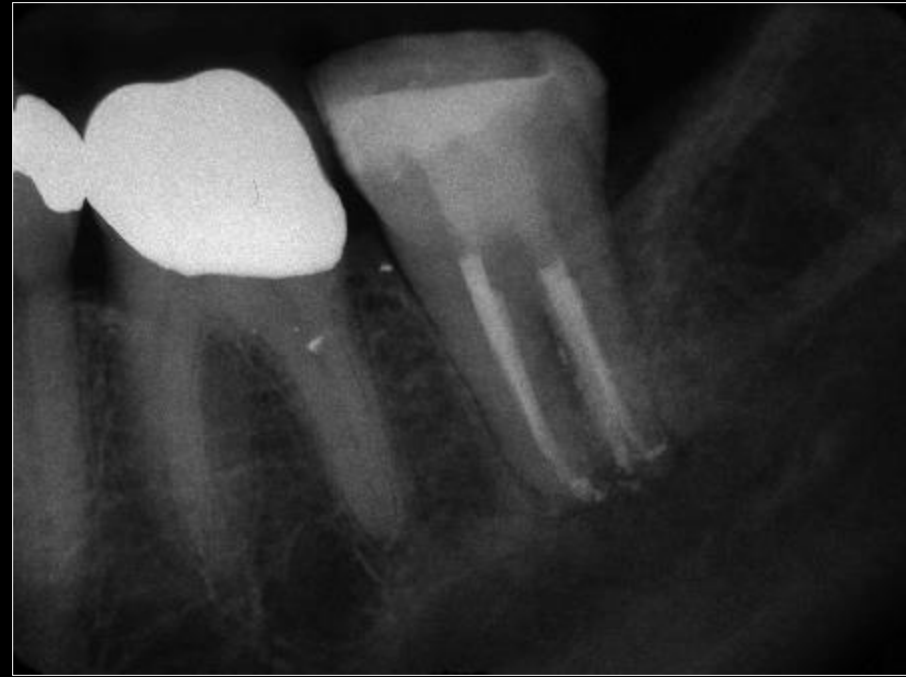

Occlusal view of distal

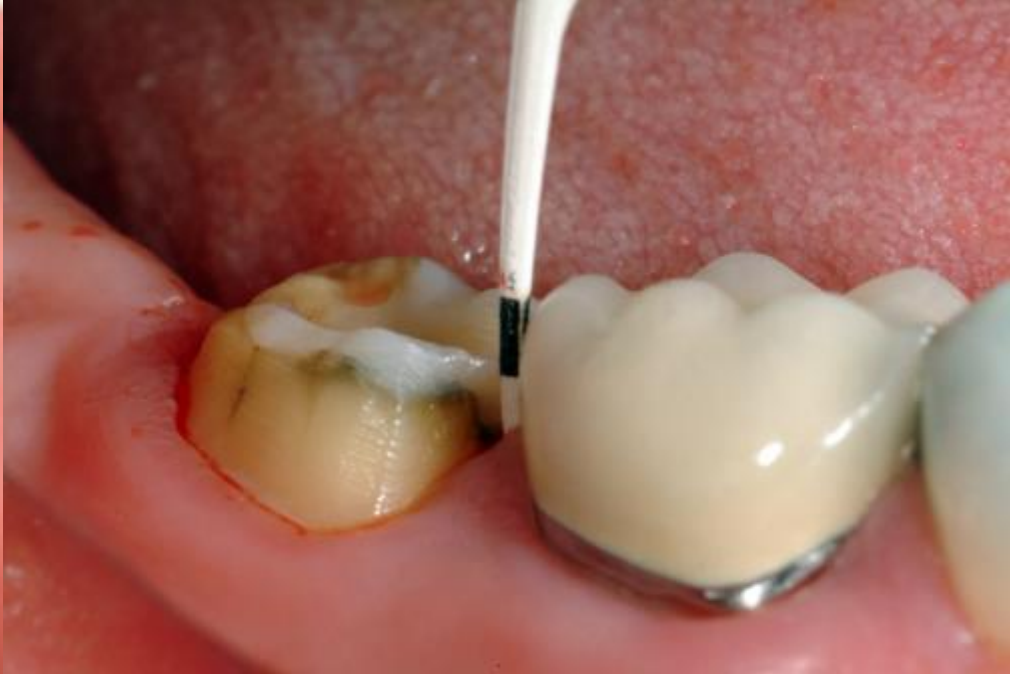
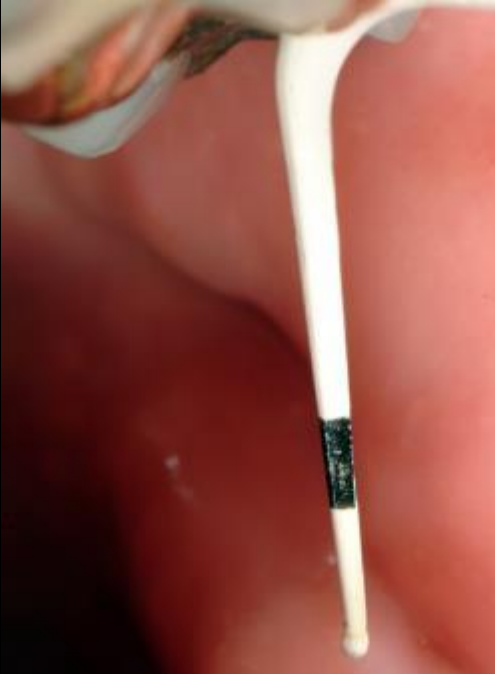


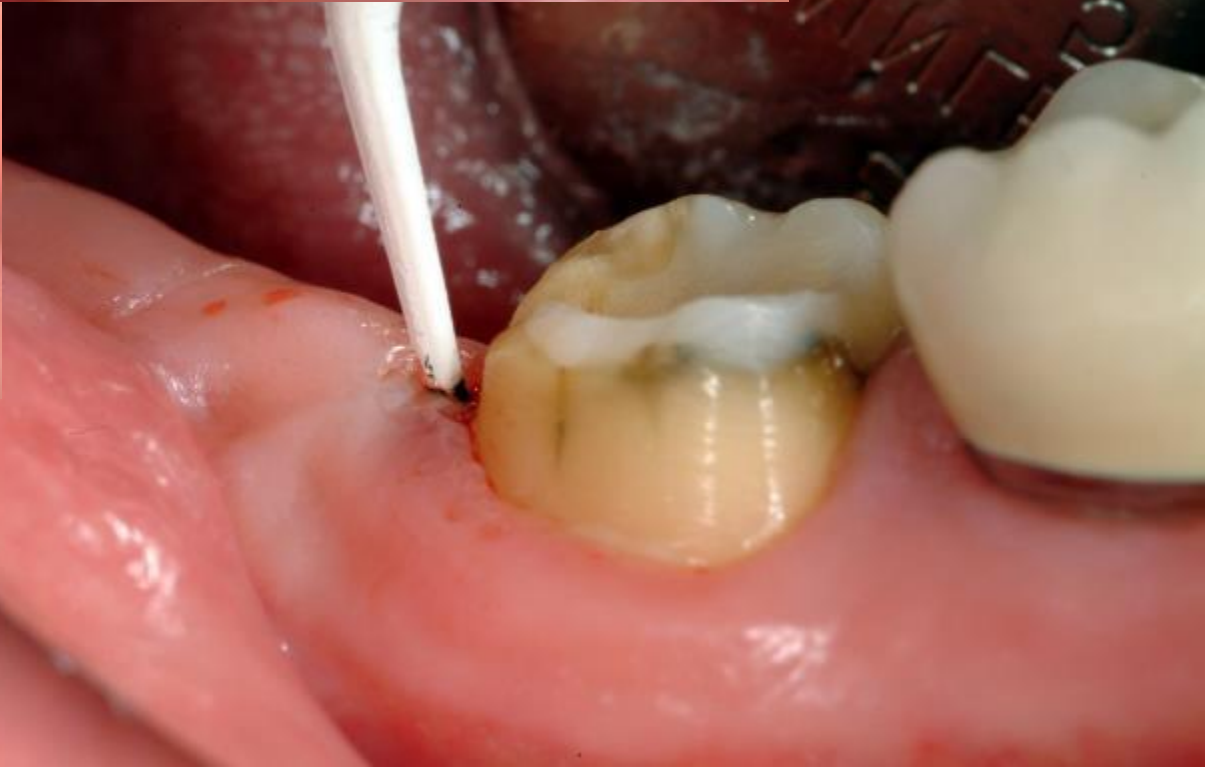
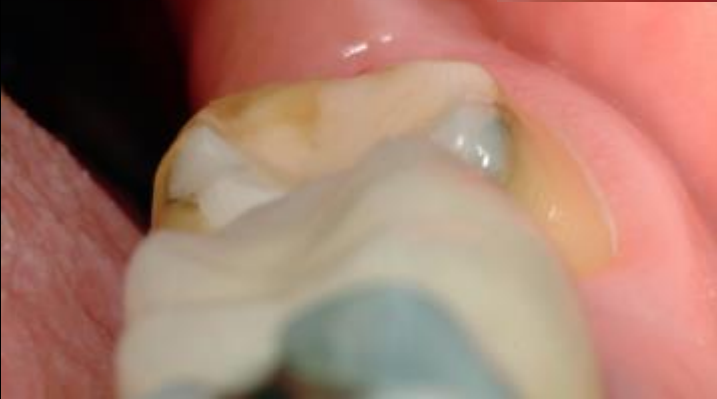Initial
appointment

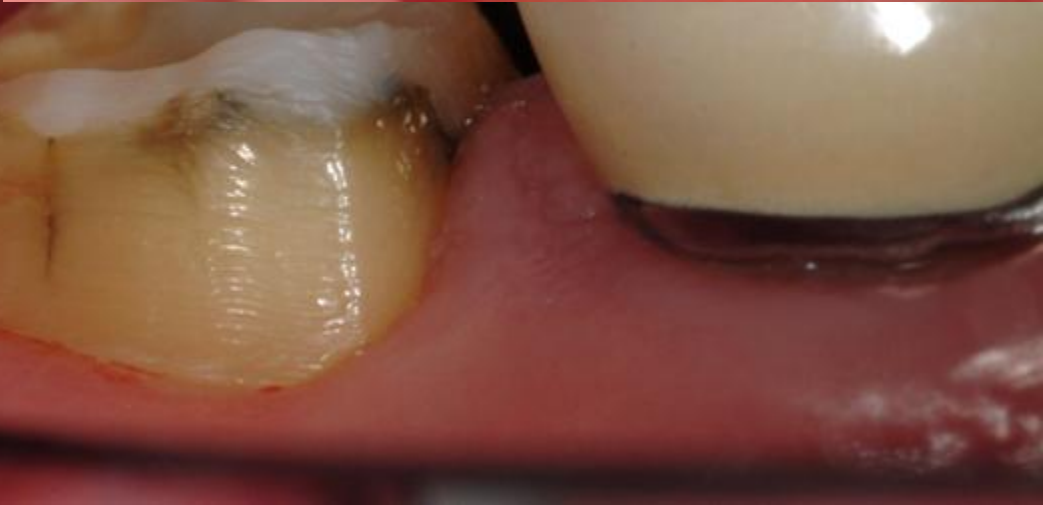
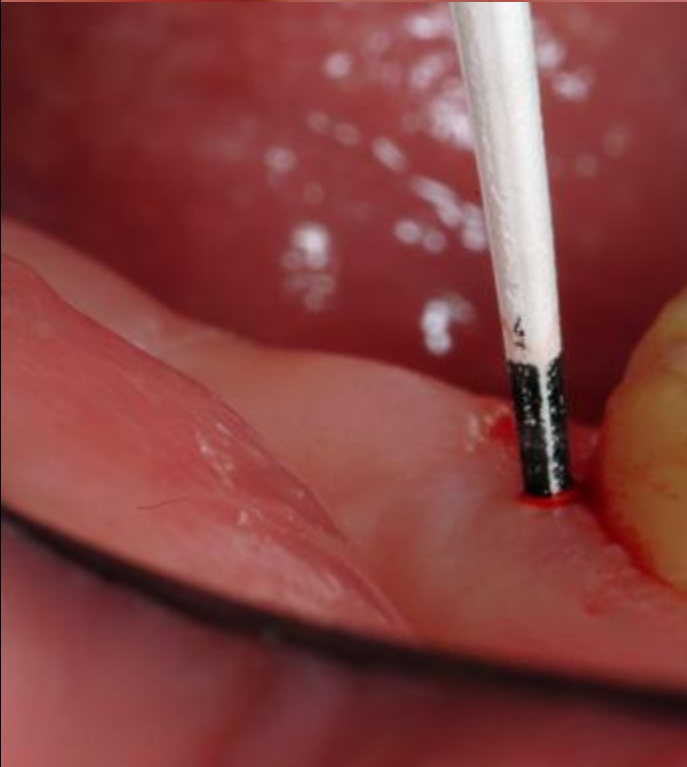
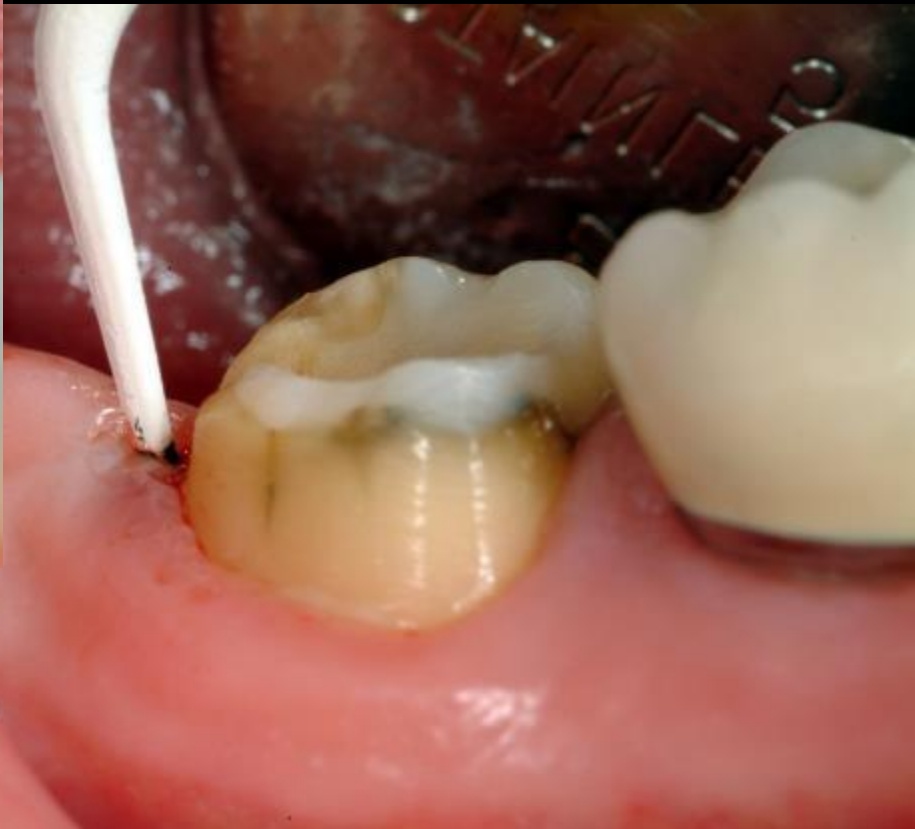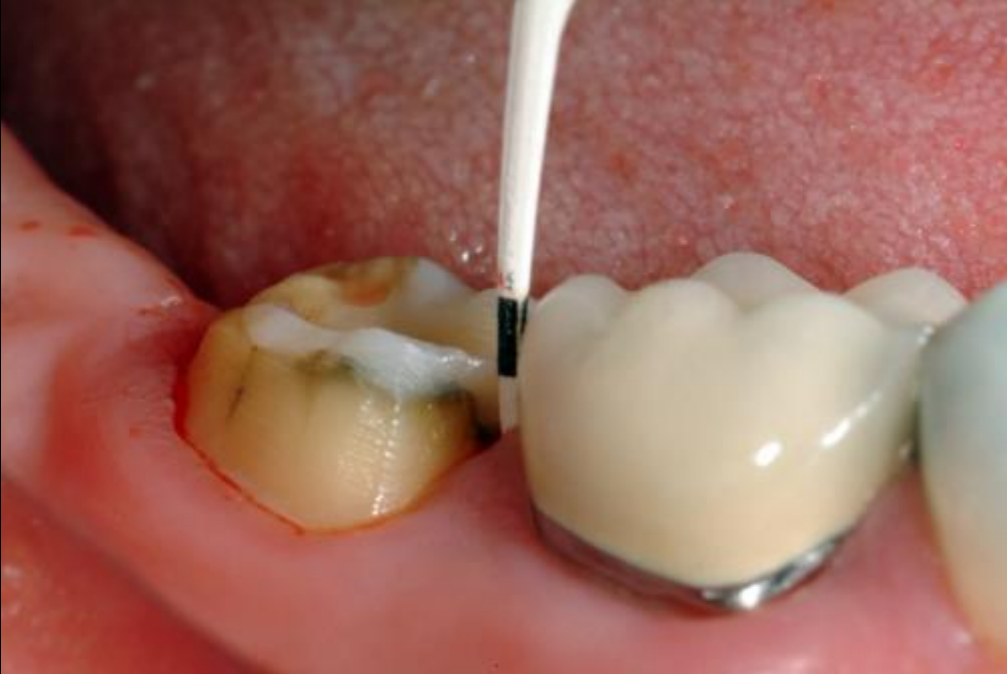3-6 month
wait with
temp crown



4 month
wait





The Old Cracked Tooth
Classification System...

Was Based on Symptoms
and Conjecture

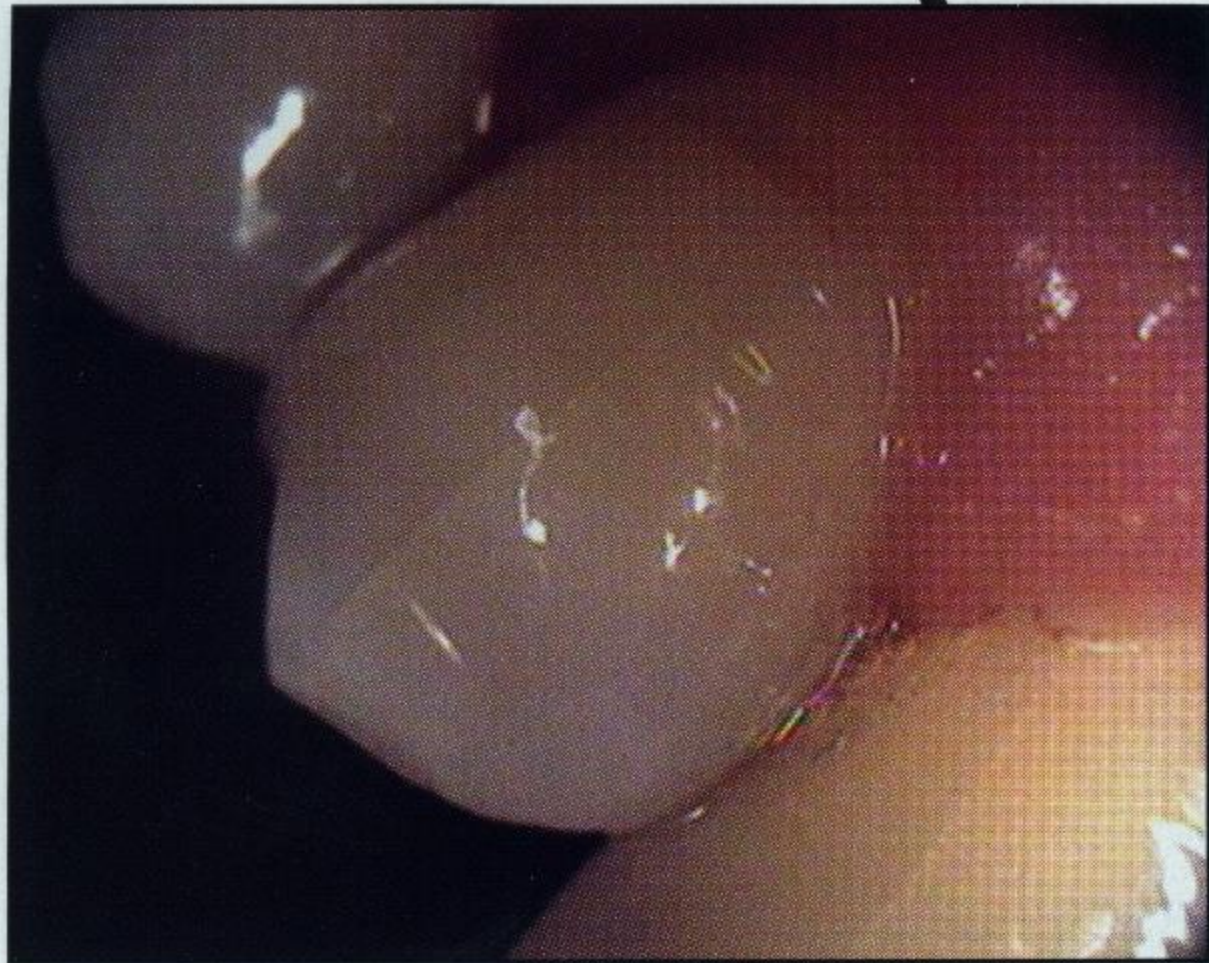
Epidemiologic
third most com
countries. This
syndrome is of

Cracked tooth syndrome

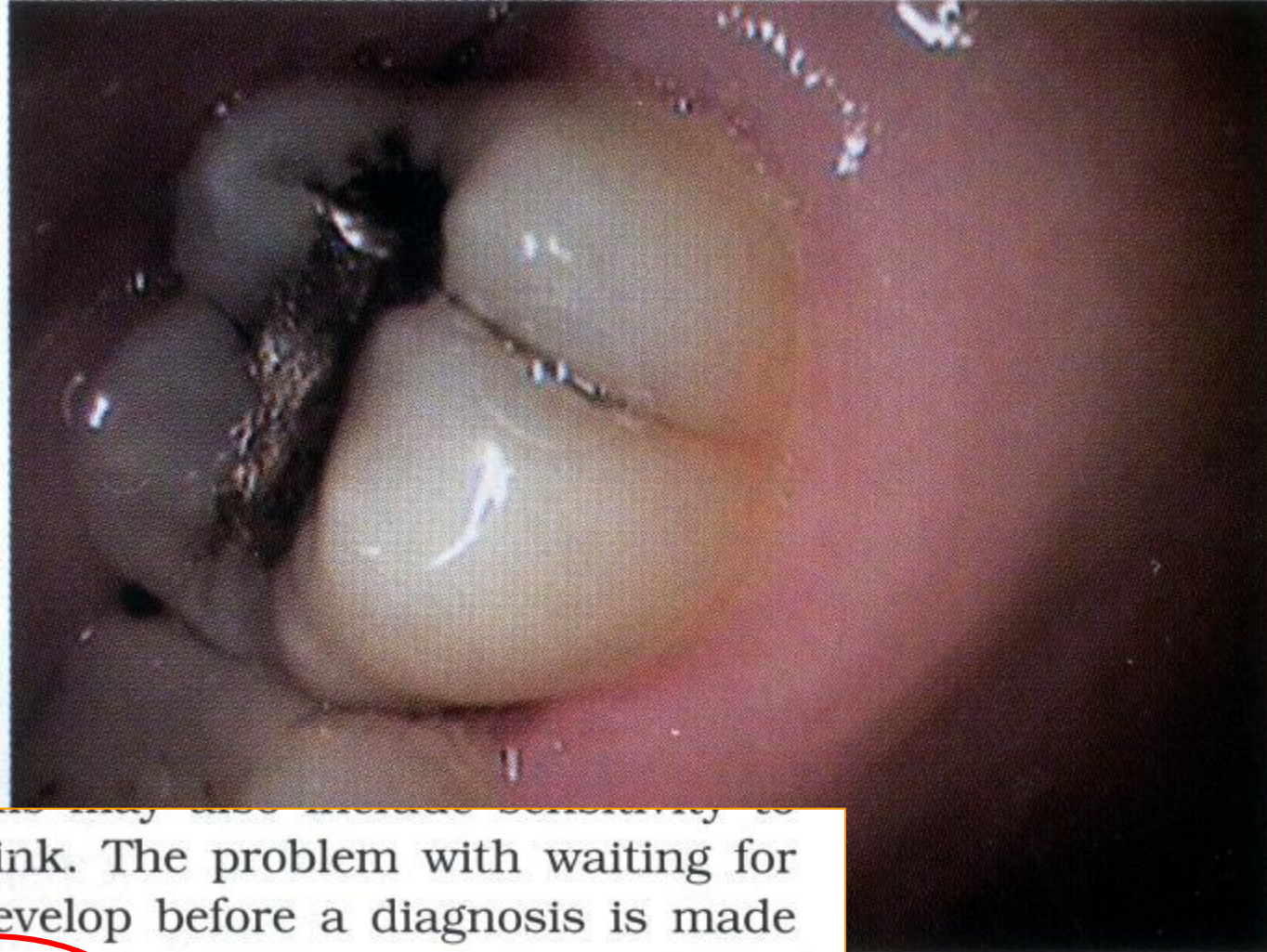
Figure 1

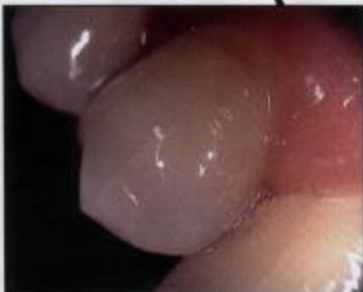

Figure 1



- Sad
main



cold food or drink. The problem with waiting for symptoms to develop before a diagnosis is made is that at this point the crack is usually at what is referred to by Clark⁵ as end-stage crack progression, requiring more aggressive treatment.

The emergence of the dental microscope has been a tremendous aid in the diagnosis and treatment of cracked teeth. The routine, methodical

“Build a bridge
from buccal to
lingual, and the
crack(s)
becomes
dormant.”



DR. ALEX FOK

Getting paid to be conservative

BIOCLEAR VS. CROWNS AND VENEERS

Bioclear is an alternative to traditional methods for enhancing a smile. Rather than preparing for a crown or veneer, the Bioclear Method preserves the natural tooth structure, enamel and tooth durability.



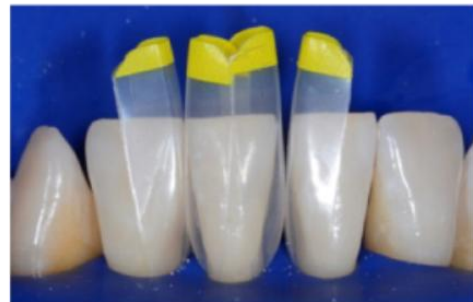
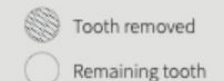AN HONEST LOOK AT CROWN PREPARATIONS

As illustrated below, crowns, veneers, and onlays require the removal of a significant amount of healthy tooth structure. Bioclear dentists can leave most or all of the tooth structure. Bioclear is a very attractive option to patients.



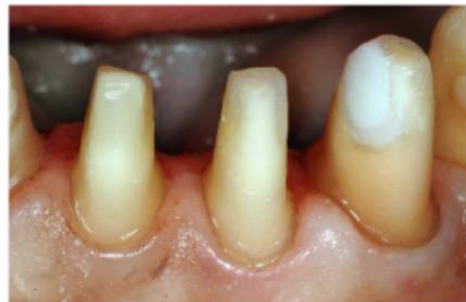~3/4 Crown
47% of tooth removed

Full Crown
76% of tooth removed



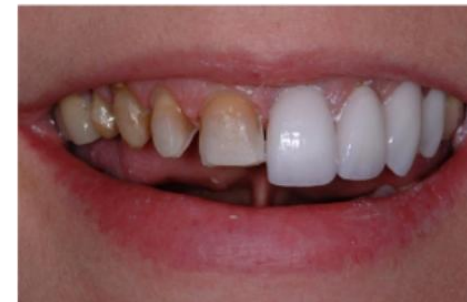BIOCLEAR PREPARATION

Bioclear allows dentists to **conserve** healthy tooth structure



CROWN PREPARATION

Crowns require dentists to **remove an average of 76%** of the tooth structure prior to the procedure



VENEER PREPARATION

Veneers require dentists to **remove an average of 47%** of the tooth structure prior to the procedure



DC BIOCLEAR LEARNING CENTER

Tacoma USA · Solihull UK
Varberg Sweden · Cairo Egypt
Syracuse Italy · Taubate Brazil
Livermore CA (Bioclear pediatrics)
Seoul Korea · Madrid/Barcelona
Sydney Australia · Baghdad Iraq

∞ BIOCLEAR

Stop by convention

booth #1242

to...

- ✓ Hear more about Bioclear courses
- ✓ Meet our team of Bioclear and Kuraray experts
- ✓ Order products
- ✓ Register for courses



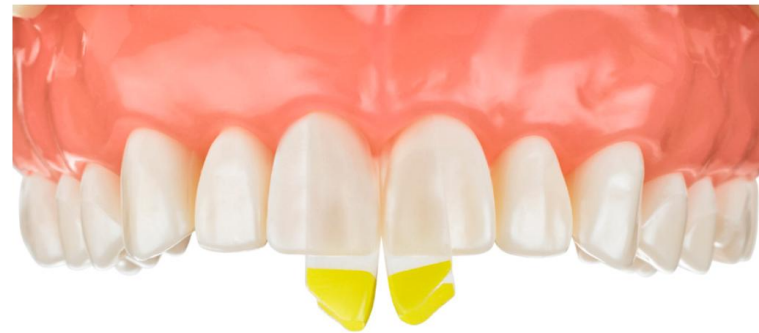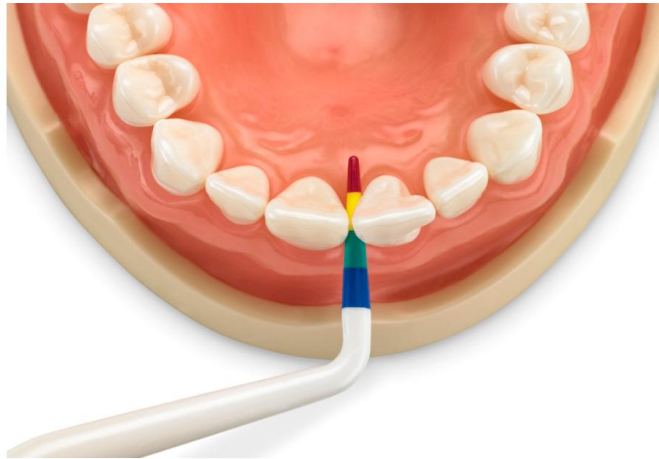
Treat yourself to a weekend with  BIOCLEAR

BLACK TRIANGLE

CERTIFICATION COURSE

18 CE CREDITS

This three-part live hands-on certification course will teach you how to treat black triangles, gingival recession, root abrasions, and perform confident restorations. In becoming a certified Bioclear black triangle doctor, you'll increase your overall skill and knowledge of Bioclear and learn to market your new skills to patients.



Upcoming Dates:

Denver


October 9th 2026

Walnut Creek

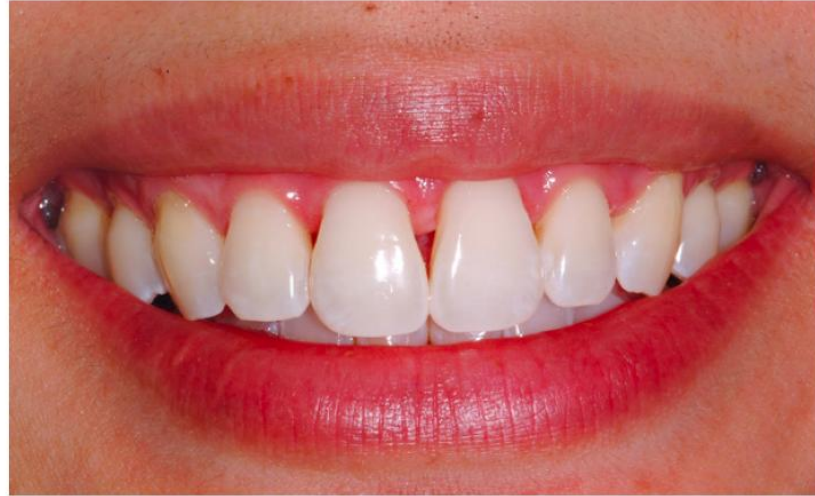August 21st 2026

Limited spots available!

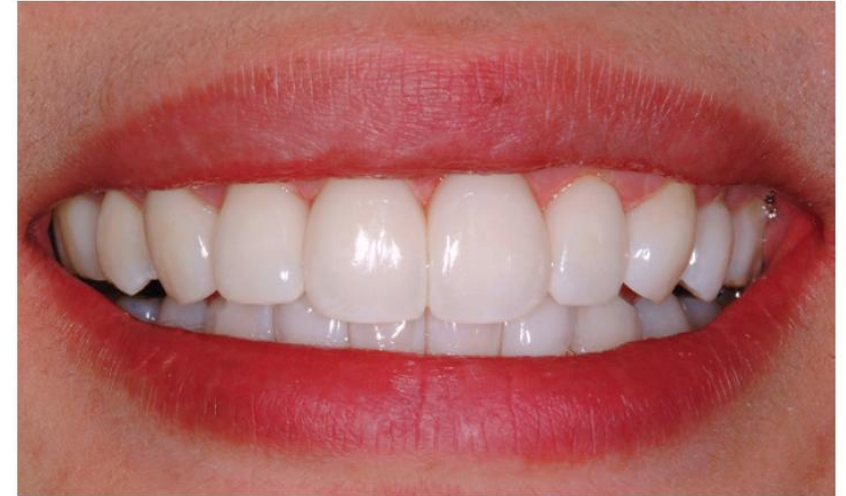Scan to learn more
& sign up for your
local BT Course!



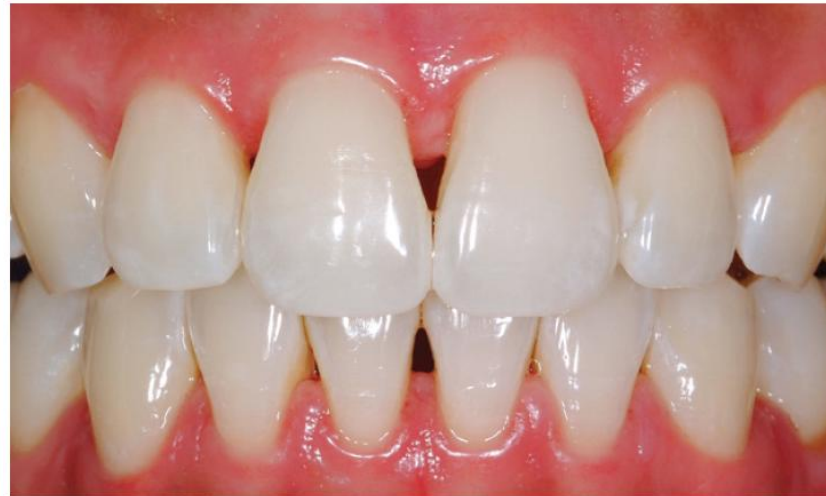www.bioclearmatrix.com/live-courses/



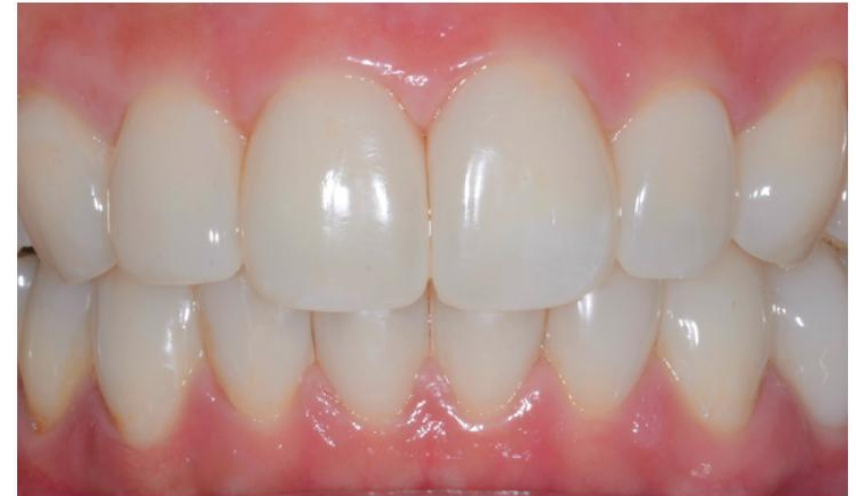BEFORE



AFTER



BEFORE



AFTER

2026 Certification Courses



- Core Anterior + Core Posterior • Complex Cases & Problem Solving
- Smile Design & Comprehensive Anterior Rejuvenation • Bioclear Alumni Summit

January

S	M	T	W	T	F	S
				1	2	3
4	5	6	7	8	9	10
11	12	13	14	15	16	17
18	19	20	21	22	23	24
25	26	27	28	29	30	31

February

S	M	T	W	T	F	S
1	2	3	4	5	6	7
8	9	10	11	12	13	14
15	16	17	18	19	20	21
22	23	24	25	26	27	28

March

S	M	T	W	T	F	S
1	2	3	4	5	6	7
8	9	10	11	12	13	14
15	16	17	18	19	20	21
22	23	24	25	26	27	28
29	30	31				

April

S	M	T	W	T	F	S
			1	2	3	4
5	6	7	8	9	10	11
12	13	14	15	16	17	18
19	20	21	22	23	24	25
26	27	28	29	30		

May

S	M	T	W	T	F	S
					1	2
3	4	5	6	7	8	9
10	11	12	13	14	15	16
17	18	19	20	21	22	23
24	25	26	27	28	29	30
31						

June

S	M	T	W	T	F	S
	1	2	3	4	5	6
7	8	9	10	11	12	13
14	15	16	17	18	19	20
21	22	23	24	25	26	27
28	29	30				

July

S	M	T	W	T	F	S
			1	2	3	4
5	6	7	8	9	10	11
12	13	14	15	16	17	18
19	20	21	22	23	24	25
26	27	28	29	30	31	

August

S	M	T	W	T	F	S
						1
2	3	4	5	6	7	8
9	10	11	12	13	14	15
16	17	18	19	20	21	22
23	24	25	26	27	28	29
30	31					

September

S	M	T	W	T	F	S
		1	2	3	4	5
6	7	8	9	10	11	12
13	14	15	16	17	18	19
20	21	22	23	24	25	26
27	28	29	30			

October

S	M	T	W	T	F	S
				1	2	3
4	5	6	7	8	9	10
11	12	13	14	15	16	17
18	19	20	21	22	23	24
25	26	27	28	29	30	31

November

S	M	T	W	T	F	S
1	2	3	4	5	6	7
8	9	10	11	12	13	14
15	16	17	18	19	20	21
22	23	24	25	26	27	28
29	30					

December

S	M	T	W	T	F	S
		1	2	3	4	5
6	7	8	9	10	11	12
13	14	15	16	17	18	19
20	21	22	23	24	25	26
27	28	29	30	31		

2027 Certification Courses



- Core Anterior + Core Posterior • Complex Cases & Problem Solving
- Smile Design & Comprehensive Anterior Rejuvenation

JANUARY

S	M	T	W	T	F	S
					01	02
03	04	05	06	07	08	09
10	11	12	13	14	15	16
17	18	19	20	21	22	23
24	25	26	27	28	29	30
31						

FEBRUARY

S	M	T	W	T	F	S
	01	02	03	04	05	06
07	08	09	10	11	12	13
14	15	16	17	18	19	20
21	22	23	24	25	26	27
28						

MARCH

S	M	T	W	T	F	S
	01	02	03	04	05	06
07	08	09	10	11	12	13
14	15	16	17	18	19	20
21	22	23	24	25	26	27
28	29	30	31			

APRIL

S	M	T	W	T	F	S
				01	02	03
04	05	06	07	08	09	10
11	12	13	14	15	16	17
18	19	20	21	22	23	24
25	26	27	28	29	30	

MAY

S	M	T	W	T	F	S
						01
02	03	04	05	06	07	08
09	10	11	12	13	14	15
16	17	18	19	20	21	22
23	24	25	26	27	28	29
30	31					

JUNE

S	M	T	W	T	F	S
		01	02	03	04	05
06	07	08	09	10	11	12
13	14	15	16	17	18	19
20	21	22	23	24	25	26
27	28	29	30			

JULY

S	M	T	W	T	F	S
				01	02	03
04	05	06	07	08	09	10
11	12	13	14	15	16	17
18	19	20	21	22	23	24
25	26	27	28	29	30	31

AUGUST

S	M	T	W	T	F	S
01	02	03	04	05	06	07
08	09	10	11	12	13	14
15	16	17	18	19	20	21
22	23	24	25	26	27	28
29	30	31				

SEPTEMBER

S	M	T	W	T	F	S
			01	02	03	04
05	06	07	08	09	10	11
12	13	14	15	16	17	18
19	20	21	22	23	24	25
26	27	28	29	30		

OCTOBER

S	M	T	W	T	F	S
					01	02
03	04	05	06	07	08	09
10	11	12	13	14	15	16
17	18	19	20	21	22	23
24	25	26	27	28	29	30
31						


NOVEMBER

S	M	T	W	T	F	S
	01	02	03	04	05	06
07	08	09	10	11	12	13
14	15	16	17	18	19	20
21	22	23	24	25	26	27
28	29	30				

DECEMBER

S	M	T	W	T	F	S
				01	02	03
					04	
05	06	07	08	09	10	11
12	13	14	15	16	17	18
19	20	21	22	23	24	25
26	27	28	29	30	31	

For a copy of today's presentation,
Learning Center info or the essential
Bioclear Library



∞ BIOCLEAR

Stop by convention

booth #1242

to...

- ✓ Hear more about Bioclear courses
- ✓ Meet our team of Bioclear and Kuraray experts
- ✓ Order products
- ✓ Register for courses

