



Modern Composite Dentistry: CRUSH your next Class II

David Clark DDS Lauren Wilson DMD

featuring

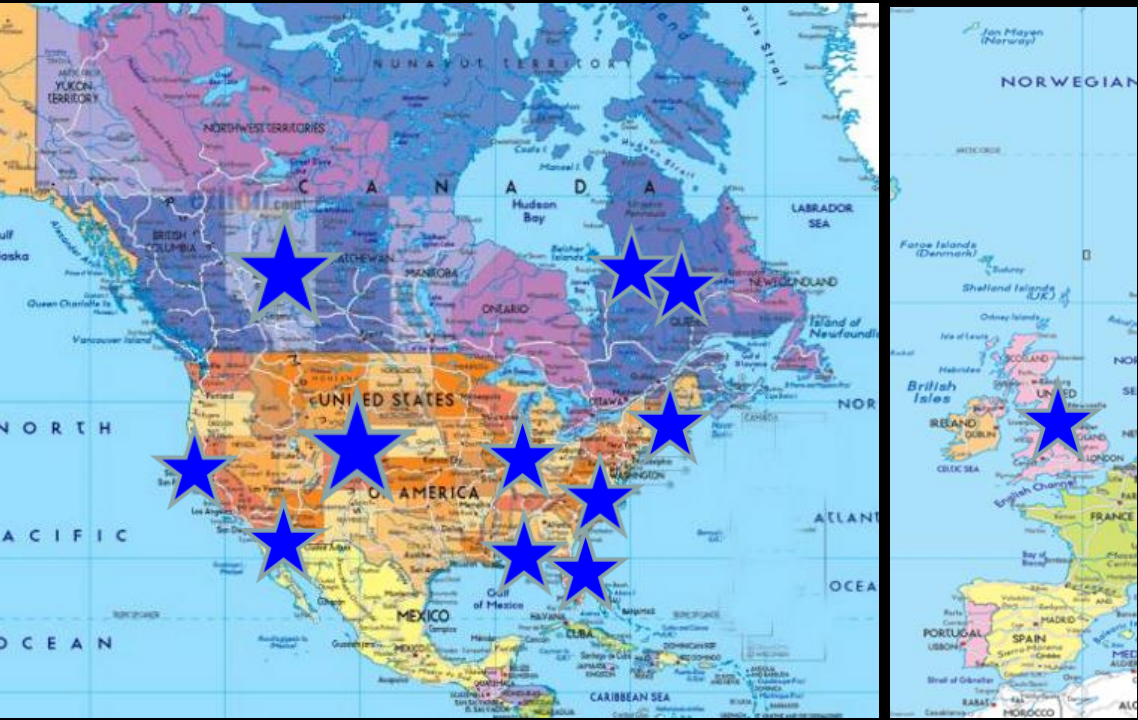
 BIOCLEAR



BIOCLEAR LEARNING CENTER

Tacoma USA · Solihull UK
Varberg Sweden · Cairo Egypt
Syracuse Italy · Taubate Brazil
Livermore CA (Bioclear pediatrics)
Seoul Korea · Madrid/Barcelona
Sydney Australia · Provence France
Baghdad Iraq

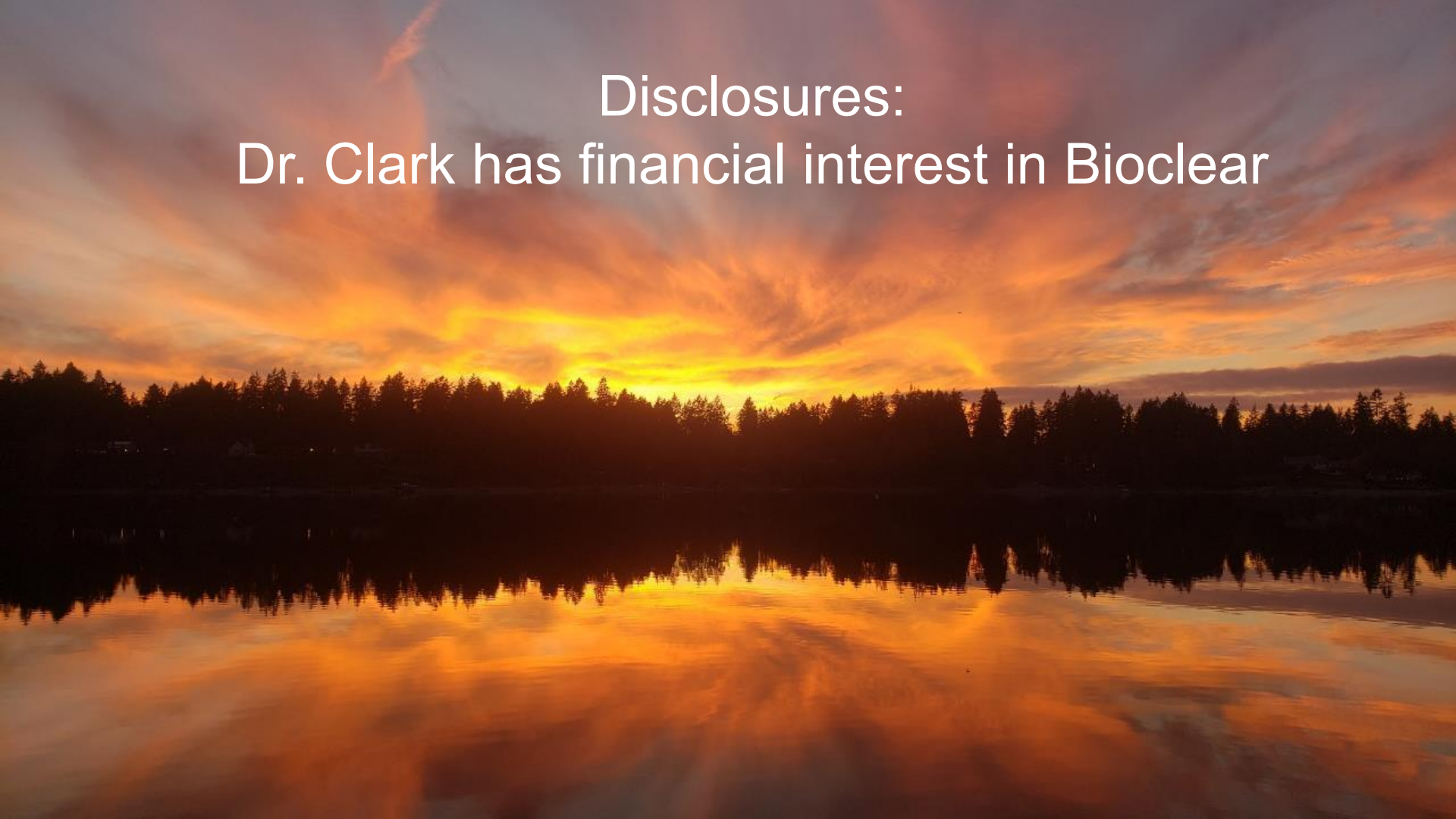Dental schools/GPR integrating the Bioclear Method



For a copy of today's presentation,
Learning Center info or the essential
Learning Center Library



Disclosures:
Dr. Clark has financial interest in Bioclear



Modern Method for Composite Restorations

Clear Anatomic Matrices, Powerful Separation

- Anterior & Posterior Matrices
- Designed to mimic nature

Injection Molded Composite

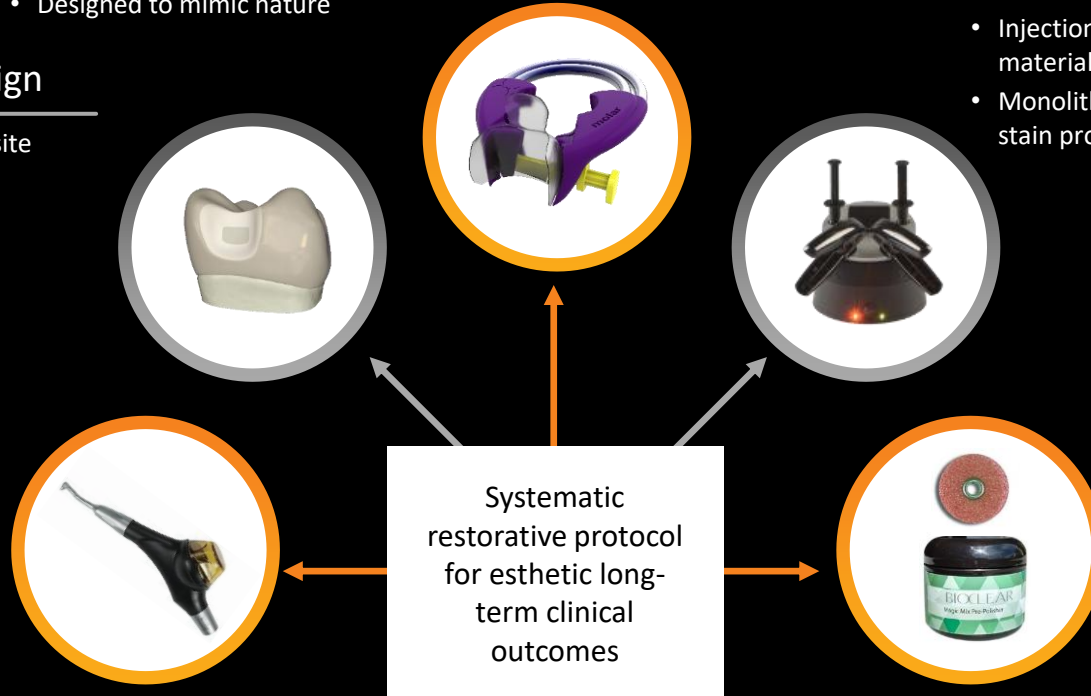
- Injection mold warmed Restorative materials
- Monolithic strength and Infinity Edge stain proof margins

Preparation Design

- Designed for composite
- Minimizes stress concentration
- Maximizes enamel involvement

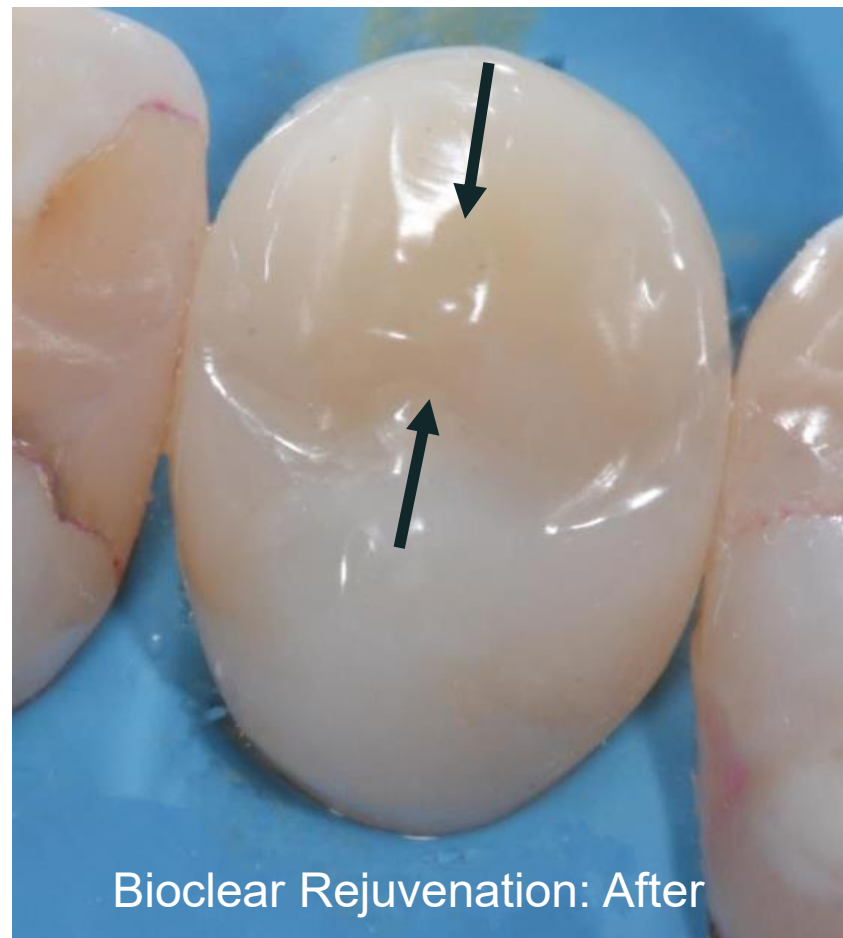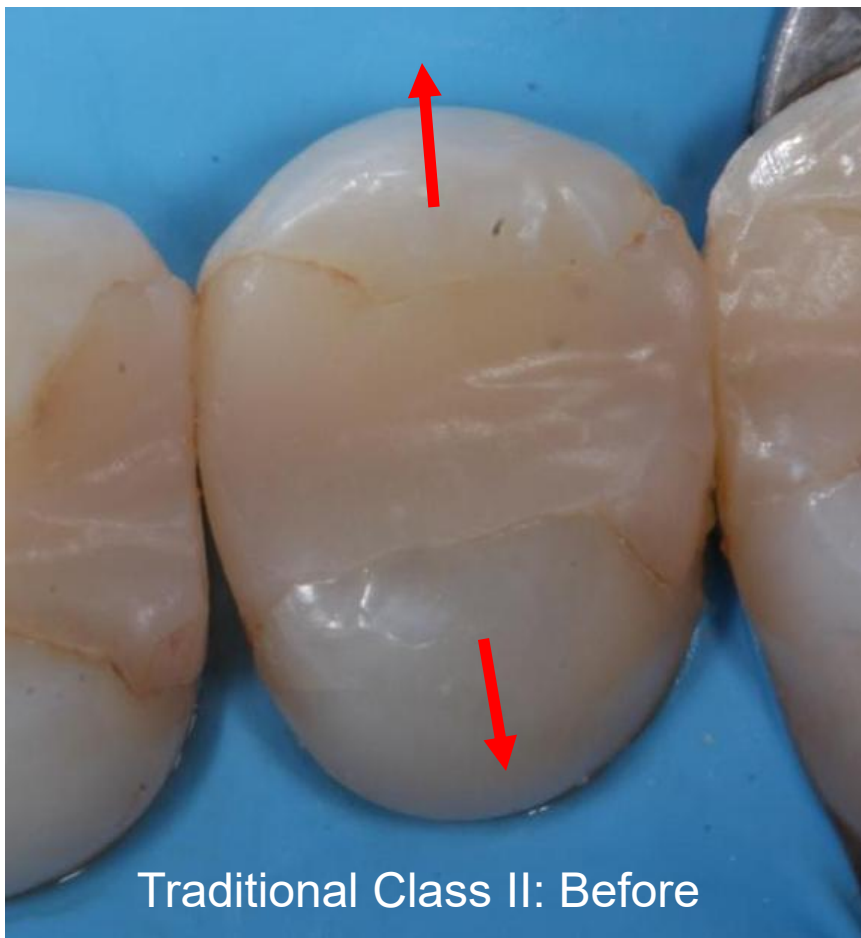Biofilm Removal

- Remove biofilm before bonding
- Allows bonding to uncut enamel
- Allows infinity edge margins



Final Polish

- “Rock Star” polish with Bioclear Magic Mix & RS Polisher



THE SCIENCE OF STRONG RESTORED TEETH




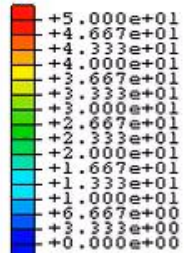
DR. DAVID CLARK



DR. ALEX FOK

Step: Step-1 Frame: 0

S, Max. Principal
(Avg: 75%)



2
3
1

ABAQUS Structural Analysis with Job Name = model-nl-con Created on Date = 25-A
ODB: model-cdm-nl.odb ABAQUS/STANDARD Version 6.6-1 Wed May 03 13:28:29 GMT Daylight

Step: Step-1
Increment 0: Span Time = 0.000
Primary Var: S, Max. Principal
Deformed Var: U Deformation Scale Factor: +1.000e+01

Epidemic of Cracked Teeth



“Around” the tooth versus
“In” the tooth



Step by Step Guide for Injection Molded Class II

1st Pillar of Modern Composite

Disclosing of Biofilm, then
Blasting to remove Biofilm plus
remove Protein Pellicle

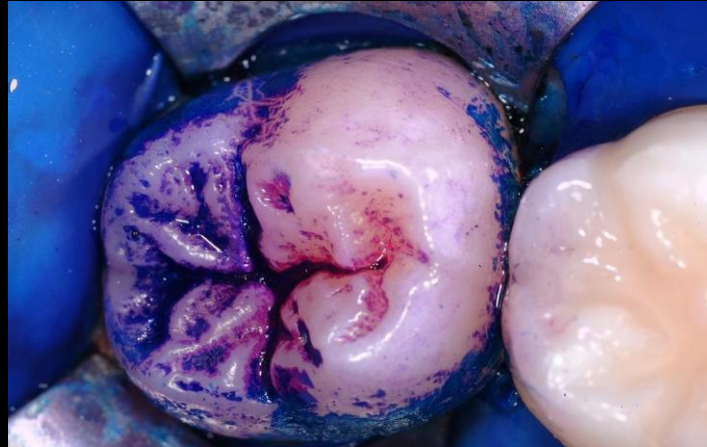Part 1 | Biofilm Removal

If you were going to paint a wall that looked like this....



...you'd prepare the surface to receive the paint and have it stay long-term.

We need to do the same with teeth...



Clean teeth surfaces allow for

- Better adhesion
- Difference between “Flash” and an infinity edge at the Tooth Restoration Interface

Does 37% phosphoric acid
(gel etchant)
remove biofilm?

Composite
Heating: Trend
or the future of
placing the
material?

Composite Heater pre-set
to 155° F



Conclusions

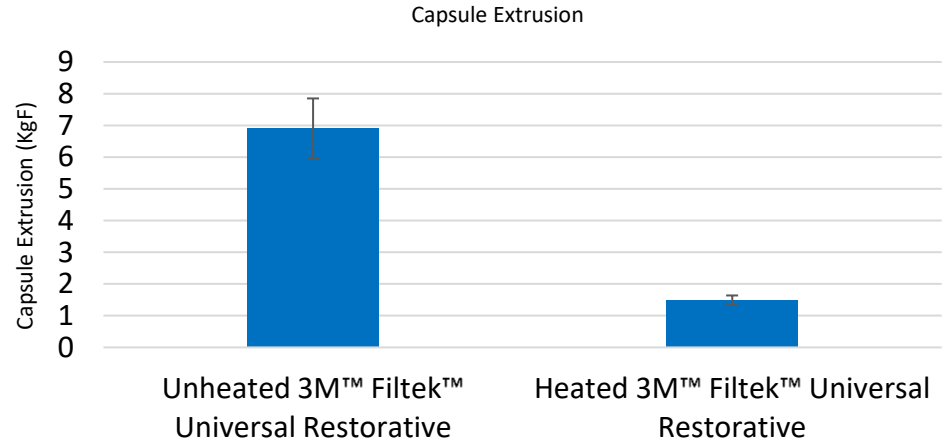
- Preheating a syringe of Filtek™ Bulk Fill Posterior to 60 °C for twenty 1 hour increments does
 - NOT harm mechanical properties such as
 - Diametral tensile strength
 - Flexural strength
 - NOT harm cure properties such as
 - Depth of cure
 - Cusp deflection (polymerization shrinkage stress)
 - NOT harm esthetic properties such as
 - Color and opacity
 - Polish retention

From: Does Preheating a Dental Composite Degrade its Post-Cure Properties?
T.D. Dunbar et al., *J Dent Res* 95 (Spec Iss A):952, 2016 (www.iadr.org).

Composite warming

Why warm?

- Handling preference
- Lowers capsule extrusion force by 75-80%



3M internal data

14% of dentists survey stated they use some type of device to warm their composite prior to placement.

3M Market Research, January, 2018 N=304 Dentists (US, Russia, UK, Brazil, Germany)

Let's go back to 2007...

“Dr. Clark, aren't we supposed to layer everything?”



Studies do not support layering to mitigate polymerization stress

- ◆ Does Incremental Filling Technique Reduce Polymerization Shrinkage Stresses?
Versluis A, et.al., J Dent Res March 1996; 75(3): 871-878
- ◆ An In Vitro Study of the Effect of Restorative Technique on Marginal Leakage in Posterior Composites
Neiva IF, et.al.; Oper Dent 1998, 23:282-289
- ◆ Microleakage and adaptation of Class II packable resin-based composites using incremental or bulk filling techniques
Gallo JR, et.al., Am J Dent 2000; 13: 205-208
- ◆ The Effects of Adhesive Thickness on Polymerization Contraction Stress of Composite
Choi KK, et.al., J Dent Res 2000; 79(3): 812-817
- ◆ Microleakage of Posterior Packable Resin Composites with and without flowable liners
Leevailoj C, et.al., Oper Dent 2001; 26: 302-307
- ◆ Marginal adaptation of Class II resin composite restorations using incremental and bulk placement techniques: and ESEM study
Idriss S, et.al., J Oral Rehab 2003; 30: 1000-1007
- ◆ A reappraisal of the incremental packing technique for light cured composite resins
Rees JS, et.al., J Oral Rehab 2004; 31: 81-94
- ◆ Cuspal deflection and depth of cure in resin-based composite restorations filled by using bulk, incremental and transtooth-illumination techniques
Carlos E. Campodonic, DDS 2011, October 2011 JADA



Hand-Packed and Layered

Monolithic and Injection-Molded

Dr. #1



Dr. #2



Courtesy Dr. Richard Price


A microscopic image of a tooth with a filling. A dark spot is visible at the interface between the filling and the tooth, indicating microleakage. The text is overlaid on a dark blue rectangular background.

Is layering a good thing or a bad thing?


Does layering relieve stress and reduce microleakage? **NO**

October 2011 JADA

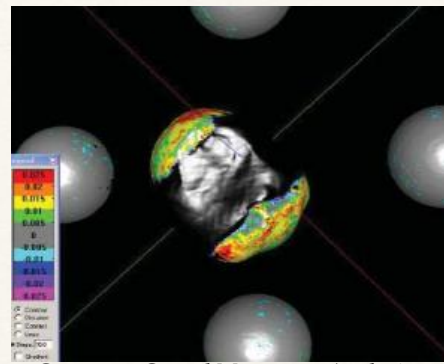
Cuspal deflection and depth of cure in resin-based composite restorations filled by using bulk, incremental and transtooth-illumination techniques



Completed Restoration



COS Scan



Computer Cuspal Movement Analysis

"Conclusions: Cuspal deflection was not affected by filling techniques."

"Filtek Supreme Plus had lower curing values below a depth of 2 mm."

"Clinical Implications. When using resin-based composite restorative materials, clinicians should be more concerned about the effect of filling techniques on curing depth than about how these techniques affect shrinkage stresses."


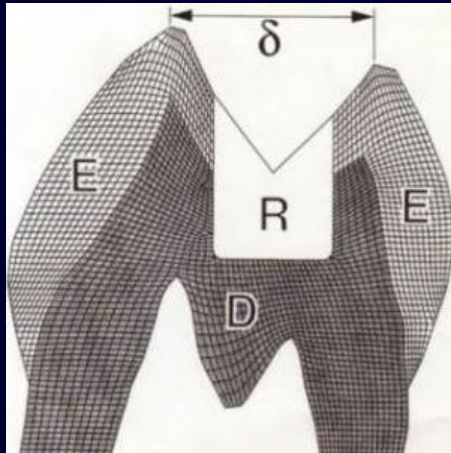
Does an incremental filling technique reduce polymerization shrinkage stresses?

Versluis A, Douglas WH, Cross M, Sakaguchi RL.

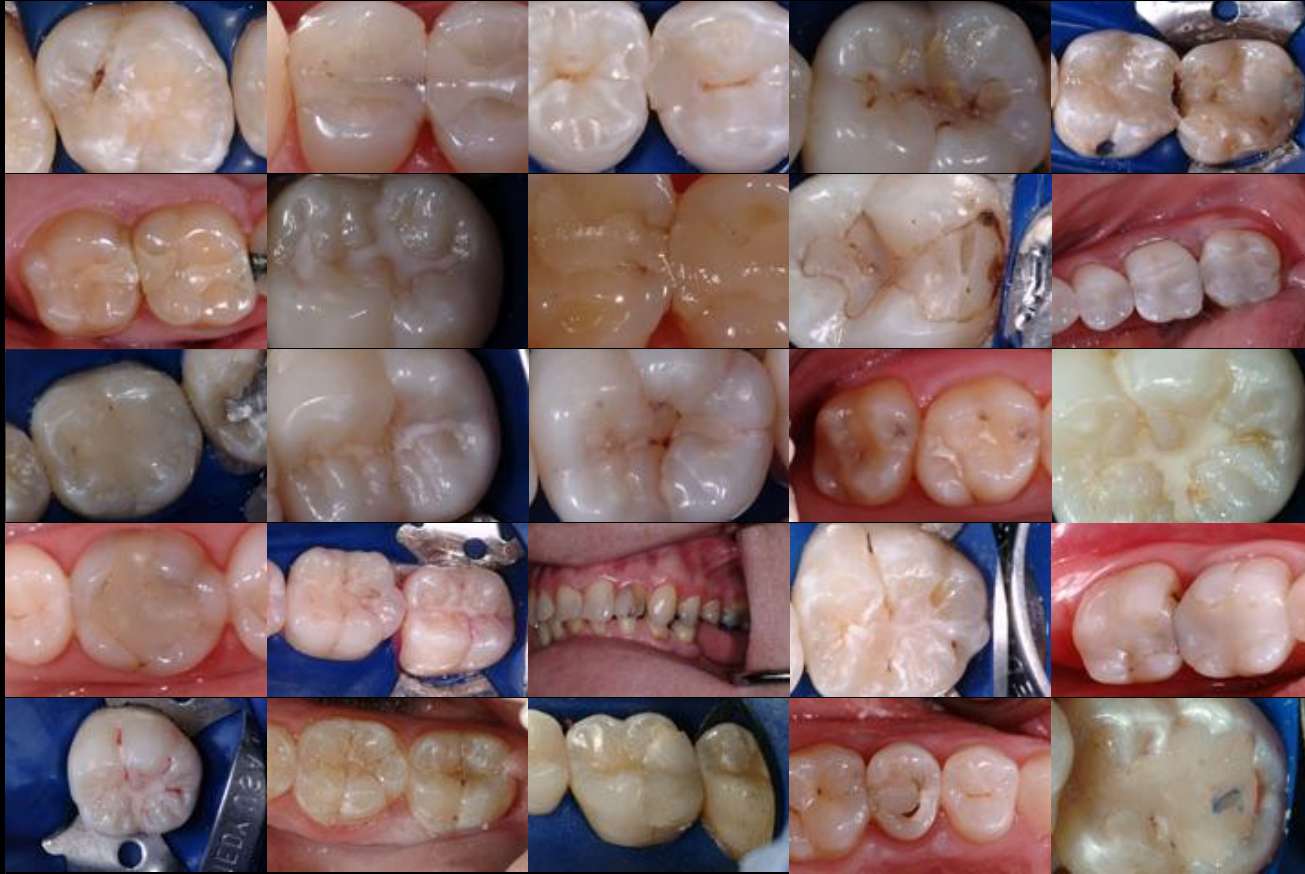Minnesota Dental Research Center for Biomaterials and Biomechanics, University of Minnesota, Minneapolis 55455, USA.

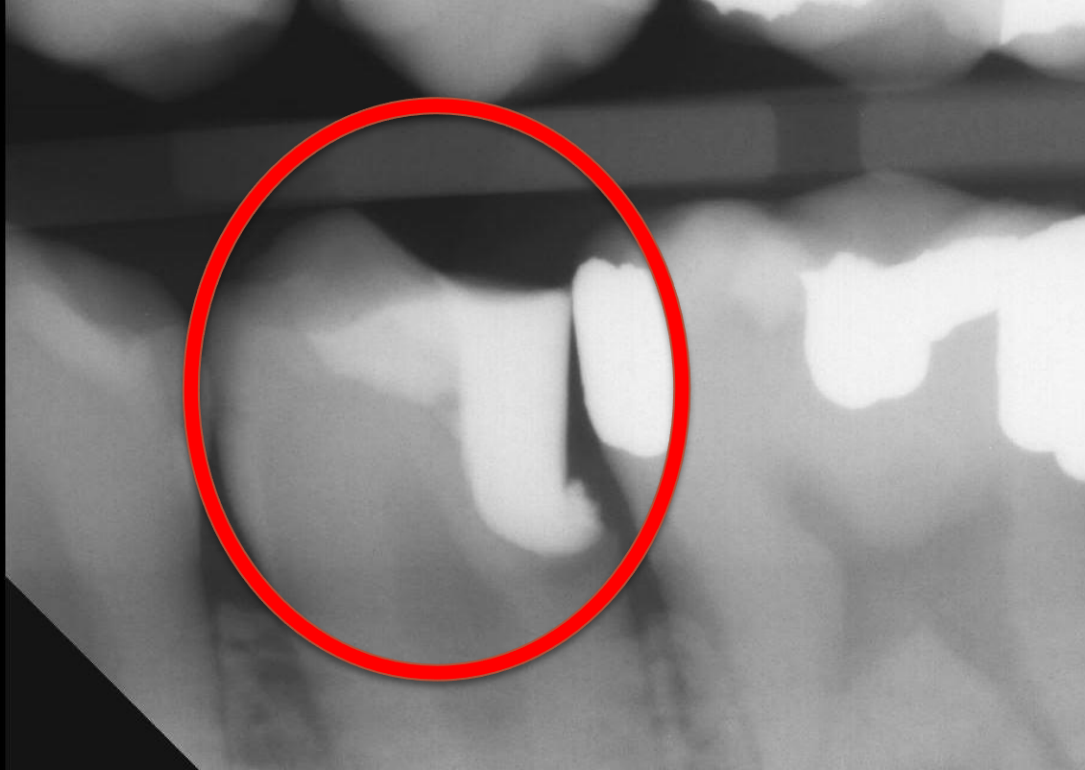Abstract

It is widely accepted that volumetric contraction and solidification during the polymerization process of restorative composites in combination with bonding to the hard tissue result in stress transfer and inward deformation of the cavity walls of the restored tooth. Deformation of the walls decreases the size of the cavity during the filling process. This fact has a profound influence on the assumption—raised and discussed in this paper—that an incremental filling technique reduces the stress effect of composite shrinkage on the tooth. Developing stress fields for different incremental filling techniques are simulated in a numerical analysis. The analysis shows that, in a restoration with a well-established bond to the tooth—as is generally desired—incremental filling techniques increase the deformation of the restored tooth. The increase is caused by the incremental deformation of the preparation, which effectively decreases the total amount of composite needed to fill the cavity. This leads to a higher-stressed tooth-composite structure. The study also shows that the assessment of intercuspal distance measurements as well as simplifications based on generalization of the shrinkage stress state cannot be sufficient to characterize the effect of polymerization shrinkage in a tooth-restoration complex. Incremental filling methods may need to be retained for reasons such as densification, adaptation, thoroughness of cure, and bond formation. However, it is very difficult to prove that incrementalization needs to be retained because of the abatement of shrinkage effects.



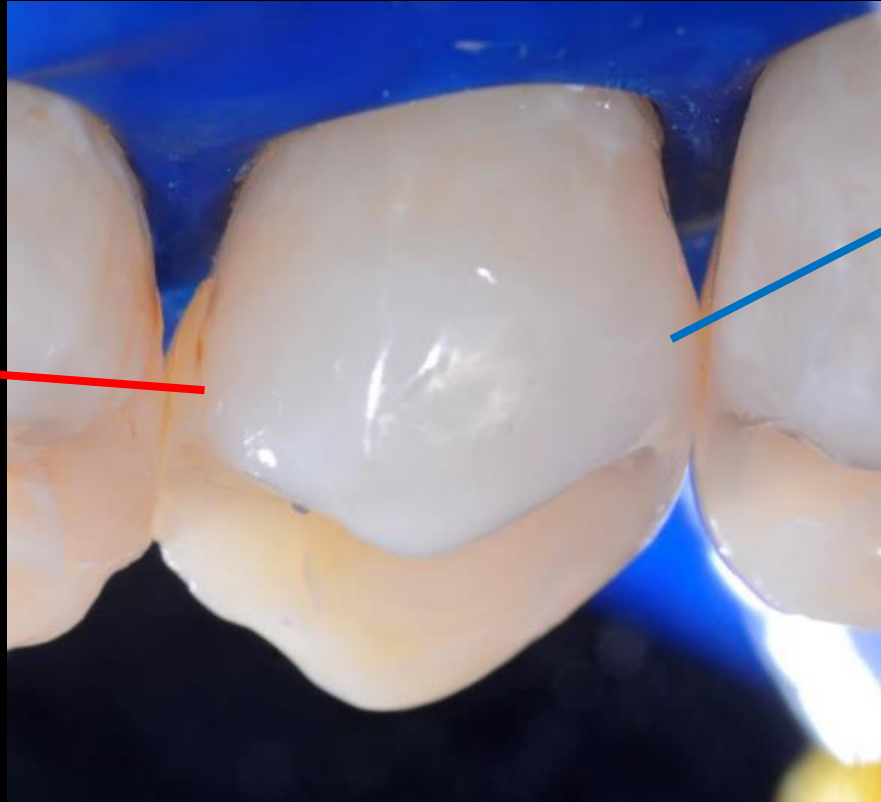Epidemic of Failing Composites





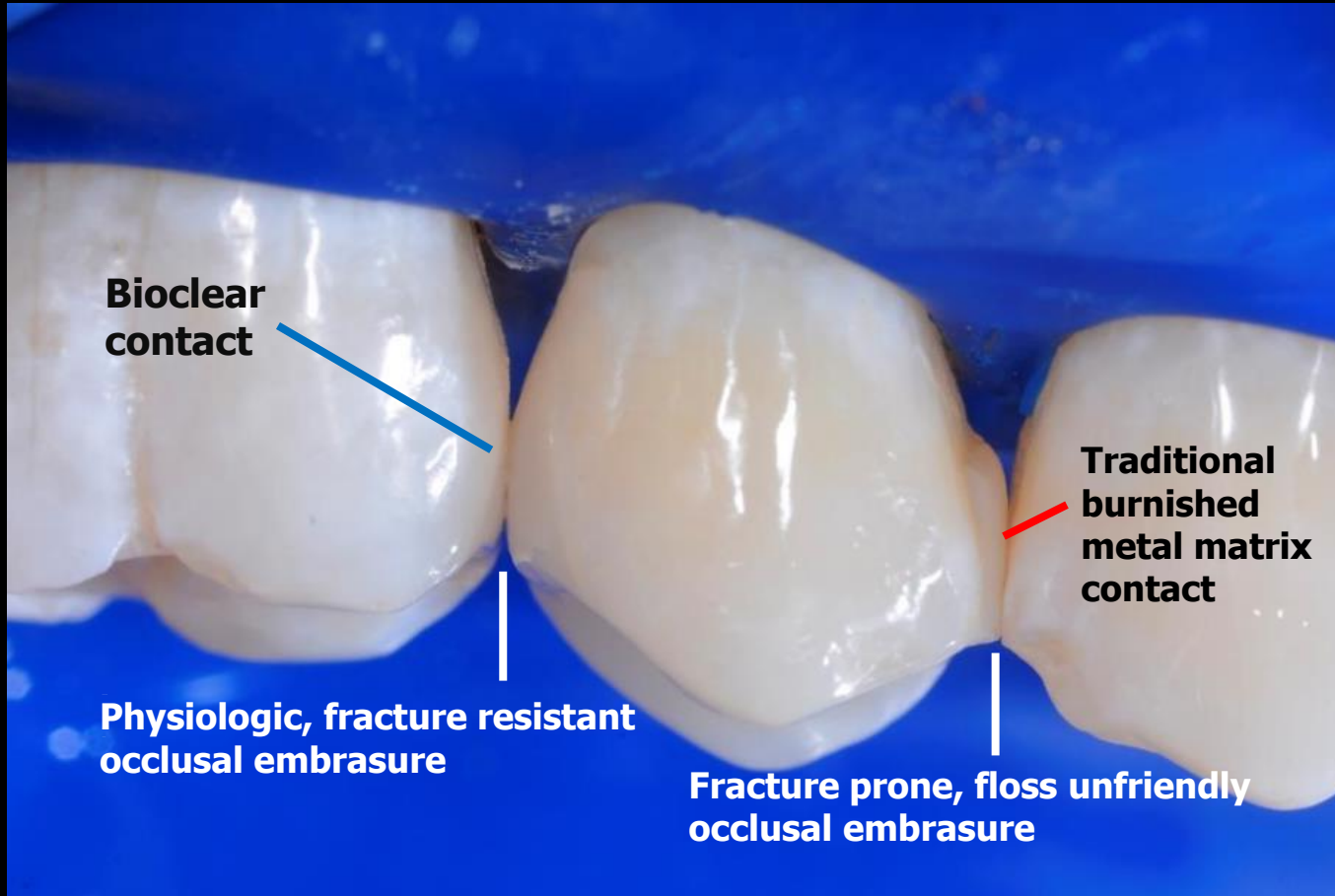
Let's compare old vs. new

Traditional box prep restoration with staining margins and burnished mediocre shape.



Bioclear restoration with Evolve Matrix, Twin Ring Universal, and Diamond Wedge combined with an infinity edge.

Buccal View Post-Op



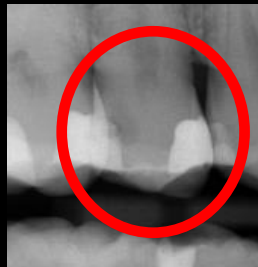
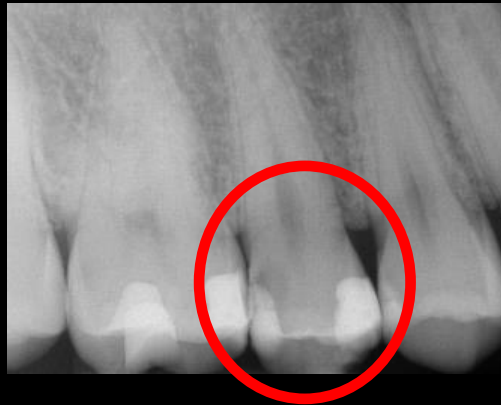**Bioclear
contact**

**Traditional
burnished
metal matrix
contact**

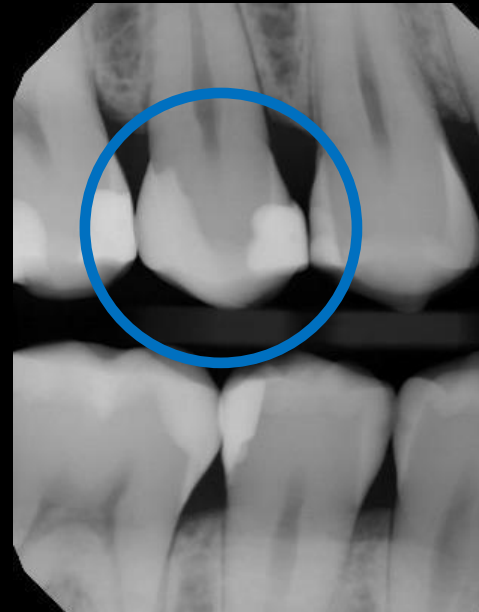
**Physiologic, fracture resistant
occlusal embrasure**

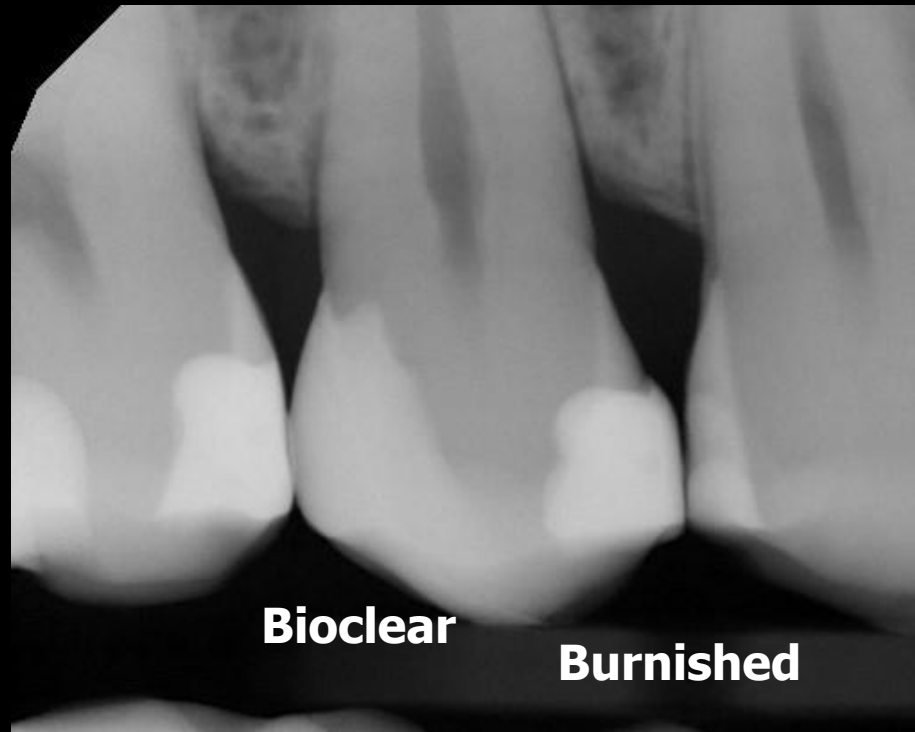
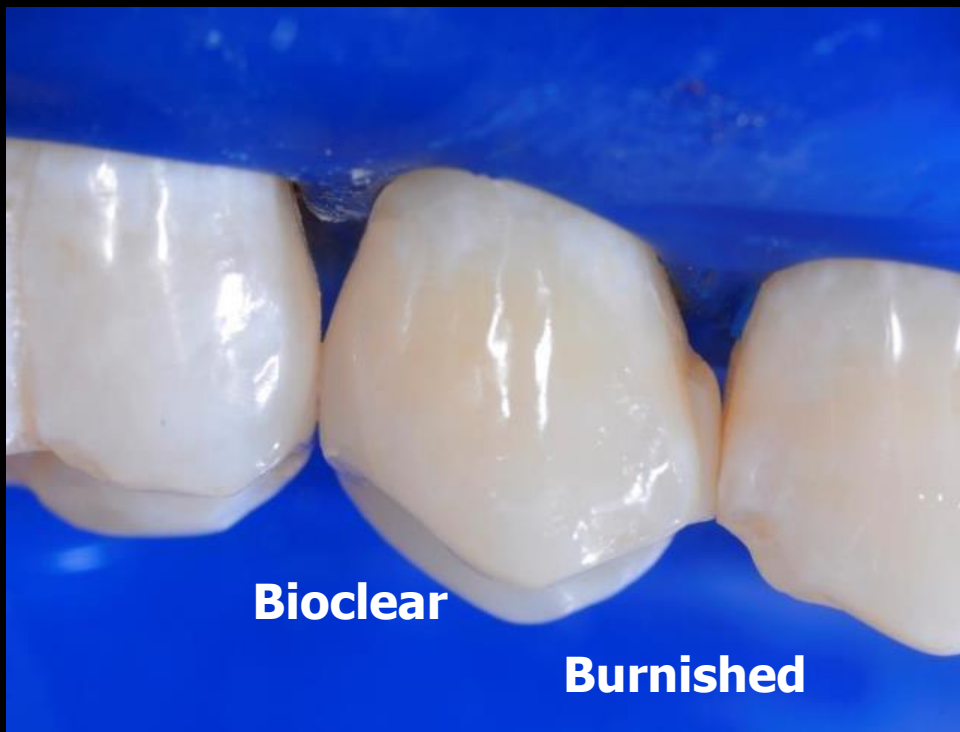
**Fracture prone, floss unfriendly
occlusal embrasure**

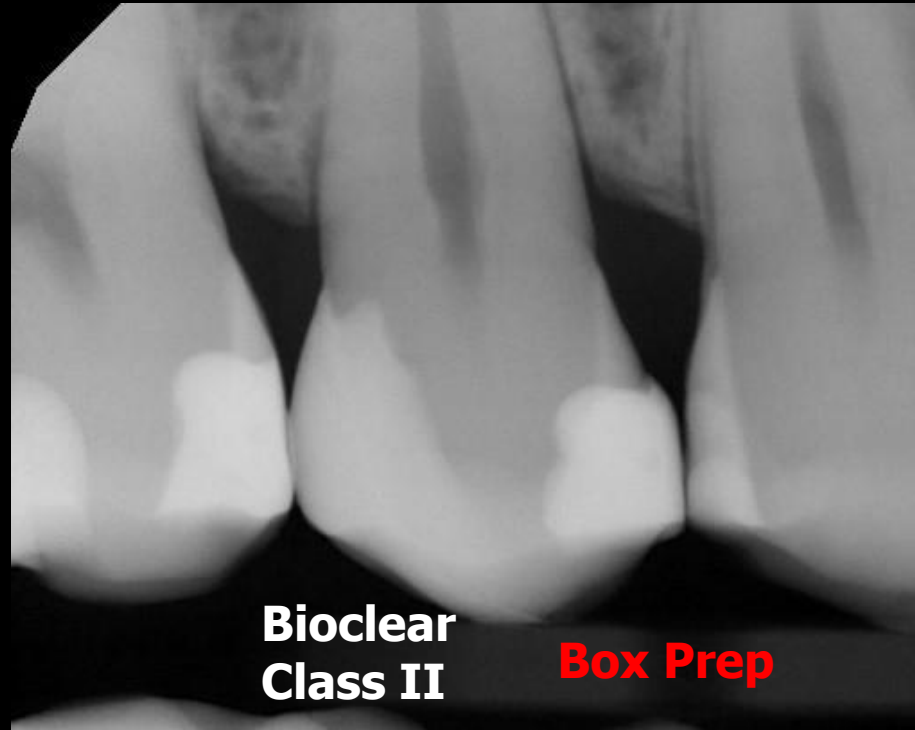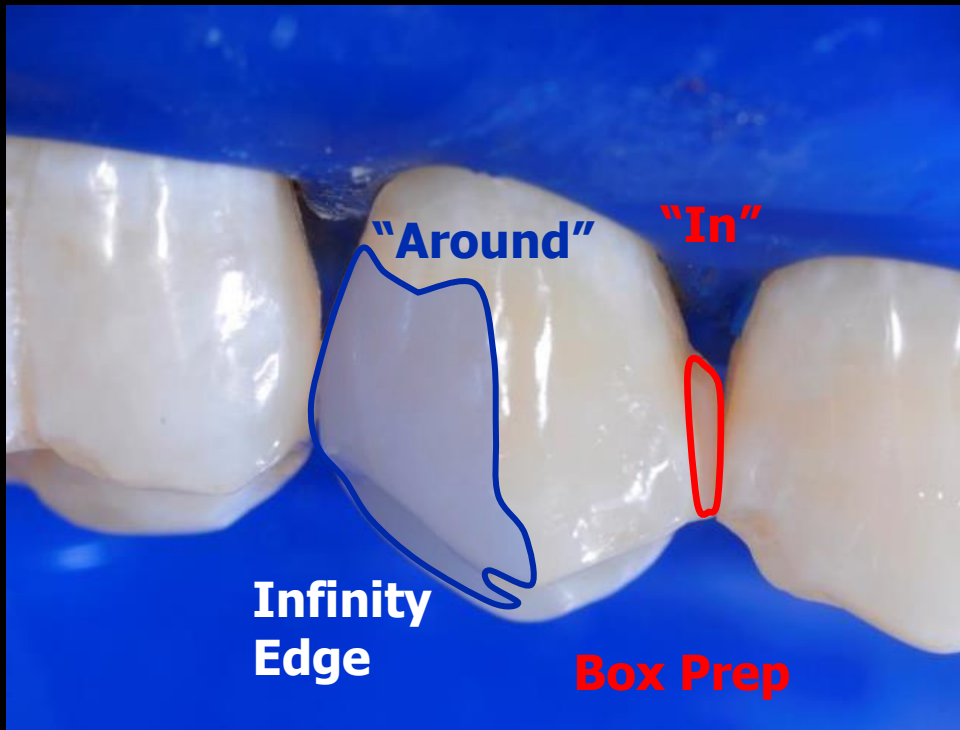
Pre-Operative Radiographs



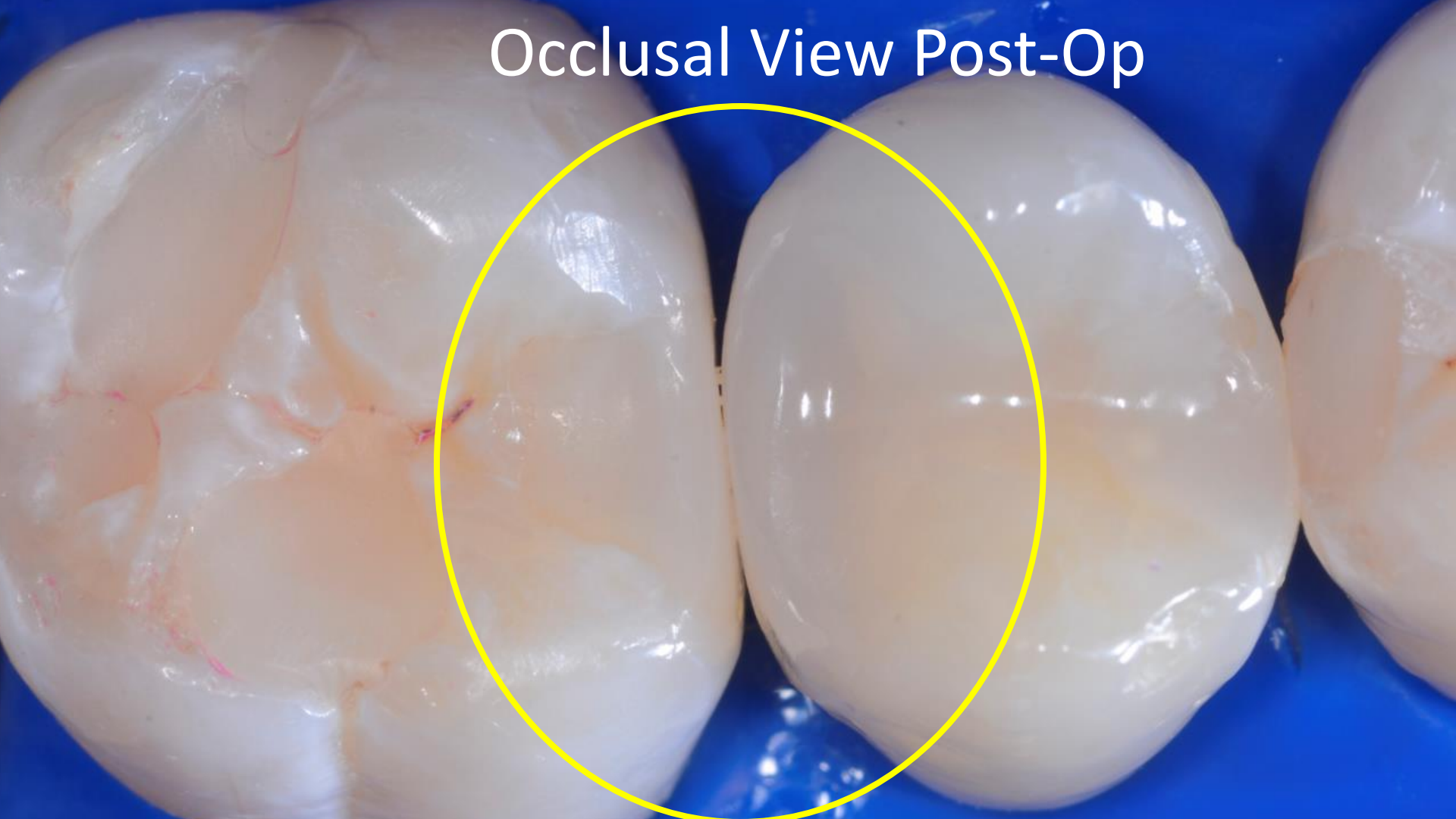
1 Year Post-Operative

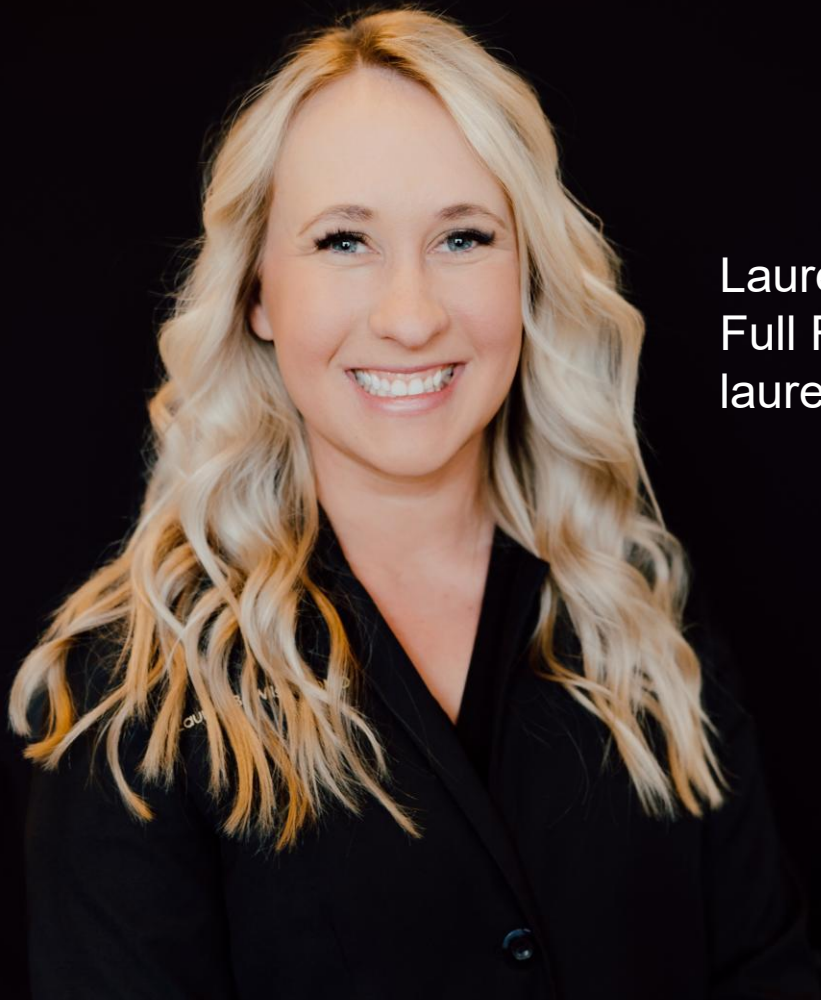





Occlusal View Post-Op





Lauren Wilson DMD
Full Faculty Bioclear Learning Center
laurenwilsondmd@bioclearmatrix.com

Recommended Bioclear Matrices by Indication

For more information contact us
Bioclear Matrix Systems
1-855-712-5327



360 Veneer

Class V and to significantly increase overjet or correct anterior open bite.



TSS Kit

Anterior Teeth:
Class III, Class IV, Class V
Fractured Incisors
Severe Wear
Composite Veneer
Full Composite Crown



BT (Black Triangle) Kit

Anterior Teeth:
Black Triangles
Peg Laterals
Diastema Closure
Instant Ortho
Class V

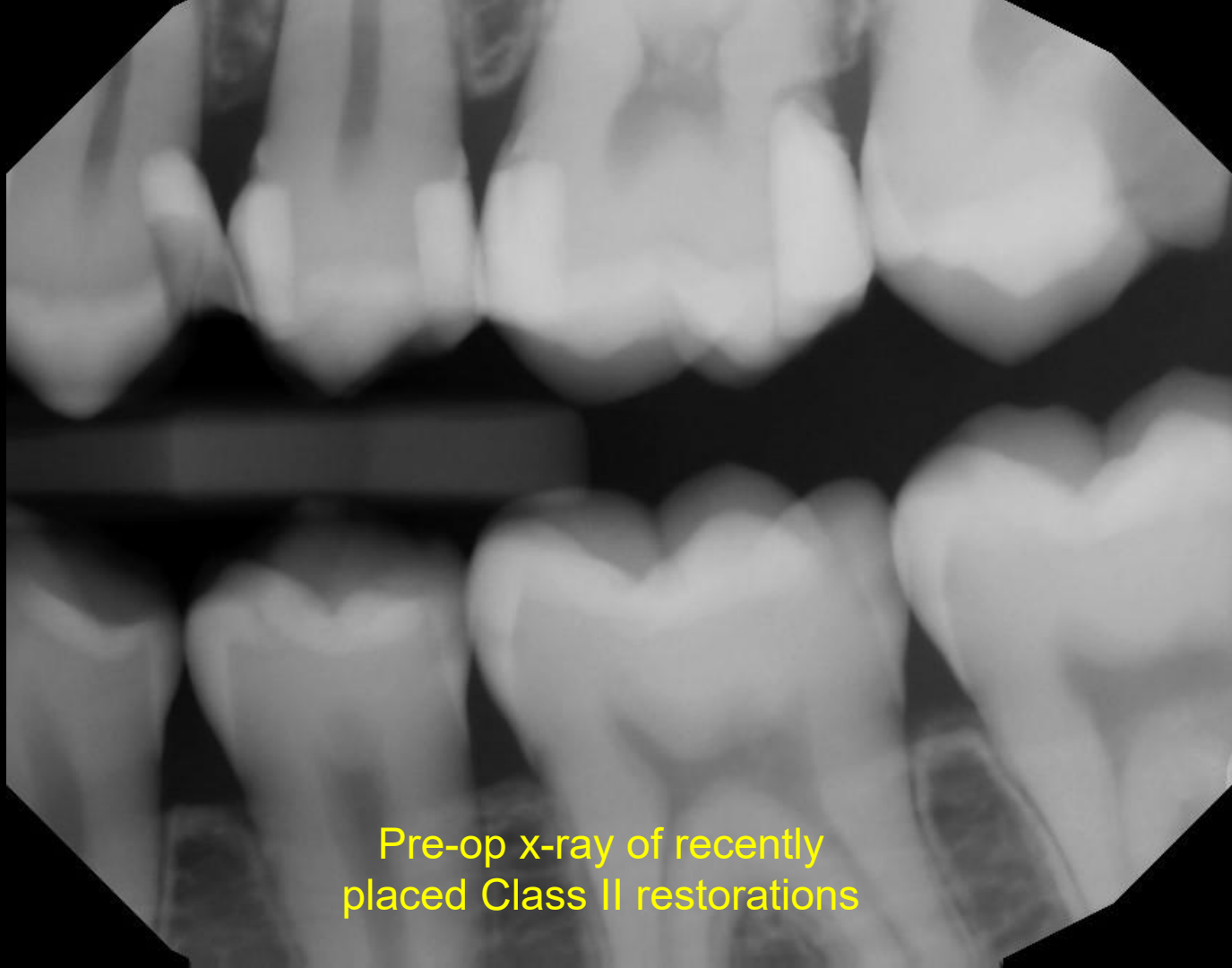

Evolve Matrix Kit

Posterior Teeth:
Class I, Class II, Class V

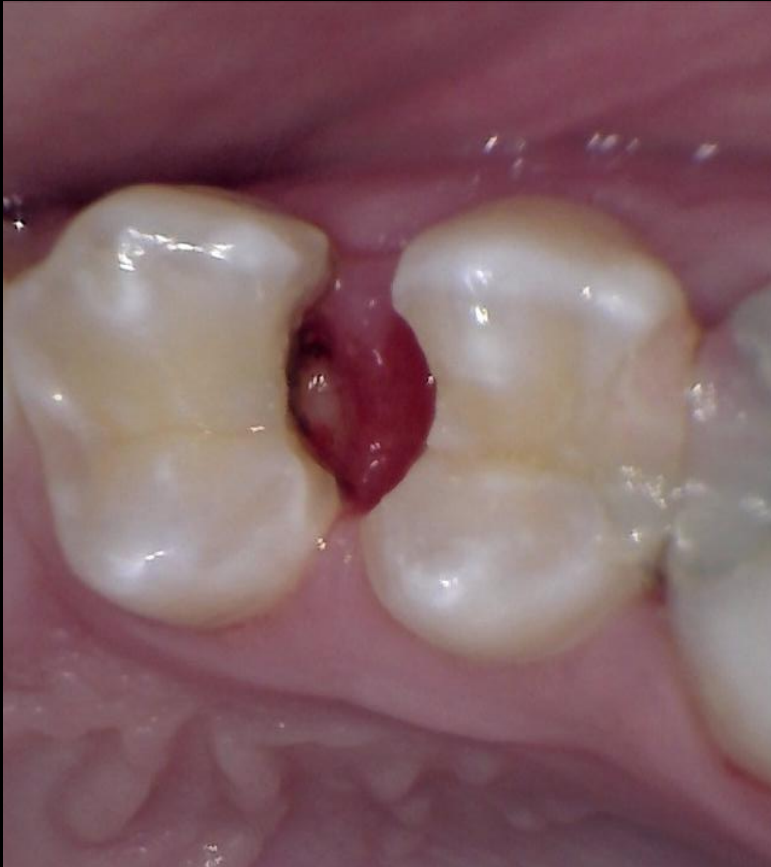15 year old new patient

“My daughter had several fillings done about 6 months ago, and she is having sensitivity. We wanted a second opinion.”



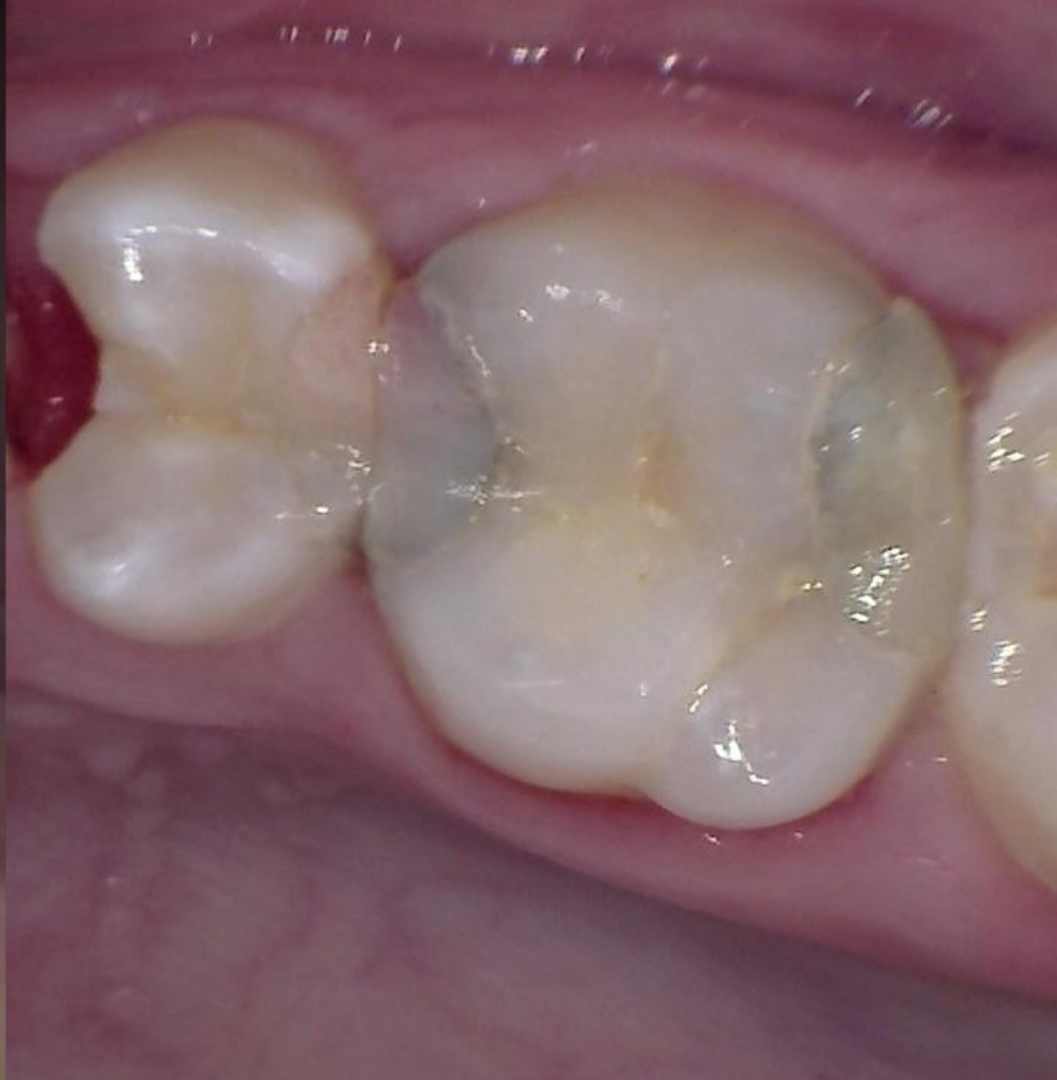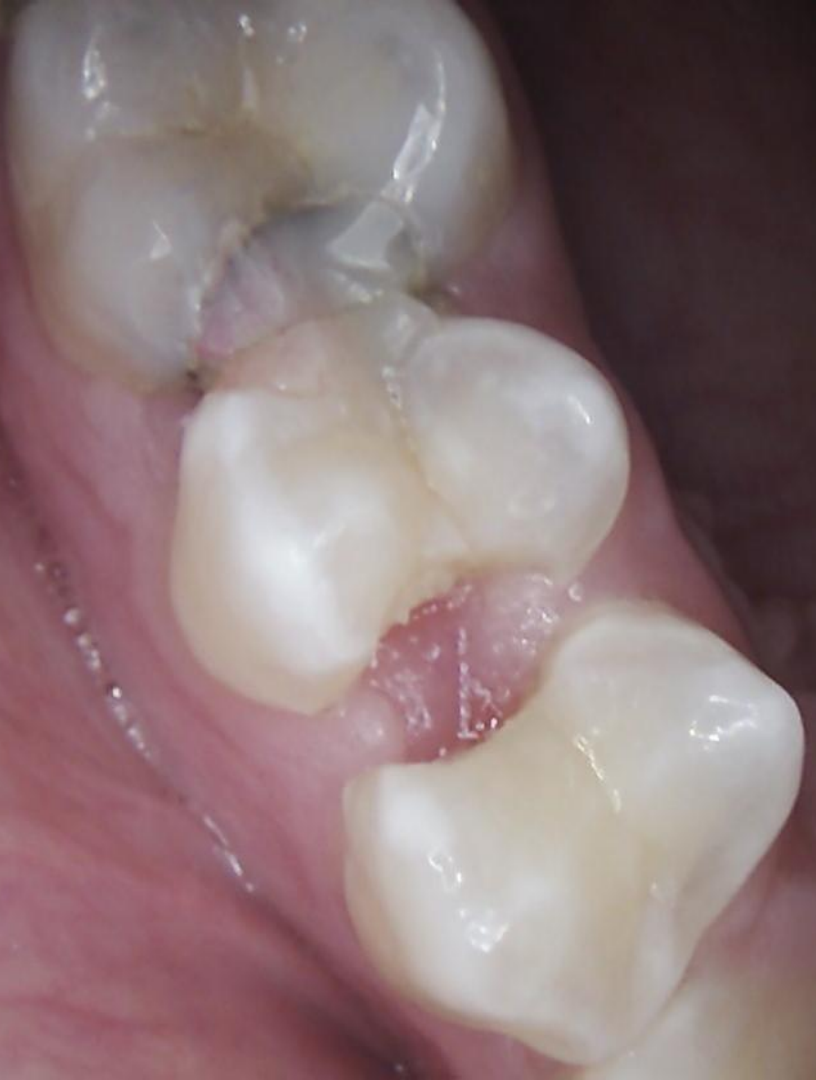Pre-op x-ray of recently placed Class II restorations

Initial Visit: Existing Restorations debonded when flossed...
Restorations “under 6 mo old”



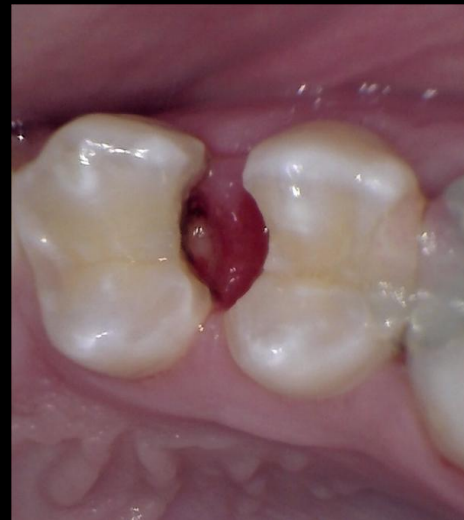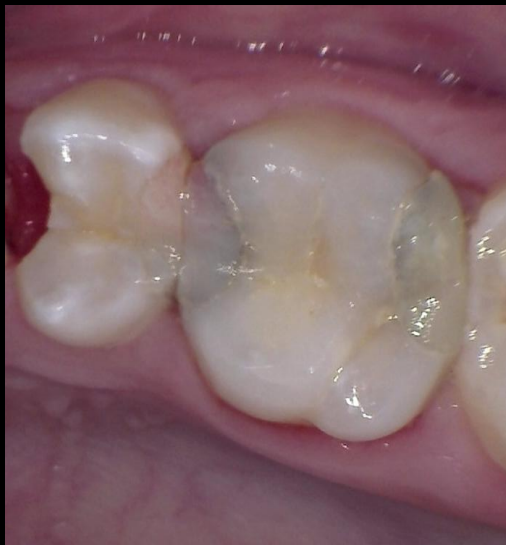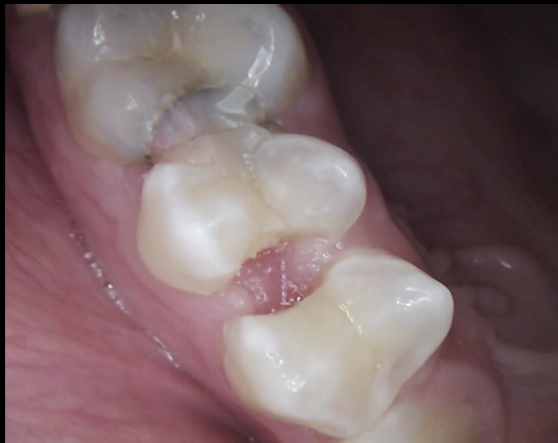Dr David Howard
faculty of Roseman
Dental School:

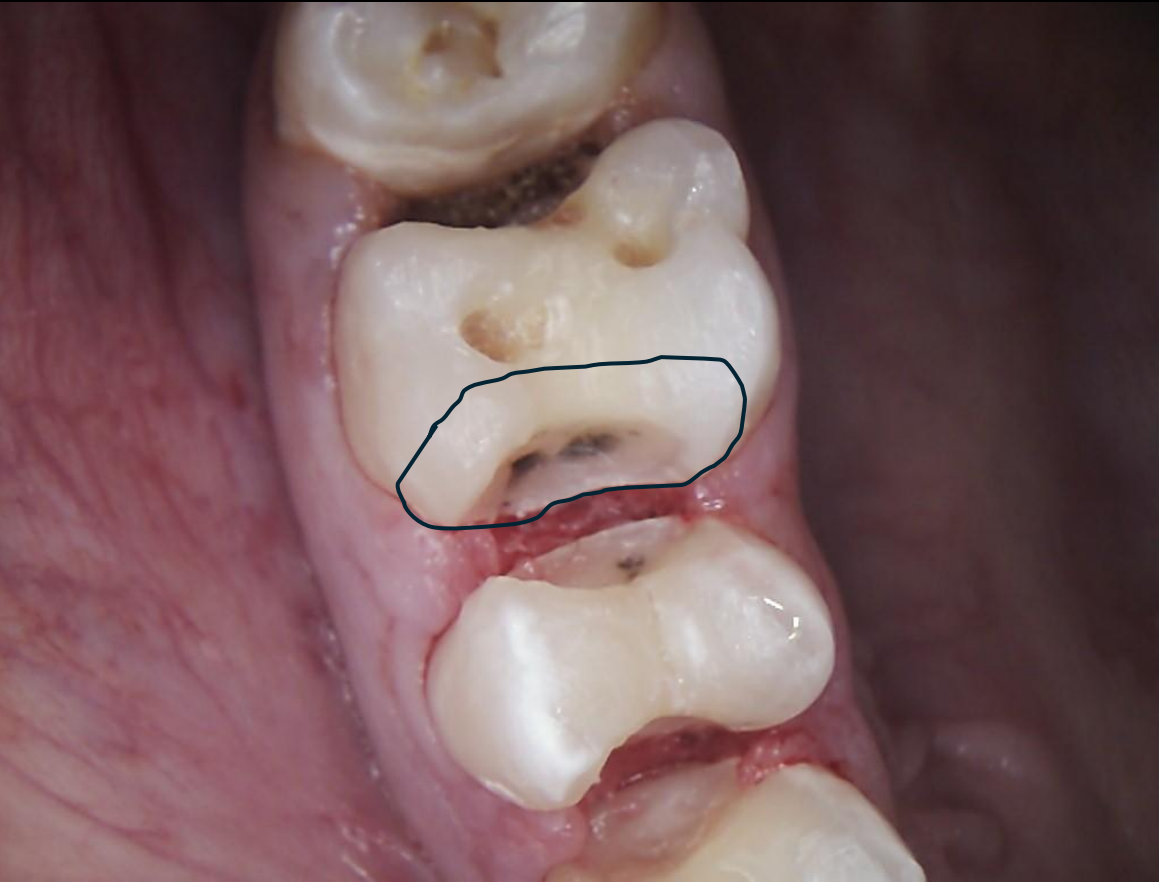
“Class II
composites are
dentistry’s dirty little
secret.”



Why?

- 1) The prep has neither retention nor compression. It is engineered to fail.
- 2) This case is a prime example that the entire system for this dentist is broken from start to finish.
- 3) Can we do better?



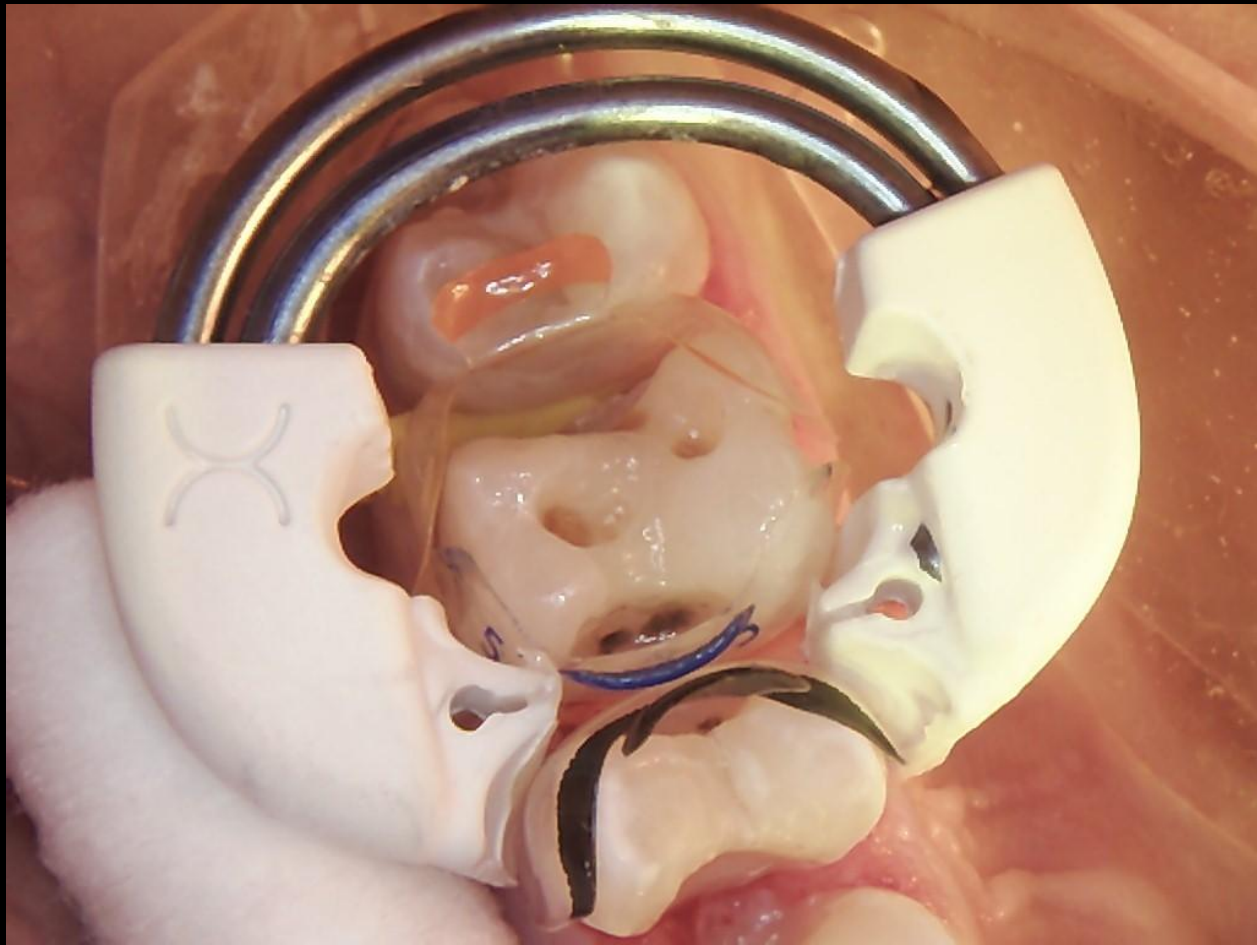


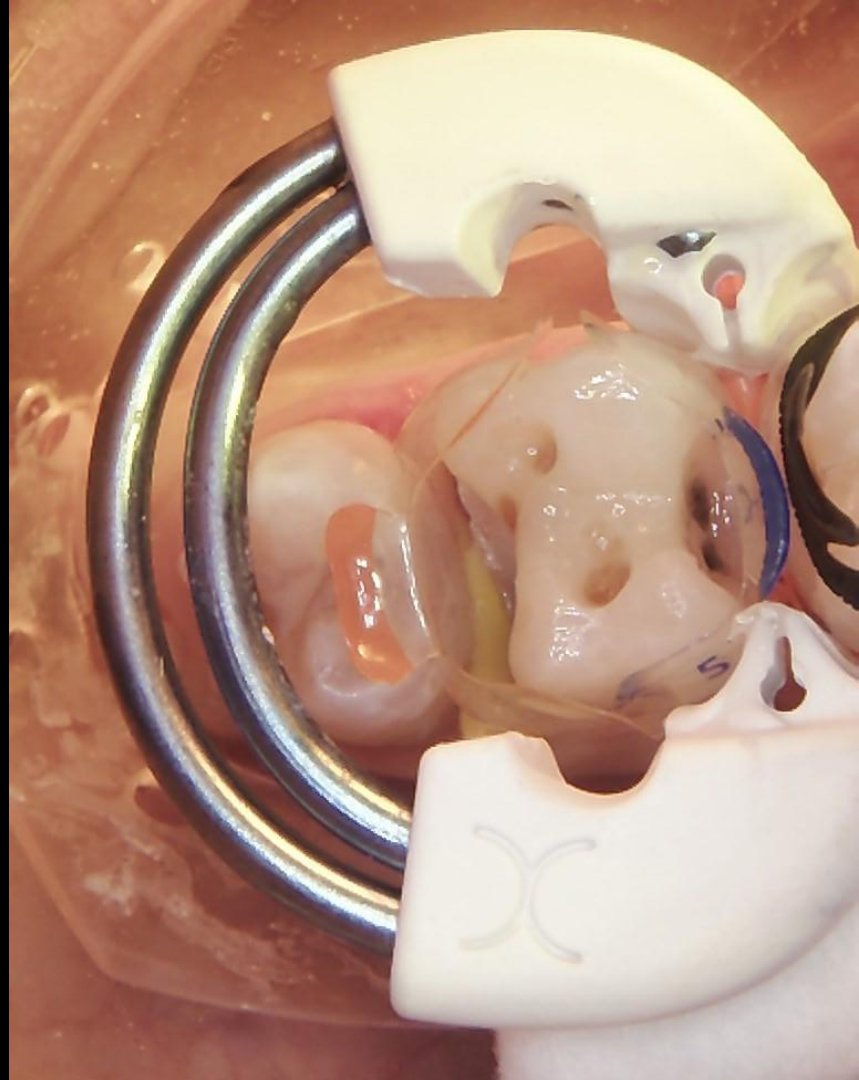“Rough Preps”

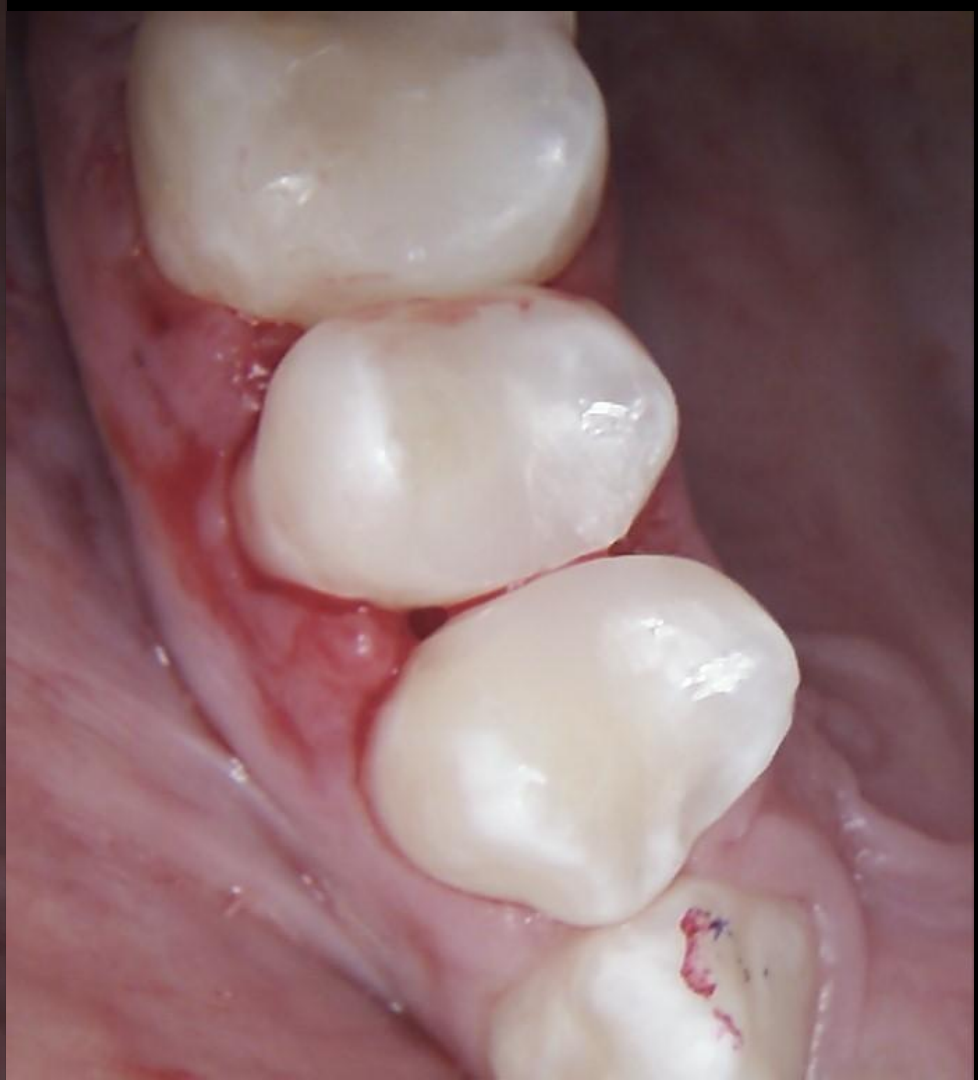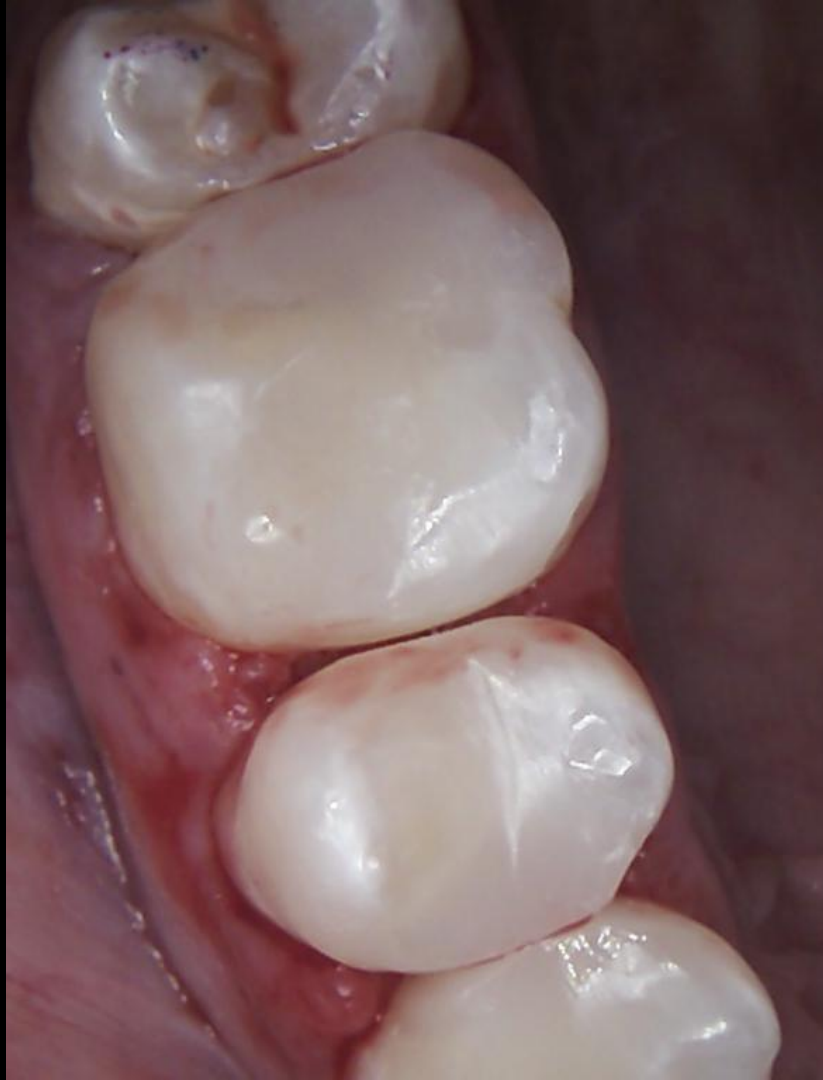DMA: Deep Margin Acquisition

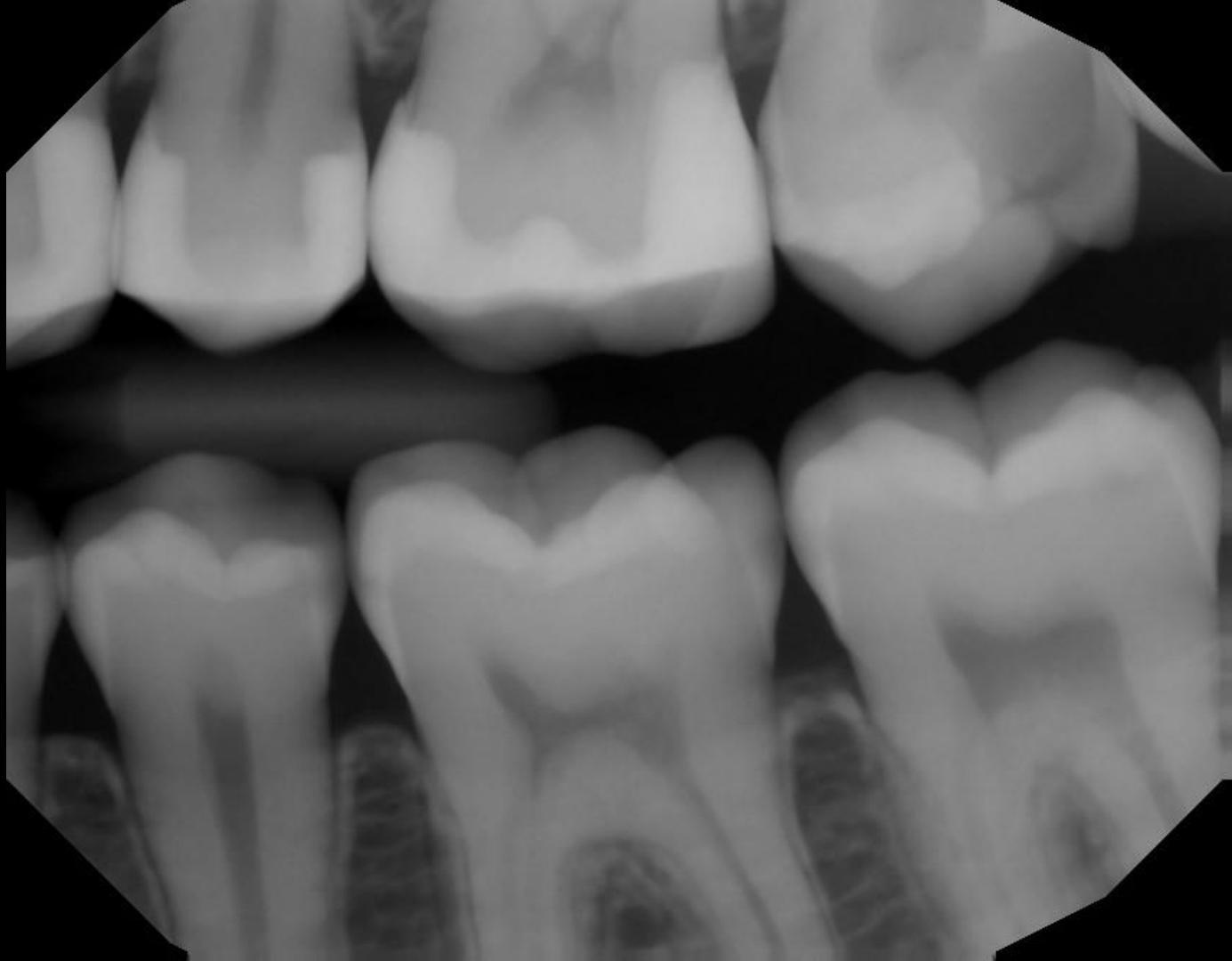
→ *packed cord prior to matrix placement*

→ Radius bevels with a minimum of 2mm of x axis (horizontal component) for a compression based restoration

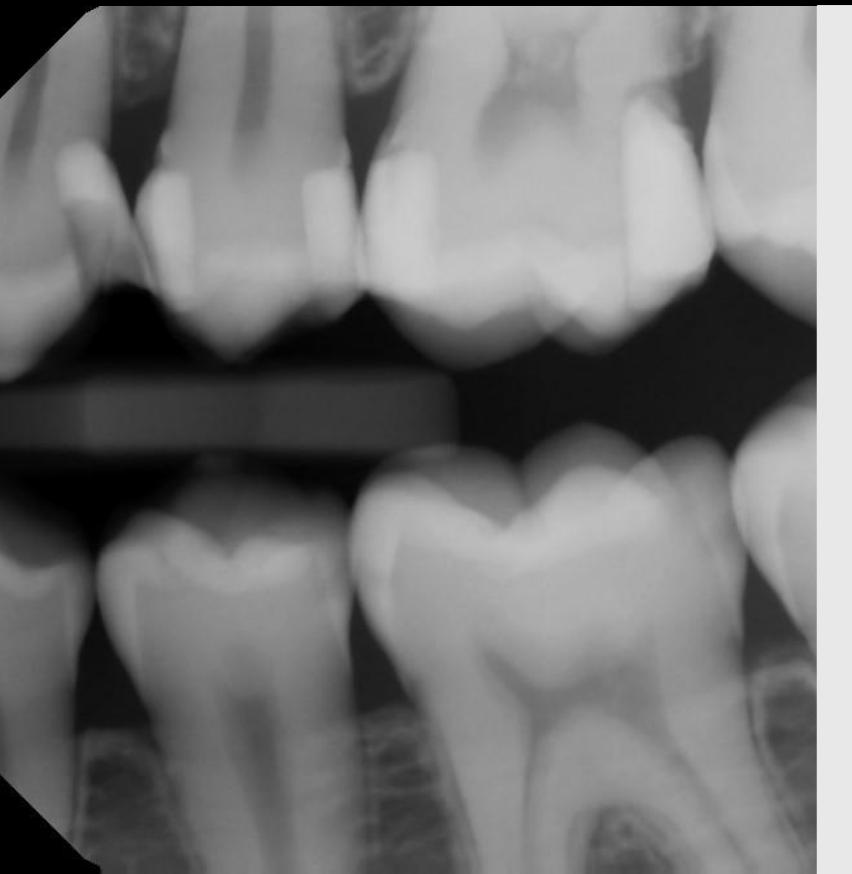




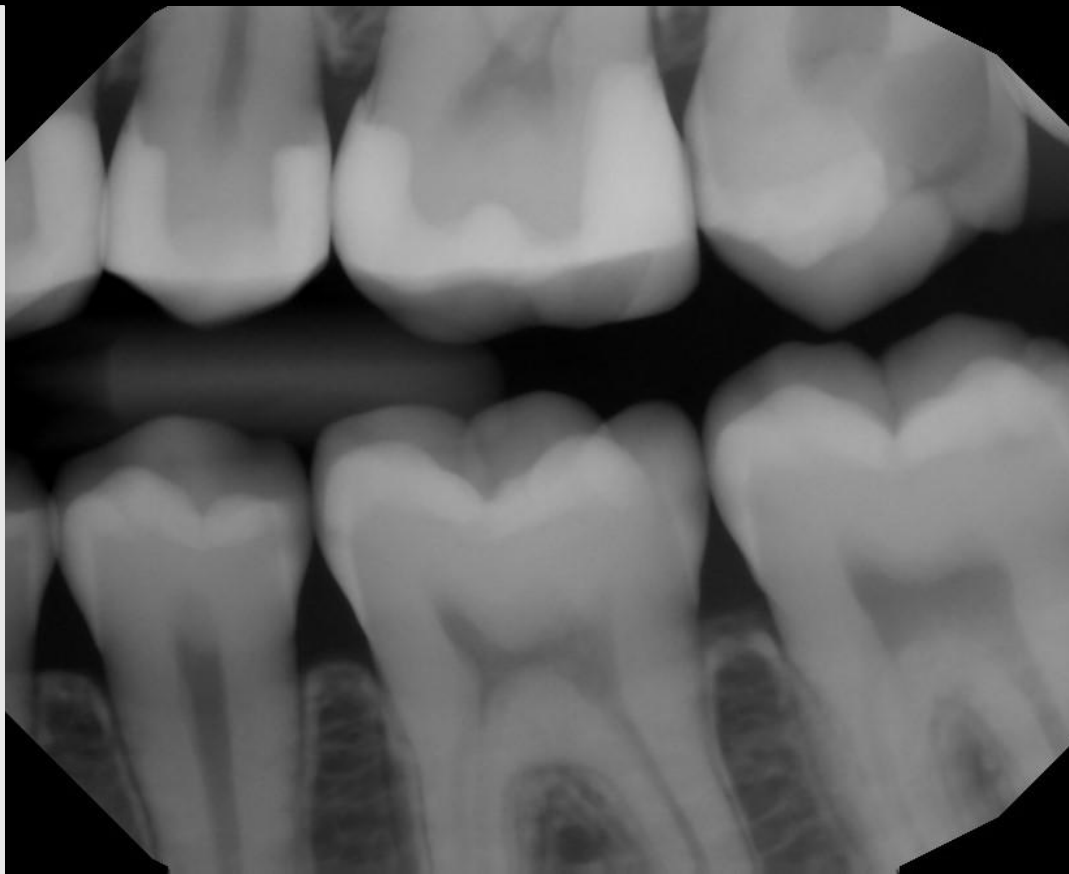


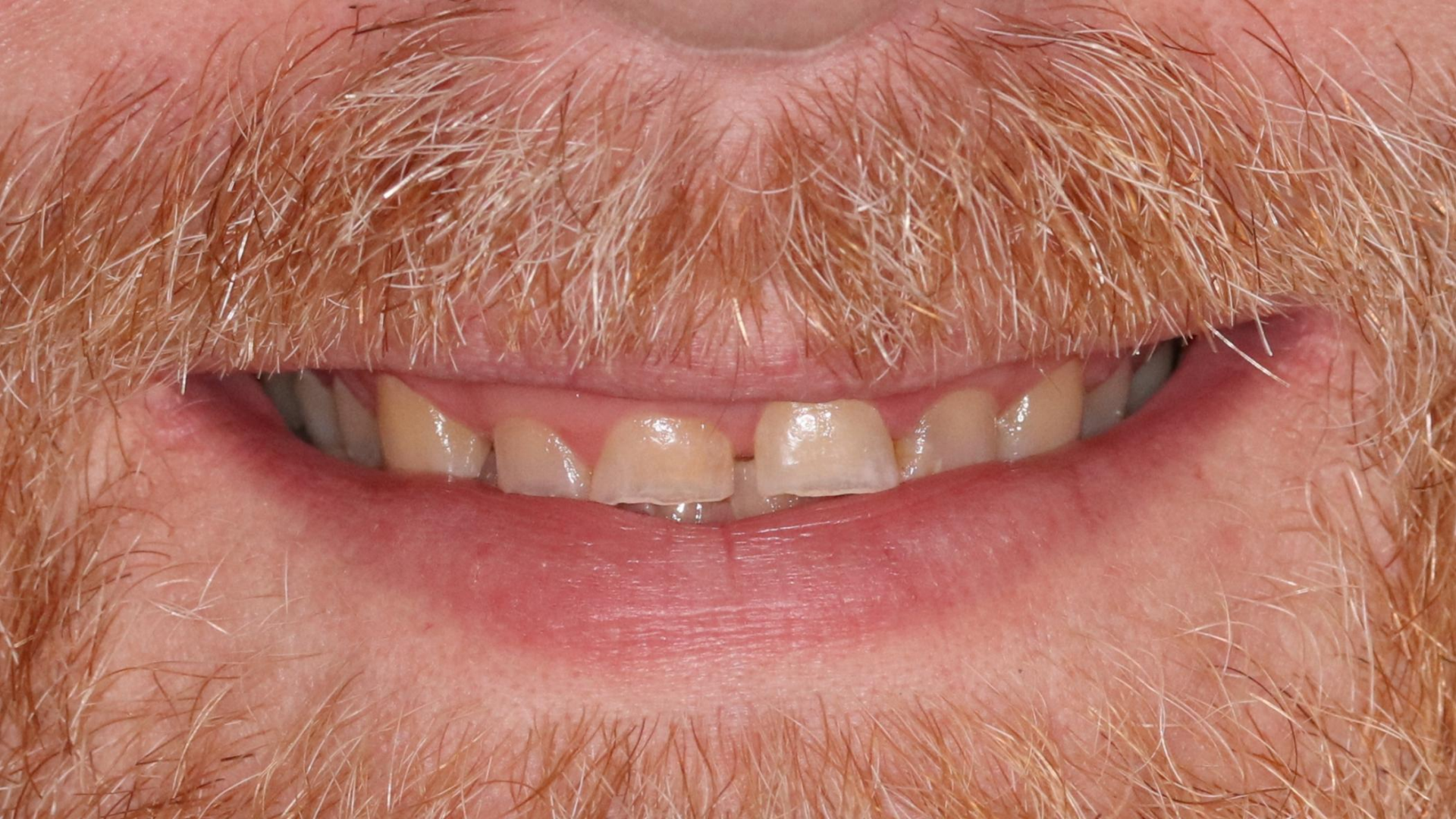

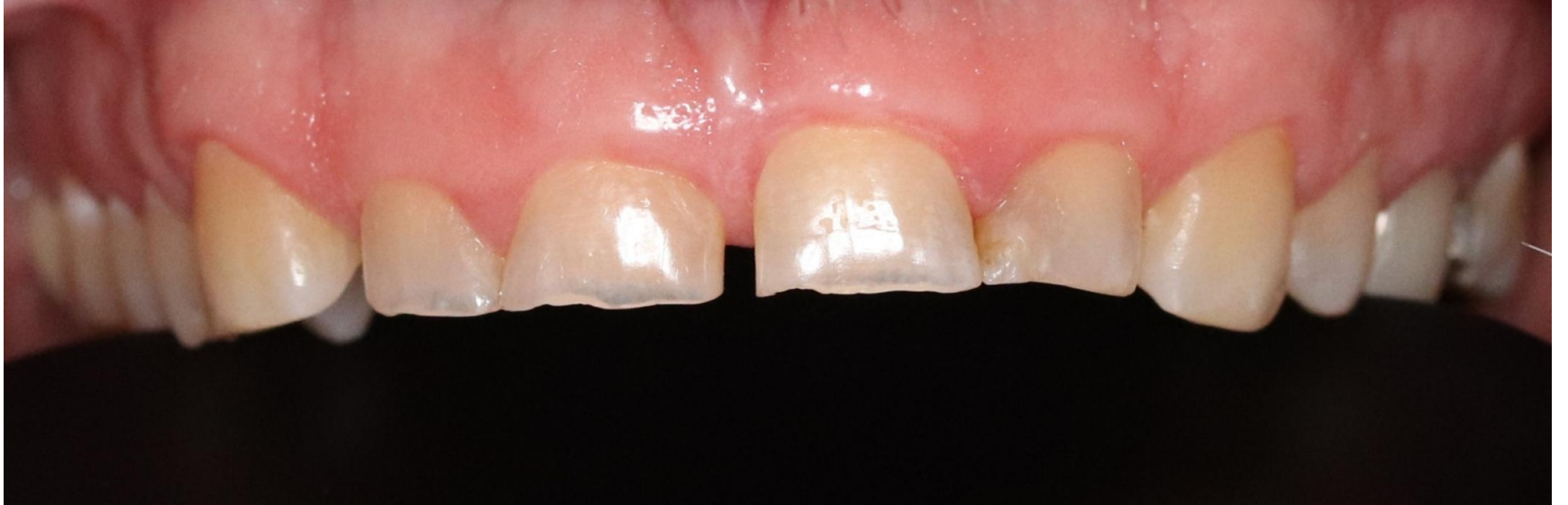Before

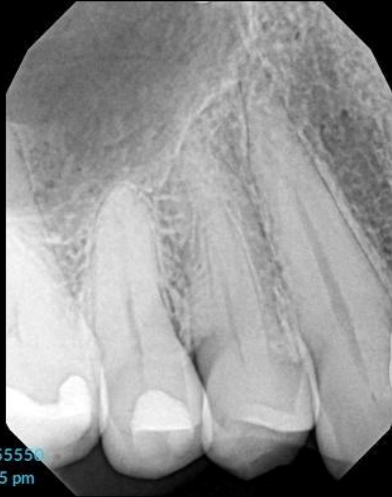

After

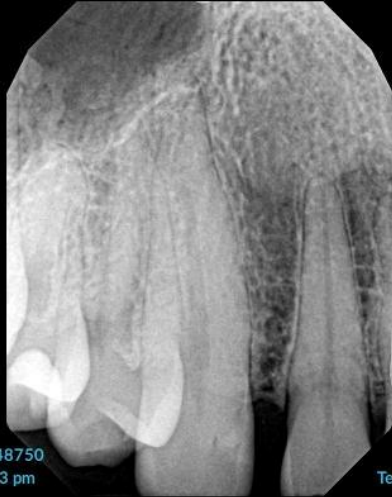






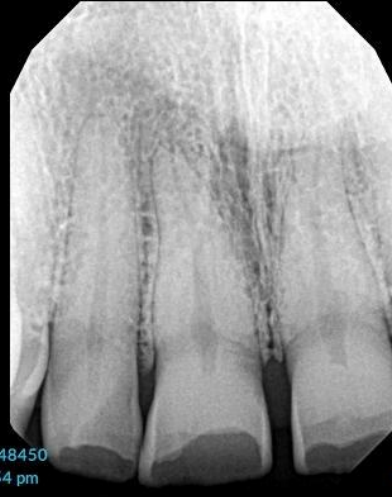
L/W: 27800/55550
8/6/2025 3:55 pm



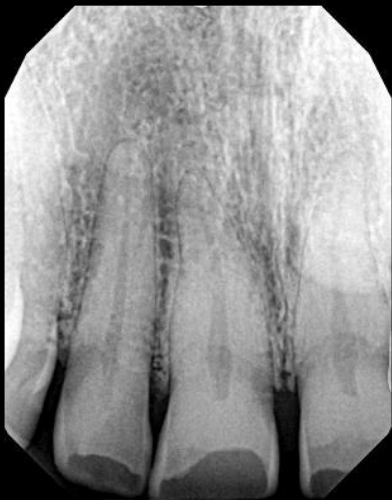L/W: 24400/48750
8/6/2025 3:53 pm

Teeth: 4-6,8 auto



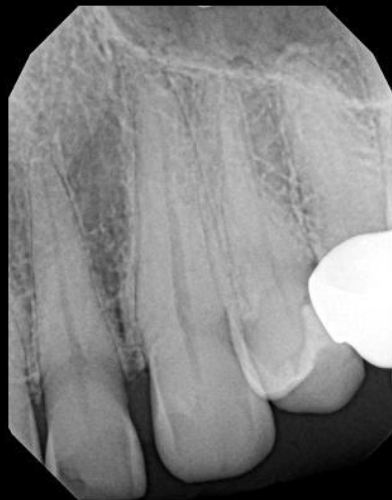L/W: 24250/48450
8/6/2025 3:54 pm

Teeth: 7-9 auto



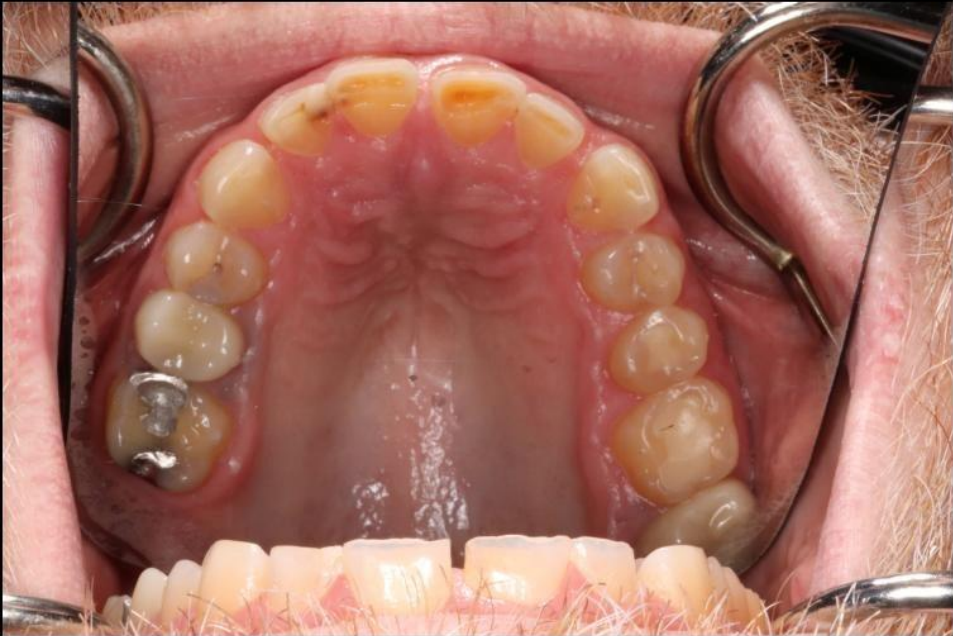L/W: 22900/45800
8/6/2025 3:54 pm

Teeth: 7-9 auto

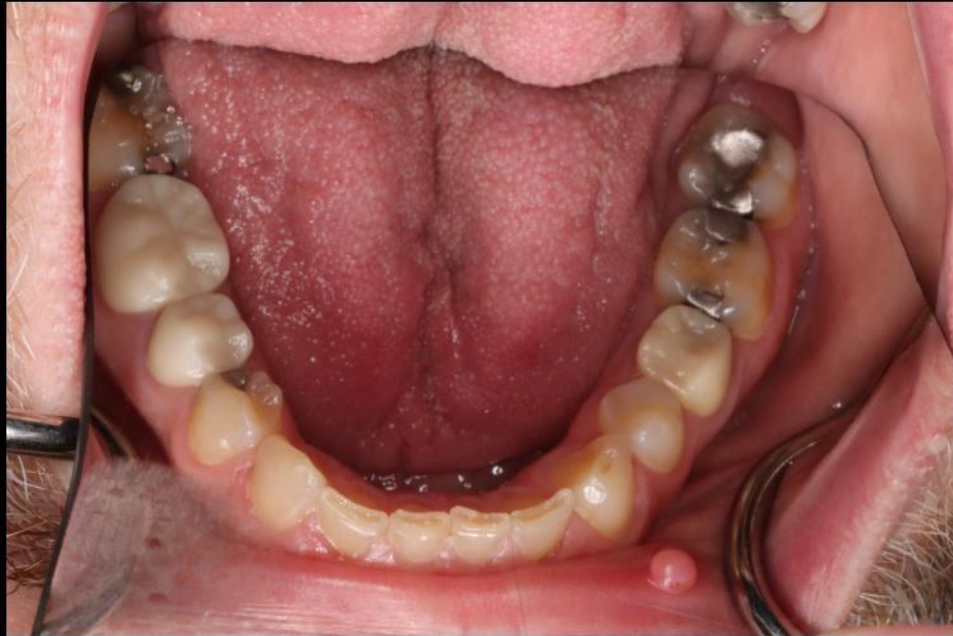

L/W: 30100/60150
8/6/2025 3:55 pm

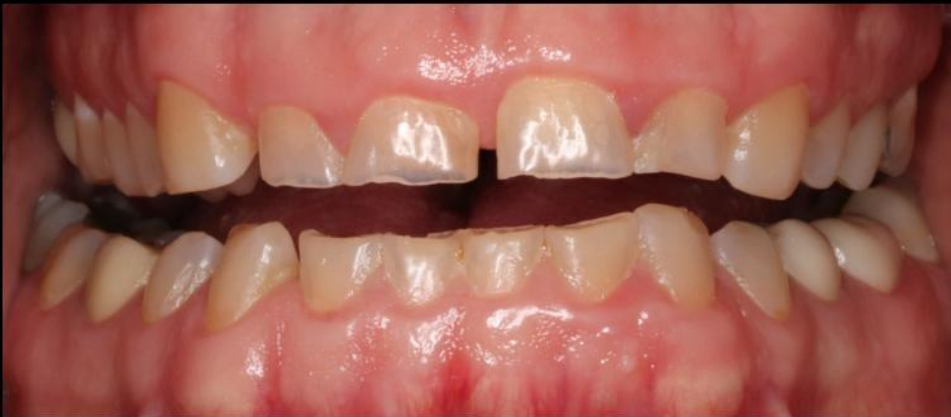Teeth: 10-12 auto



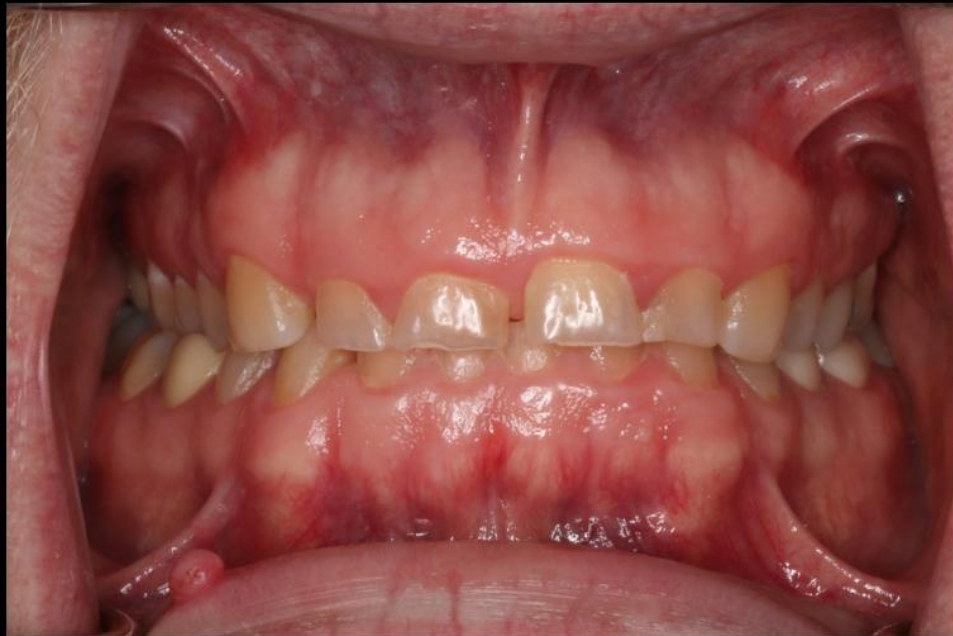8/6/2025 3:28 pm



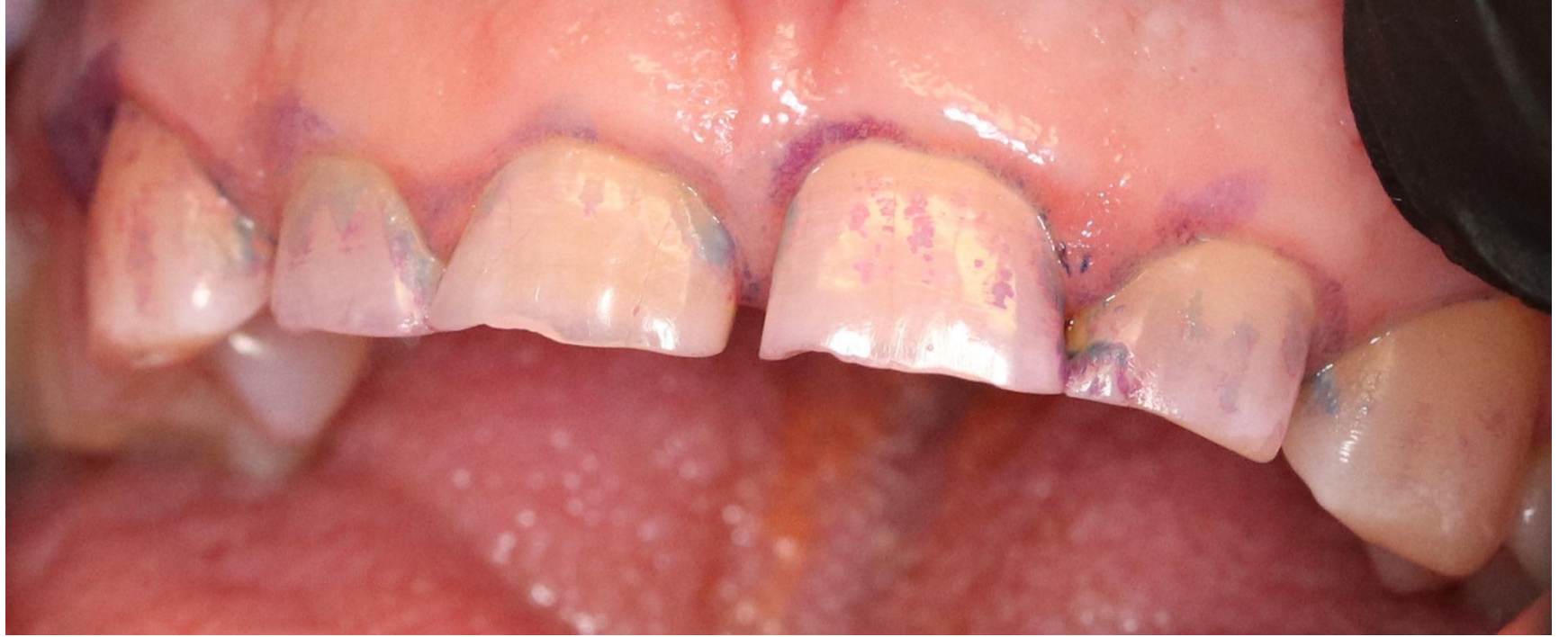8/6/2025 3:31 pm

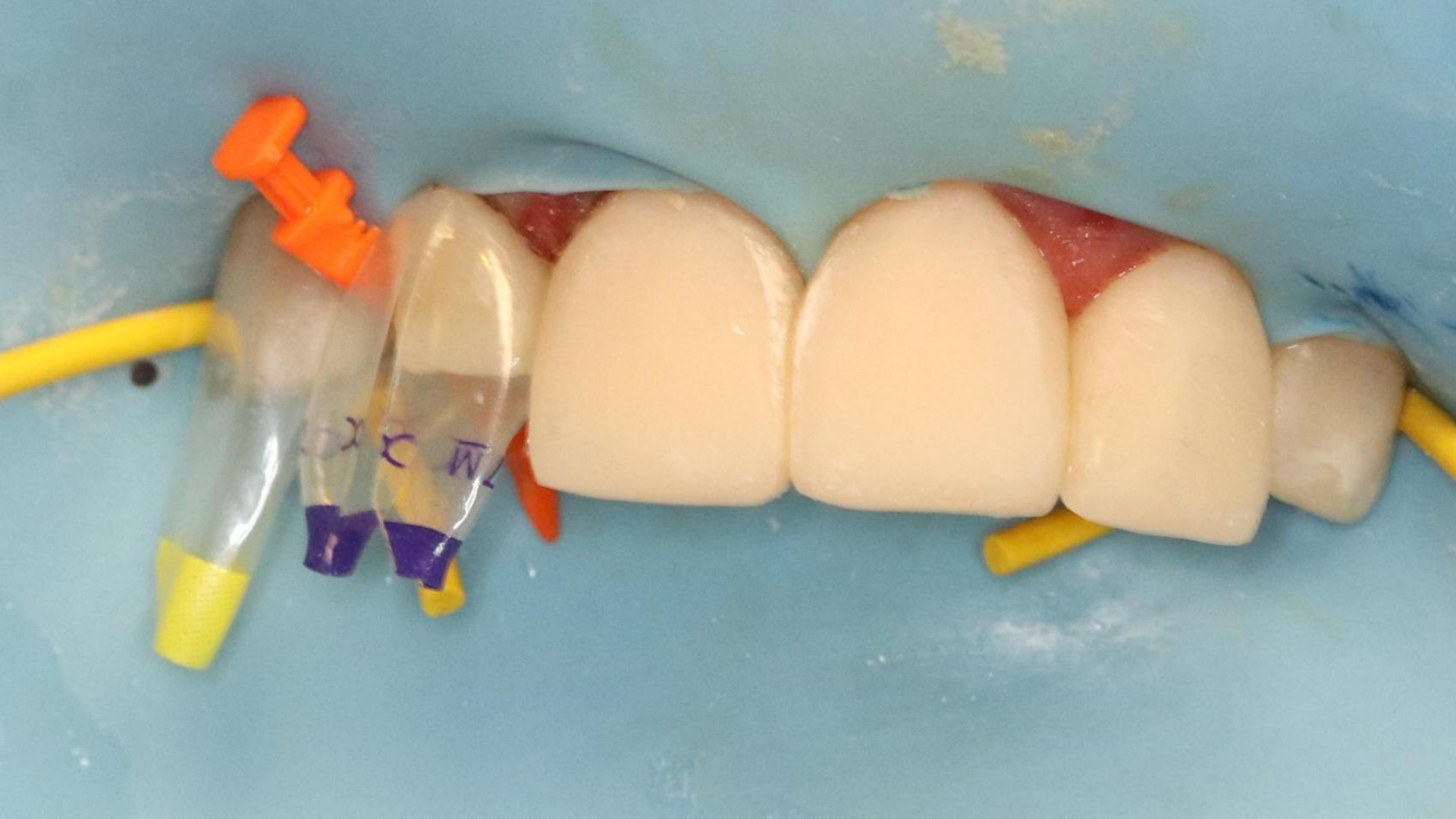

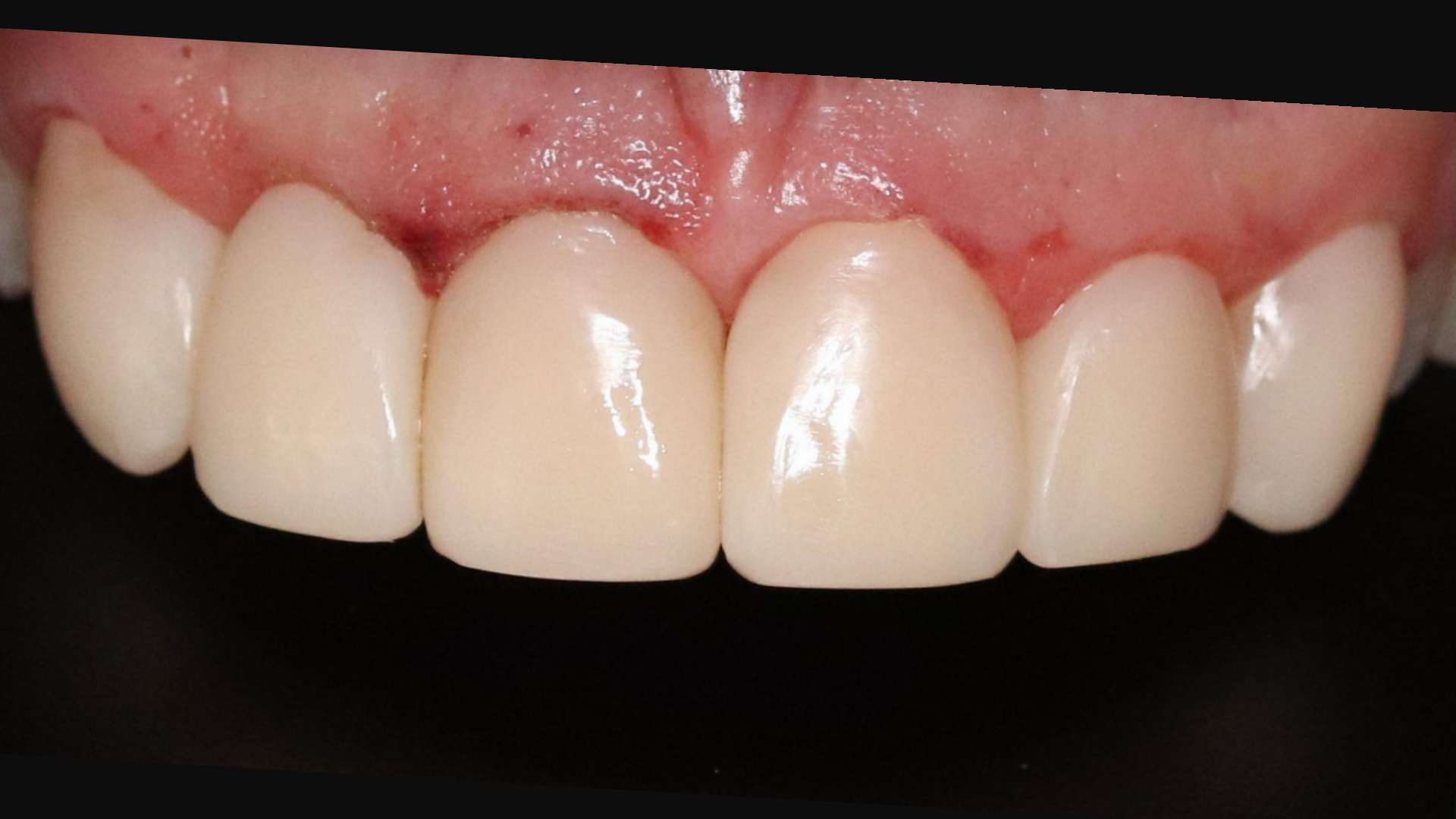8/6/2025 3:28 pm
ⓘ Image has been cropped

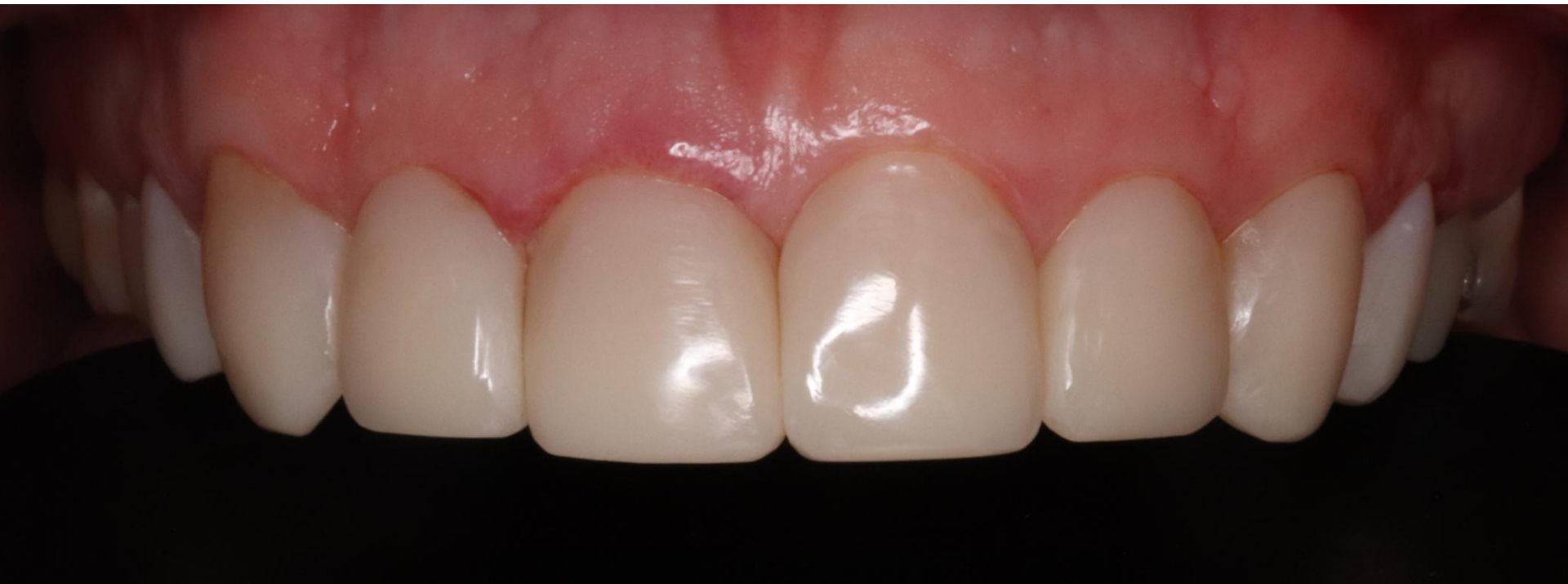

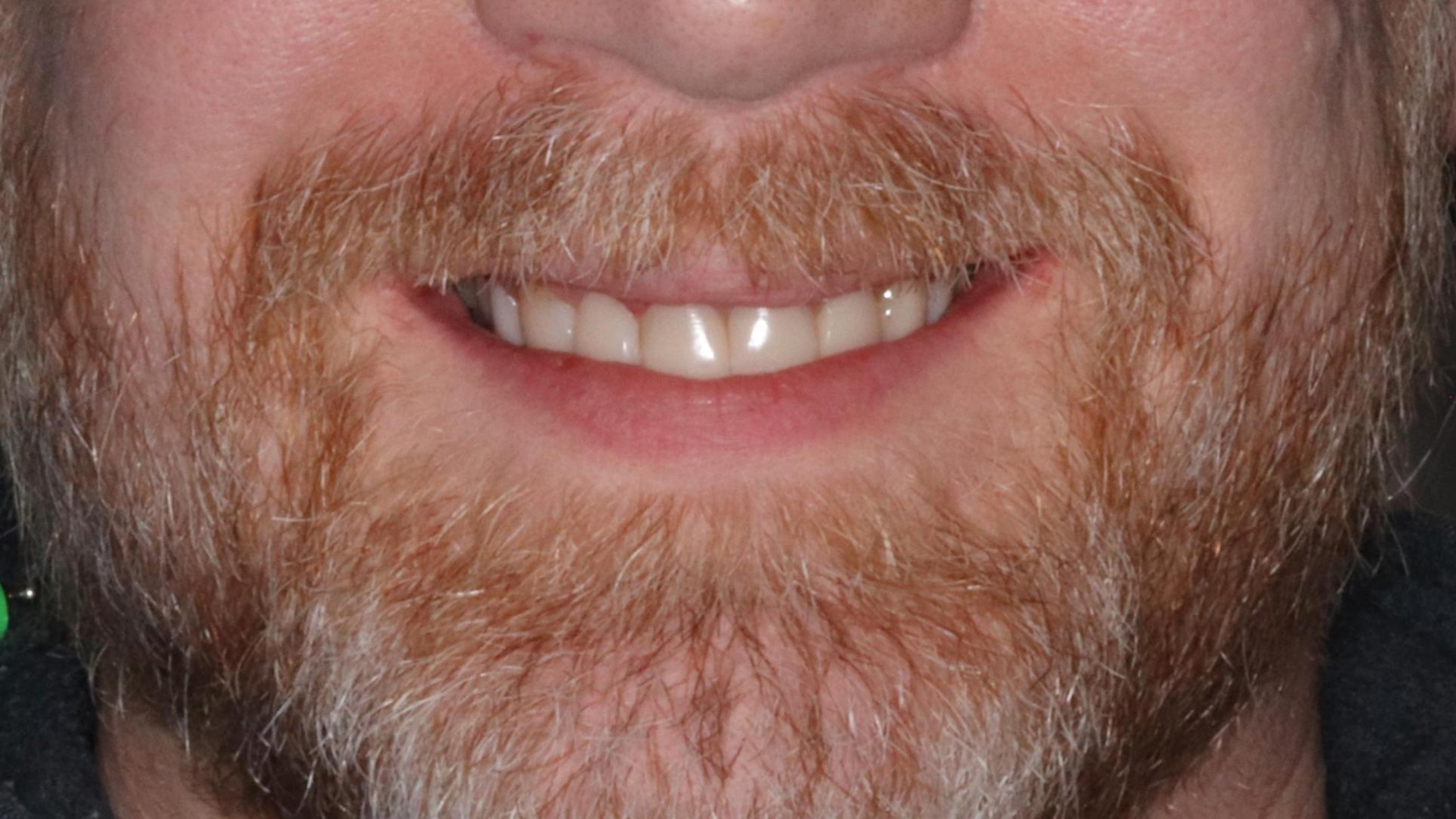8/6/2025 3:28 pm

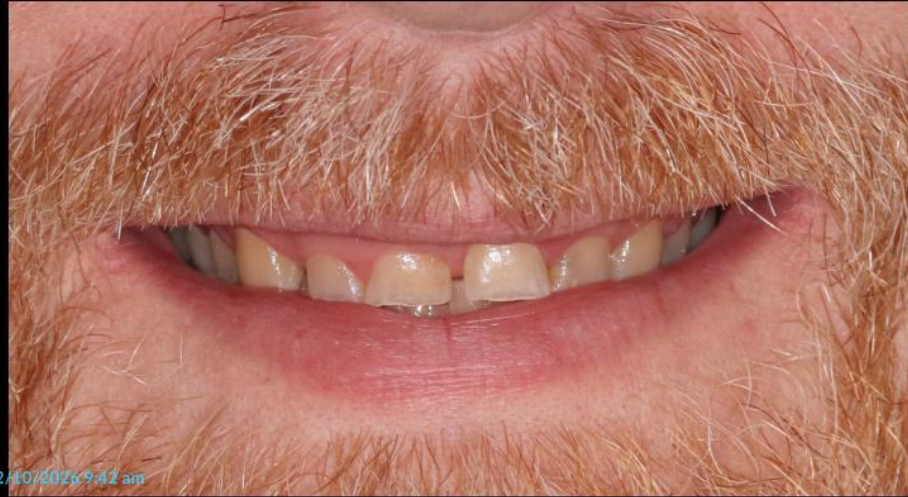




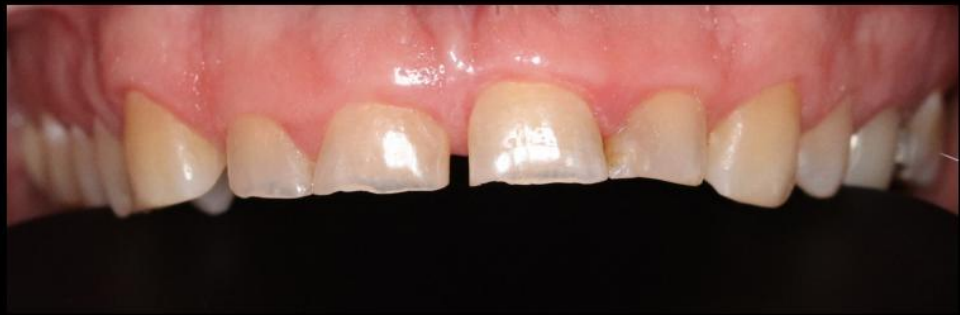




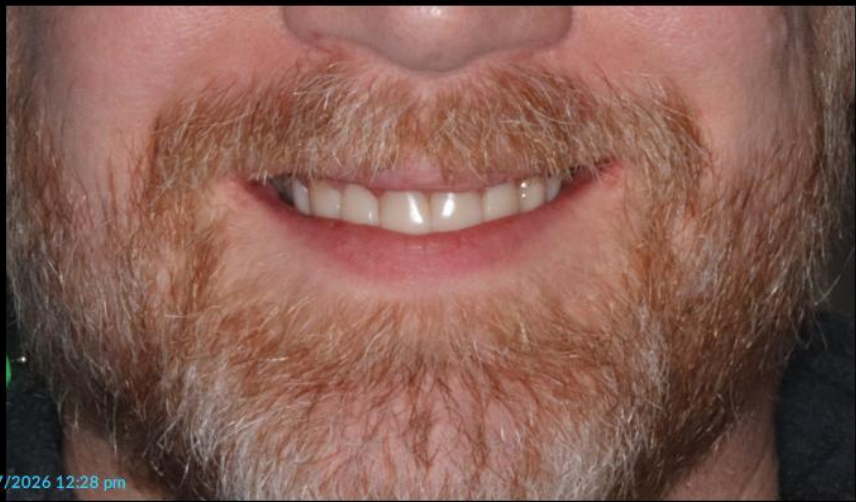

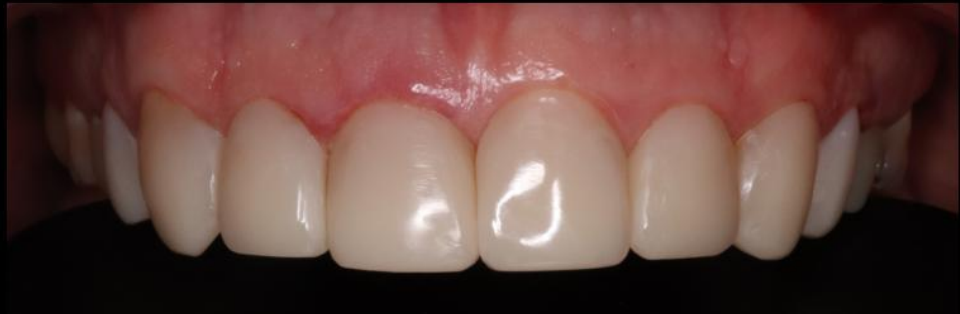2/10/2026 9:42 am



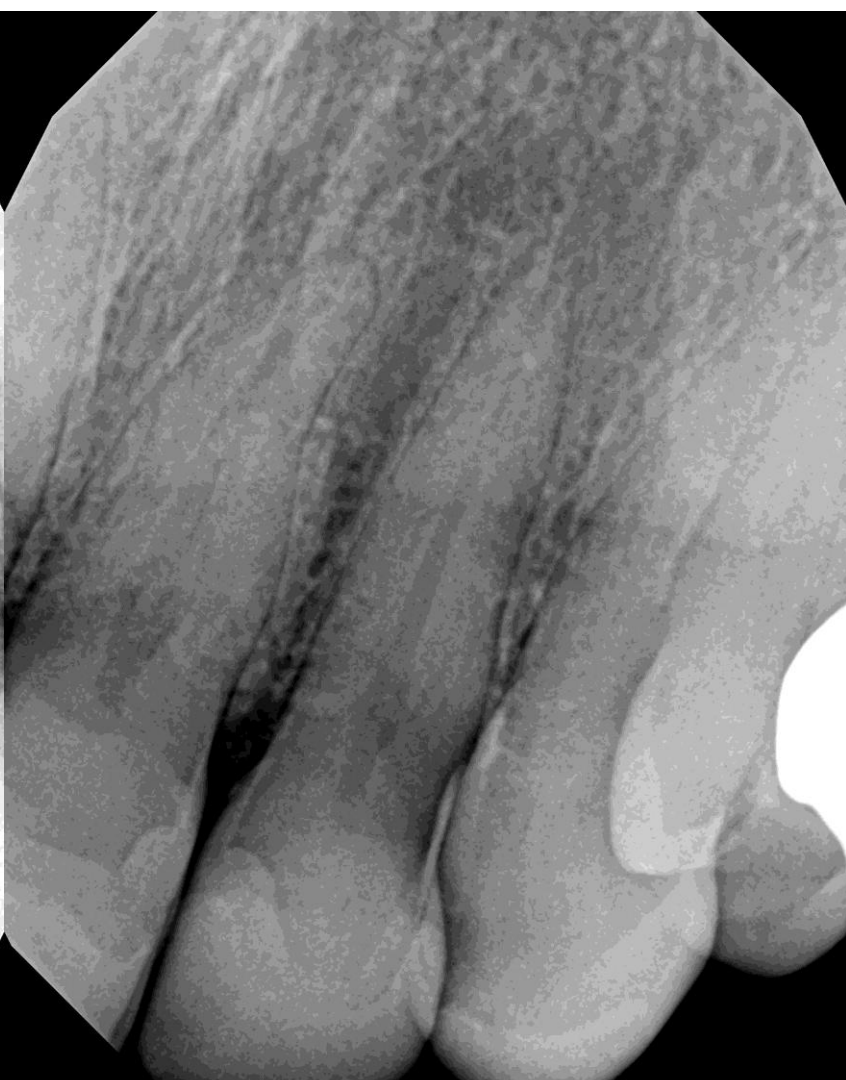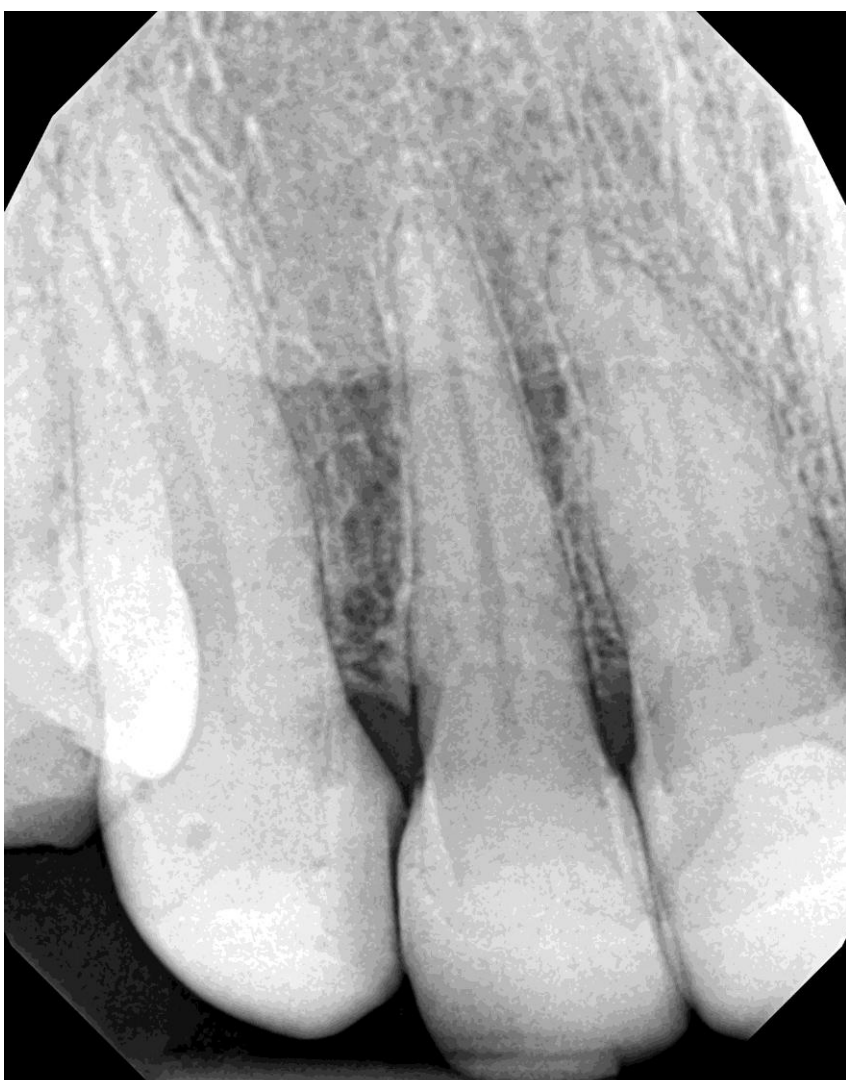2/10/2026 9:32 am



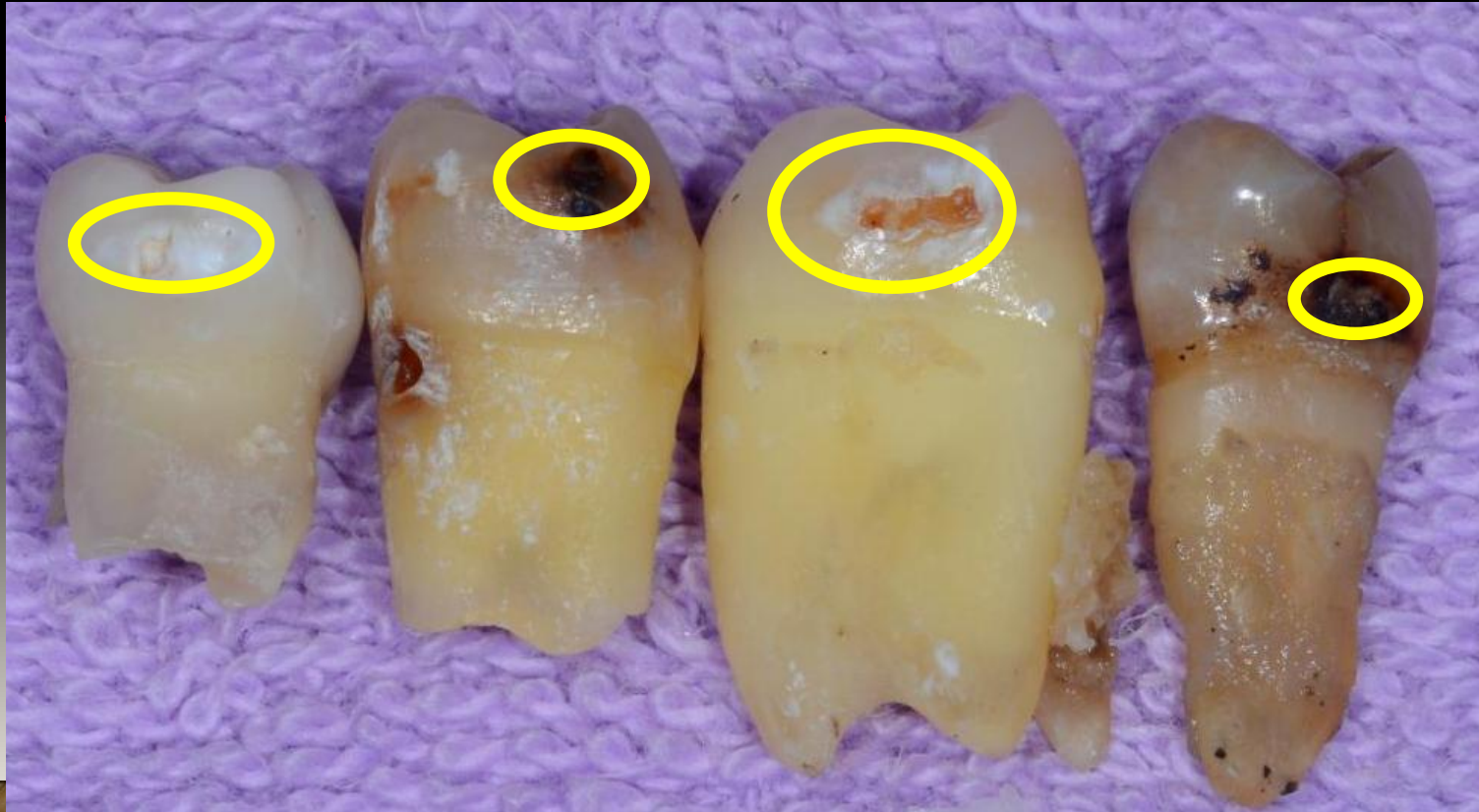2/17/2026 12:28 pm



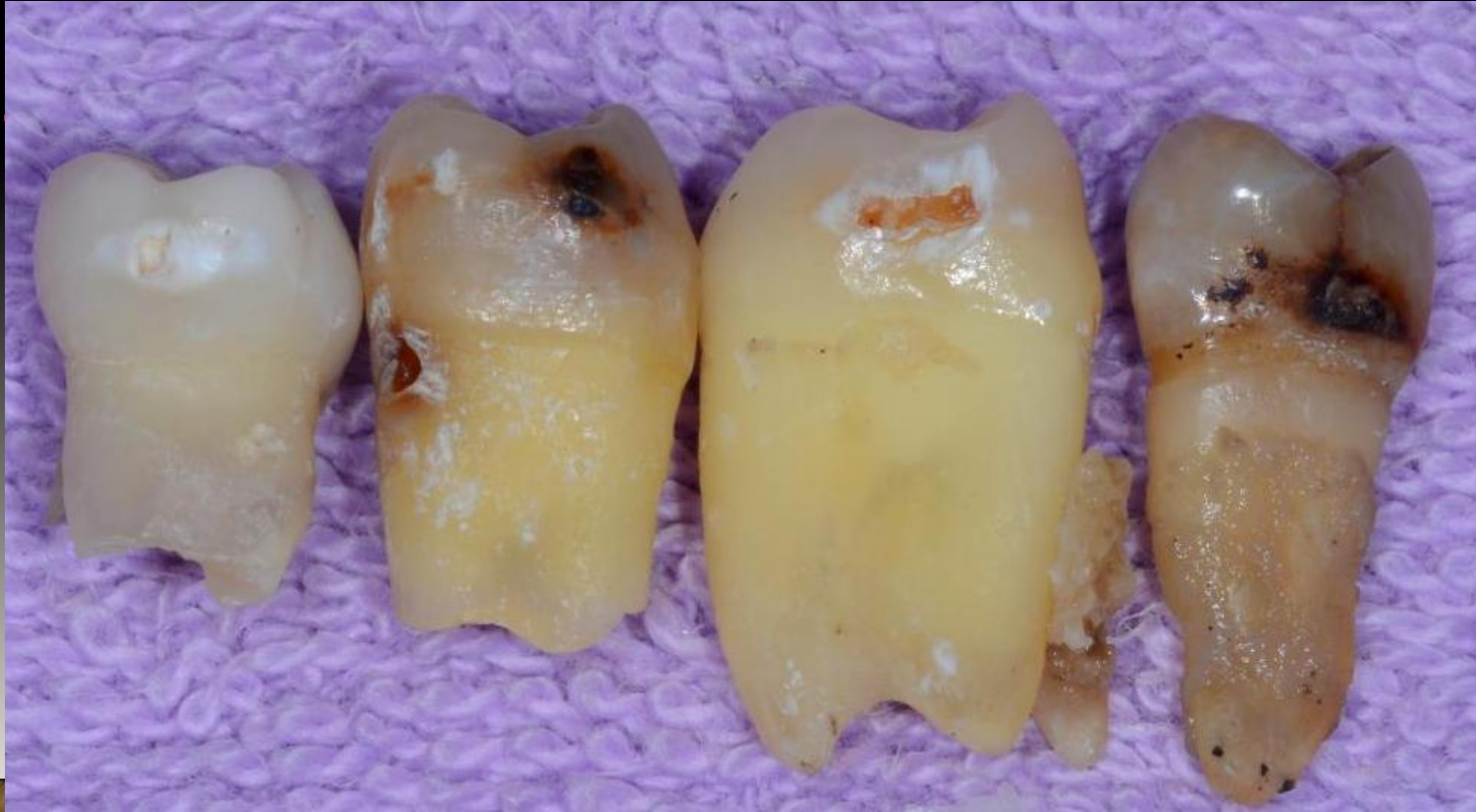2/17/2026 12:29 pm



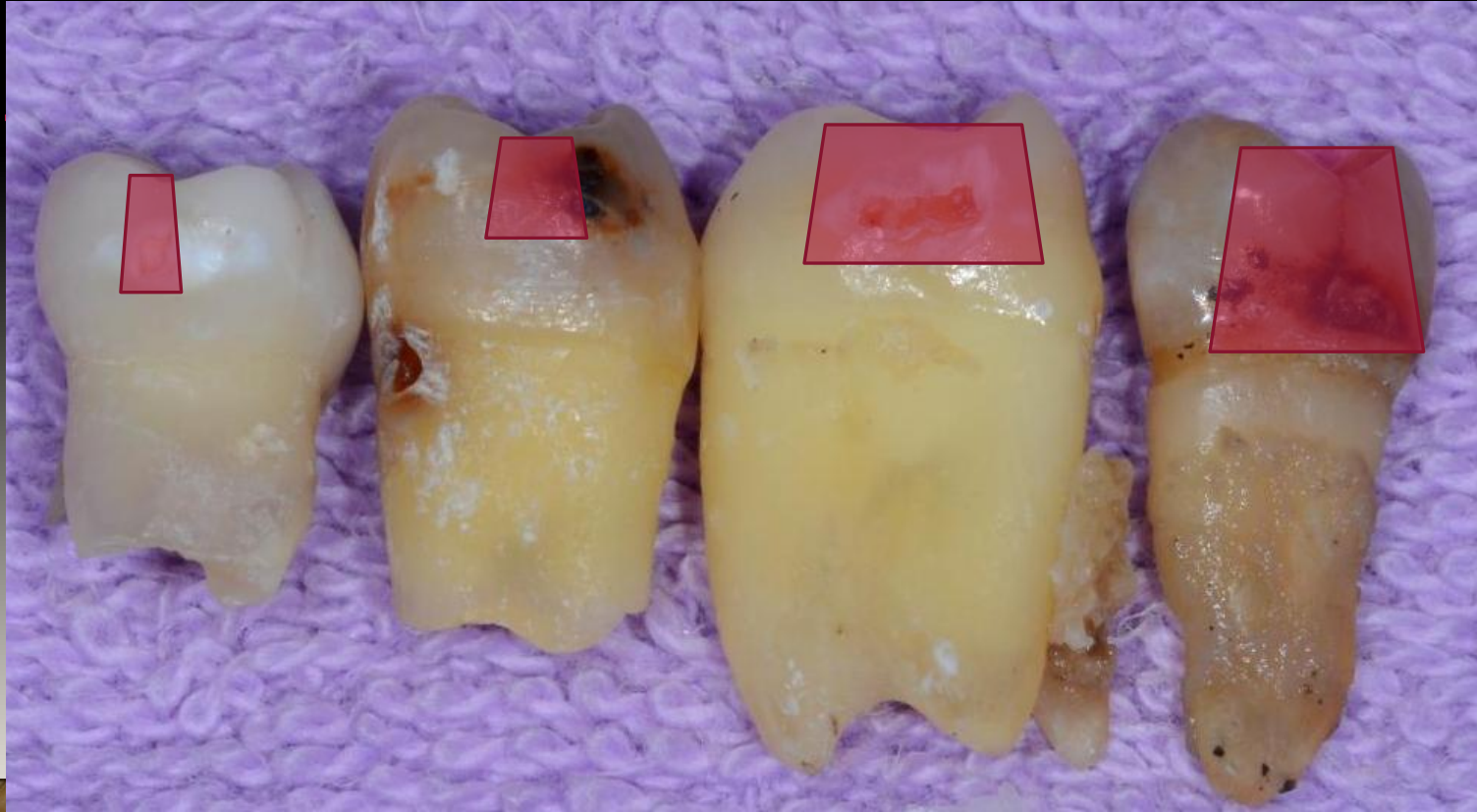
CAVITATION VS APRISMATIC ENAMEL



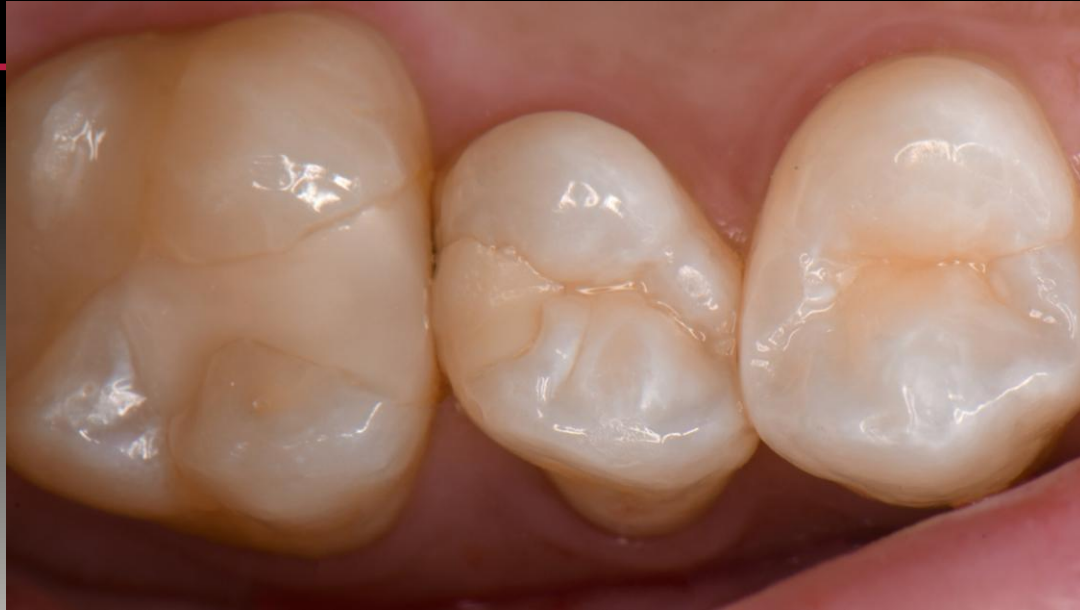WHY WOULD WE PUT A MARGIN IN THE *DISEASE ZONE*?



FOUR WAYS TO CUT A TRAGIC SLOT PREP

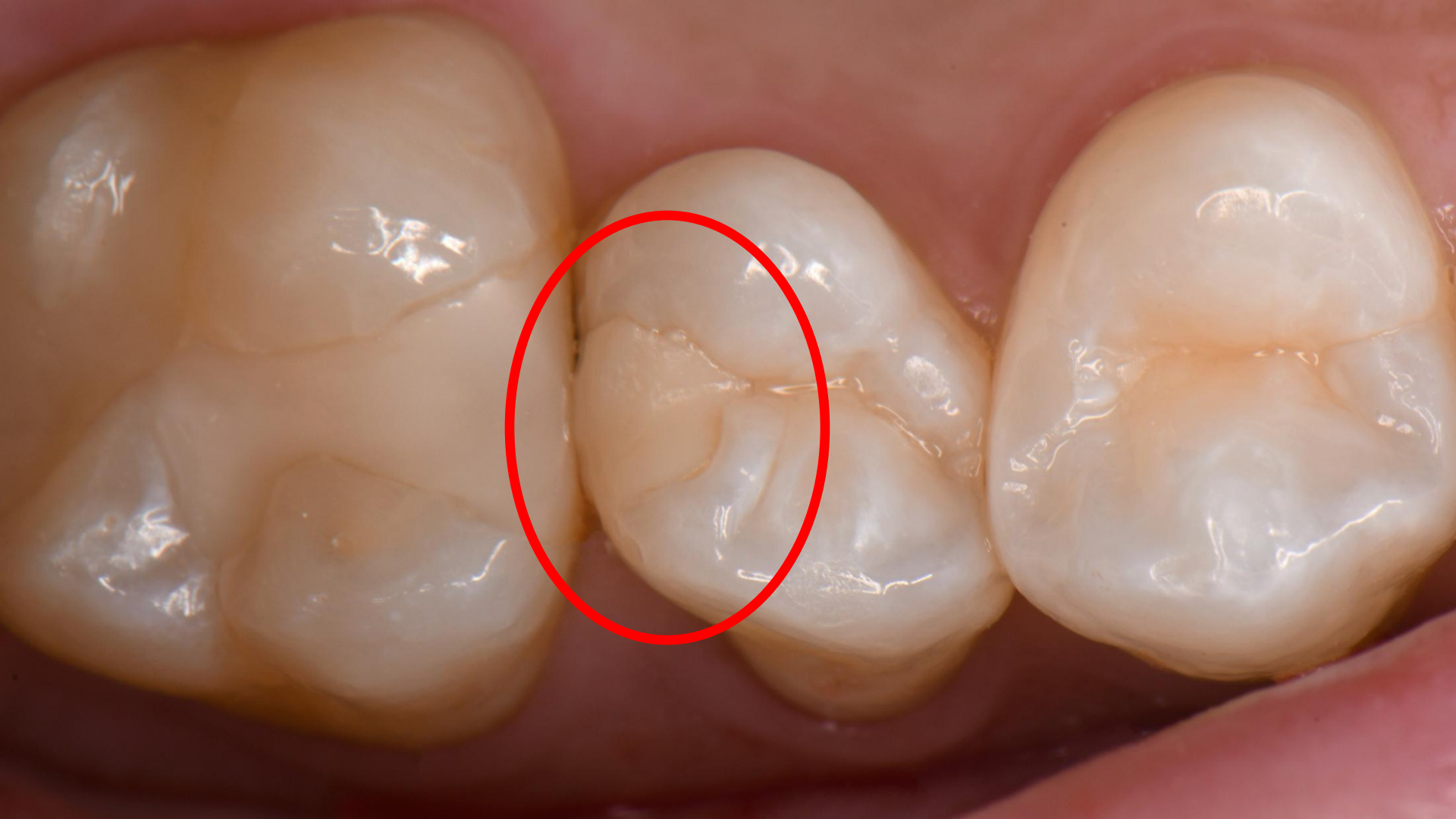

LET'S PUT IT ALL TOGETHER WITH EVOLVE



The Bioclear Evolve All In One Kit

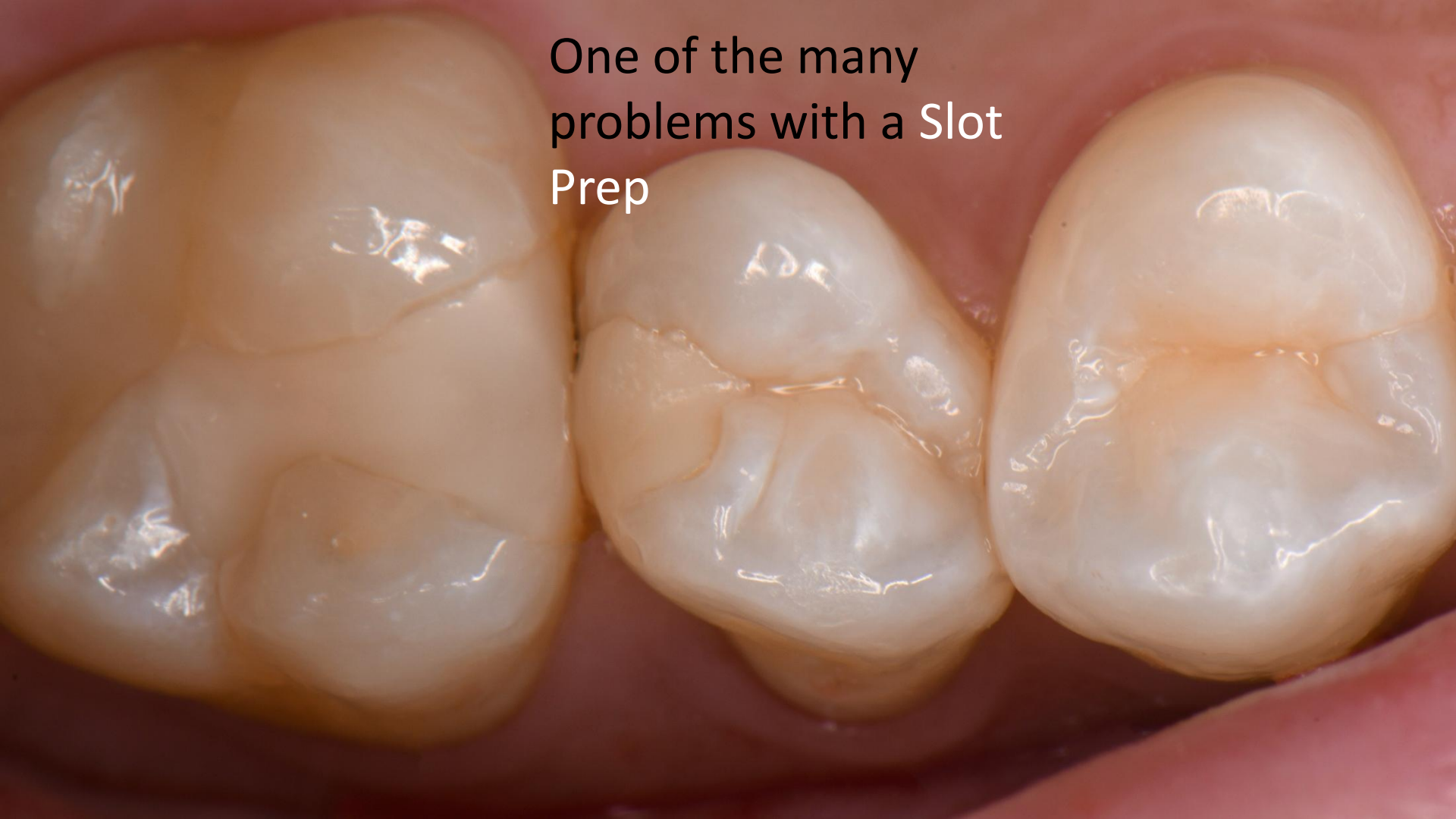


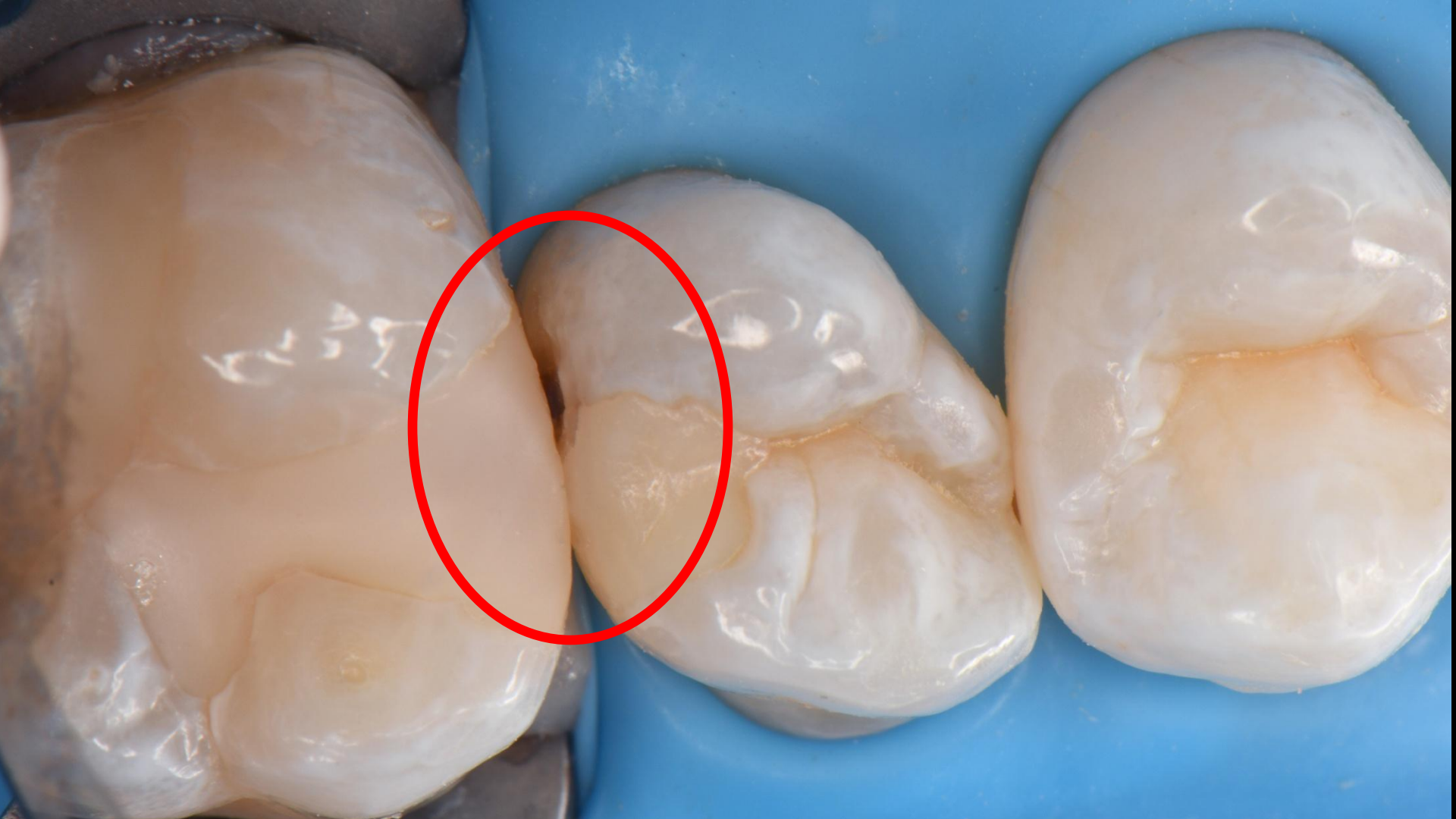
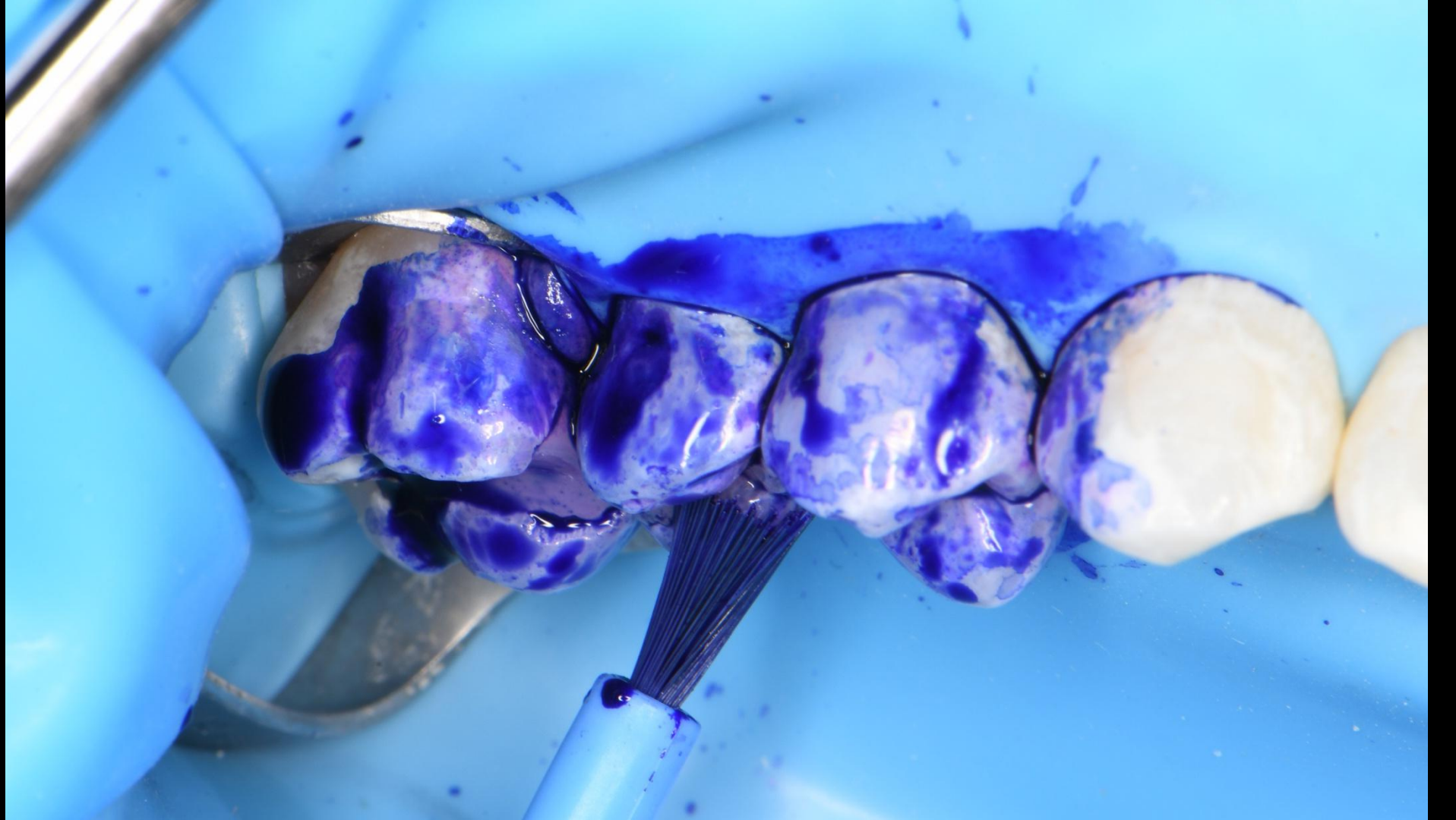One of the many
problems with a Slot
Prep

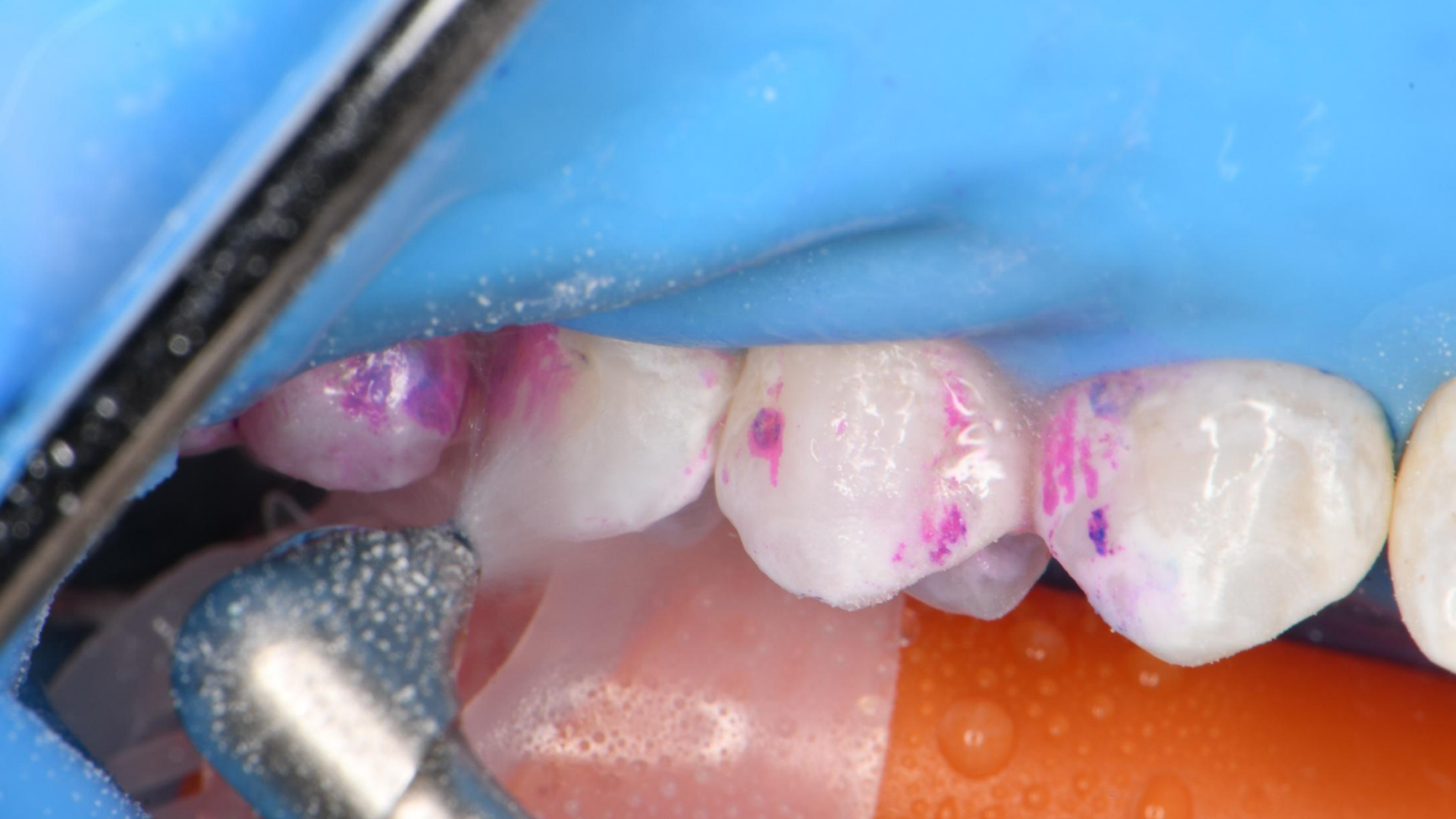

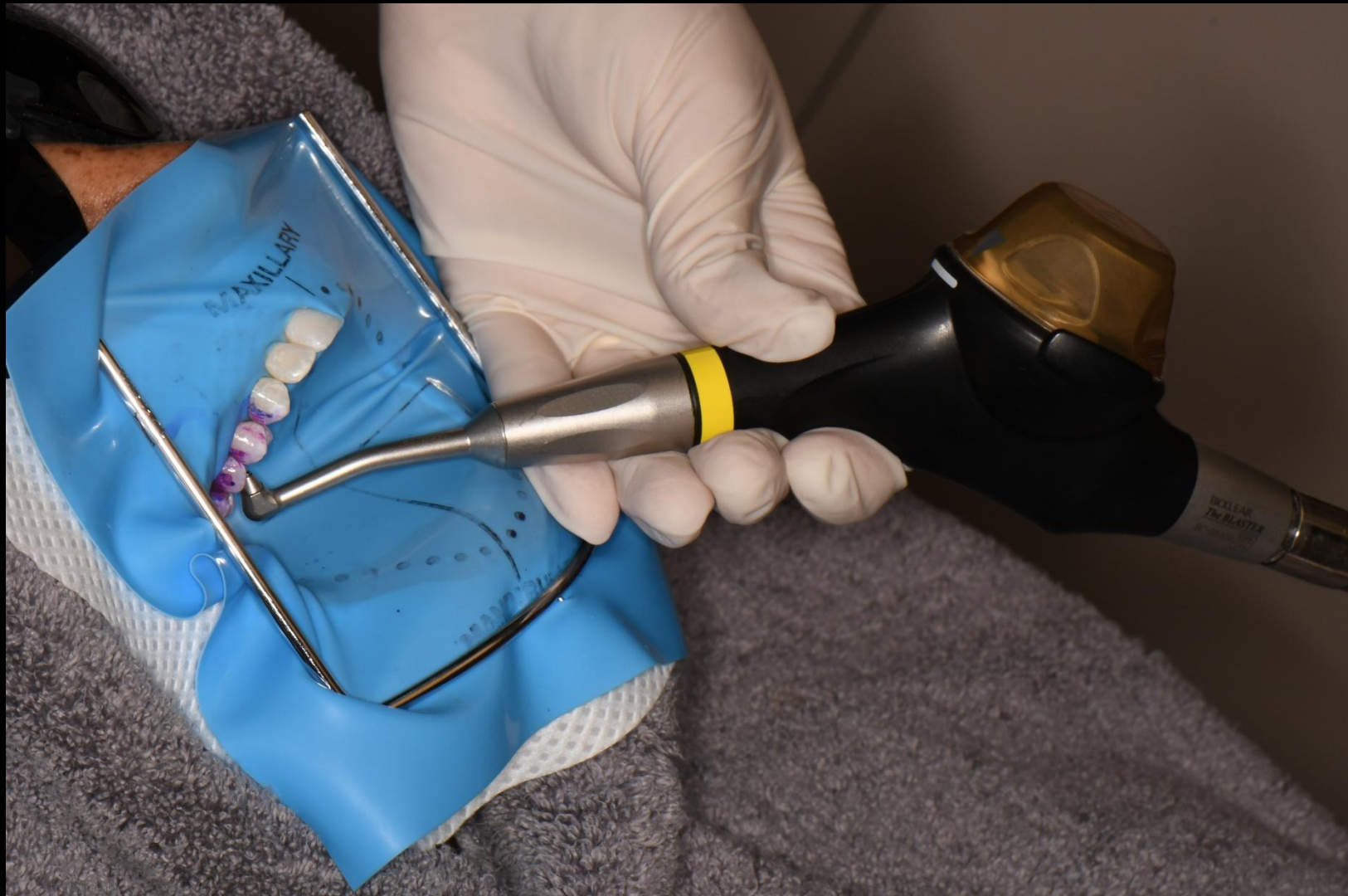One of the many
problems with a Slot
Prep

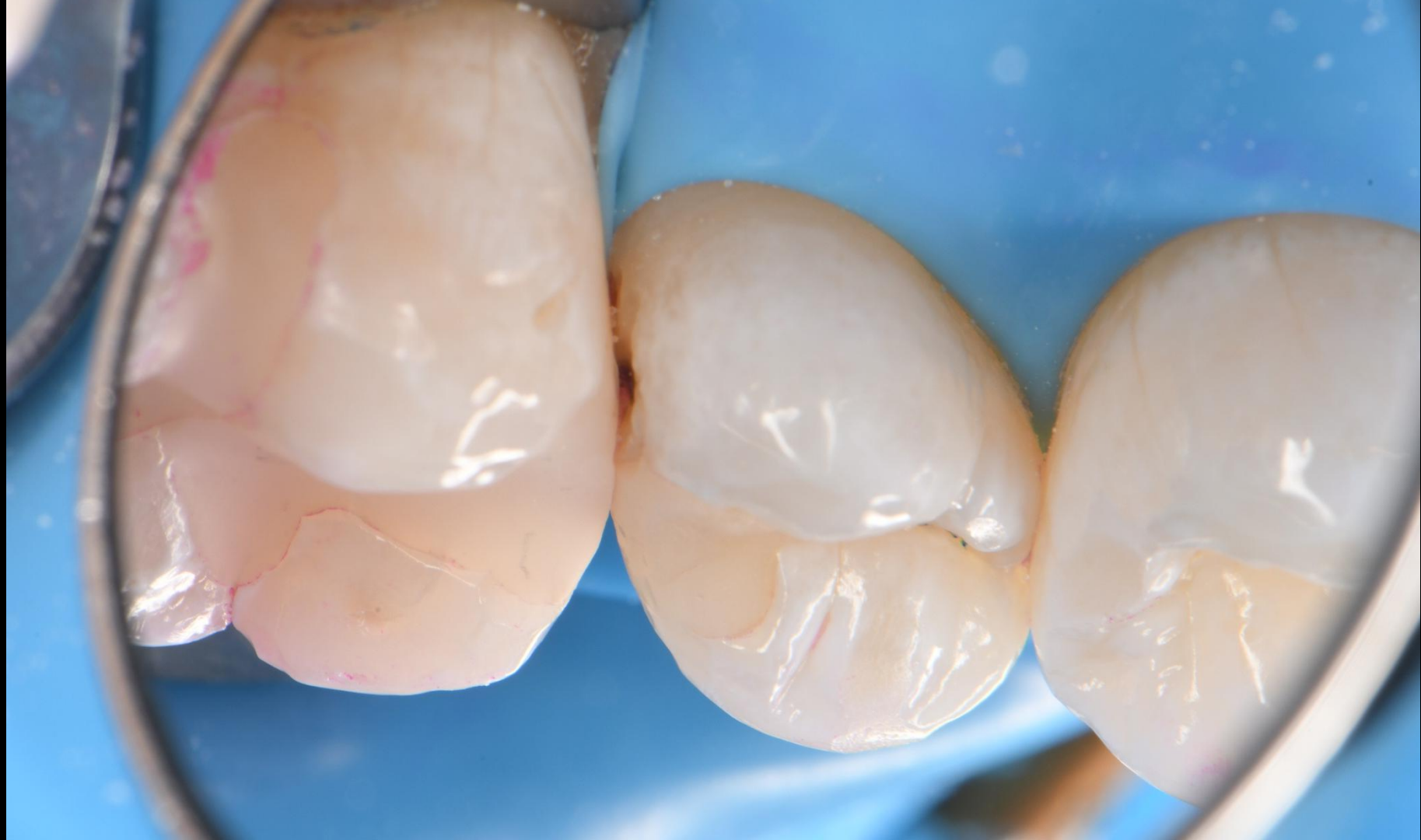


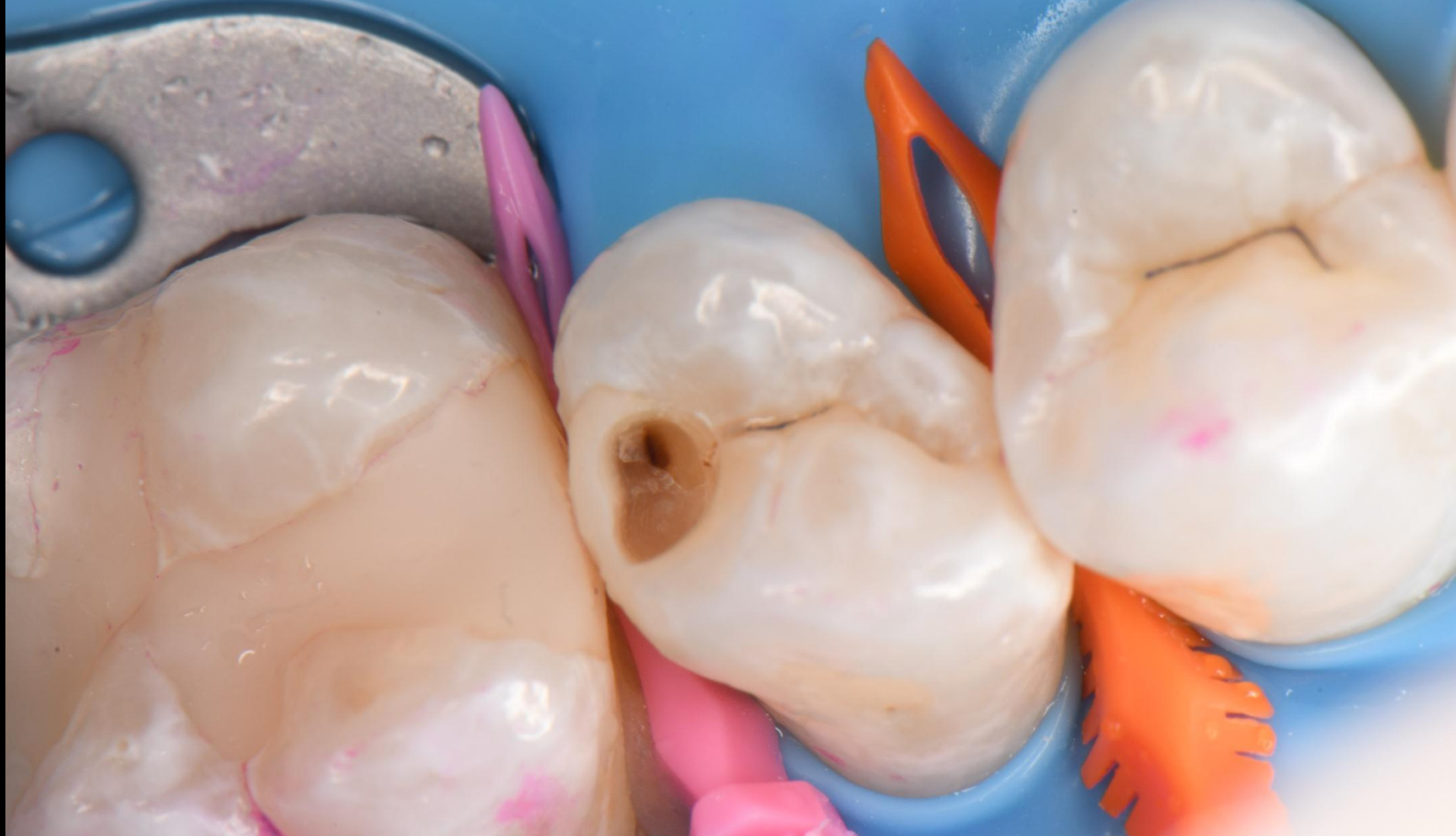


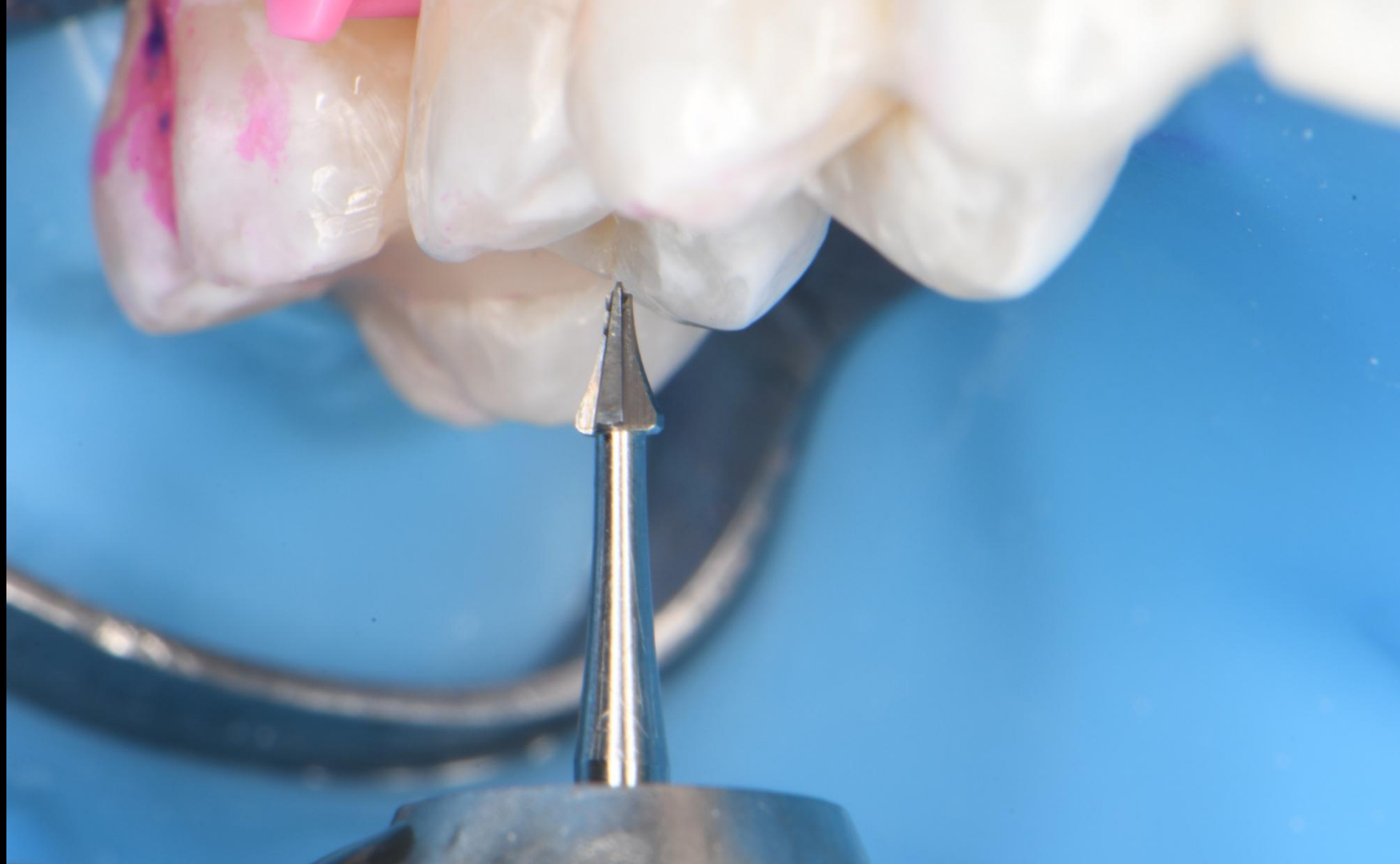


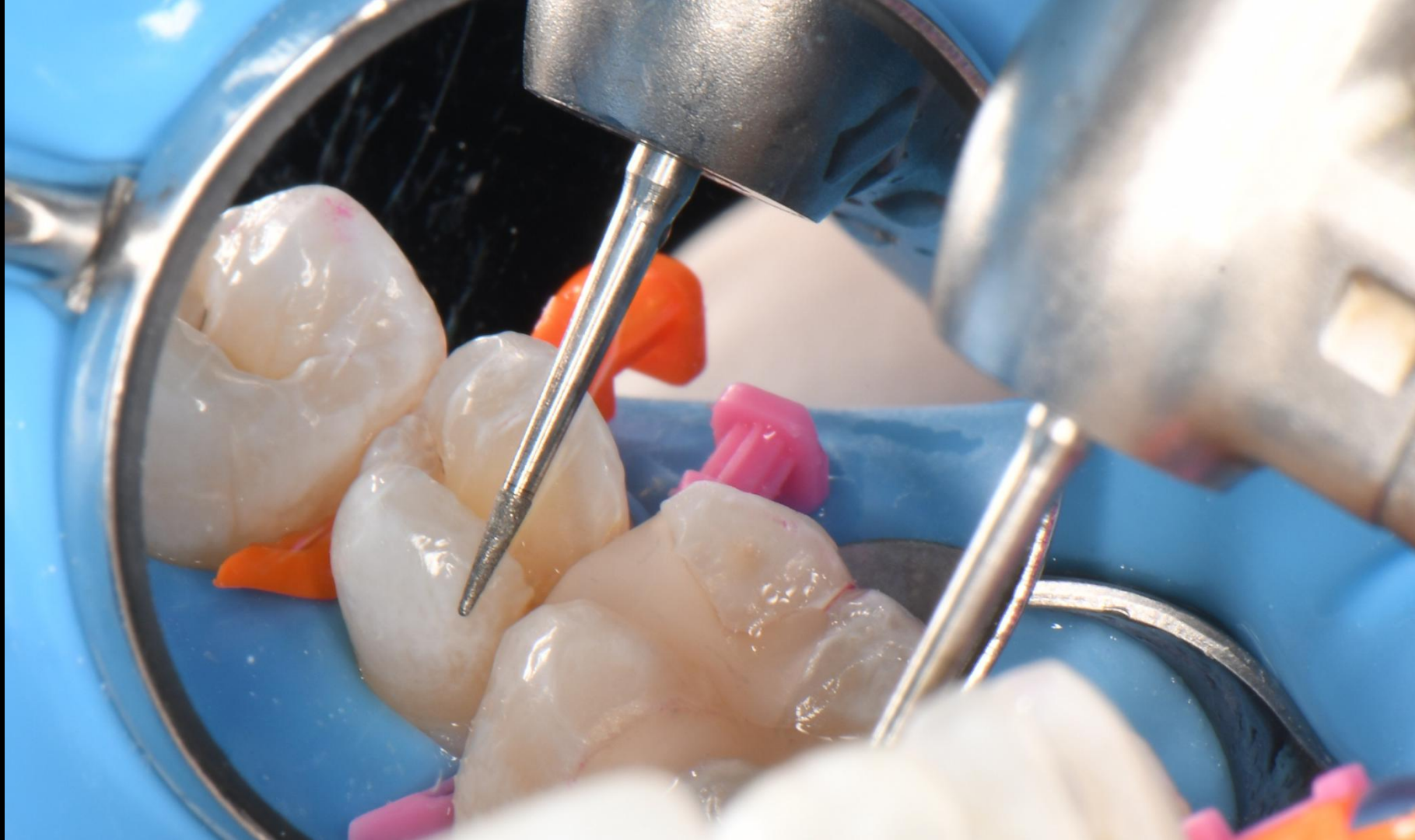


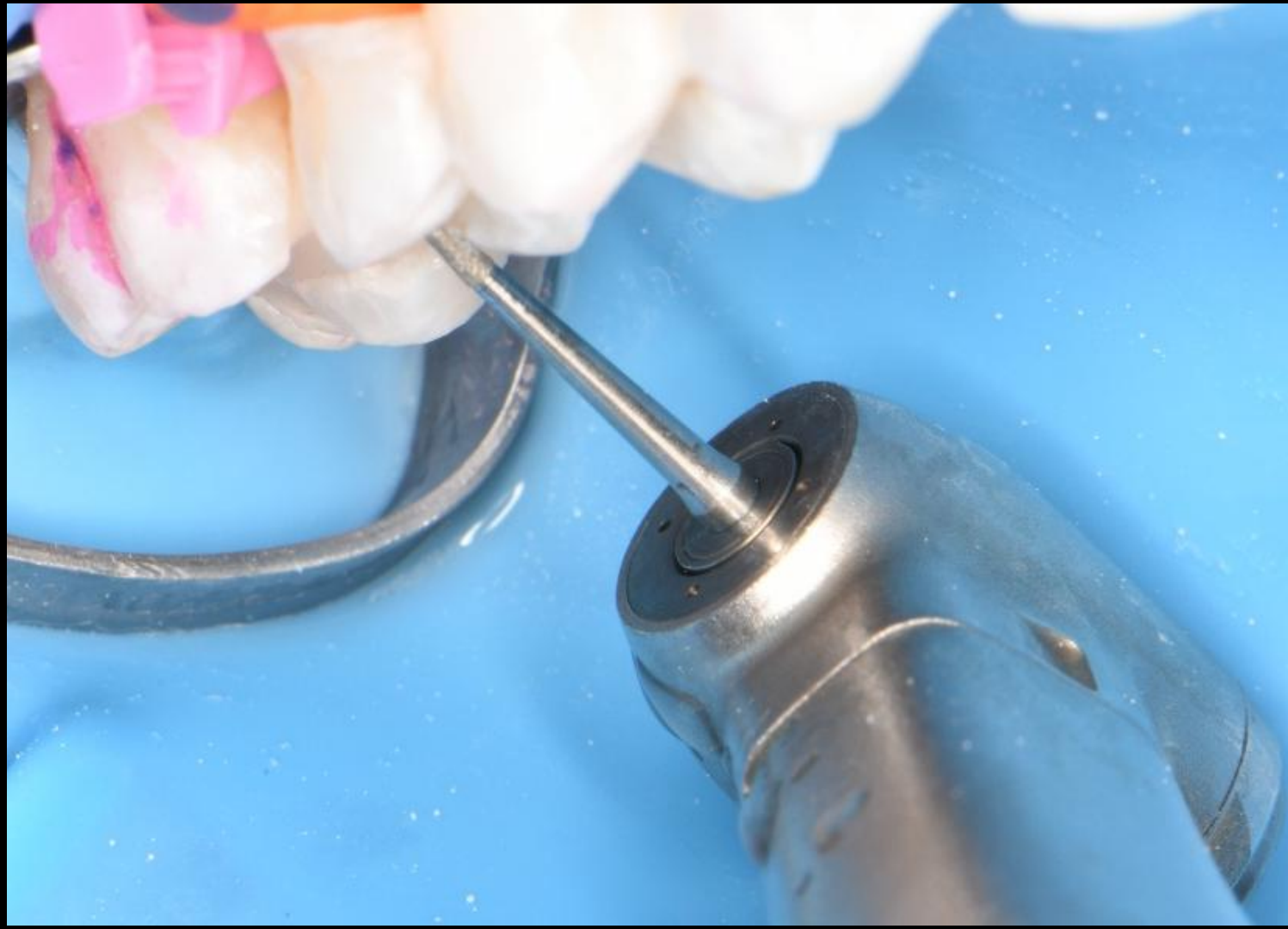


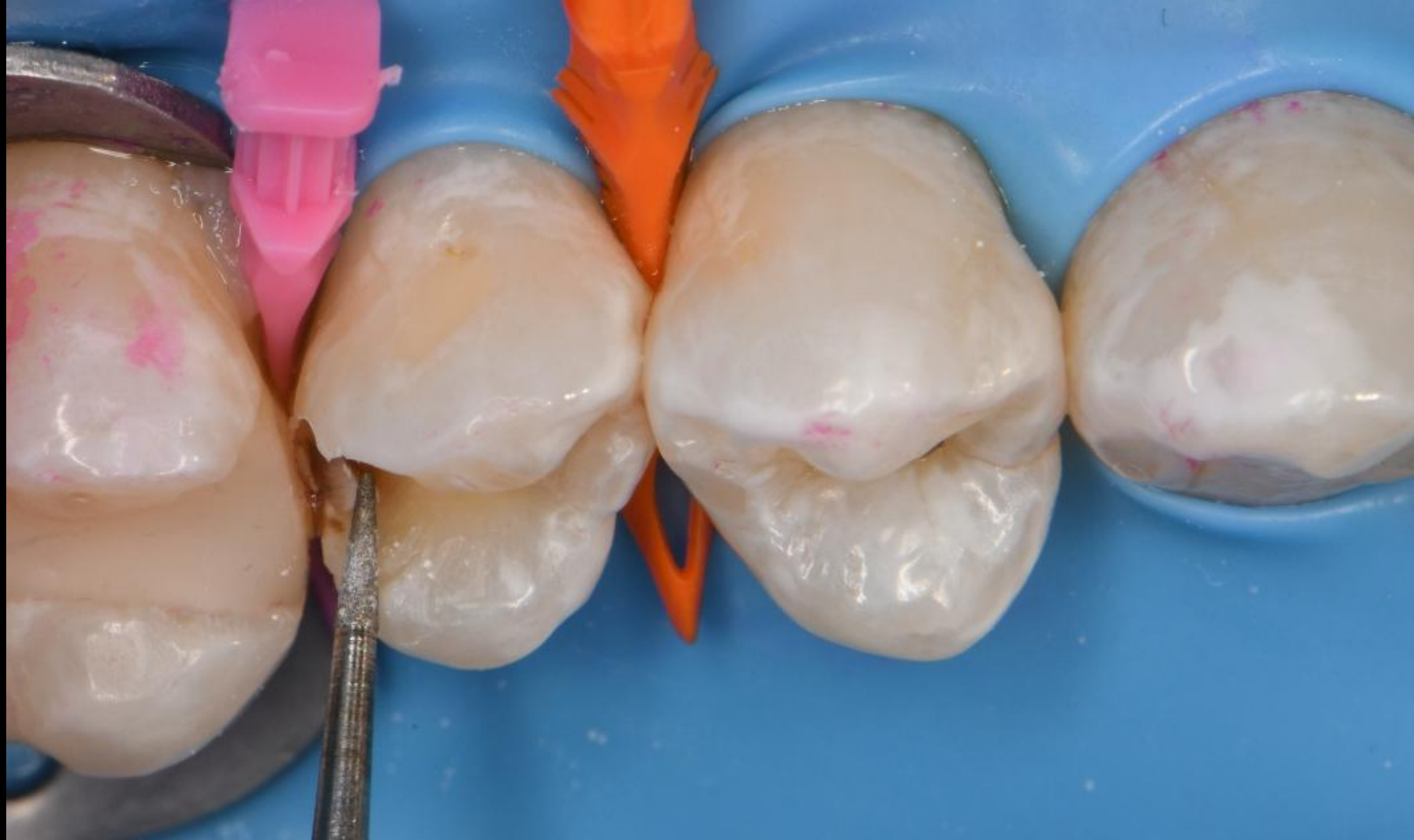
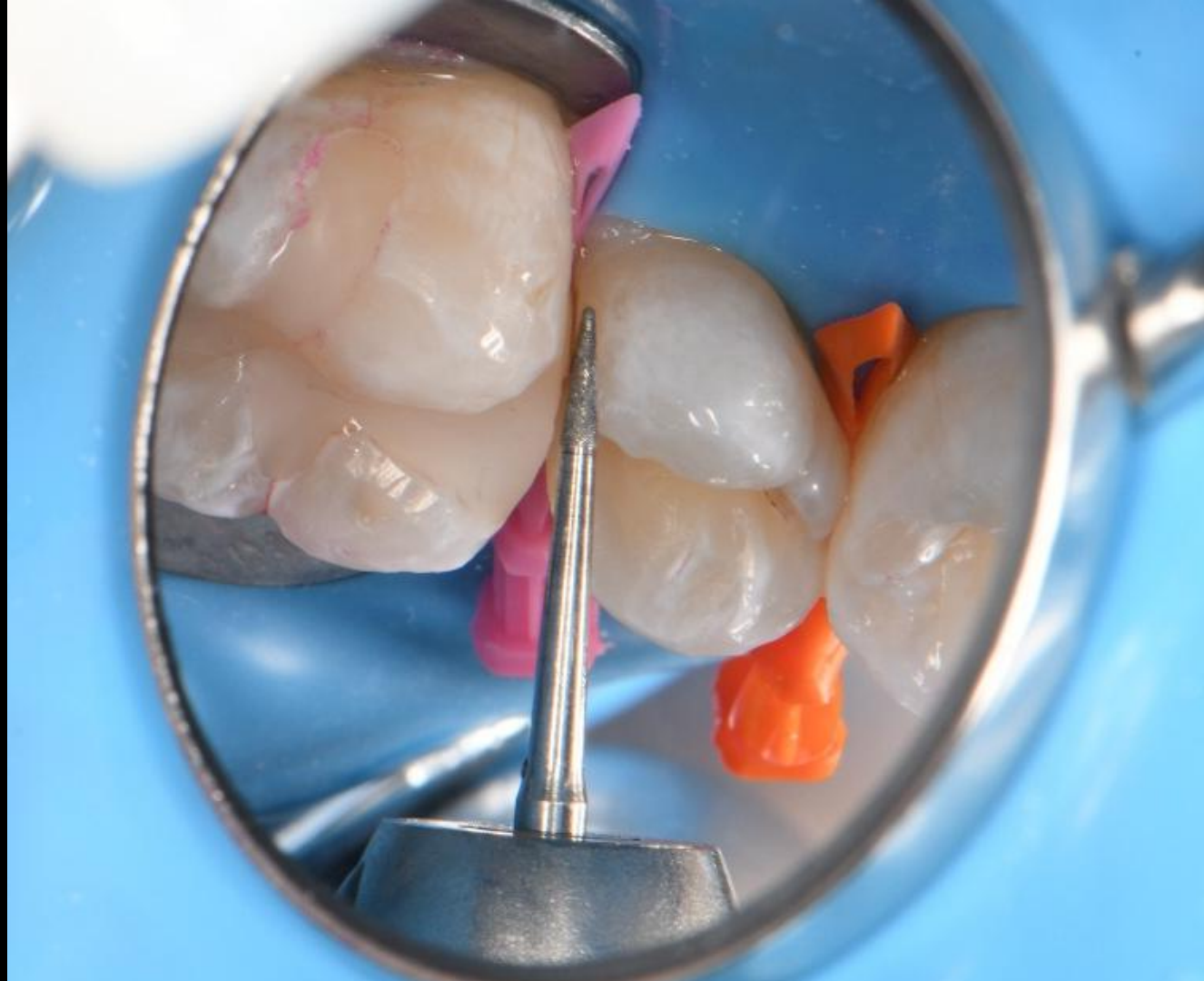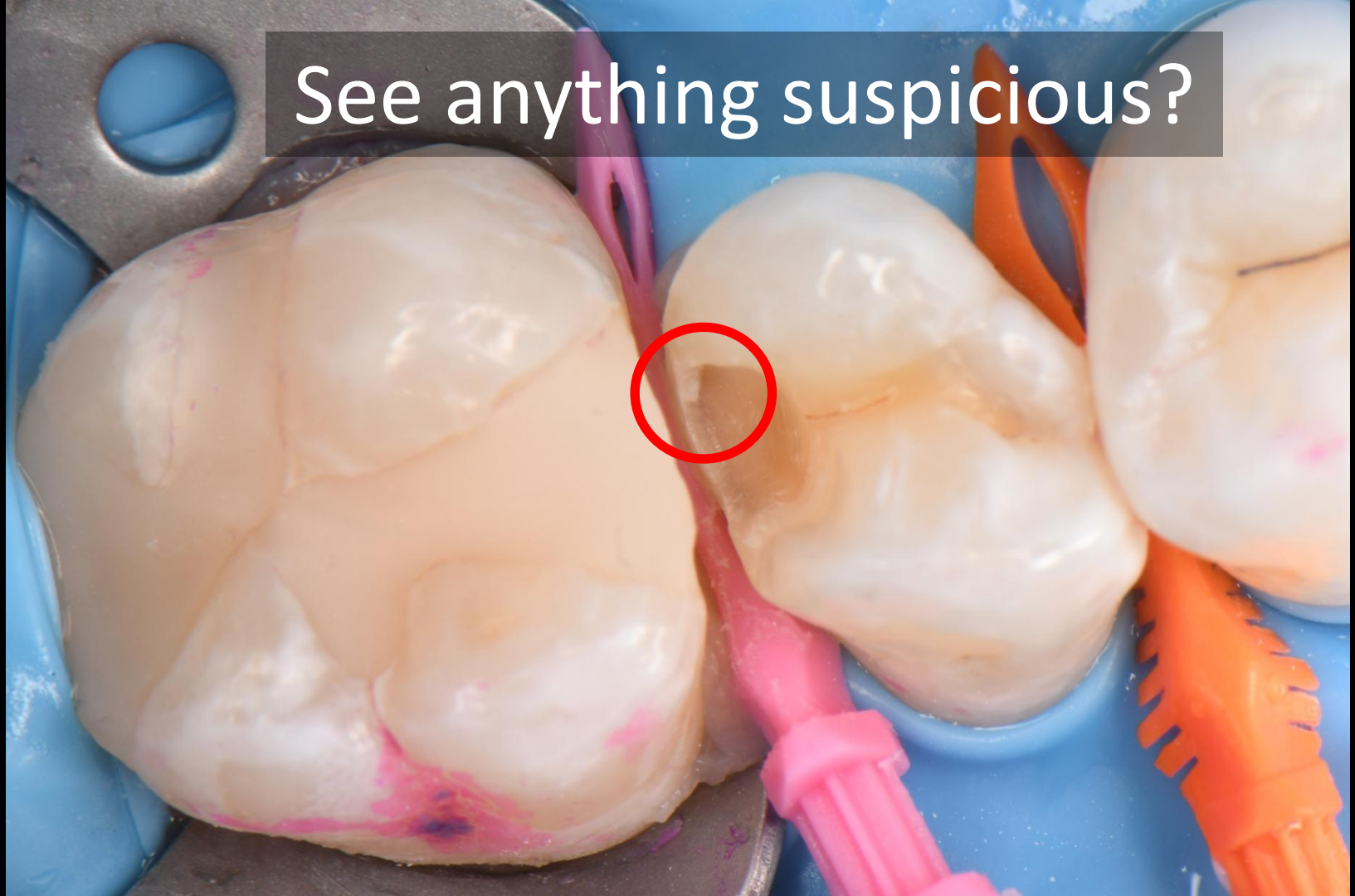








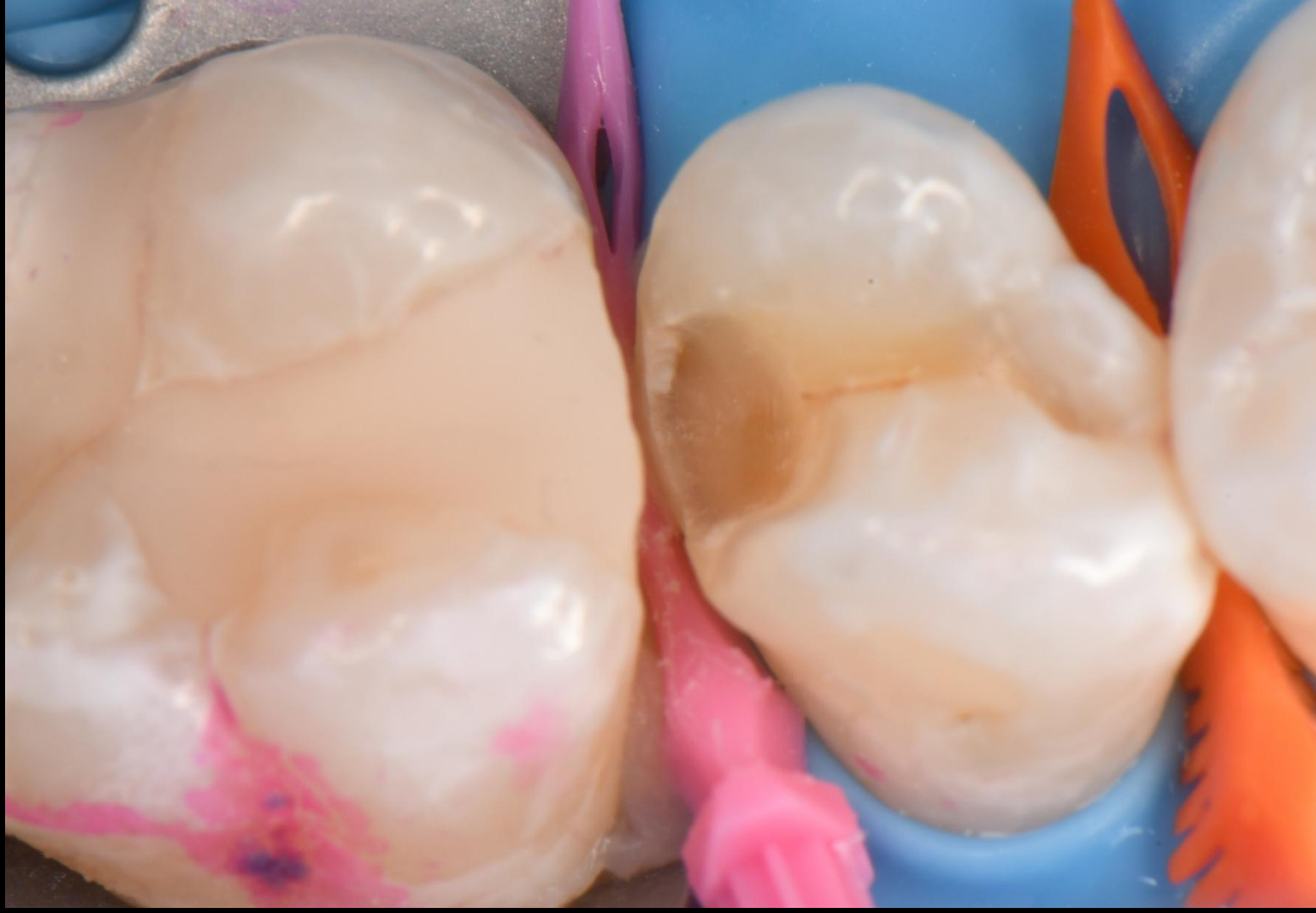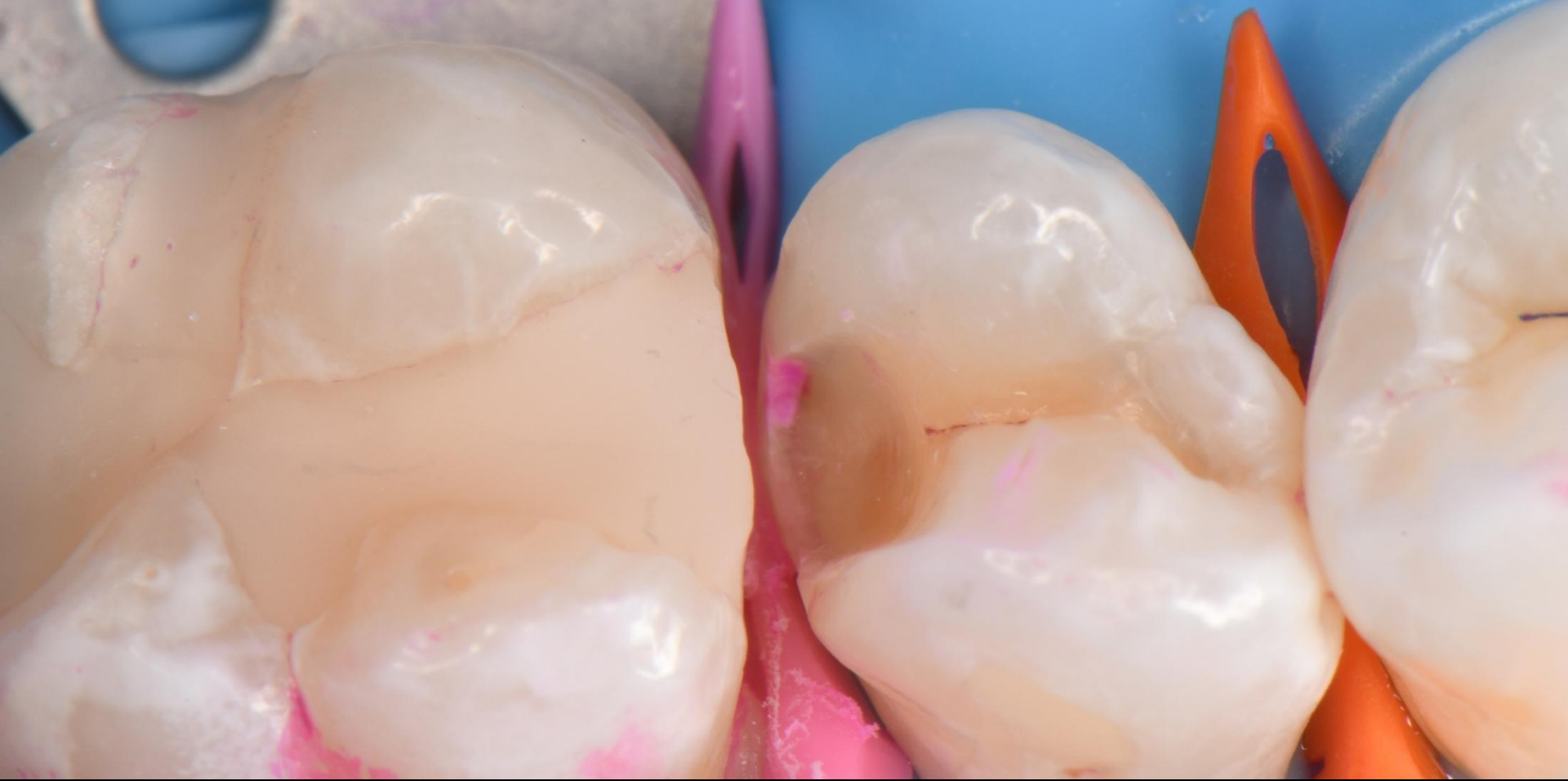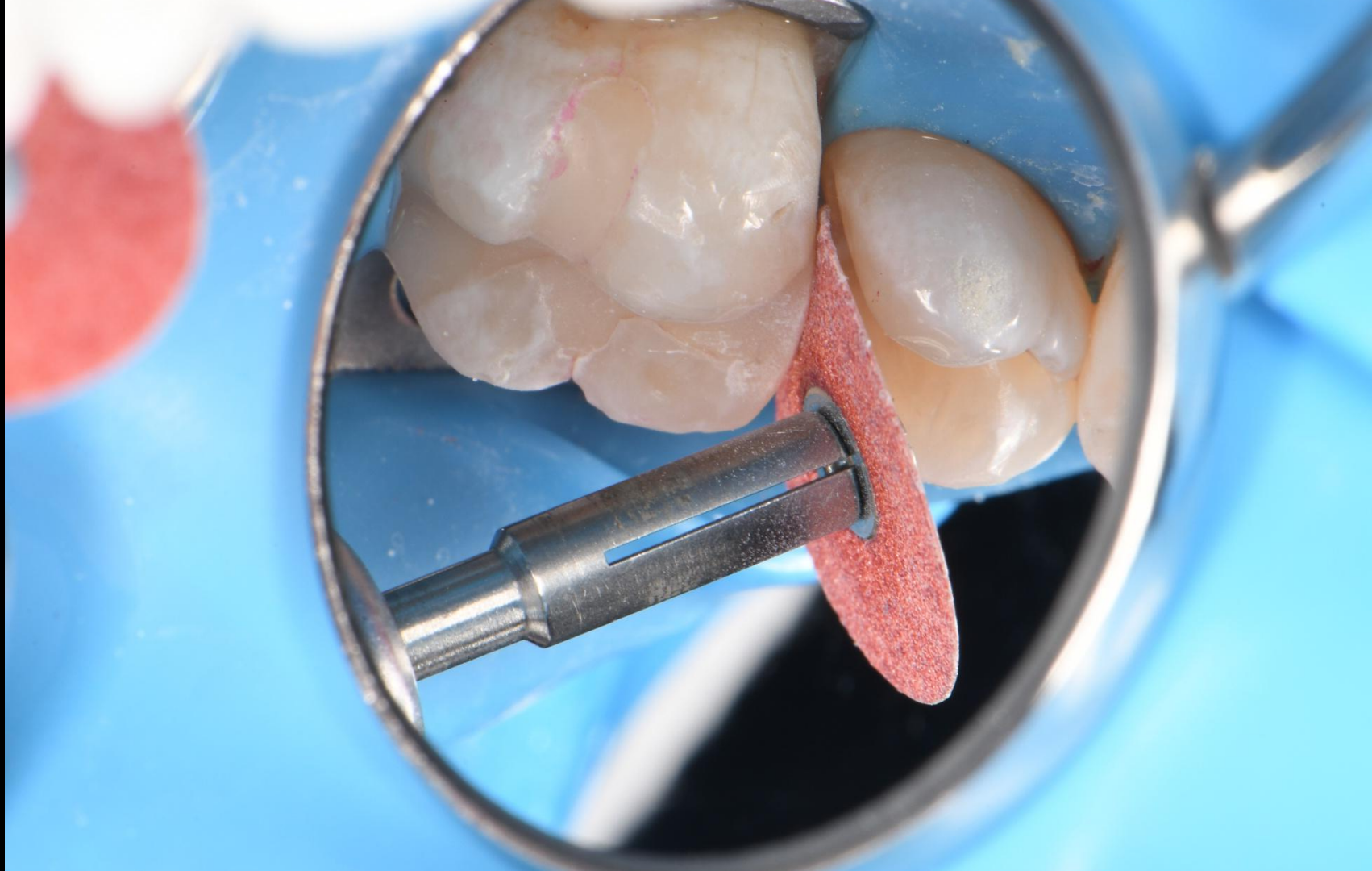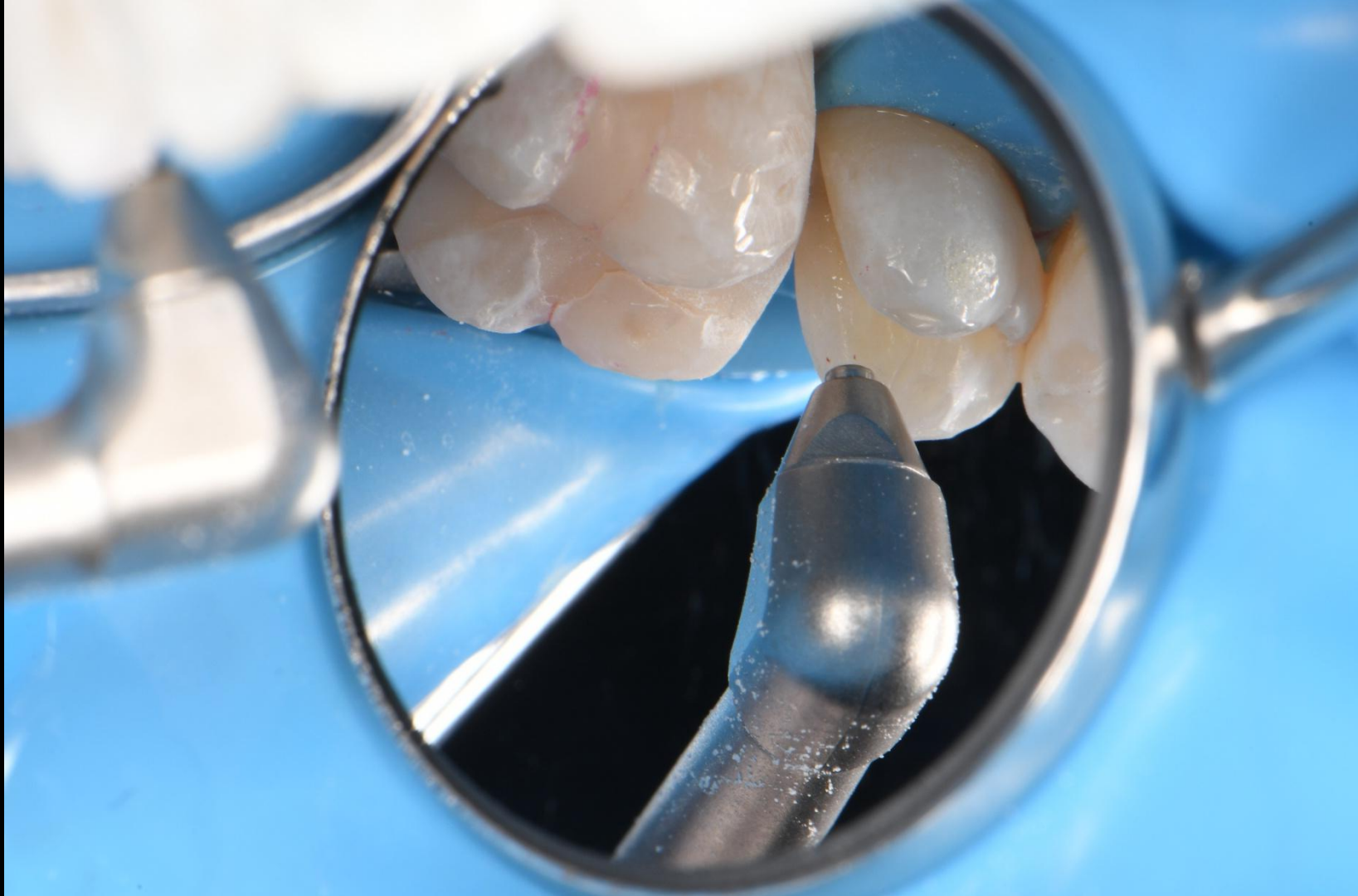See anything suspicious?



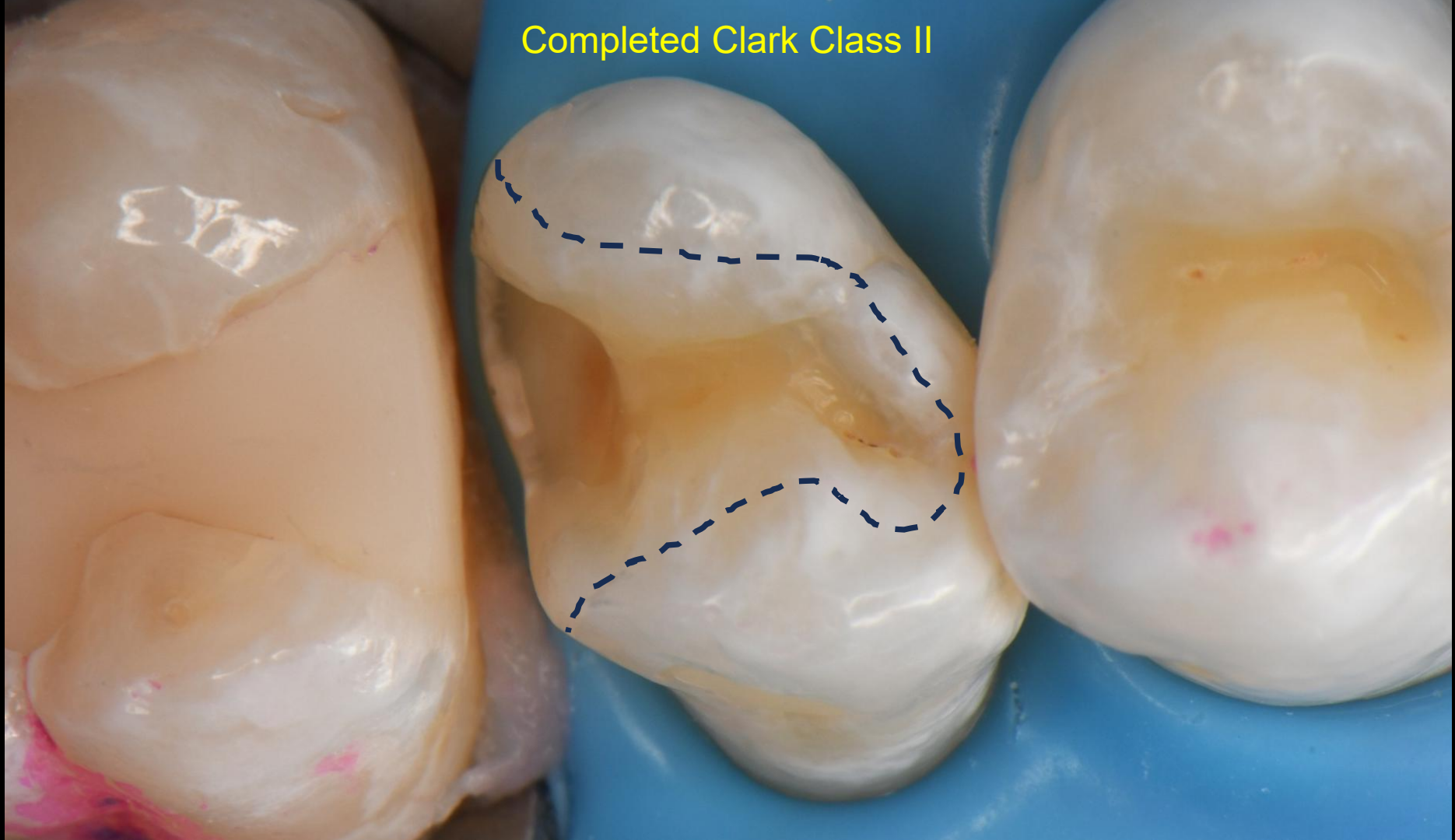


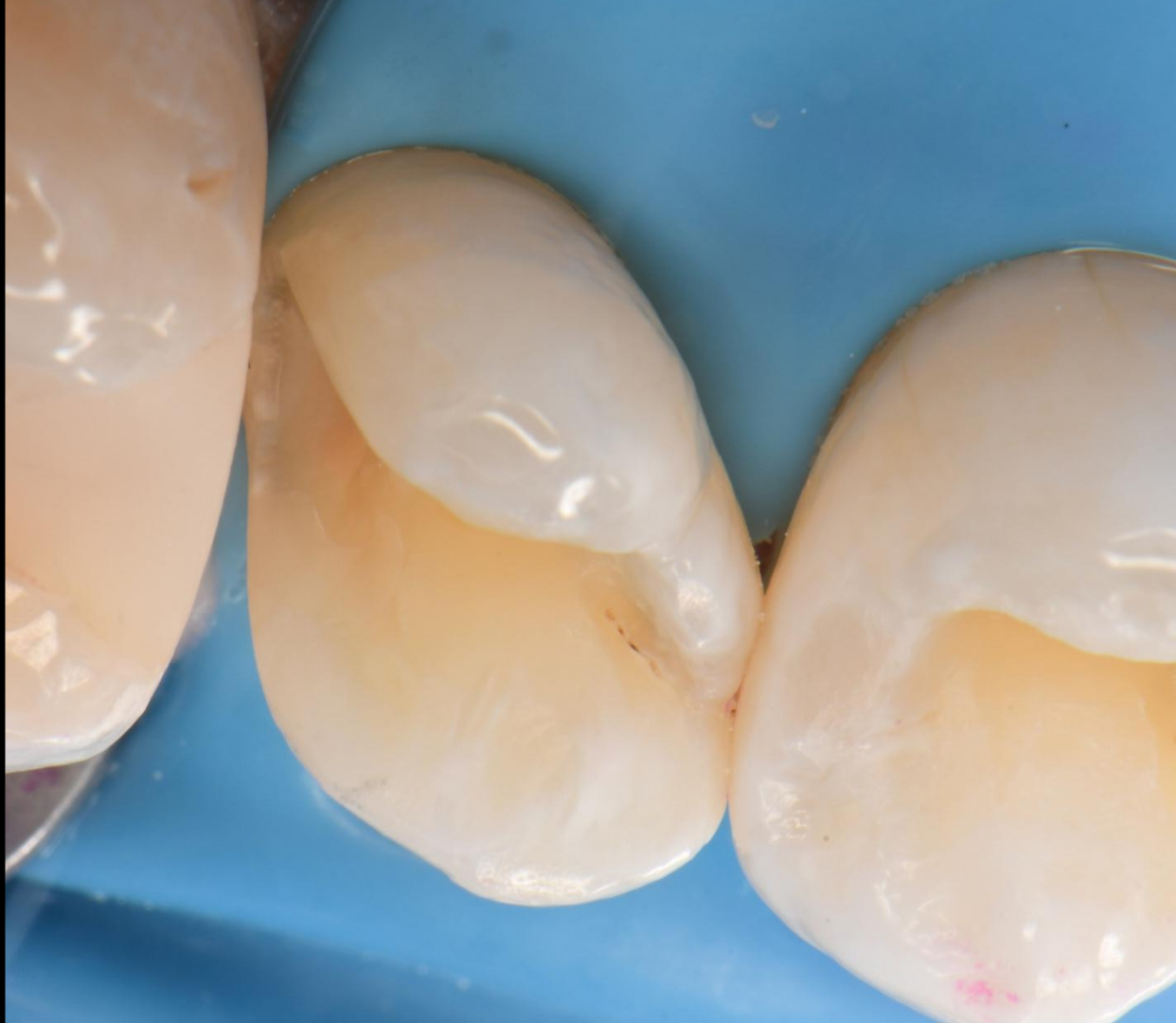




Completed Clark Class II

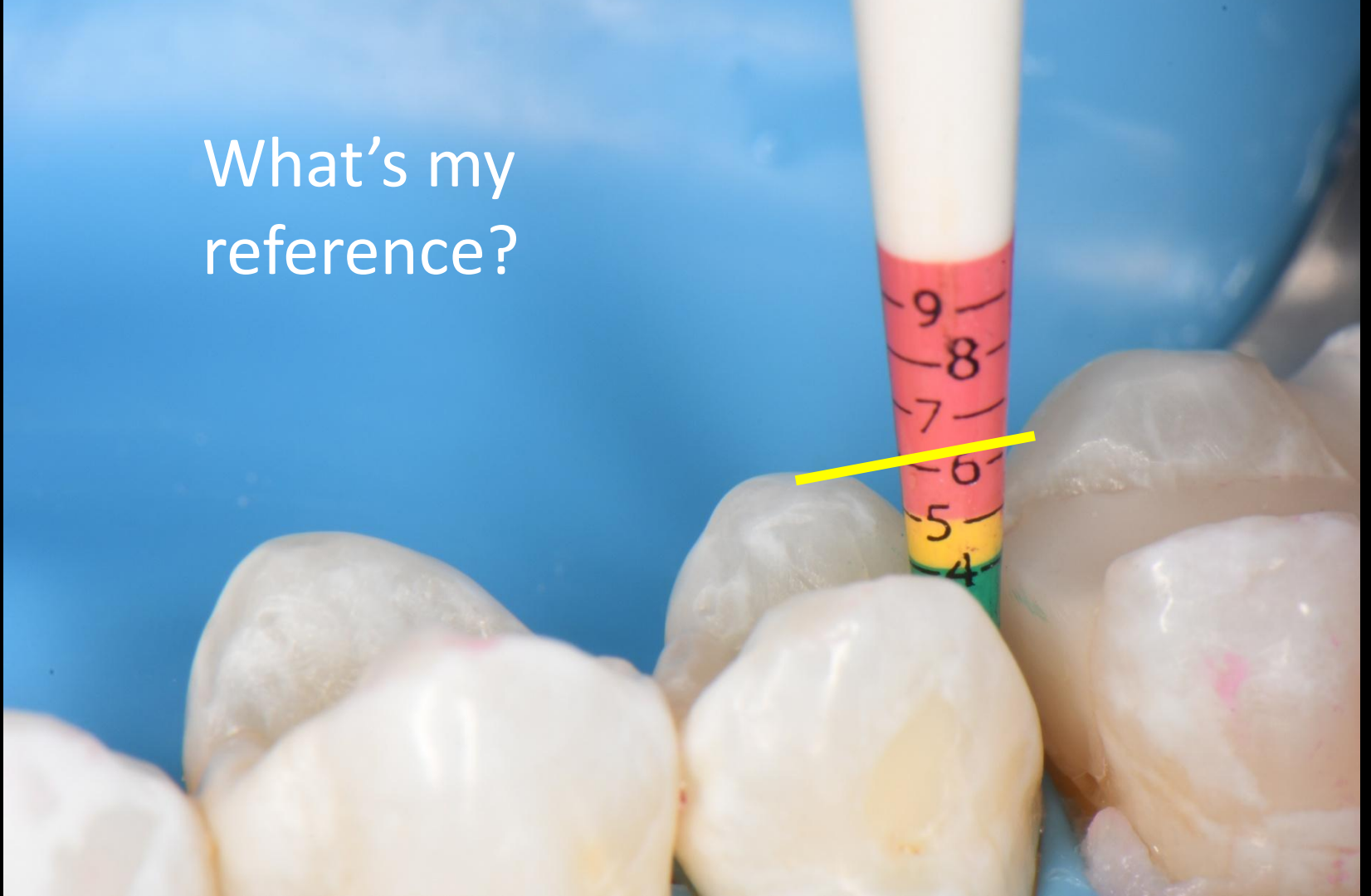


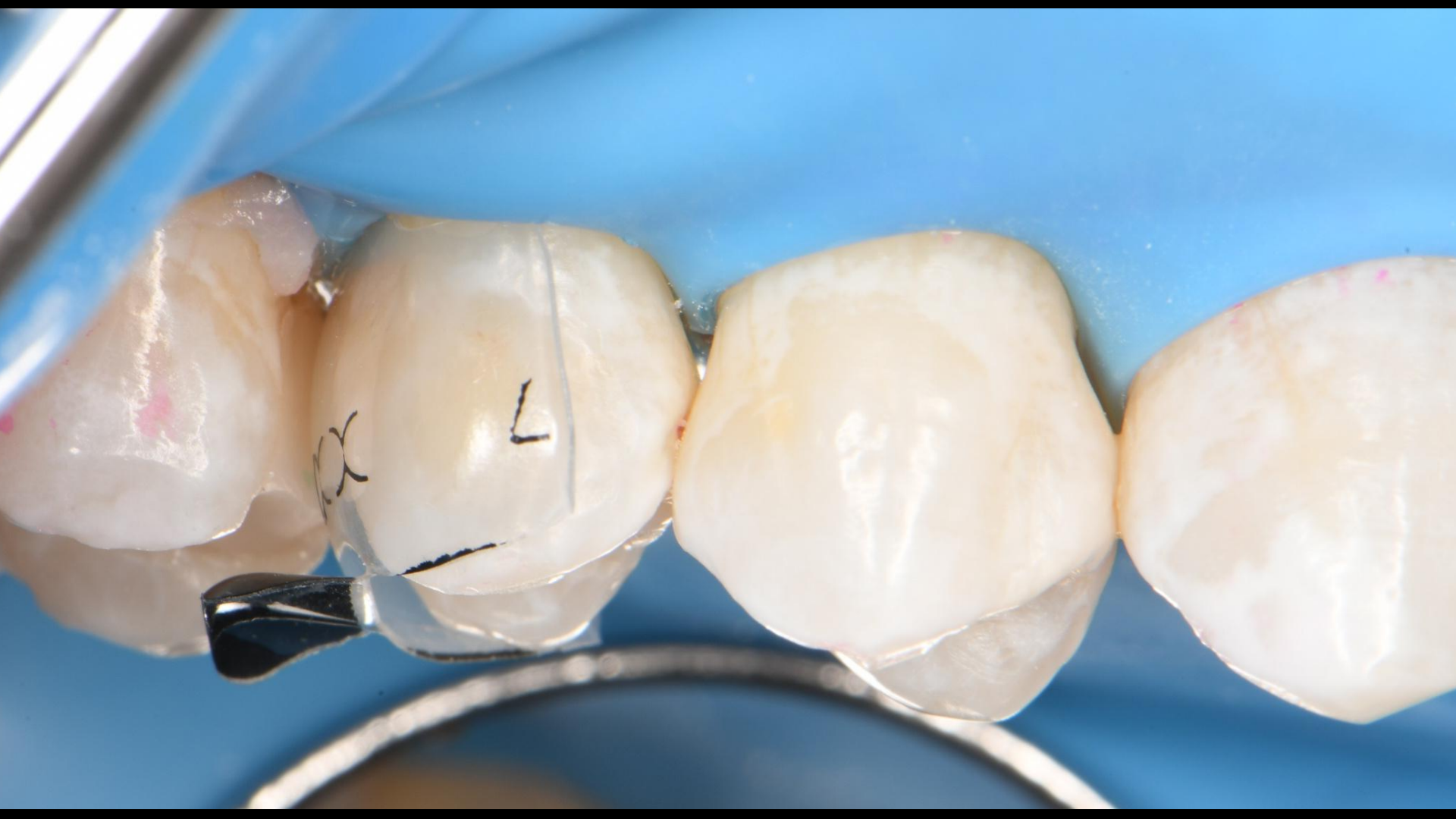
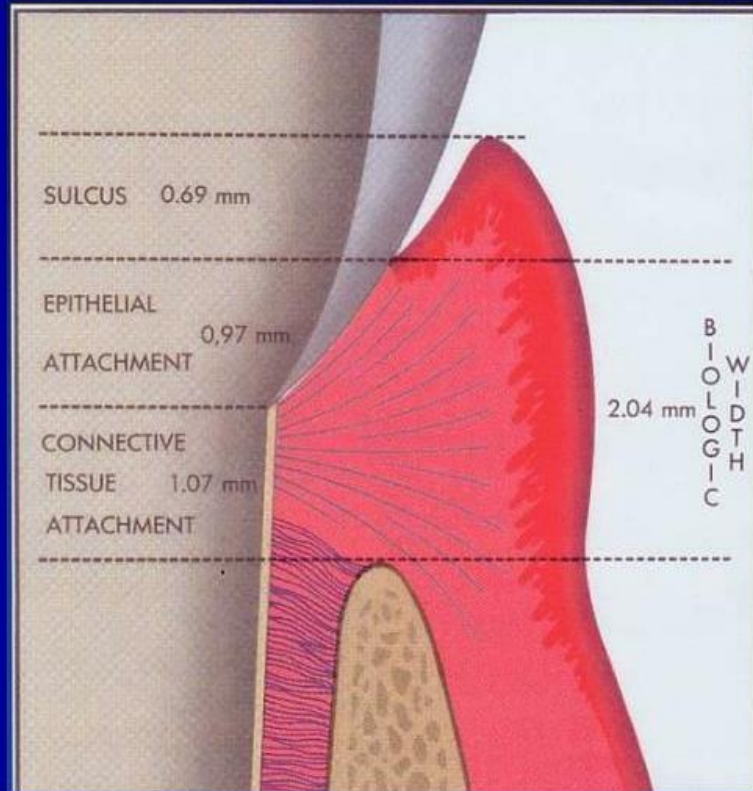
What's my
reference?

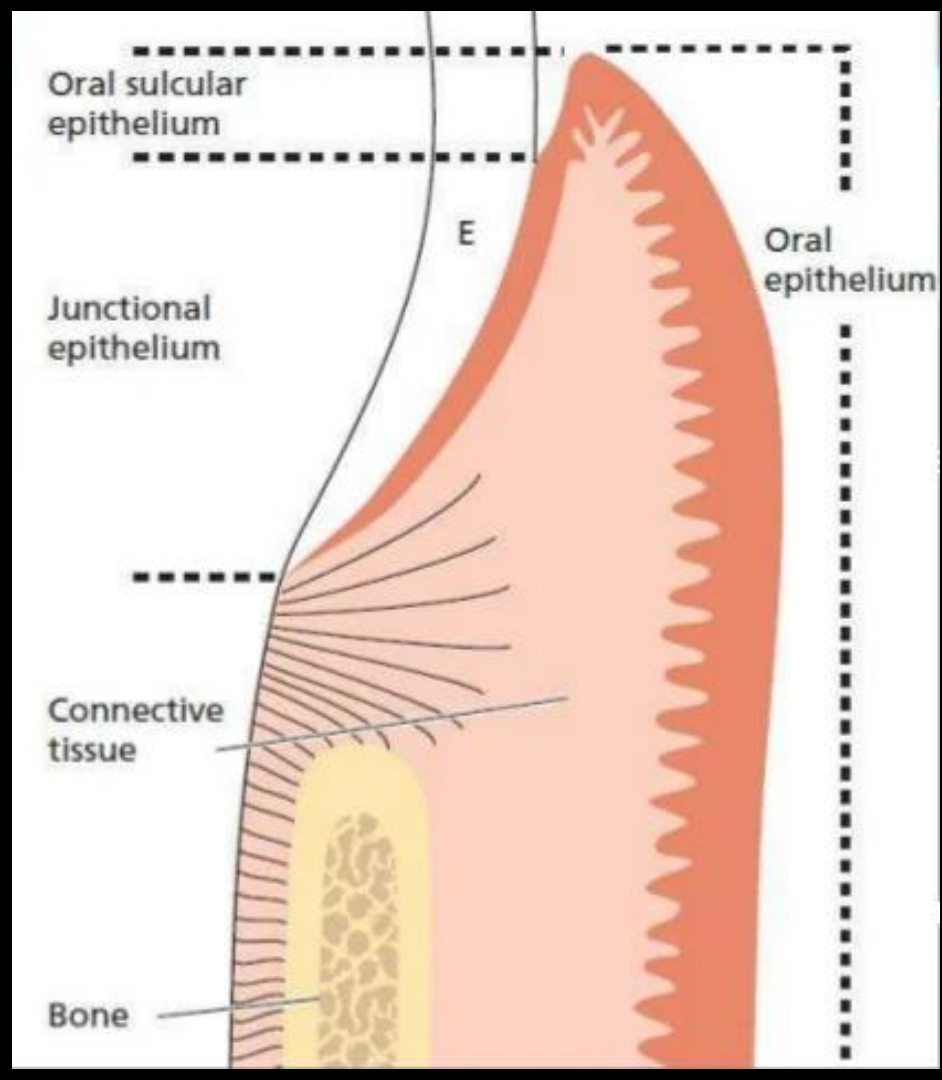
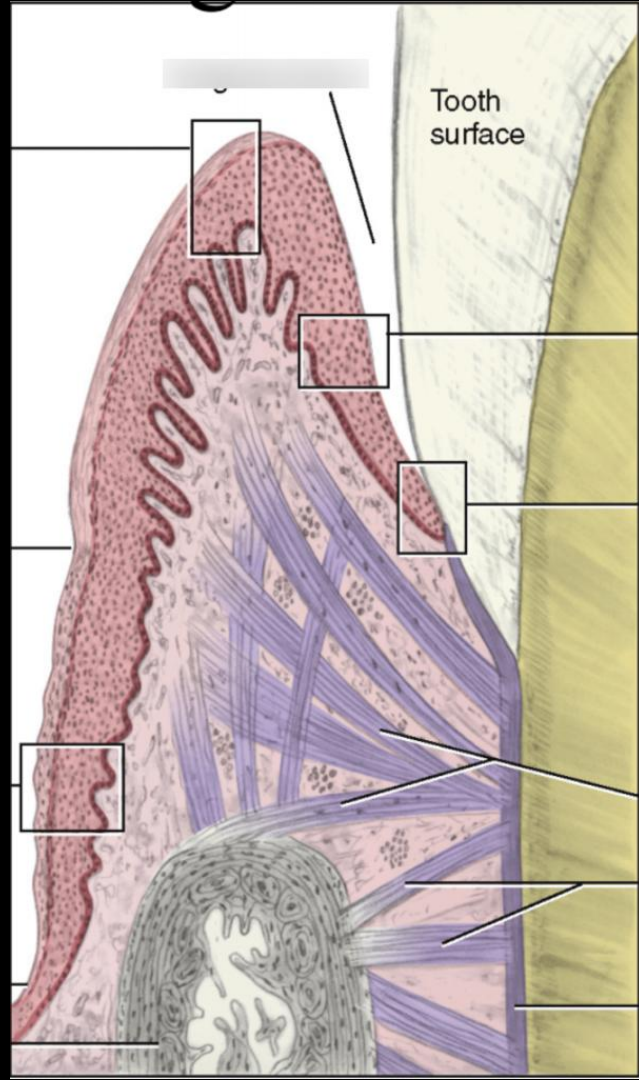


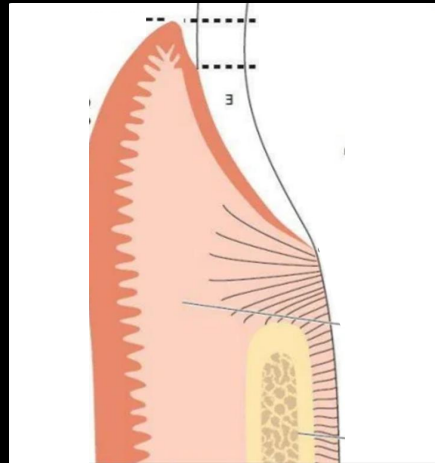
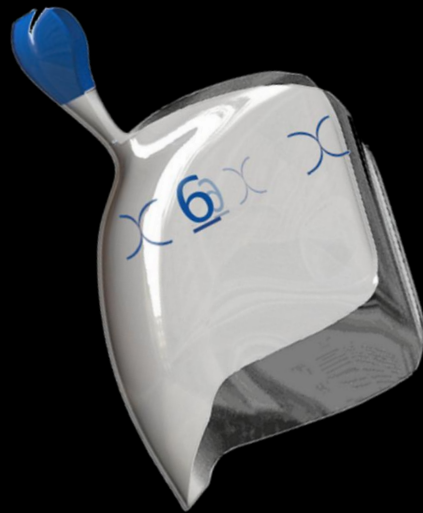What's my
reference?

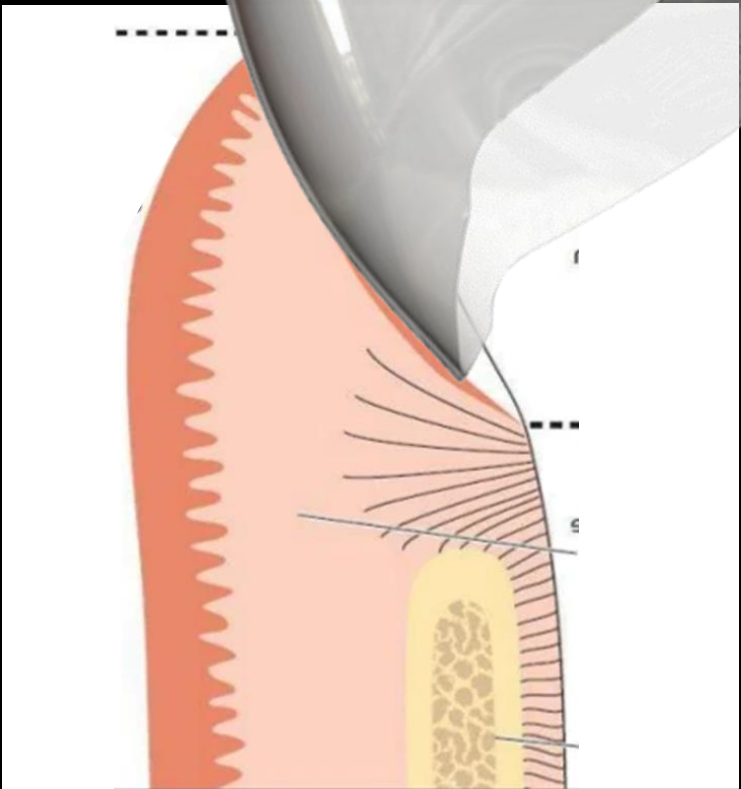


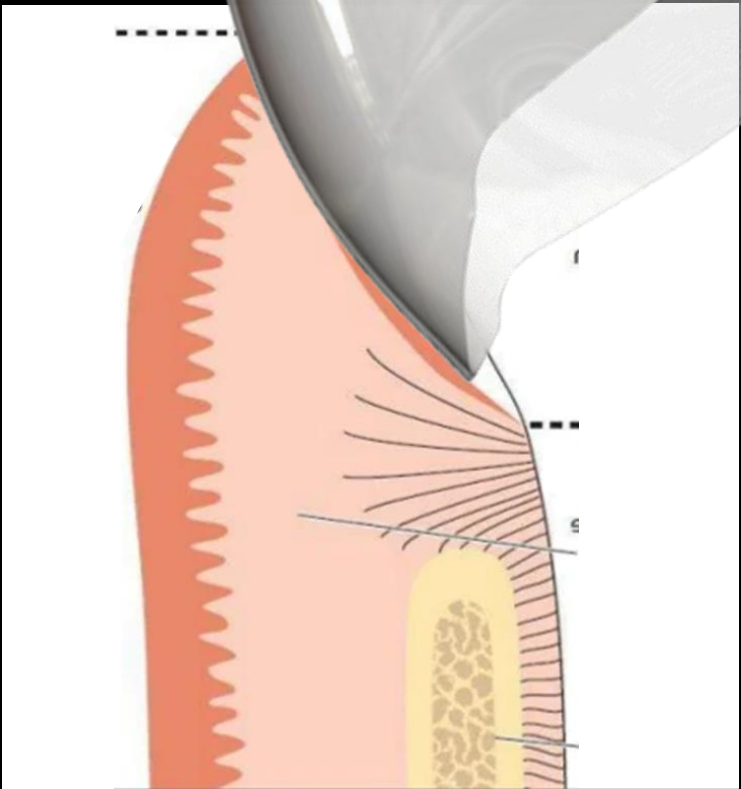


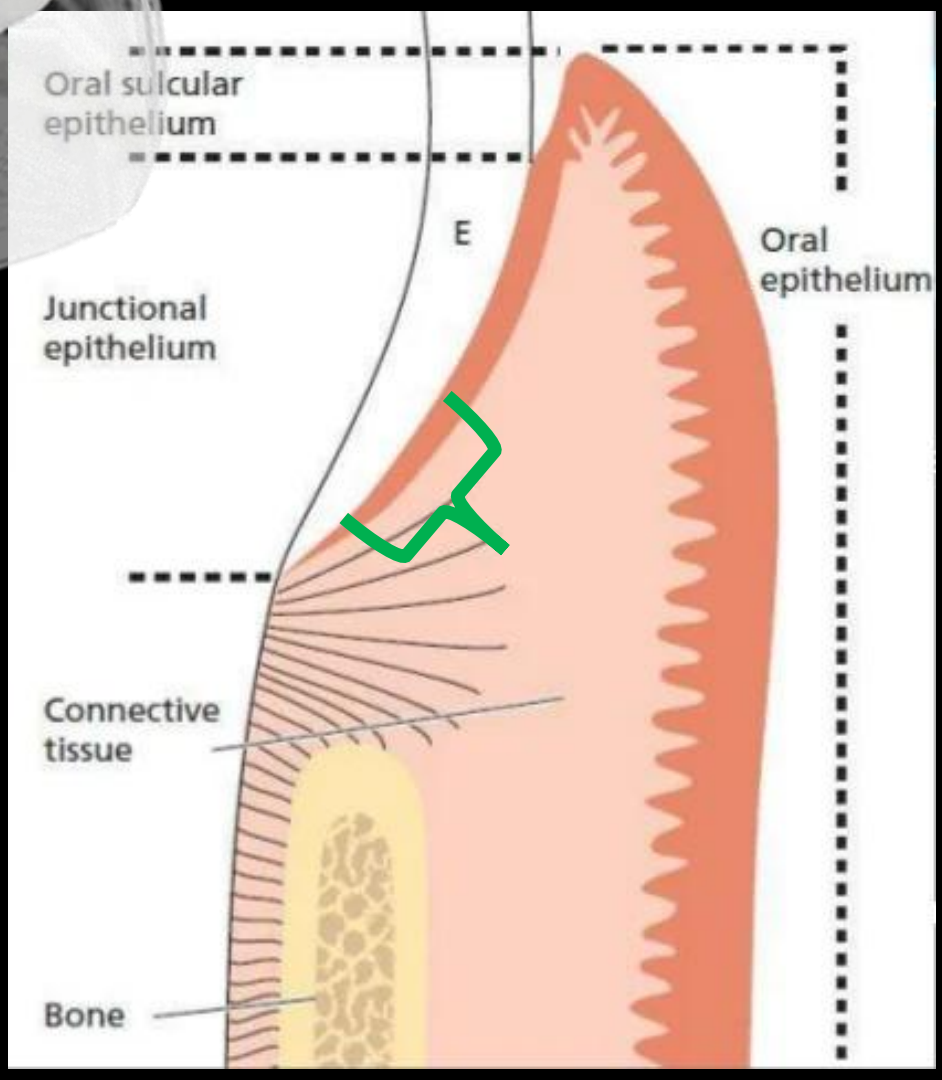
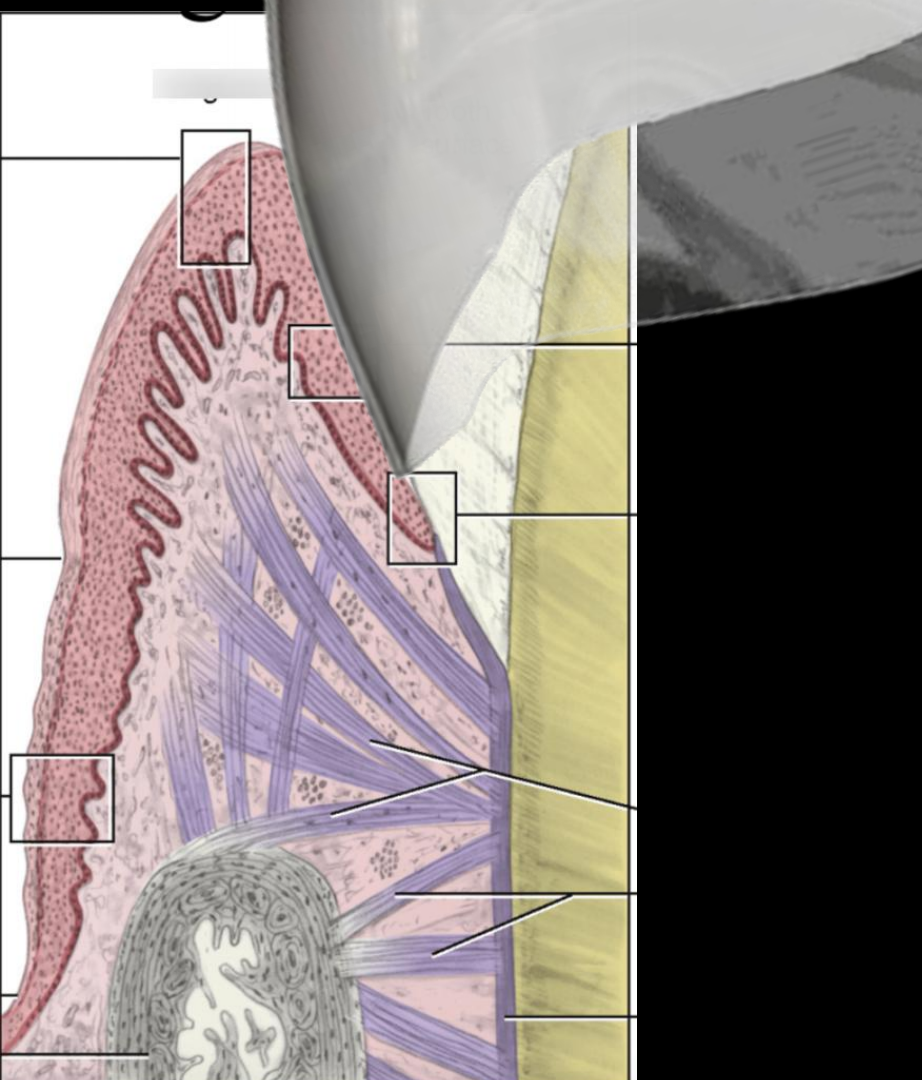


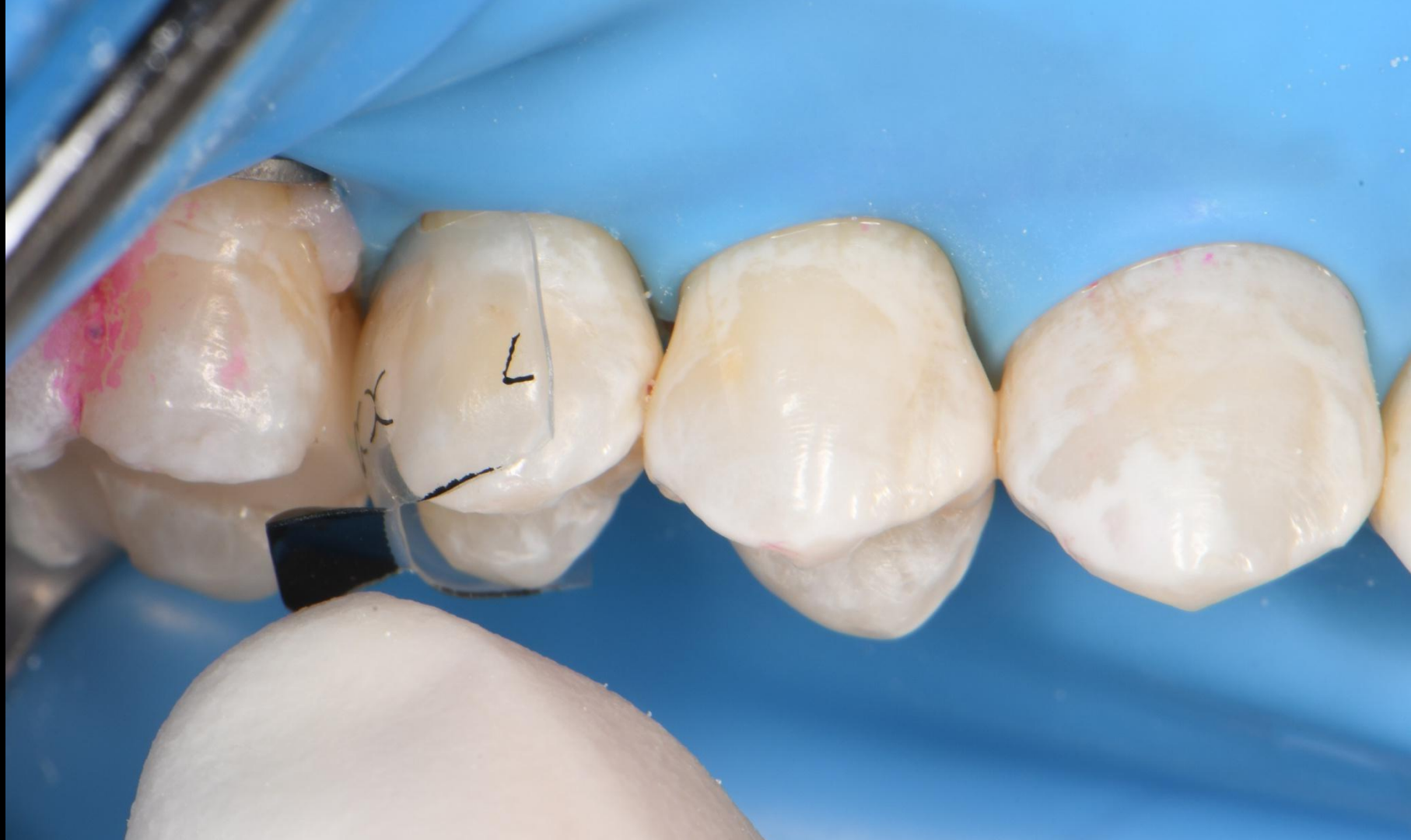


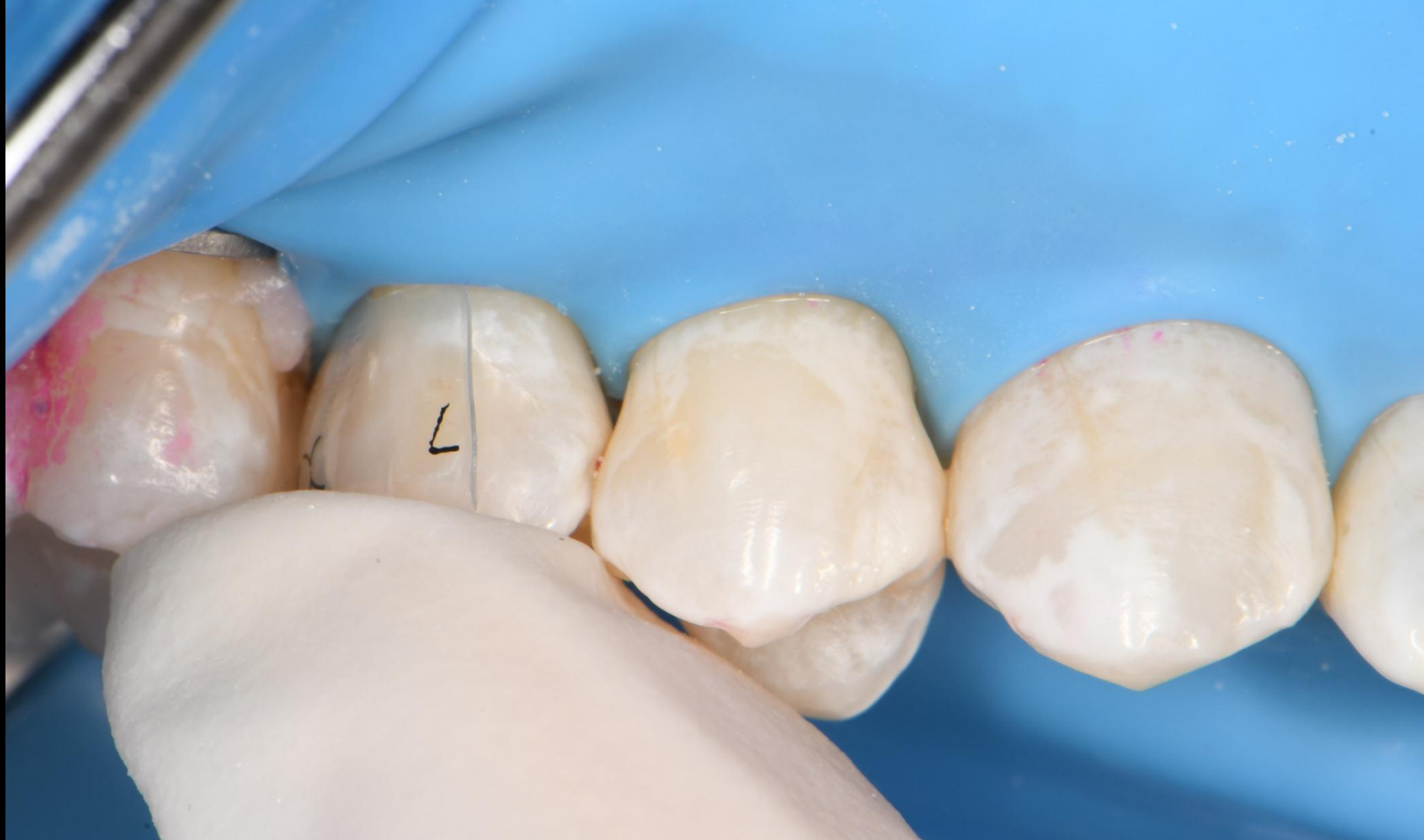


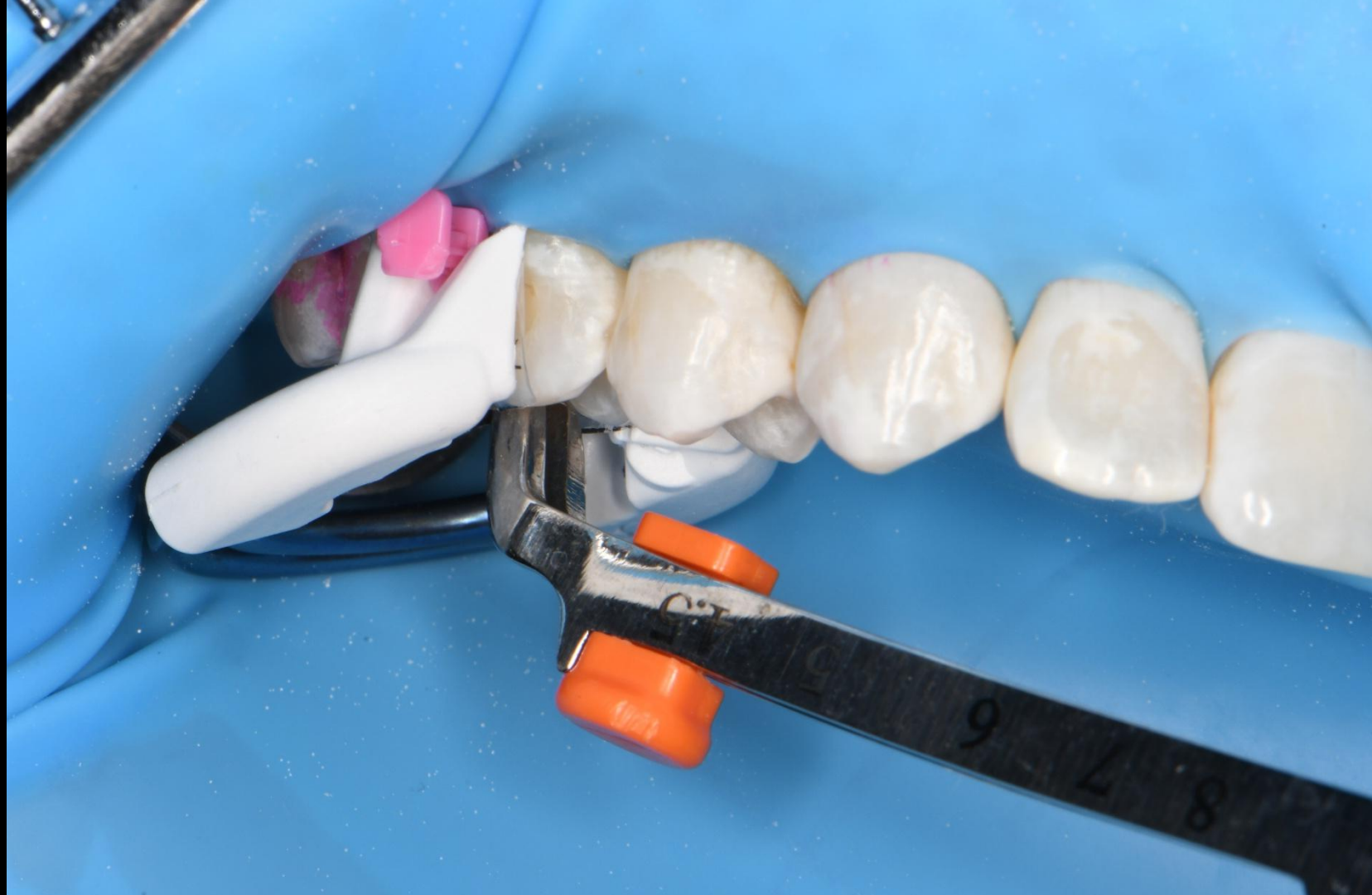


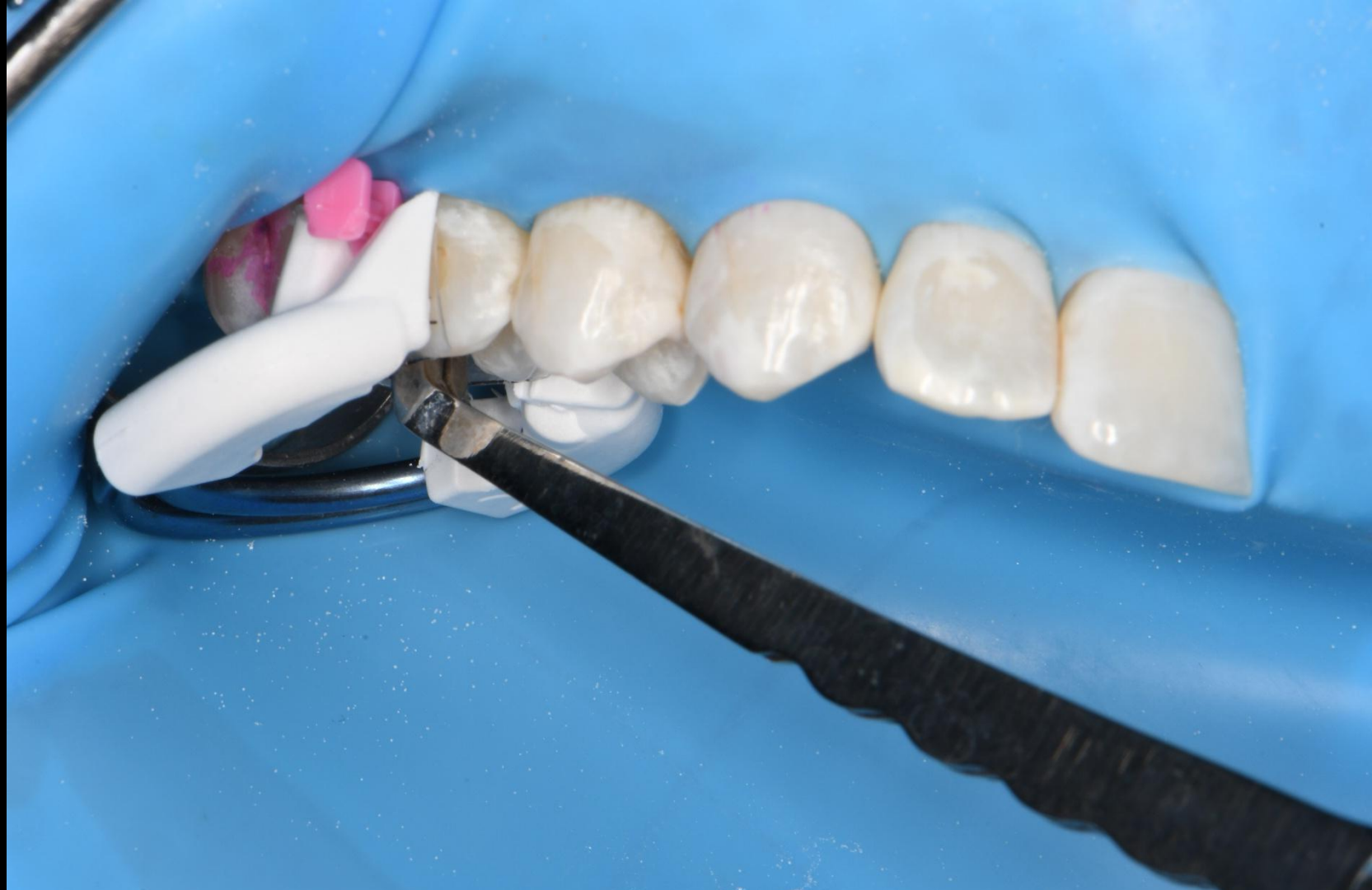
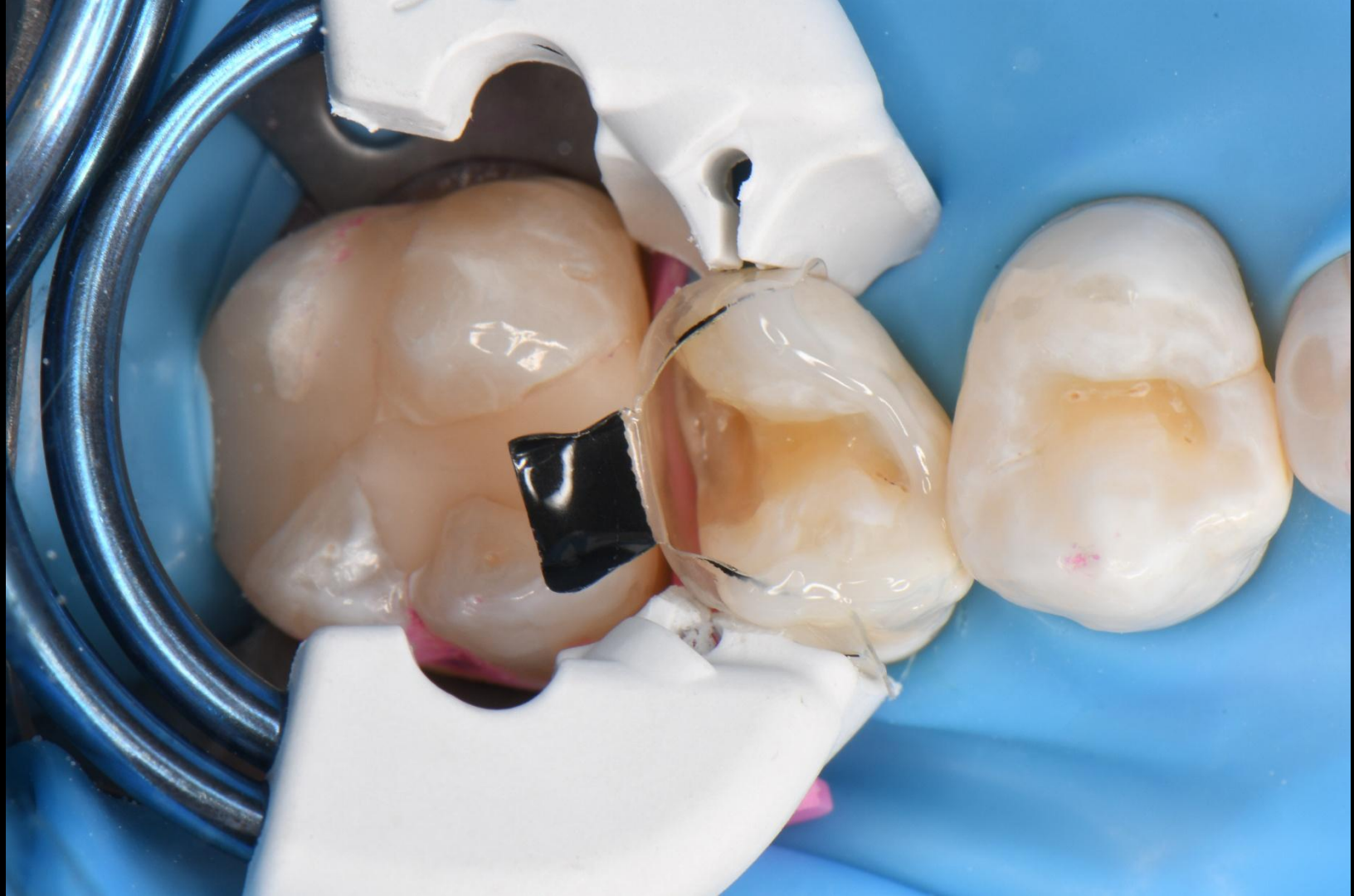


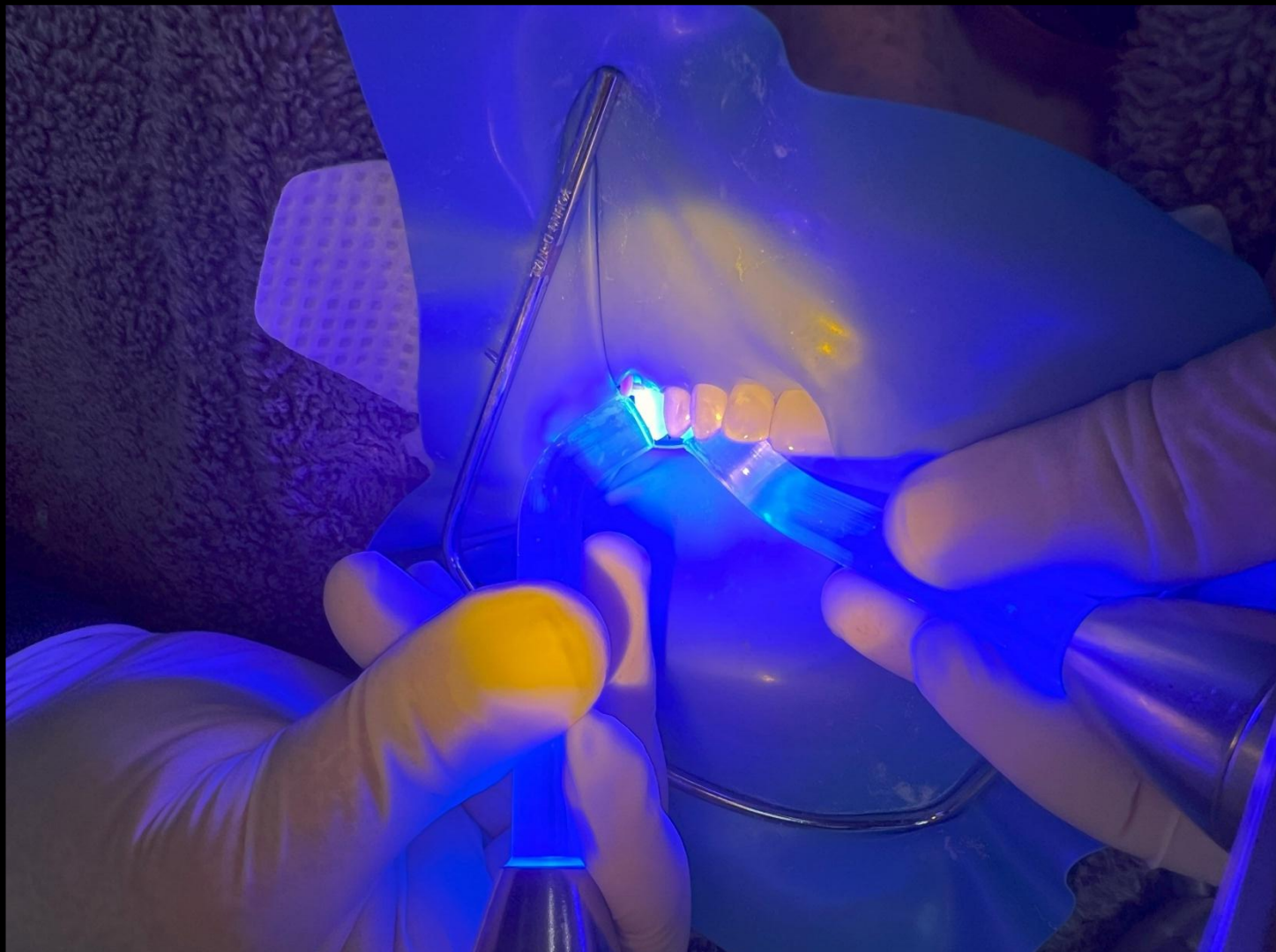






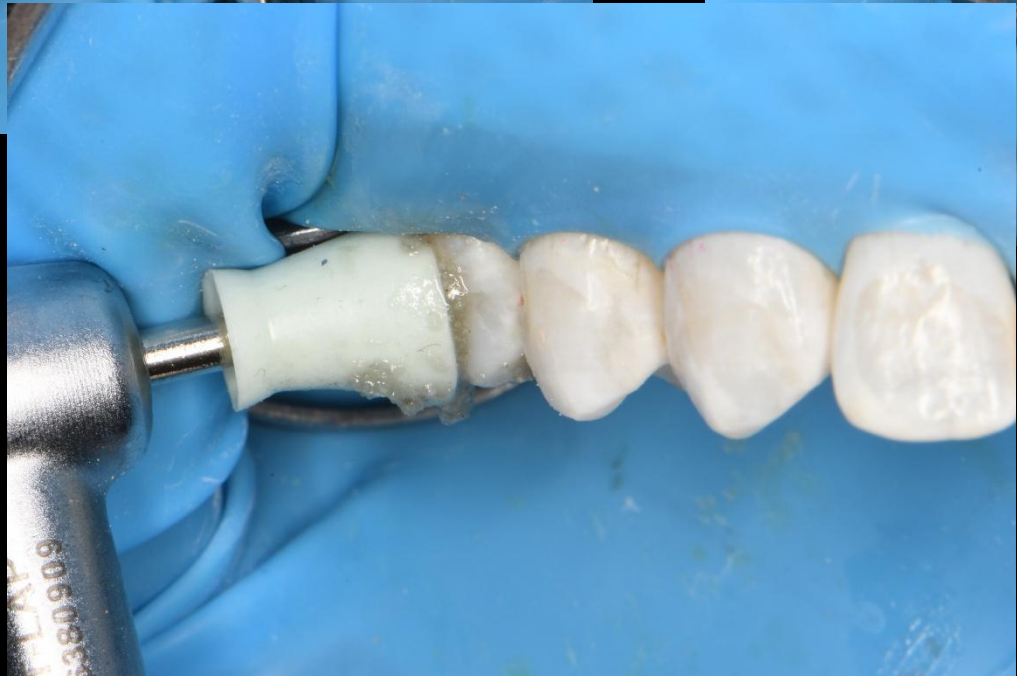
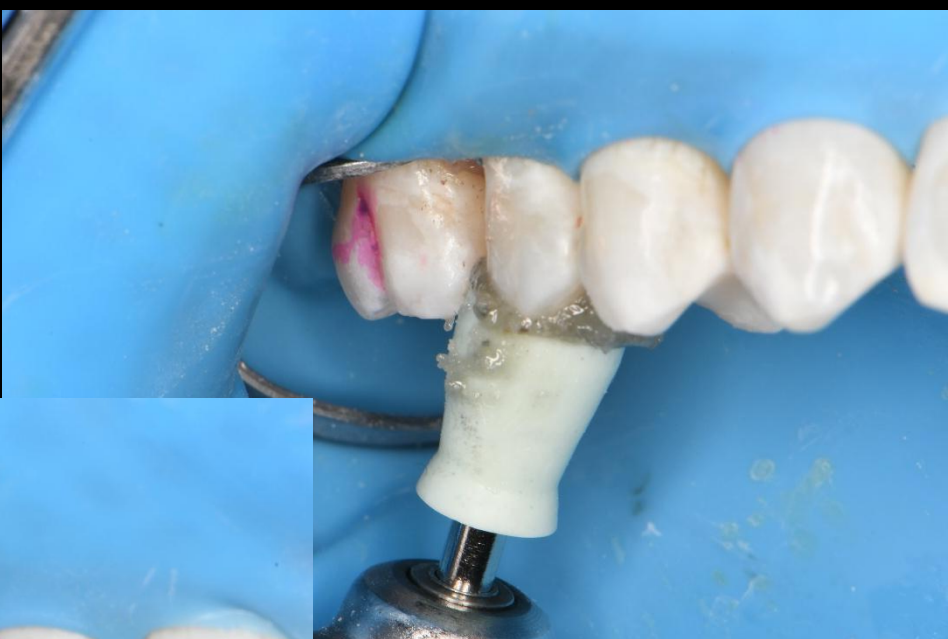
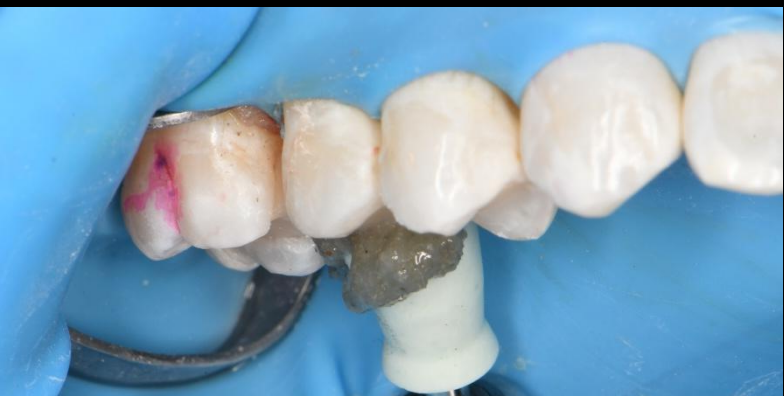


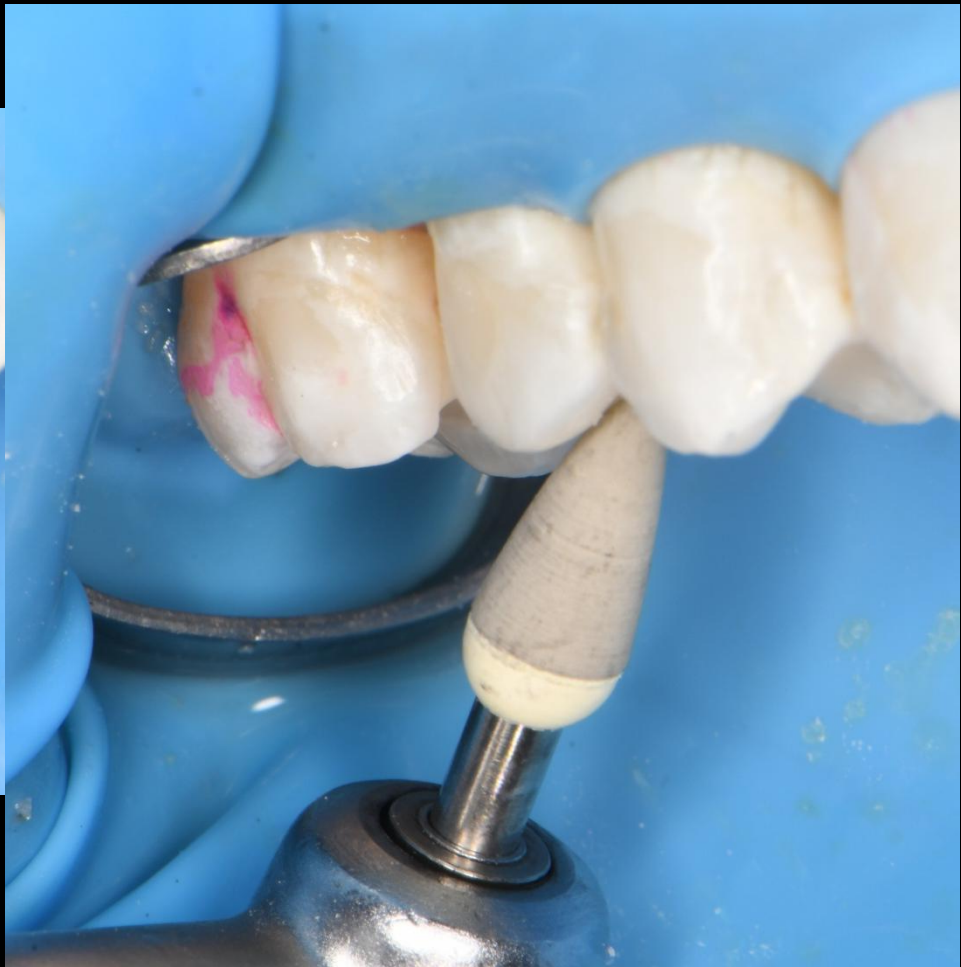
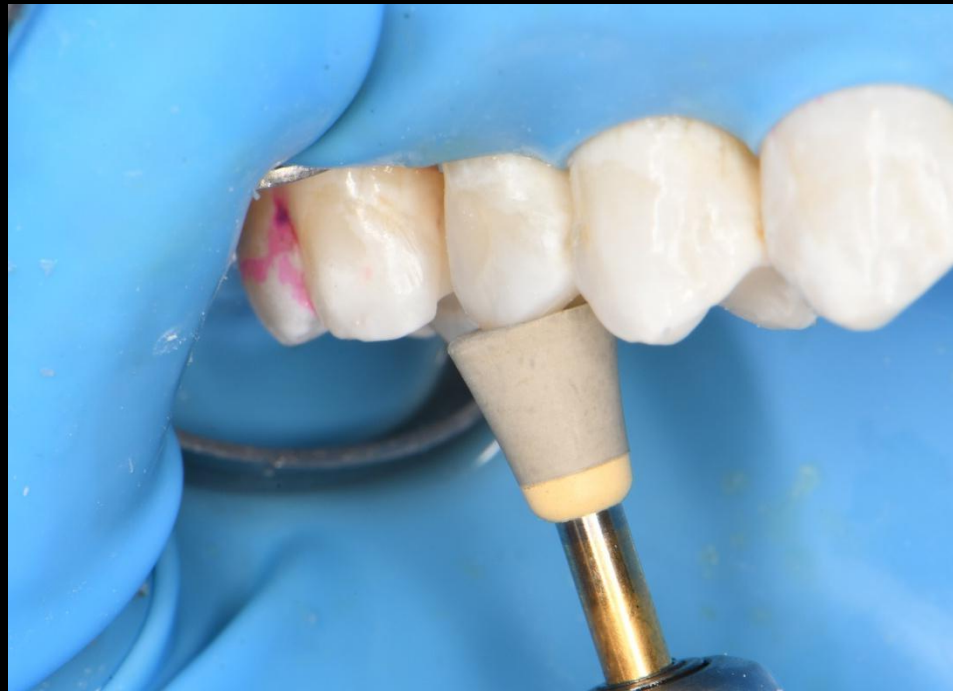


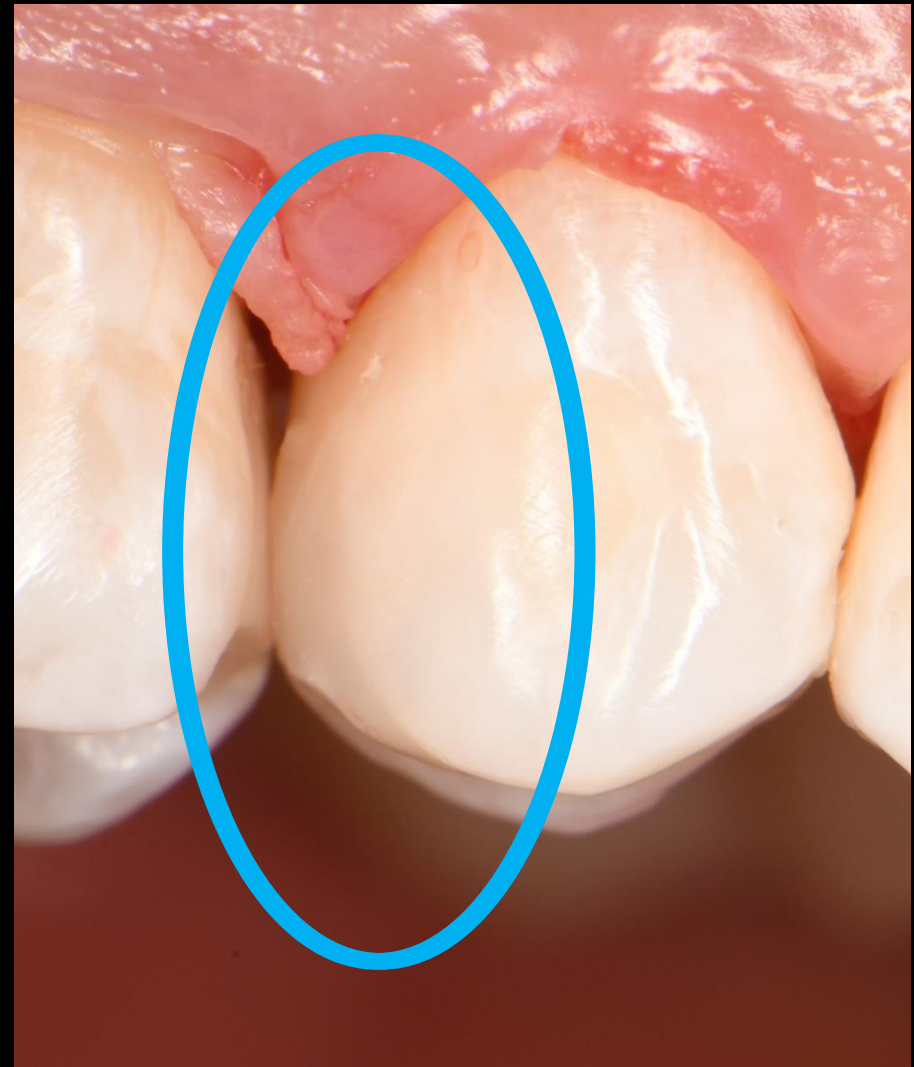
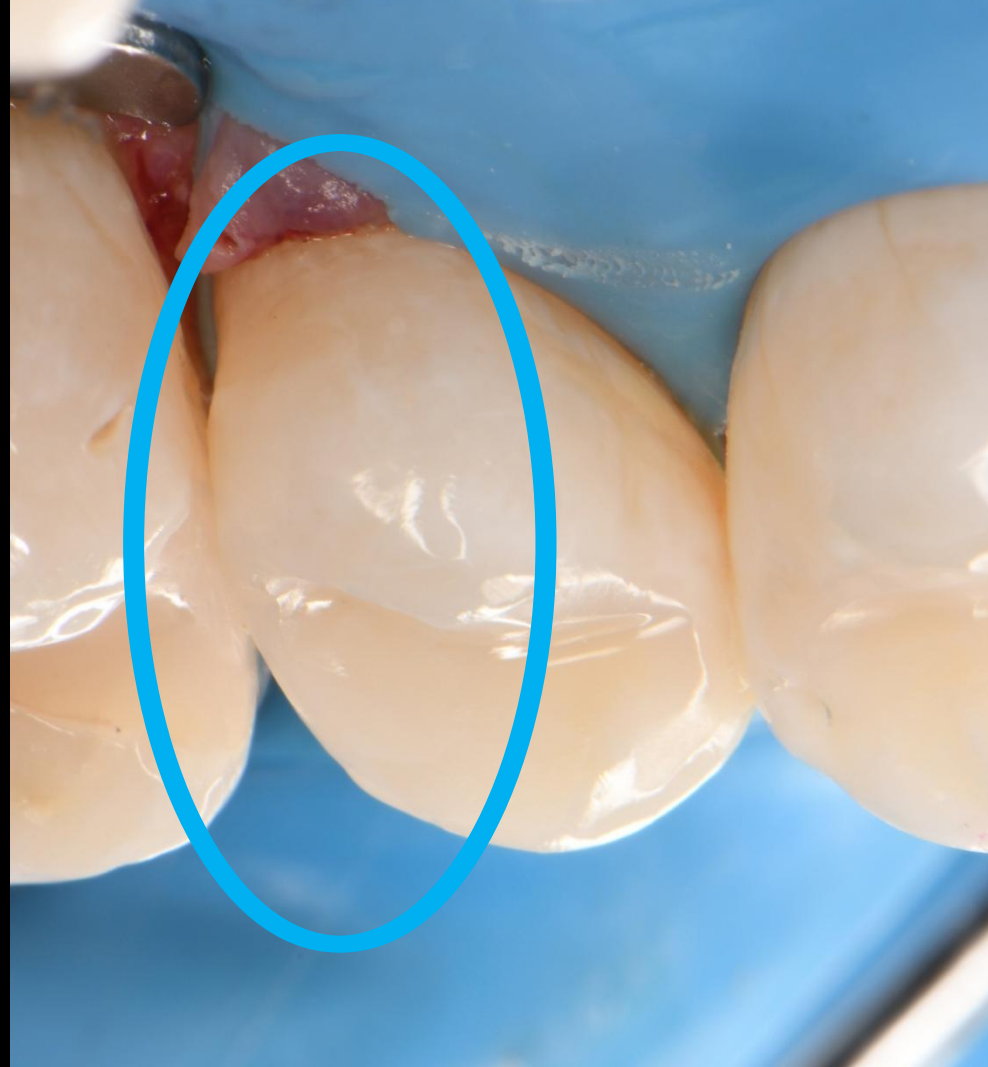


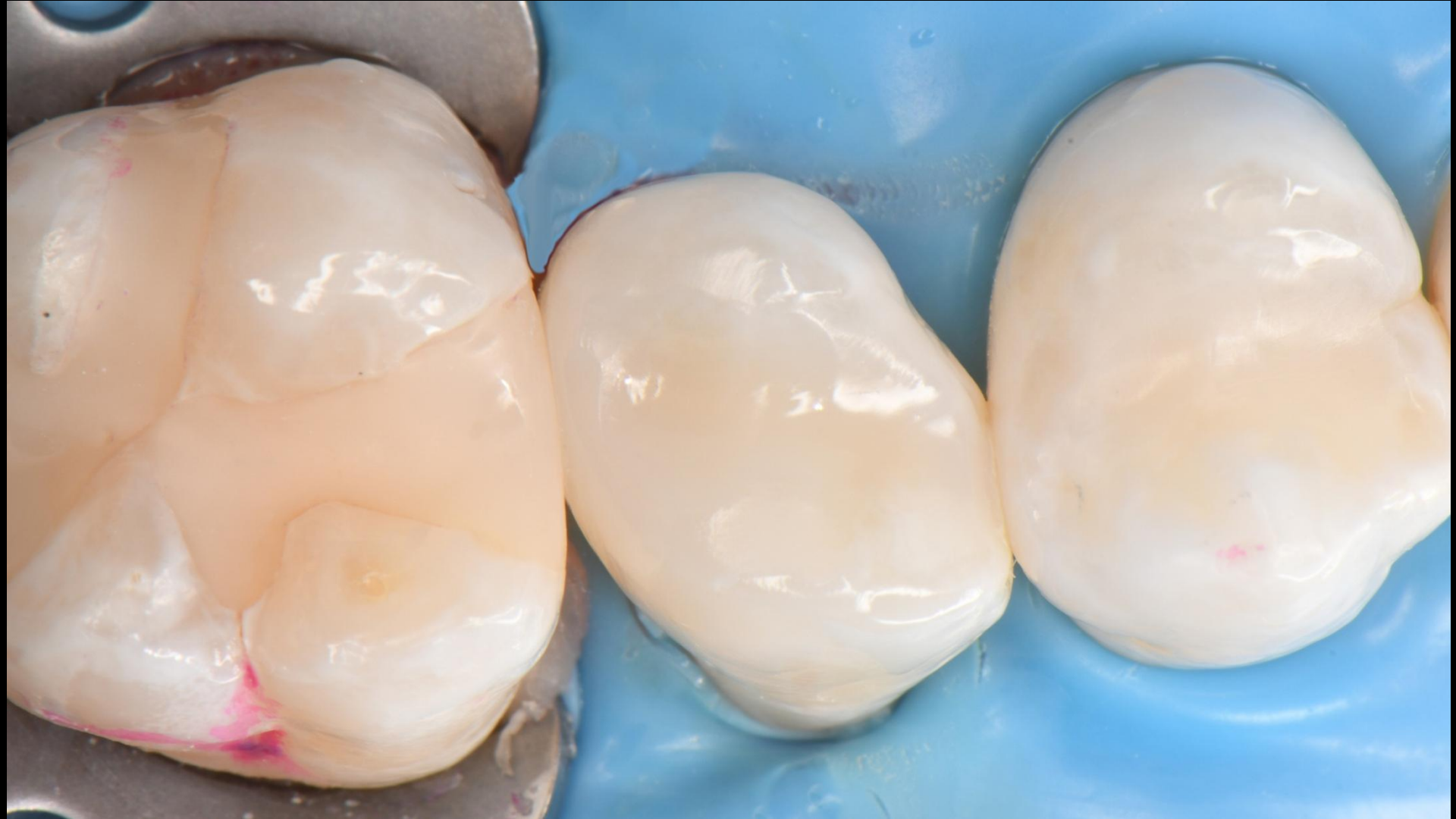
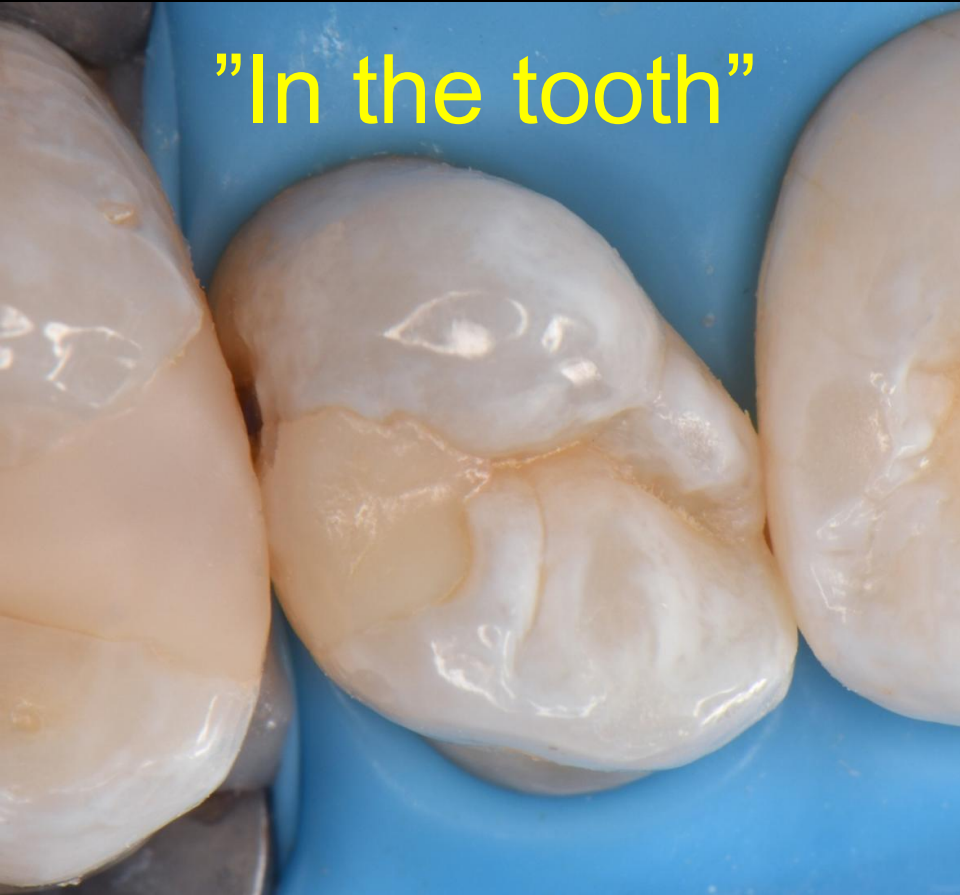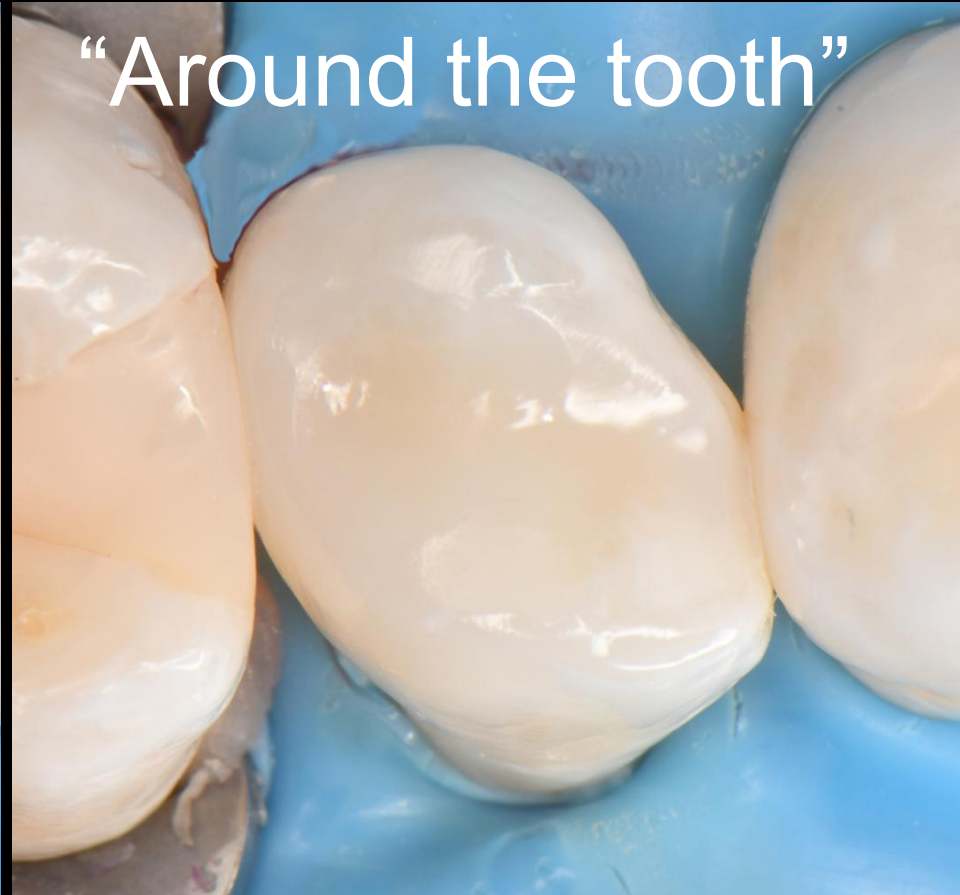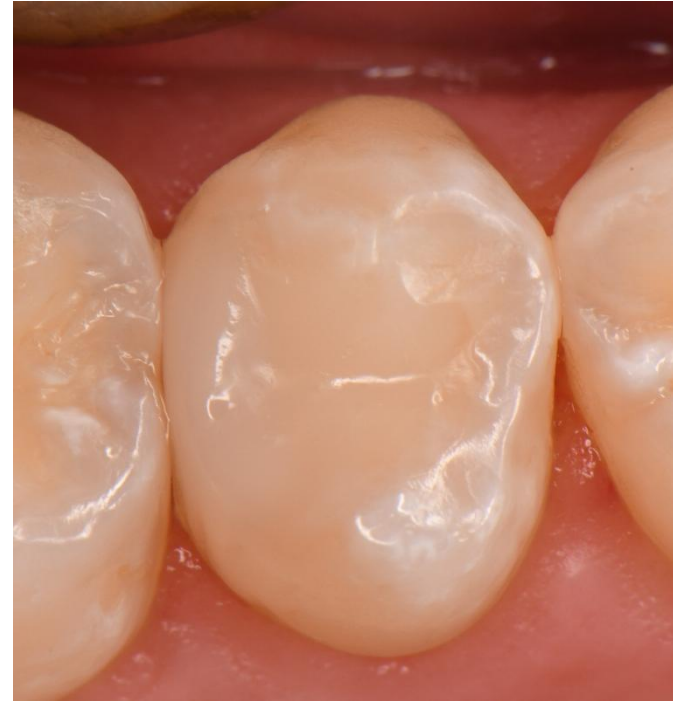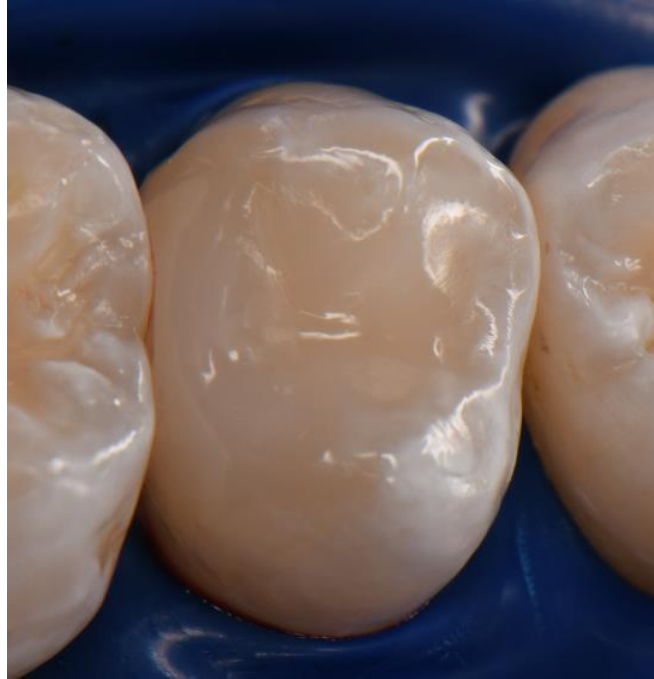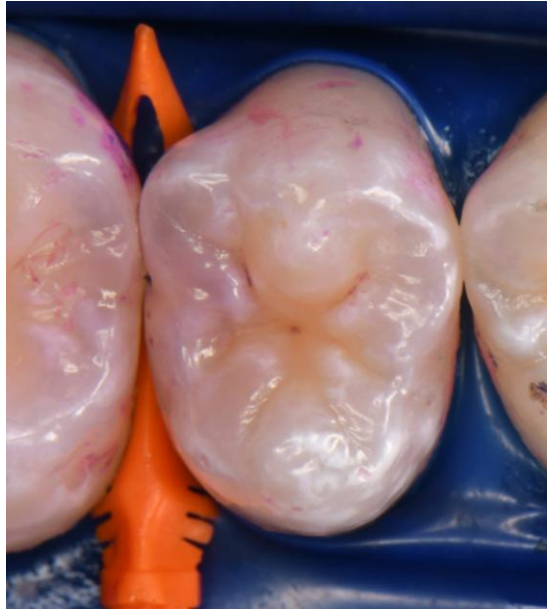"In the tooth"



"Around the tooth"



Similar Case: Pre-op, post op, and 3 year follow up



Monumental changes from 1890

- Adhesive Dentistry
- Engineering
- Fluoride
- Abundance of fermentable carbohydrates
- Doubling of average lifespan

Common Concerns with Posterior Composite Restorations

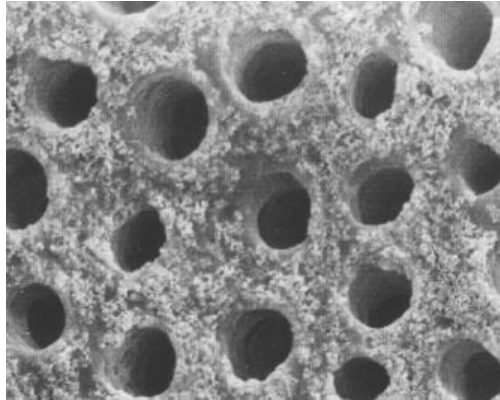
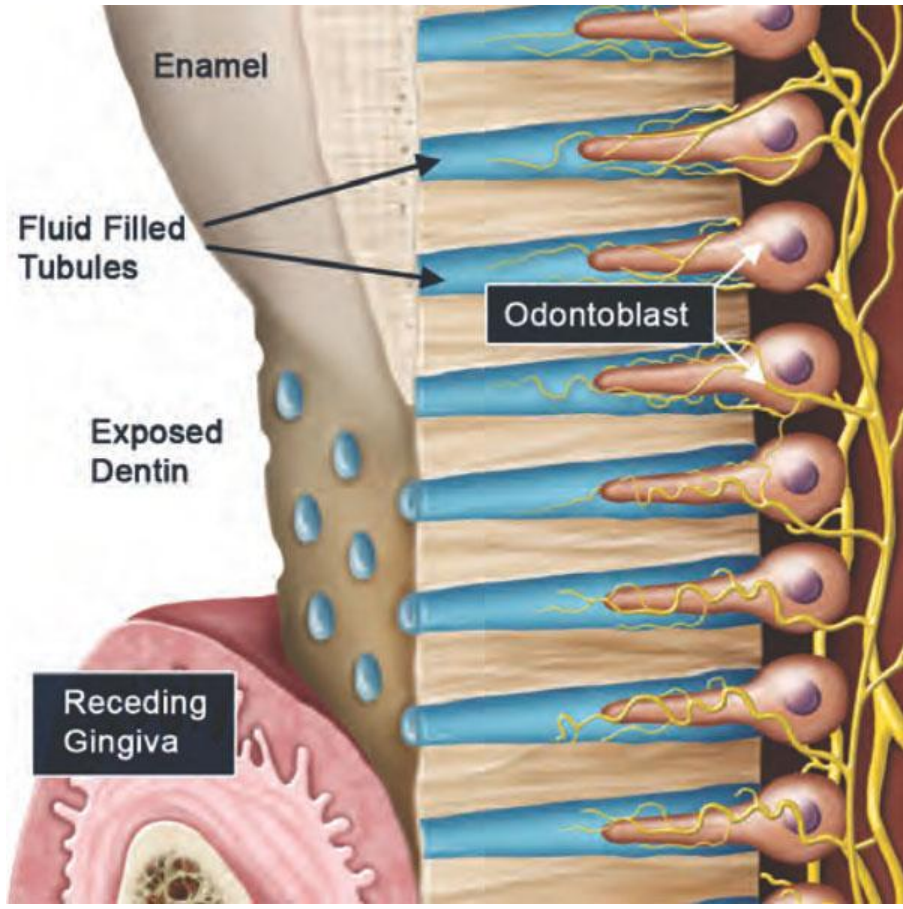
Longevity

Posterior composites in one study showed a
350% higher failure rate than did
amalgam restorations

(2.4 years longevity versus 8.9 years for amalgam)

Palotie U, Vehkalahti M. Acta Odontol Scand. 2002 Dec;60(6):325-9. Reasons for replacement and the age of failed restorations in posterior teeth of young Finnish adults.

Epidemic of Sensitivity



Contact Issues

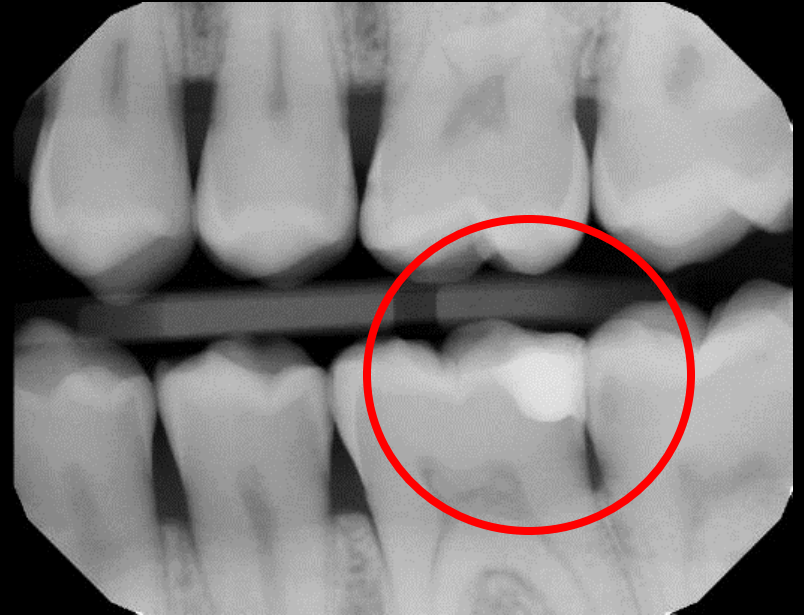
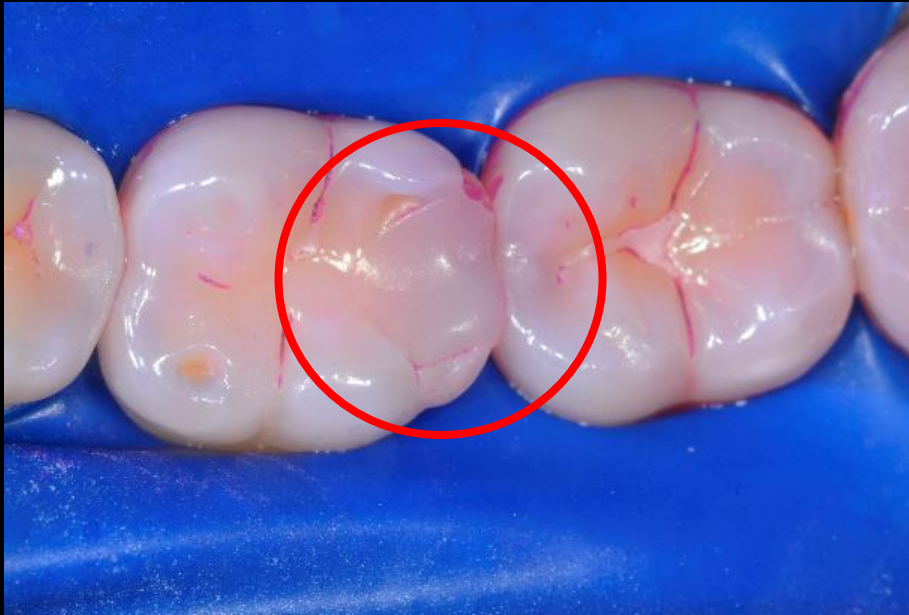Point contacts

Burnished contacts

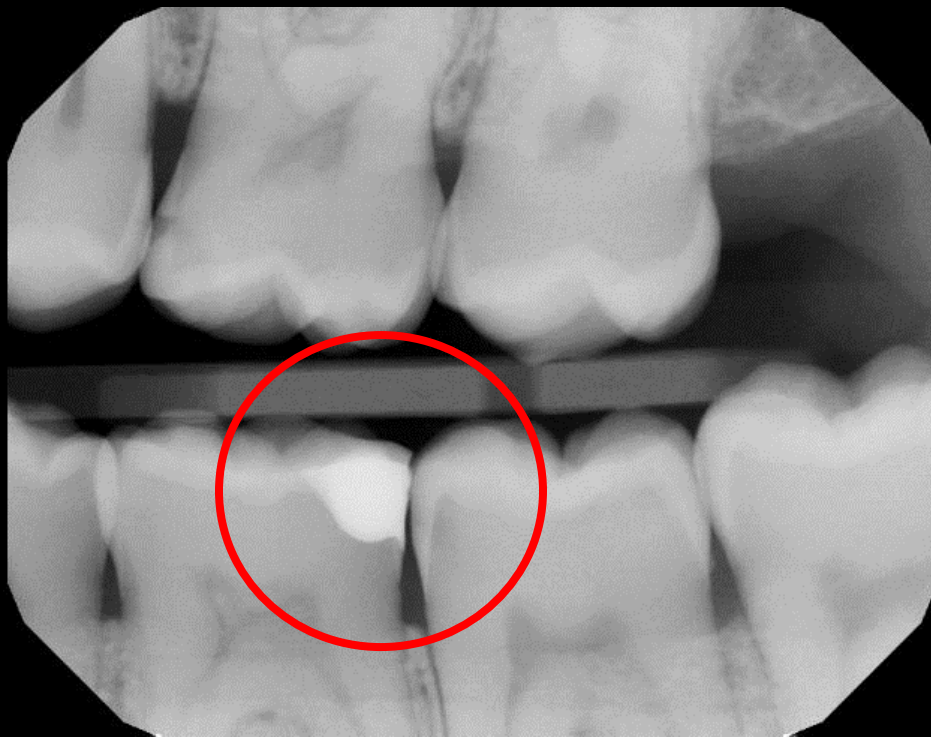
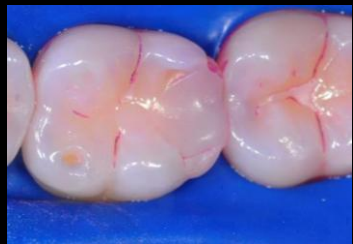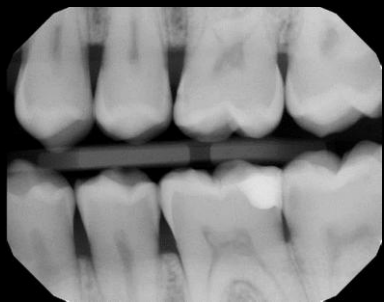Open contacts

Overhangs

Contact Issues

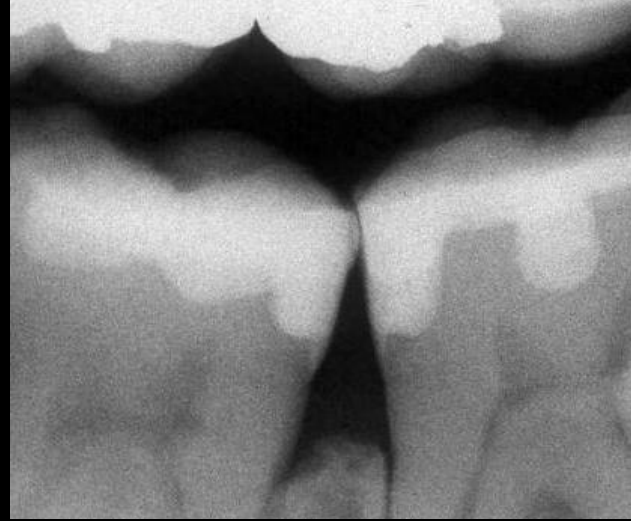
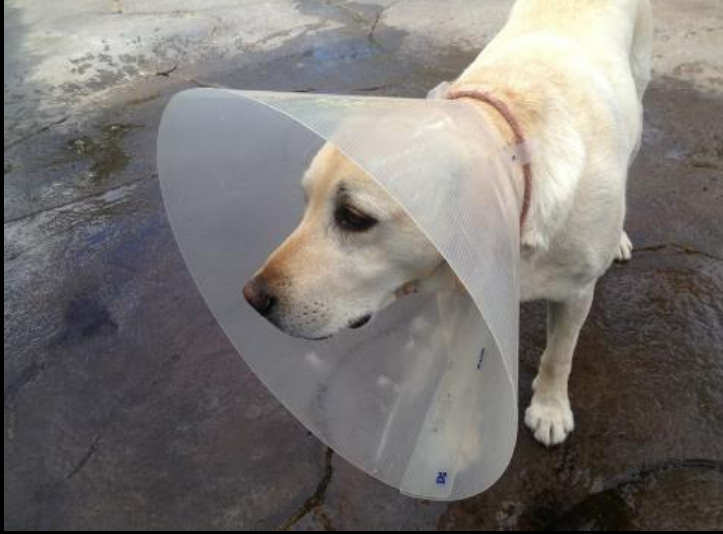
Contact Issues

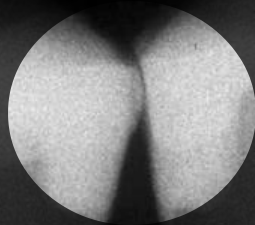

Amalgam based matrix





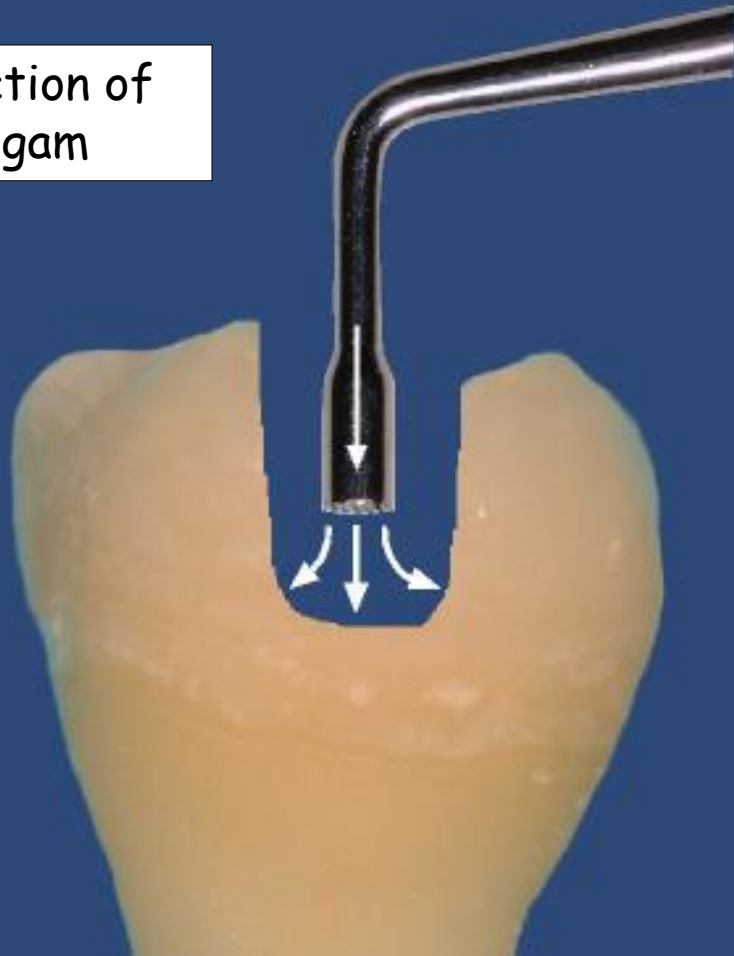
“cone of shame”-Amalgam based matrix



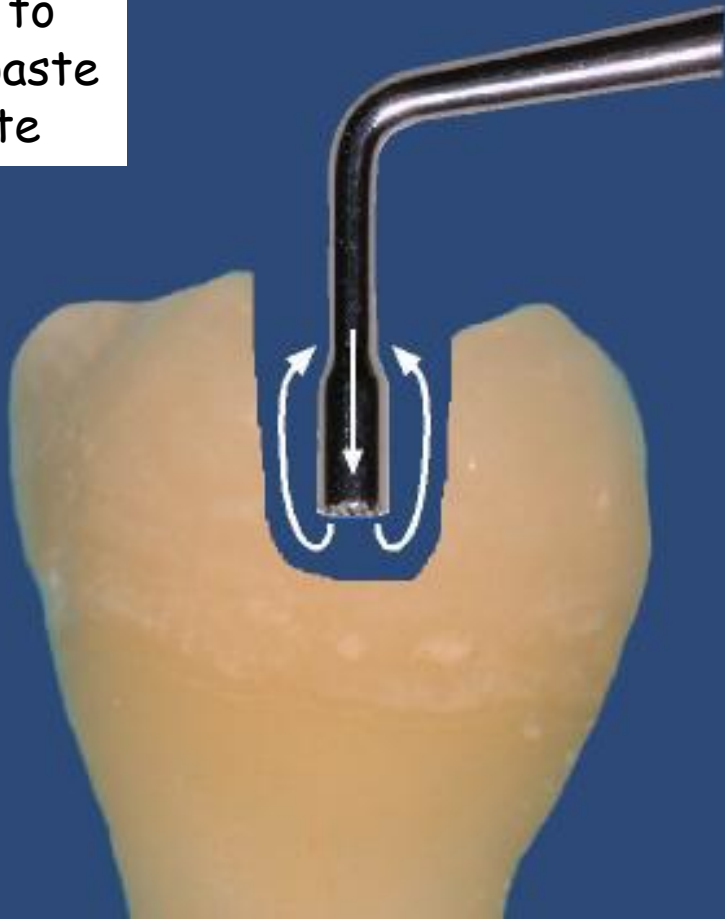
The S.K.K. or...
Silly Kissy
Contact

Why?

Compaction of
amalgam

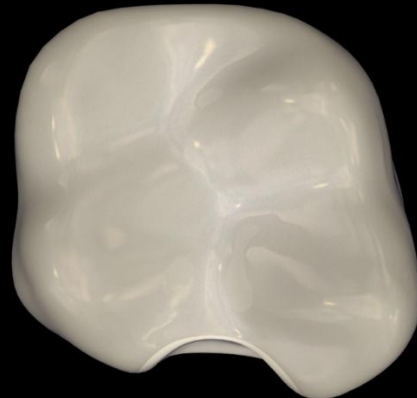
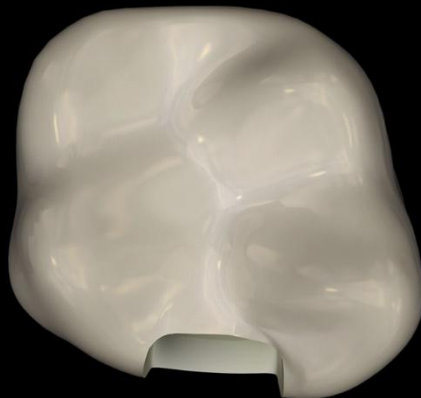
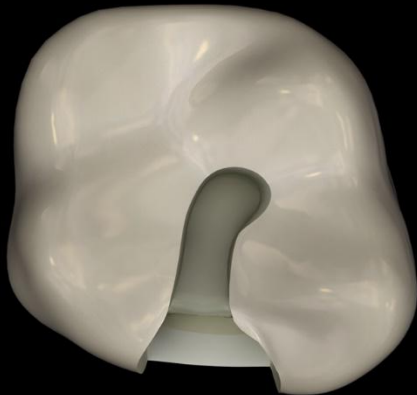
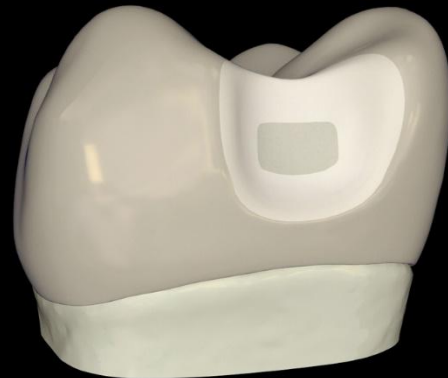
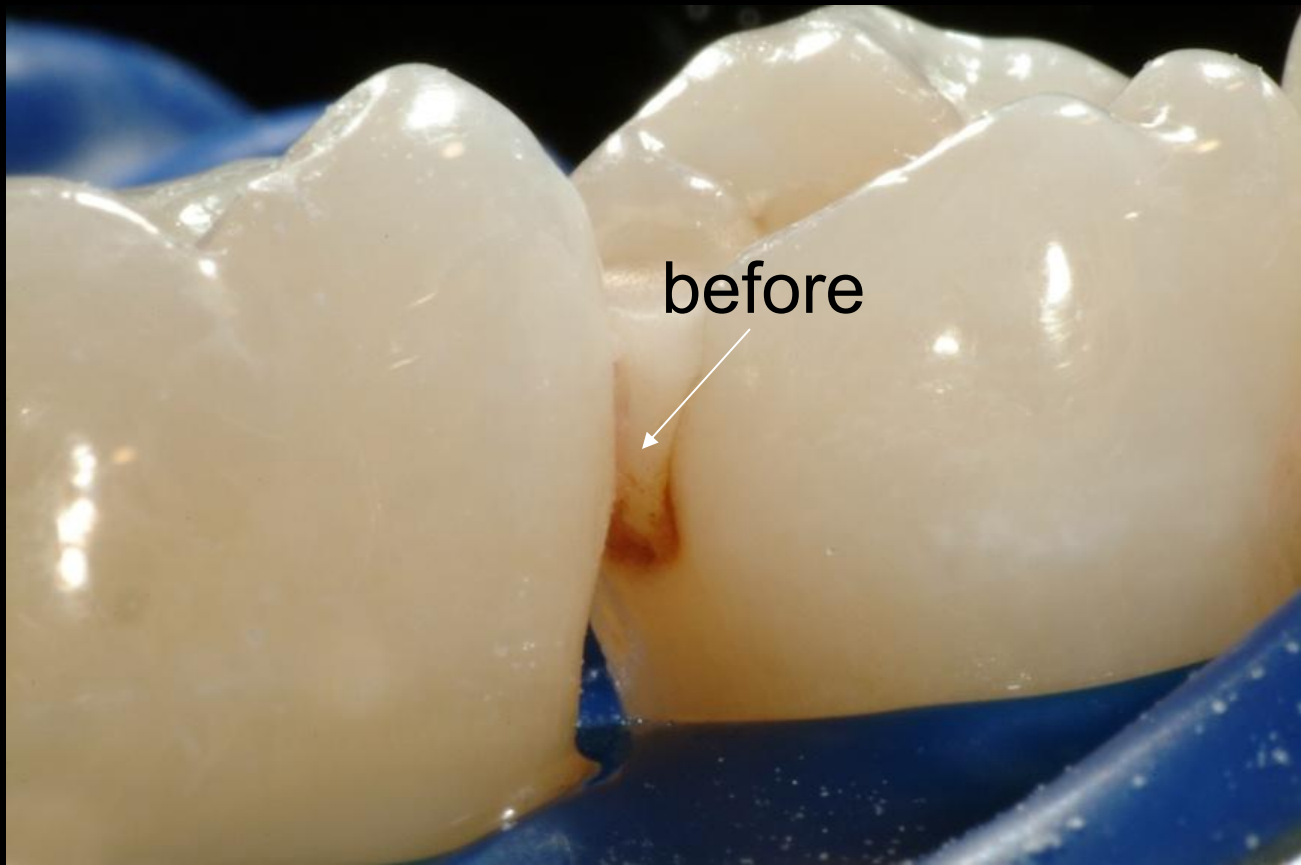Inability to
condense paste
composite



Modern Class II Cavity Preparation Design

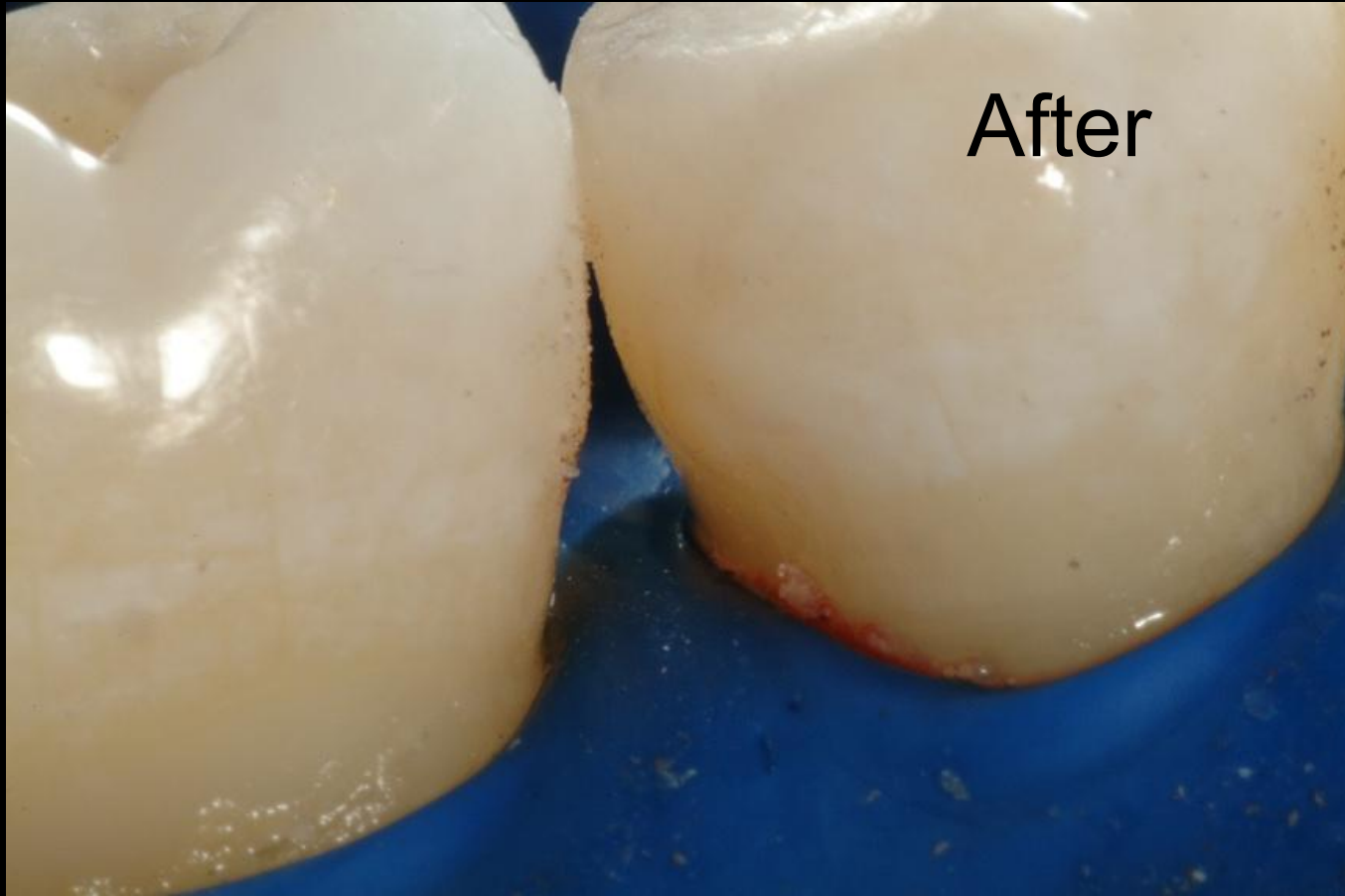The Prep?

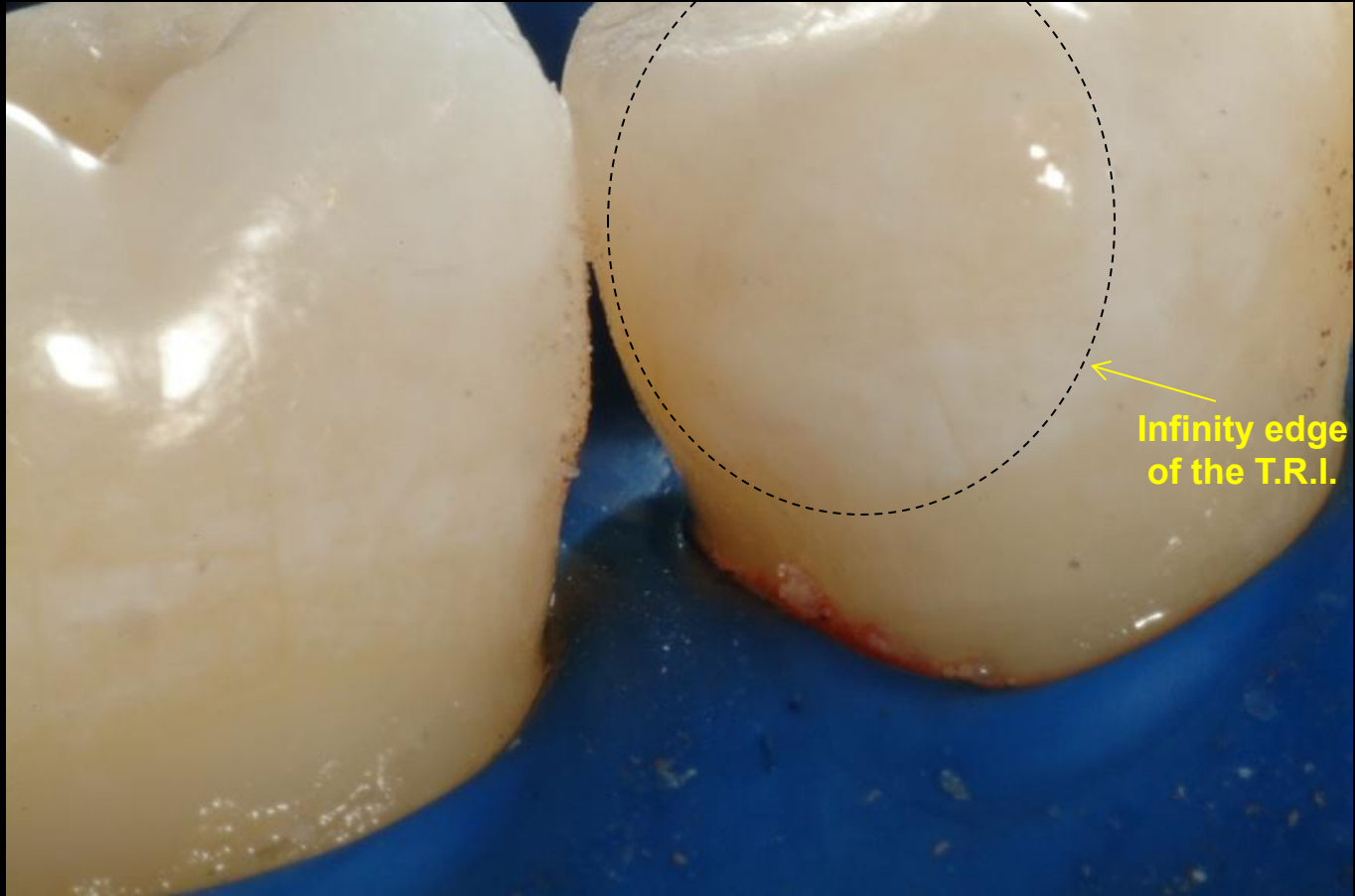



before

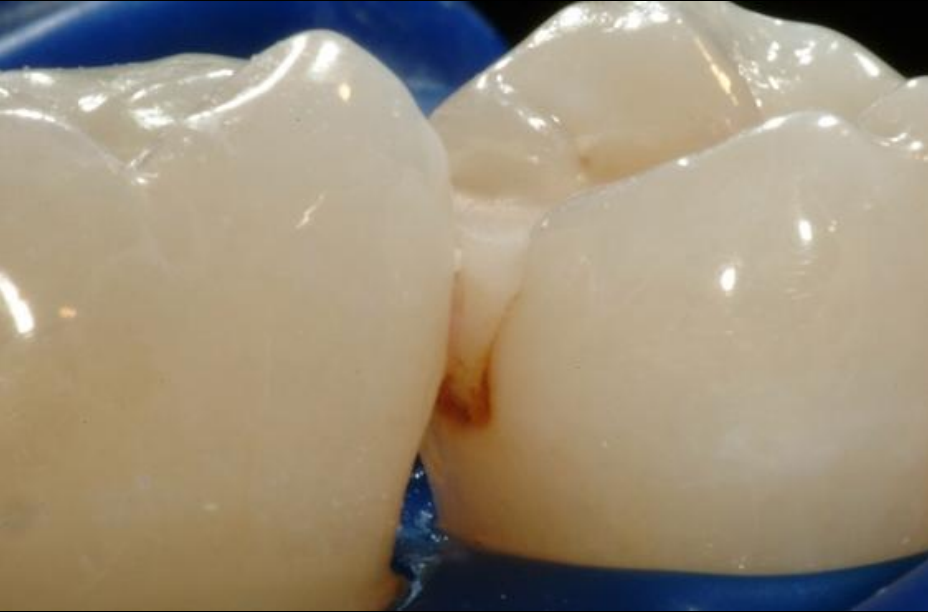The Bioclear method



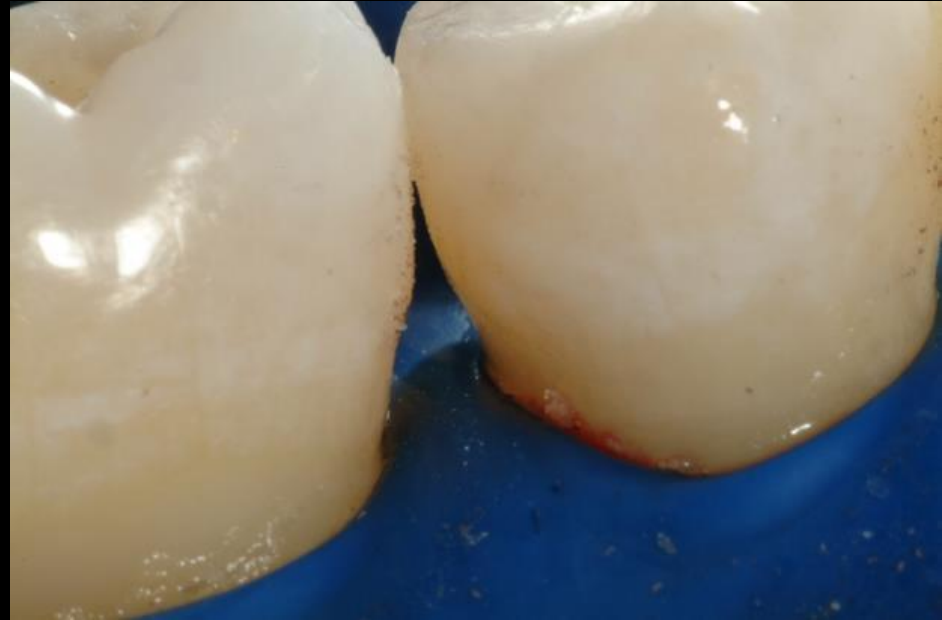

Infinity edge
of the T.R.I.

The Bioclear Injection Molding Approach

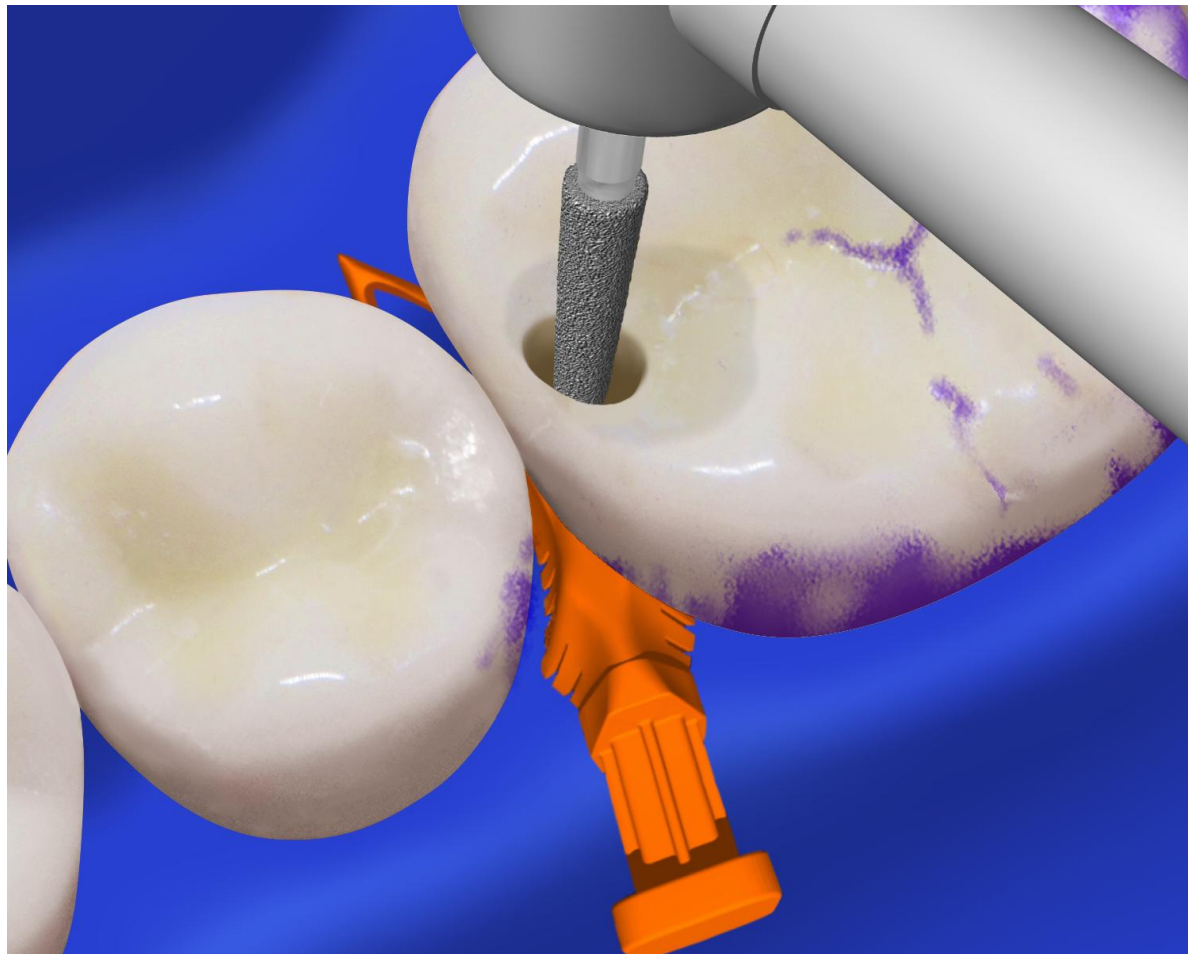


Failing composite;
traditional preparation

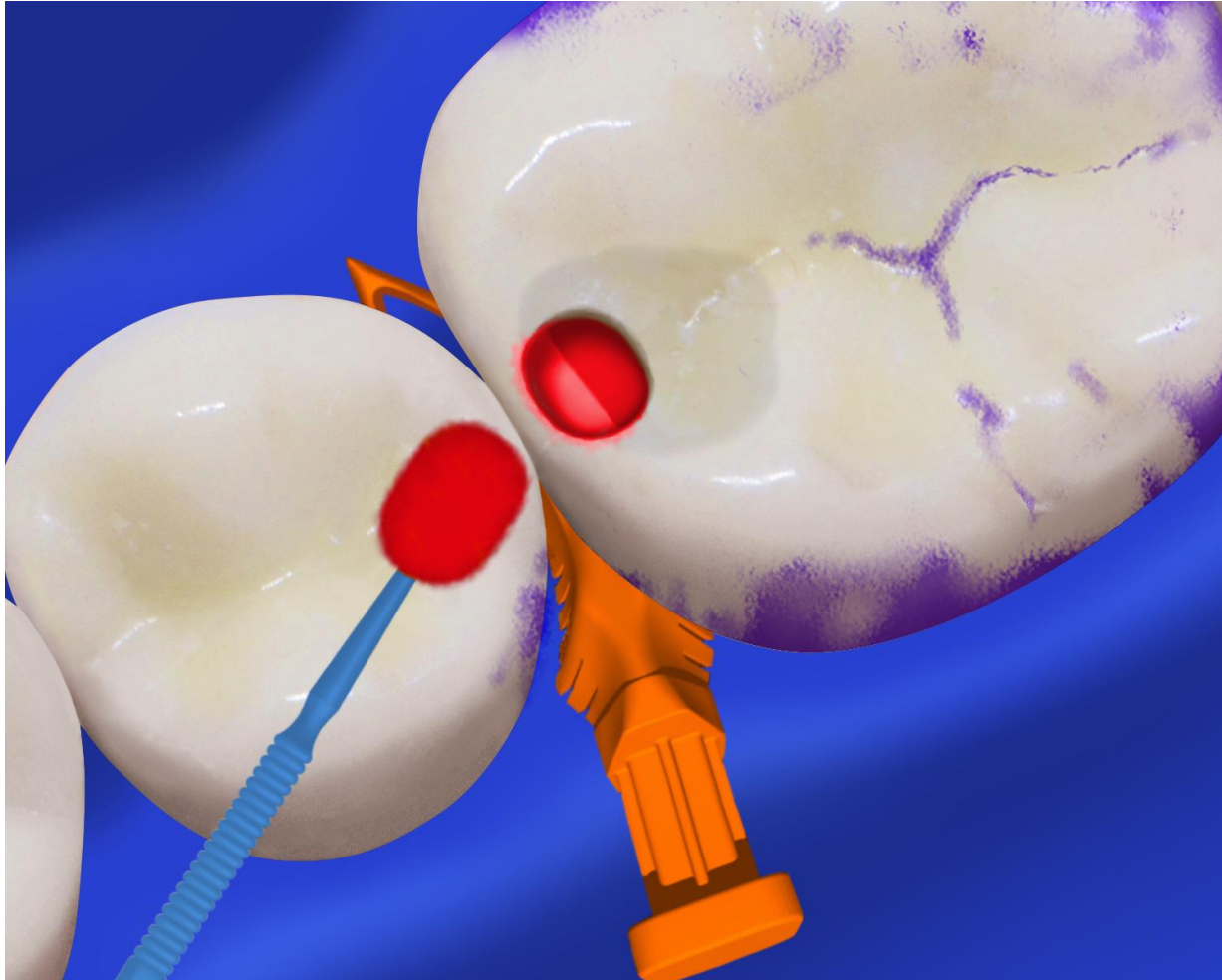


Re-Restored using the
Bioclear Evolve System and Method

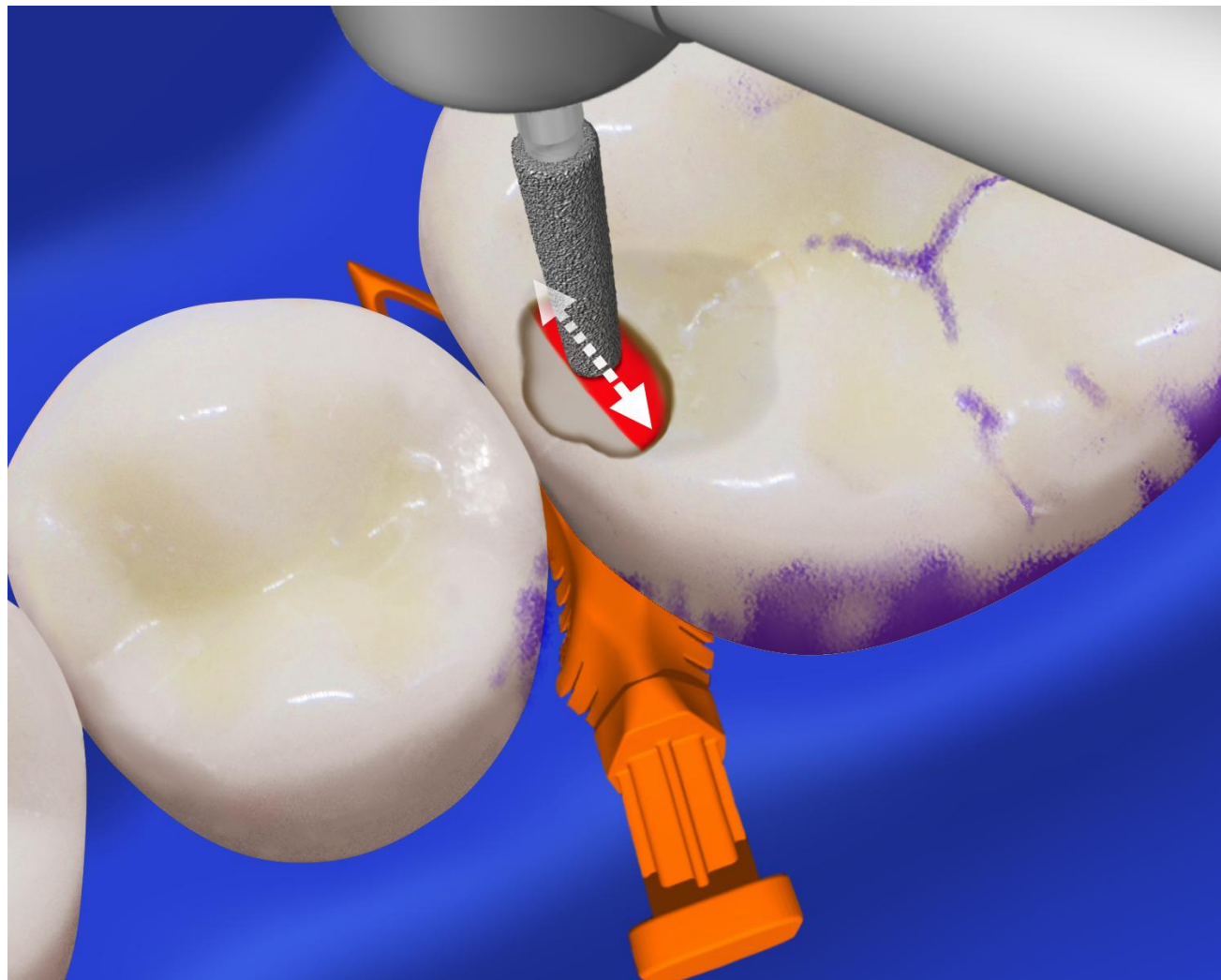
3) SS White Bur #3 is dropped into the at the suspected cavitation area. (Bur is used with water coolant)



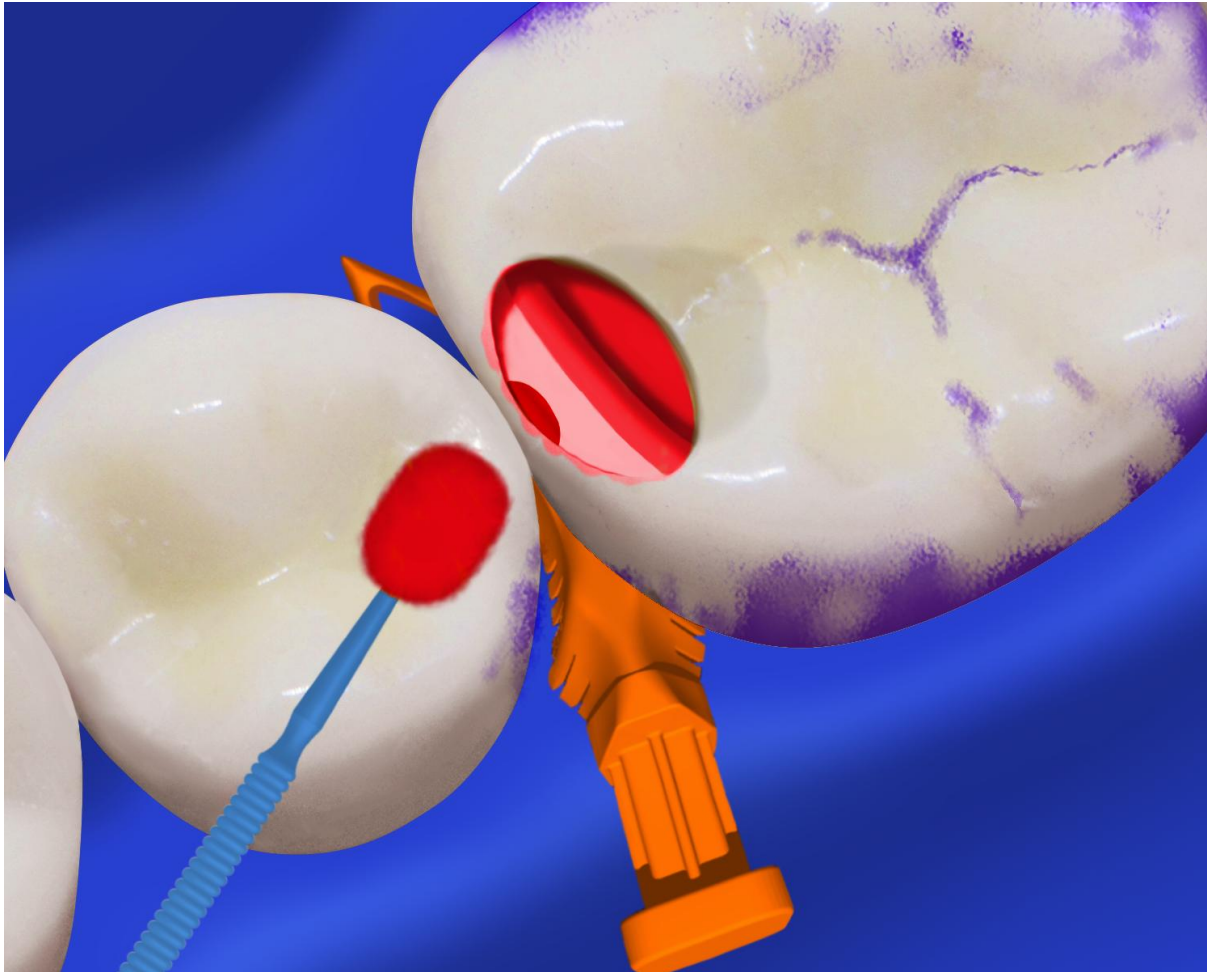
4) Caries indicator identifies dentin caries. Assessment of cavitation and caries to adjust bur movements. Axial dentin caries and healthy DEJ tissue should not be removed.



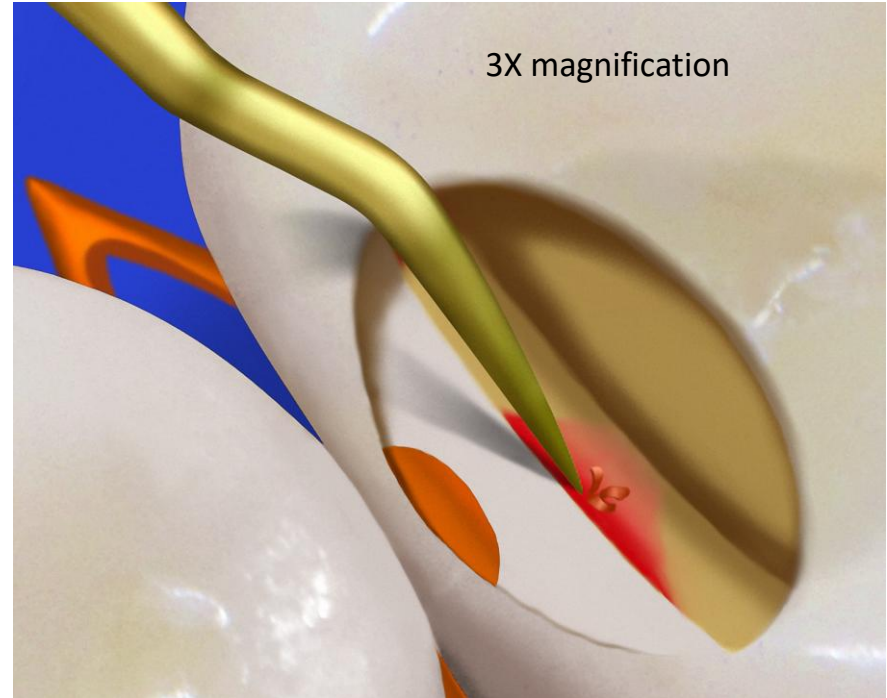
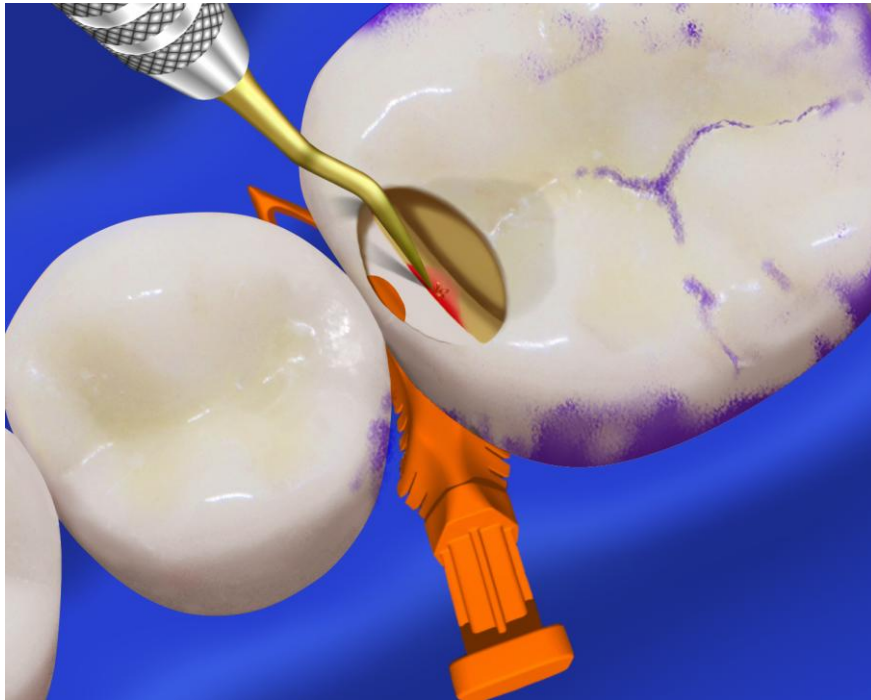
5) SS White bur #3 is kept *inside* of the cavity prep as DEJ caries removal proceeds.

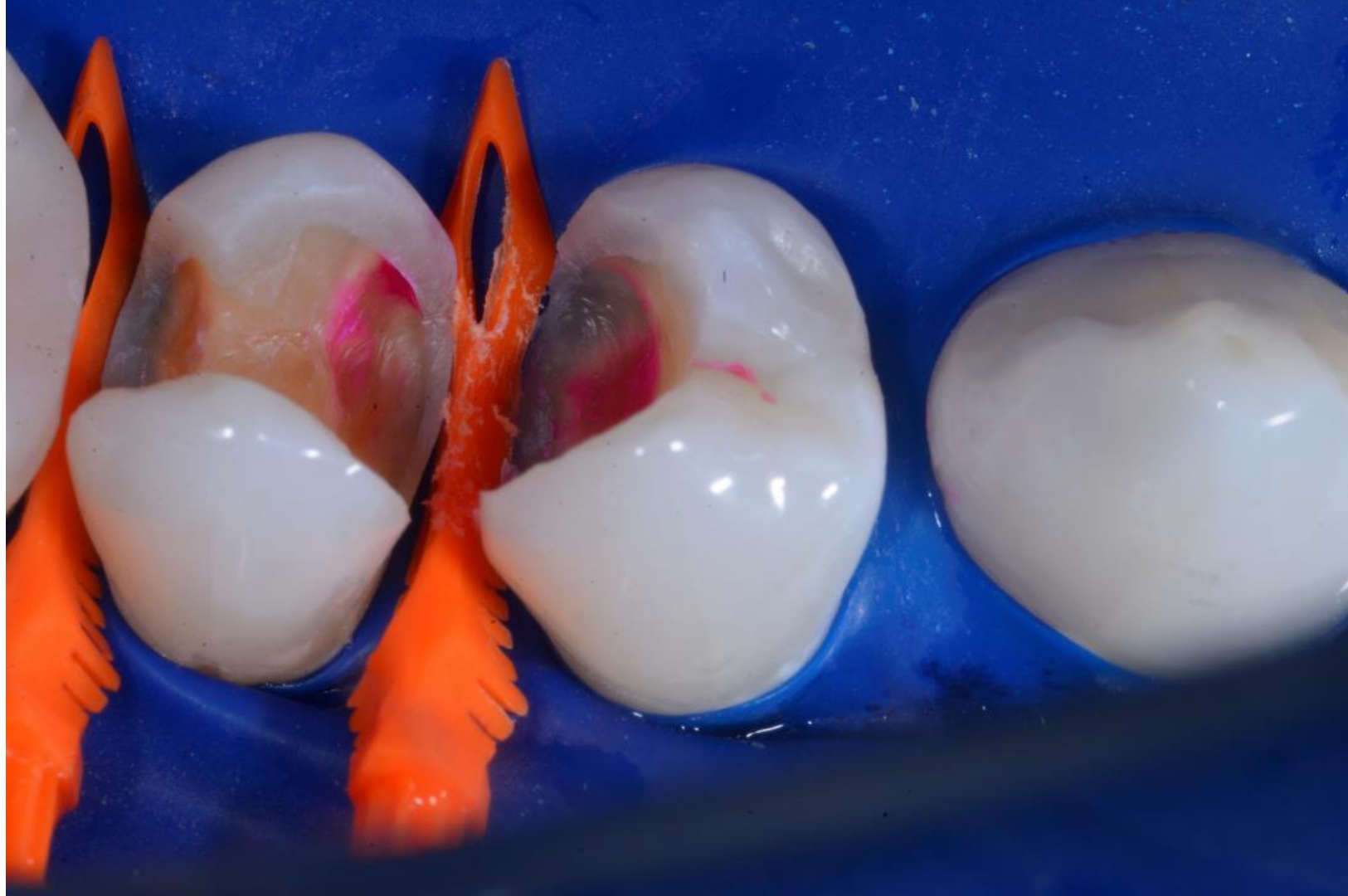

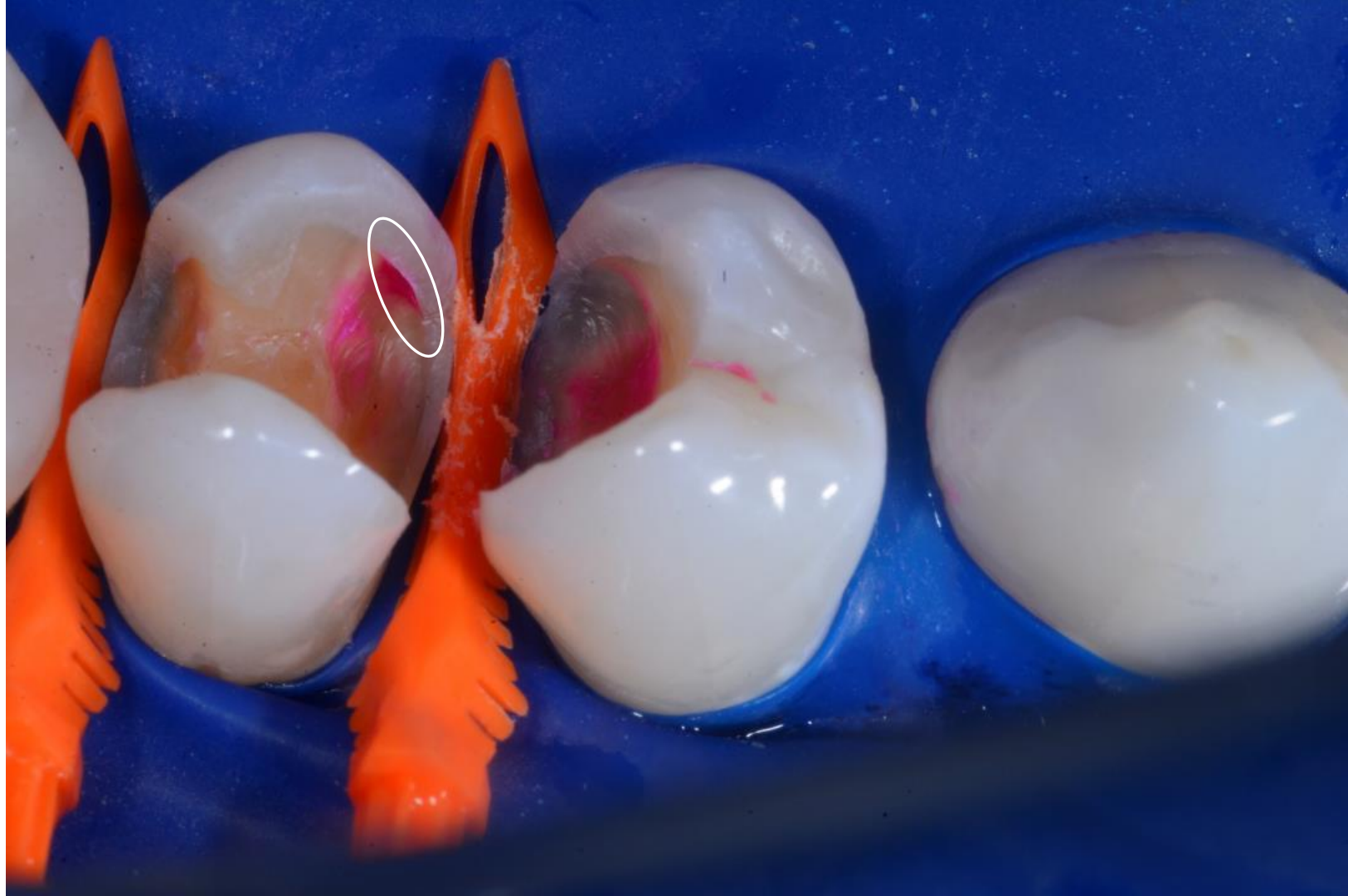6) Second caries indicator application. indicator application is repeated as needed until a negative stain is produced (clean dentin at the DEJ).

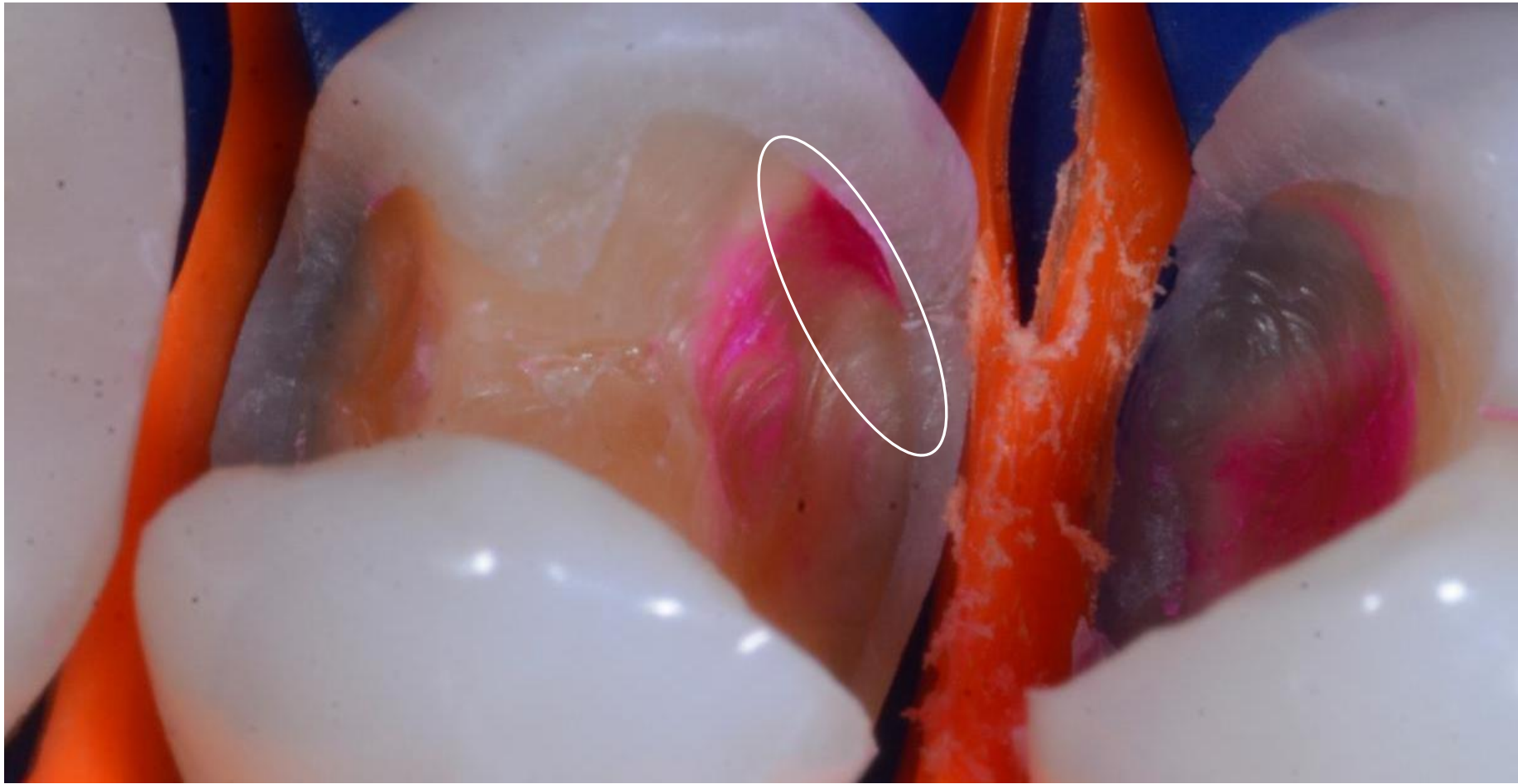


7) Clark explorer is used to achieve tactile test of healthy vs. carious DEJ dentin. Cumulative diagnosis with hardness test and caries indicator is recommended.

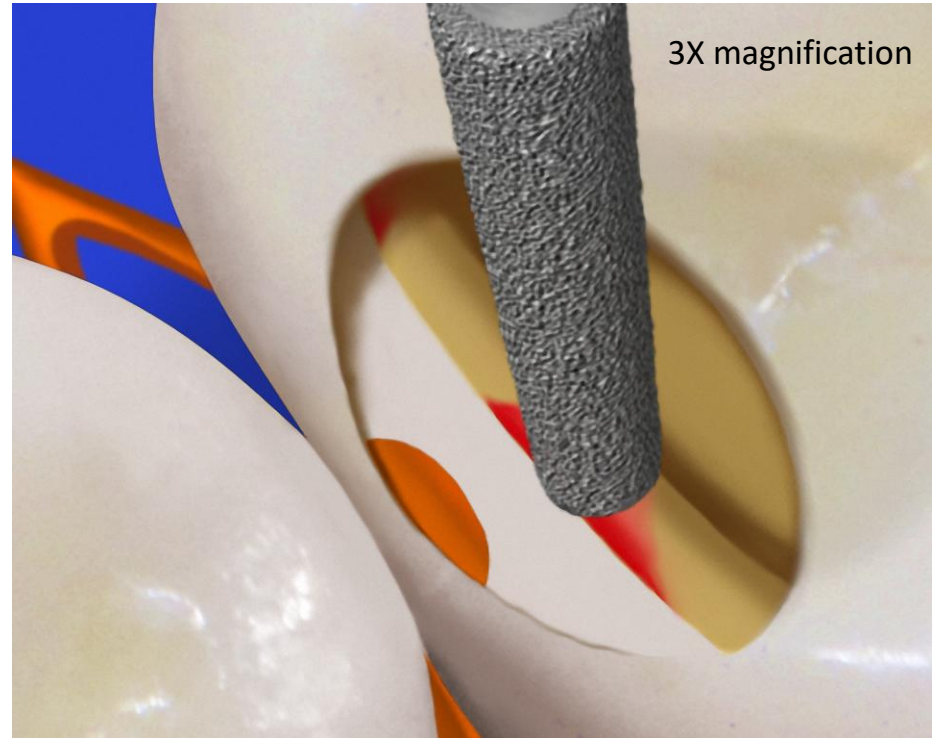
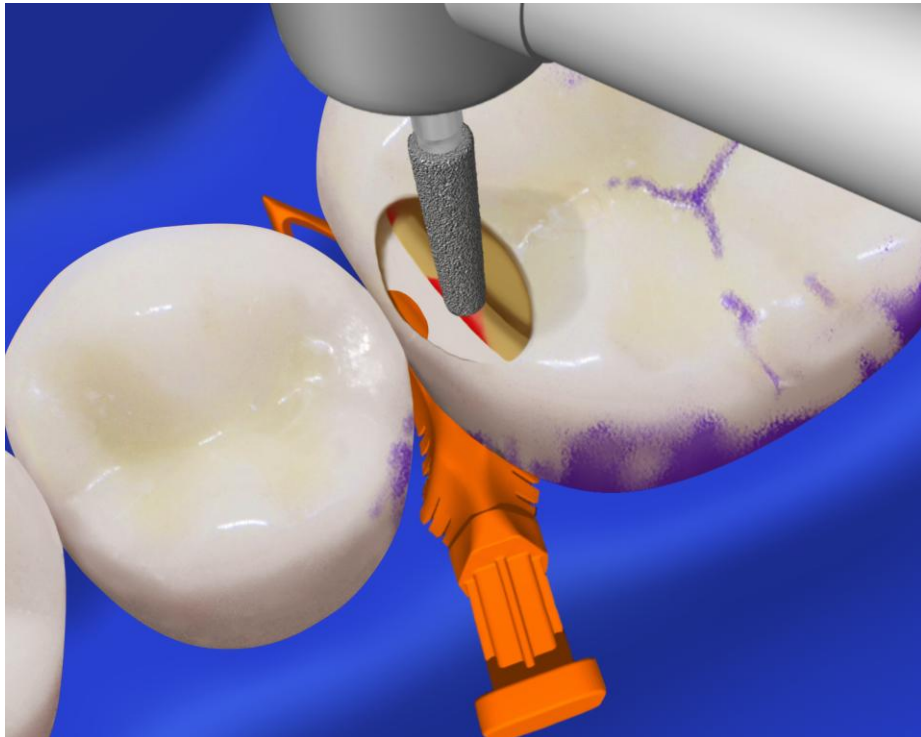




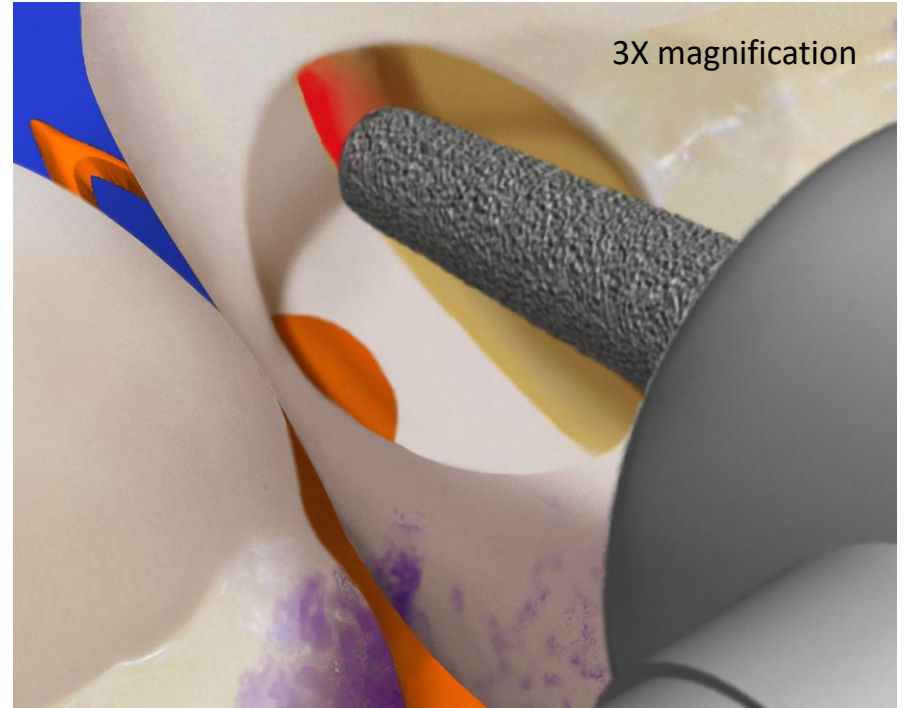
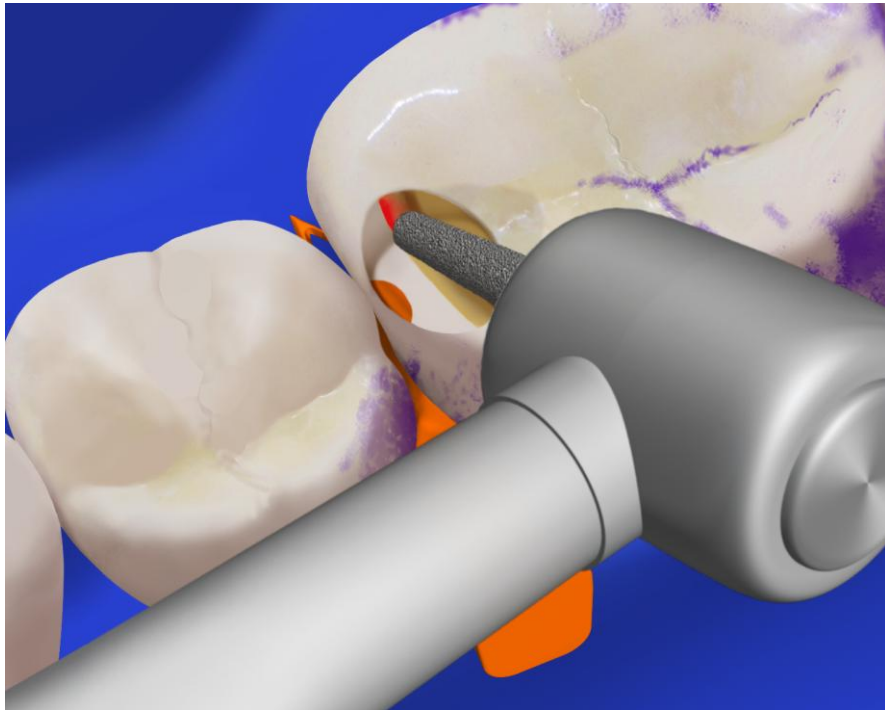




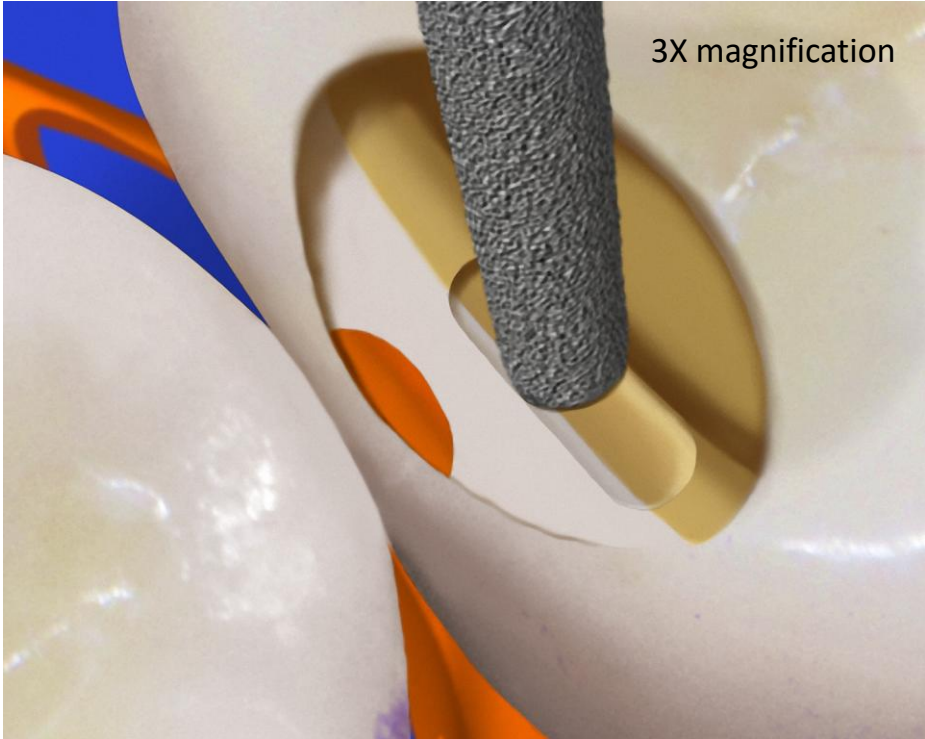
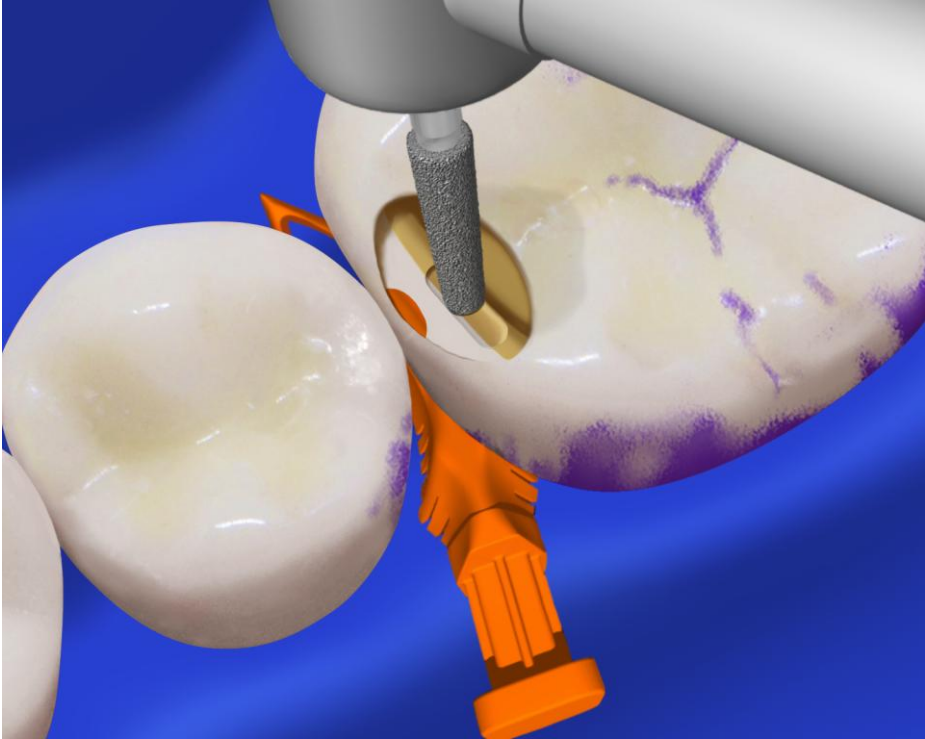
8) Final DEJ caries removal on gingival zone with SS White #3 bur



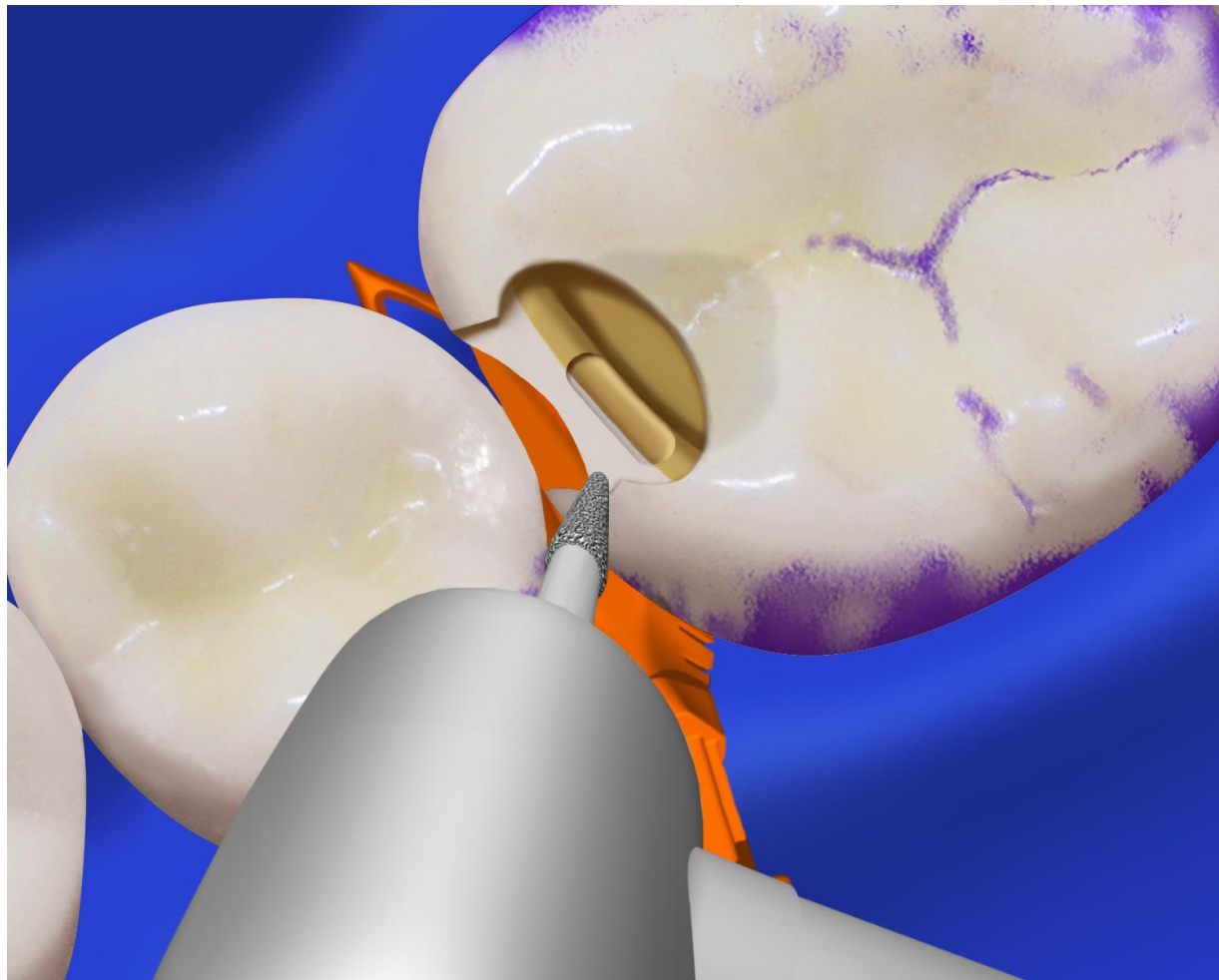
9) Buccal and caries at DEJ is also performed. Angle of bur can be changed for conservative access.



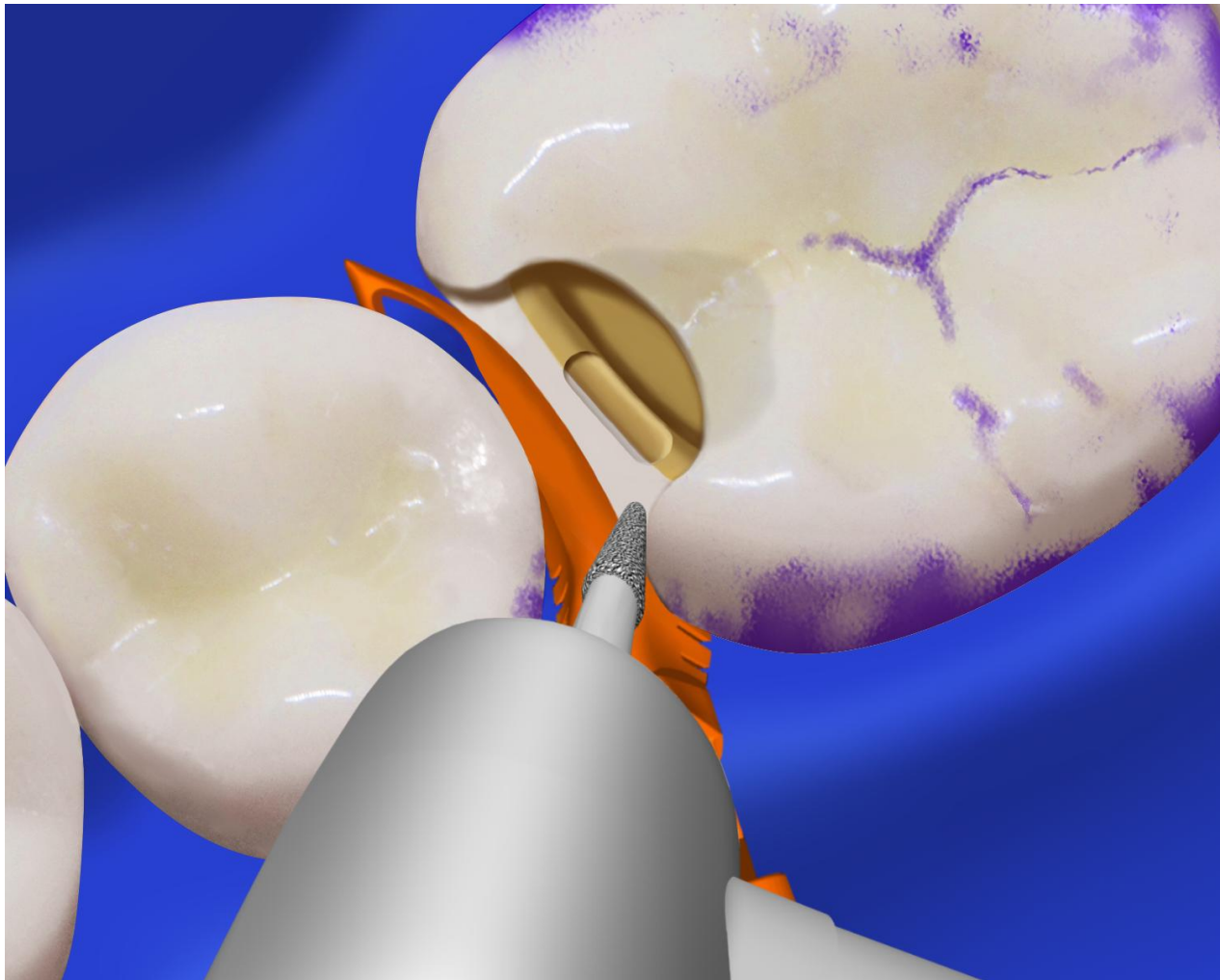
10) Final caries removal at DEJ is shown and natural cavitation area is shown.



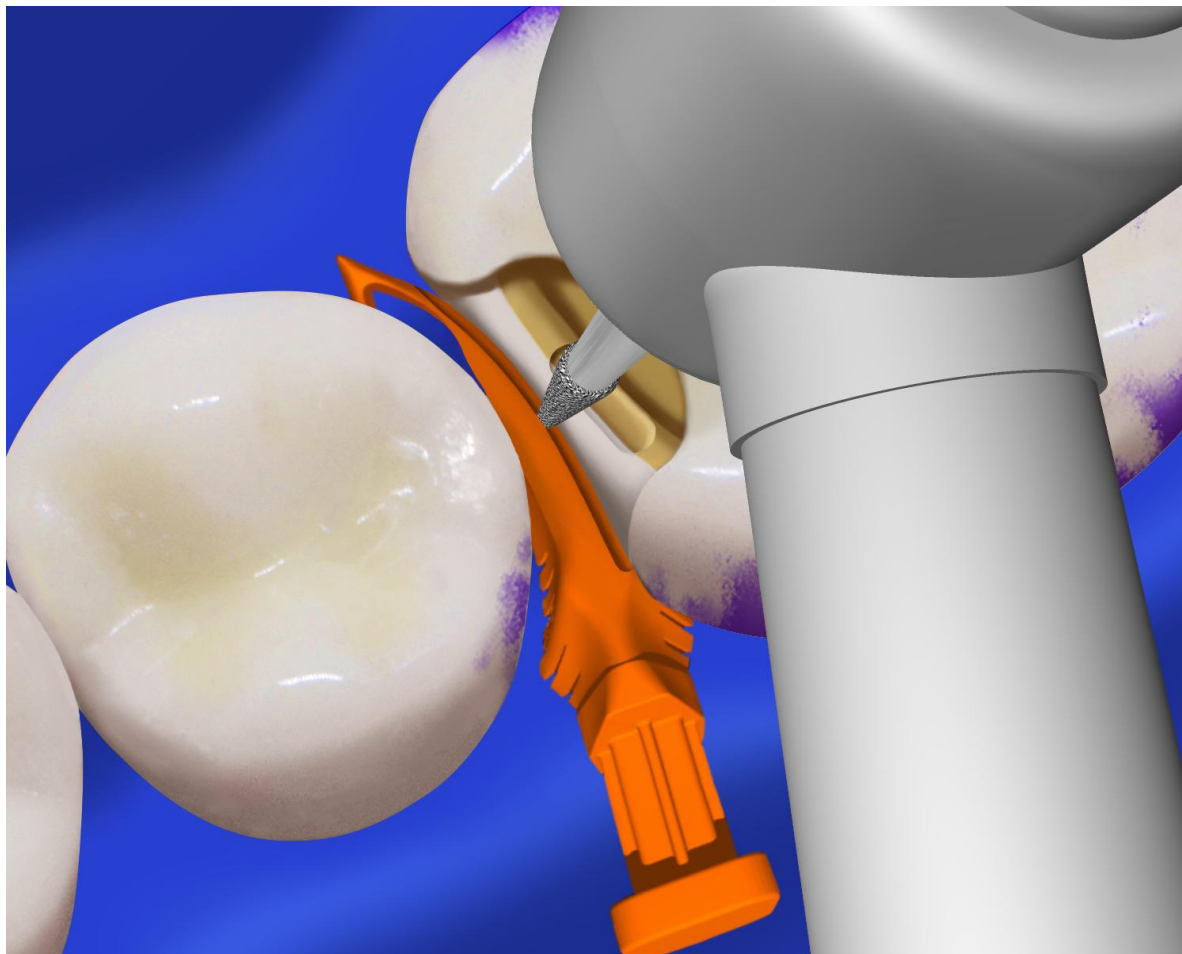
11) SS White Bur #6 is used to break all contacts. Bur can be used either wet or dry)

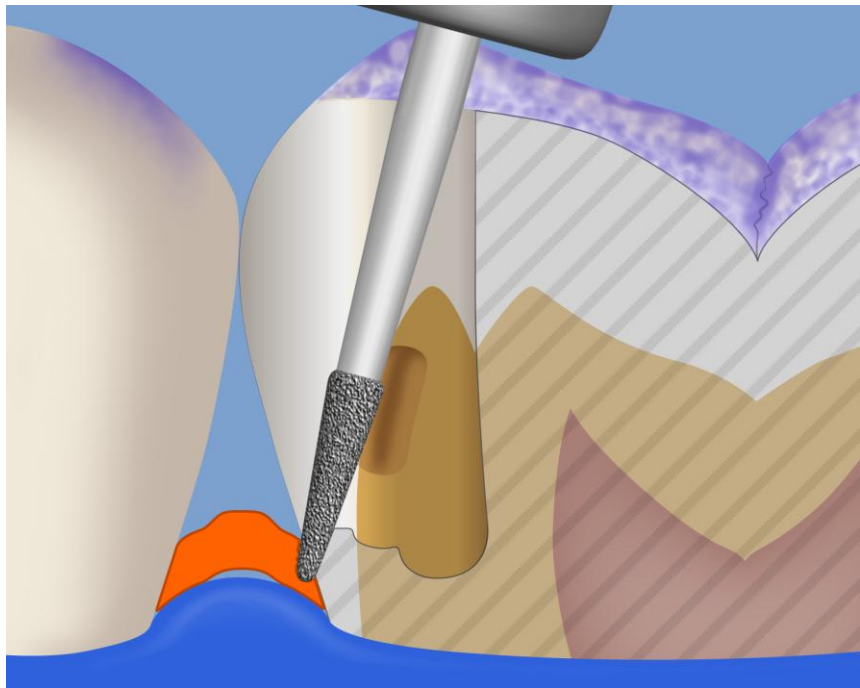


12) SS White bur
#6 Bur is used to
create the radius
bevel.

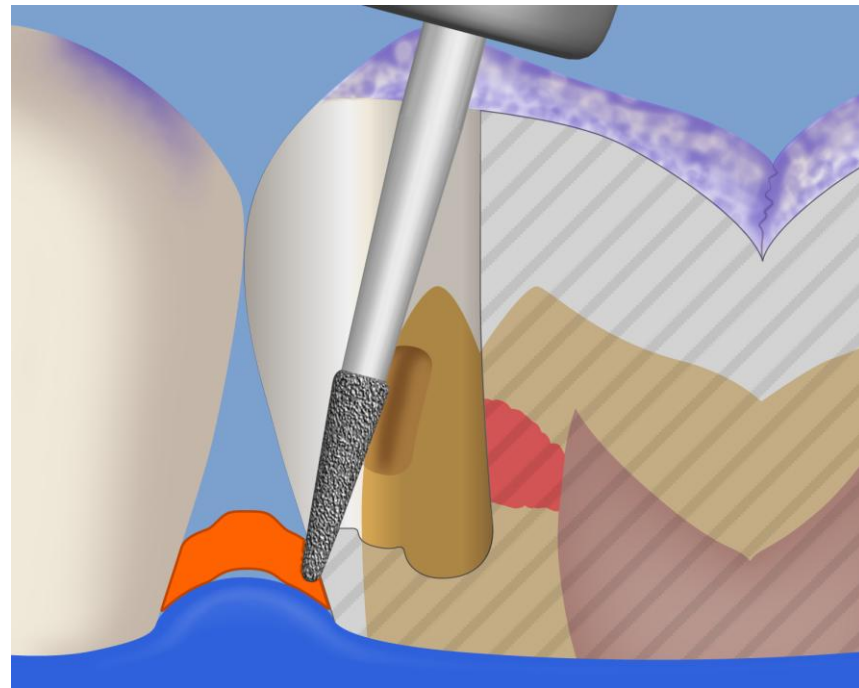


13) Create the gingival bevel.
Diamond wedge can be removed if wedge is an encumbrance to bur.



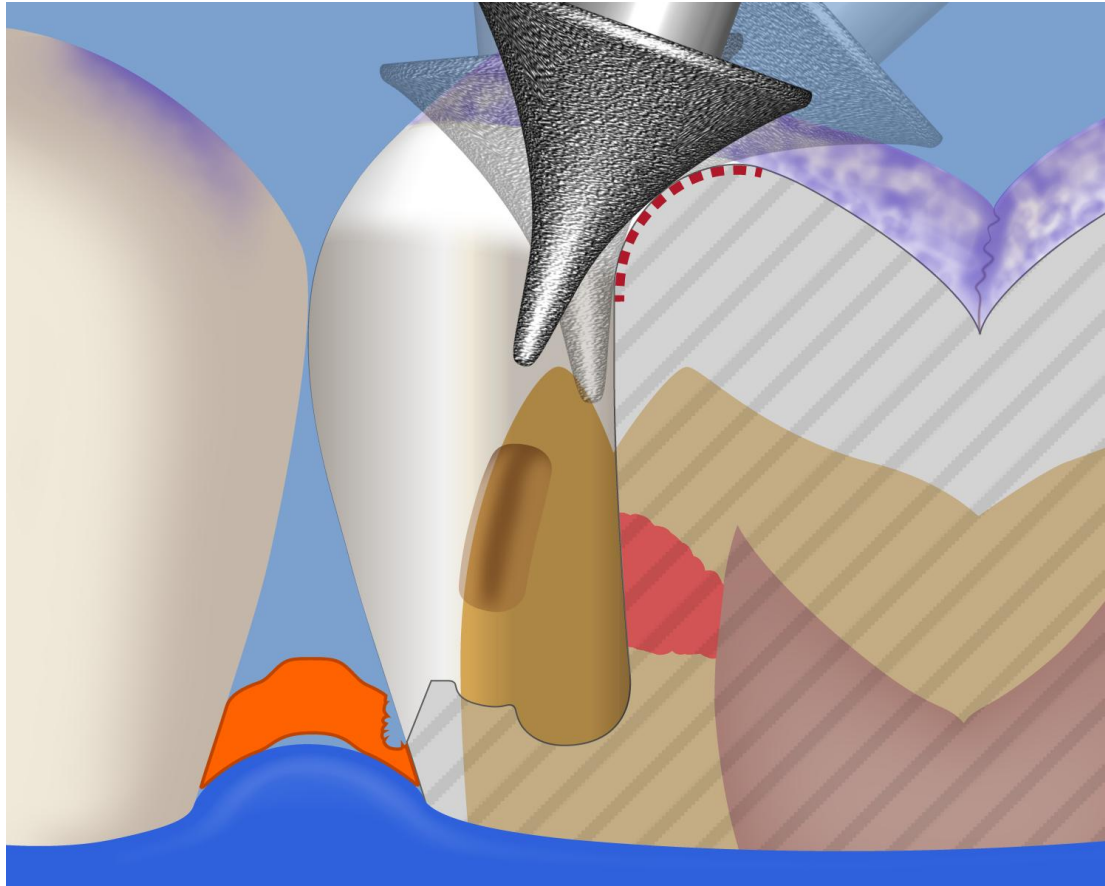


Cross section view of step 13

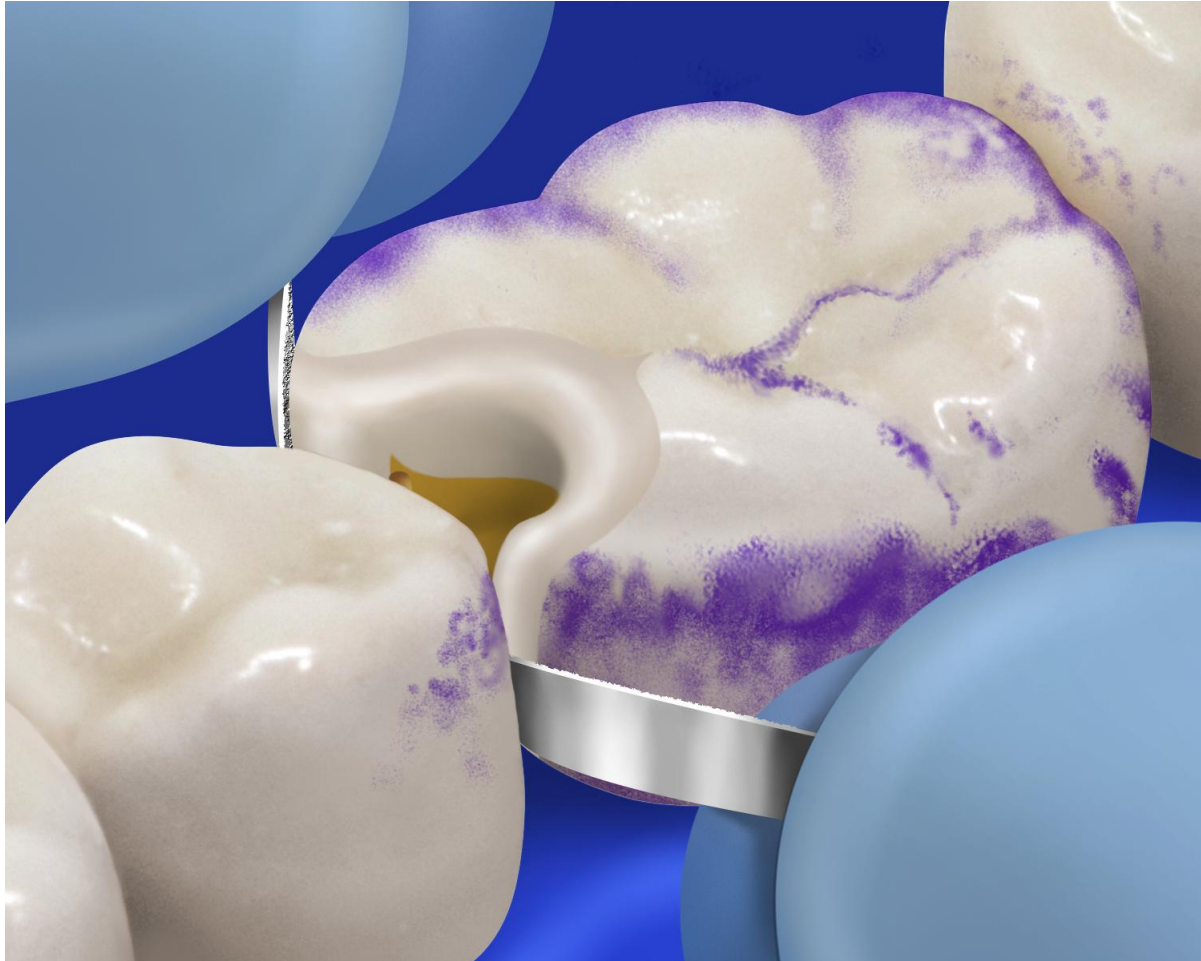


Cross section view of step 13 with
Selective Caries Removal

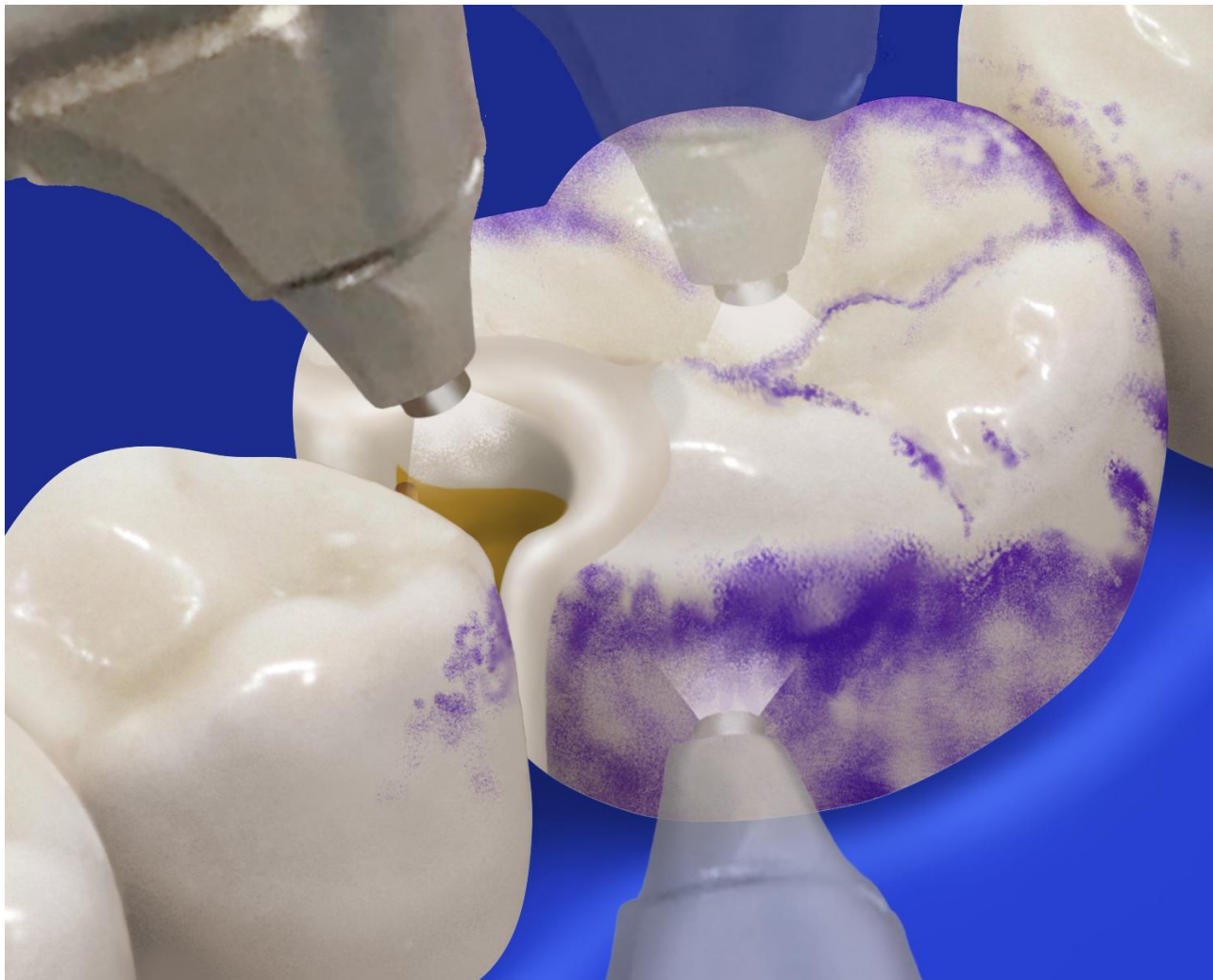14) SS White Calla
Lily bur #3 is used
to create radius
bevel/compression
joint on occlusal
enamel.



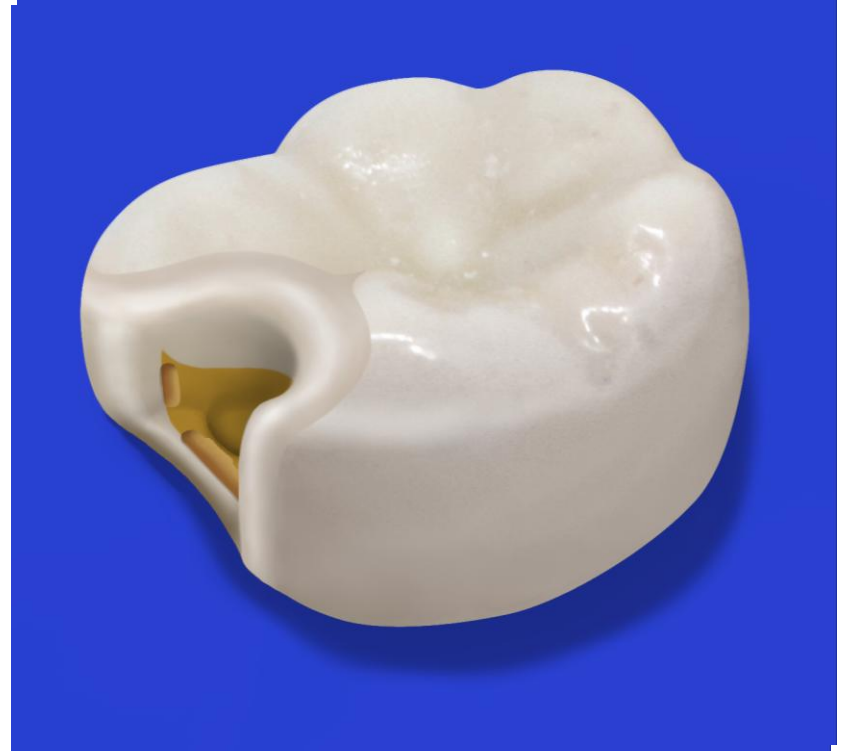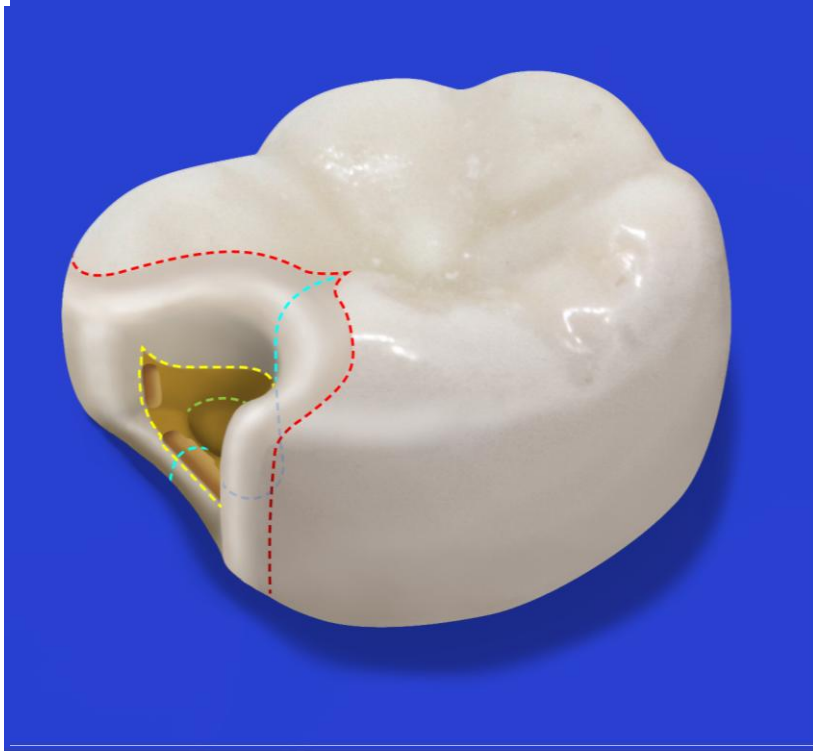
15) SS White strip removes loose enamel rods on entire preparation and hard deposits in the infinity edge area apical to the gingival bevel.



16) Bioclear Blaster with aluminum tri-hydroxide is used to clean inside and outside of preparation.



Final views of completed Bioclear Class II Preparation.



Max Planck *Nobel Prize, 1918*



“A new scientific truth does not triumph by convincing its opponents and making them see the light, but rather because its opponents eventually die, and a new generation grows up that is familiar with it.”

Are all
Separators
Equal?

NO!



Stretched to 20mm ONCE!!!





And now most of the power is permanently lost

Once the yield of the metal/shape is reached, the metal undergoes plastic deformation

Stretched to 20mm Twenty Times

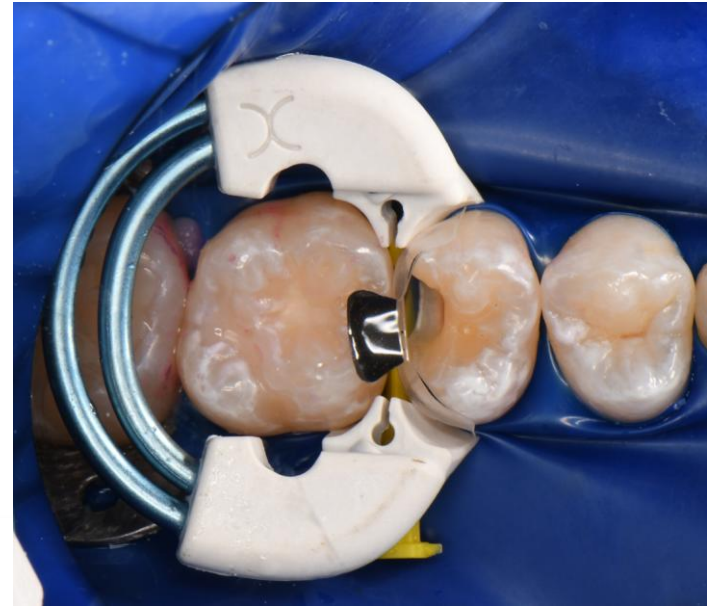


Stretched to 20mm Twenty Times



TwinRing Universal

∞ BIOCLEAR






How do we win the *Snug Contact Game?*

- Power
- Strategy
- Technique



How do we win the *Snug Contact Game?*

- Power
- Strategy
- Technique



Nate Lawson DMD PhD

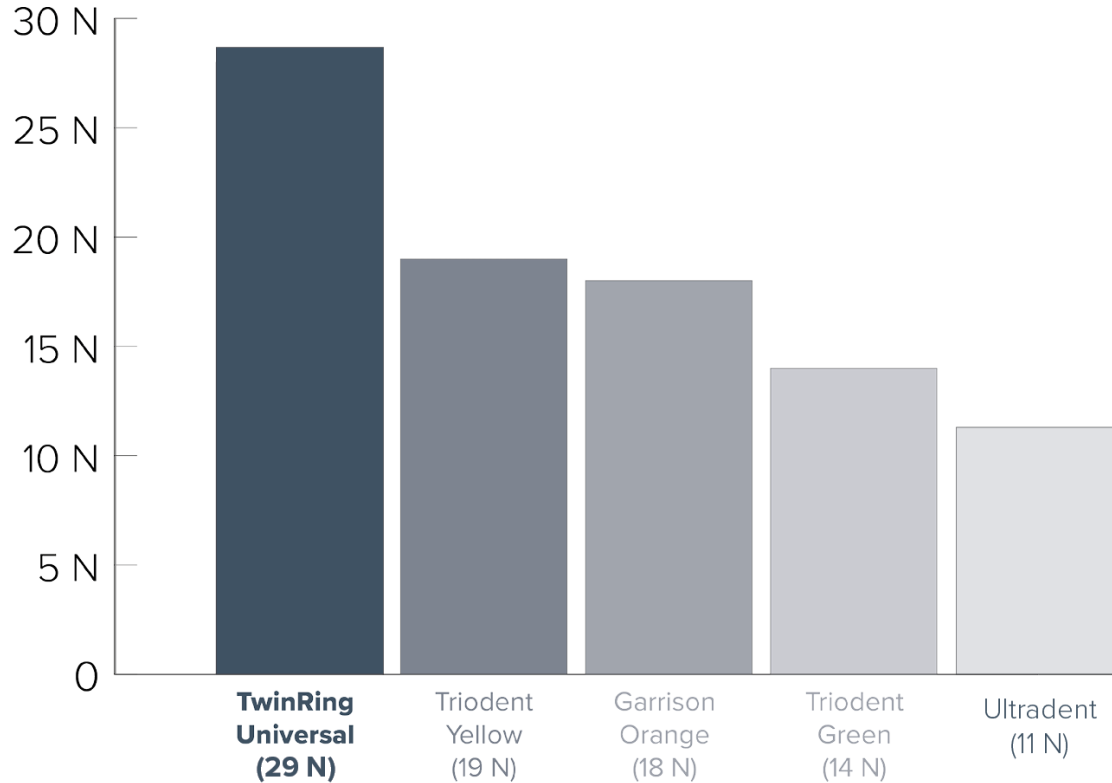
Director of the Division of Biomaterials and Pranit Bora. BDS, MDS.

Resident, Division of Biomaterials UAB School of Dentistry



TwinRing Universal
28 N

TwinRing Universal Instron Comparison



Note: Rings tested are not new and some rings stretch out quickly and lose up to half of their power after multiple uses. 1N = 1kg (m/s/s)

∞ BIOCLEAR

Bioclear Matrices - Posterior





EVOLVE --- MATRIX

Premolar



Molar



EVOLVE
MATRIX

Premolar Evolve: Width & Profile

- Evolve premolar matrices come in one width and profile – Black – to fit a variety of premolar tooth shapes

BLACK EVOLVE

Designed with an aggressively rounded emergence profile. Shaped specifically for premolar teeth, these matrices can be used anywhere you would typically use a Biofit matrix or BT matrices on premolars.

Tip: Rotate the matrix into place.



Premolar Normal
Width

Black Premolar Evolve

BIOCLEAR



5 Sizes

5mm

6mm

7mm

8mm

10mm

- Curved profile
- Normal width for a premolar



5 Sizes

5mm

6mm

7mm

8mm

9mm

- Curved profile
- Normal width

Molar Evolve: Width & Profile

- Evolve matrices come in three widths and profiles – Blue, Orange, and Pink – to fit a variety of posterior tooth shapes

BLUE EVOLVE

Designed with an aggressively rounded emergence profile and an average width. Blue Evolve is suitable for the majority of posterior cases.

Tip: Rotate the matrix into place.



Normal width

ORANGE EVOLVE

Features a flatter emergence profile than the Blue Evolve. Orange Evolve is perfect for patients with average-sized molars where the tooth is too flat for the Blue Evolve

Tip: Use the Orange Evolve if the Blue Evolve inverts



Wide Molar



3 Sizes

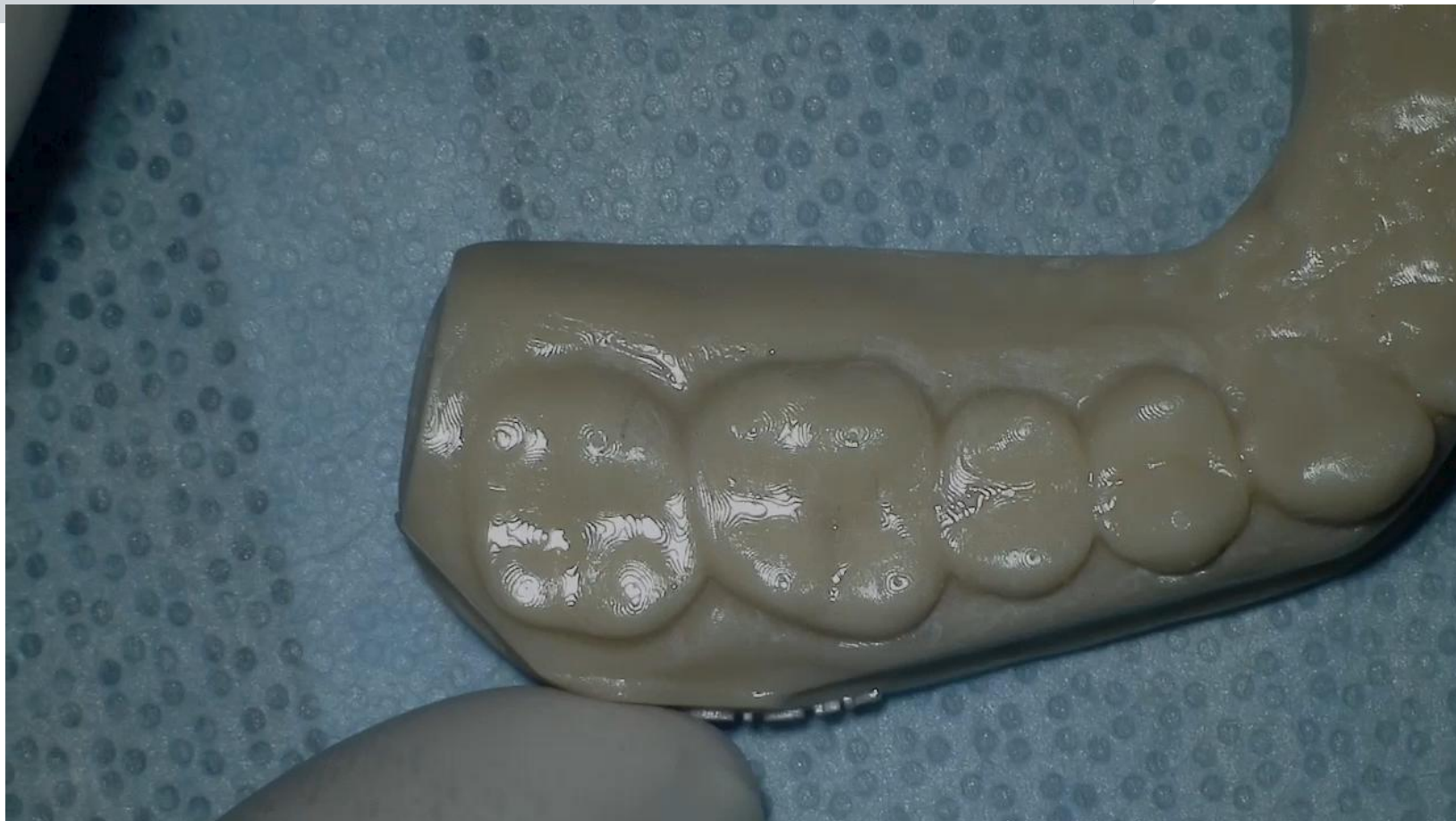6mm

7mm

9mm

- Curved/straight profile
- Wider width

The slip-off test



∞ BIOCLEAR

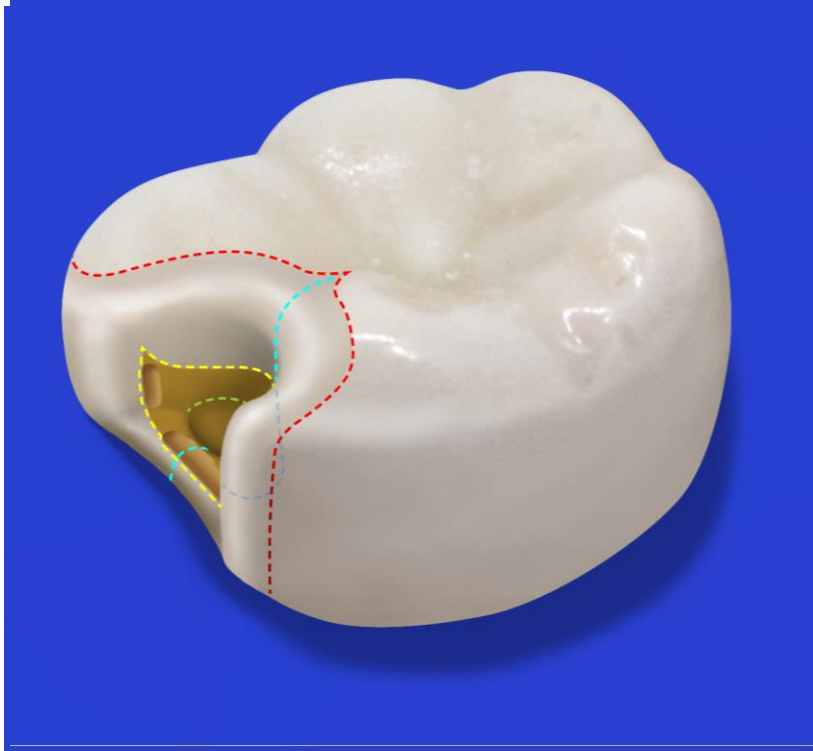
The Adjustable Push-Pull Instrument

for Ideal Contacts

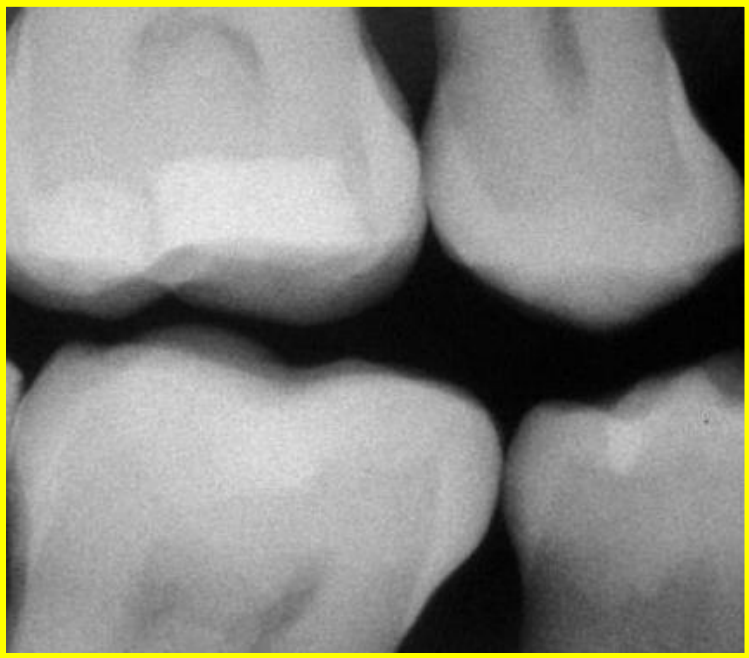


EVOLVE MATRIX SYSTEM

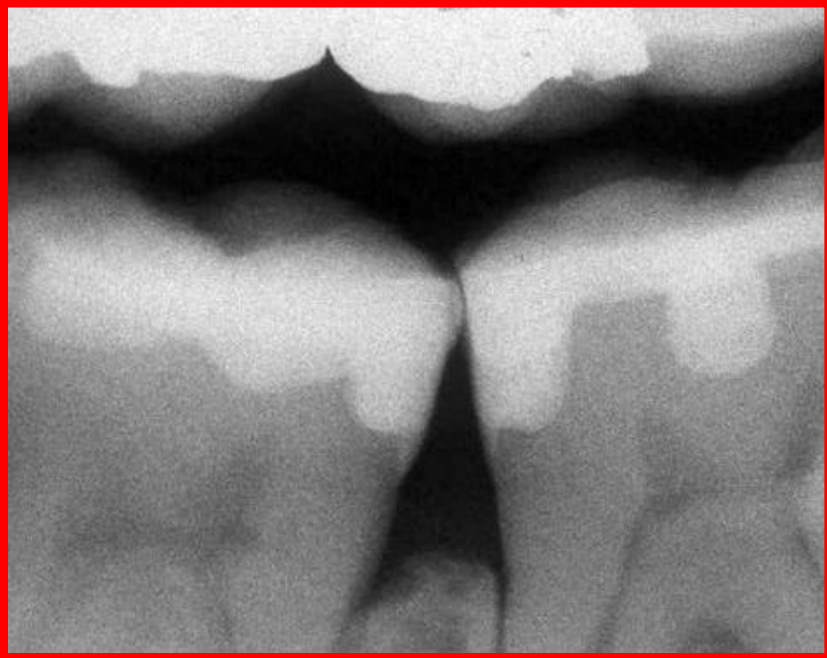Final views of completed Bioclear Class II Preparation.



Natural Contacts

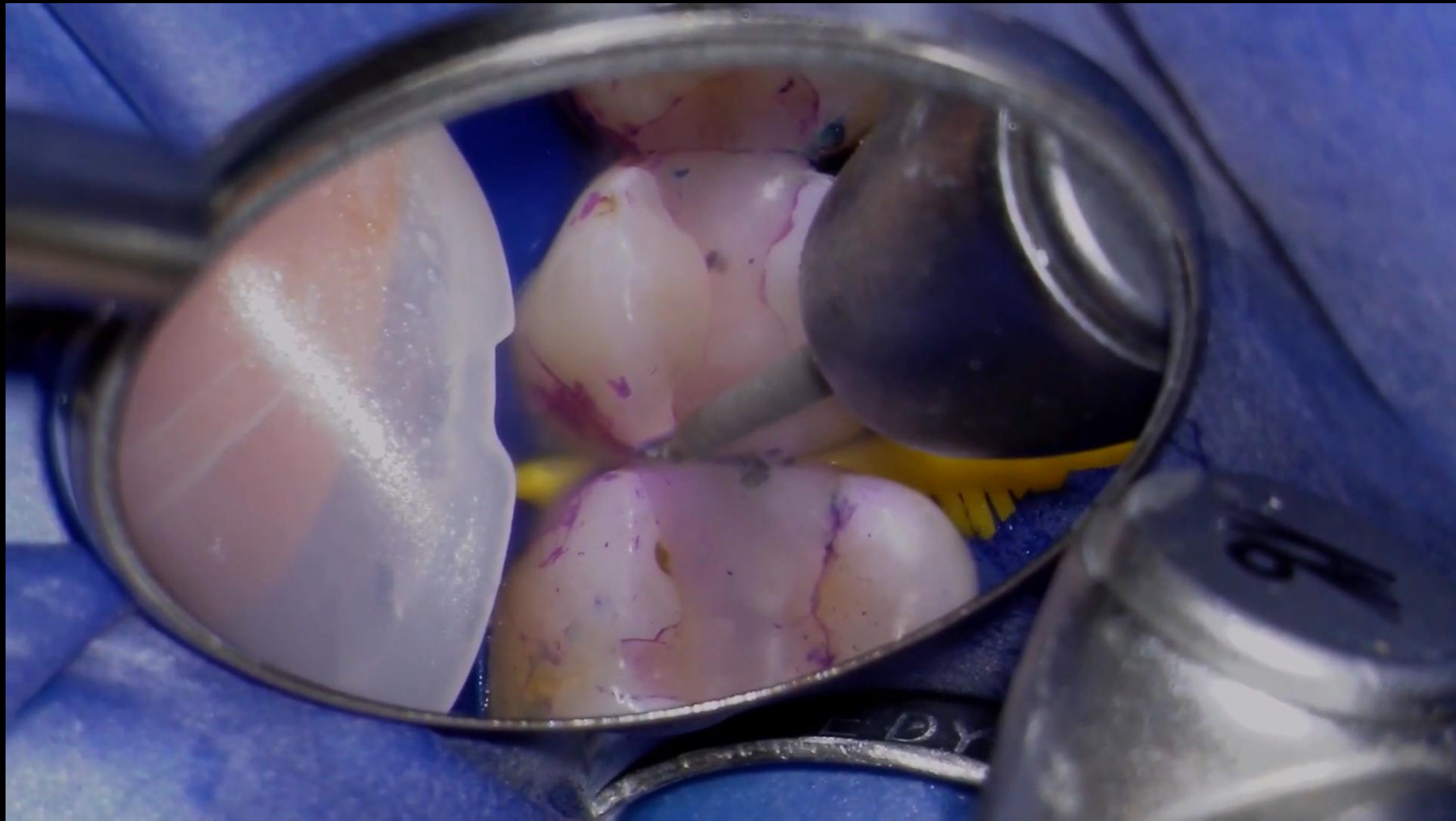


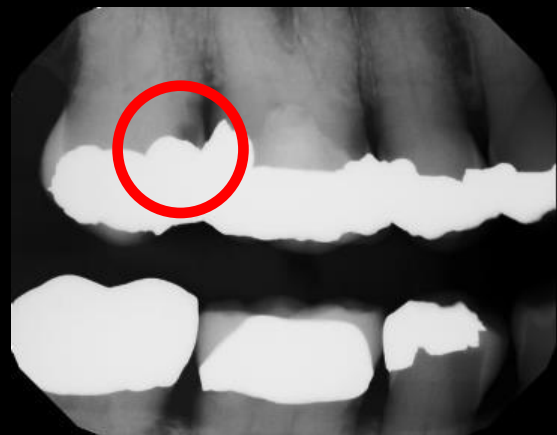
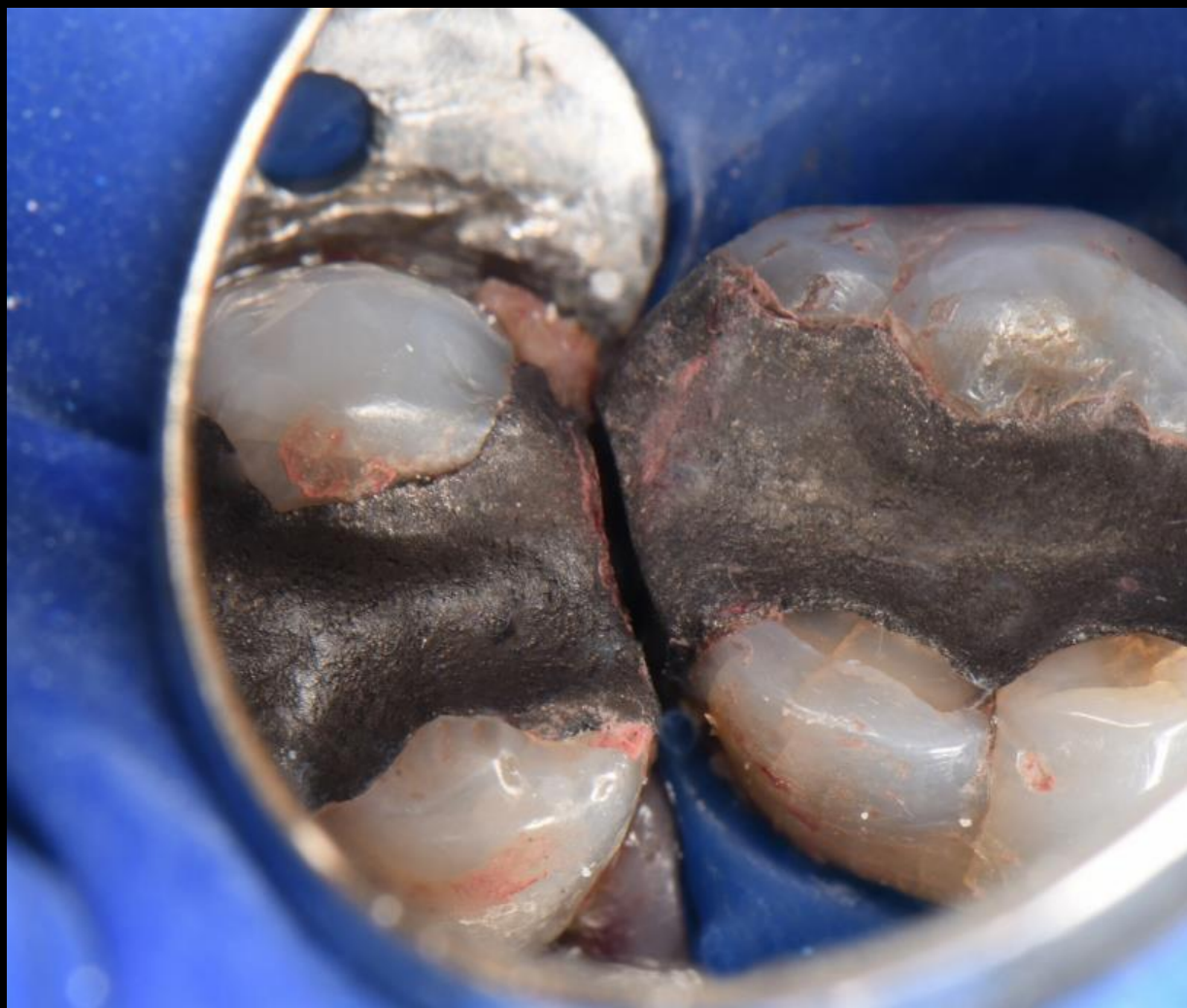Traditional Composite Contacts



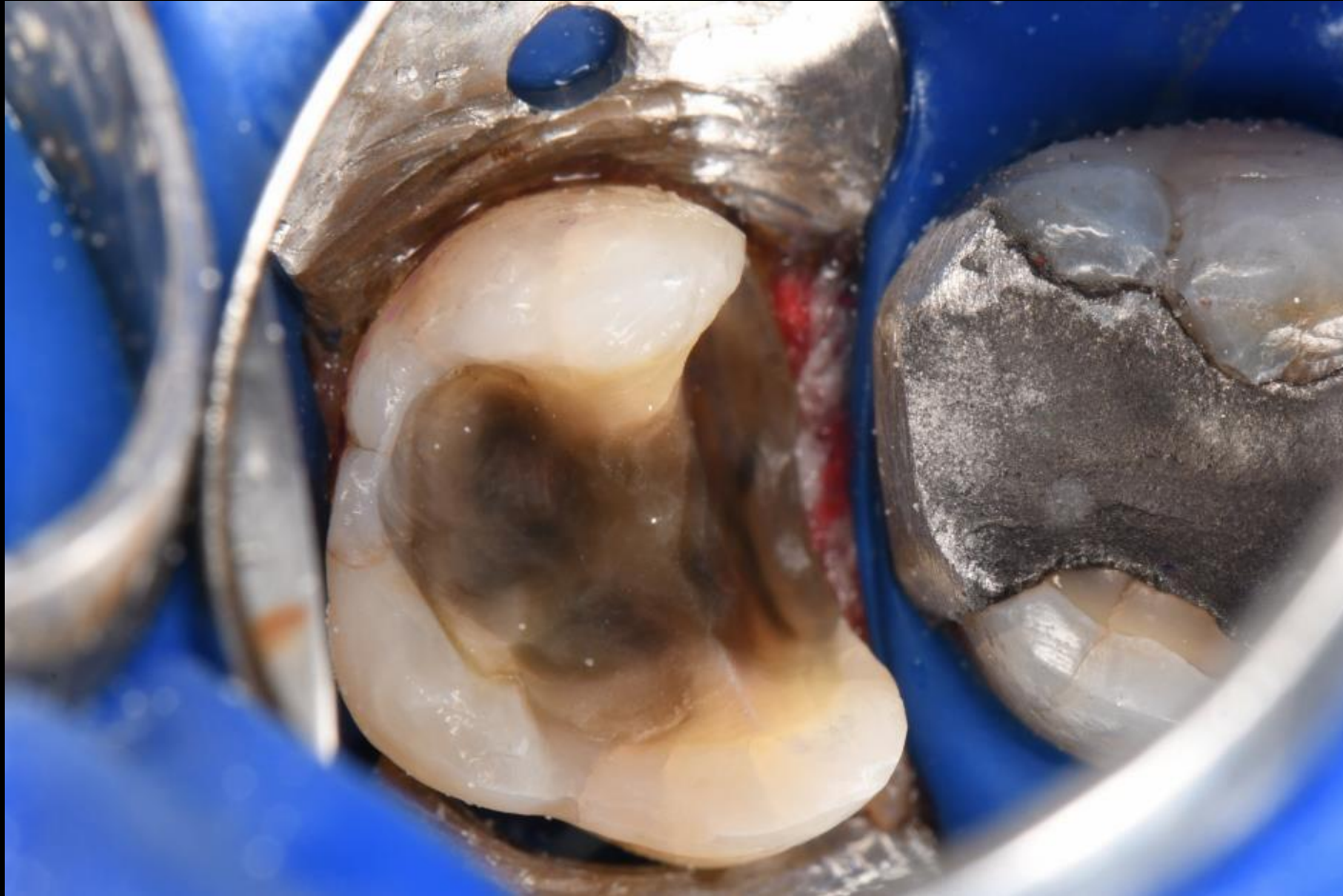What about deep decay?

Three-Point Spot Weld plus
Deep Margin Acquisition (DMA)
Clinical Video



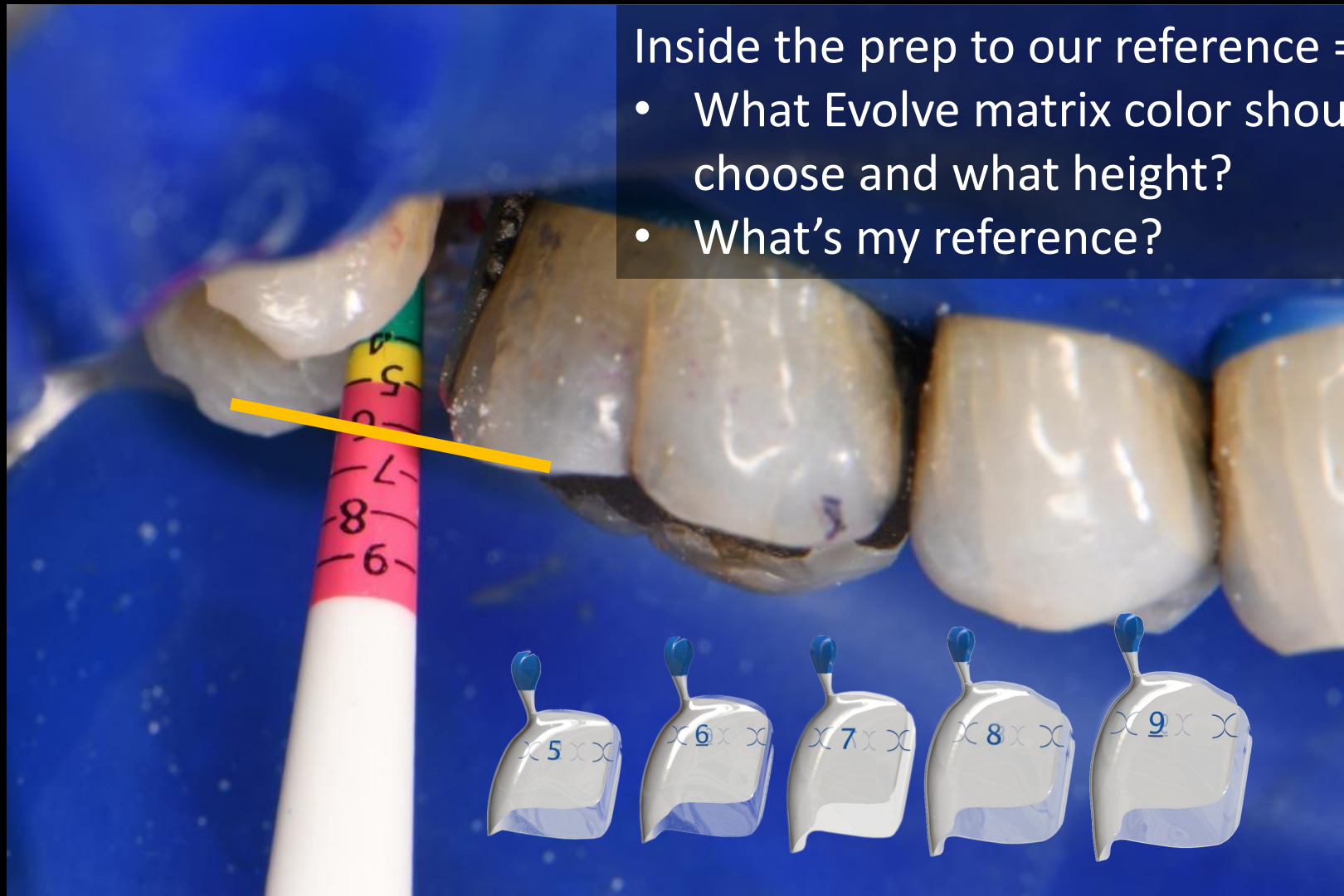

Deep Margin Acquisition (DMA)



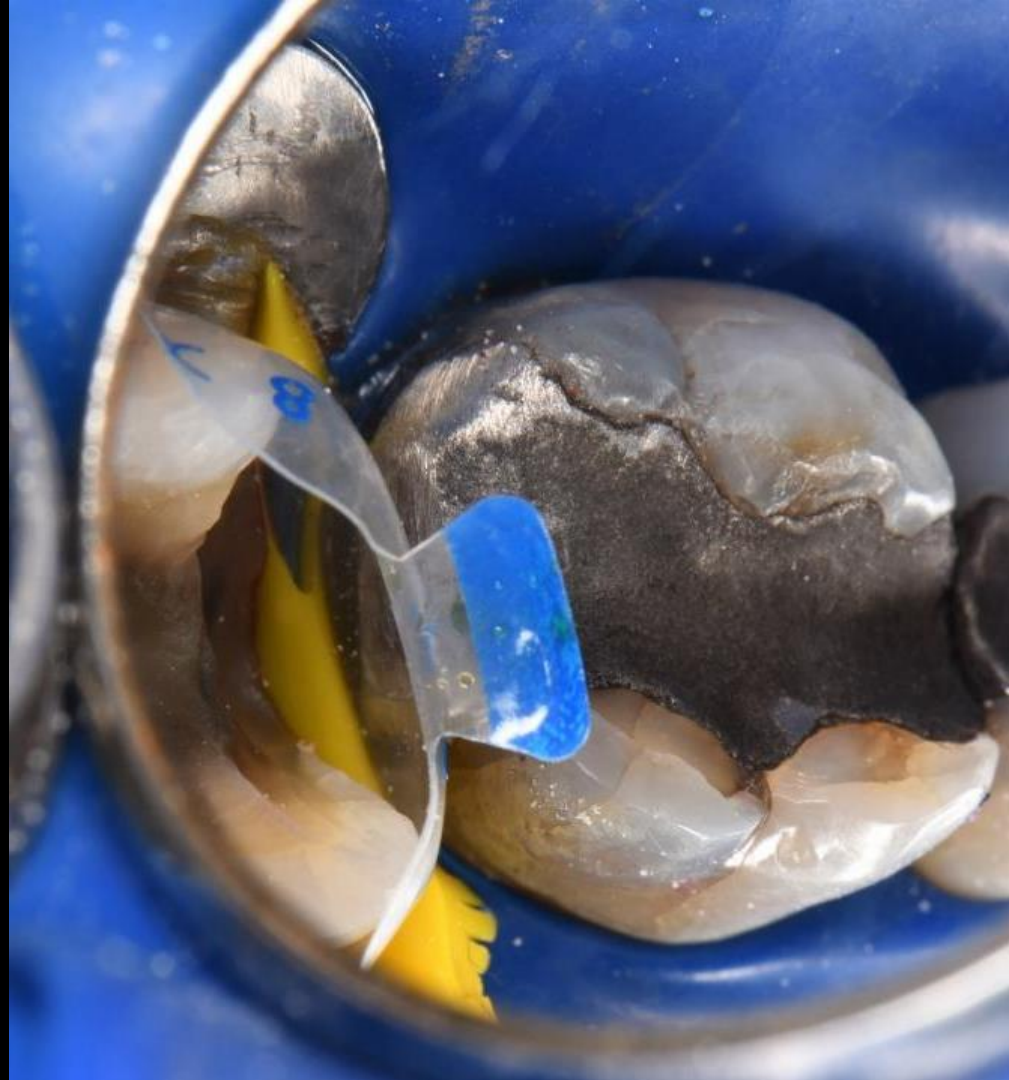Inside the prep to our reference = 6mm

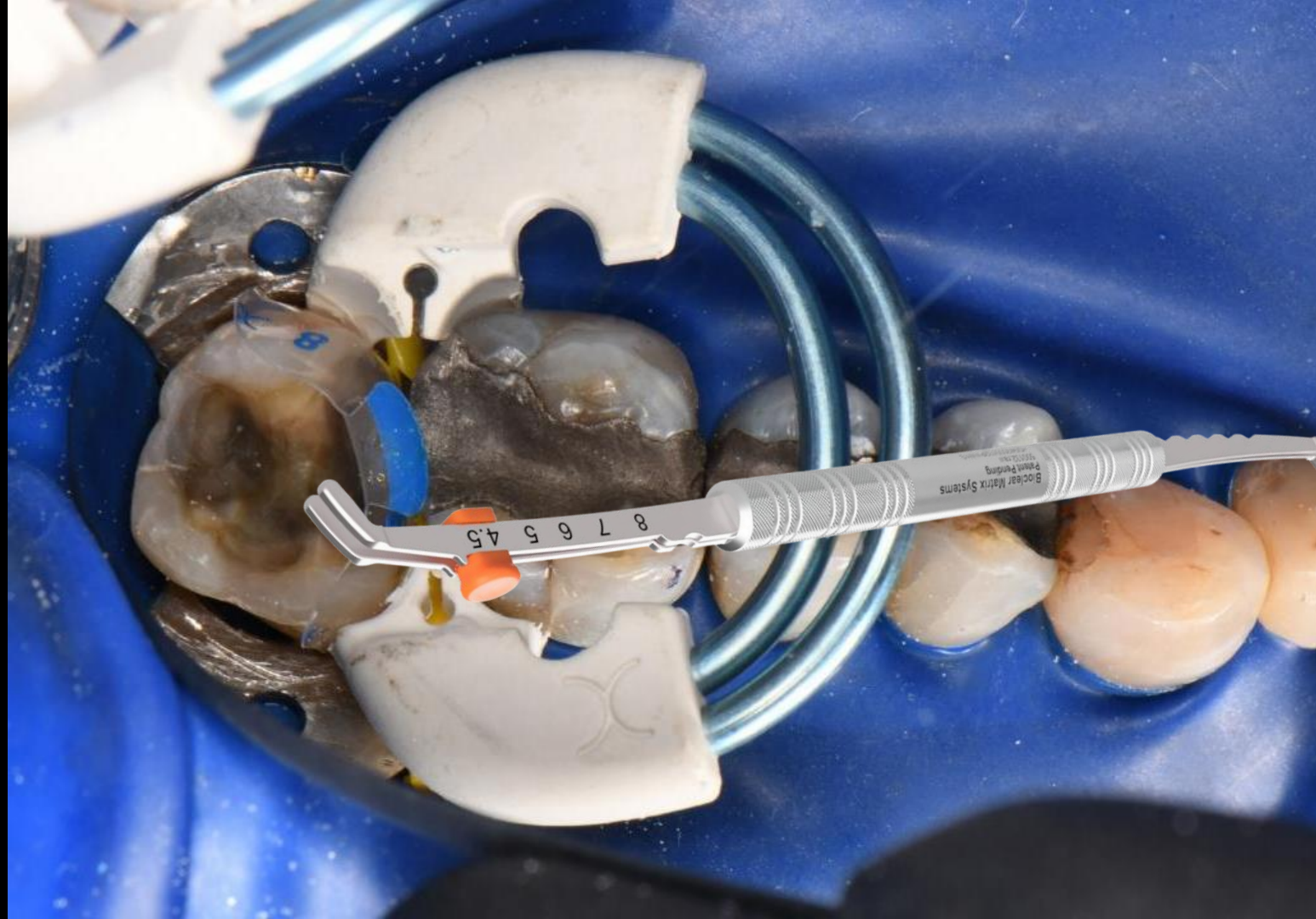- What Evolve matrix color should you choose and what height?
- What's my reference?

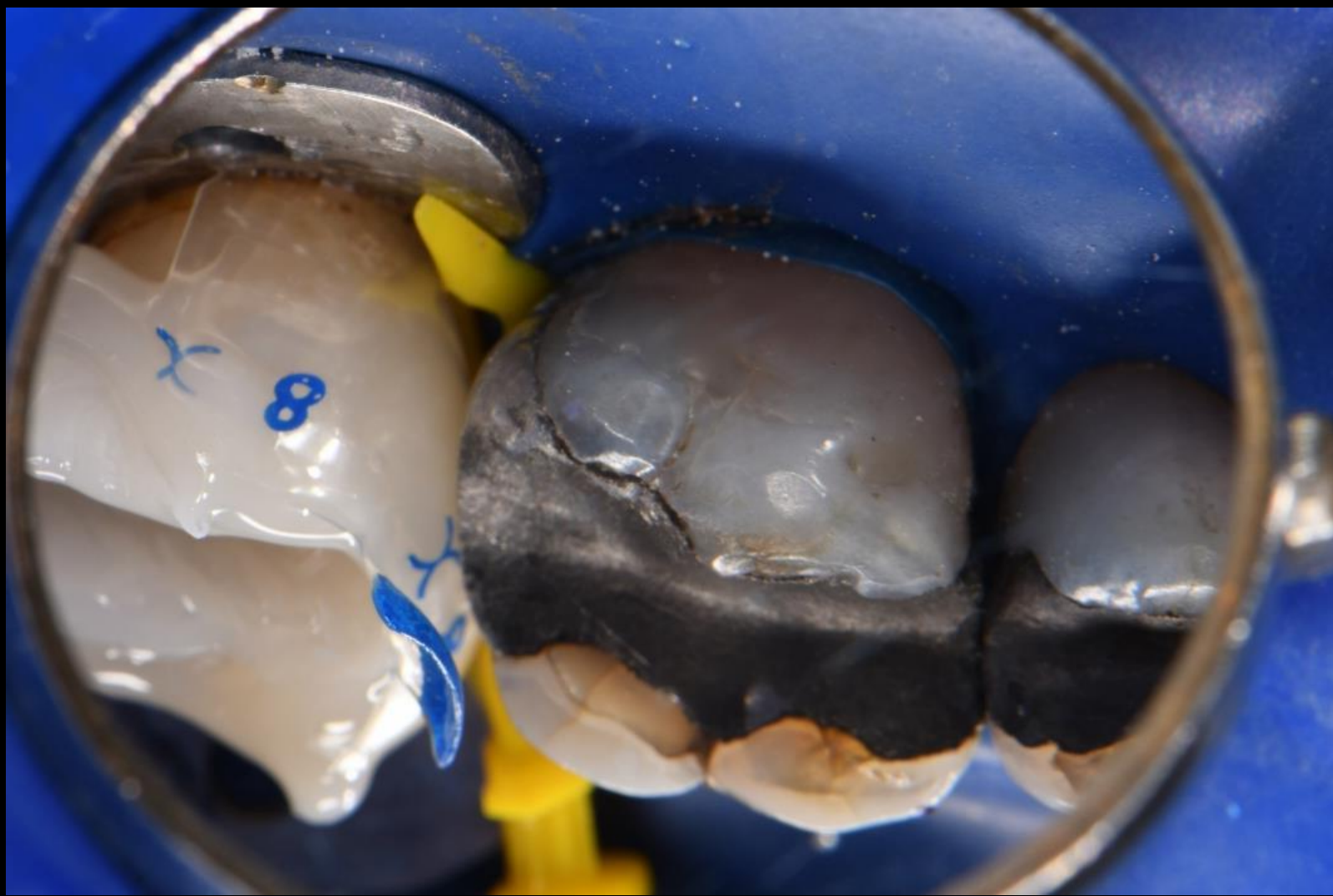




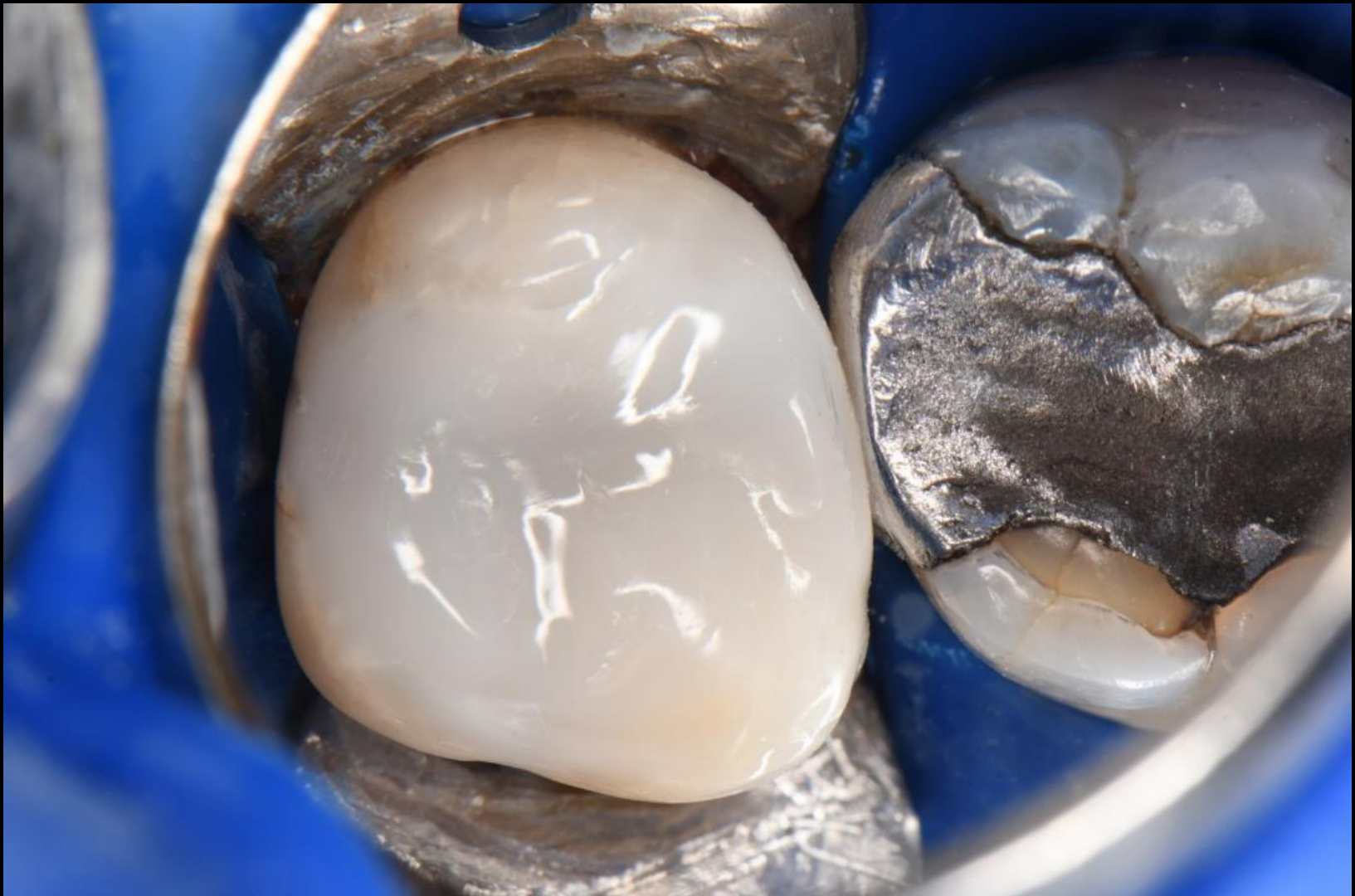


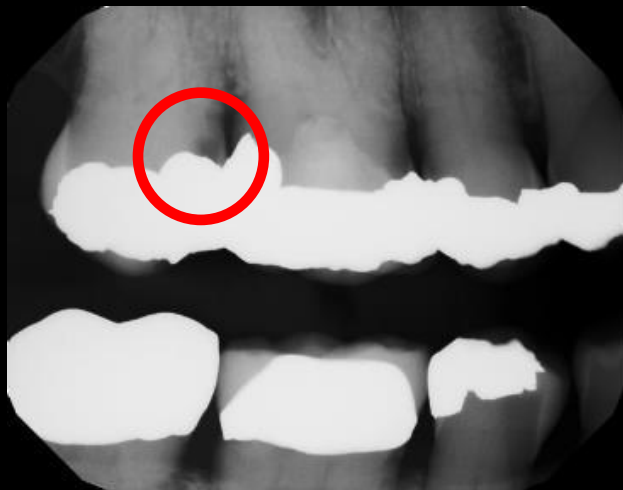




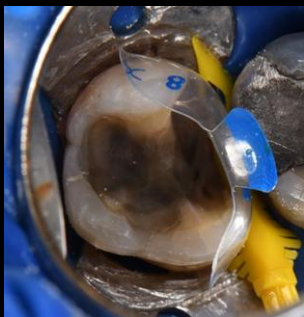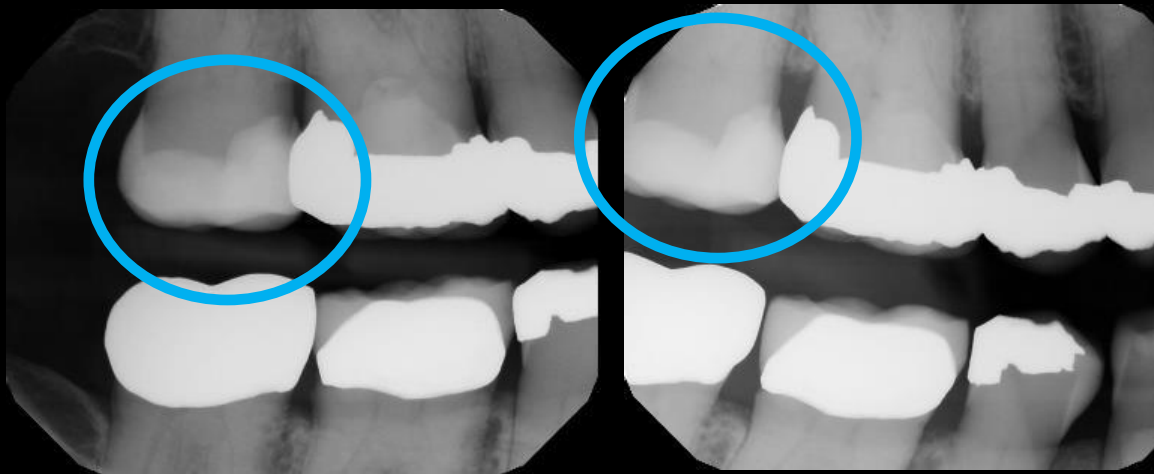




Pre-op



Post-op (two views)

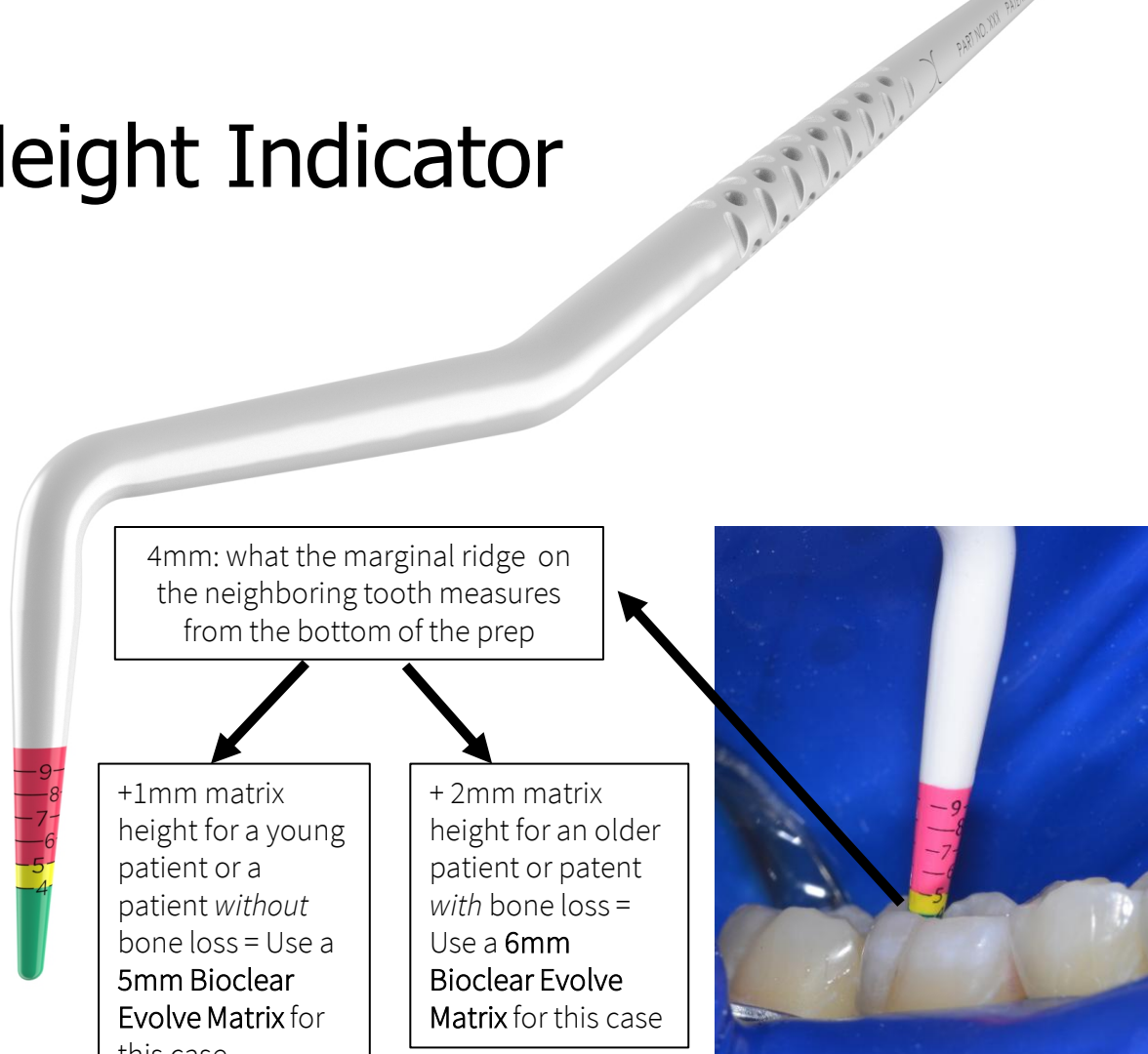


Evolve Matrix Height Indicator

Matrix Height Indicator:

Numbers are printed on the indicator so the correct Evolve matrix for a restoration is chosen the first time. This helps reduce waste when incorrect matrices are chosen.

Once you have measured the depth of the cavity in relation to the marginal ridge of the neighboring tooth, you will generally need to add 1-2mm from that reading.



Evolve Matrix Height Indicator

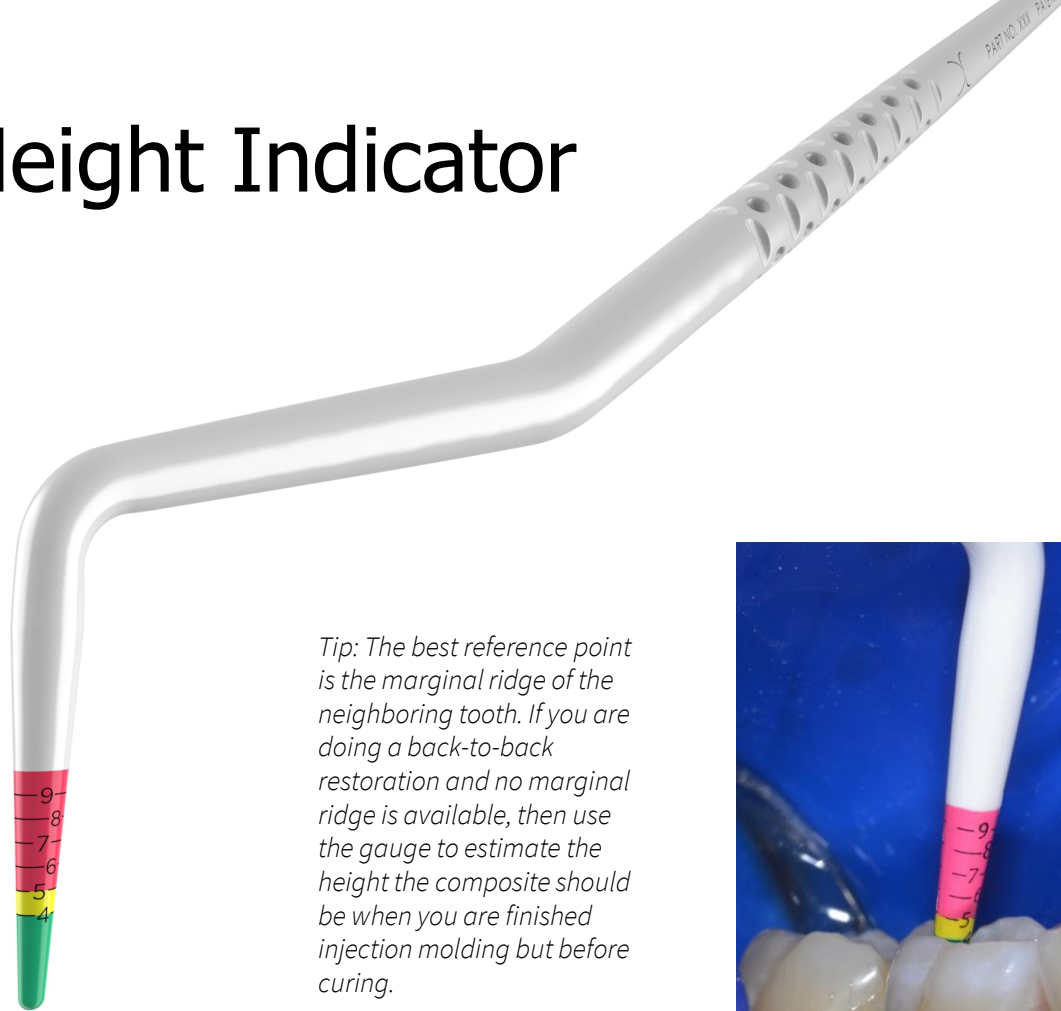Go/No-Go:

The colored tip indicates if a cavity prep can be cured in one layer or if more must be used.

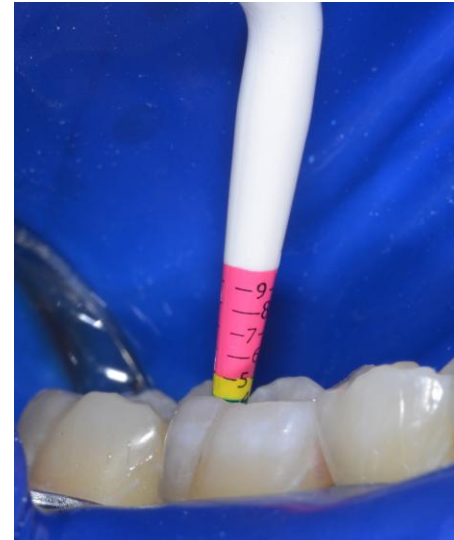Red: NO-GO the composite will be deeper than 5mm

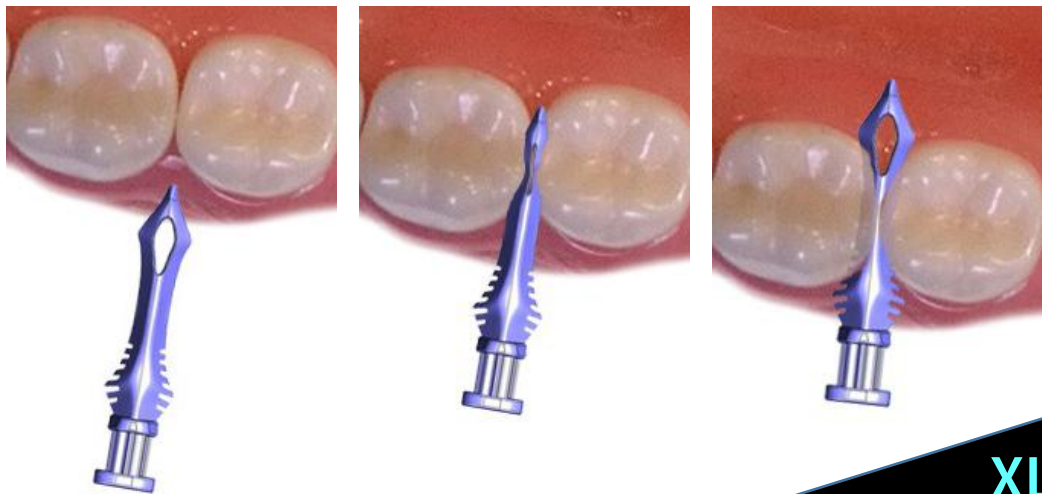Yellow: GO WITH CONDITIONS

Green: GO



Tip: The best reference point is the marginal ridge of the neighboring tooth. If you are doing a back-to-back restoration and no marginal ridge is available, then use the gauge to estimate the height the composite should be when you are finished injection molding but before curing.





 **DIAMOND**
WEDGE



The modern composite procedure

- Adhesion versus mechanical retention
- Preparation design based on engineering
- Compression Joints vs Tension Joints
- Biofilm Removal and the Infinity EdgeTooth Restoration Interface
- **Selective Caries Removal**
- Monolithic injection molding
- Rock Star Polish

110 YEARS OF DEDICATION TO ADVANCING ORAL HEALTH SCIENCE
JADA
 THE JOURNAL OF THE AMERICAN DENTAL ASSOCIATION
 JULY 2023

SMILECON 2023:
 Preview 643

SYSTEMATIC REVIEW
 Self-Assembling Peptide P₁₁₋₄ Use on Caries Lesions 580

INVESTIGATION
 Effects of In-Office Bleaching Agents on Nanofilled Resin Composite 592

CLINICAL REPORT
 The Prevalence and Severity of Enamel Craze Lines 601

COVER STORY
Restorative Treatments for Caries Lesions: ADA Clinical Practice Guideline 551

Diagram showing treatment options for caries lesions:
 Cervical third of facial or lingual (Class V) → Amalgam, conventional GIC, or resin-modified GIC
 Cervical third of facial or lingual (Class V) → Pit and fissure (Class I) → Amalgam, resin composite, or resin-modified GIC
 Pit and fissure (Class I) → Resin-modified GIC or conventional GIC
 If not feasible → Conventional GIC

Table 1. Definitions of carious tissue removal approaches and clinical presentation of caries lesion.

CARIOUS TISSUE REMOVAL APPROACHES (THAT IS, THE EXTENT OF CARIOUS TISSUE REMOVED)

Nonselective Caries Removal	Carious tissue is removed until hard dentin is reached. Also known as complete caries removal.
Selective Caries Removal	Carious tissue is removed until soft or firm dentin is reached. Also known as partial or incomplete caries removal.
Stepwise Caries Removal	Carious tissue is first removed until soft dentin is reached and then a temporary restoration is placed. Months later, the restoration and carious tissue are removed until firm dentin is reached and a permanent restoration is then placed. Also known as 2-step caries removal.
No Carious Tissue Removal	No carious tissue is removed prior to the placement of a definitive restoration.

CLINICAL PRESENTATION OF CARIES LESIONS

Moderate Caries Lesion	International Caries Detection and Assessment System codes 3 and 4
Advanced Caries Lesion	International Caries Detection and Assessment System codes 5 and 6

Clinical Practice Guideline
Cover Story
Evidence-based clinical practice guideline on restorative treatments for caries lesions
 A report from the American Dental Association

ABSTRACT
Background. An expert panel convened by the American Dental Association (ADA) Council on Scientific Affairs together with the ADA Science and Research Institute's program for Clinical and Translational Research conducted a systematic review and developed recommendations for the treatment of moderate and advanced cavitated caries lesions in patients with vital, non-endodontically treated primary and permanent teeth.
Types of Studies Reviewed. The authors searched for systematic reviews comparing carious tissue removal (CTR) approaches in Ovid MEDLINE, Embase, Cochrane Database of Systematic Reviews, and Trip Medical Database. The authors also conducted a systematic search for randomized controlled trials comparing direct restorative materials in Ovid MEDLINE, Embase, Cochrane Central Register of Controlled Trials, ClinicalTrials.gov, and the World Health Organization International Clinical Trials Registry Platform. The authors used the Grading of Recommendations Assessment, Development, and Evaluation approach to assess the certainty of the evidence and formulate recommendations.
Results. The panel formulated 16 recommendations and good practice statements: 4 on CTR approaches specific to lesion depth and 12 on direct restorative materials specific to tooth location and surfaces involved. The panel conditionally recommended for the use of conservative CTR approaches, especially for advanced lesions. Although the panel conditionally recommended for the use of all direct restorative materials, they prioritized some materials over the use of others for certain clinical scenarios.
Practical implications. The evidence suggests that more conservative CTR approaches may decrease the risk of adverse effects. All included direct restorative materials may be effective in treating moderate and advanced caries lesions on vital, nonendodontically treated primary and permanent teeth.
Key Words. Evidence-based dentistry; clinical practice guideline; direct restorative materials; caries; general dentistry; pediatric dentistry; American Dental Association.

JADA 2023;154(7):551-566
<https://doi.org/10.1016/j.jada.2023.04.011>

Restorative dentistry is integral to managing caries.¹ The decisions involved in restoring teeth are complex and based on the balance of several factors such as prognosis, caries risk and activity assessment, and clinical or radiographic signs of caries.^{2,3} When indicated, various carious tissue removal (CTR) approaches (that is, the extent of carious tissue removed) and direct restorative materials are available to restore moderate and advanced (Table 1) caries lesions on vital, nonendodontically treated primary and permanent teeth.

Copyright © 2023 American Dental Association. All rights reserved.

JADA 154(7) • <http://jada.ada.org> • July 2023

551





Table 1. Definitions of carious tissue removal approaches and clinical presentation of caries lesion.

CARIOUS TISSUE REMOVAL APPROACHES (THAT IS, THE EXTENT OF CARIOUS TISSUE REMOVED)	
Nonselective Caries Removal	Carious tissue is removed until hard dentin is reached. Also known as complete caries removal.
Selective Caries Removal	Carious tissue is removed until soft or firm dentin is reached. Also known as partial or incomplete caries removal.
Stepwise Caries Removal	Carious tissue is first removed until soft dentin is reached and then a temporary restoration is placed. Months later, the restoration and carious tissue are removed until firm dentin is reached and a permanent restoration is then placed. Also known as 2-step caries removal.
No Carious Tissue Removal	No carious tissue is removed prior to the placement of a definitive restoration.

CLINICAL PRESENTATION OF CARIES LESIONS	
Moderate Caries Lesion	International Caries Detection and Assessment System codes 3 and 4
Advanced Caries Lesion	International Caries Detection and Assessment System codes 5 and 6


“To treat **moderate caries lesions** of vital permanent teeth, the panel suggests prioritizing the use of SCR over nonselective i.e., complete caries removal.”

Evidence to Decisions: 1) Desirable and **undesirable effects**, 2) Values and preferences, 3) Cost, 4) Acceptability, 5) Feasibility



“Undesirable effects of traditional caries removal: Patient discomfort during treatment, pulp exposure, pulp necrosis, pulpal complications due to infection, and tooth loss.”

July 2023



Selective Caries Removal (SCR) is the new standard of care

BOOM!*

*Just one hundred and thirty-three years later


JCDA article the next month (August 2023)

ADA Publishes Guideline on Restorative Treatments for Caries Lesions

A new American Dental Association (ADA) clinical practice guideline suggests conservative methods to treat tooth decay in primary and permanent teeth could lead to better outcomes when used with common restorative materials. An expert panel of dentists developed guidelines on this topic after extensive review of approximately 300 published studies.

The guideline, published in the July 2023 issue of *The Journal of the American Dental Association*, contains 16 recommendations regarding treatment of moderate and advanced tooth decay in primary and permanent teeth that have not received orthodontic treatment. It suggests that conservative carious tissue removal (CTR) is less likely to result in adverse outcomes like nerve exposure or a failed filling. The recommendations also identify selective CTR as an effective treatment option in most cases of moderate or advanced decay in primary and permanent teeth.

This is the ADA's second clinical practice guideline in a series on caries treatment. The new restoration guideline, and existing recommendations on non-restorative treatment for tooth decay, are available at: ada.org/cariesguidelines *



“An expert panel developed guidelines after an extensive review of 300 published studies.”

“(SCR) is less likely to result in adverse outcomes...”


JCDA article the next month (August 2023)

ADA Publishes Guideline on Restorative Treatments for Caries Lesions

A new American Dental Association (ADA) clinical practice guideline suggests conservative methods to treat tooth decay in primary and permanent teeth could lead to better outcomes when used with common restorative materials. An expert panel of dentists developed guidelines on this topic after extensive review of approximately 300 published studies.

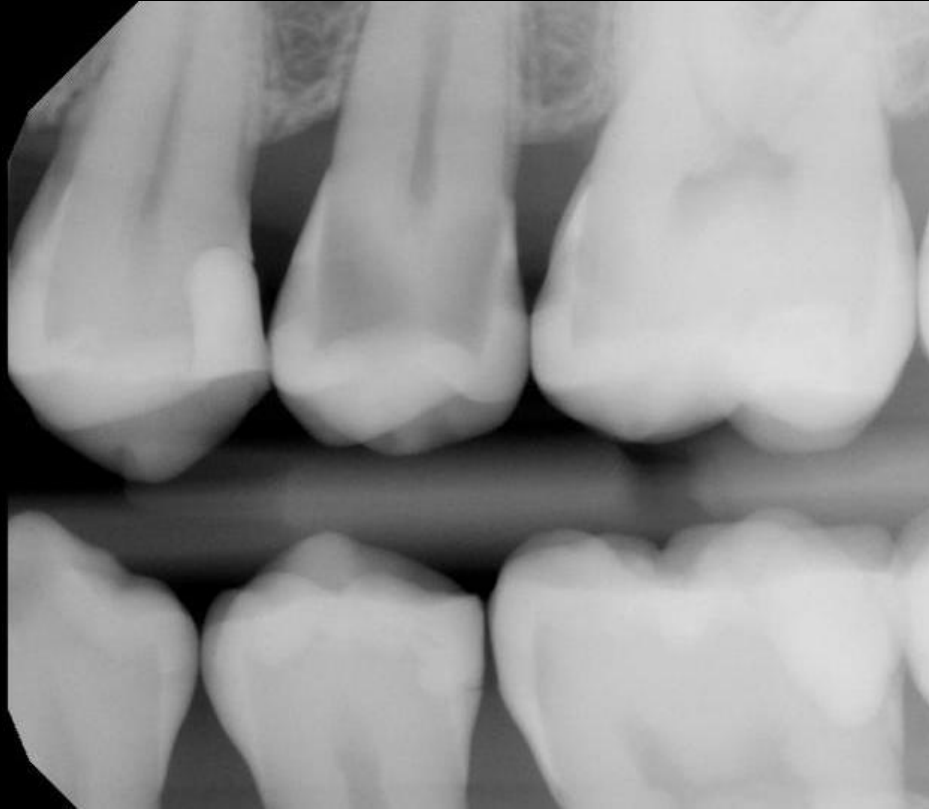
The guideline, published in the July 2023 issue of *The Journal of the American Dental Association*, contains 16 recommendations regarding treatment of moderate and advanced tooth decay in primary and permanent teeth that have not received orthodontic treatment. It suggests that conservative carious tissue removal (CTR) is less likely to result in adverse outcomes like nerve exposure or a failed filling. The recommendations also identify selective CTR as an effective treatment option in most cases of moderate or advanced decay in primary and permanent teeth.

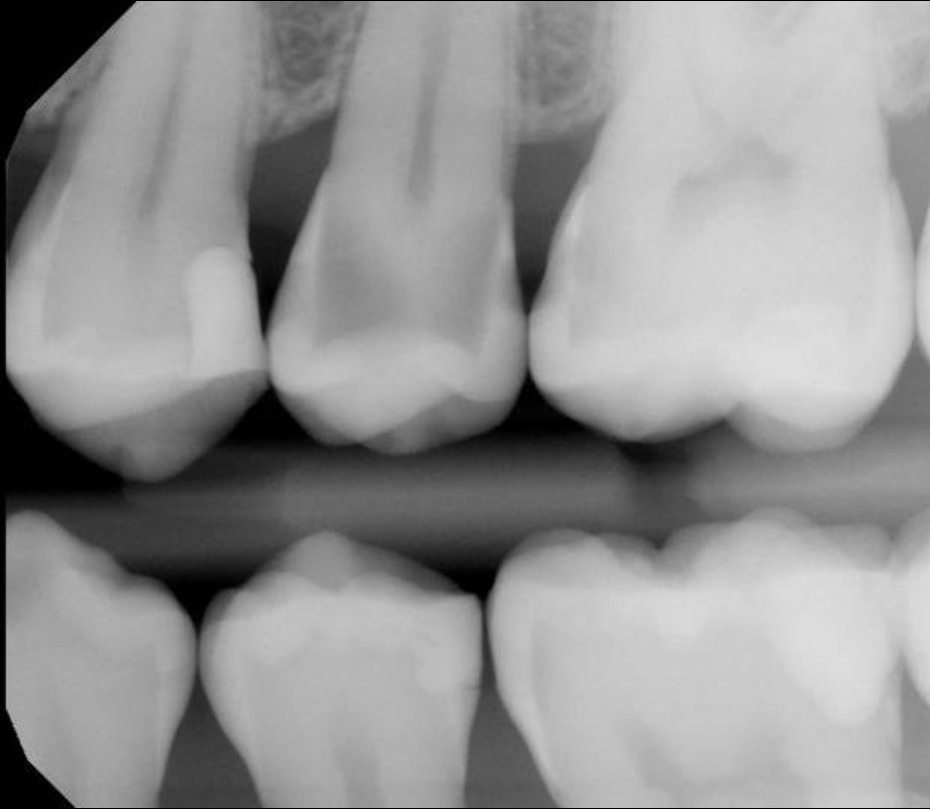This is the ADA's second clinical practice guideline in a series on caries treatment. The new restoration guideline, and existing recommendations on non-restorative treatment for tooth decay, are available at: ada.org/cariesguidelines *



“(SCR) Could lead to better outcomes with **ordinary restorative materials** (i.e. no more liners or bases)”

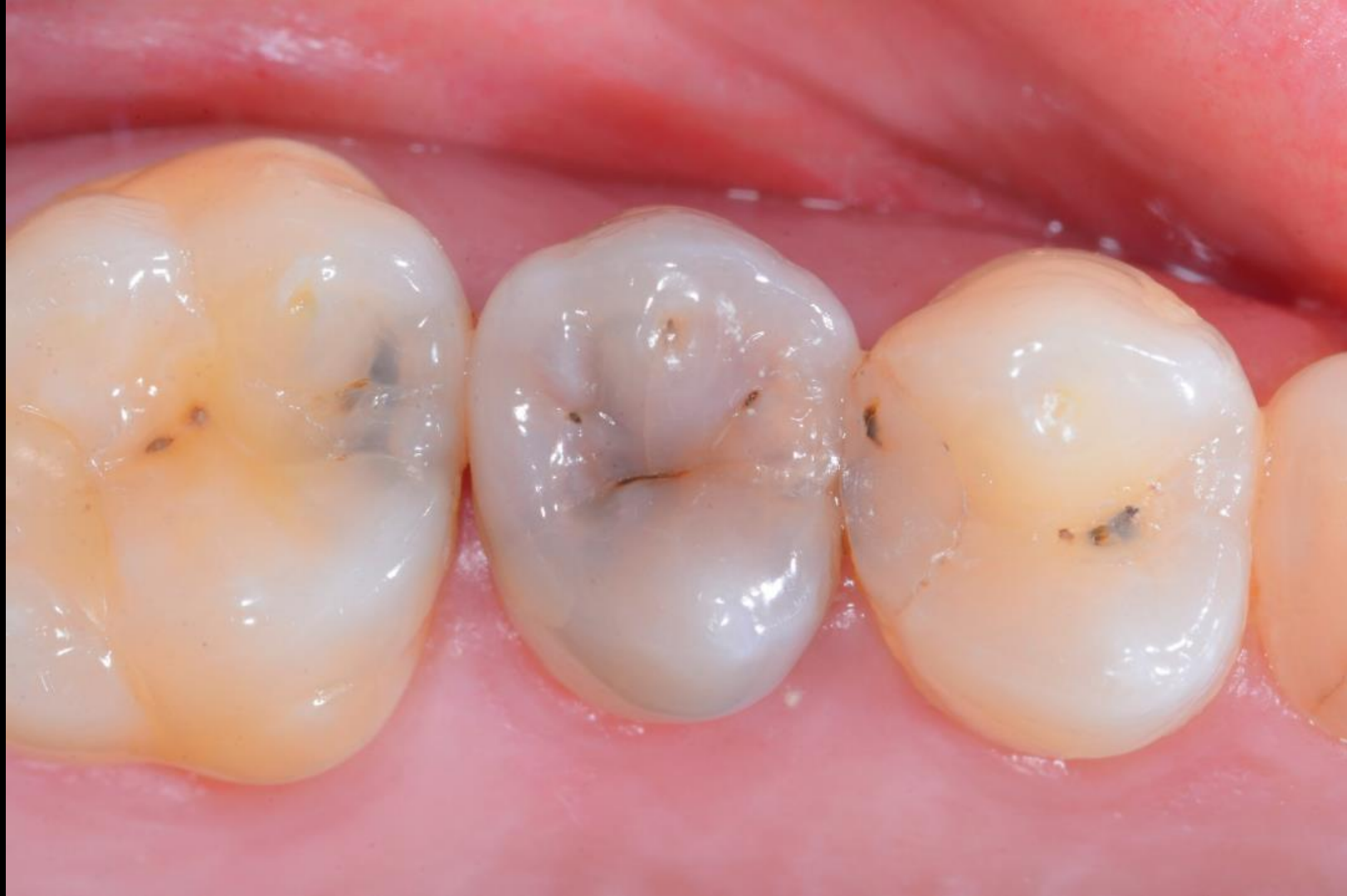Selective Caries Removal plus Deep Margin Acquisition clinical case





“Your website says you are a Certified Bioclear Provider offer the Selective Caries Technique (Modified Hall) as an alternative to root canals”

“My current office recommends endo, post, buildup & crown, but I have no pain”



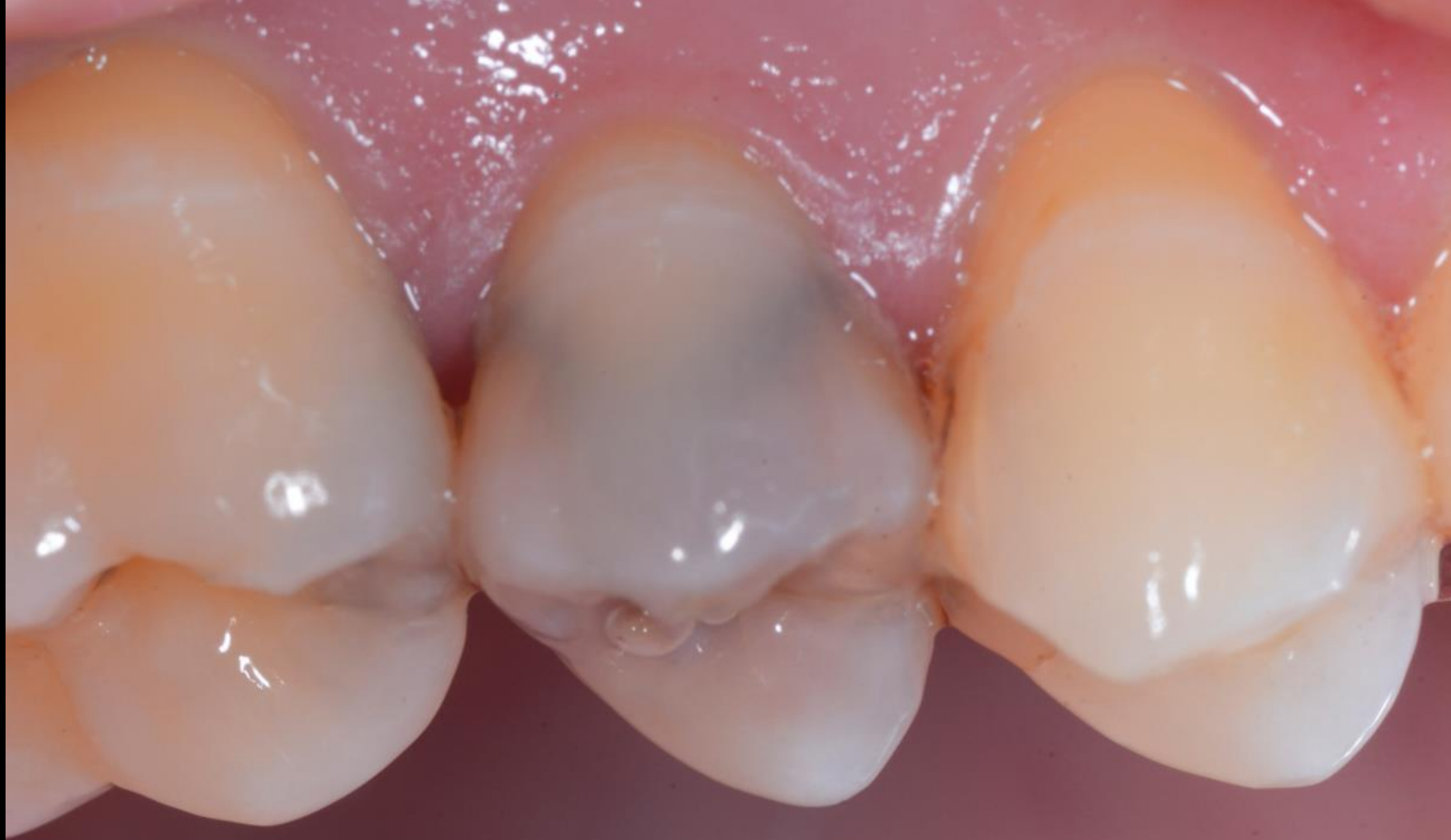11/10/20	BIO	2999A	Selective Caries Removal	13	\$175.00	\$0.00	\$175.00
----------	-----	-------	--------------------------	----	----------	--------	----------

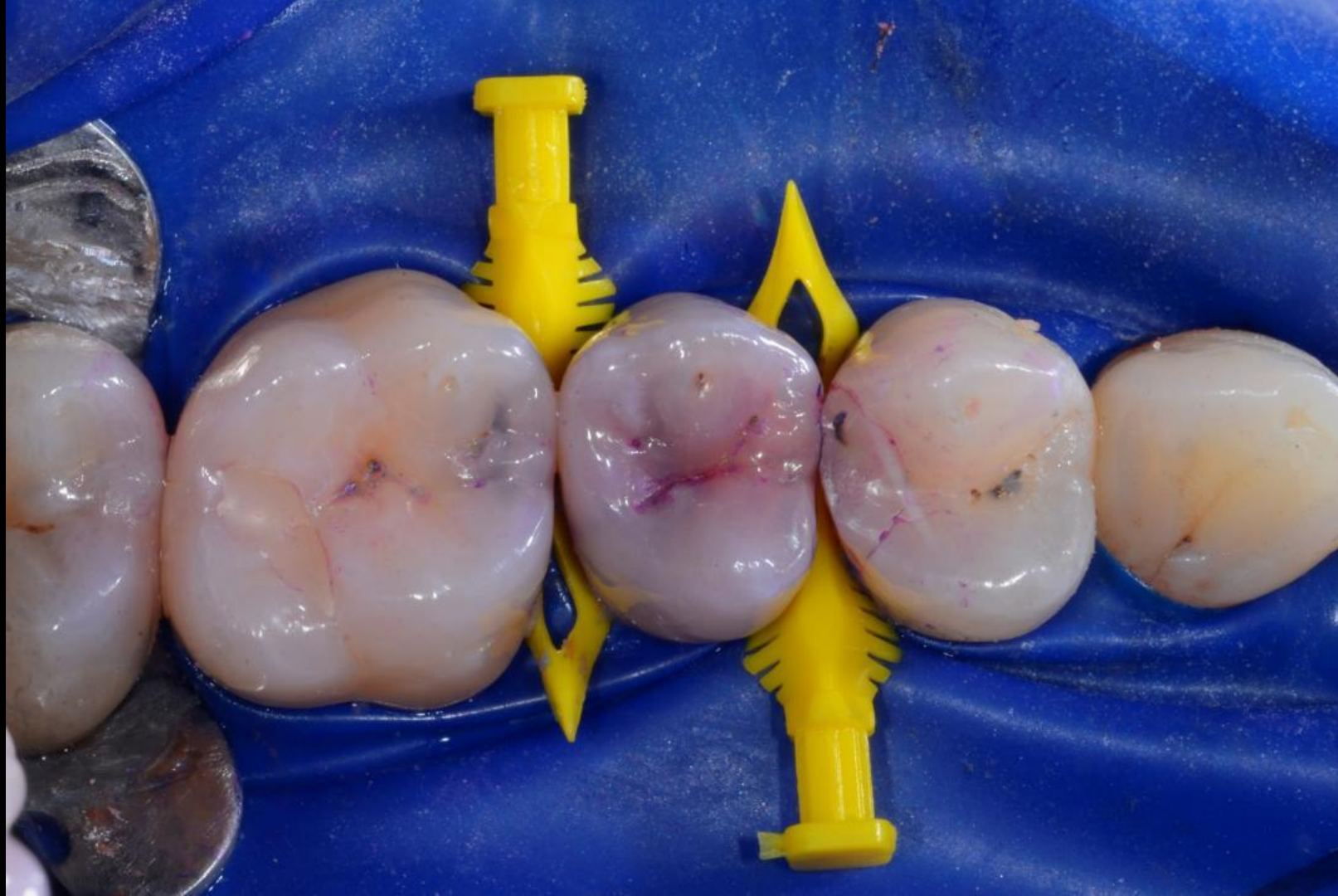Subtotal for This Phase:					\$175.00	\$0.00	\$175.00
---------------------------------	--	--	--	--	----------	--------	----------

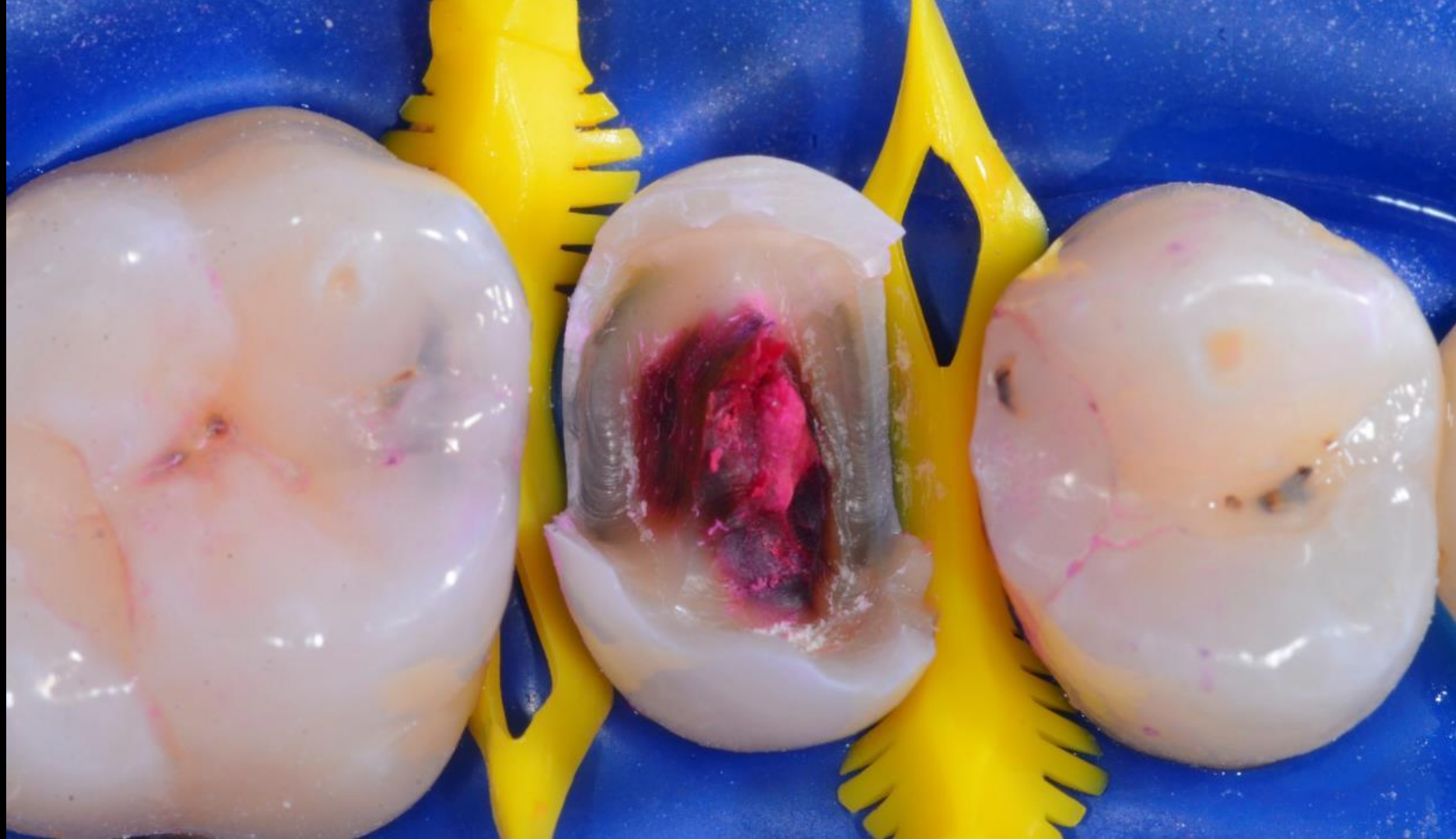11/10/20	BIO	299.8	BIOCLEAR POSTERIOR OVERLA	13	\$1,032.00	\$0.00	\$1,032.00
----------	-----	-------	---------------------------	----	------------	--------	------------

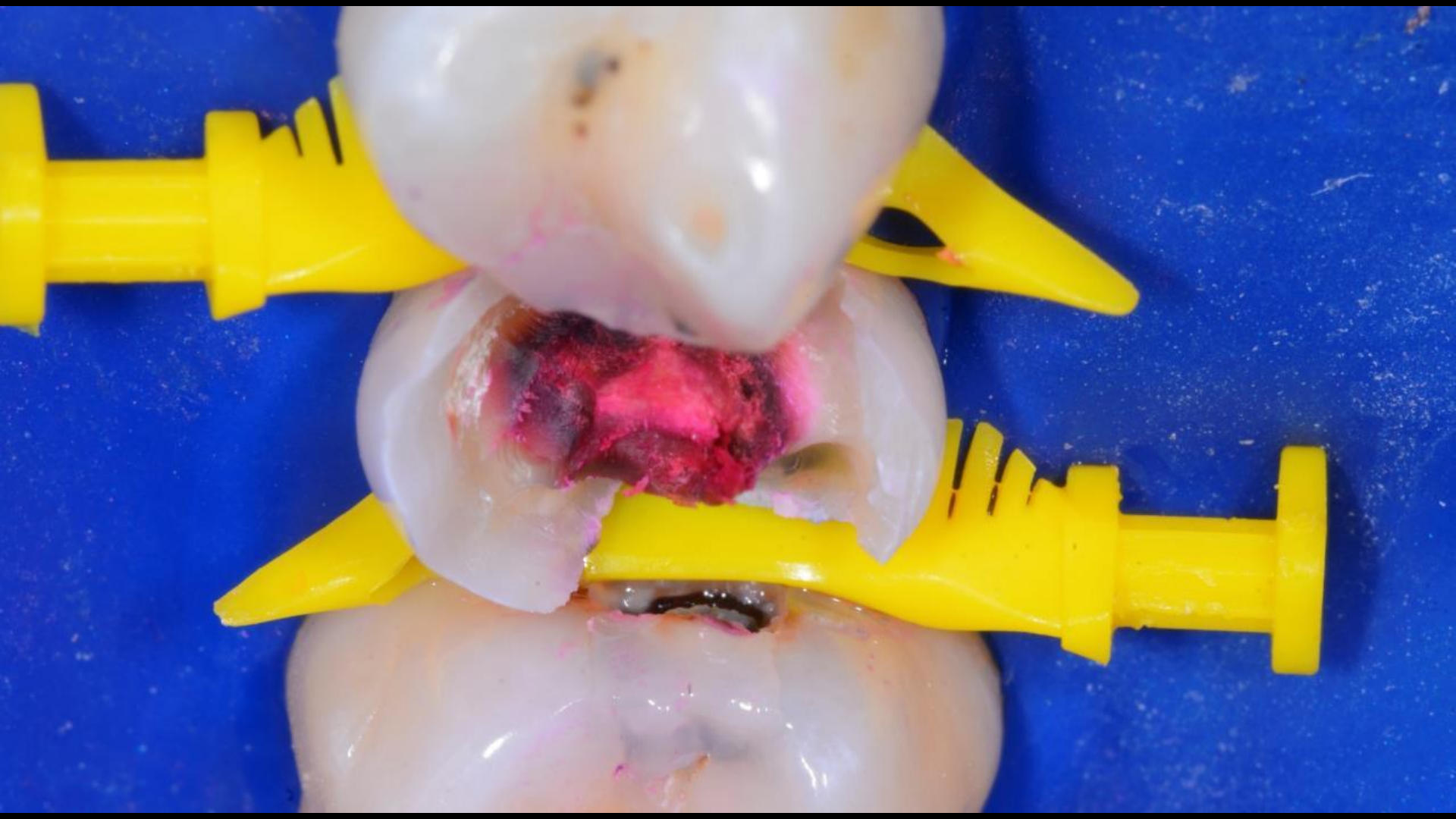Subtotal for This Phase:					\$1,032.00	\$0.00	\$1,032.00
---------------------------------	--	--	--	--	------------	--------	------------

\$1,207.00



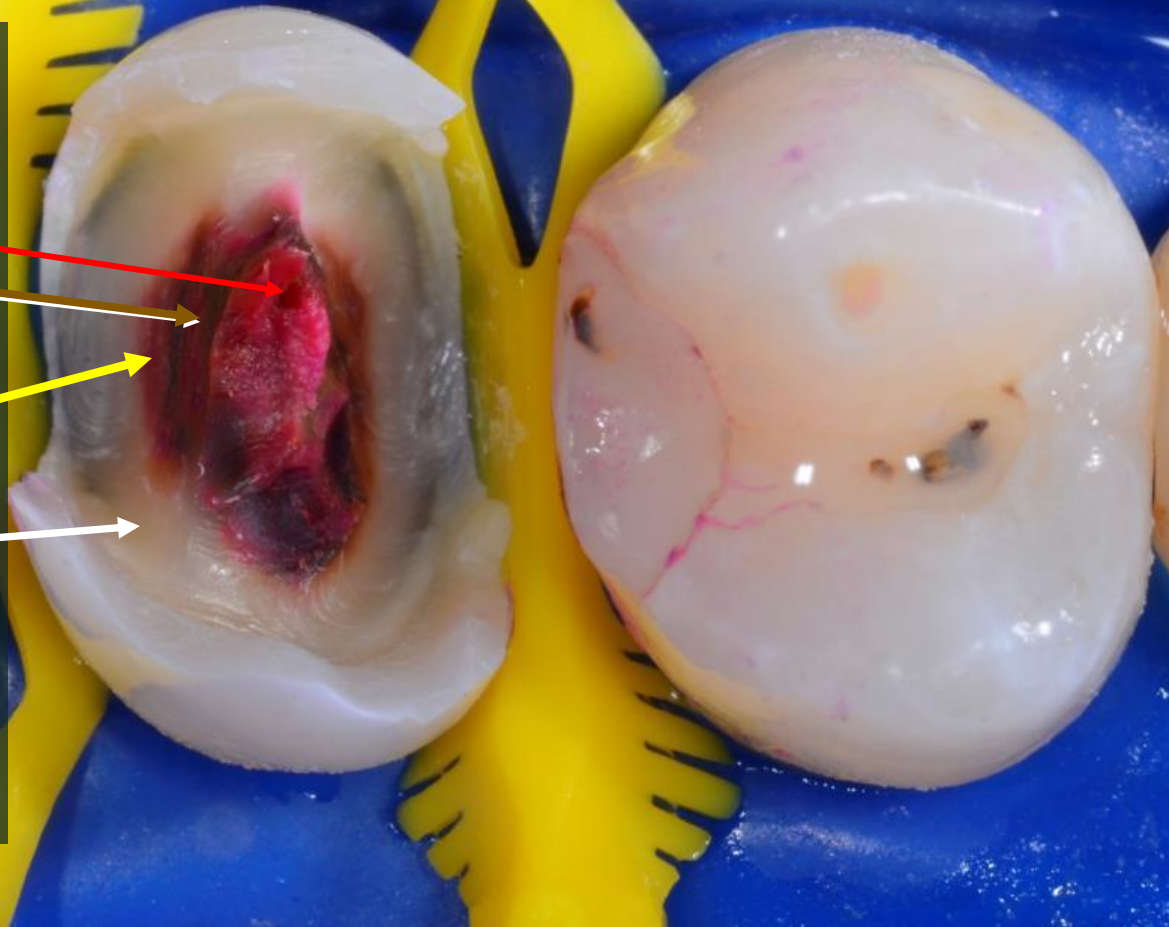






Simplification of dentin zones for restorative dentist:

- 1) **Loose Dentin**
- 2) **Smooth Soft Dentin**
- 3) **Affected Dentin:
hard-ish and funny color**
- 4) **Sound Dentin**



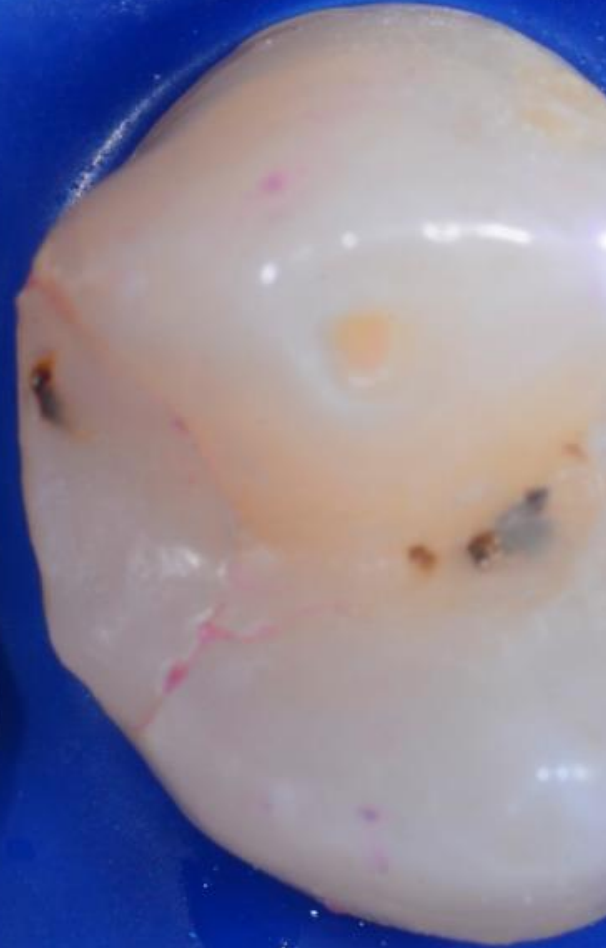
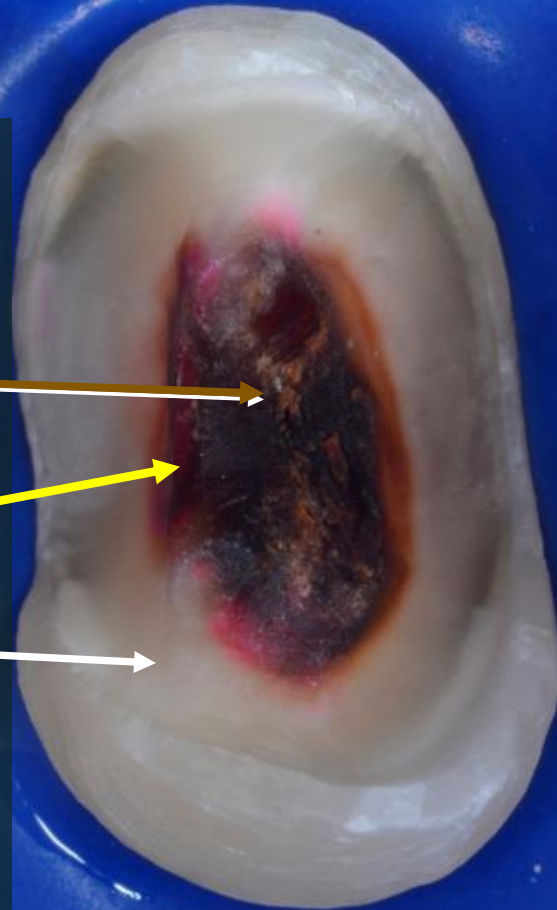
Simplification of dentin zones for restorative dentist:

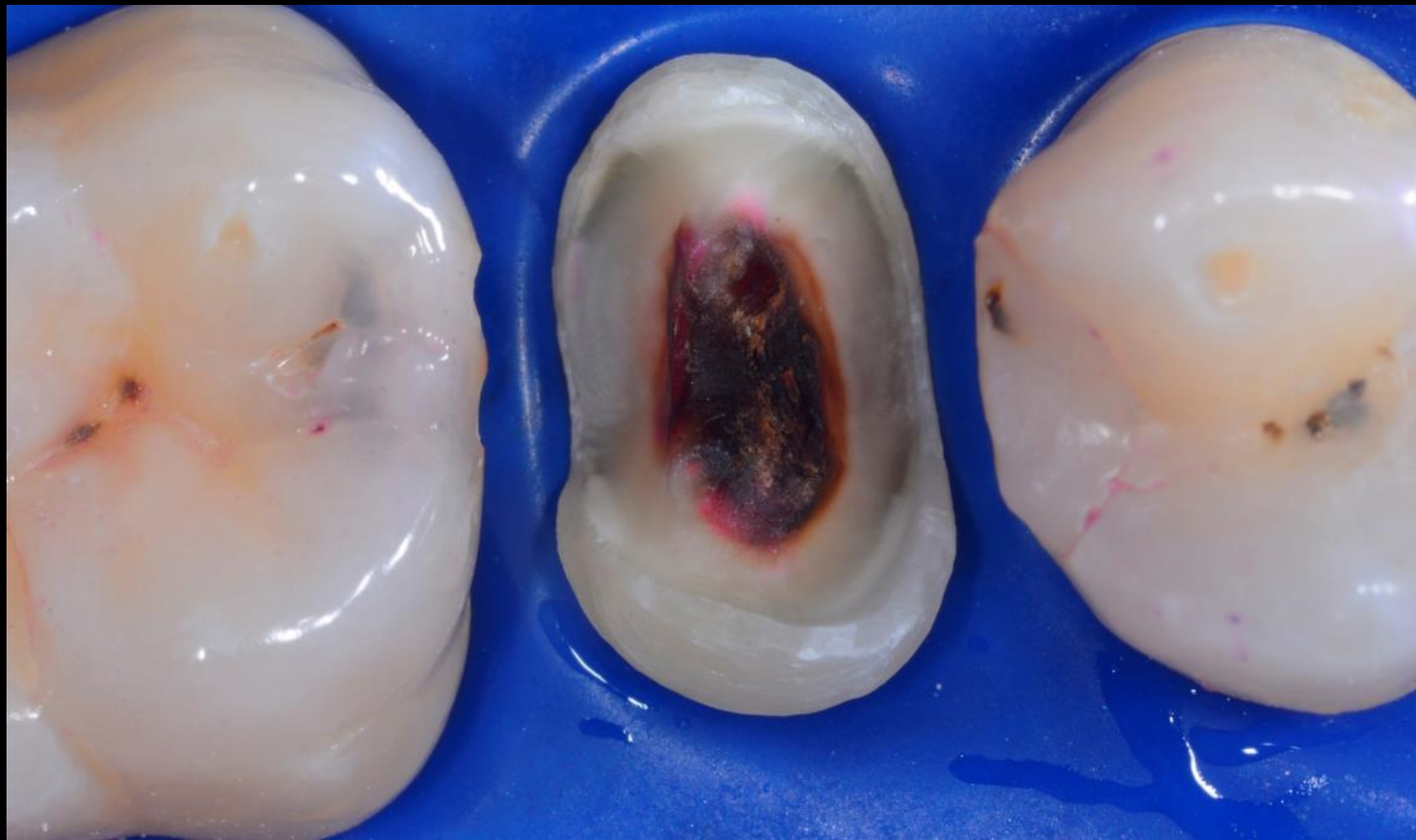1) **Loose Dentin**

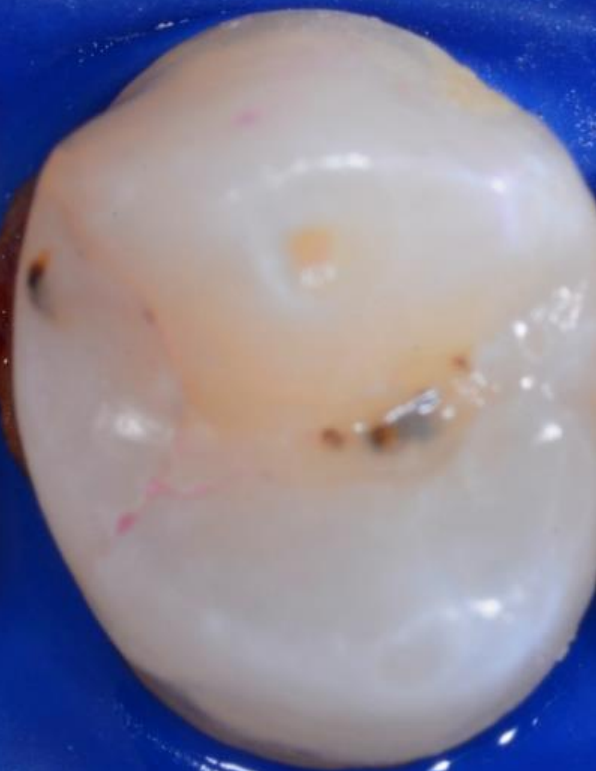
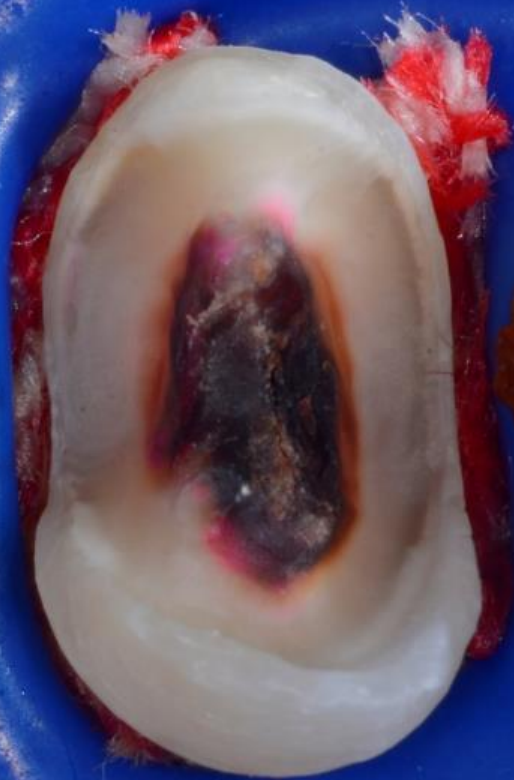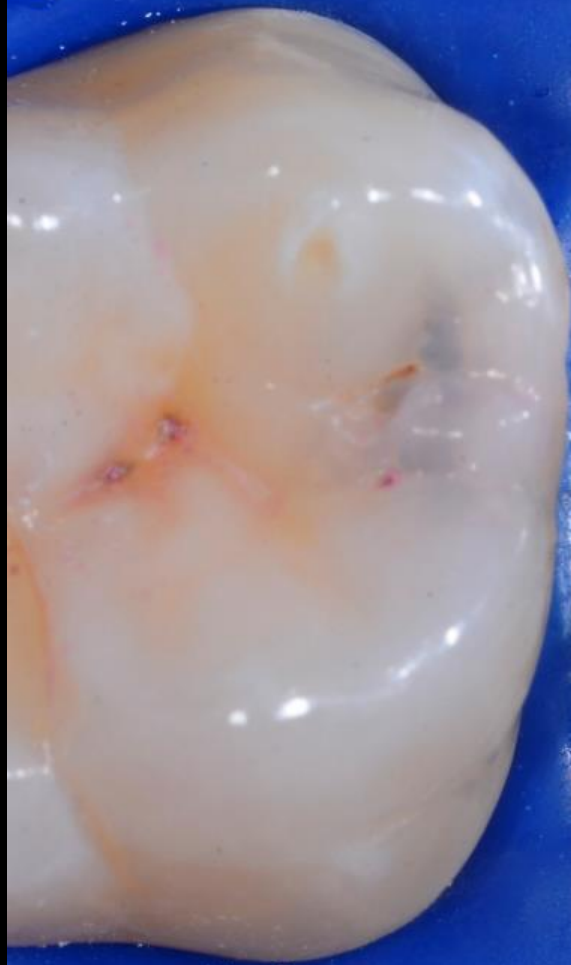
2) **Smooth Soft Dentin**

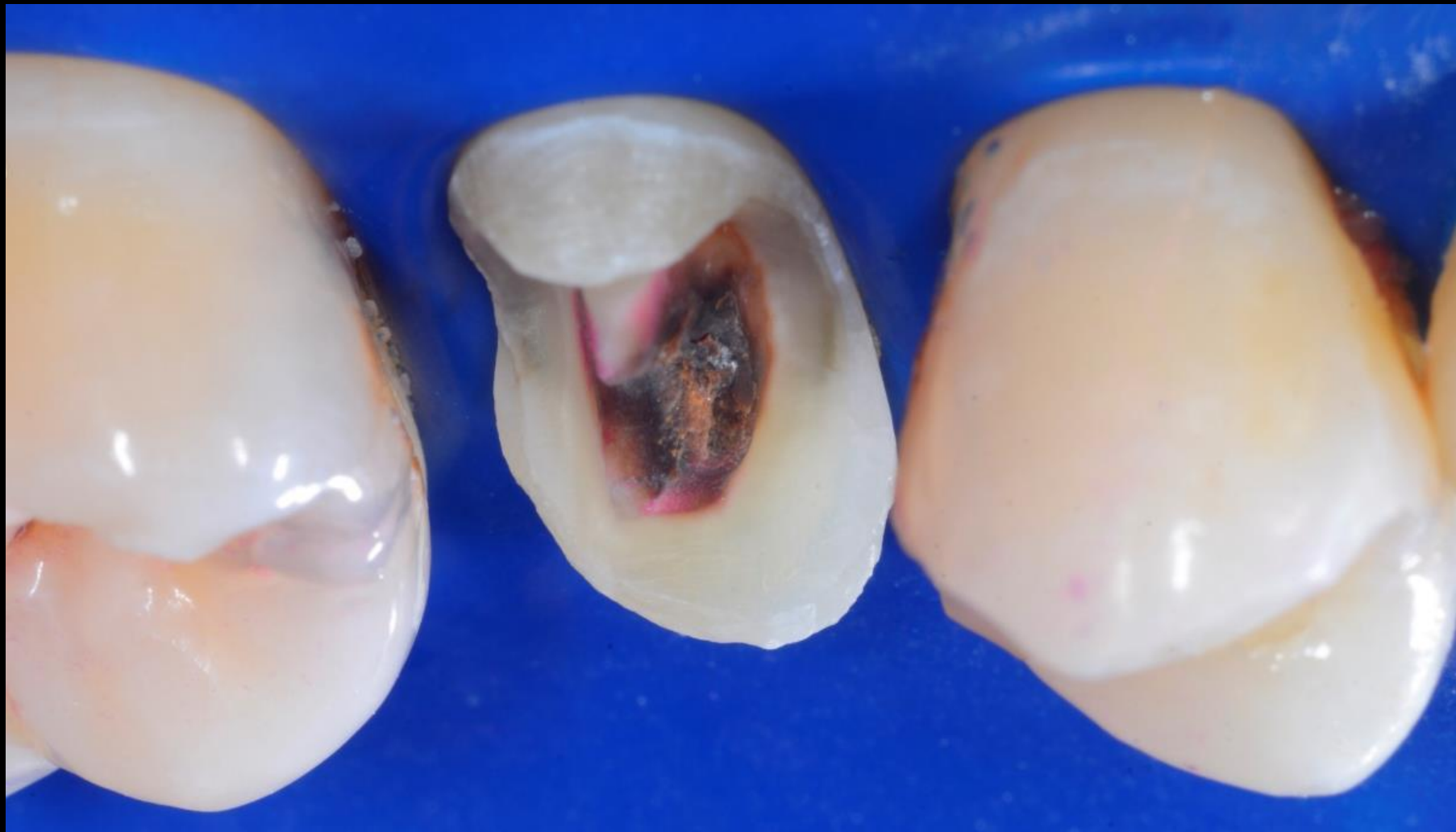3) **Affected Dentin:
hard-ish and funny color**

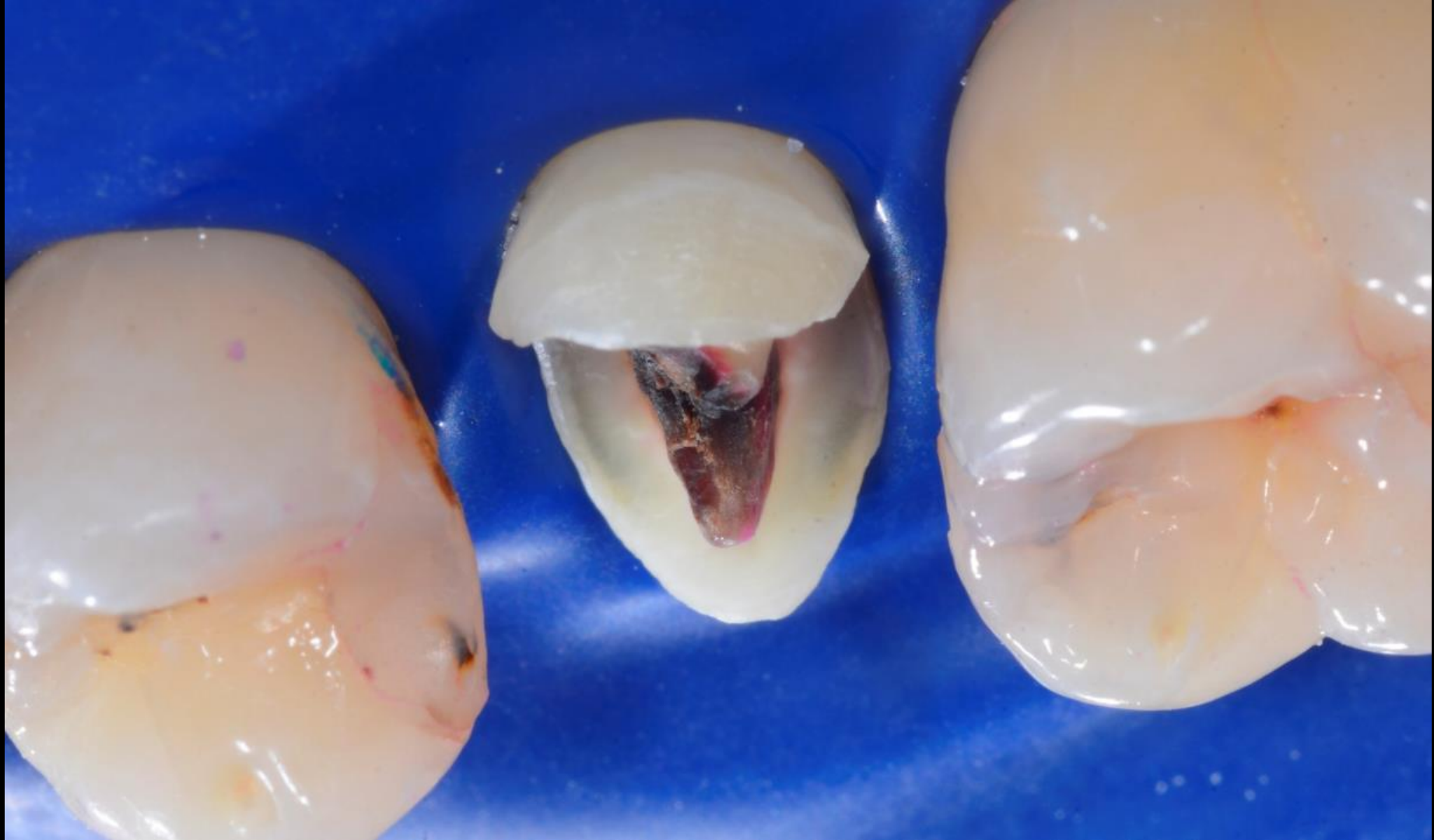4) **Sound Dentin**

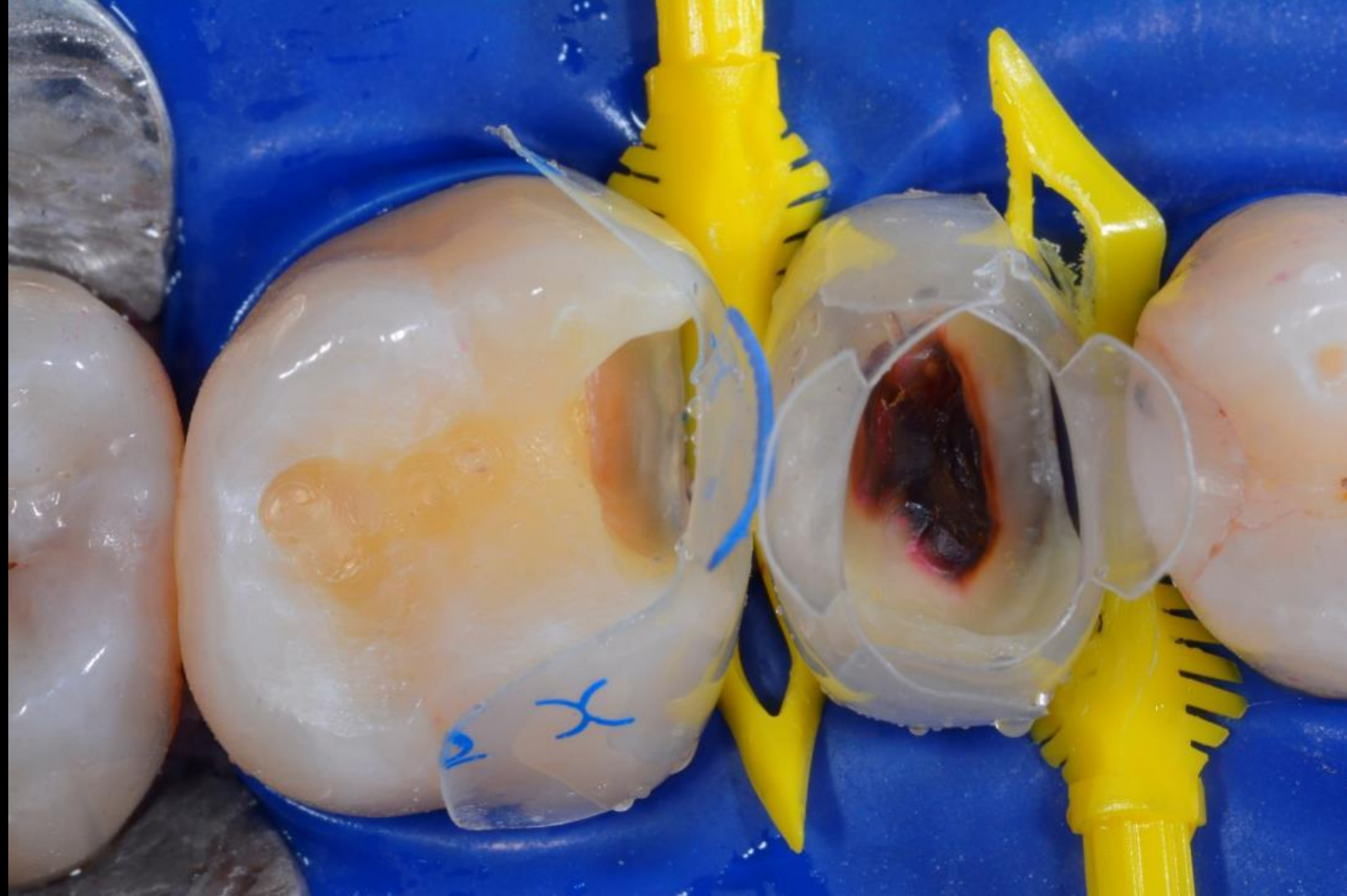


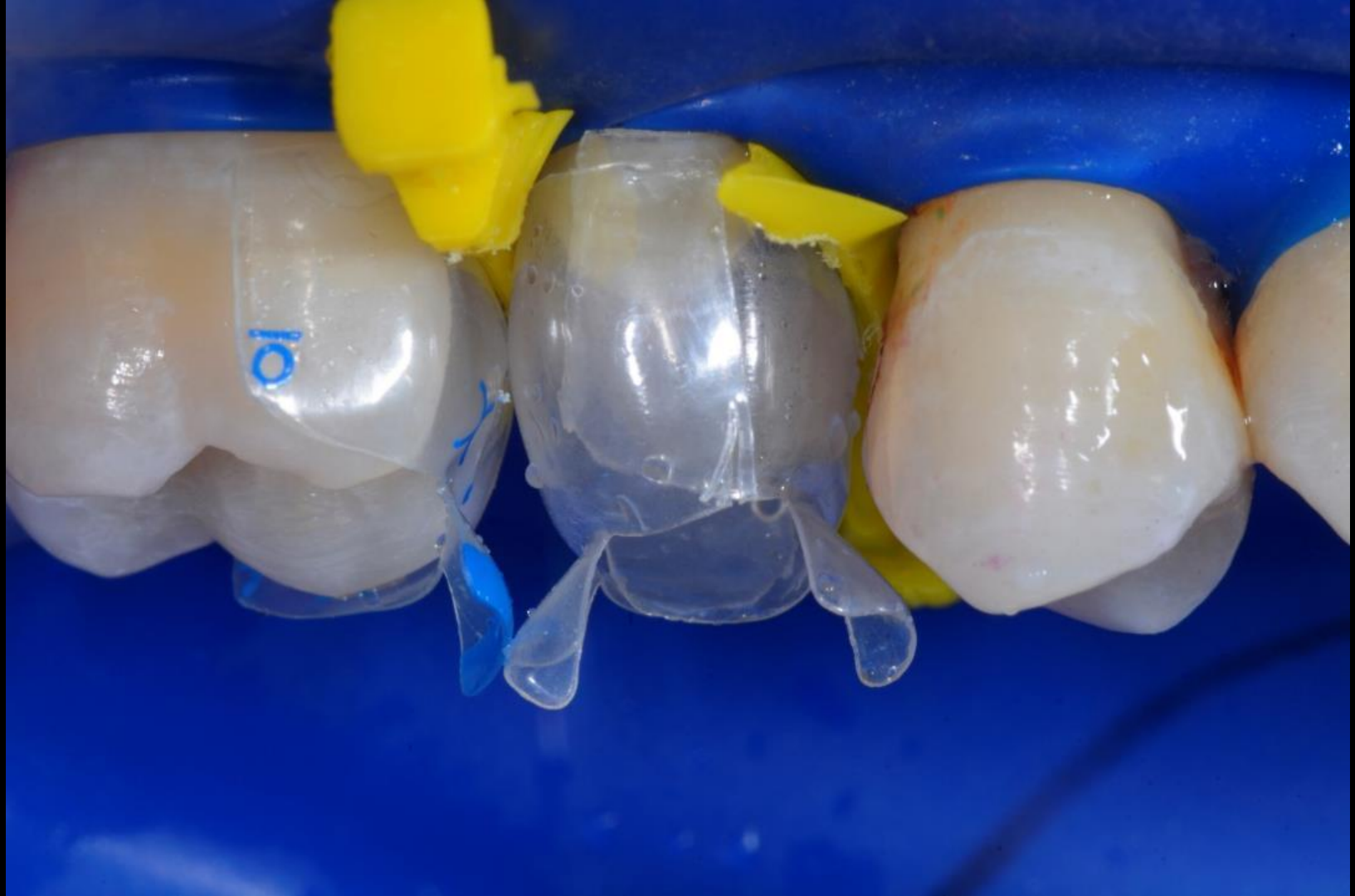


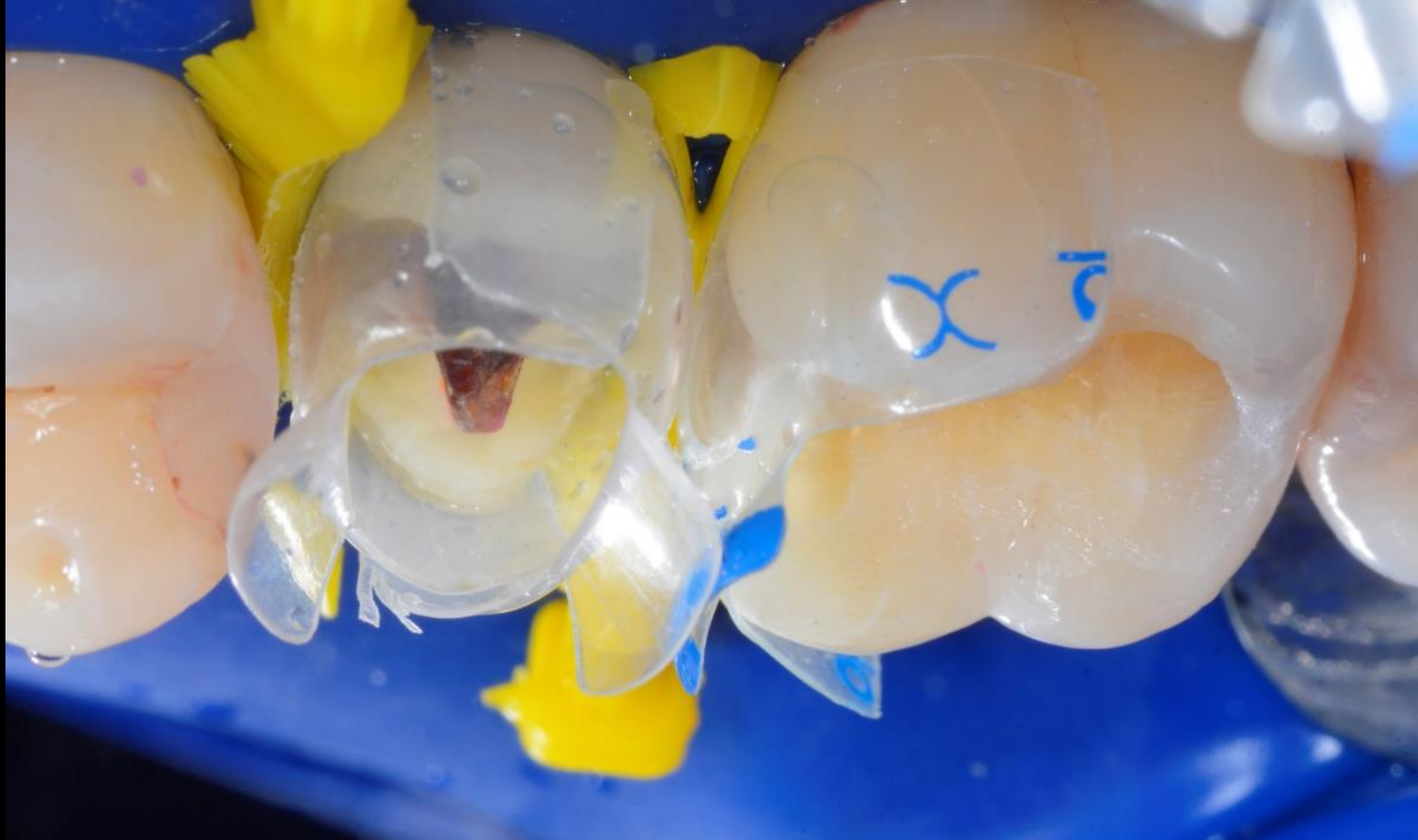




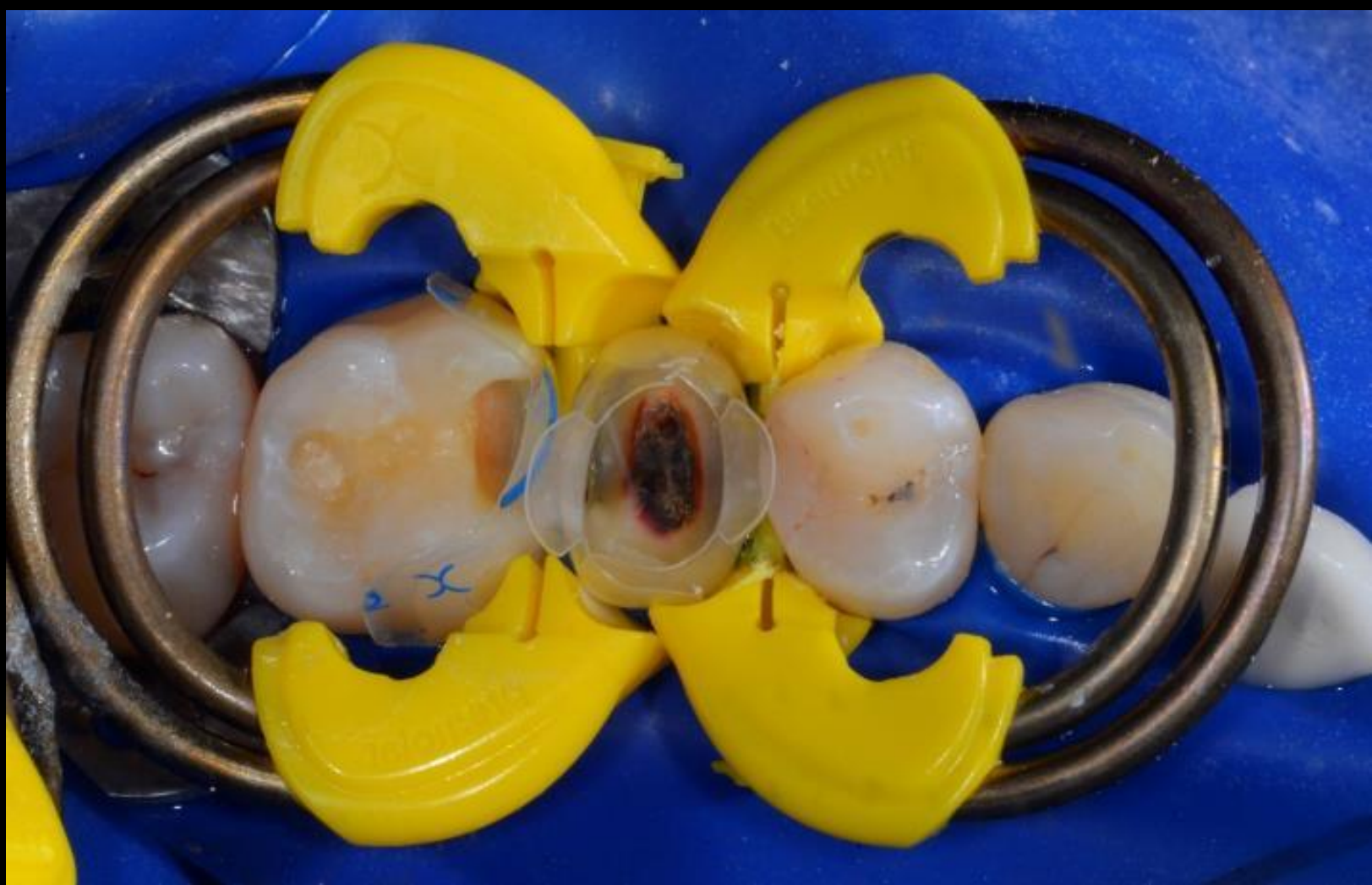




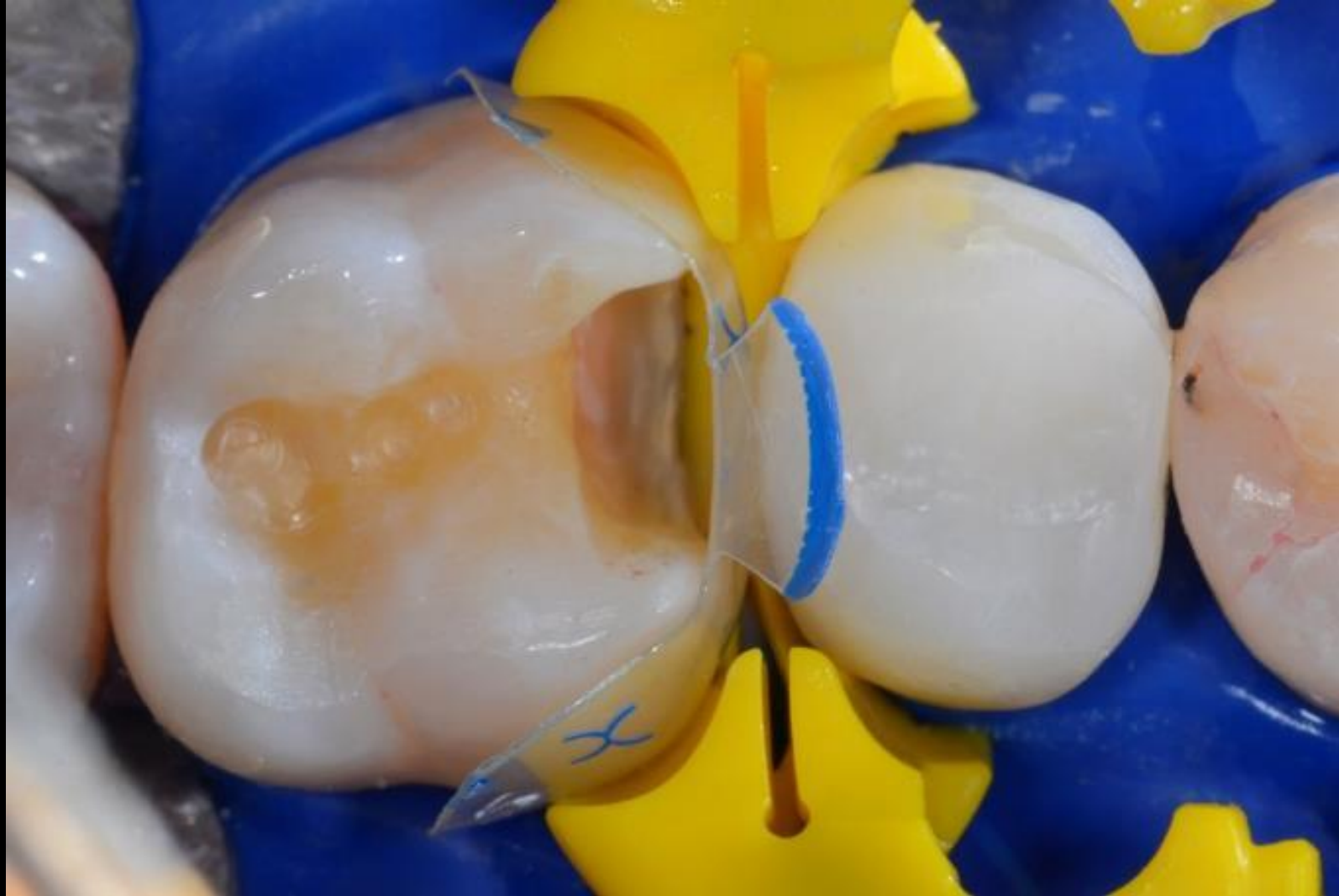

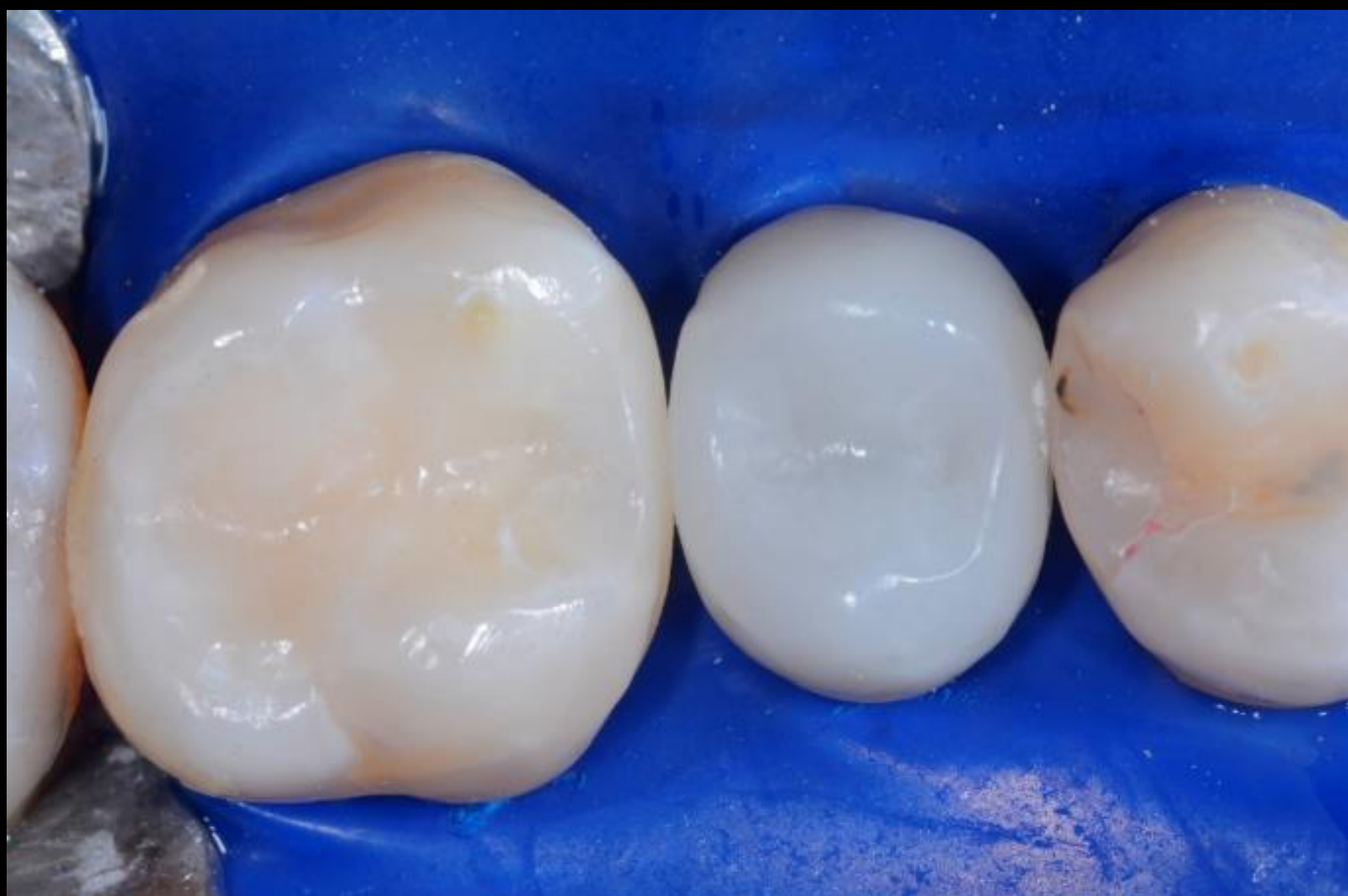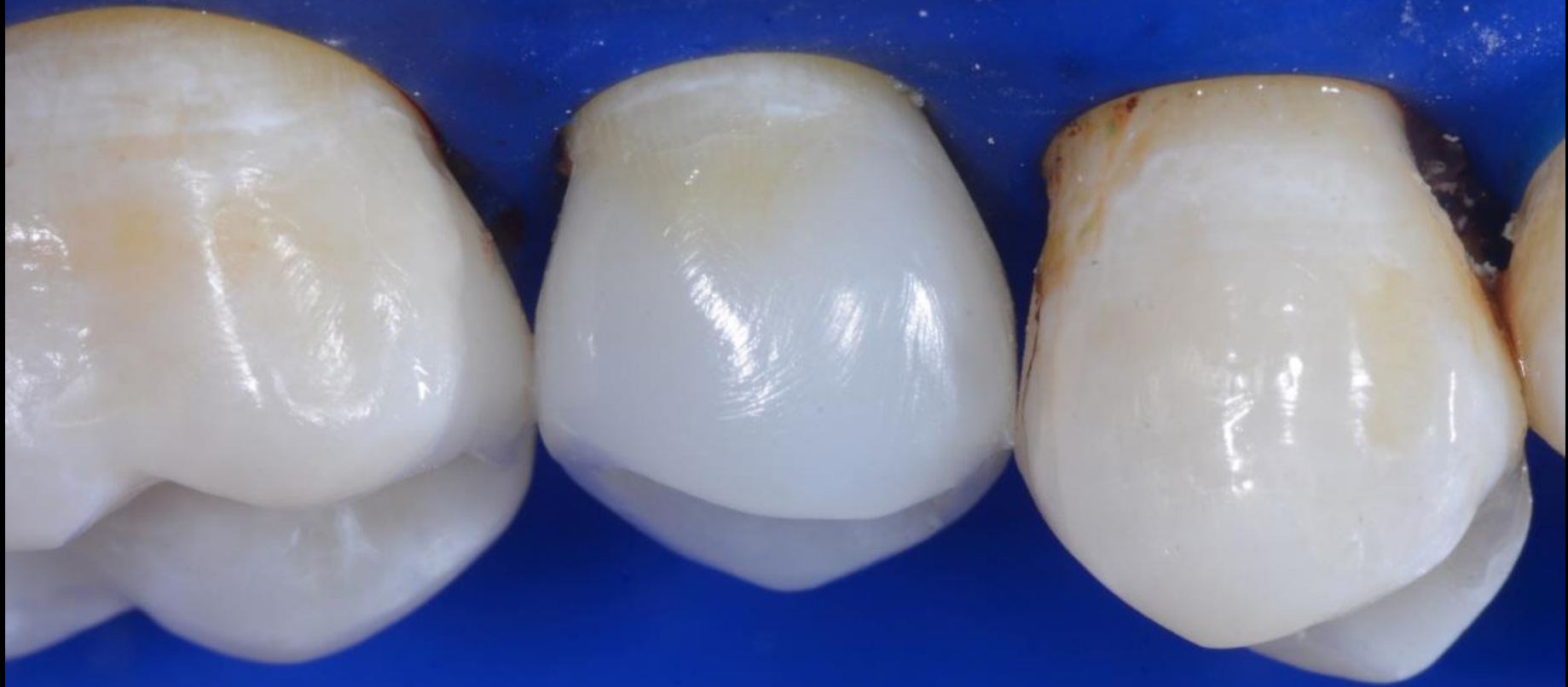8 keys to ideal contacts with Injection Molding

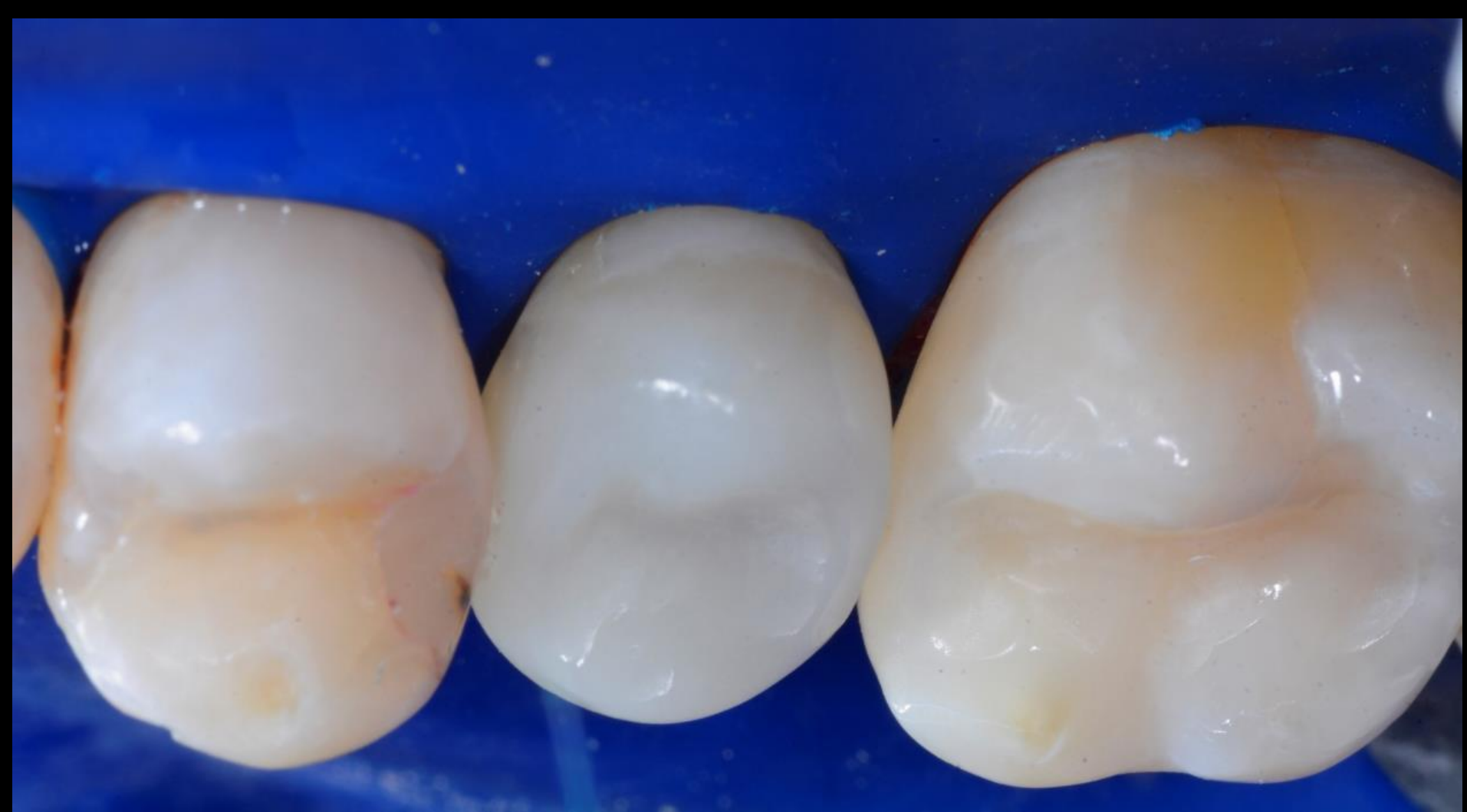- ✓ Change the Prep
- ✓ Pre-wedging
- ✓ Choose the correct matrix height
- ✓ Optimize the neighboring contact
- ✓ Progressive wedging
- ✓ Place separator like a rubber dam clamp
- ✓ Spot Weld Push/Pull.. Rehearse first★
- ✓ Quadrant Strategy Do the unilateral contact last

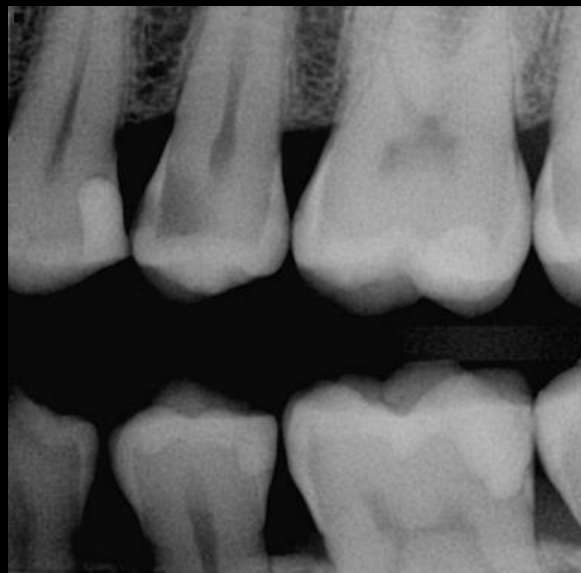




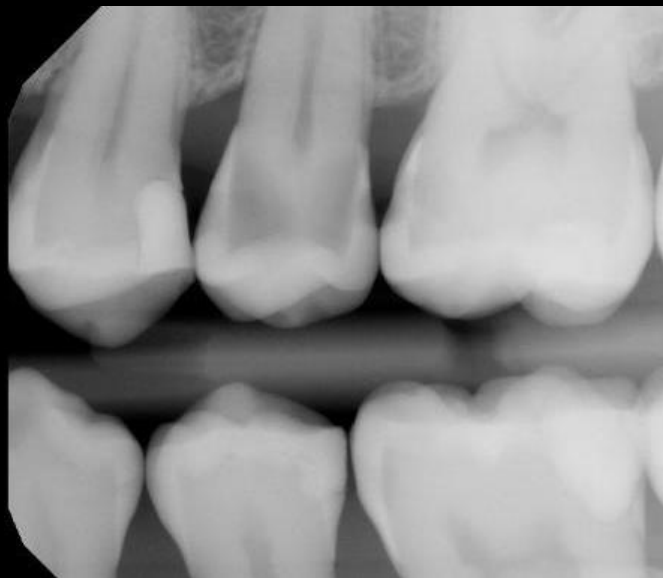


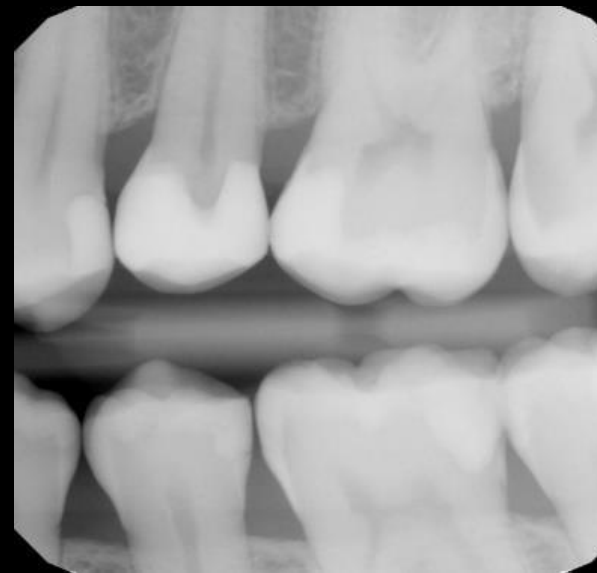




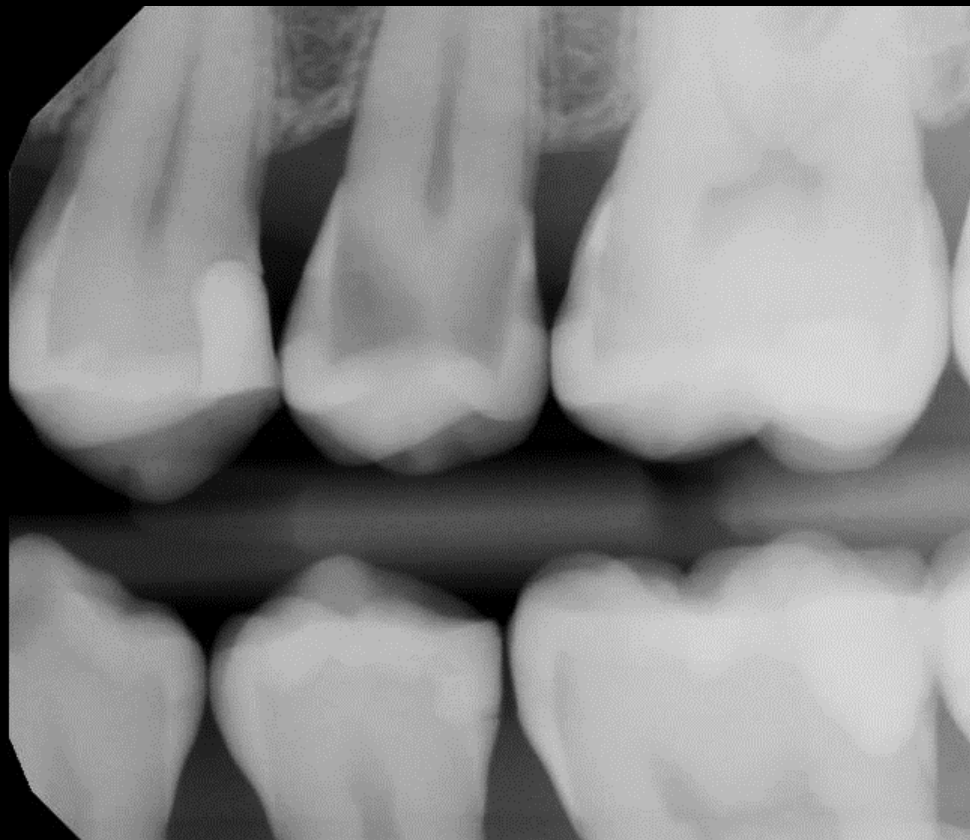2018



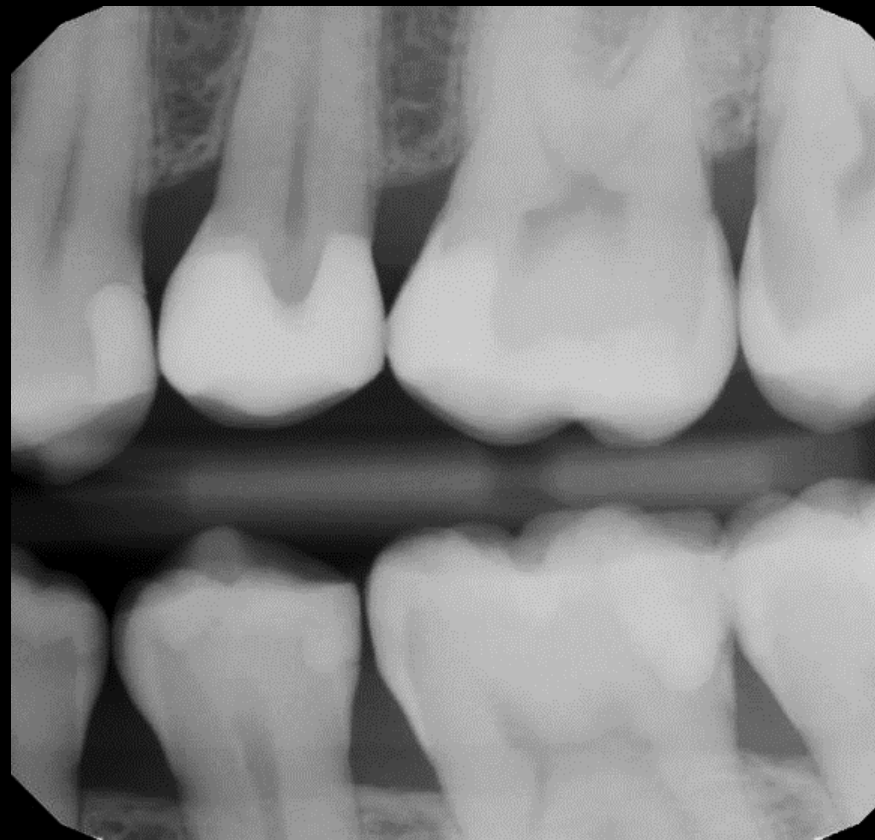2020



2020 post op

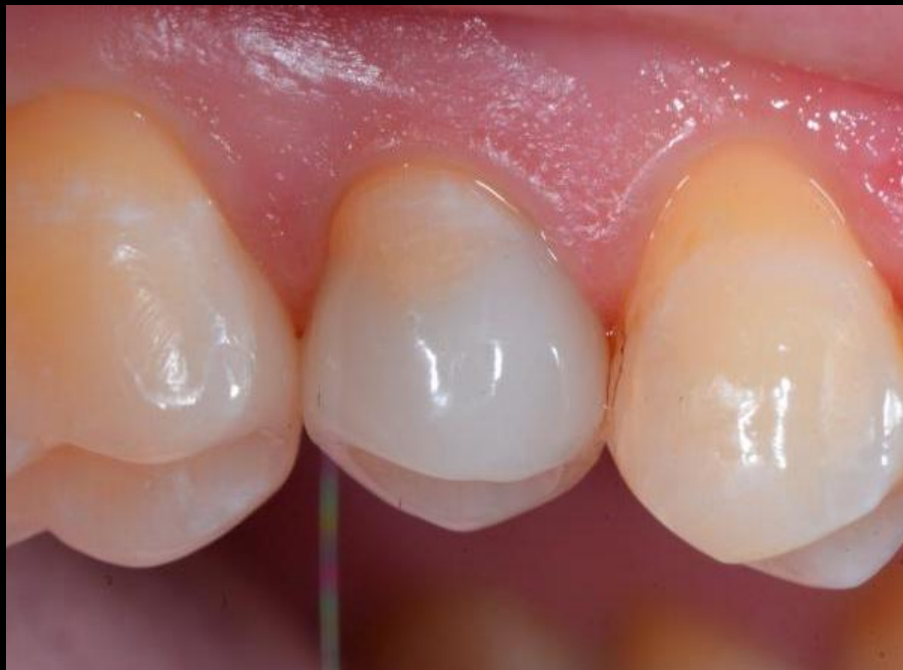
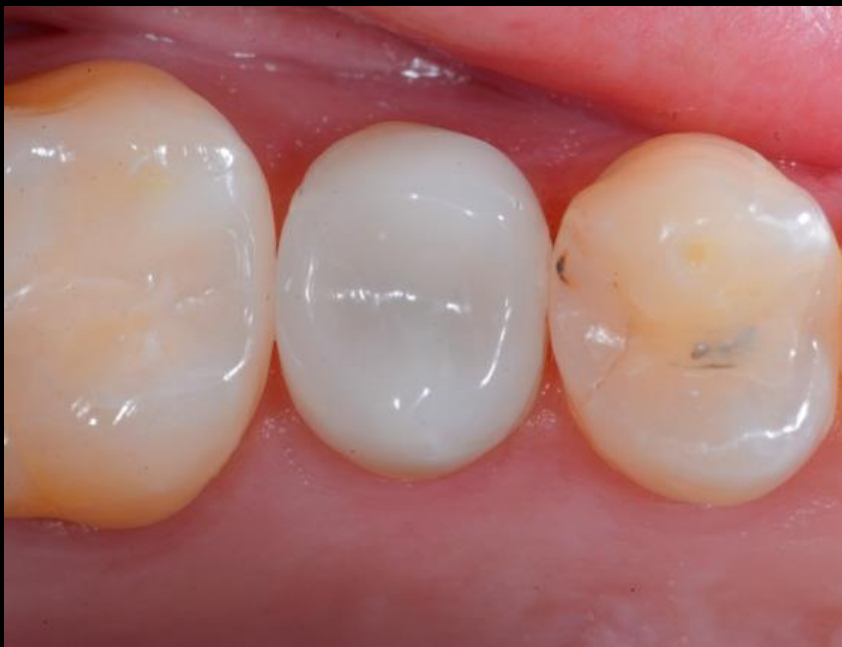
hopeless

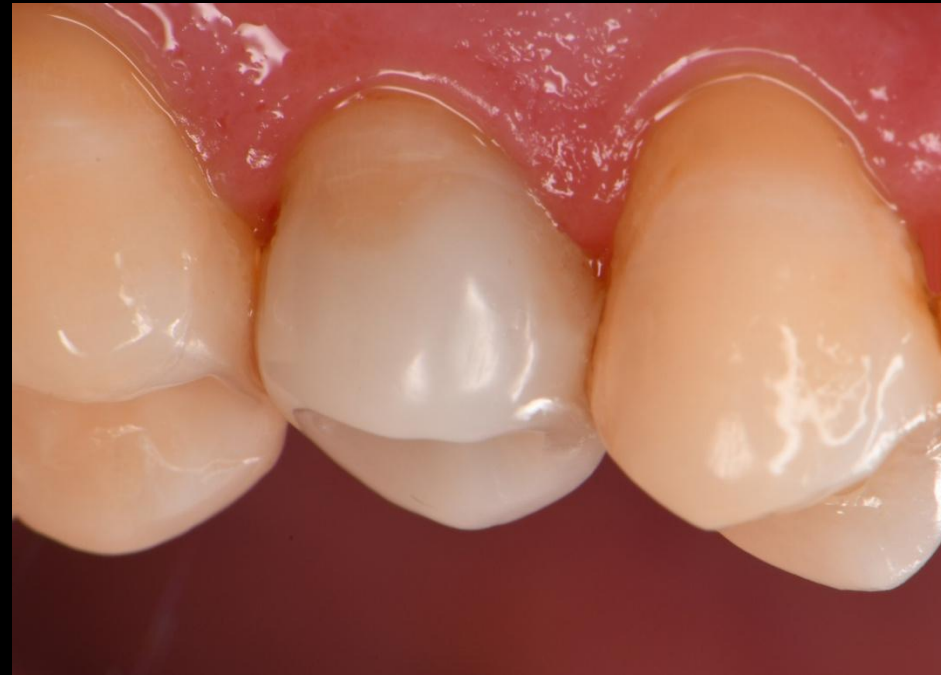
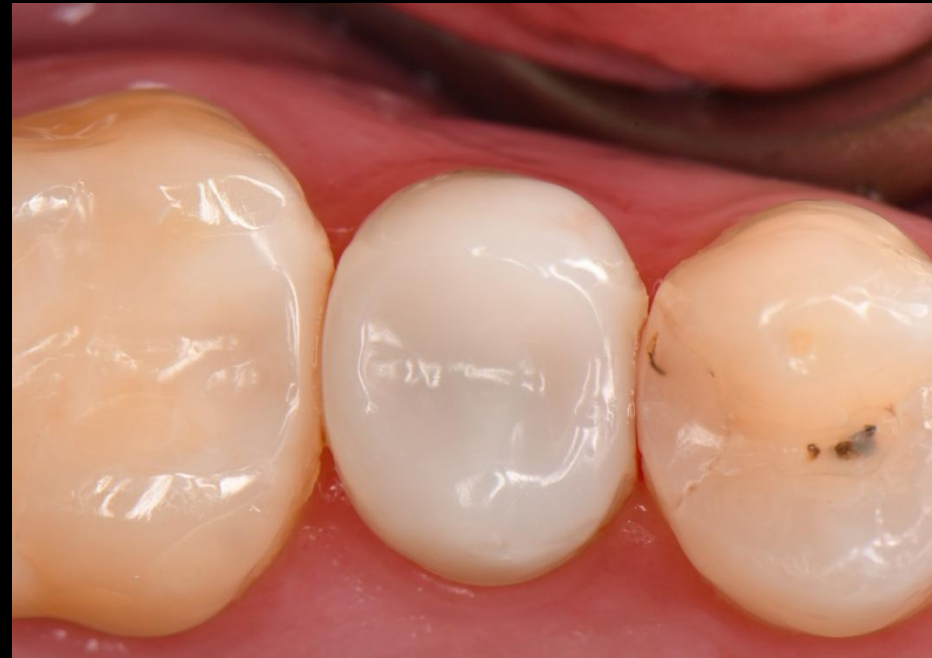
hopeful

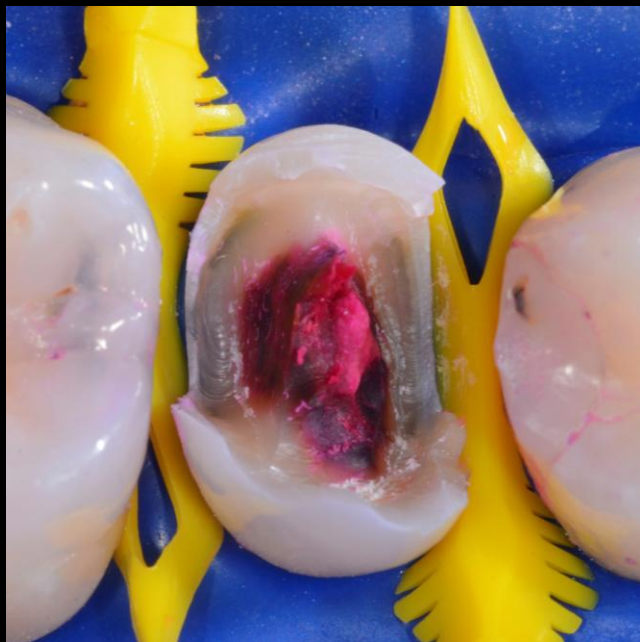2 week follow up



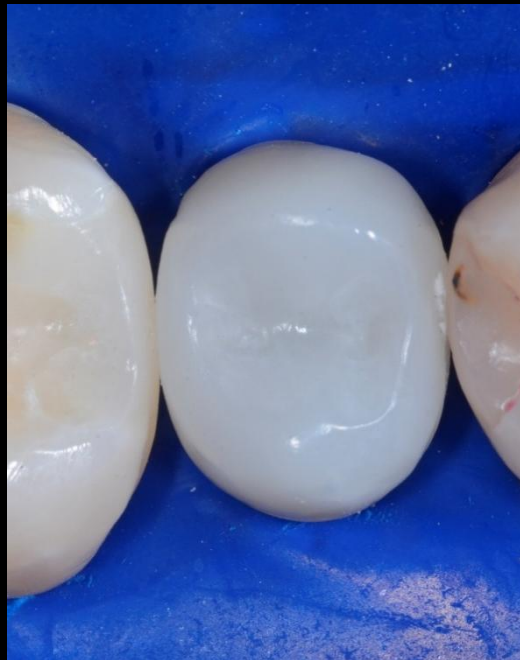3-year follow up



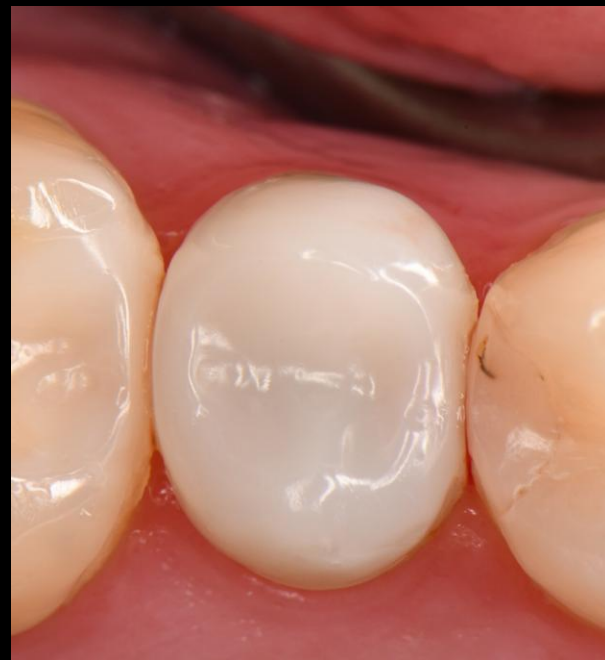Mid treatment



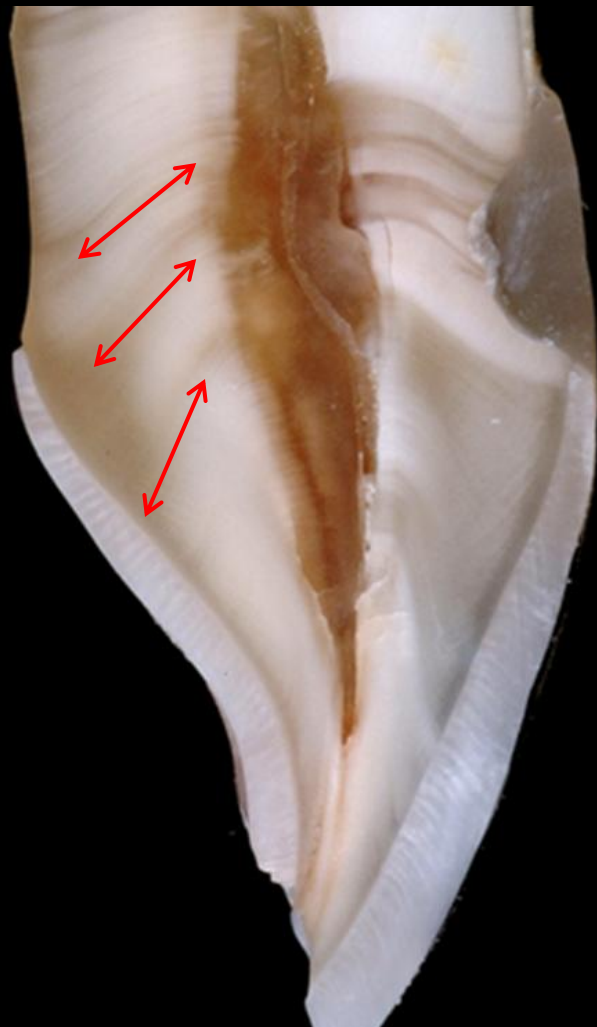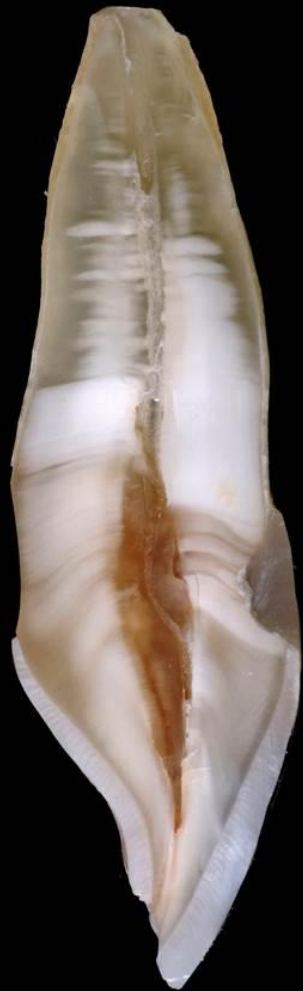post-op



3-year follow up



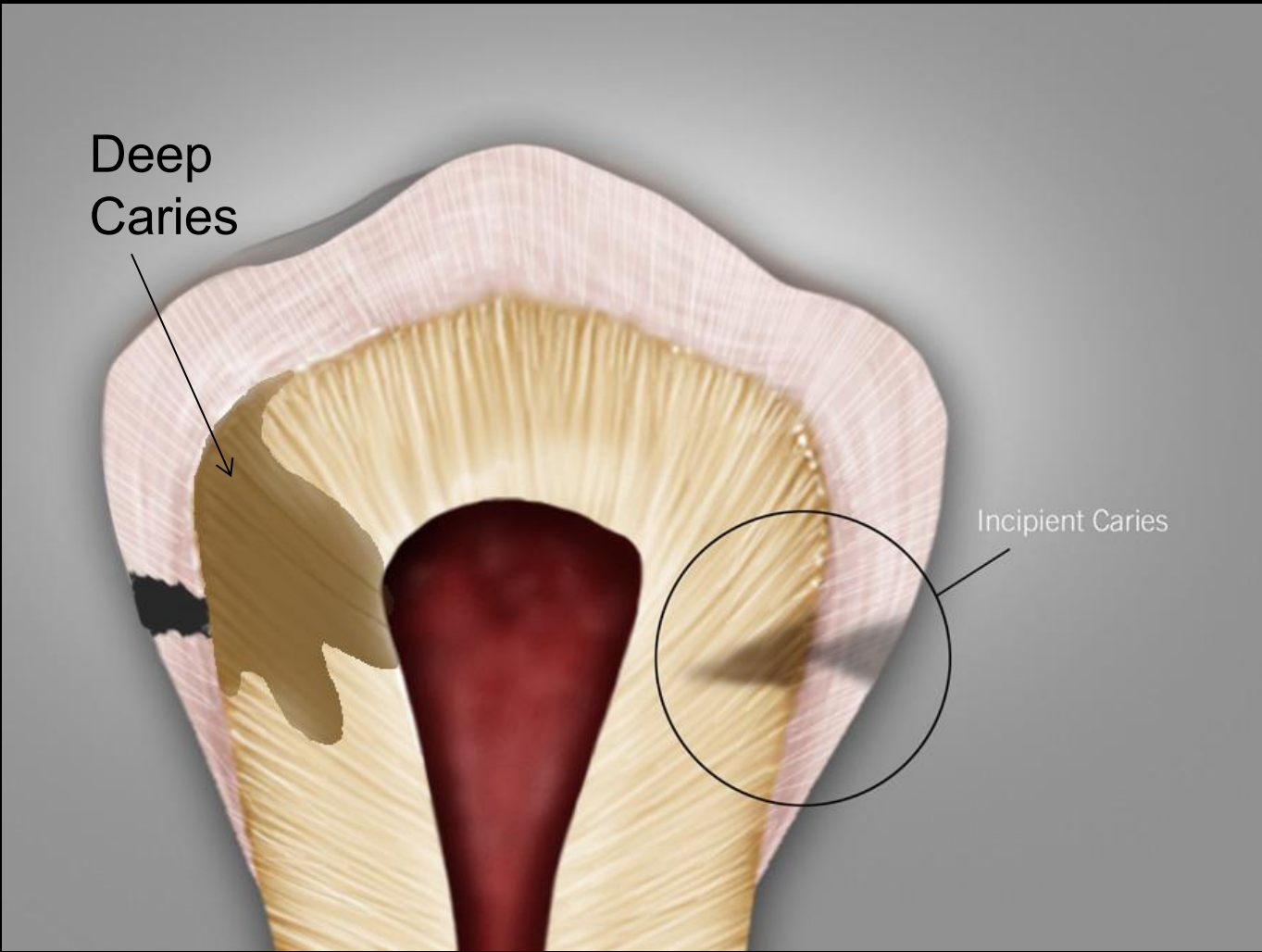

Caries Progression and Selective Caries Removal (SCR) or Modified Hall Technique



Deep
Caries



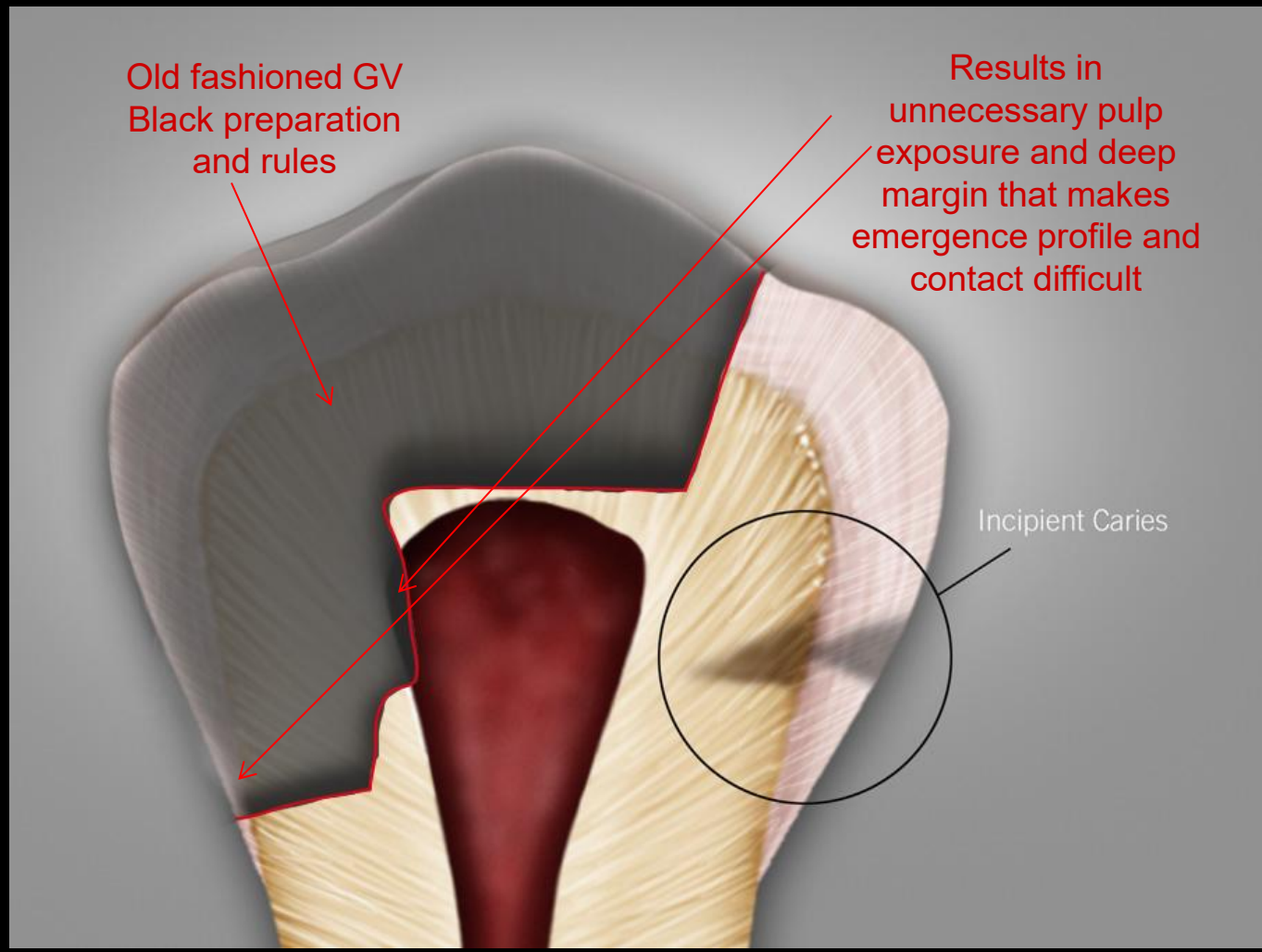
Incipient Caries



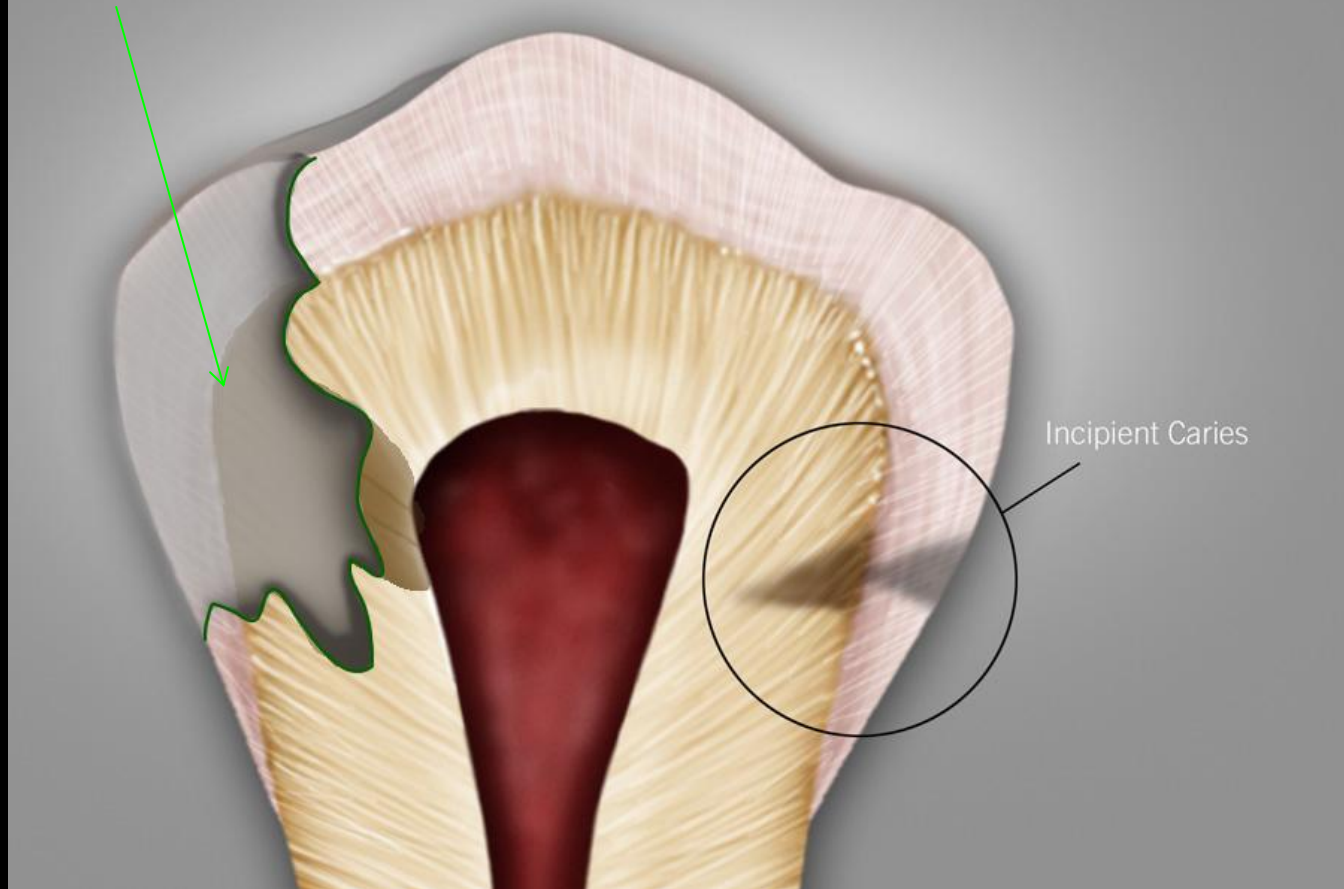
Old fashioned GV
Black preparation
and rules

Results in
unnecessary pulp
exposure and deep
margin that makes
emergence profile and
contact difficult

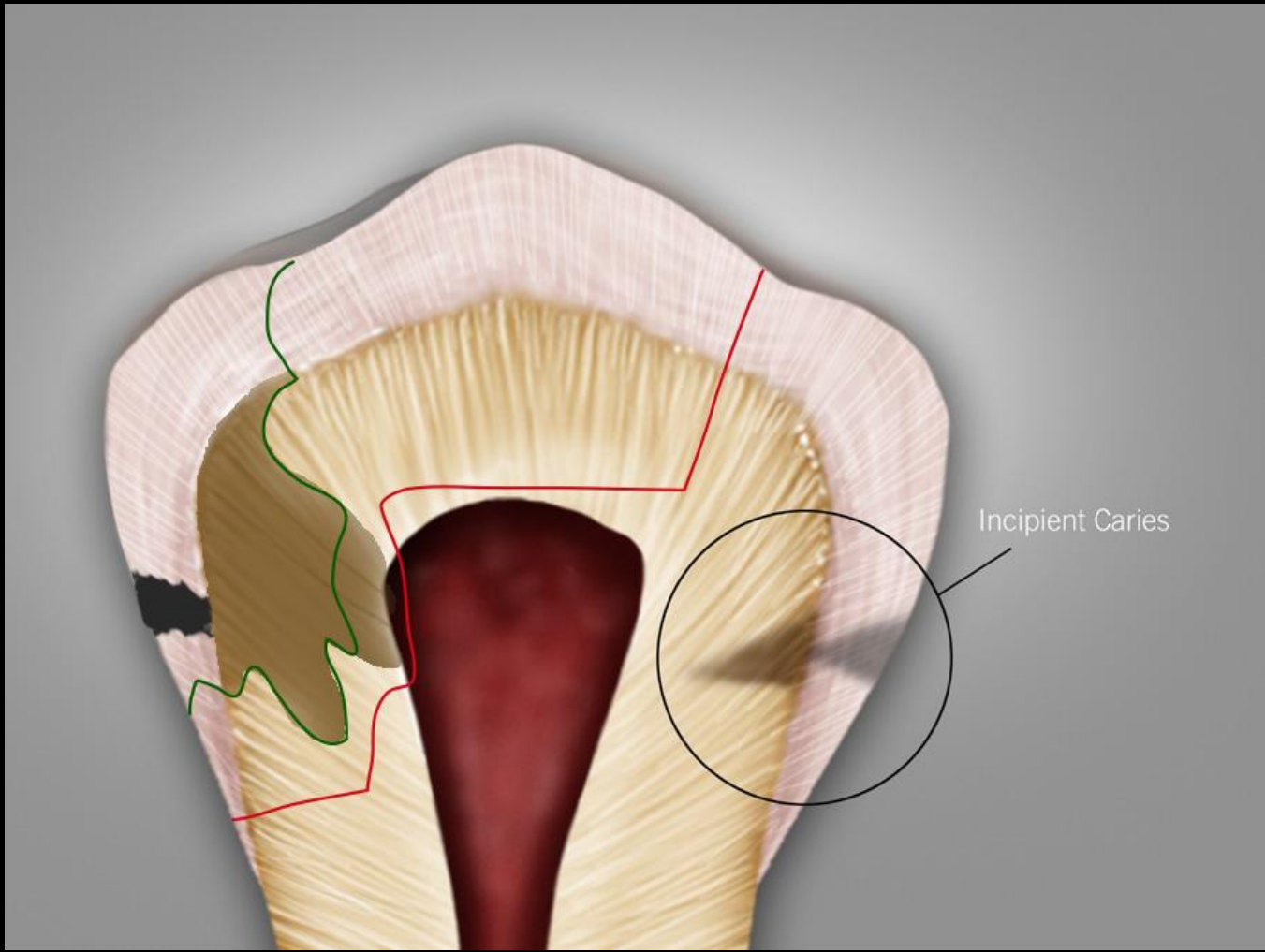
Incipient Caries



Modern "Clark Class II"



Incipient Caries



Incipient Caries

What is the ultimate pulp capping agent?

- DyCal?
- RMGI?(Vitrebond/Fuji IX)
- MTA?
- Dentin in a Capsule? (Septodont)
- Caulk Snuggly stuff?
- Bonded resin?
- None of the above?

What is the ultimate pulp capping agent?

- A well sealed TRI and a **beret of soft smooth dentin**
(Past al dente dentin)

What are the 3 rules of pulp capping?

1. Don't expose the pulp
2. Don't expose the pulp
3. Don't expose the pulp

Hundreds of Selective Caries Removal (SCR) studies show remarkably and consistently high success rates. SCR is preferred by most patients over RCT or pulpotomy.

Qualitative and Quantitative Radiographic Assessment of Sealed Carious Dentin: A 10-Year Prospective Study	Oral Surg Oral Med Oral Pathol Oral Radiol Endod 2010	Objective: the objective of this study was to assess radiographic outcomes after partial carious dentin removal performed in deep caries lesions over a 10-year period.	10-year survival rate of the pulp: 100% in 13 teeth	Sealing of carious dentin arrested the caries process, promoted deposition of tertiary dentin, and induced mineral gain in the radiolucent zone.
The Monitoring of Deep Caries Lesions After Incomplete Dentine Caries Removal: Results After 14-18 Months	Clin Oral Investig 2006	Objective: this paper aims to assess radiographic changes after incomplete carious dentine removal and tooth sealing.	Survival rate of the pulp: 97% in 31 teeth	Complete dentine caries removal is not essential to control caries progression.
The Hall Technique: a randomized controlled clinical trial of a novel method of managing carious primary molars in general dental practice: acceptability of the technique and outcomes at 23 months	BMC Oral Health 2007	Objective: Study the simplified method of managing carious primary molars using preformed metal crowns cemented with no local anesthetic, caries removal, or tooth preparation, and compare to traditional pulpotomy and metal crown.	2-year survival rate was 89%, outperforming traditional treatment by 11%	The Hall technique was preferred to conventional restorations by the majority of children, carers and GDP's.
Long-Term Survival of Indirect Pulp Treatment Performed in Primary and Permanent Teeth with Clinically Diagnosed Deep Carious Lesions	Journal of Endodontics 2010	Objective: Examine clinically and radiographically the 3-year survival of teeth treated with Indirect Pulp Treatment	3-year survival rate was 96% for 125 primary molars and 93% for 45 permanent teeth.	IPT performed in primary and permanent teeth of young patients may result in a high 3-year survival rate Note: Frank decay was retained.
Outcomes of Partial and Complete Caries Excavation in Permanent Teeth: A 18-Month Clinical Study	Contemp Clin Dent 2018	Objective: Clinical and radiographic outcomes of partial caries removal vs. complete caries removal in permanent teeth with deep carious lesions.	Survival rate of the pulp: 92.5%	Leaving a layer of soft, wet dentin adjacent to the pulpal wall could be an elective treatment option for mature permanent teeth with deep carious lesions.
Clinical Performance of Sealed Composite Restorations Placed Over Caries Compared with Sealed and Unsealed Amalgam Restorations	JADA 1987	Objective: To identify differences in the clinical outcomes of carious lesions sealed with composite vs. amalgams placed over caries-free preparations.	Survival rate of the pulp: 100%	There was no significant clinical difference between occlusal caries sealed with composite vs caries-free occlusal preps restored with amalgams over 2 years.
Sealing vs Partial caries Removal in Primary Molars: a RCT.	BMC Oral Health 2014	Objective: To assess the efficacy of arresting dentinal caries either with sealants or partial caries removal and composite restorations	18-month survival rate of the pulp: 100% for 17 teeth	Composite sealing of caries can arrest their progression therefore its complete removal is not necessary.
Conventional Caries Removal and Sealed Caries in Permanent Teeth: A Microbiological Evaluation	J Dent 2012	Objective: To compare bacterial load after conventional carious dentine removal with incomplete carious dentine removal and	Survival rate: 100%	It is not necessary to remove all carious dentin before a restoration is placed.

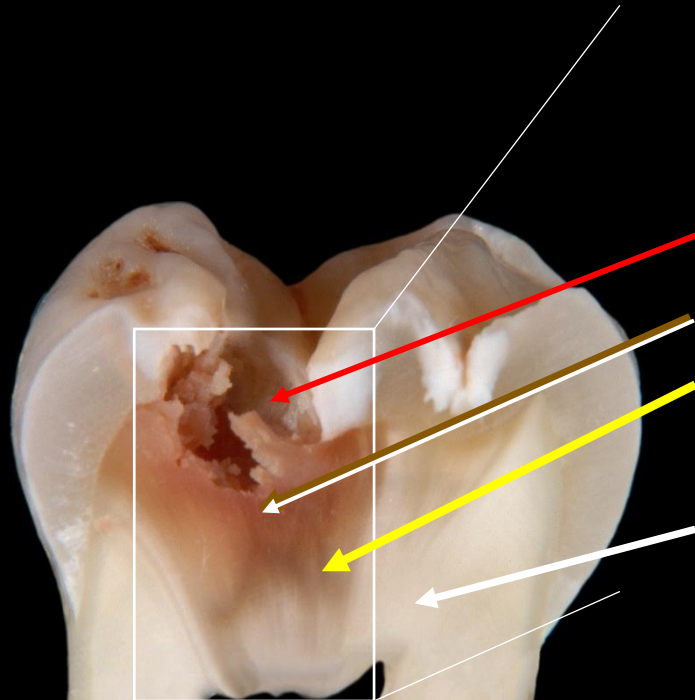
Partial Caries Removal in Deep Caries Lesions: A 5-Year Multicenter Randomized Controlled Trial	Clin Oral Investig 2018	Objective: To evaluate the effects of partial caries removal on pulp vitality five years after the procedure was performed.	Five-year survival rate: 80% of 121 teeth	Partial caries removal reduced the occurrence of pulp necrosis.
Effect of Different Liners on Pulpal Outcome After Partial Caries Removal: A preliminary 12 Months Randomized Controlled Trial	Caries Res 2019	Objective: To compare the effects of liners on pulp health outcomes 12 months after partial caries removal and restoration with composite.	12-month survival rate of the pulp: 94.6%	Partial removal of carious dentin does not interfere with pulp vitality or restoration survival, and liners are not necessary for the success of the procedure.
The Hall Technique 10 Years on: Questions and Answers	Br Dent J 2017	Objective: To review the success rate of sealing carious lesions.	5-year survival rate of the pulp: 97%	Sealing carious lesion is successful and this method is now regarded as a viable management options for carious primary molars
Sealing caries in primary molars: Randomized control trials, 5-year results	J Dent Res 2011	Objective: To compare clinical and radiographic failures of sealing carious lesions vs complete caries removal	5-year survival rate of the pulp: 95% of 264 teeth	Sealing caries outperformed conventional caries removal methods in preserving tooth vitality.
Ultrastructural and Microbiological Analysis of the Dentin Layers Affected by Caries Lesions in Primary Molars Treated by Minimal Intervention	Pediatr Dent 2007	Objective: To understand the effects that sealing carious lesions has on bacteria left in carious dentin.	60-day survival rate of pulp: 96%	Bacterial population decreased by 96% and carious dentine showed better tissue organization following sealing of the lesion.

In Contrast, Direct Pulp Capping study showed a much higher failure rate than SCR

Prognostic Factors for Clinical Outcomes According to Time After Direct Pulp Capping	JOE 2013	Objective: Identify what factors are significant for the survival rate of the pulp THREE YEARS after direct pulp capping with MTA and Dycal.	3-year Survival rate of the pulp: 67.4% of 70 teeth capped with MTA; 52.5% of 105 teeth capped with Dycal.	Selection of pulp capping material is important for pulp survival.
--	----------	--	--	--

Selective Caries Removal or the Modified Hall Technique

Don't expose the pulp, establish a clean TRI and maintain frank caries where possible.



As a restorative dentist:

- 1) Loose Dentin
- 2) Pasta al Dente Dentin
- 3) Affected Dentin: hard-ish and funny color
- 4) Sound Dentin

Saving Natural Tooth Substance – With Confidence

Preparation guidelines have changed considerably over time. Over 100 years ago, G.V. Black promoted “extension for prevention”, today, the philosophy is “prevention of extension” (F.J.T. Burke, Dent. Update 2003, 30, 492-502), supported by guidelines for minimally invasive dentistry.

Minimally invasive preparations have meaningful benefits for patients:

- Increased tooth longevity
- Lower risk of pulpal exposure
- Reduced need for painful root canal treatments



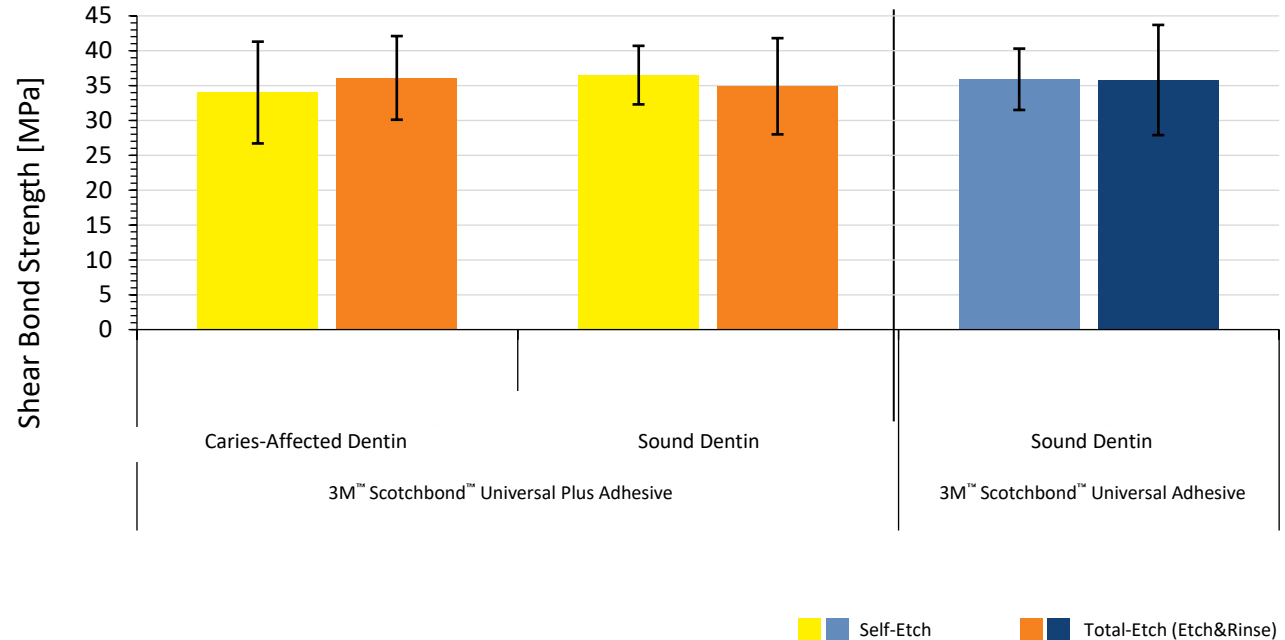
Long term survival of restorations depends on a stable bond to enamel and dentin. With minimally invasive dentistry, caries-affected dentin is preserved during excavation.

3M™ Scotchbond™ Universal Plus Adhesive bonds to firm caries-affected dentin with similar strength as to sound dentin, so you can have confidence in your minimally invasive preparations.

Strong Bonding to Caries-Affected Dentin

Strong bonding to caries-affected dentin helps preserve tooth structure

Cariou human molars were prepared with a polymer bur (SmartBur™ II, SS White) to expose caries-affected dentin. In both etching modes, 3M™ Scotchbond™ Universal Plus Adhesive achieved similar shear bond strength to caries-affected dentin and sound dentin as the control 3M™ Scotchbond™ Universal Adhesive. This high bond strength makes it well suited for MID procedures.



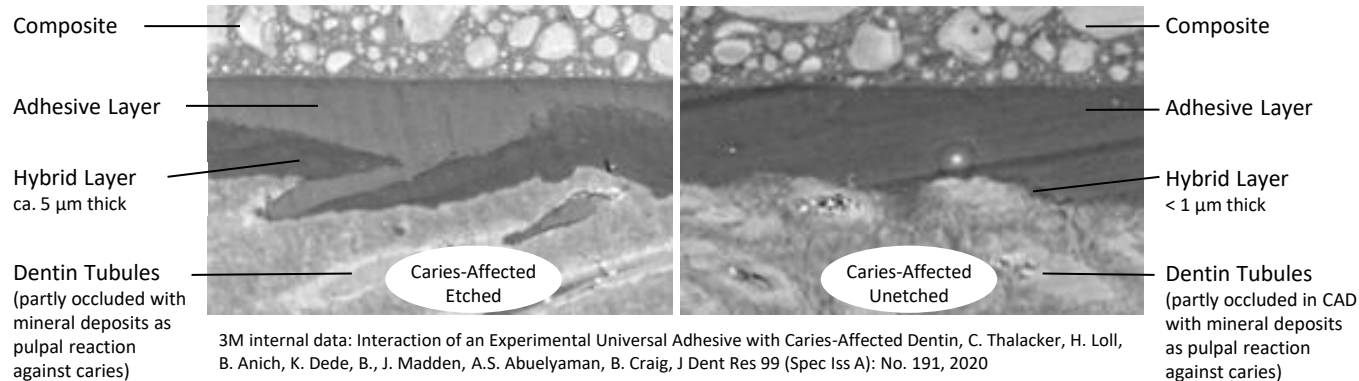
3M internal data: Interaction of an Experimental Universal Adhesive with Caries-Affected Dentin, C. Thalacker, H. Loll, B. Anich, K. Dede, B., J. Madden, A.S. Abuelyaman, B. Craig, J Dent Res 99 (Spec Iss A): No. 191, 2020

Well-Defined Hybrid Layer on Caries-Affected Dentin

Supports minimally invasive dentistry to preserve natural tooth substance

3M™ Scotchbond™ Universal Plus Adhesive helps preserve natural tooth structure in MID procedures and when preparing near the pulp by forming a continuous hybrid layer without voids or gaps on both caries-affected and sound dentin. A well-defined hybrid layer effectively seals caries-affected dentin areas.

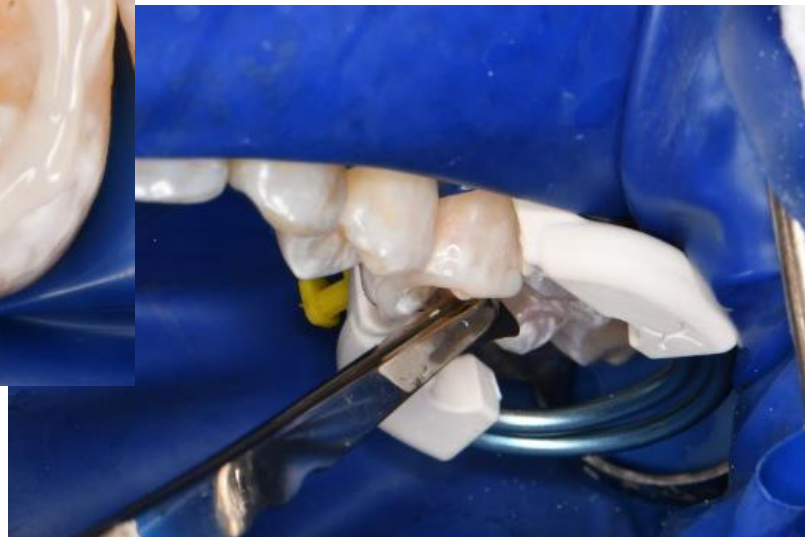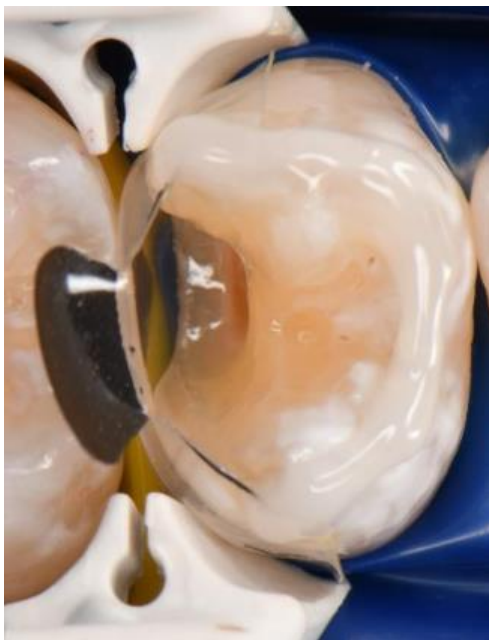
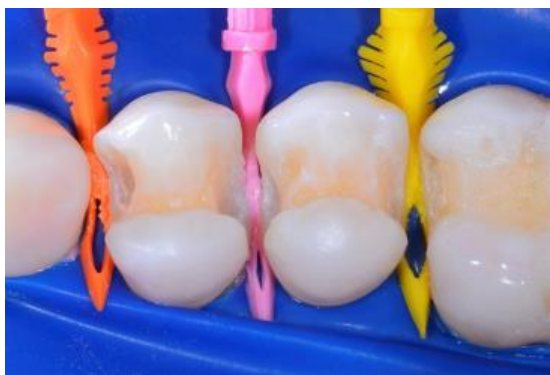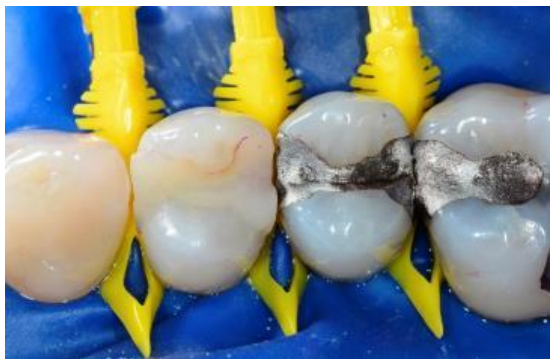SEM study – hybrid layer on caries-affected dentin (etched and unetched)



SCR: We have a lot to talk about...

- 1) How much clean dentin do I need on the periphery to seal in decay?
- 2) Better question: How much clean dentin can I afford?

Core Posterior Solutions



∞ BIOCLEAR

Stop by convention

booth #3902

to...

- ✓ Hear more about Bioclear courses
- ✓ Meet our team of Bioclear nuts
- ✓ Order products
- ✓ Register for courses
- ✓ Learn why Bioclear is a BIG DEAL!

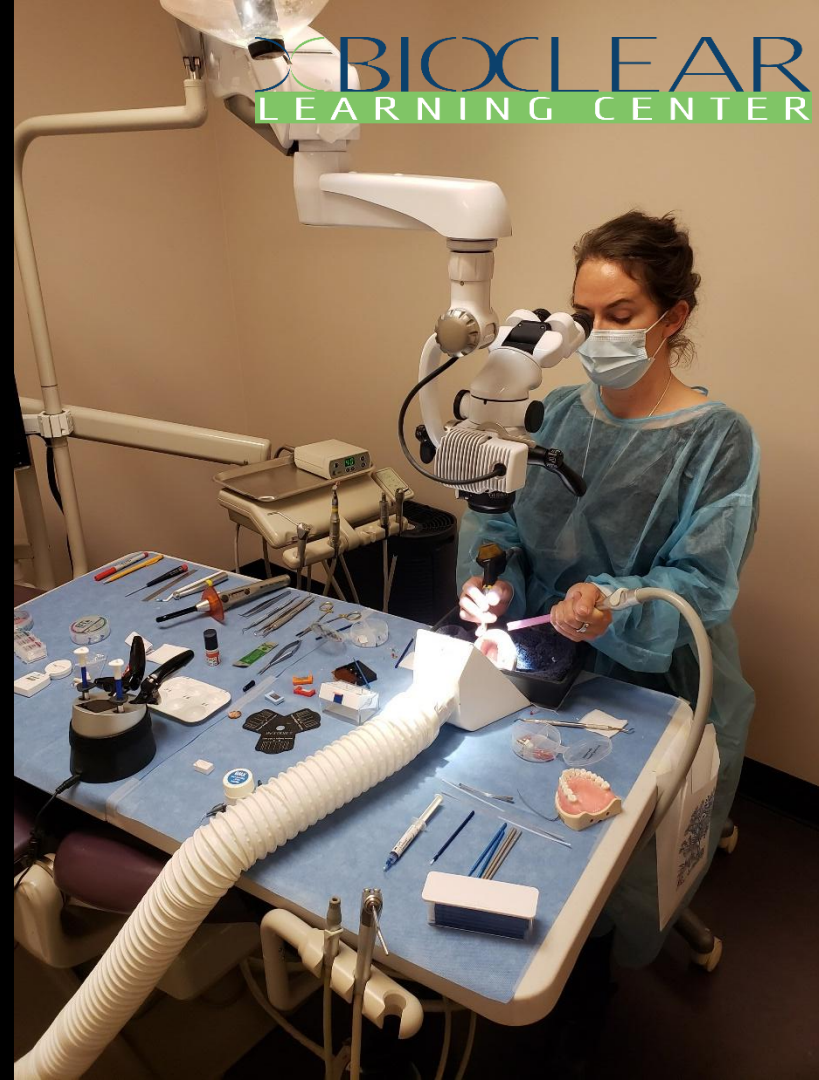
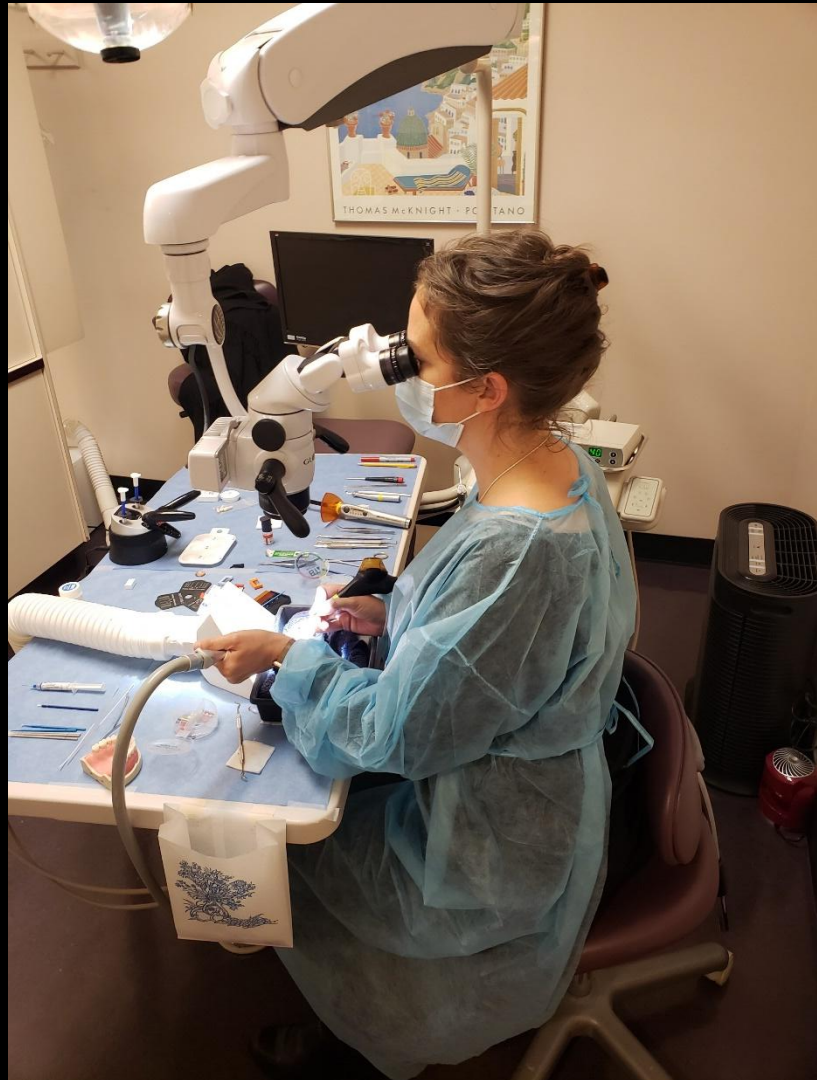


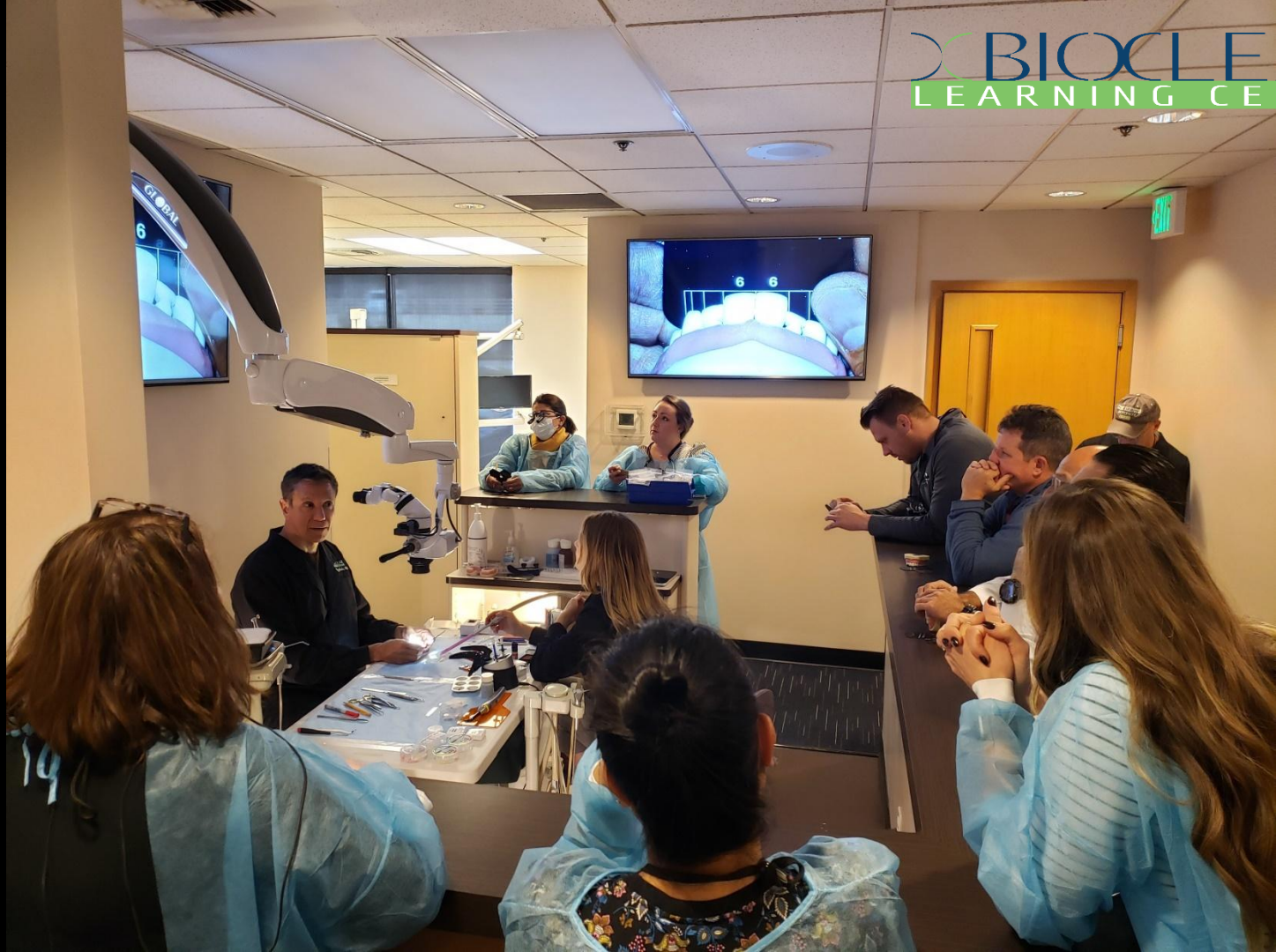 **BIOCLEAR**

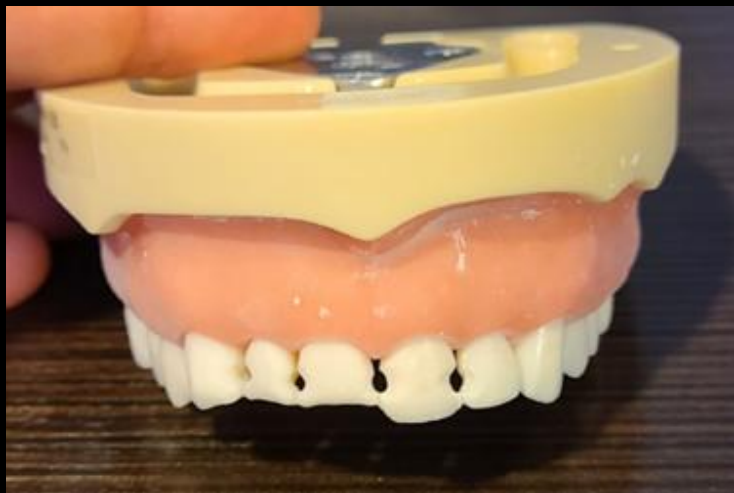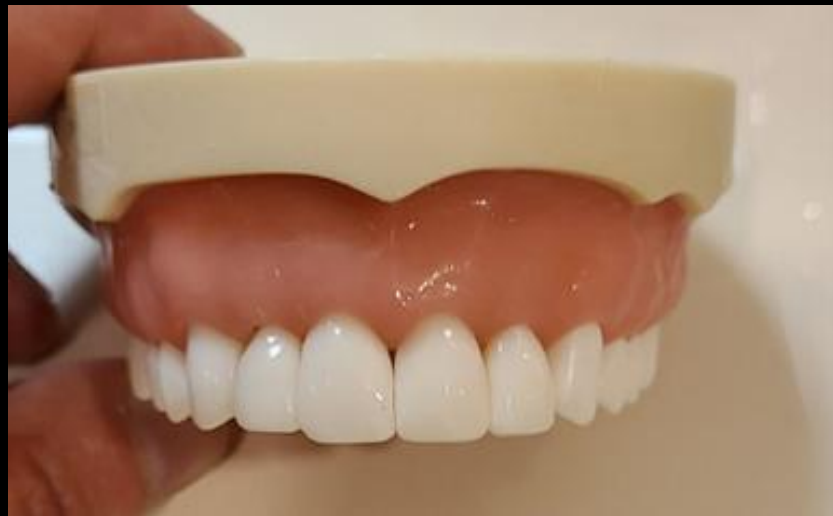L E A R N I N G C E N T E R

Tacoma USA · Solihull UK
Varberg Sweden · Cairo Egypt
Syracuse Italy



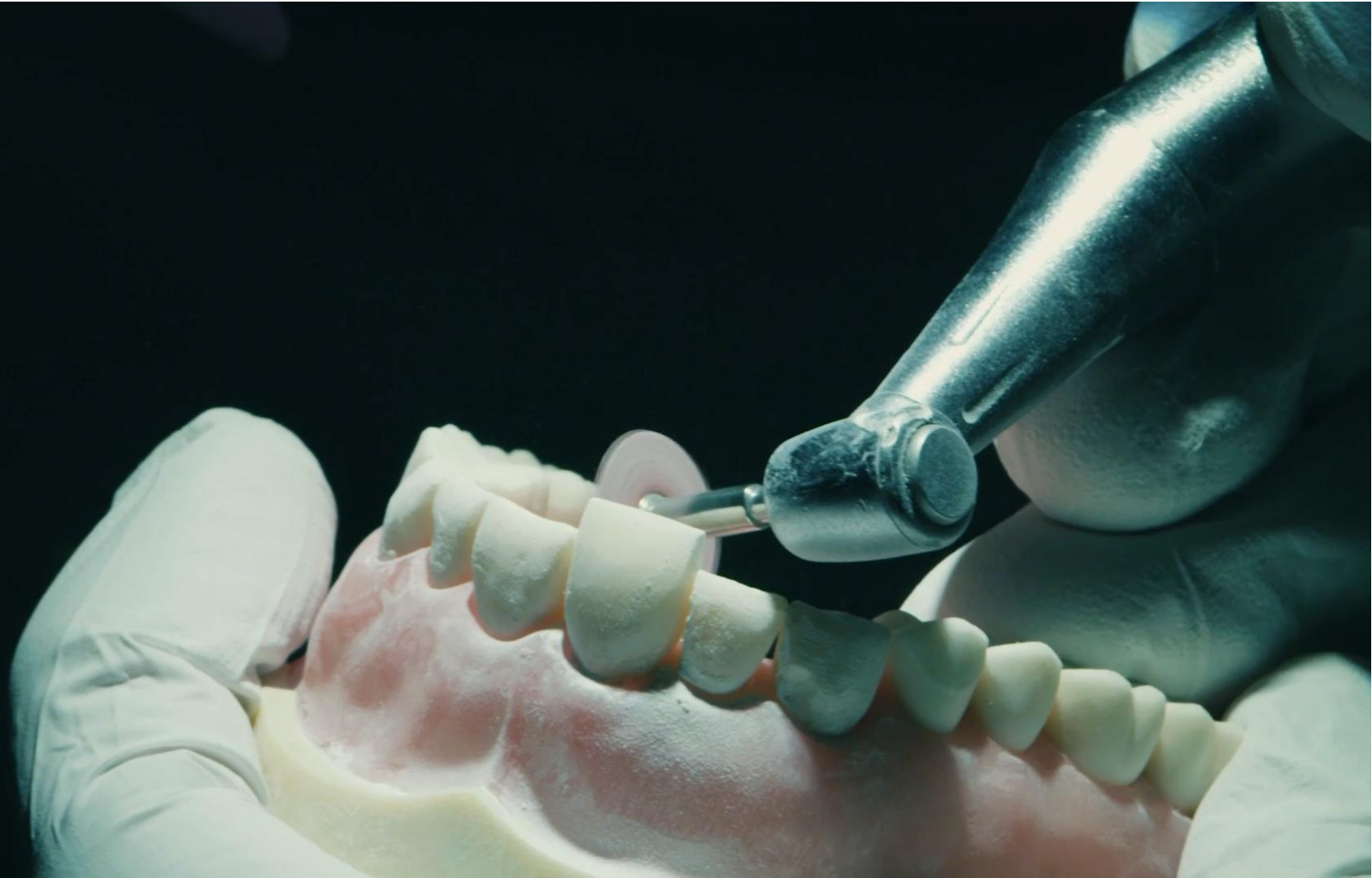





Last week's attendees at the certification course







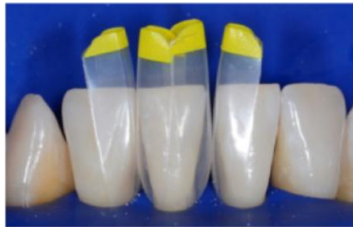
BIOCLEAR LEARNING CENTER

Tacoma USA · Solihull UK
Varberg Sweden · Cairo Egypt
Syracuse Italy · Taubate Brazil
Livermore CA (Bioclear pediatrics)
Seoul Korea · Madrid/Barcelona
Sydney Australia · Baghdad Iraq

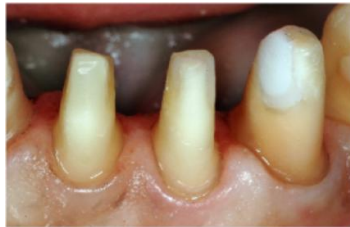Getting paid to be conservative

BIOCLEAR VS. CROWNS AND VENEERS

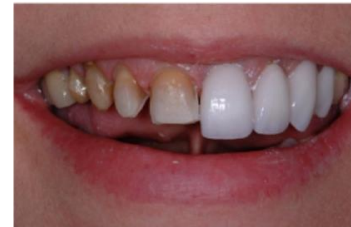Bioclear is an alternative to traditional methods for enhancing a smile. Rather than preparing for a crown or veneer, the Bioclear Method—expanding the possibilities of dentistry—conserves the natural tooth structure, tooth enamel and tooth durability.



BIOCLEAR PREPARATION
Bioclear allows dentists to **conserve** healthy tooth structure



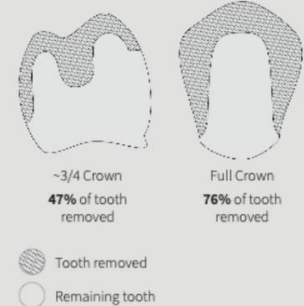
CROWN PREPARATION
Crowns require dentists to **remove an average of 76%** of the tooth structure prior to the procedure



VENEER PREPARATION
Veneers require dentists to **remove an average of 47%** of the tooth structure prior to the procedure

AN HONEST LOOK AT CROWN PREPARATIONS

As illustrated below, crowns, veneers, and onlays require the removal of a significant amount of healthy tooth structure. Bioclear dentists can leave most or all of the tooth structure. Bioclear is a very attractive option to patients.



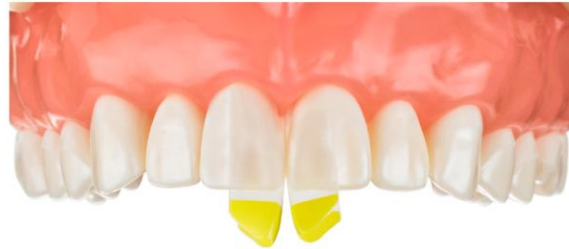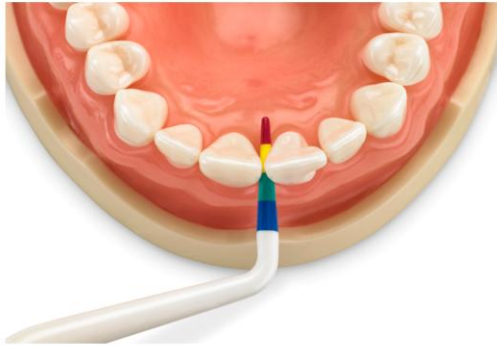
Treat yourself to a weekend with  BIOCLEAR

BLACK TRIANGLE

CERTIFICATION COURSE

18 CE CREDITS

This three-part live hands-on certification course will teach you how to treat black triangles, gingival recession, root abrasions, and perform confident restorations. In becoming a certified Bioclear black triangle doctor, you'll increase your overall skill and knowledge of Bioclear and learn to market your new skills to patients.

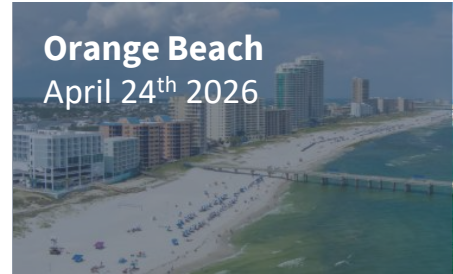


Upcoming Dates:

Washington DC
May 8th 2026



Orange Beach
April 24th 2026

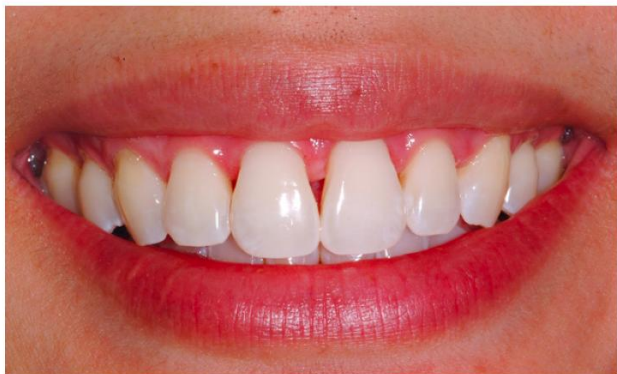

Limited spots available!

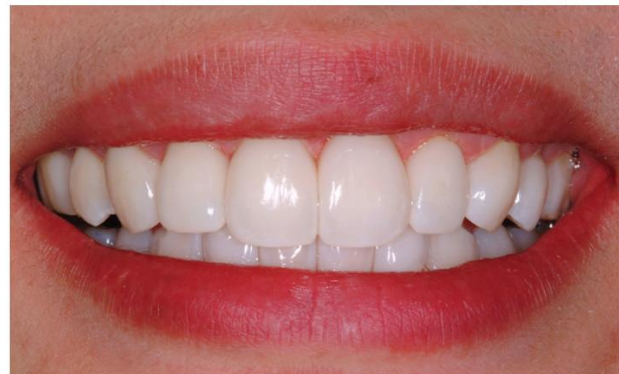Scan to learn more
& sign up for your
local BT Course!



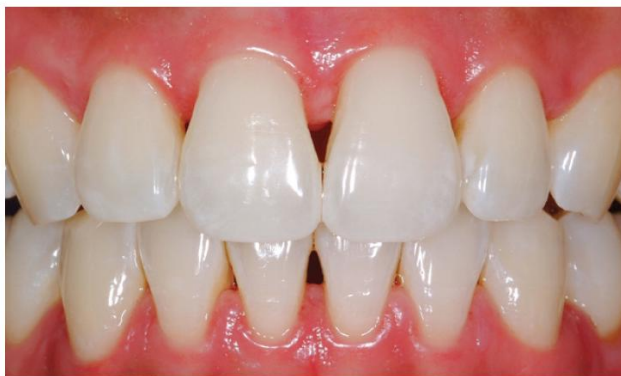www.bioclearmatrix.com/live-courses/



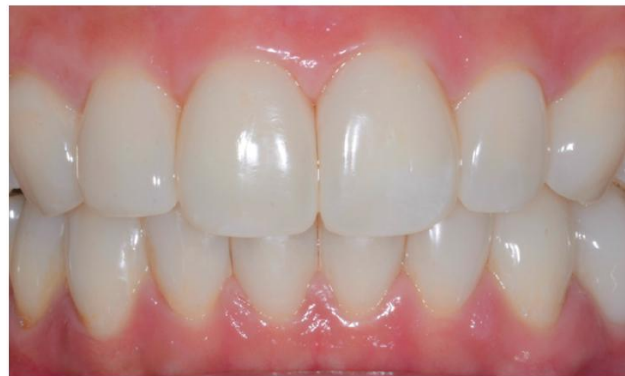BEFORE



AFTER



BEFORE



AFTER

∞ BIOCLEAR

Stop by convention

booth #3902

to...

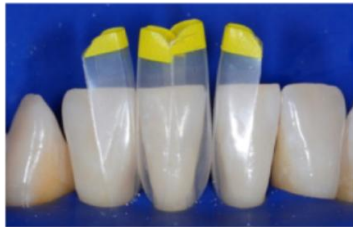
- ✓ Hear more about Bioclear courses
- ✓ Meet our team of Bioclear nuts
- ✓ Order products
- ✓ Register for courses
- ✓ Learn why Bioclear is a BIG DEAL!



Getting paid to be conservative

BIOCLEAR VS. CROWNS AND VENEERS

Bioclear is an alternative to traditional methods for enhancing a smile. Rather than preparing for a crown or veneer, the Bioclear Method—expanding the possibilities of dentistry—conserves the natural tooth structure, tooth enamel and tooth durability.



BIOCLEAR PREPARATION
Bioclear allows dentists to **conserve** healthy tooth structure



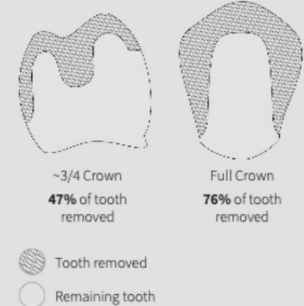
CROWN PREPARATION
Crowns require dentists to **remove an average of 76%** of the tooth structure prior to the procedure



VENEER PREPARATION
Veneers require dentists to **remove an average of 47%** of the tooth structure prior to the procedure

AN HONEST LOOK AT CROWN PREPARATIONS

As illustrated below, crowns, veneers, and onlays require the removal of a significant amount of healthy tooth structure. Bioclear dentists can leave most or all of the tooth structure. Bioclear is a very attractive option to patients.





BIOCLEAR


LEARNING CENTER

Tacoma USA · Solihull UK
Varberg Sweden · Cairo Egypt
Syracuse Italy



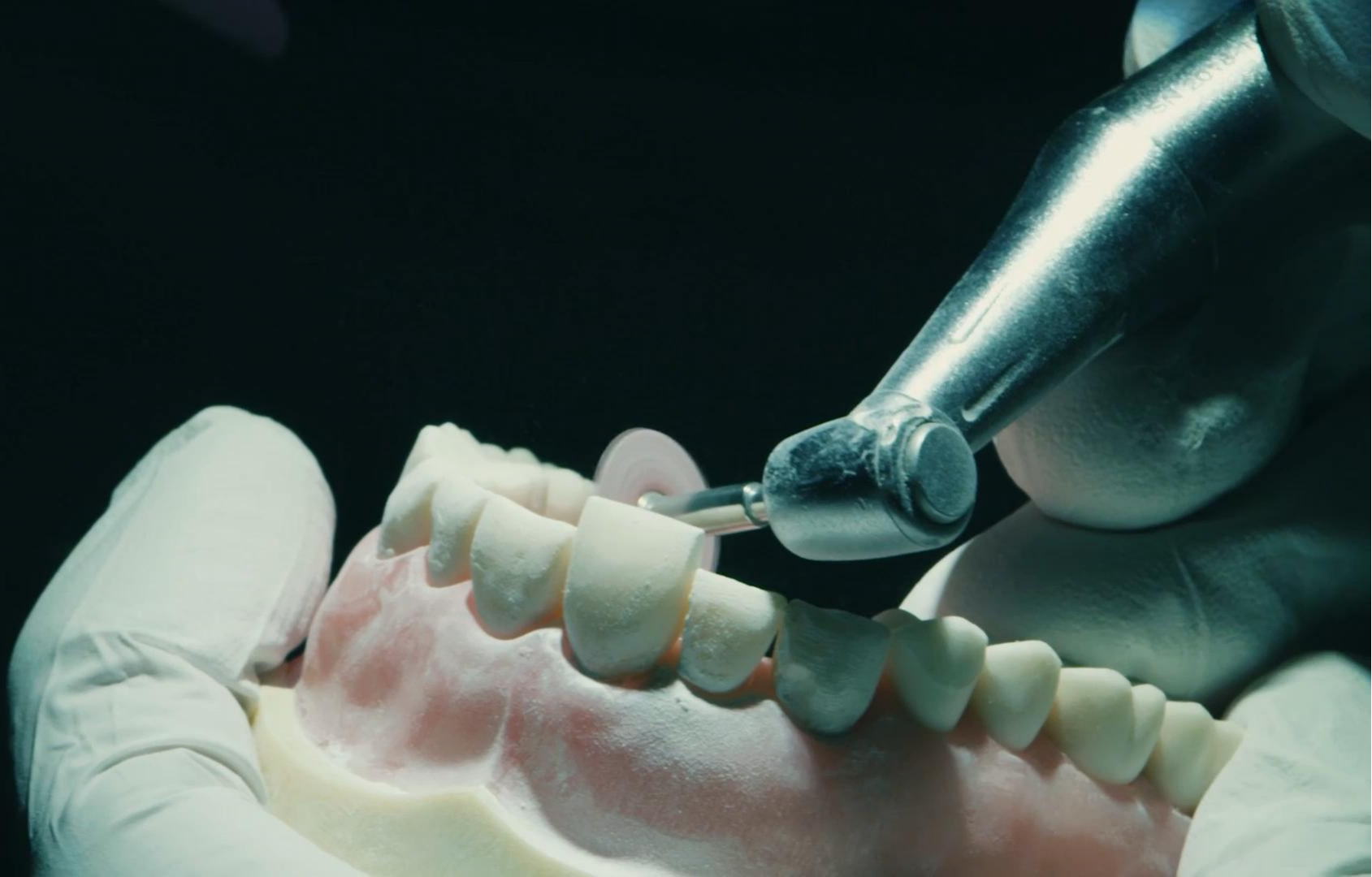






Last week's attendees at the certification course





2026 Certification Courses



- Core Anterior + Core Posterior • Complex Cases & Problem Solving
- Smile Design & Comprehensive Anterior Rejuvenation • Bioclear Alumni Summit

January

S	M	T	W	T	F	S
				1	2	3
4	5	6	7	8	9	10
11	12	13	14	15	16	17
18	19	20	21	22	23	24
25	26	27	28	29	30	31

February

S	M	T	W	T	F	S
1	2	3	4	5	6	7
8	9	10	11	12	13	14
15	16	17	18	19	20	21
22	23	24	25	26	27	28

March

S	M	T	W	T	F	S
1	2	3	4	5	6	7
8	9	10	11	12	13	14
15	16	17	18	19	20	21
22	23	24	25	26	27	28
29	30	31				

April

S	M	T	W	T	F	S
			1	2	3	4
5	6	7	8	9	10	11
12	13	14	15	16	17	18
19	20	21	22	23	24	25
26	27	28	29	30		

May

S	M	T	W	T	F	S
				1	2	
3	4	5	6	7	8	9
10	11	12	13	14	15	16
17	18	19	20	21	22	23
24	25	26	27	28	29	30
31						

June

S	M	T	W	T	F	S
	1	2	3	4	5	6
7	8	9	10	11	12	13
14	15	16	17	18	19	20
21	22	23	24	25	26	27
28	29	30				

July

S	M	T	W	T	F	S
			1	2	3	4
5	6	7	8	9	10	11
12	13	14	15	16	17	18
19	20	21	22	23	24	25
26	27	28	29	30	31	

August

S	M	T	W	T	F	S
						1
2	3	4	5	6	7	8
9	10	11	12	13	14	15
16	17	18	19	20	21	22
23	24	25	26	27	28	29
30	31					

September

S	M	T	W	T	F	S
		1	2	3	4	5
6	7	8	9	10	11	12
13	14	15	16	17	18	19
20	21	22	23	24	25	26
27	28	29	30			

October

S	M	T	W	T	F	S
				1	2	3
4	5	6	7	8	9	10
11	12	13	14	15	16	17
18	19	20	21	22	23	24
25	26	27	28	29	30	31


November

S	M	T	W	T	F	S
1	2	3	4	5	6	7
8	9	10	11	12	13	14
15	16	17	18	19	20	21
22	23	24	25	26	27	28
29	30					

December

S	M	T	W	T	F	S
		1	2	3	4	5
6	7	8	9	10	11	12
13	14	15	16	17	18	19
20	21	22	23	24	25	26
27	28	29	30	31		

For a copy of today's presentation,
Learning Center info or the essential
Learning Center Library



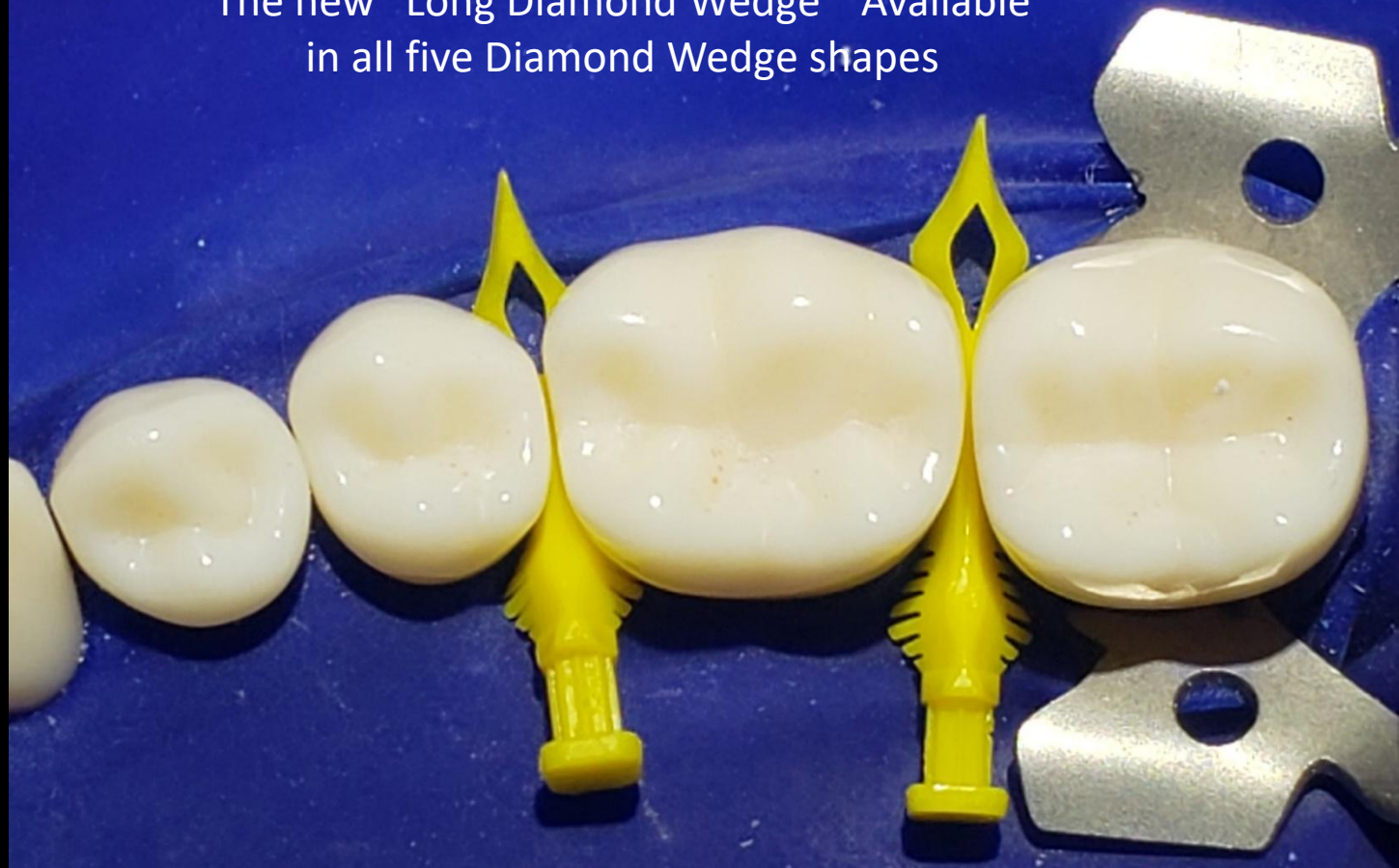
Course
Code:
6940



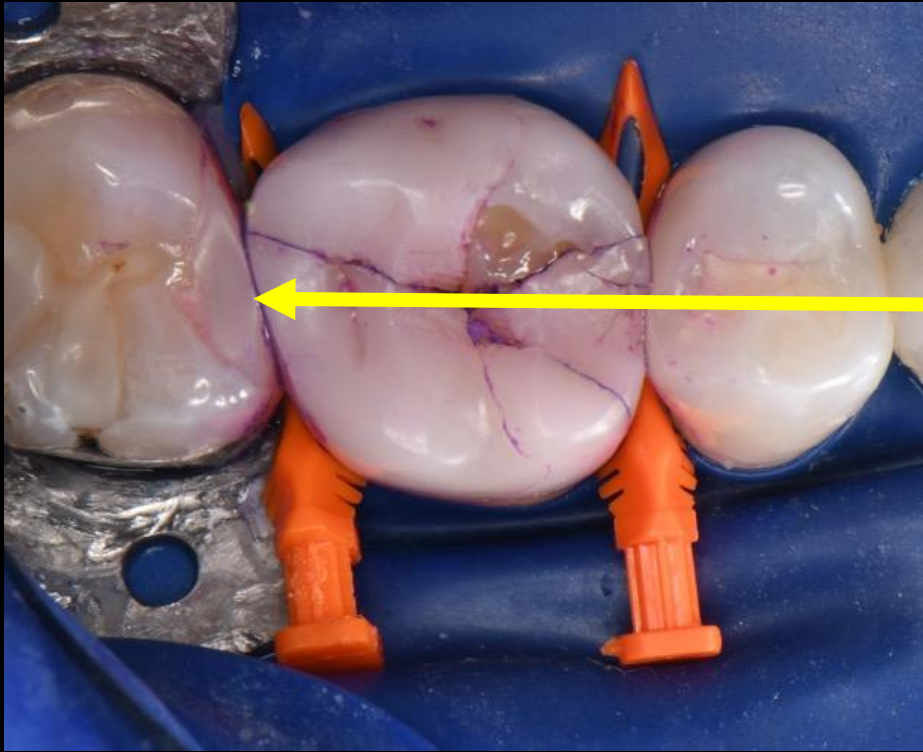
BIOCLEAR LEARNING CENTER


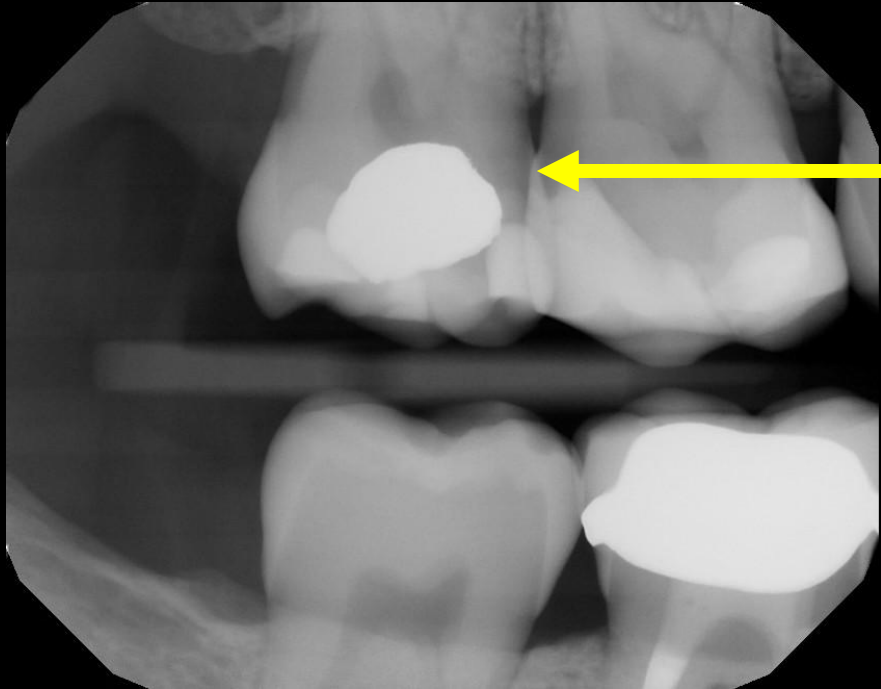
Tacoma USA · Solihull UK
Varberg Sweden · Cairo Egypt
Syracuse Italy · Taubate Brazil
Livermore CA (Bioclear pediatrics)
Seoul Korea · Madrid/Barcelona
Sydney Australia · Provence France

The new “Long Diamond Wedge” Available
in all five Diamond Wedge shapes

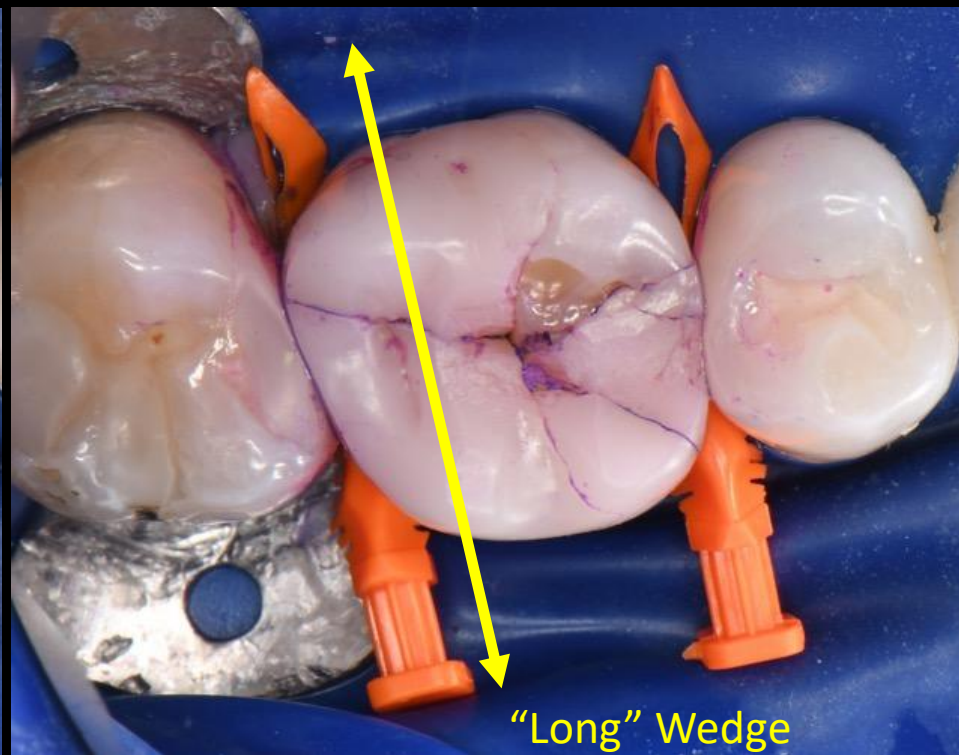
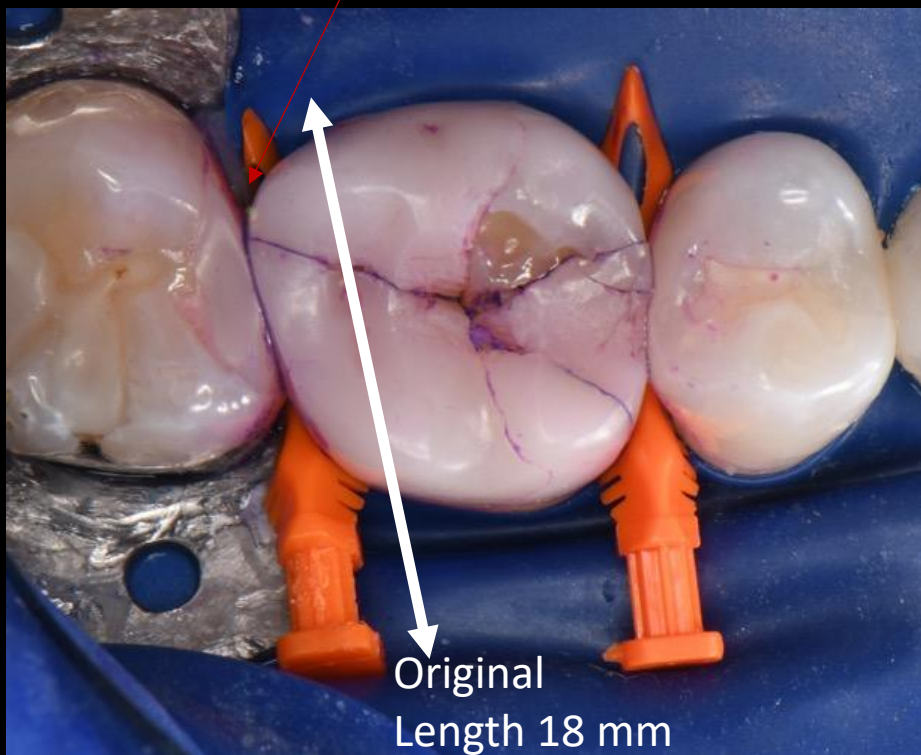


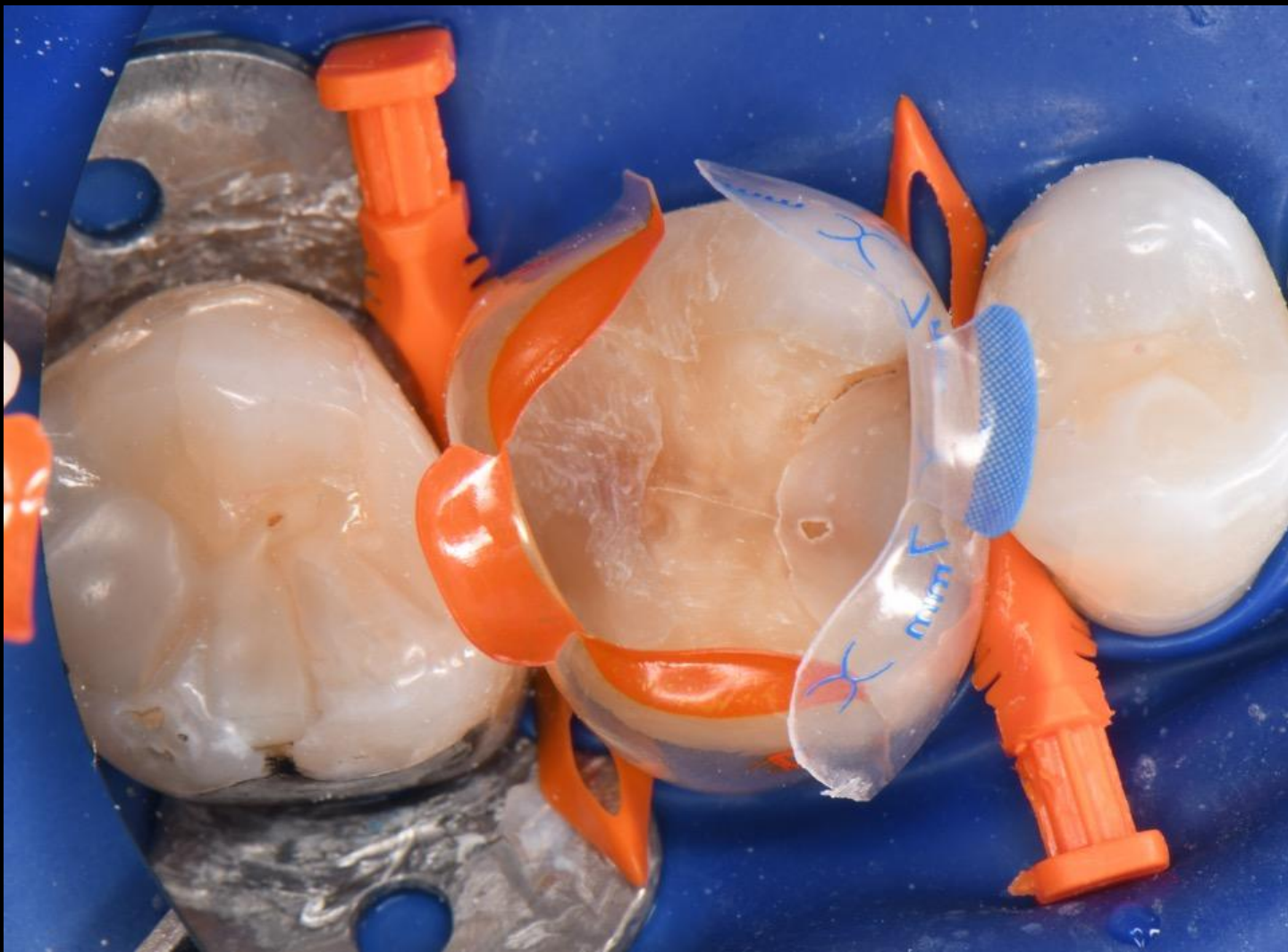

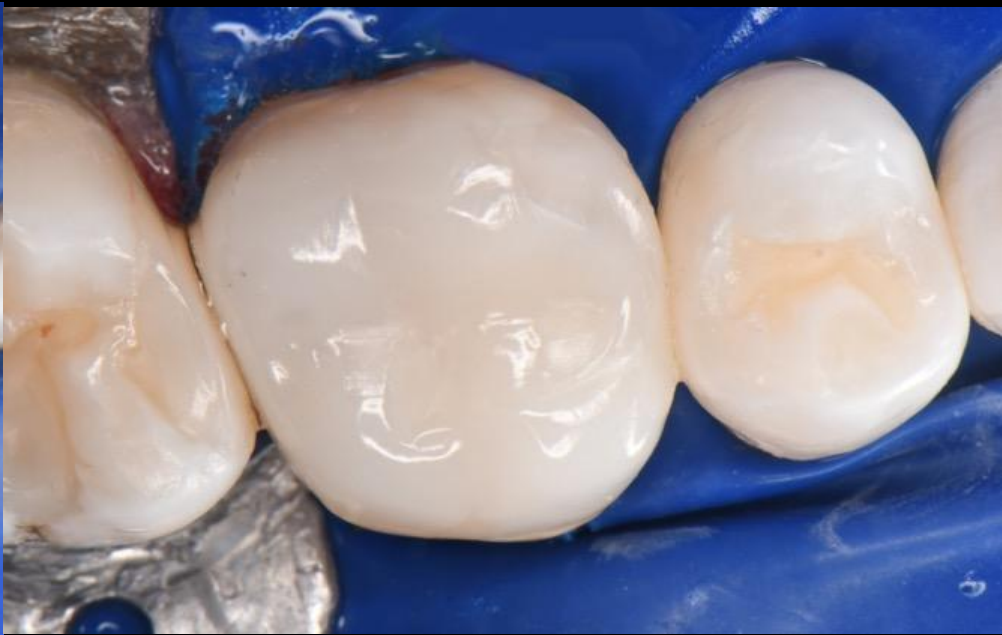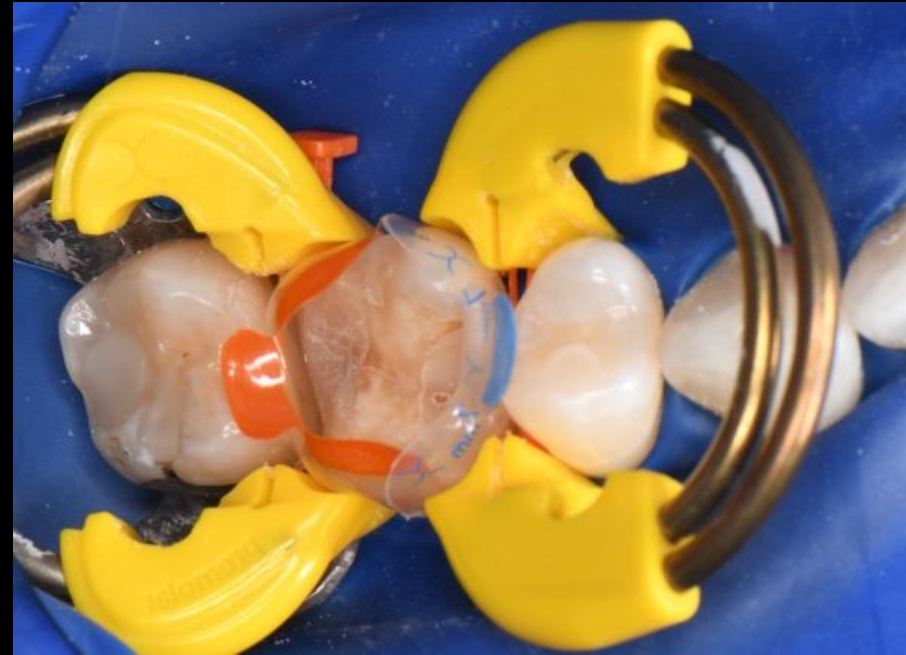




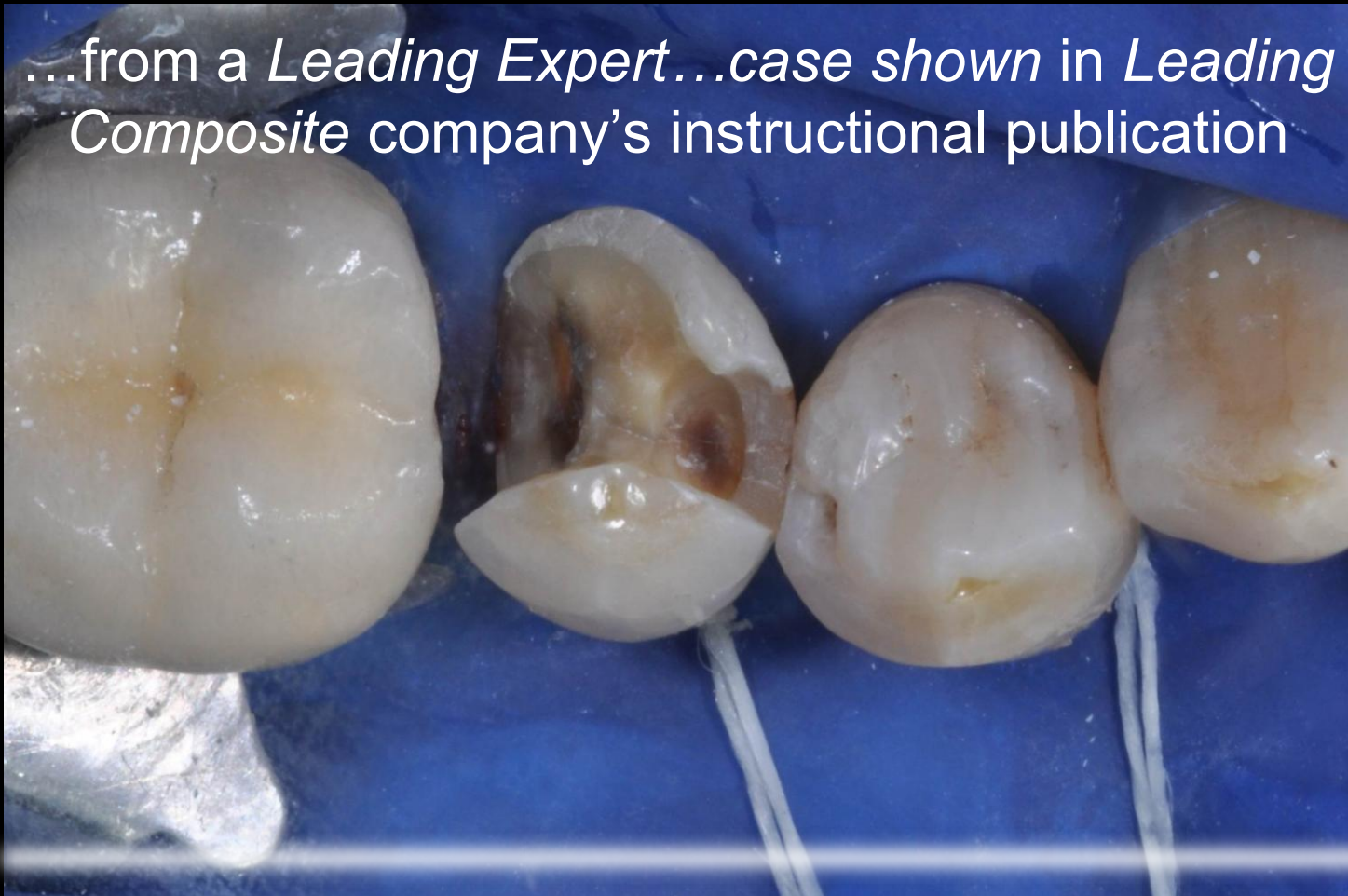The new “Long Diamond Wedge” Available
in all five Diamond Wedge shapes

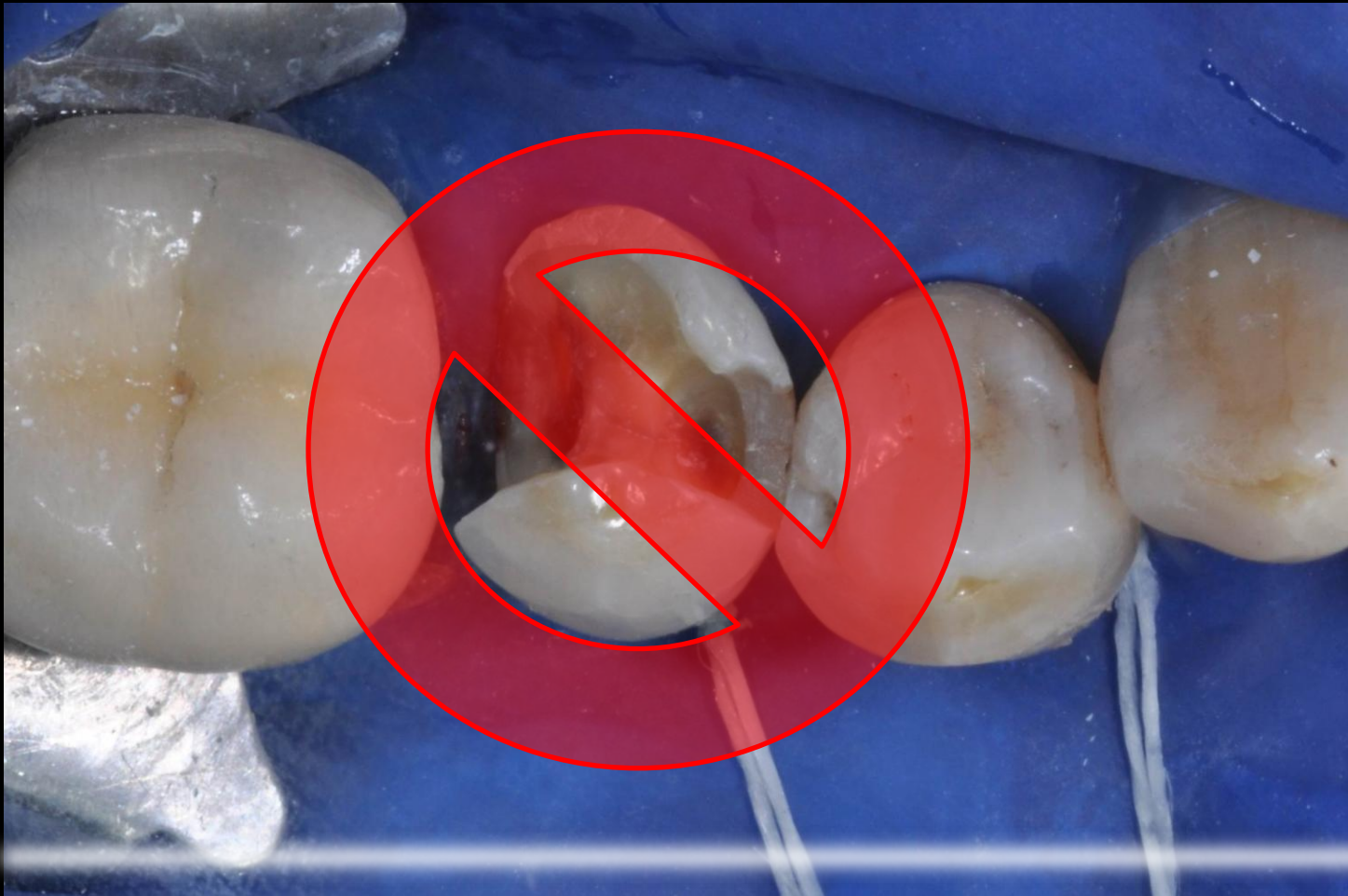





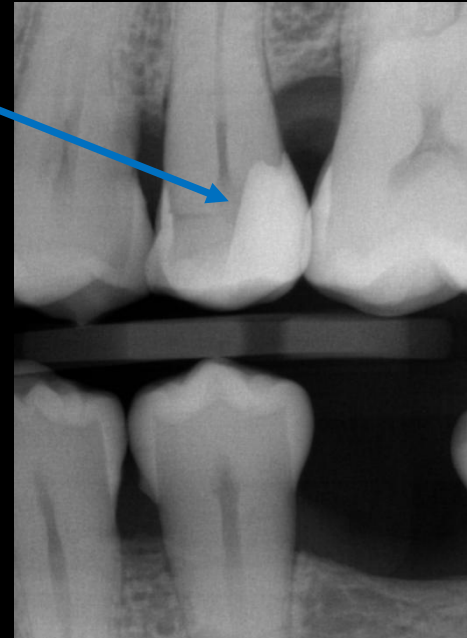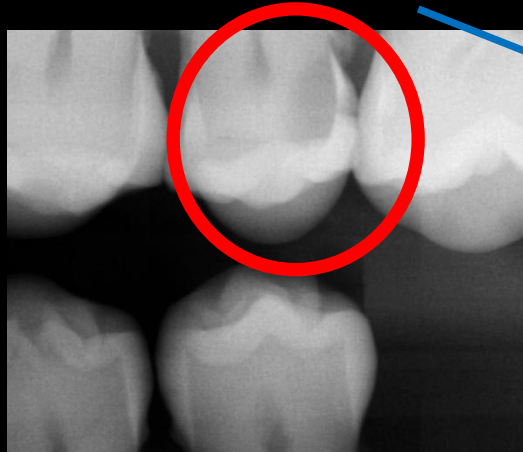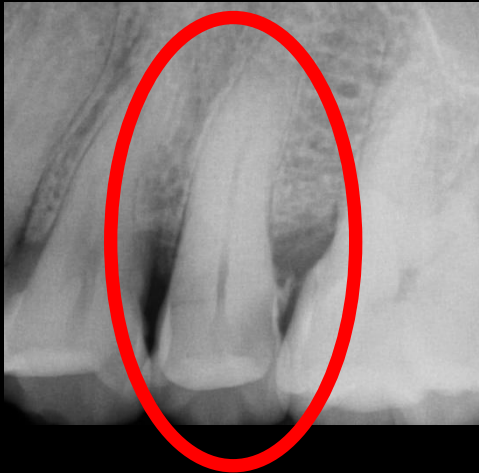
...from a *Leading Expert*...case shown in *Leading Composite* company's instructional publication

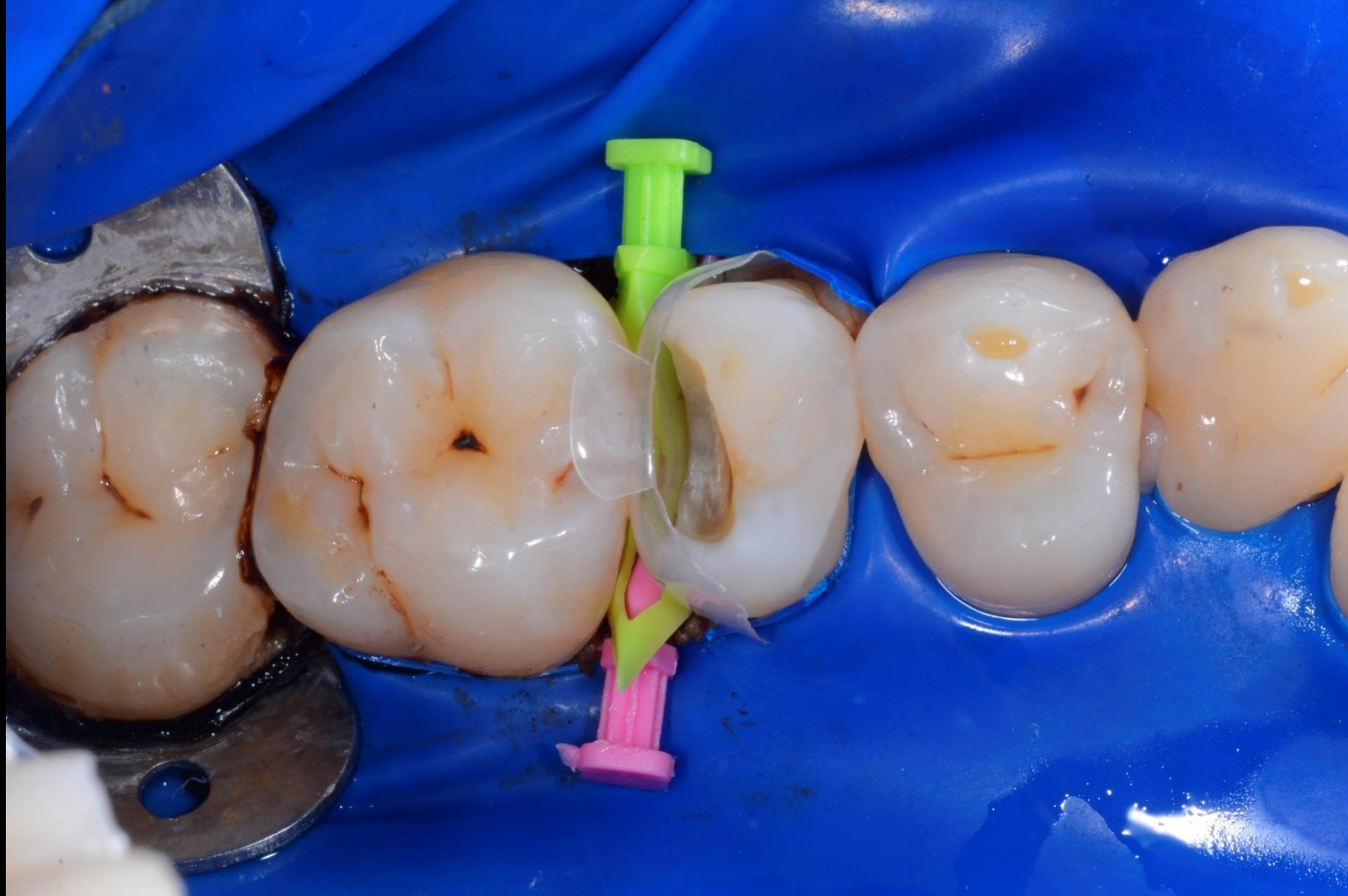



Arturo's first appointment:

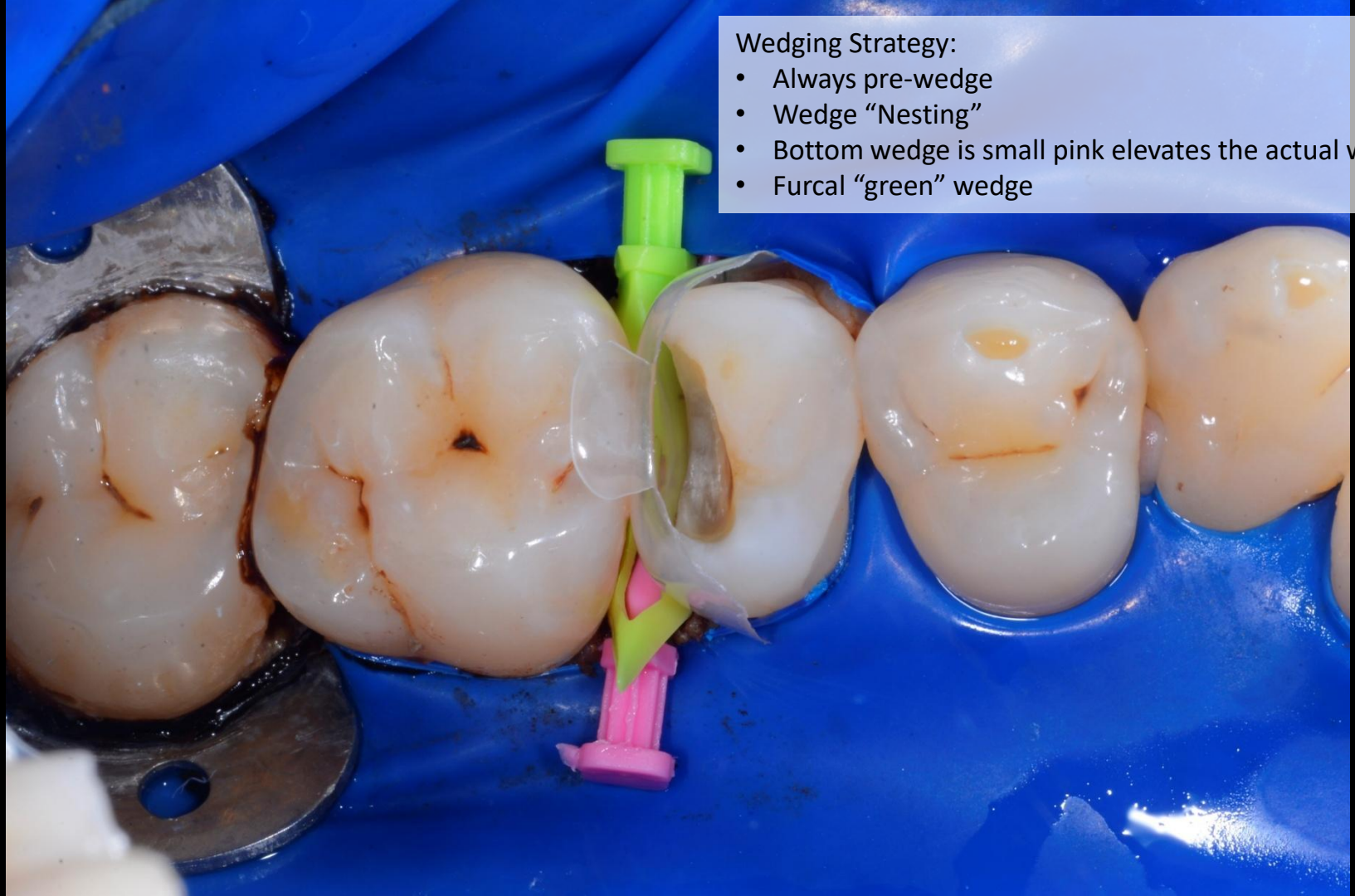- Flight Risk
- Chief Complaint – painful food impaction 13-14
- Limited Resources
- Not a good candidate for multi-appointment
- Calculus Removal took longer than the prep
- Little to no post operative pain
- SCR (Modified Hall): 0999 code \$175 add'l fee

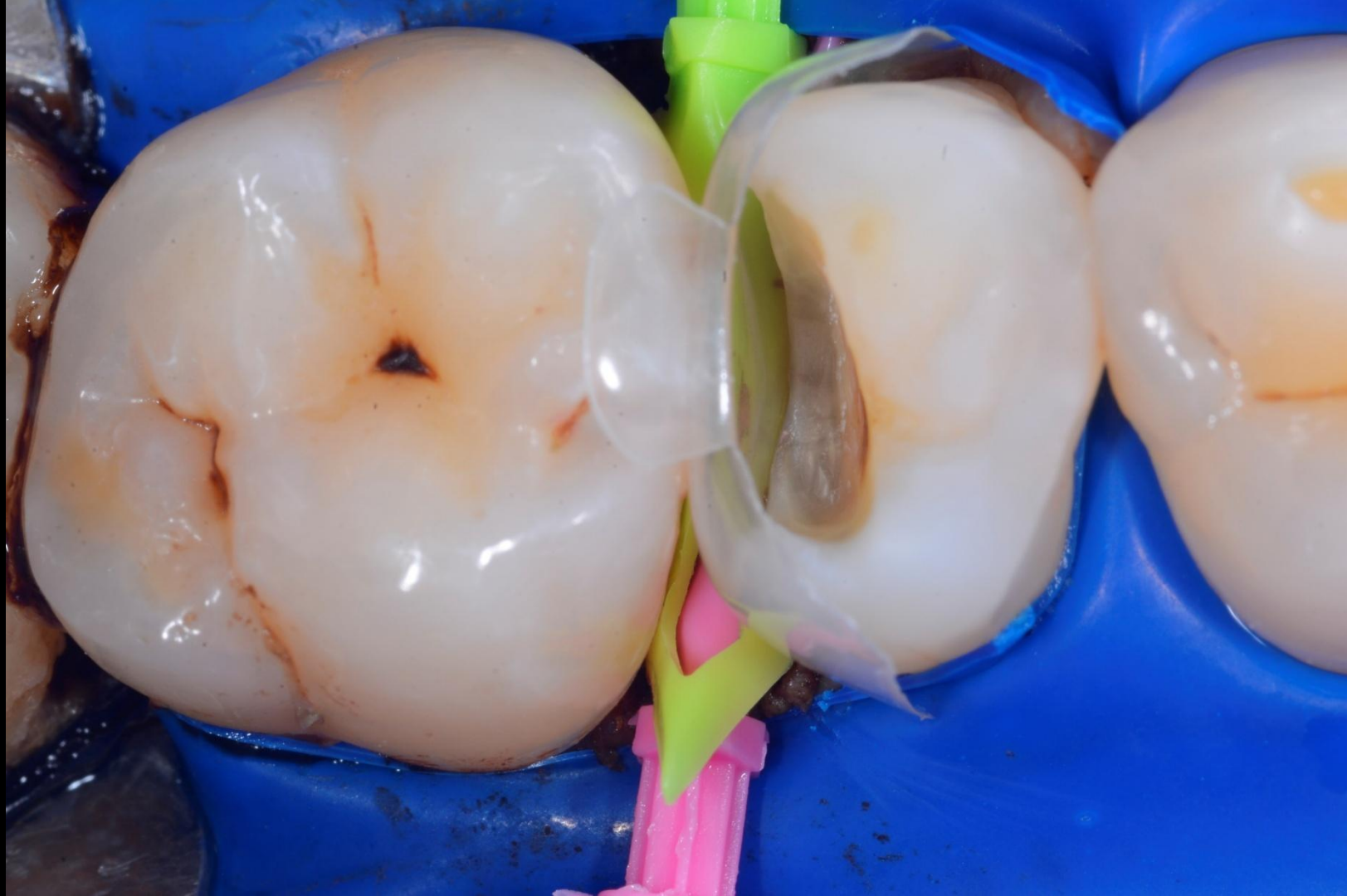


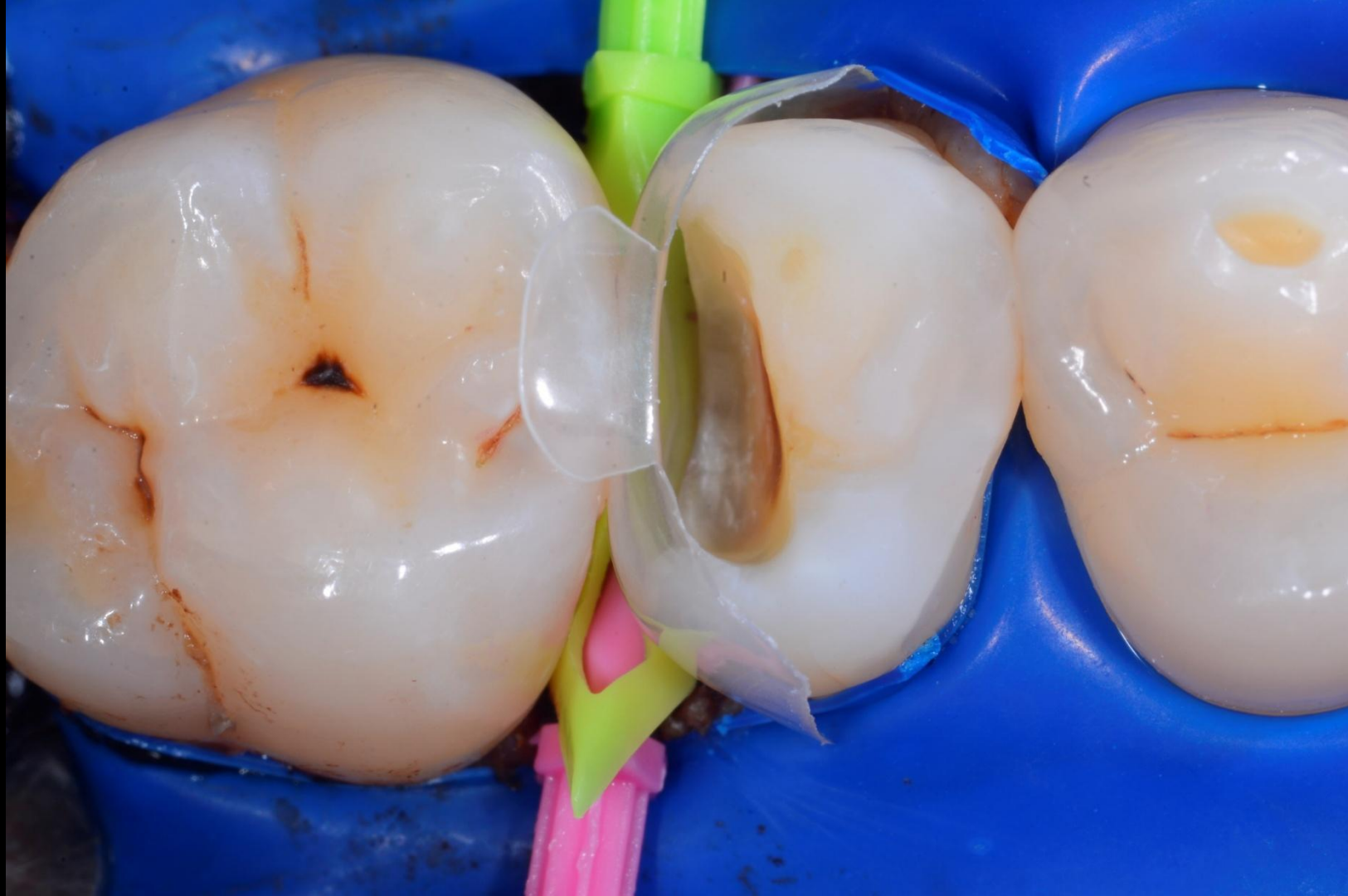
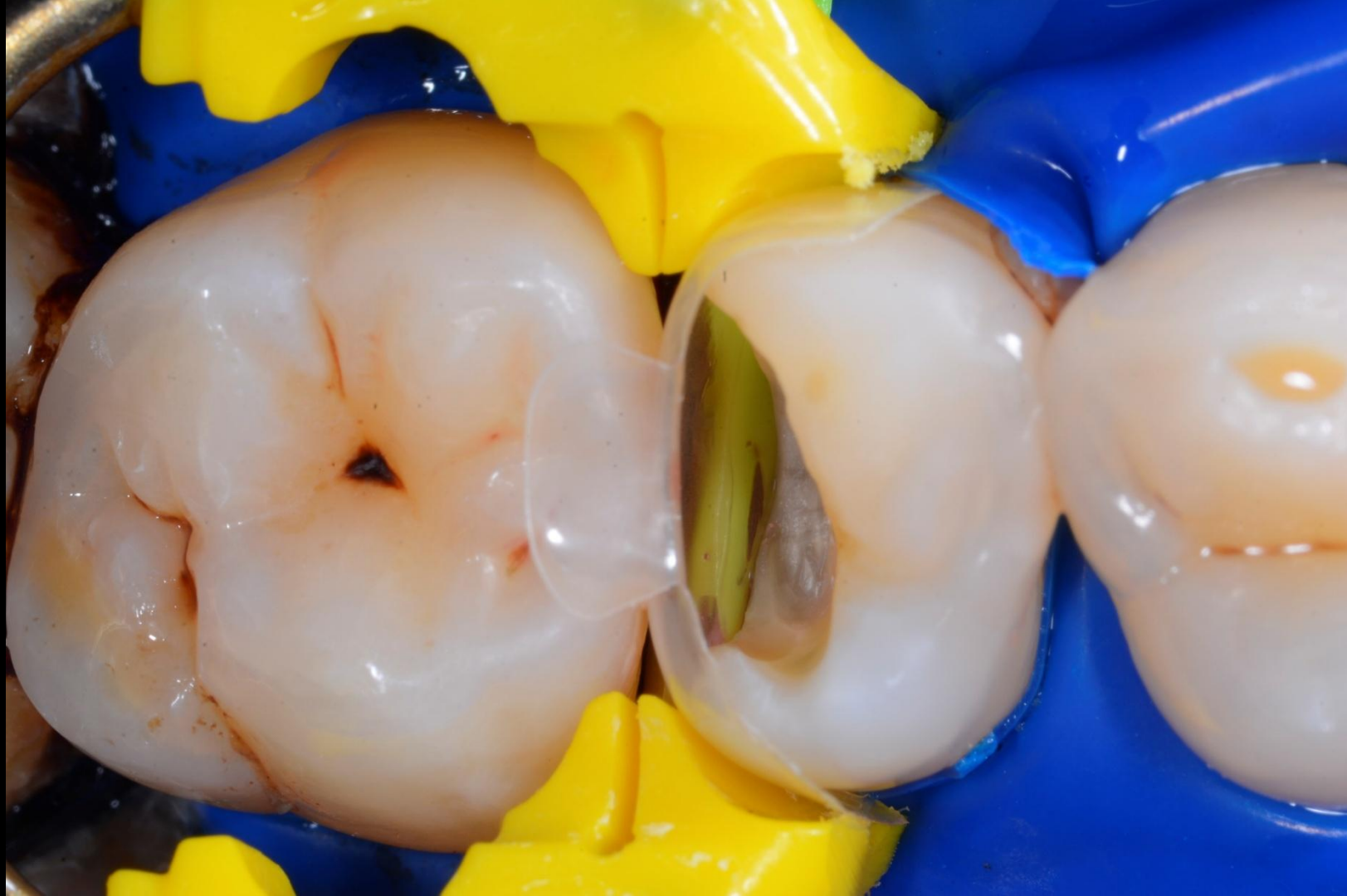Wedging Strategy:

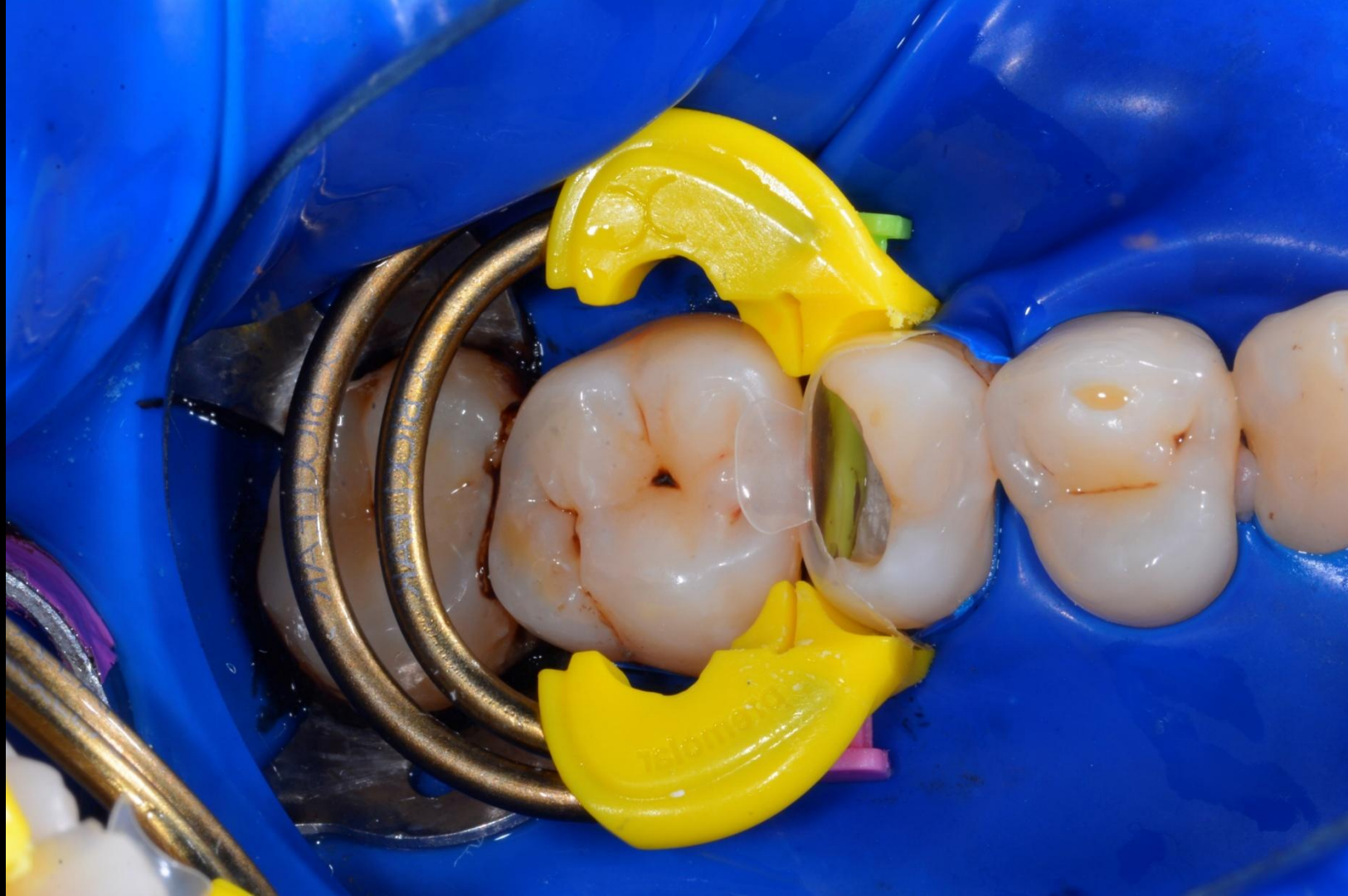- Always pre-wedge
- Wedge “Nesting”
- Bottom wedge is small pink elevates the actual wedge
- Furcal “green” wedge

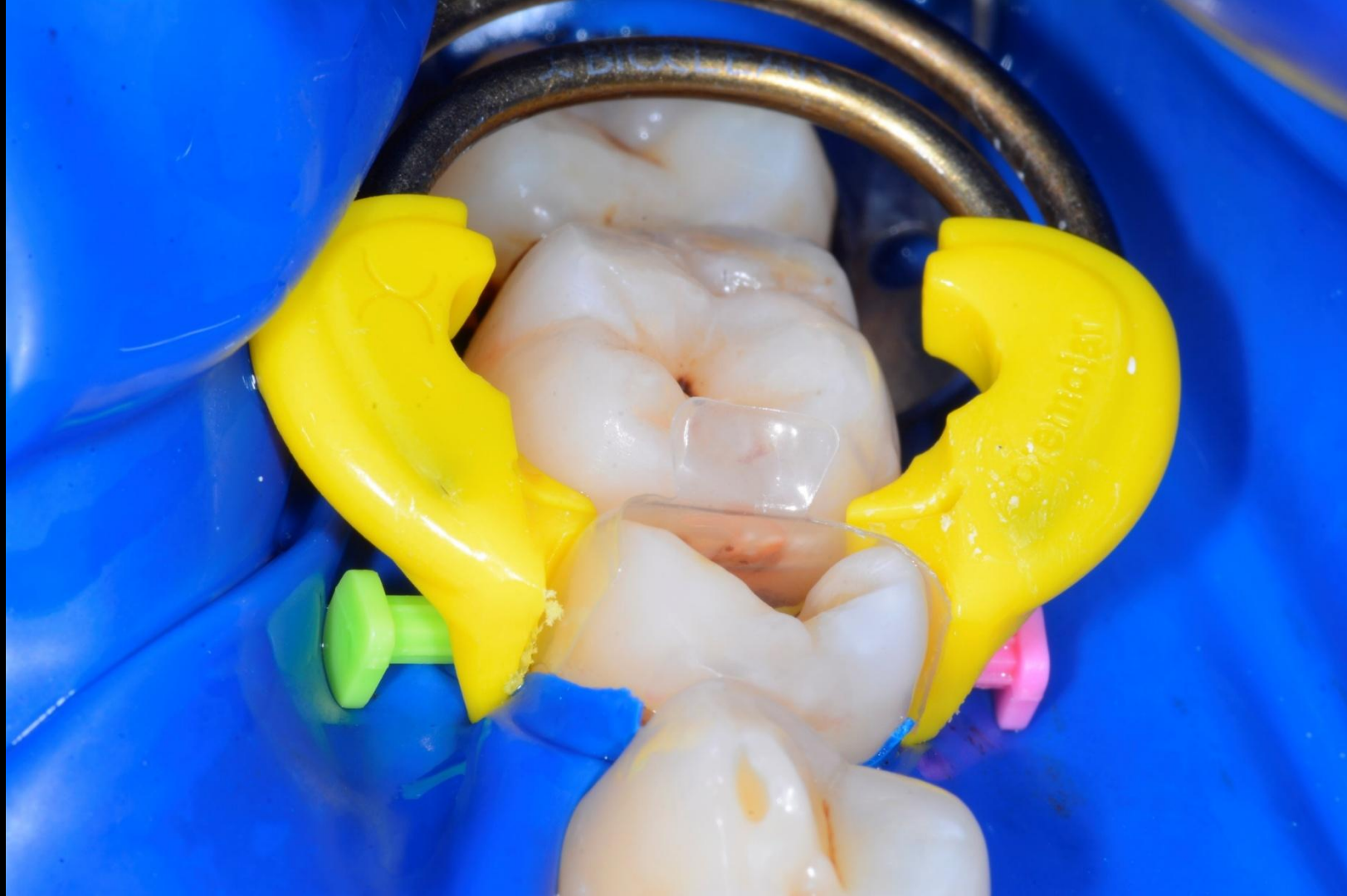


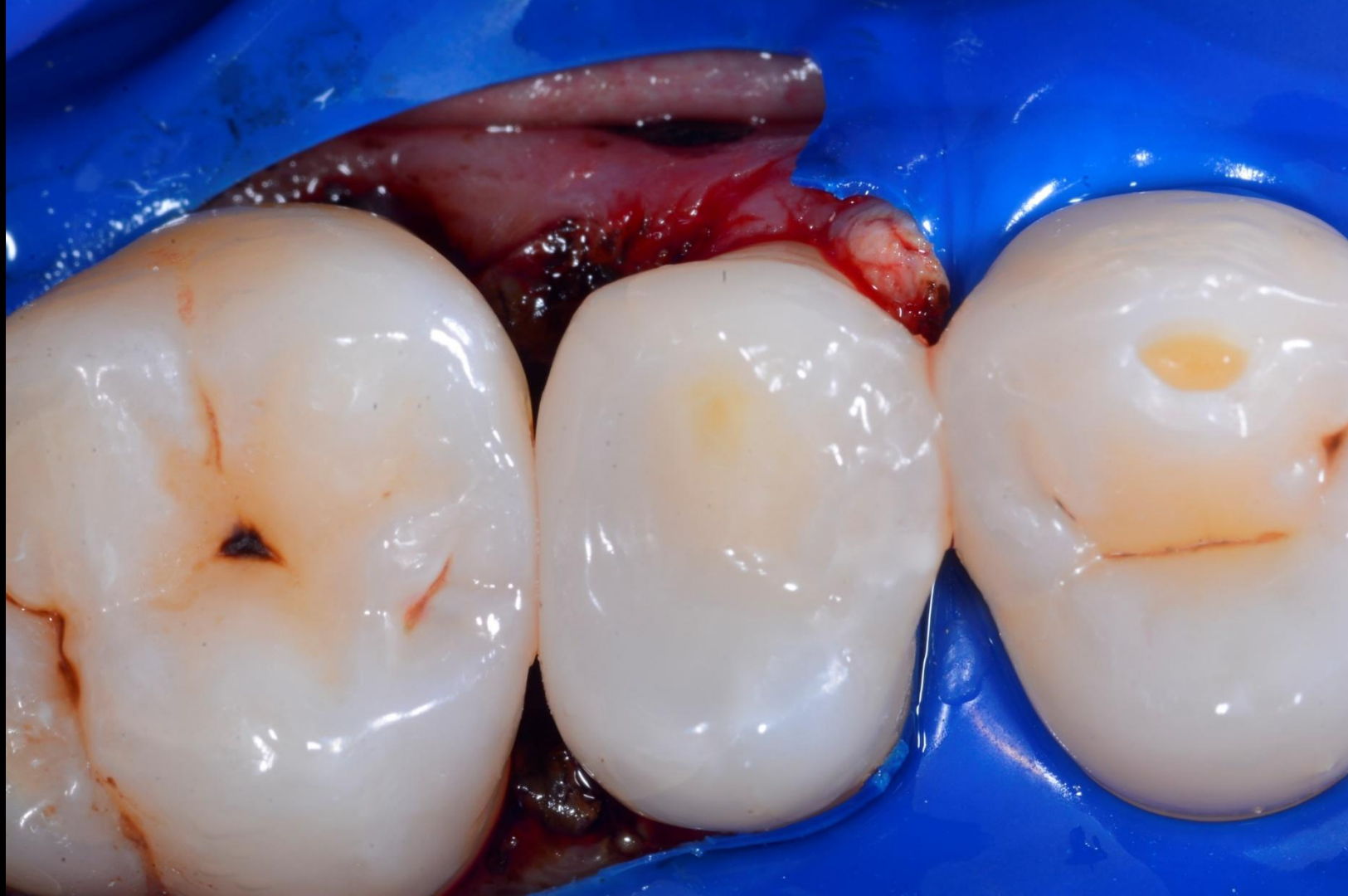


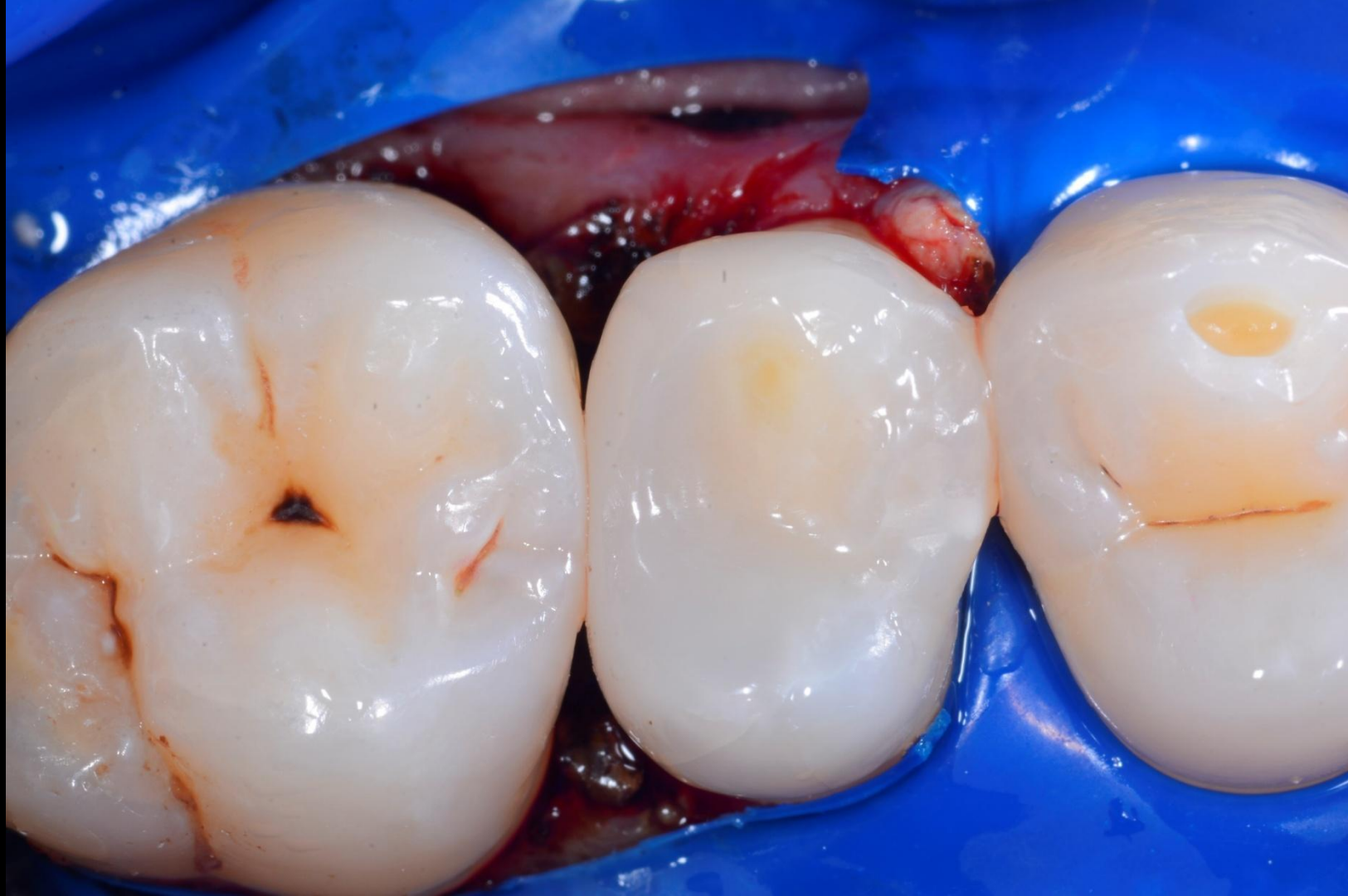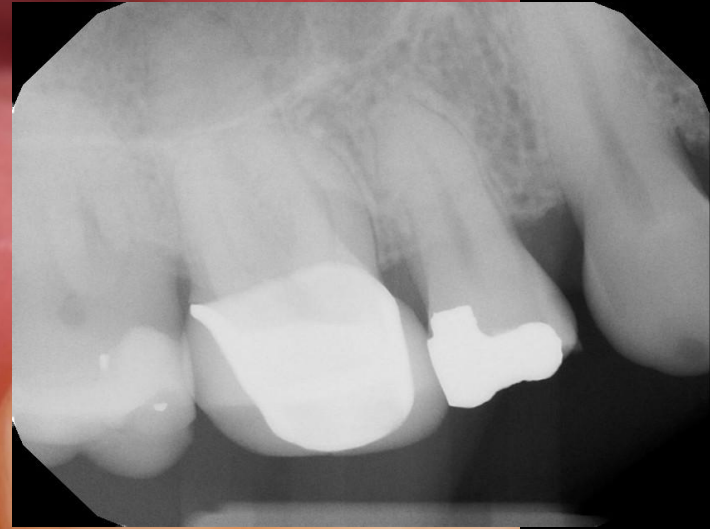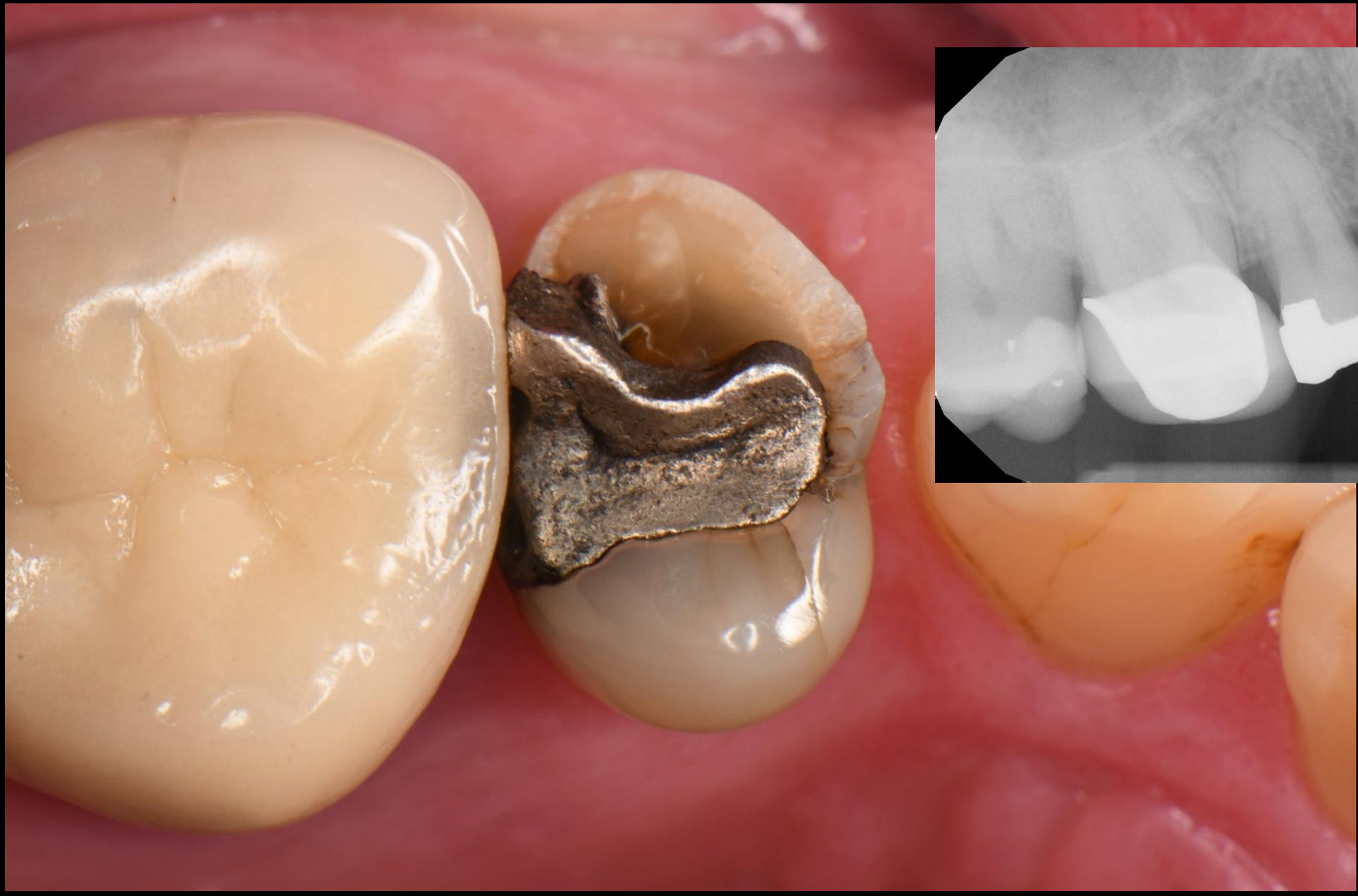




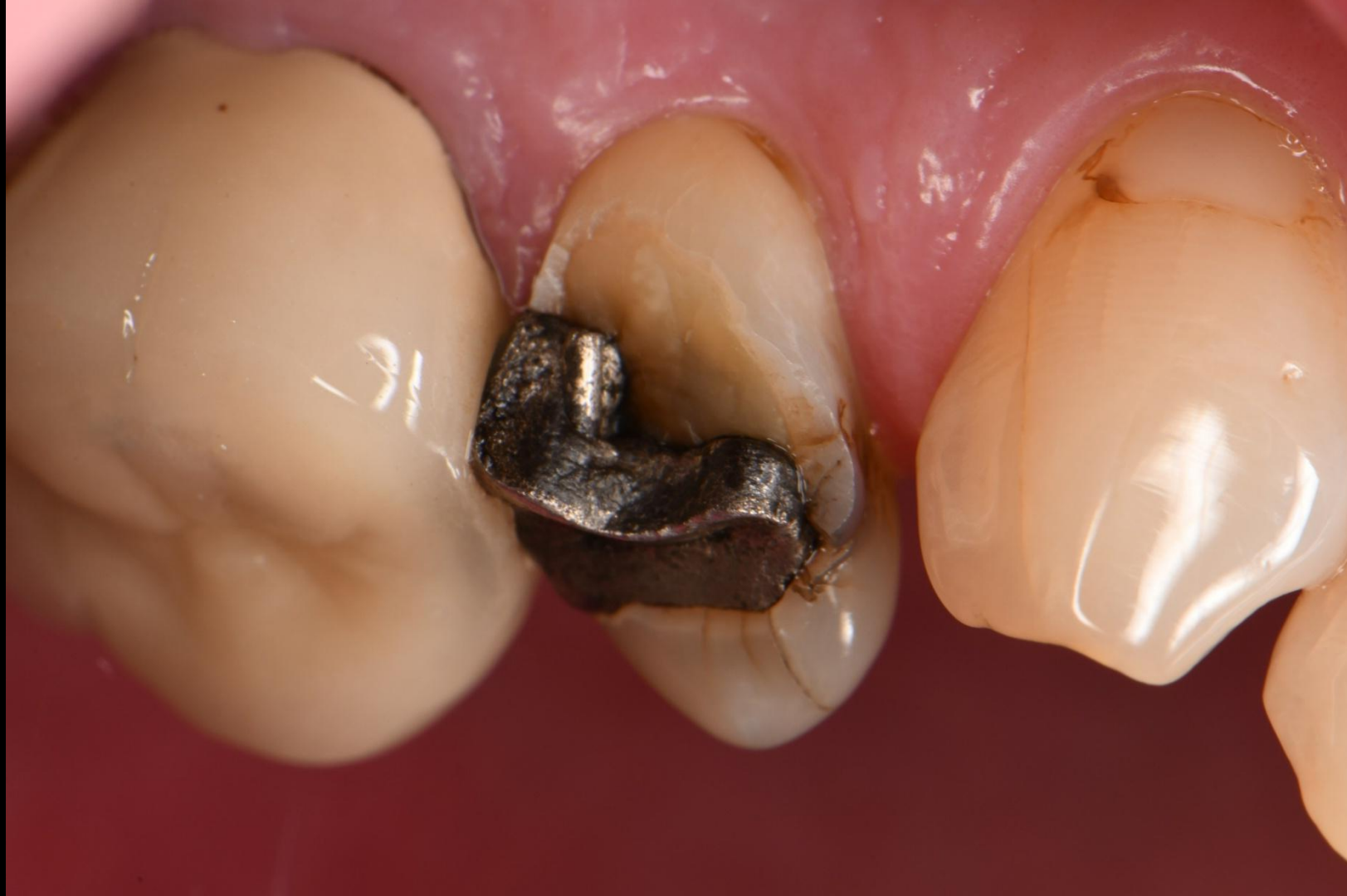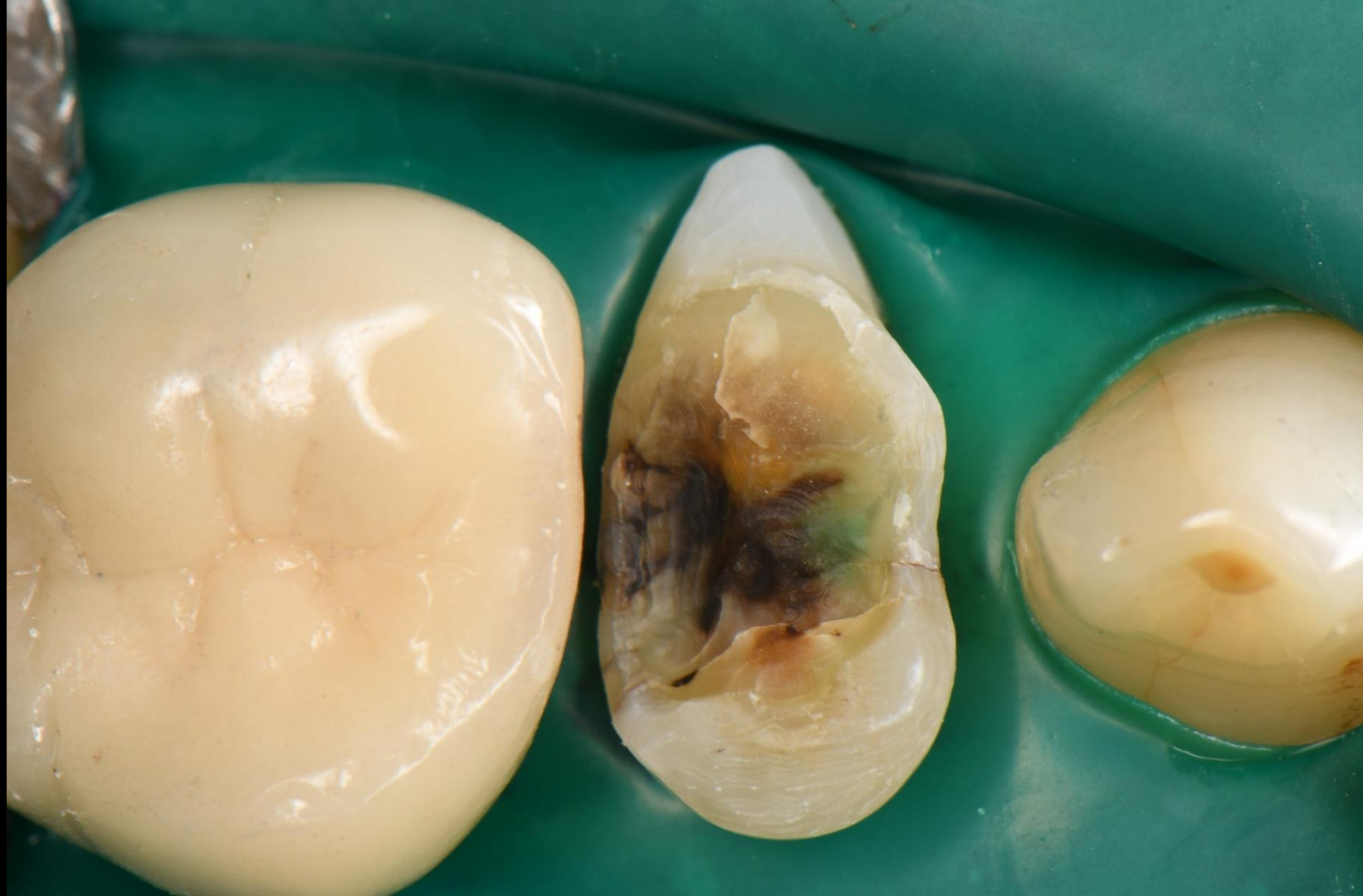




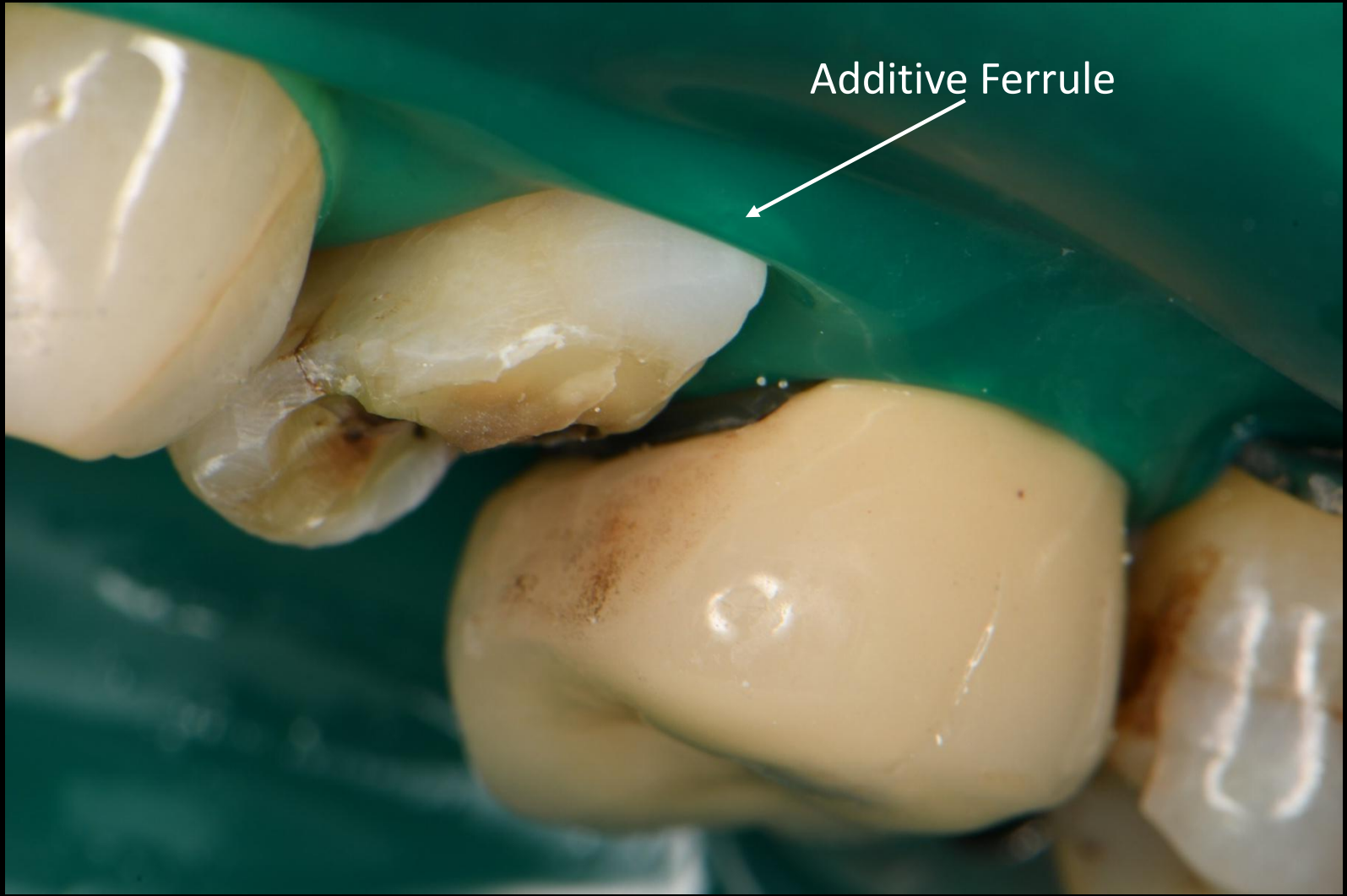




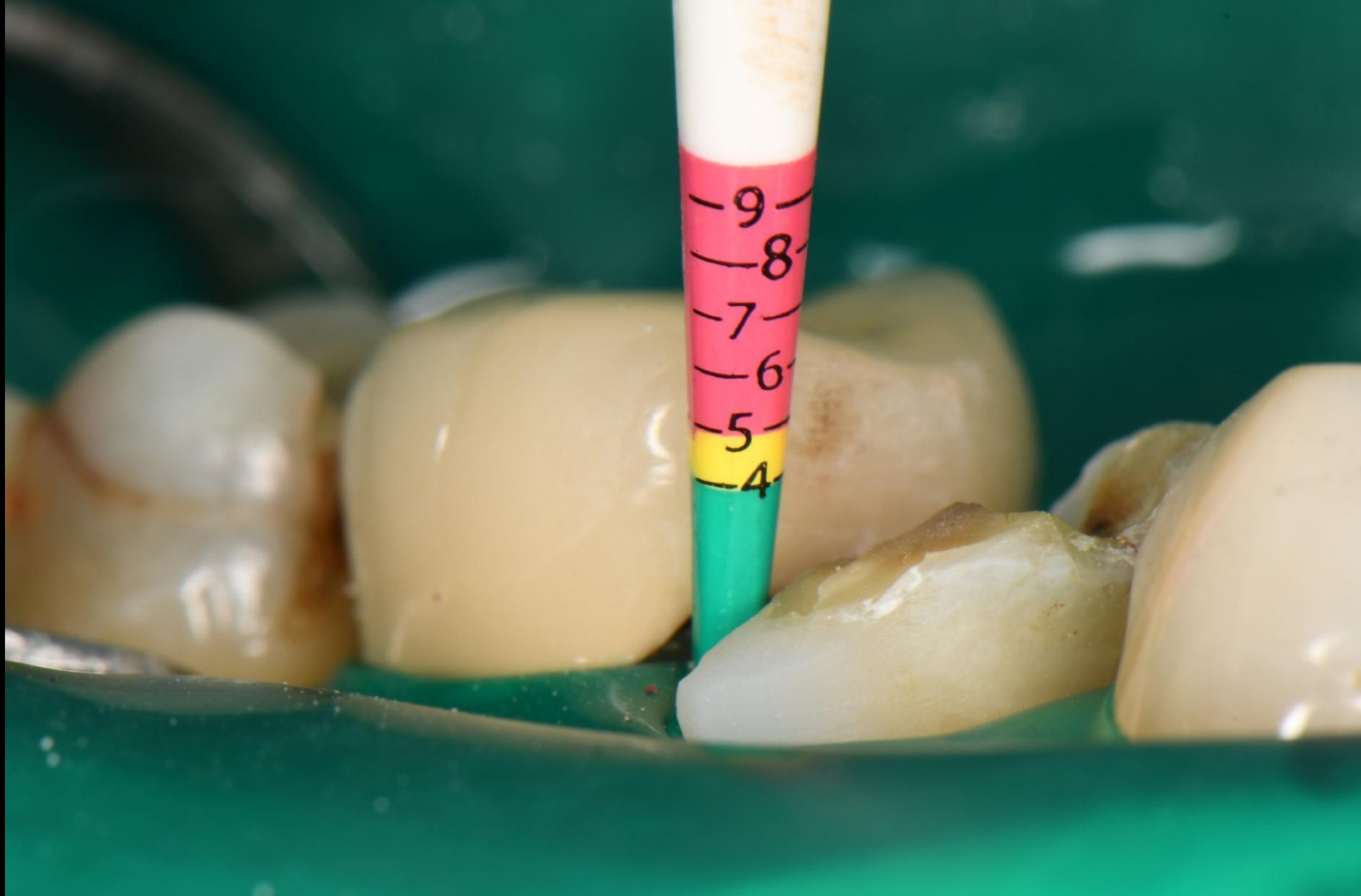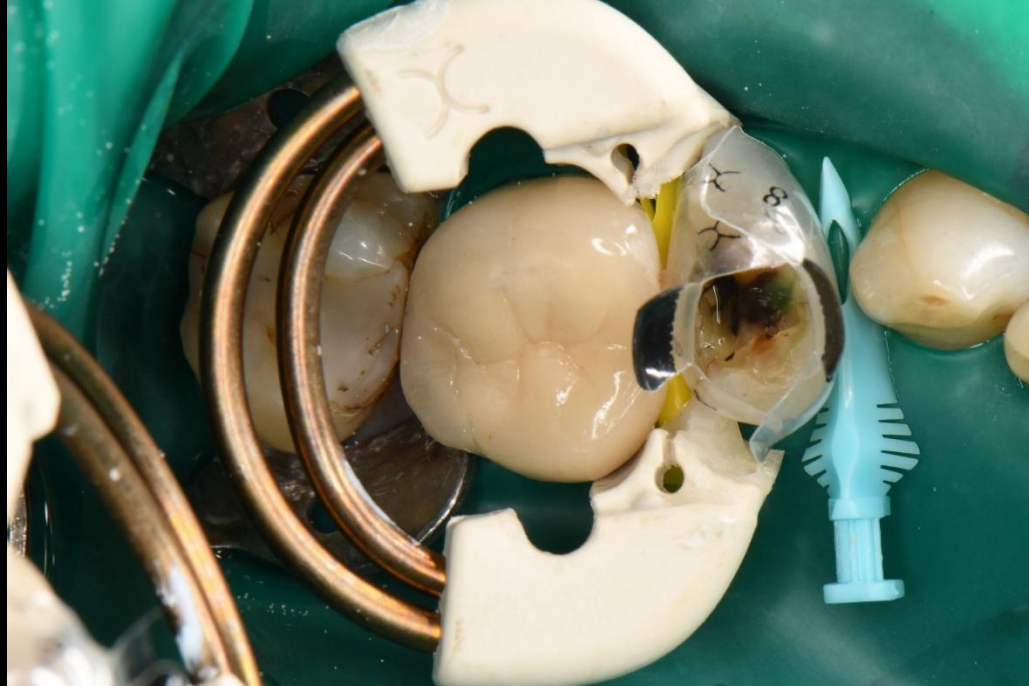




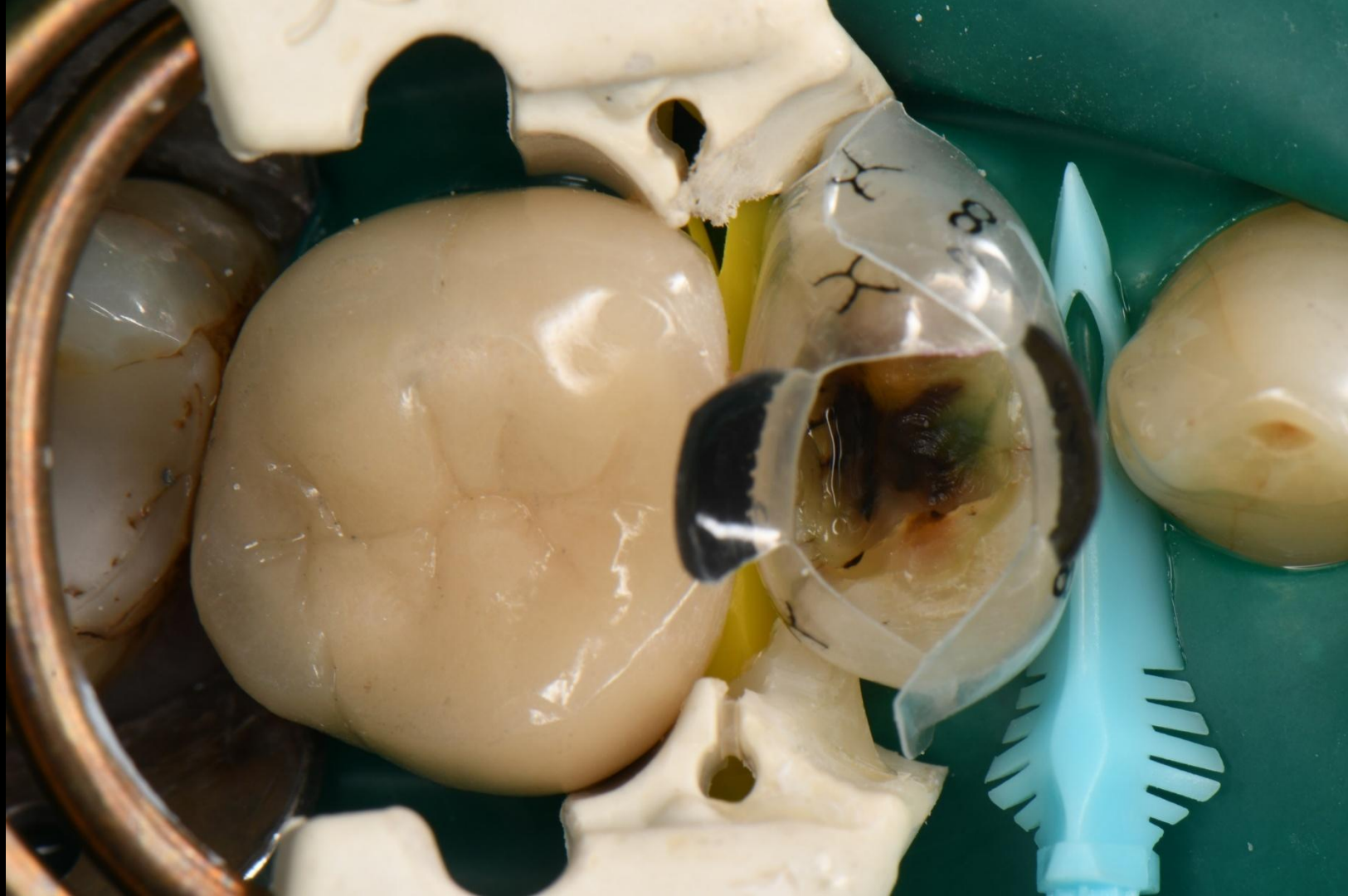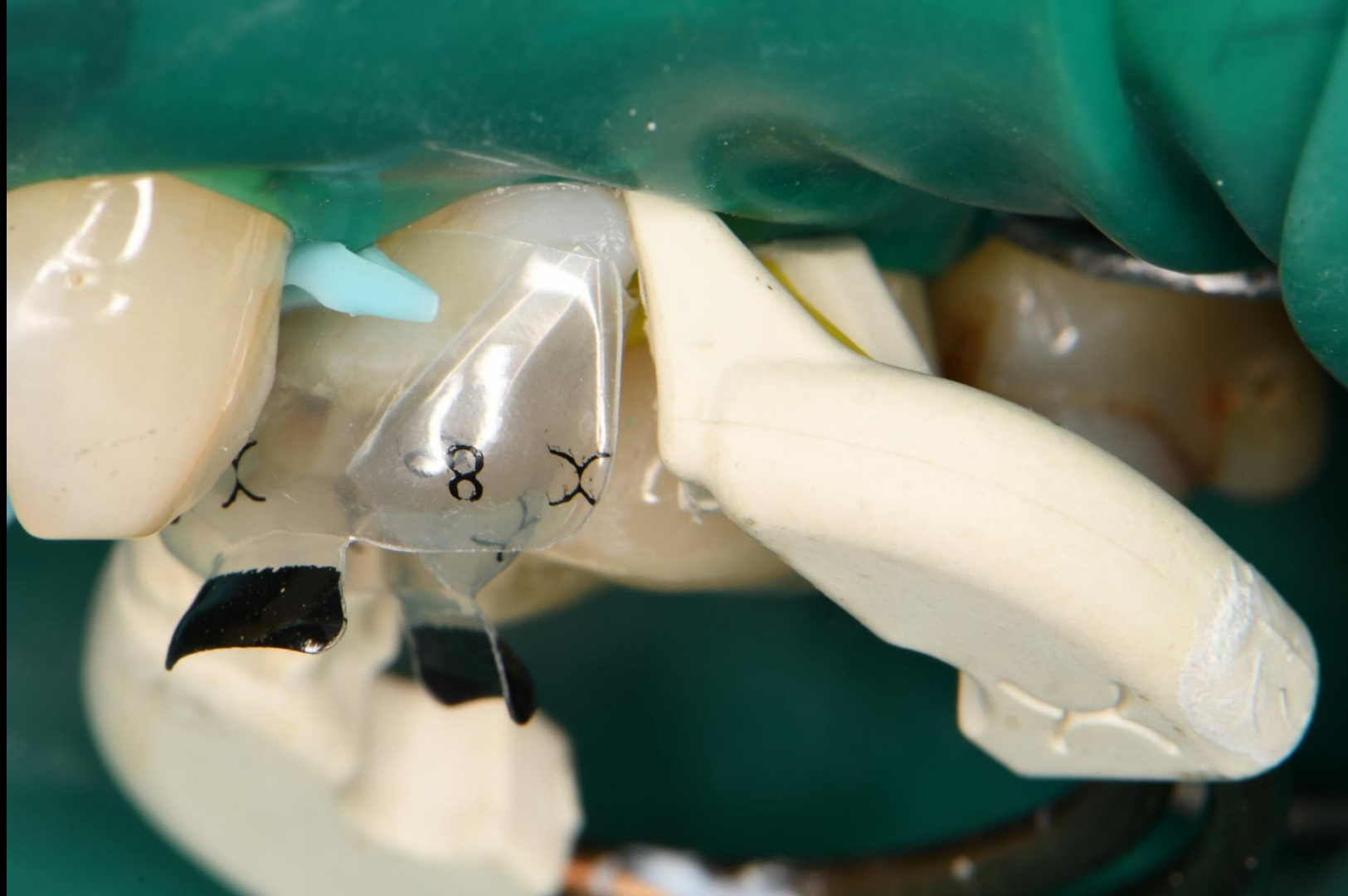Additive Ferrule

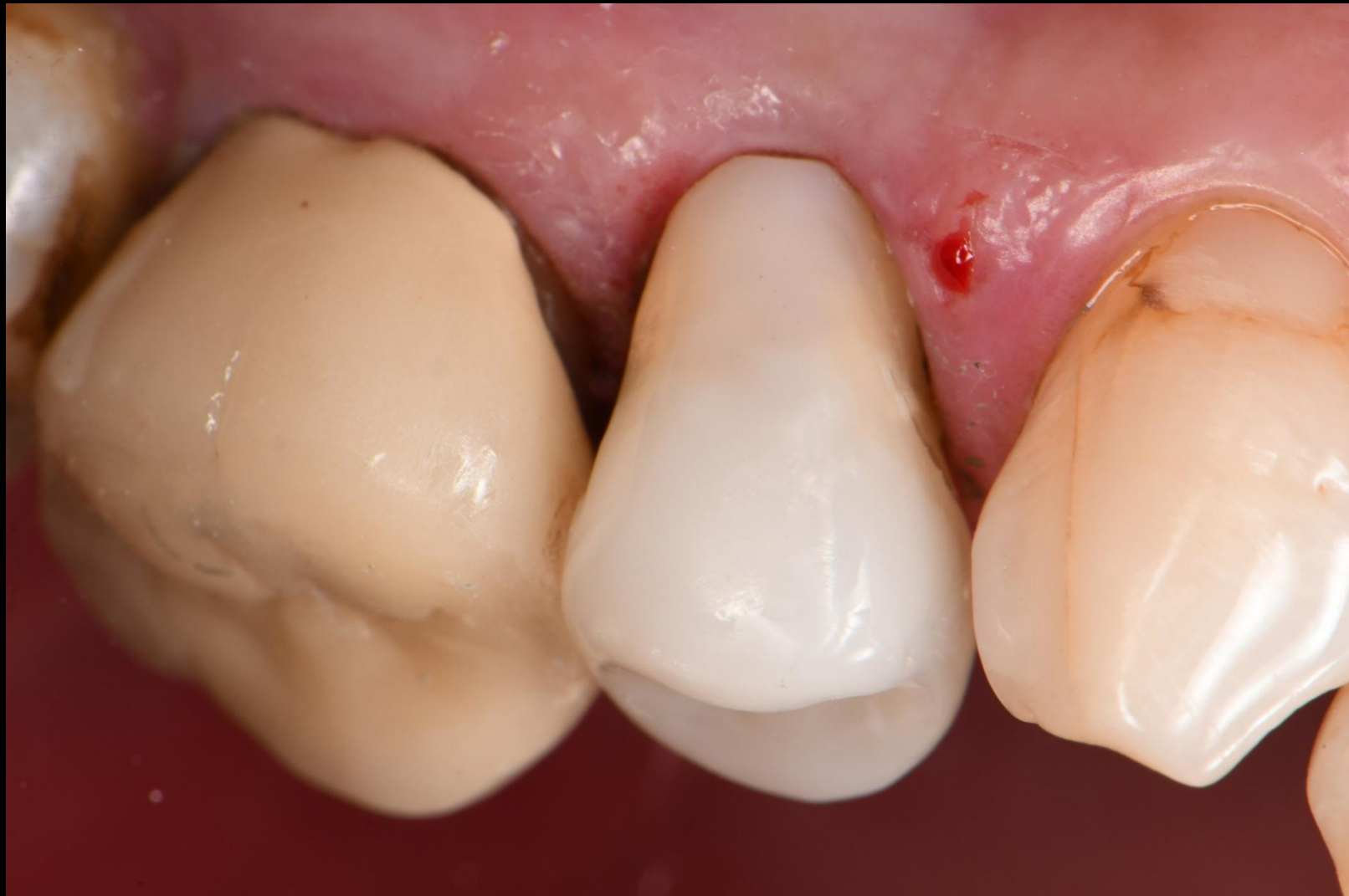


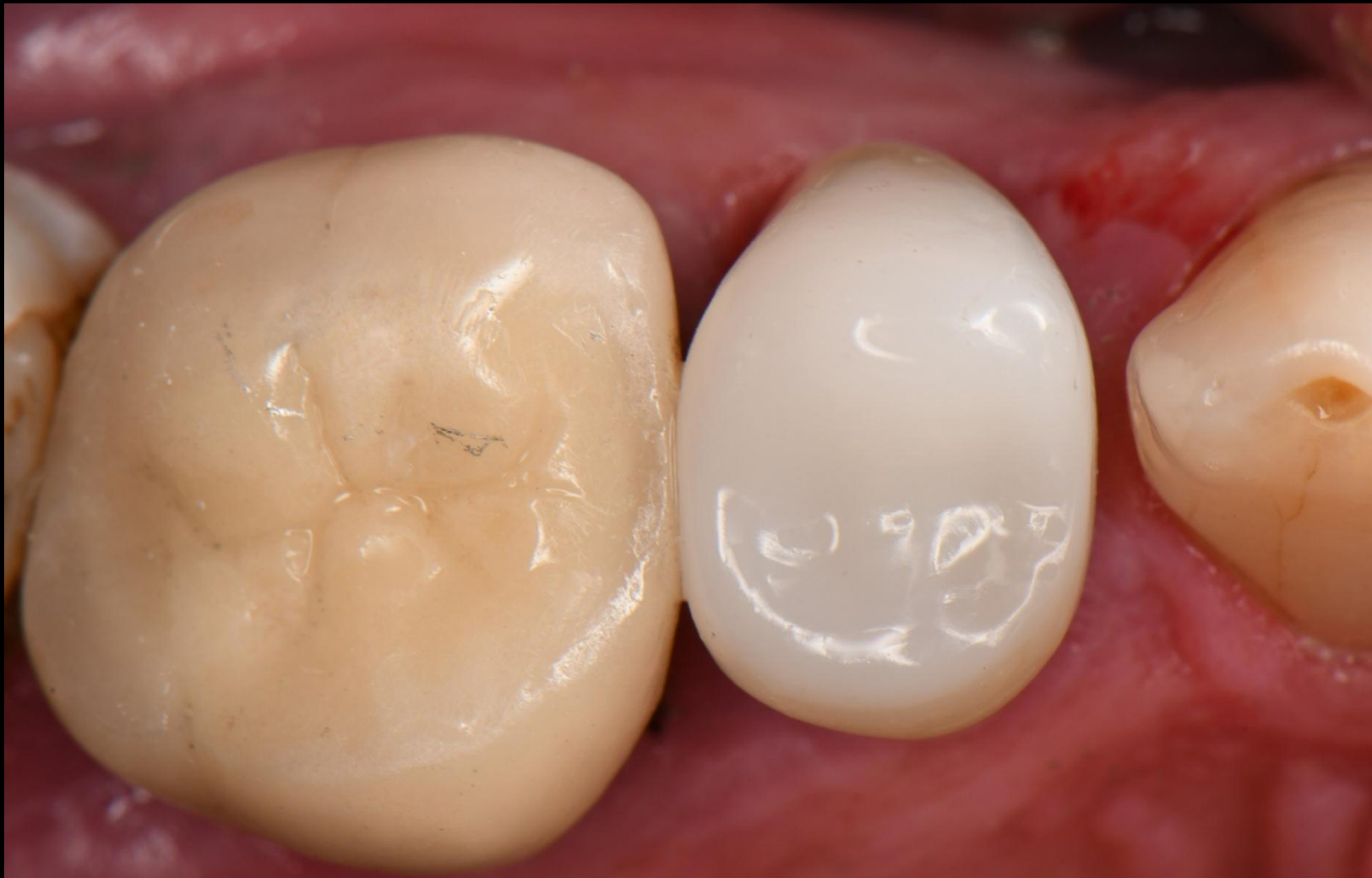


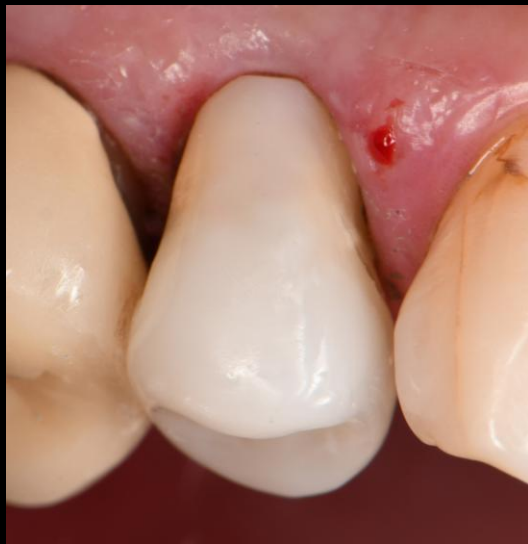
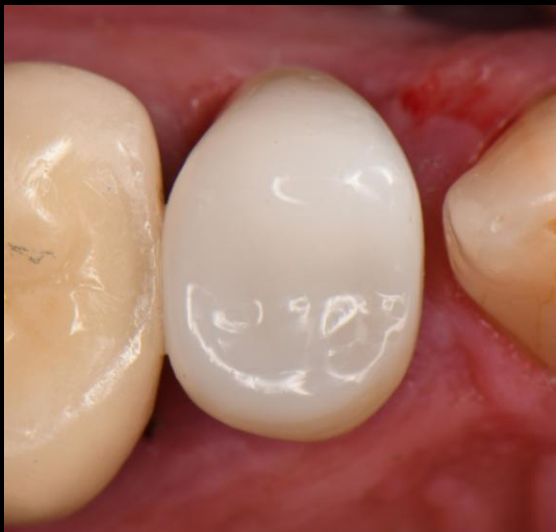
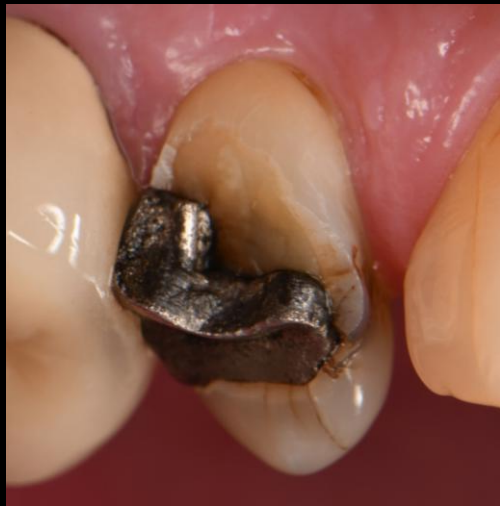
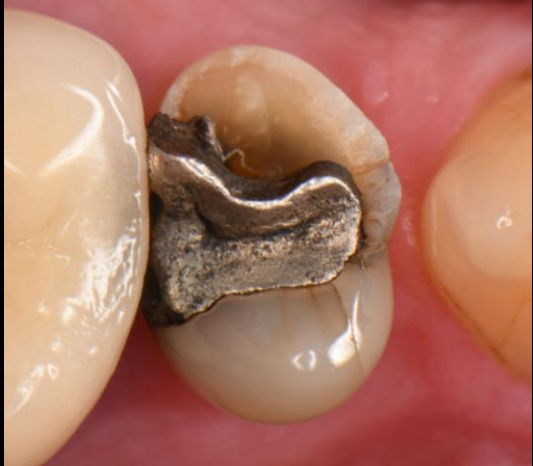








Dr. Rafael Bustamante
Full Faculty



Dr. David
Founder & F



Dr. Joshua Solomon
Full Faculty



Dr. Abd
F



Dominic Hassall
 Full Faculty



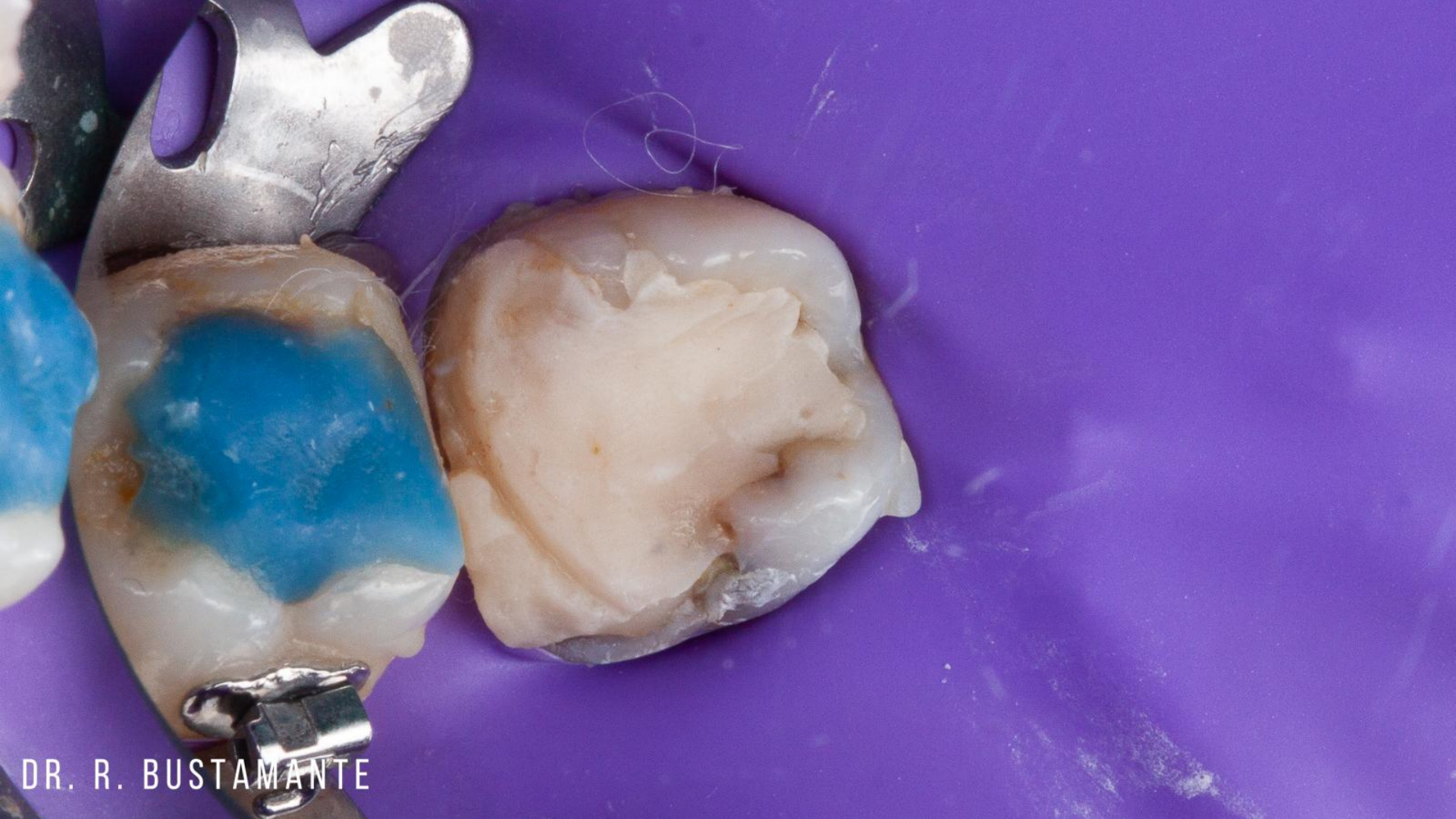Dr. Marco Maiolino
Full Faculty



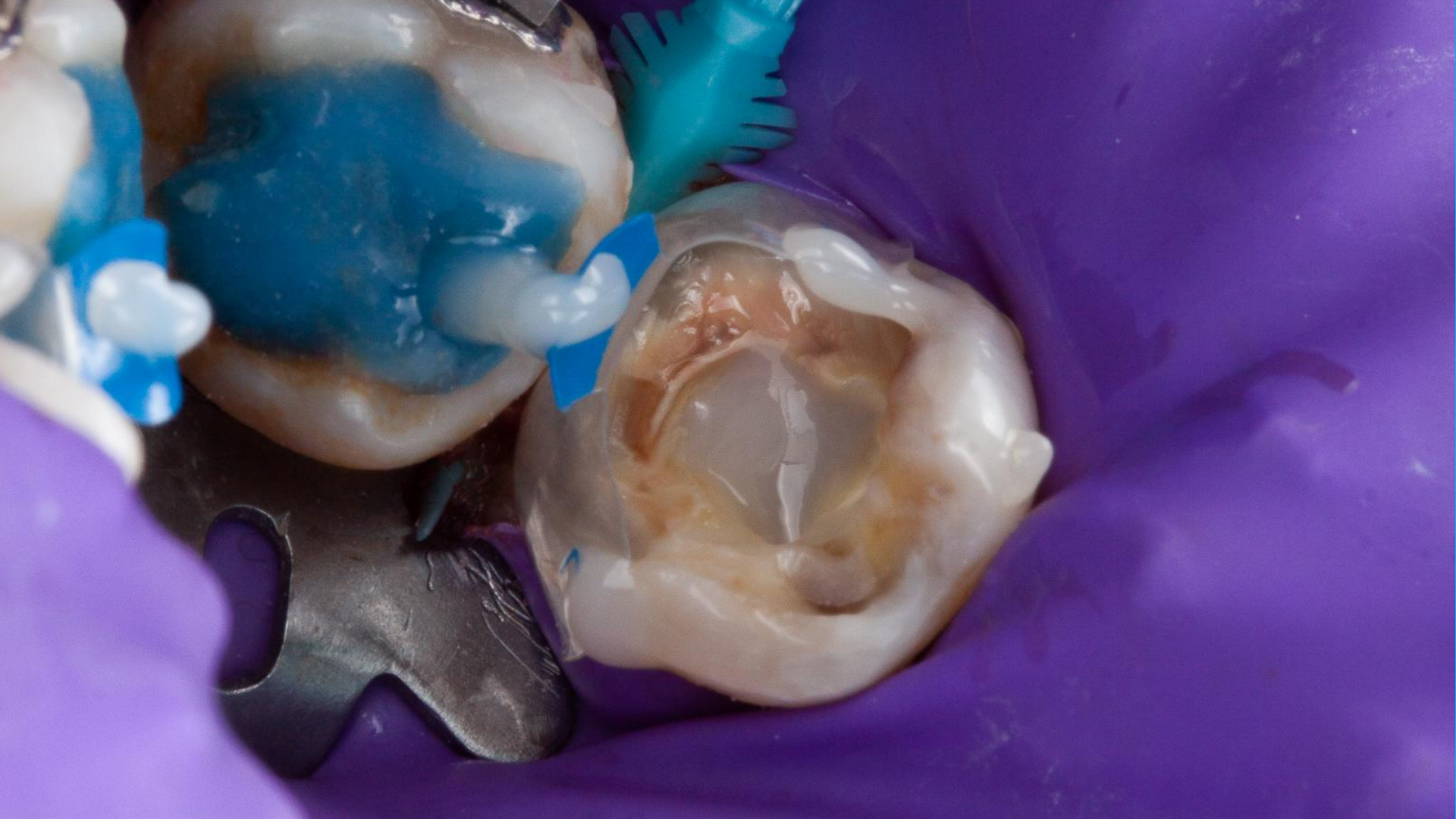Agnes
 y Track

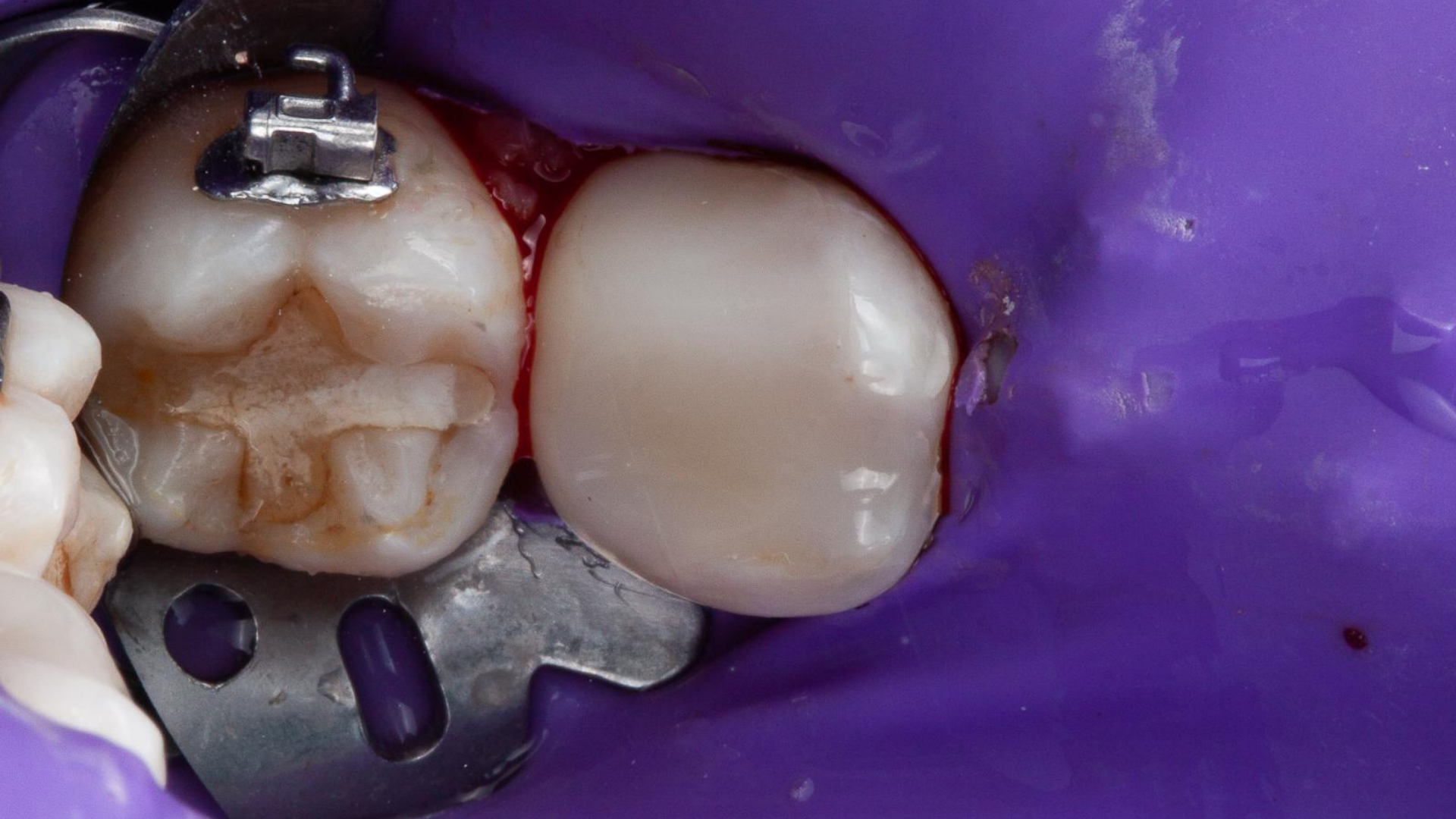

Dr. David Carroll
Adjunct Faculty



DR. R. BUSTAMANTE

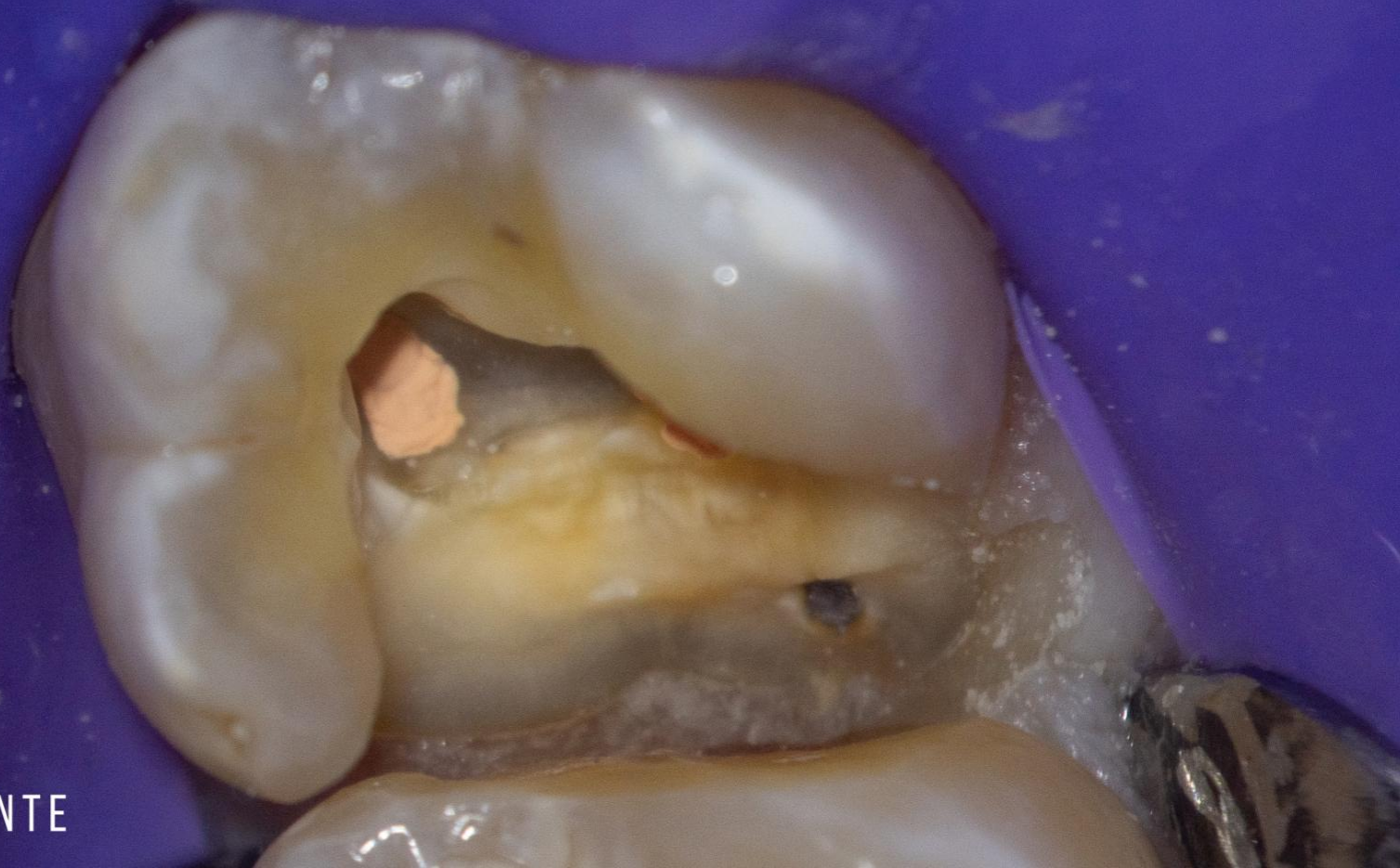

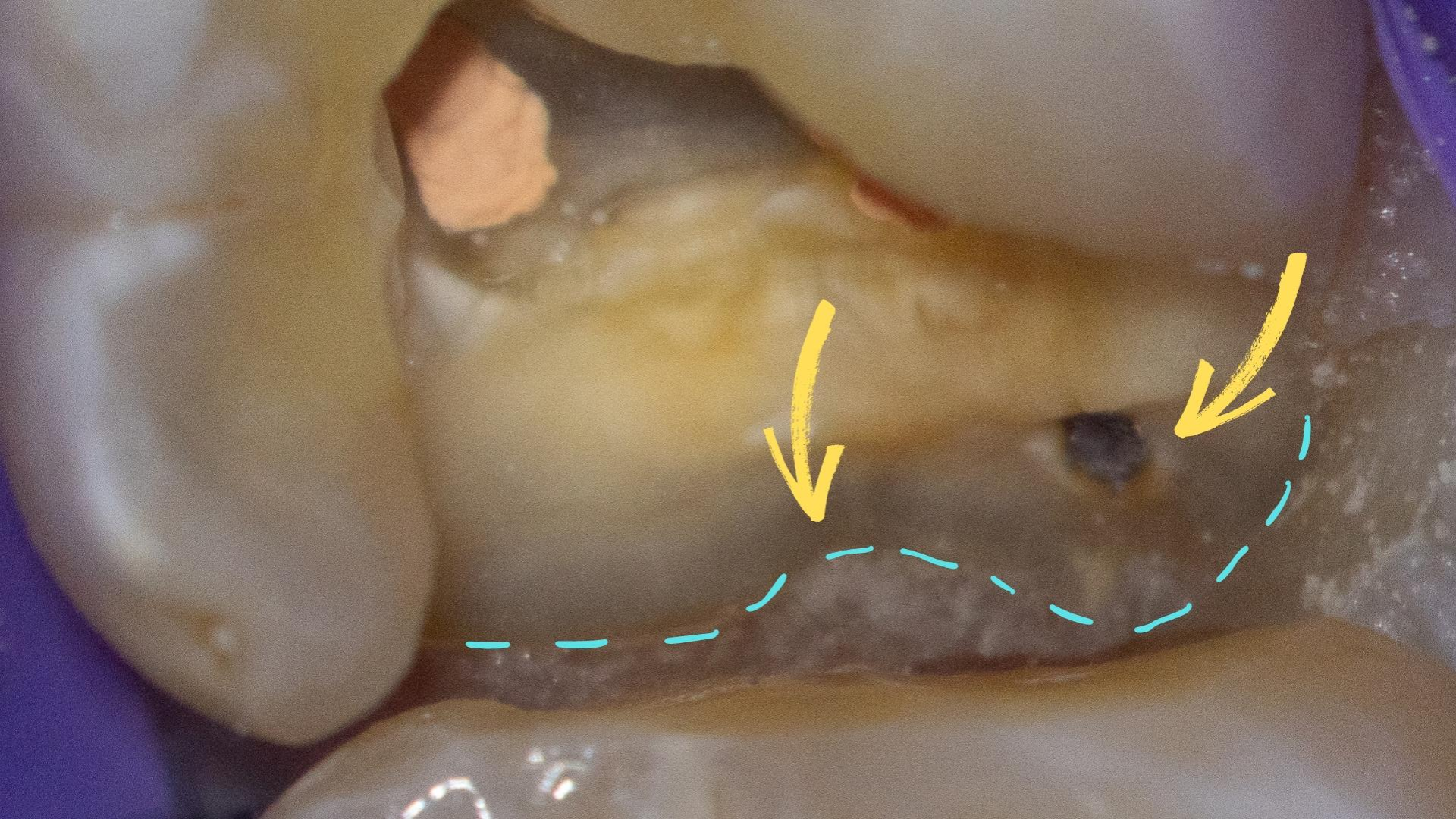


A close-up photograph of a tooth, likely a premolar, showing a large filling and a crown preparation. The filling is a light orange color and is located in the central part of the tooth. The crown preparation is a large, dark, irregularly shaped cavity on the lingual side of the tooth. The tooth is surrounded by a blue, textured material, possibly a dental wax or a protective covering. The background is a solid blue color.

DR. R. BUSTAMANTE

DR. R. BUSTAMANTE

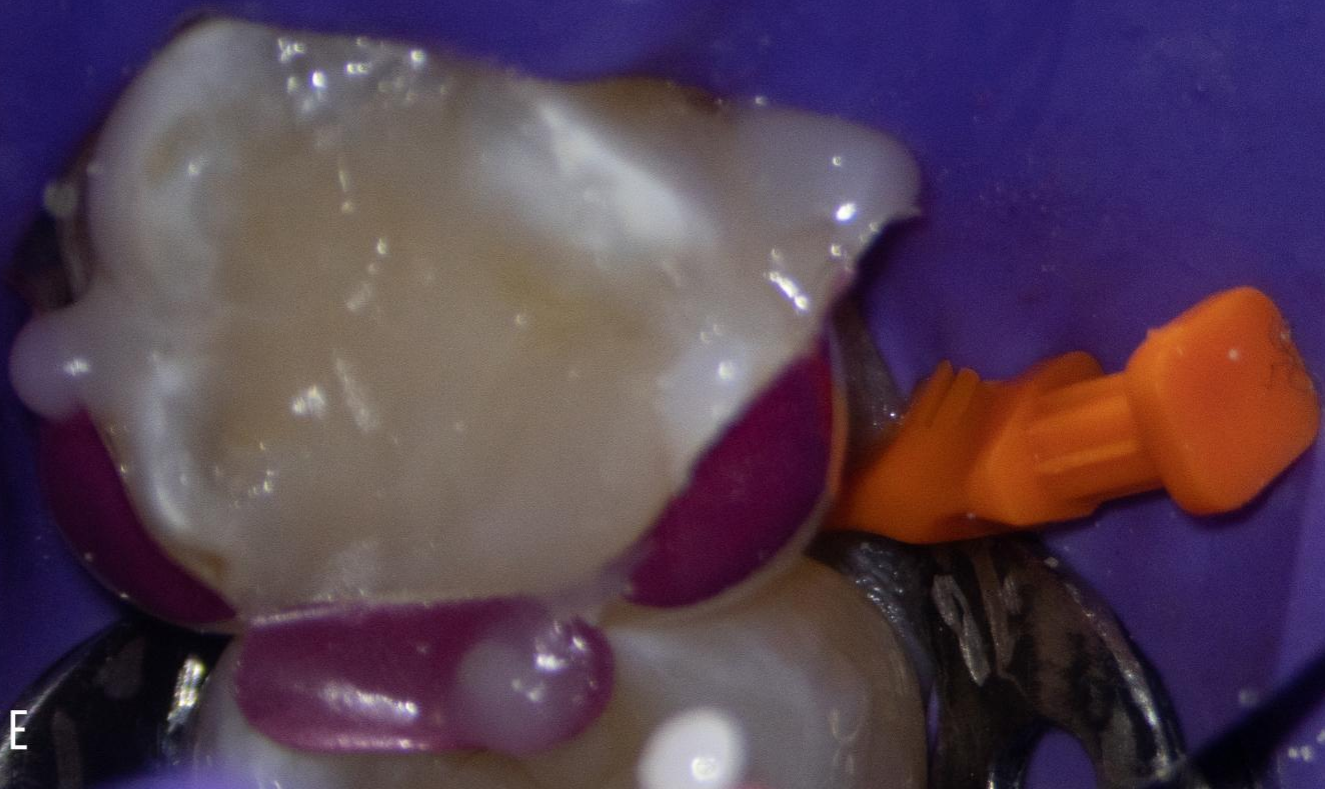


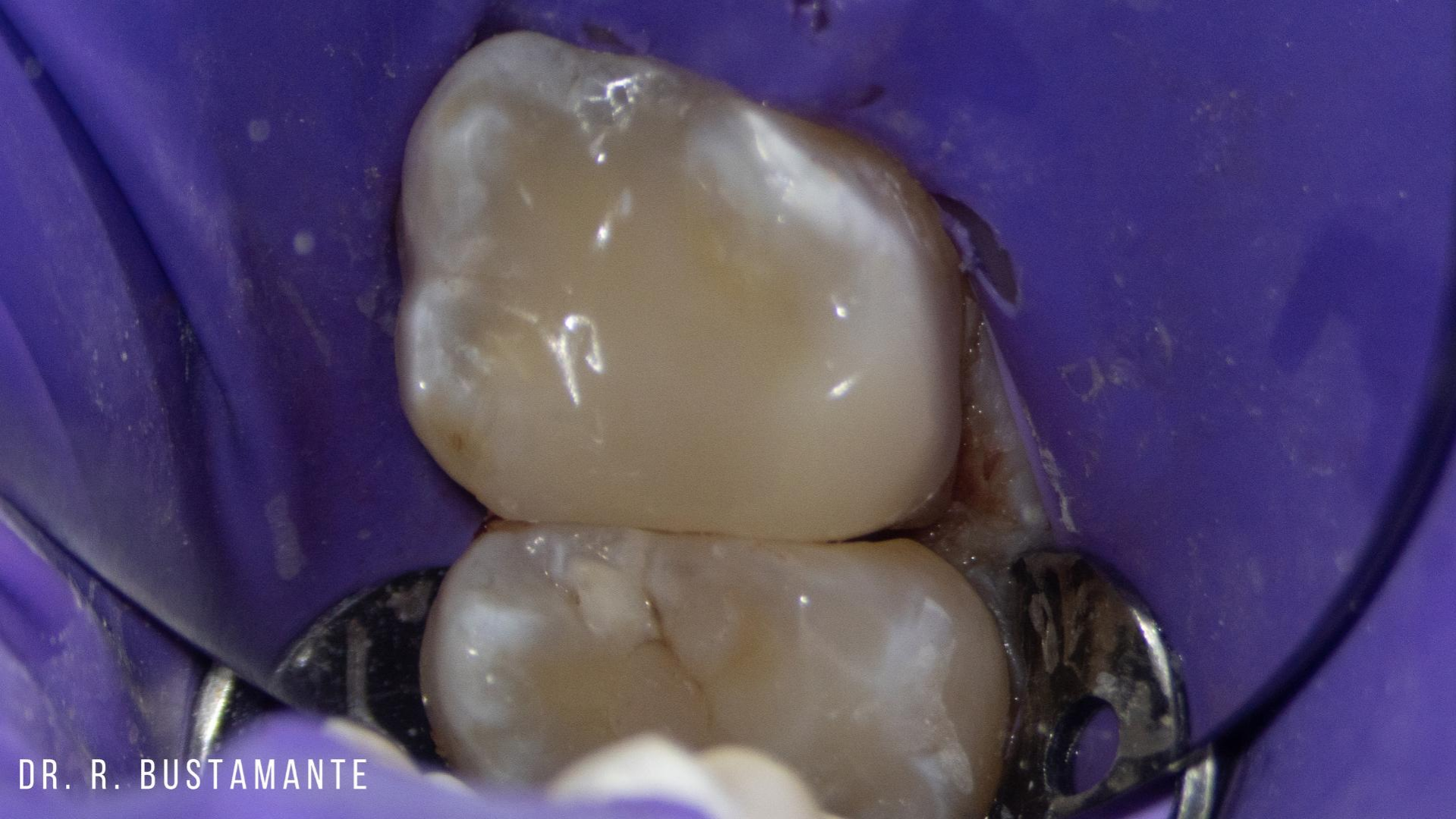
A close-up photograph of a dental crown, likely a metal-ceramic or porcelain-fused-to-metal crown, held in a metal tray. The crown is light-colored with a central opening, possibly for a post or a specific type of crown. The crown is surrounded by white gauze or paper. The background is a solid blue color.

DR. R. BUSTAMANTE

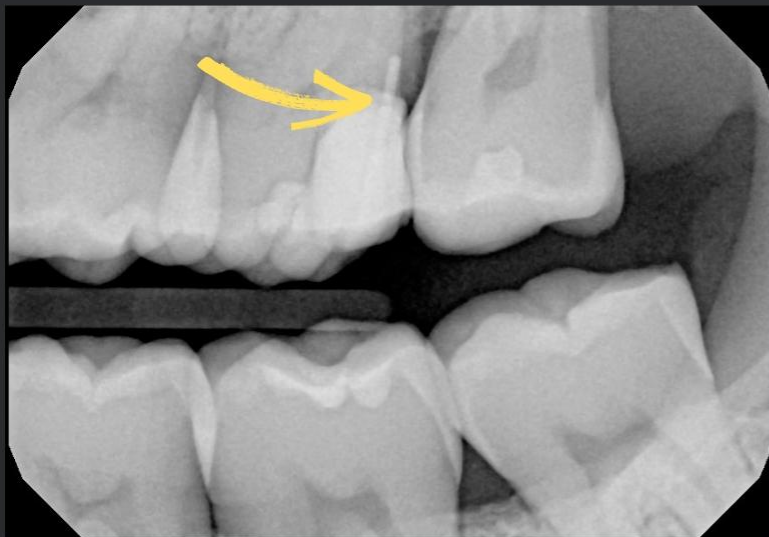DR. R. BUSTAMANTE



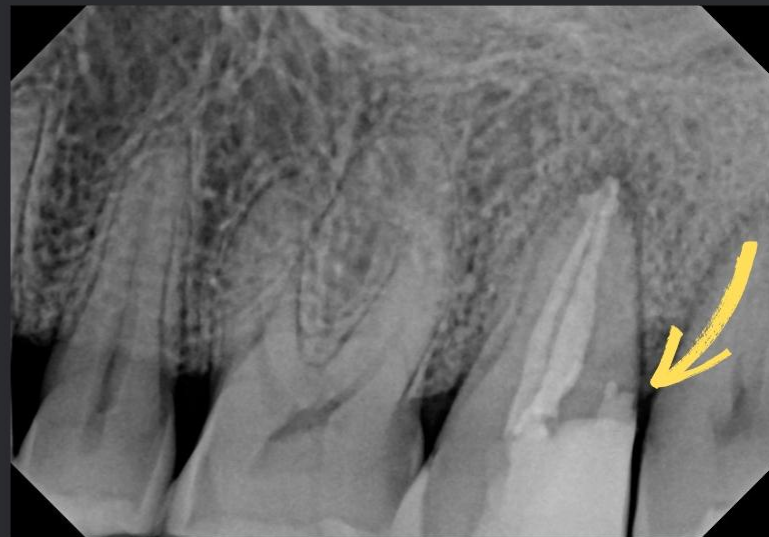


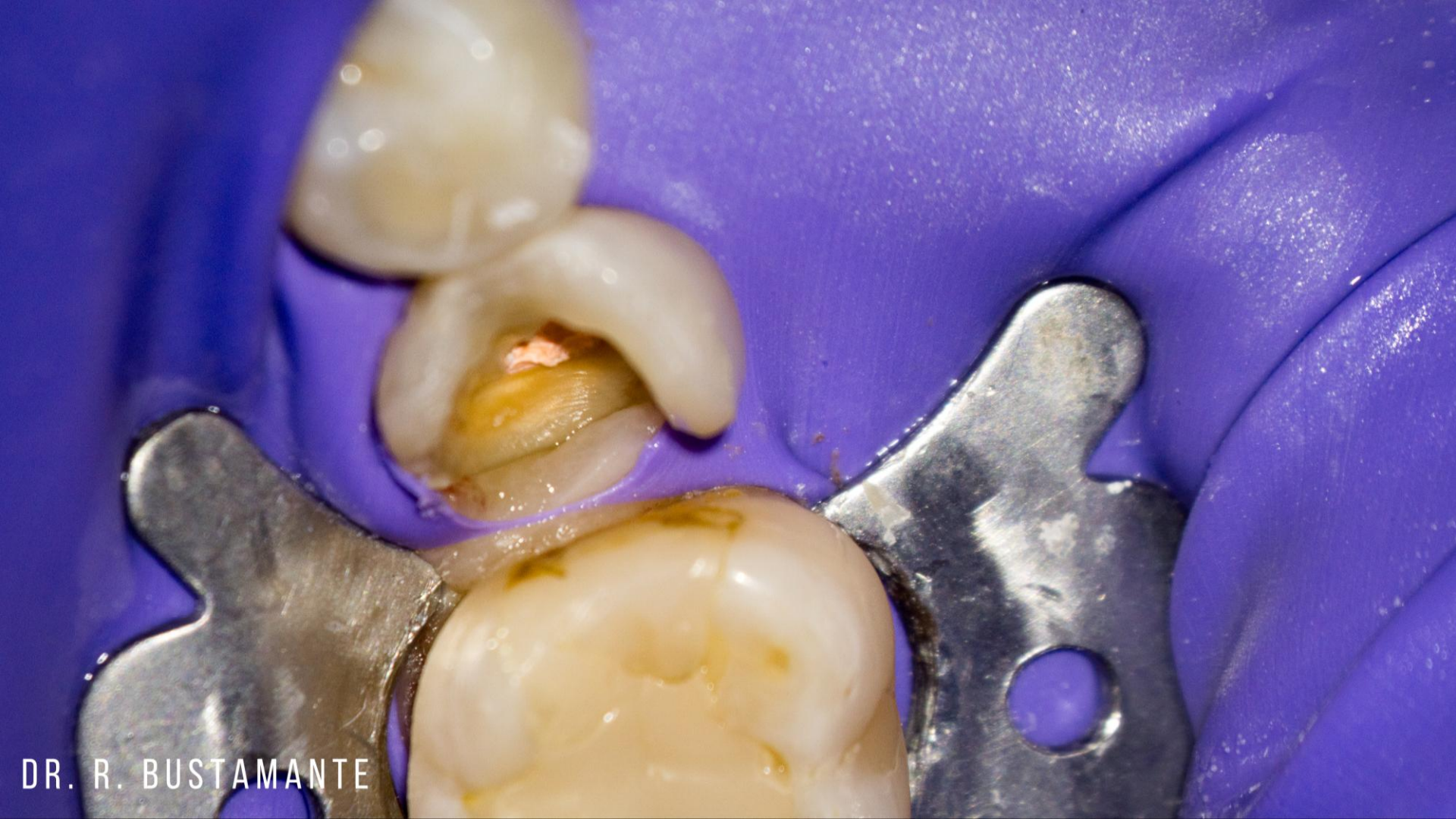DR. R. BUSTAMANTE

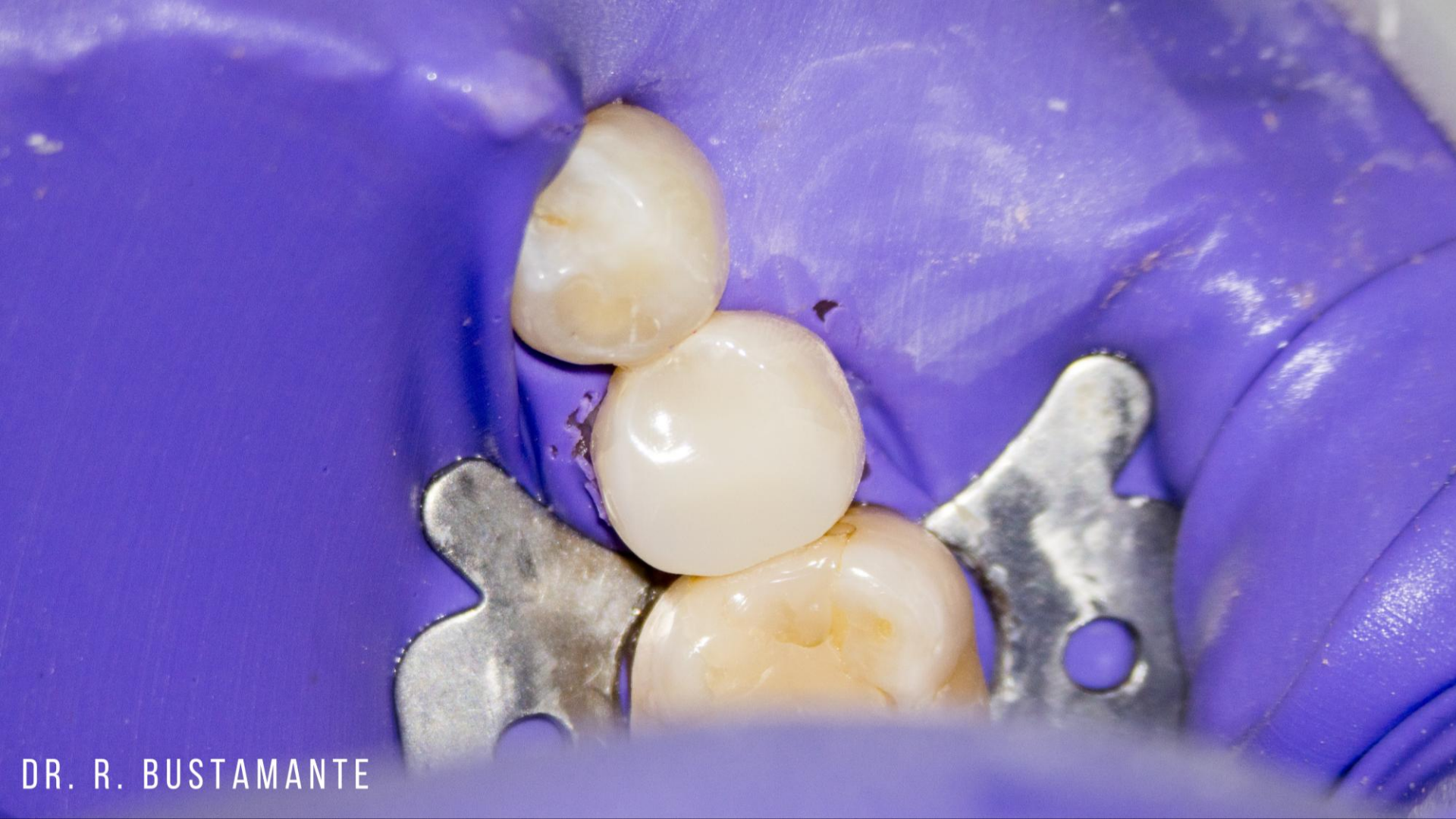Before



After

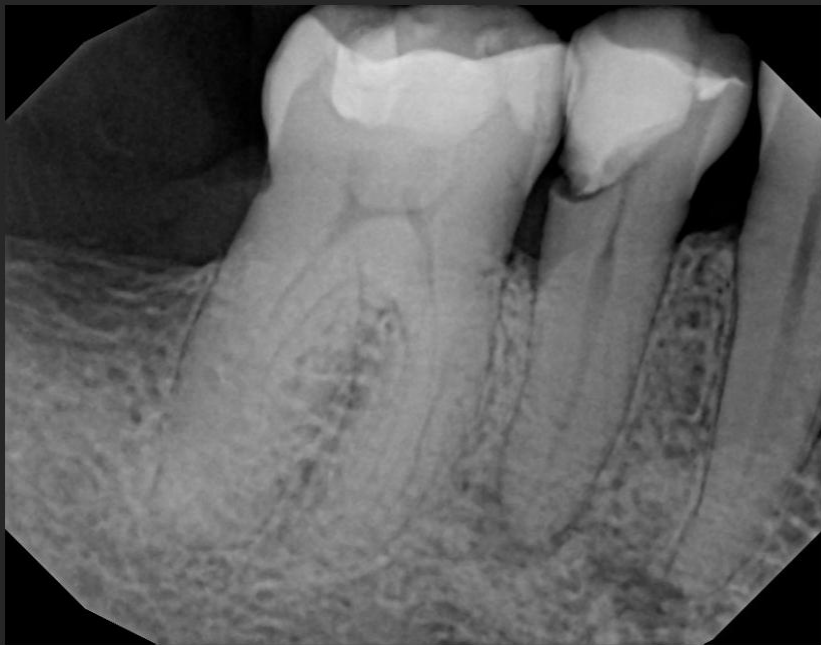




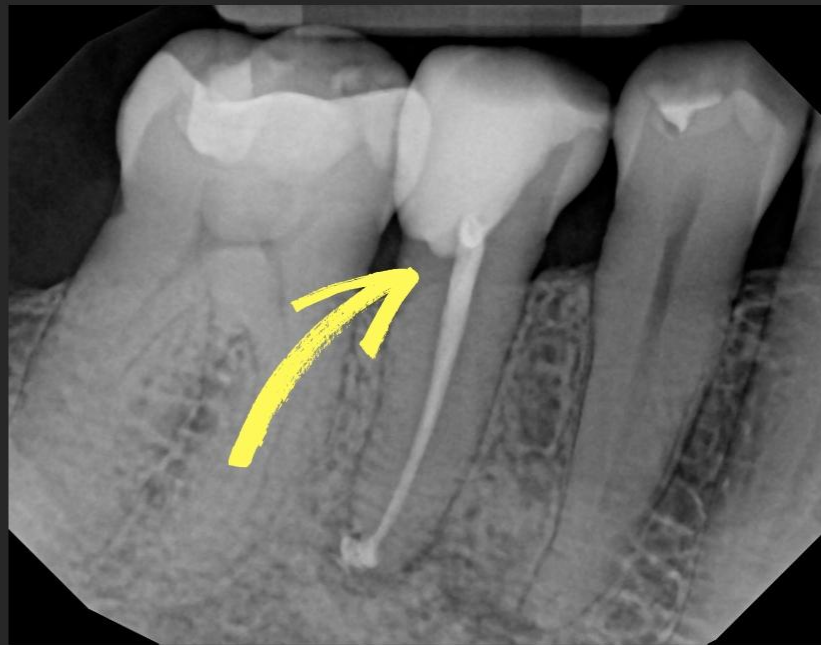

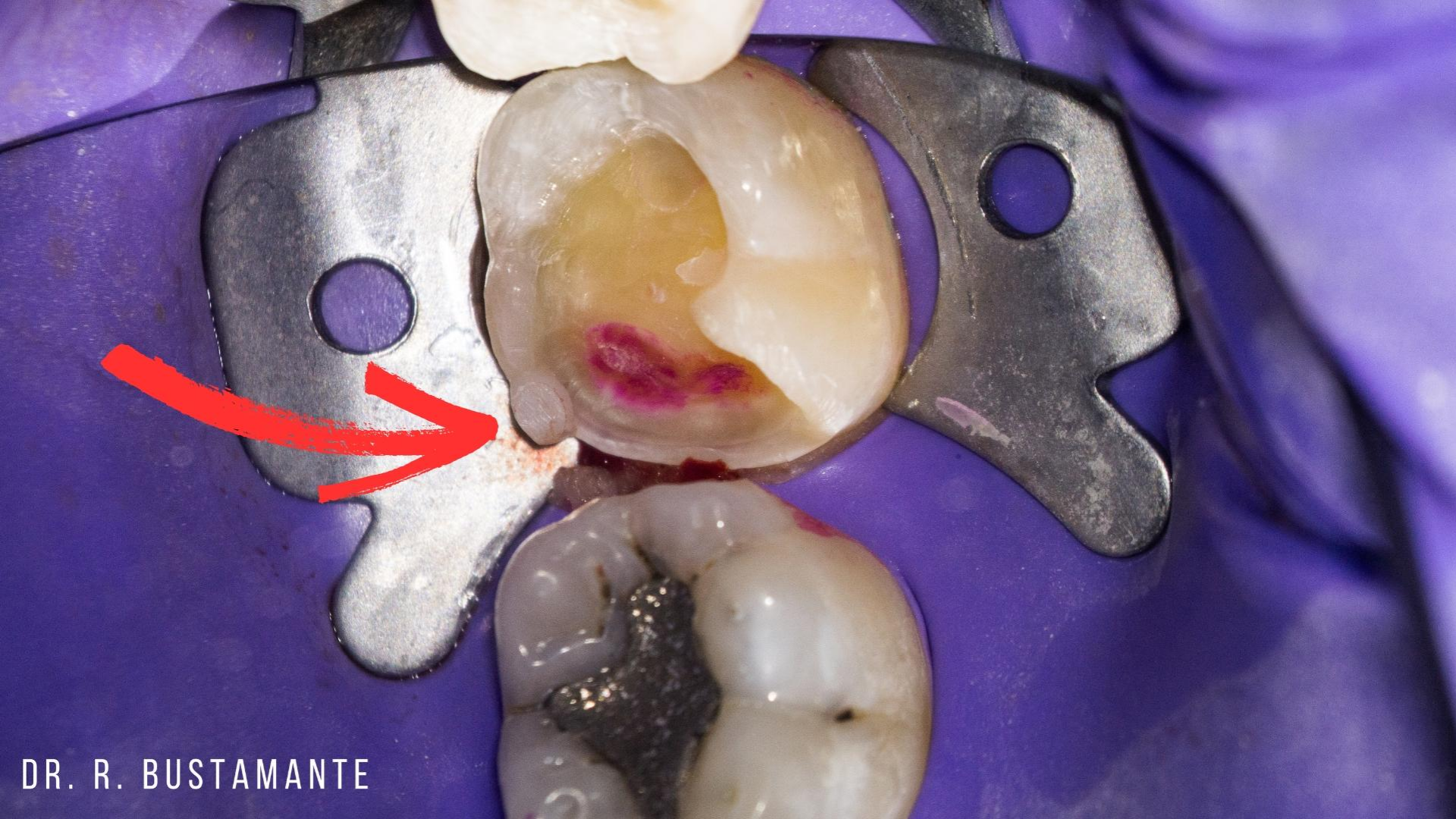DR. R. BUSTAMANTE

BEFORE

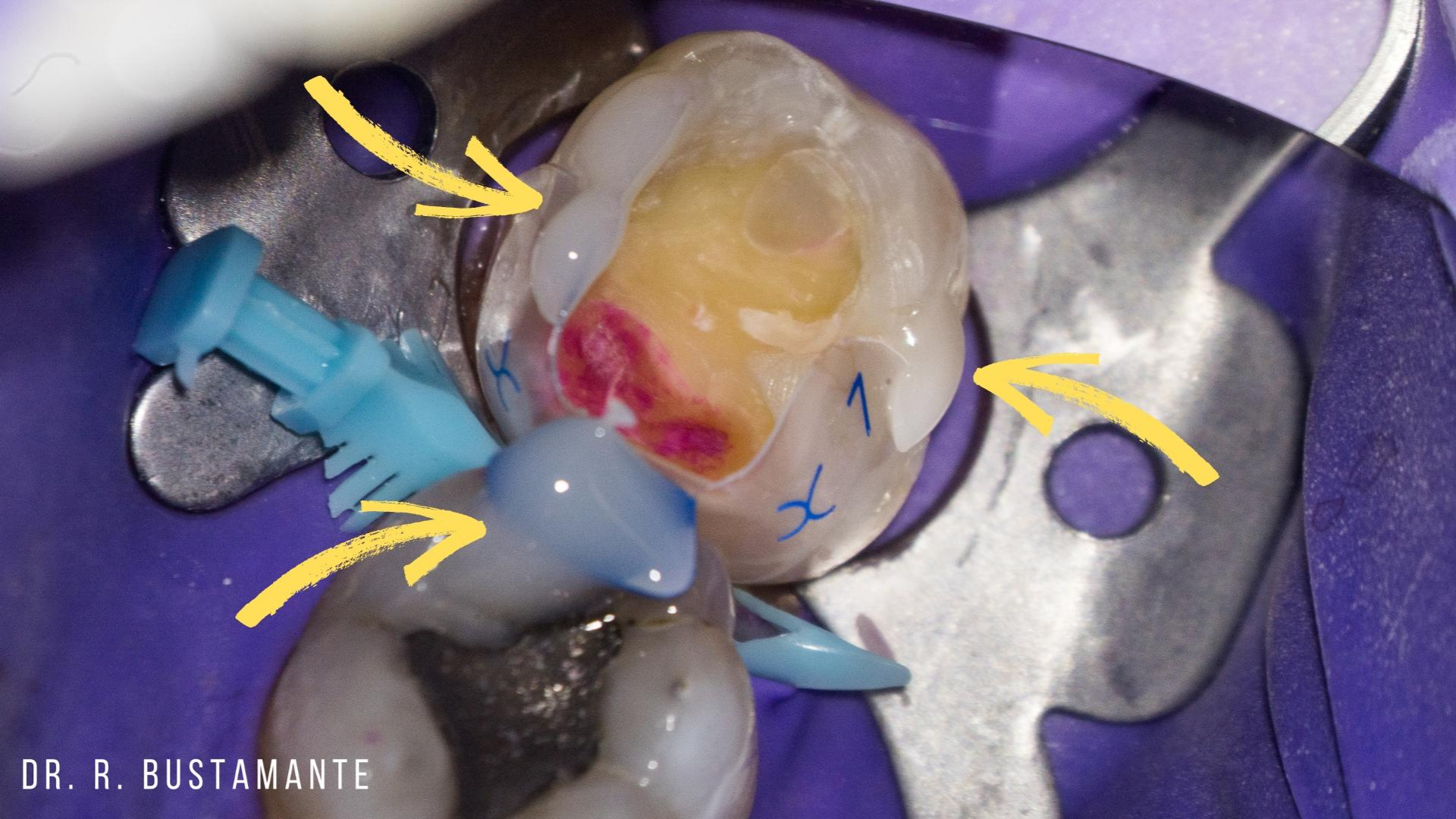


AFTER



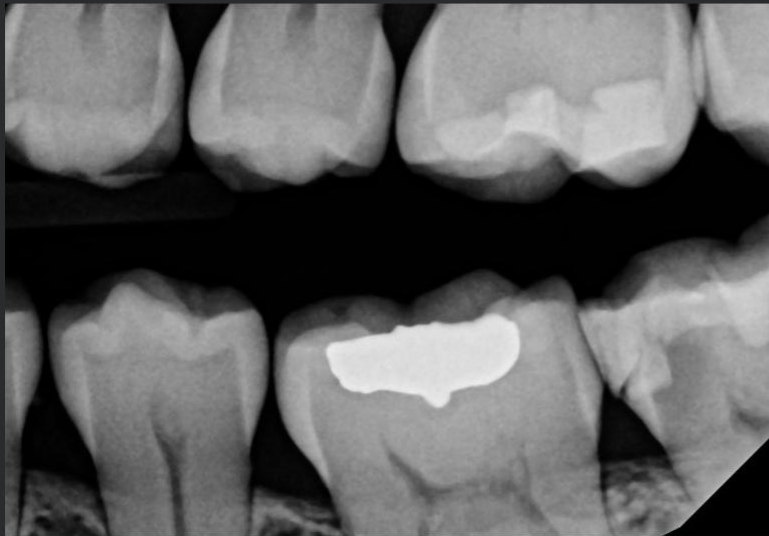

DR. R. BUSTAMANTE

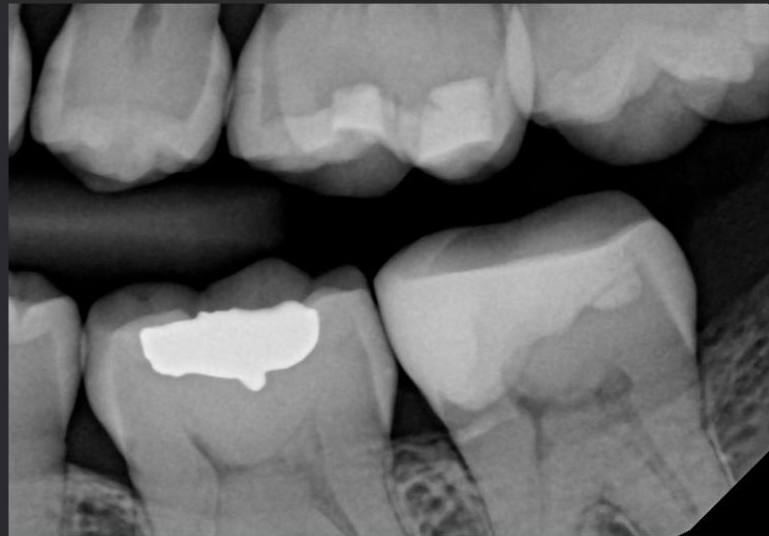

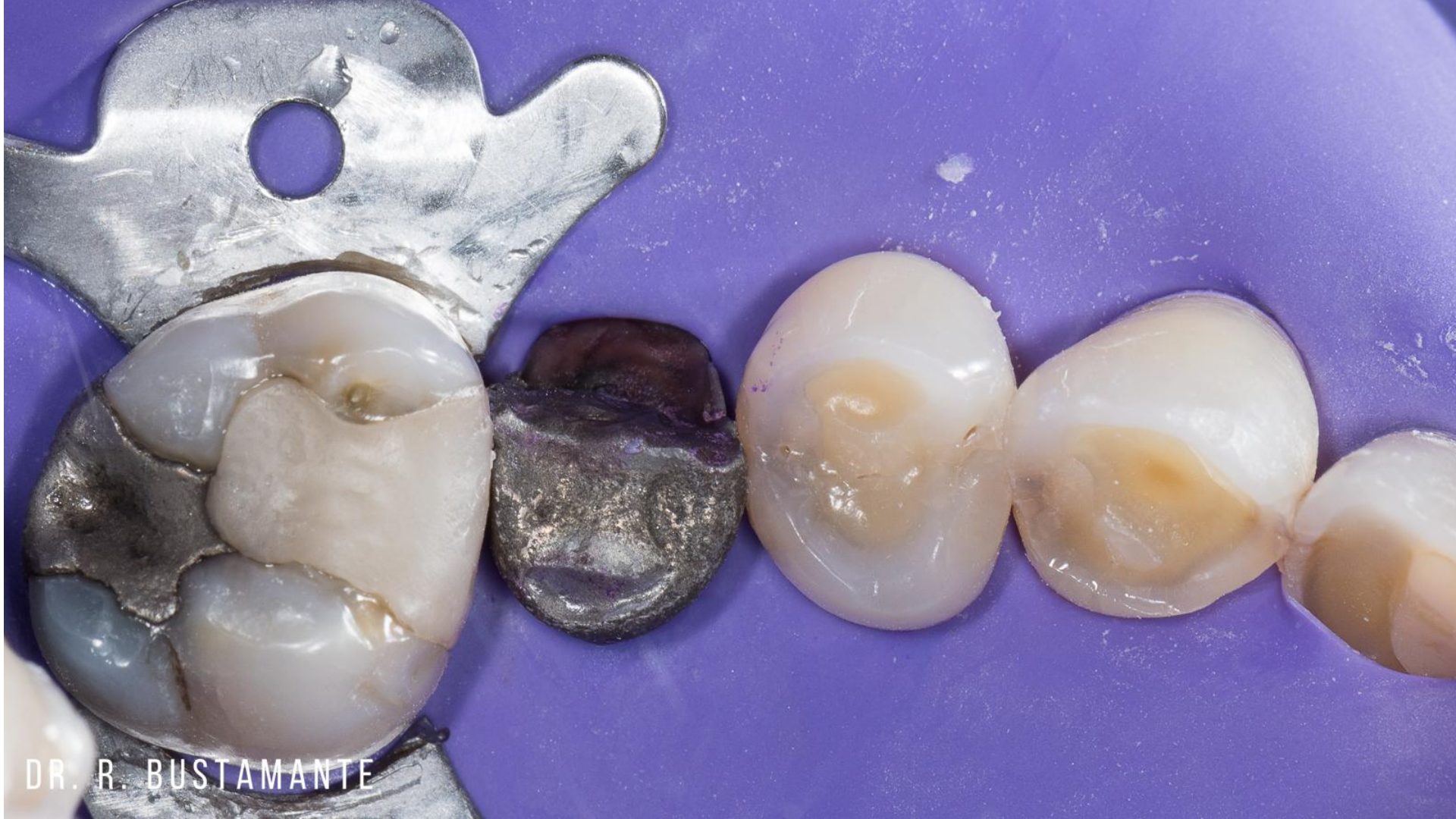DR. R. BUSTAMANTE

Before

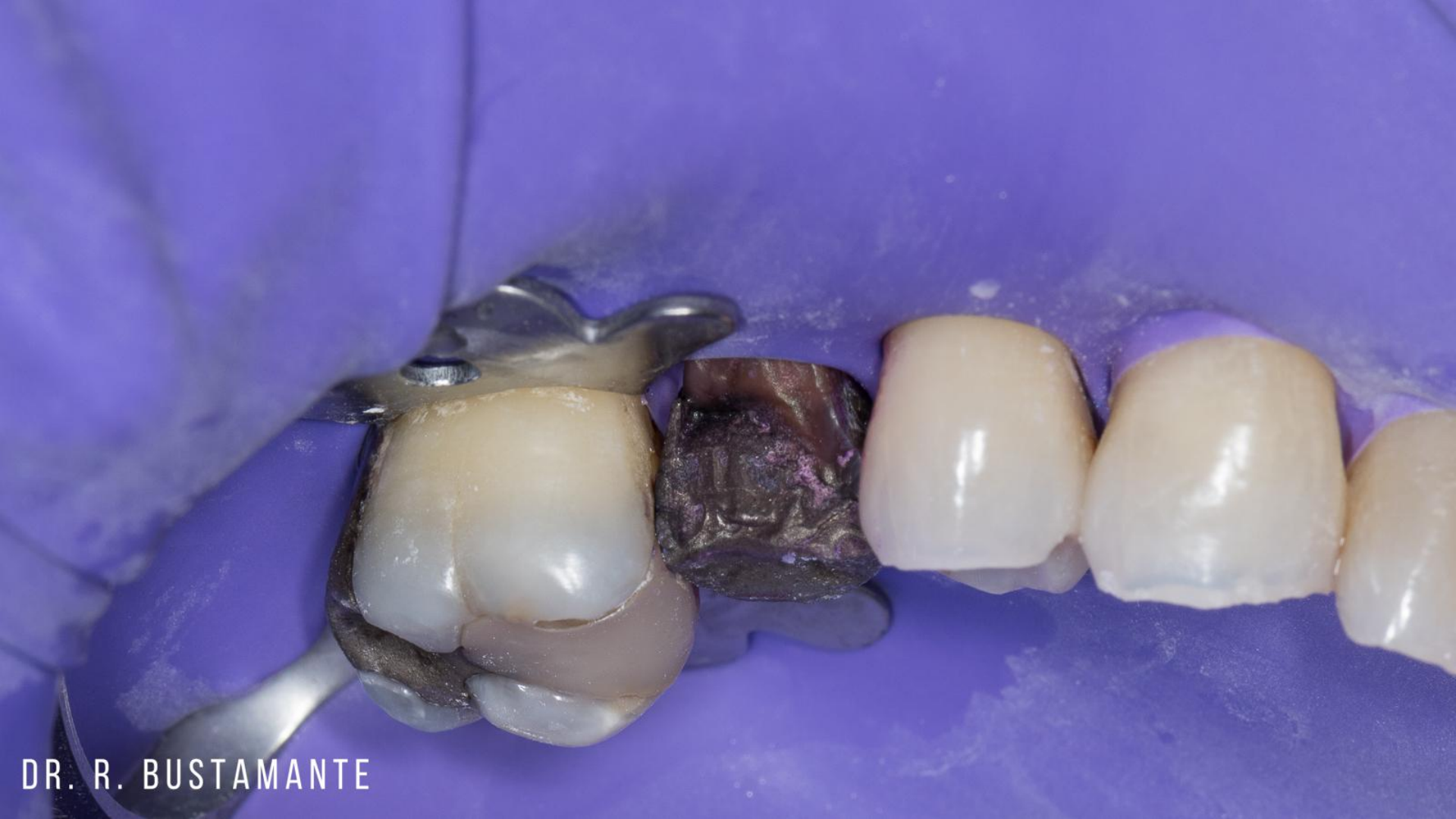

After

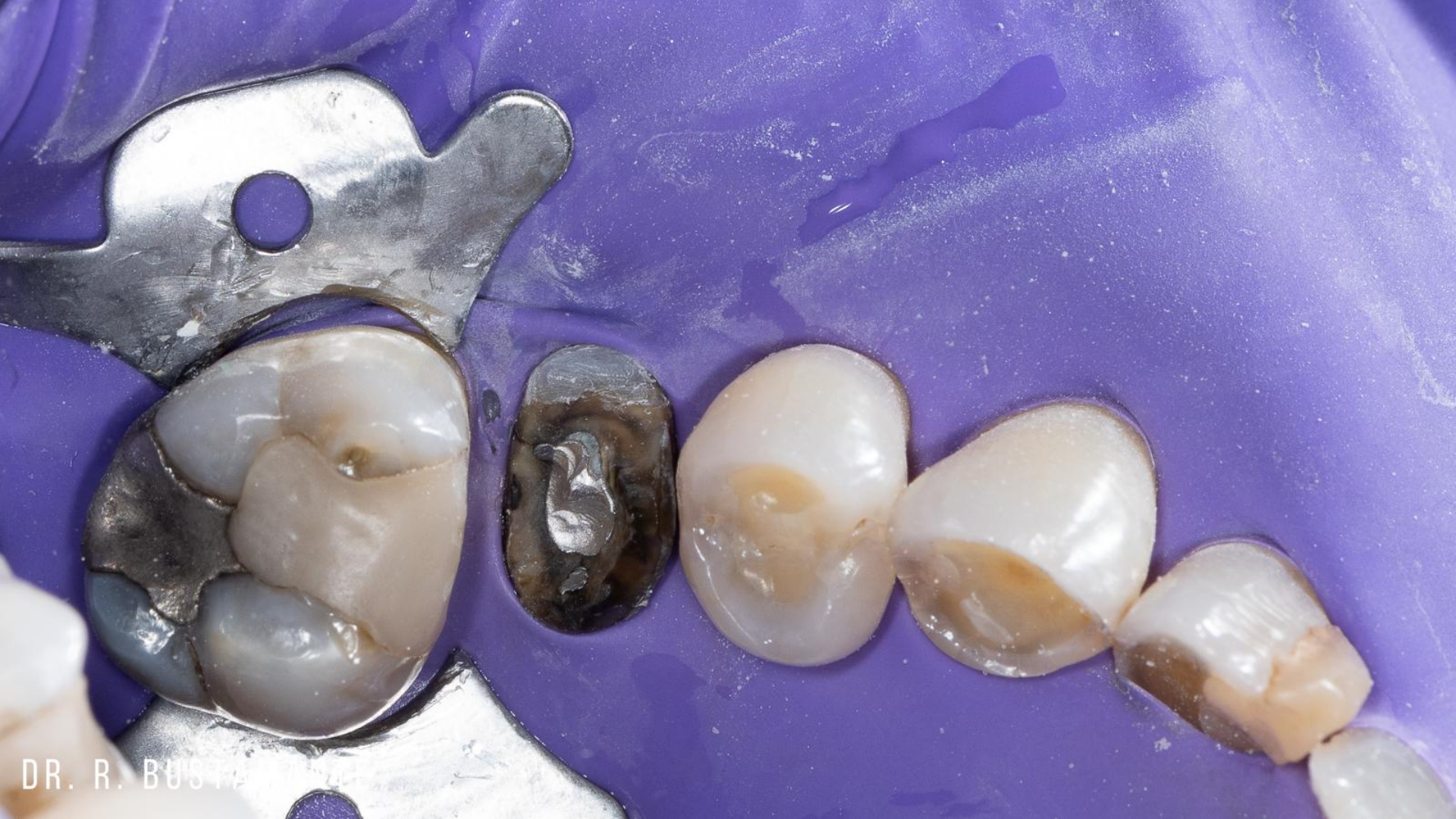



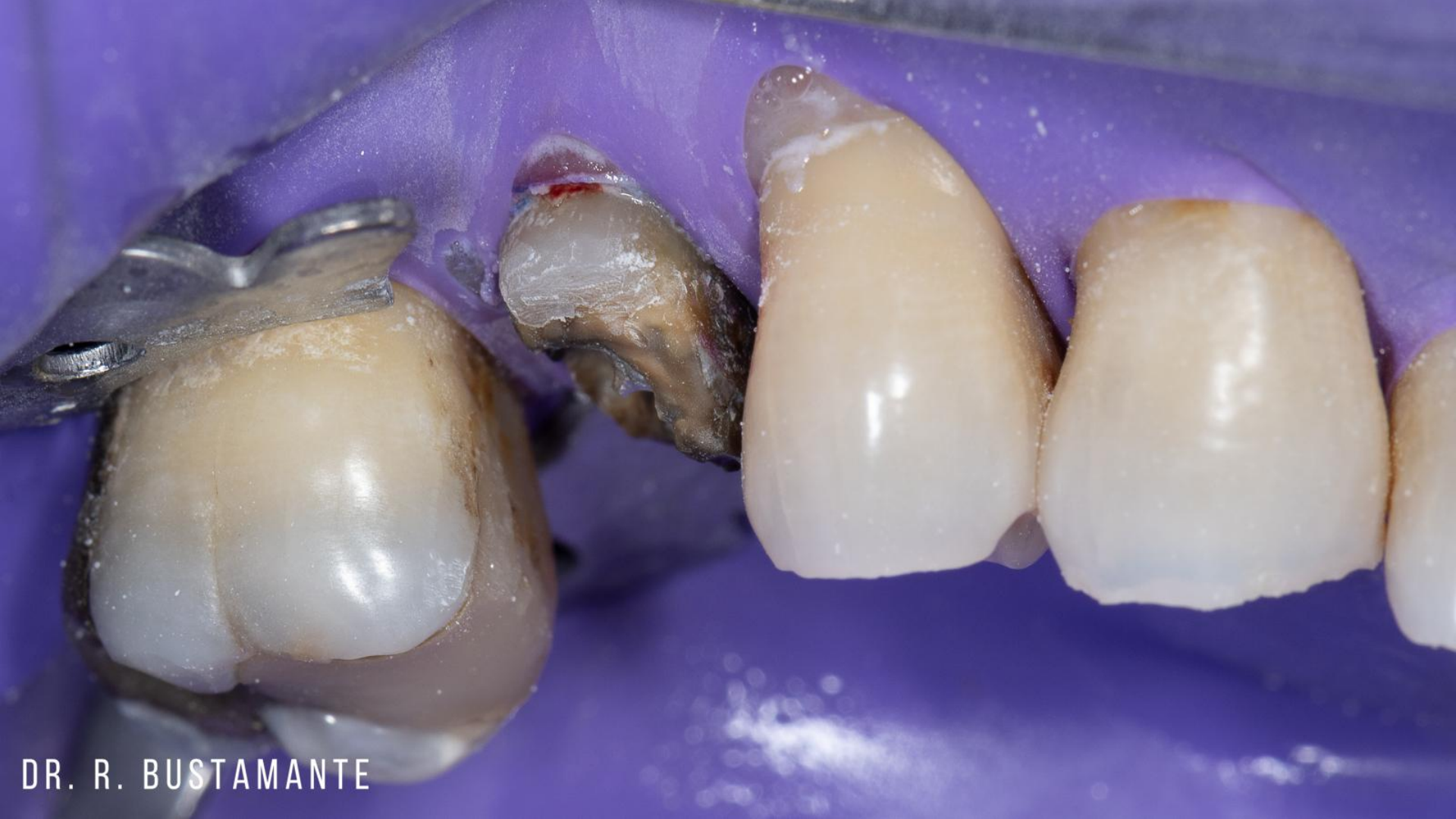DR. R. BUSTAMANTE



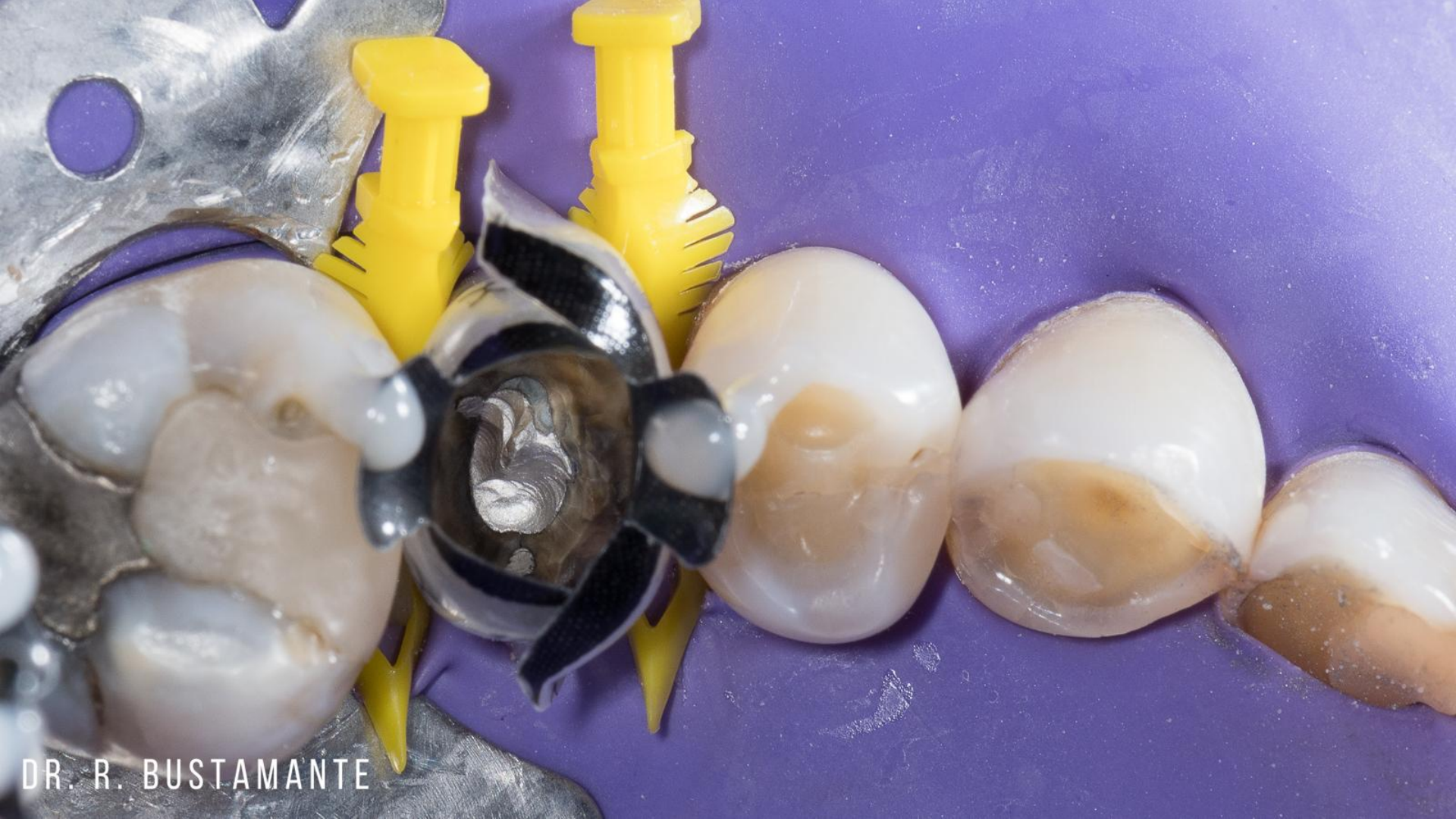DR. R. BUSTAMANTE



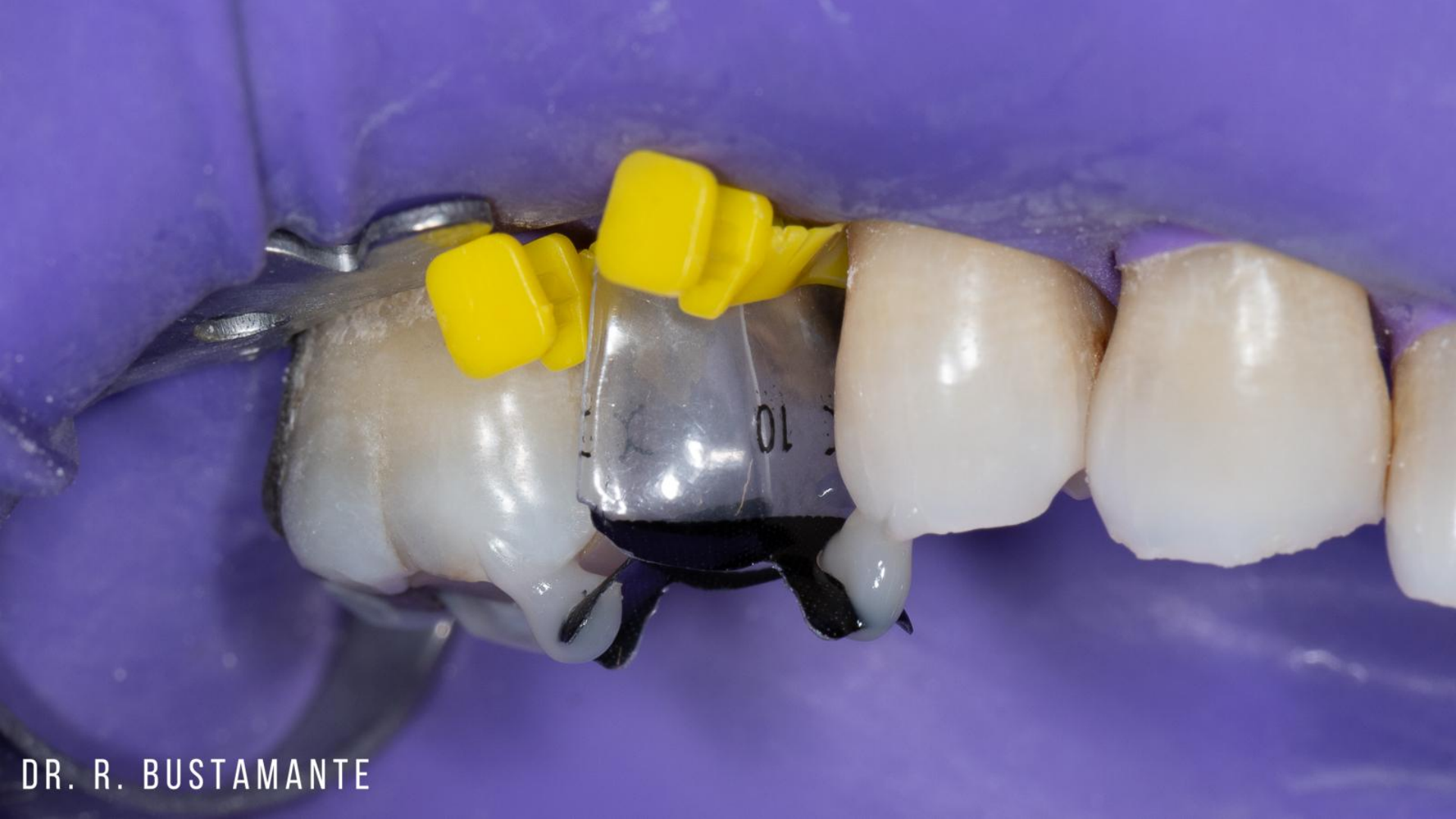DR. R. BUSTAMANTE



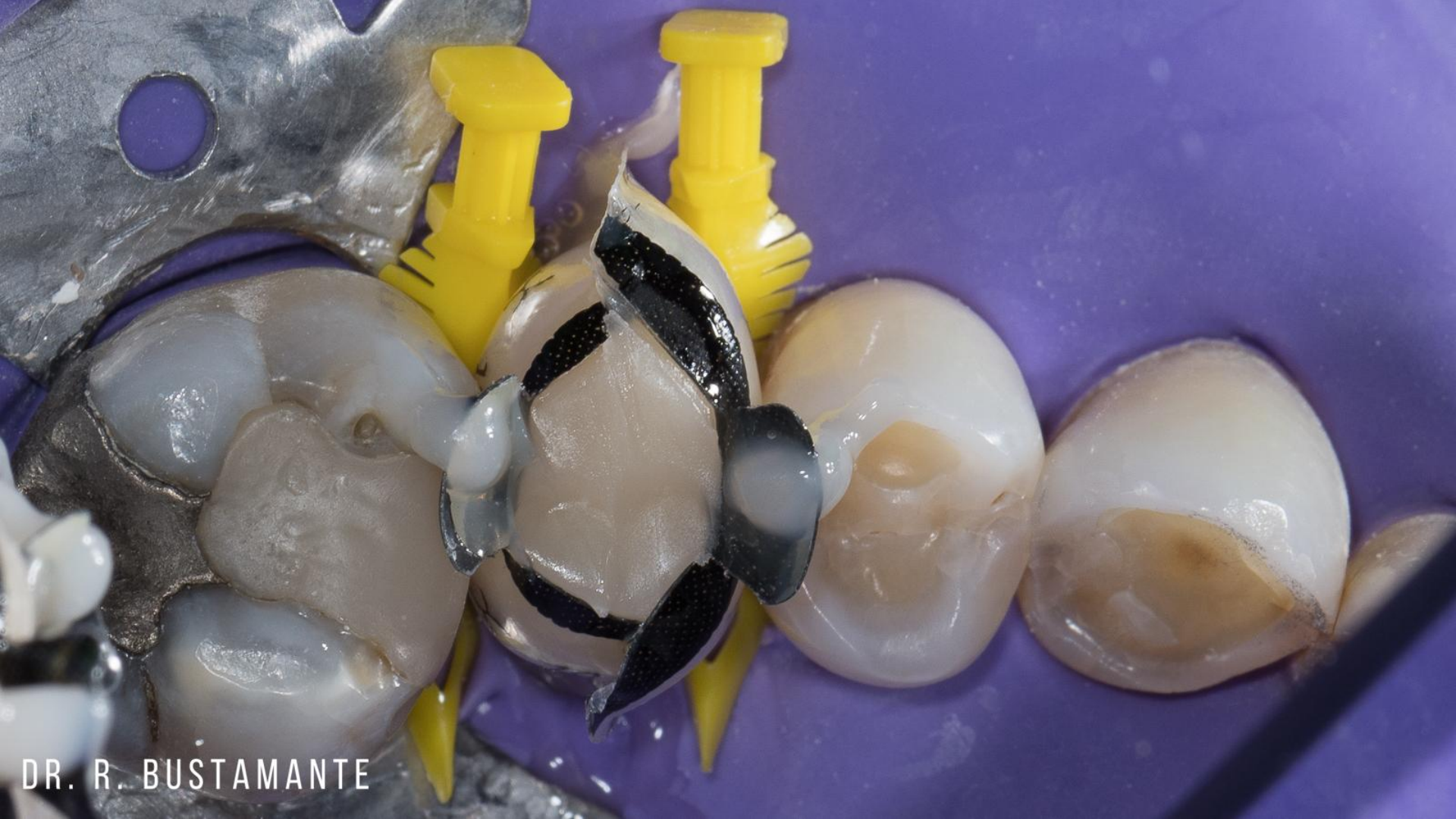DR. R. BUSTAMANTE



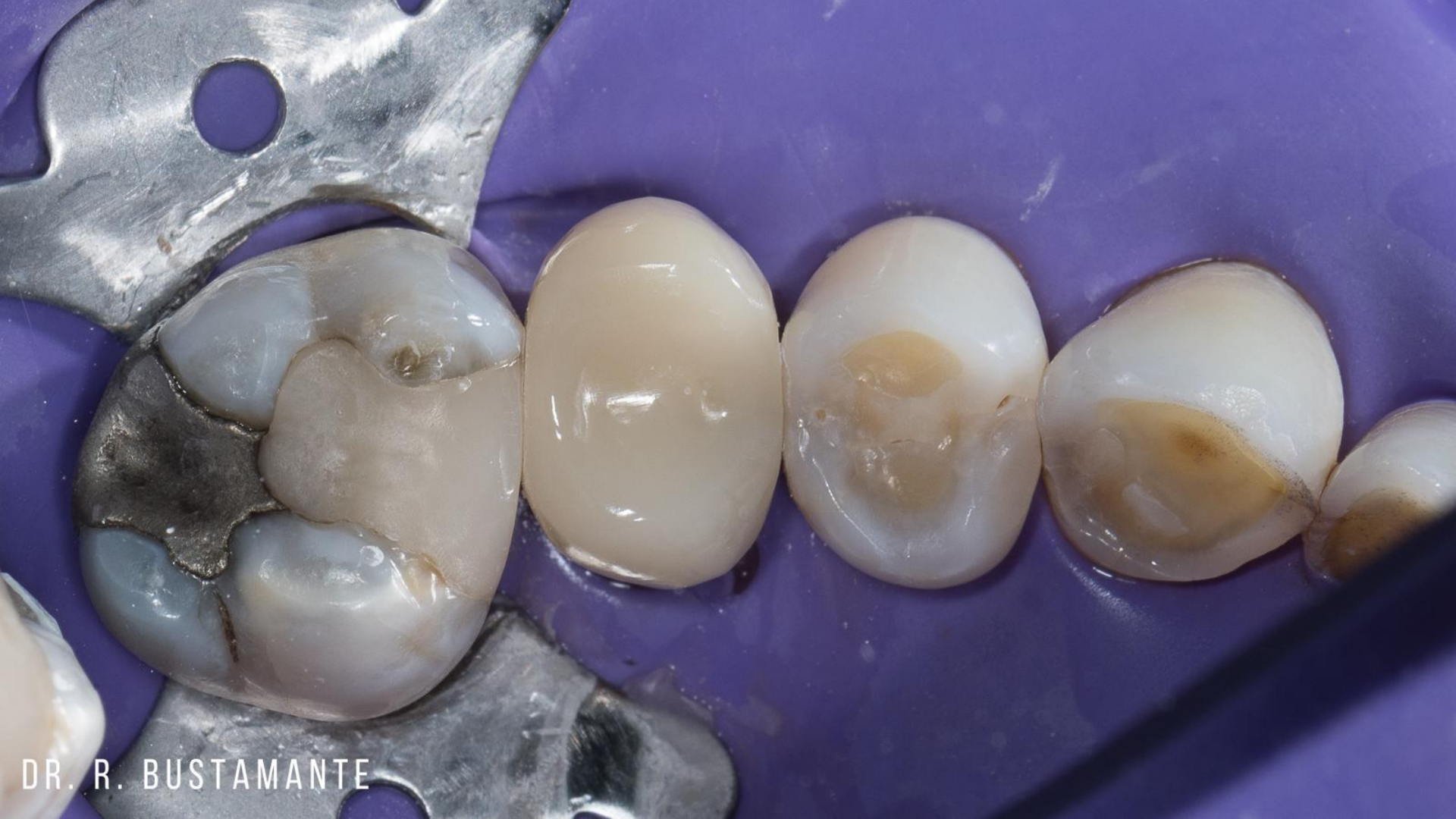DR. R. BUSTAMANTE



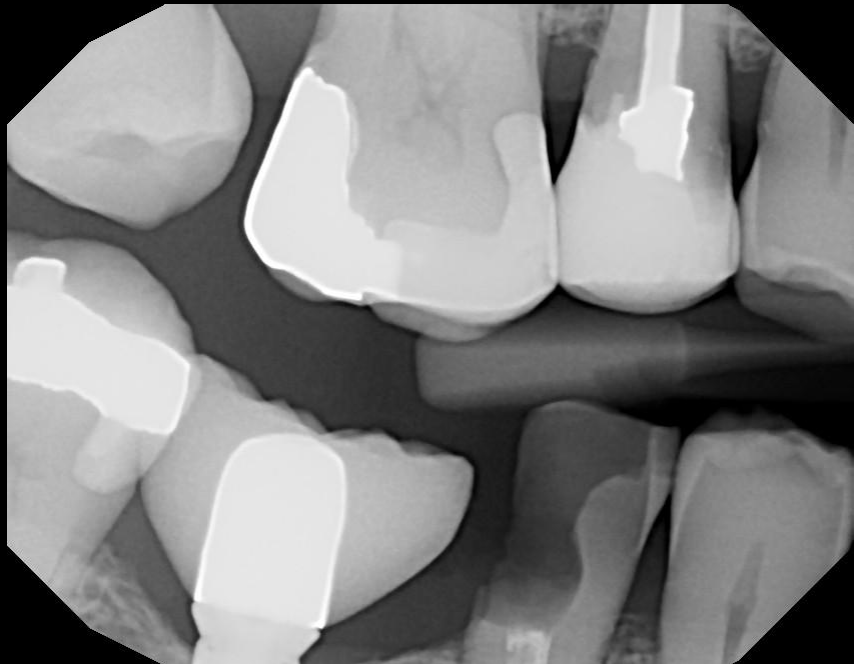
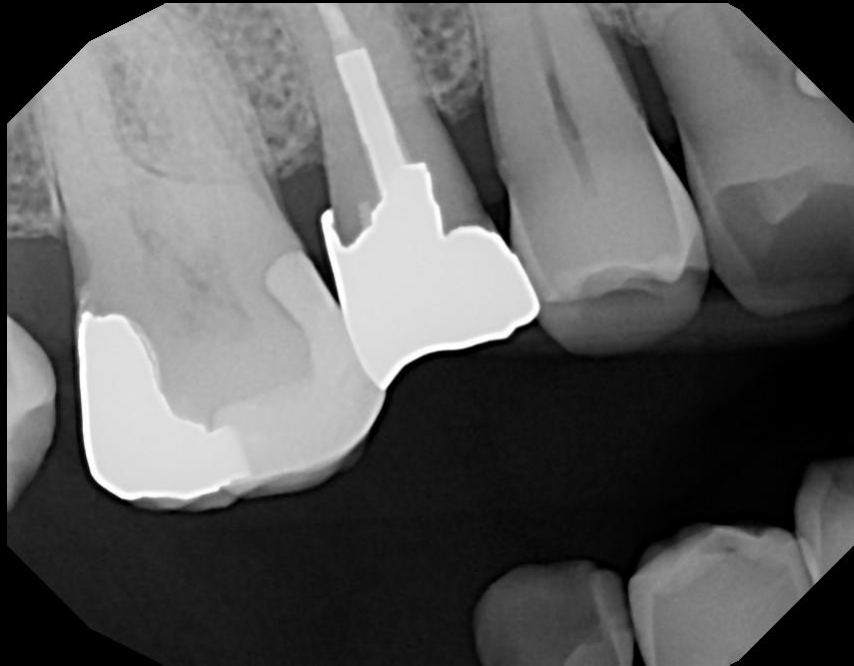DR. R. BUSTAMANTE



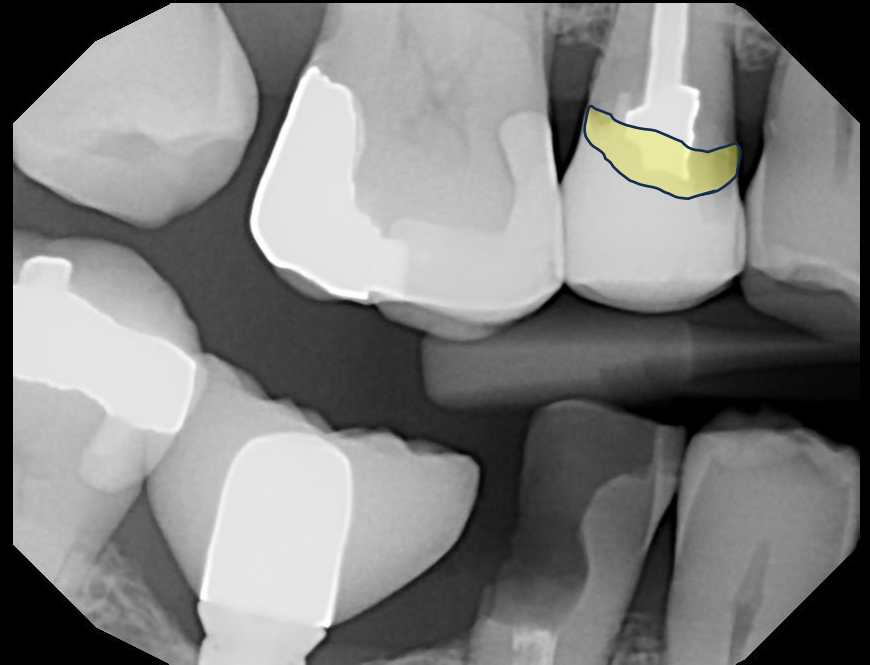
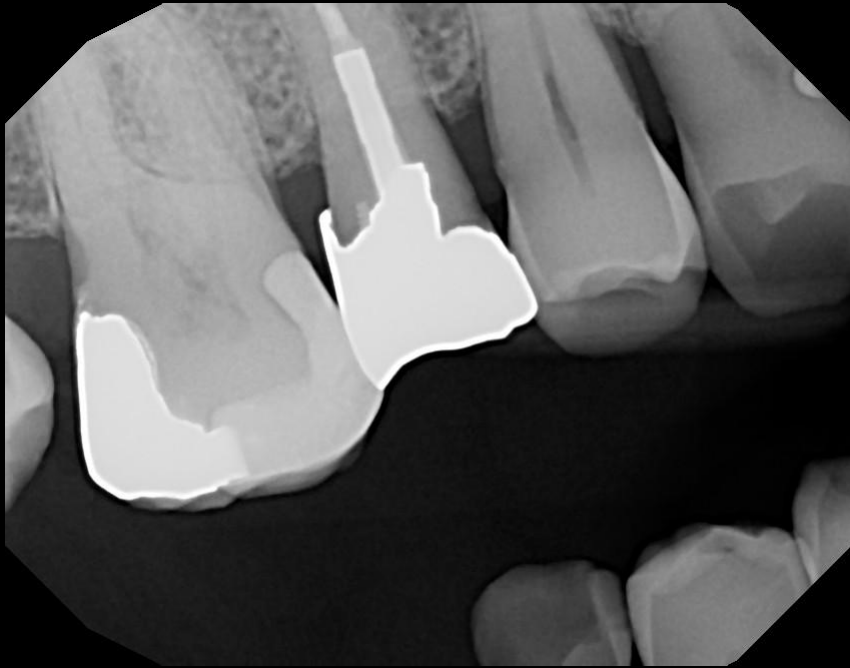DR. R. BUSTAMANTE



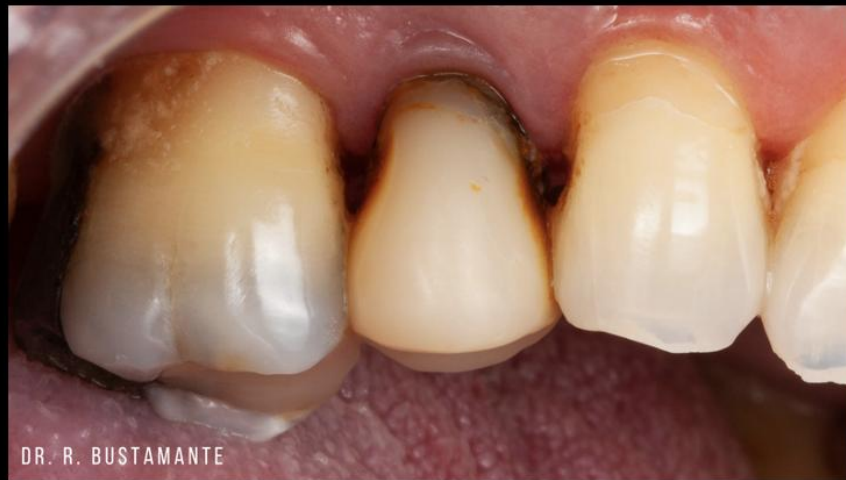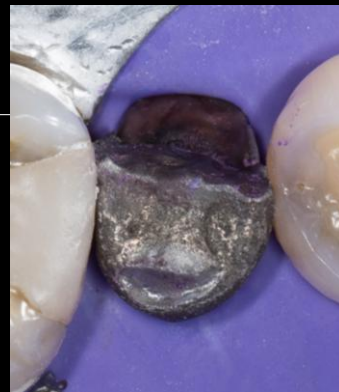DR. R. BUSTAMANTE



Bioclear Additive Ferrule



16-MONTH FOLLOW-UP



DR. R. BUSTAMANTE

