



DC BIOCLEAR LEARNING CENTER

Tacoma USA · Solihull UK
Varberg Sweden · Cairo Egypt
Syracuse Italy · Taubate Brazil
Livermore CA (Bioclear for
pediatrics)



The **Bioclear Learning Center** provides a new pathway for dentists and their office to transition from traditional **GV Black dentistry**, to the extraordinary world of **modern direct dentistry**.



Bioclear Learning Center Faculty



Dr. Rafael Bustamante
Faculty Track




Dr. David Clark
Founder & Full Faculty



Dr. Charles Regalado
Full Faculty



Dr. Claire Burgess
Full Faculty



Dr. Dominic Hassall
Full Faculty



Dr. Marco Maiolino
Full Faculty



Dr. Joshua Solomon
Full Faculty



Dr. Abdelrahman Tawfik
Full Faculty



Dr. Johan Hagman
Full Faculty



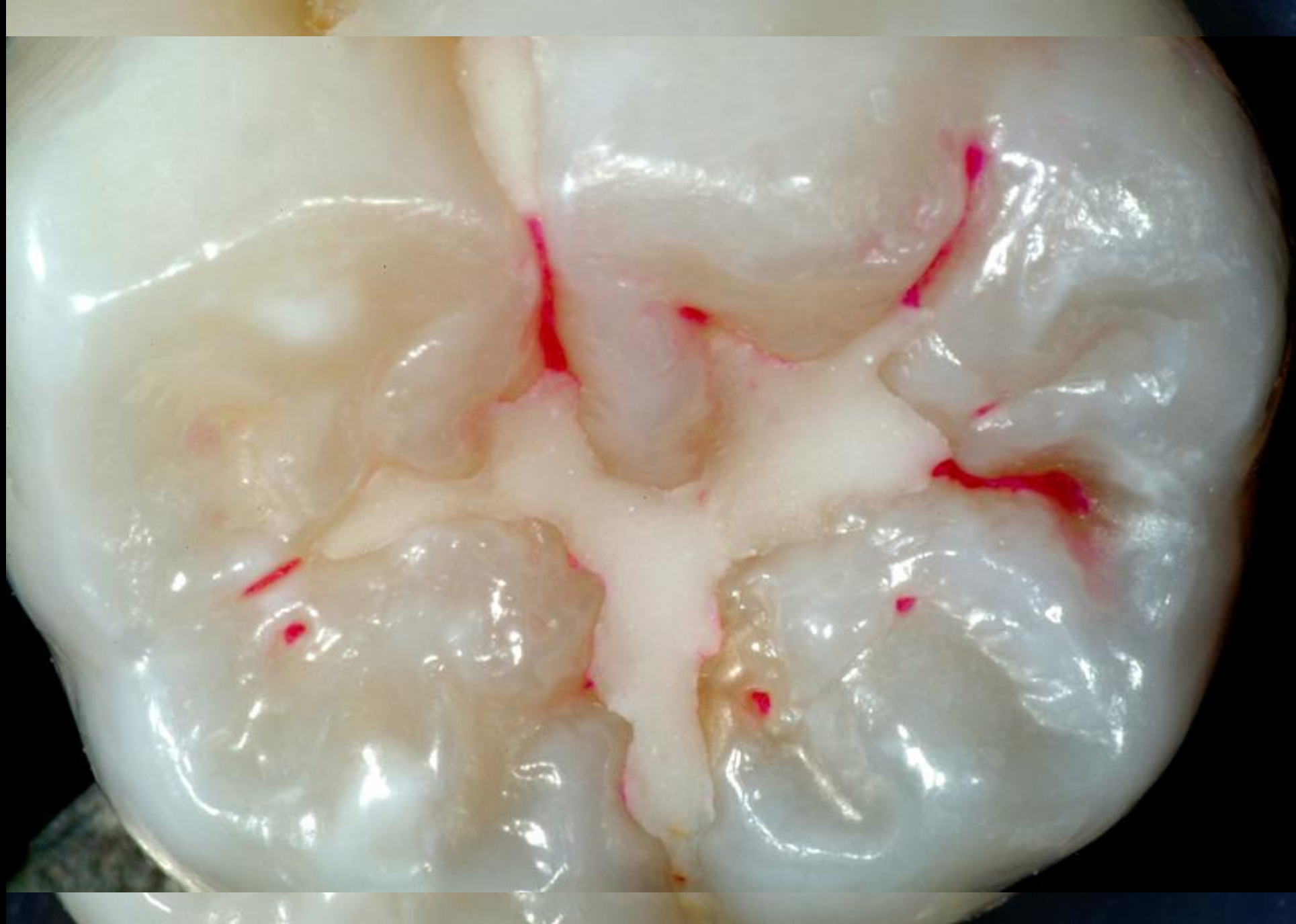Dr. John Khademi
Adjunct Faculty



Dr. Alison Agnes
Faculty Track



Dr. David Carroll
Adjunct Faculty



Traditional sealants engage a very small portion of the overall defect in many cases. The technique is based on a less than realistic idea of how deep and complex these defects are, and how much biofilm is in and around pits, fissures and cul-de-sacs.

traditional sealants over decay?

“No, Traditional sealants only engage 17% of the average pit/fissure and therefore the grooves should be opened with fissurotomy burs”

“YES, Sealants should be placed over incipient (non cavitated) caries...mechanical preparation of enamel is **not** recommended”

ADA
Professional Product Review
PUBLICATION OF THE ADA COUNCIL ON SCIENTIFIC AFFAIRS

VOL. 3 | ISSUE 1

IN THIS ISSUE

- Glass Ionomer-Containing Cements Lab Notes 1
- Practitioner Input 5
- Glass Ionomer-Containing Restoratives Lab Notes 6
- Practitioner Input 10
- Academic Corner 10
- Pit and Fissure Sealants Lab Notes 11
- Practitioner Input 13
- Interview 14
- Academic Corner 15

THE BOTTOM LINE
David C. Soren, DMD, MS, Editor

Glass Ionomer Cements
Between the two self-curing prep glass ionomers, GC Fuji II LC, a resin-modified glass ionomer, and Ketac Bond Plus Applap, a resin-modified glass ionomer, both products were highly rated products in terms of favorable film thickness of all cements tested when tested at the manufacturer's stated working thickness. Sealants, a composite more comparable to a Fuji Plus, a resin-modified glass ionomer, appears to have the most glass ionomer advantages. It had among the highest

Glass Ionomer Restorative Materials
GC Fuji II LC, a resin-modified glass ionomer, and Ketac Bond Plus Applap were both highly rated products in terms of favorable film thickness of all cements tested when tested at the manufacturer's stated working thickness. Sealants, a composite more comparable to a Fuji Plus, a resin-modified glass ionomer, appears to have the most glass ionomer advantages. It had among the highest

Pit & Fissure Sealants
Each enamel body sealant remains the most effective strategy for preventing caries. Glass ionomer sealants should be considered when moisture control is a concern. UltraSeal XT and CSeal were the most highly rated products by dentists. HeliSeal and Agre had the lowest shrinkage areas and lowest rate of area development during curing, which may contribute to better marginal seal.

GLASS IONOMER-CONTAINING CEMENTS
Lab Notes

In the ADA laboratory, we tested acid erosion, radiopacity, film thickness, compressive strength, flexural strength, flexural modulus and setting times.

To show how the products performed in relationship to one another, we are presenting our laboratory results on the following scale. The score value for each product is shown below the product name with the standard deviation in parentheses. Products listed in the same box had similar performance according to statistical analysis of the results (100-90; ANOVA and One-Way ANOVA on Kruskal-Wallis, p<0.05).

For a complete description of our test methods, visit www.ada.org/press/pr/.

GC Fuji Cem	GlassLinc	Ketac Bond Applap	Principle
GC Fuji Cem 100-90(10)	GlassLinc 100-90(10)	Ketac Bond Applap 100-90(10)	Principle 100-90(10)
GC Fuji Plus - Capable	Infiltek	Paracore Dual Sealants	ReliX Luting Plus
GC Fuji Plus - Capable 100-90(10)	Infiltek 100-90(10)	Paracore Dual Sealants 100-90(10)	ReliX Luting Plus 100-90(10)

Editor: David C. Soren, DMD, MS, pps@ada.org

ADA
American Dental Association
www.ada.org
111 East Chicago Avenue
Chicago, Illinois 60611-4242

COVER STORY
Pit-and-fissure sealants
Evidence-based recommendations from the ADA Council on Scientific Affairs 257

- Executive summary of recommendations, after 256
- **RELEVANT ANNOUNCEMENTS**
- Effect of dental sealants on bacterial levels in caries lesions 271
- Four-handed delivery and retention of resin-based sealants 281

CLINICAL PRACTICE
Sealant effectiveness and quality of life in Nigerian adolescents 201

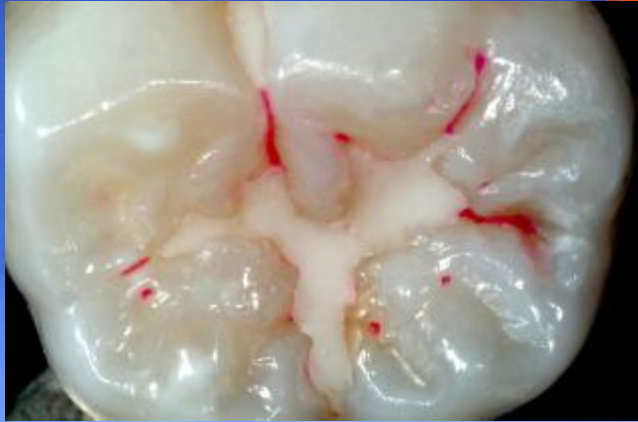RESEARCH
Effect of sealant on caries and enamel attrition 209

TRENDS
Preparing ourselves to engage in practice-based research 209

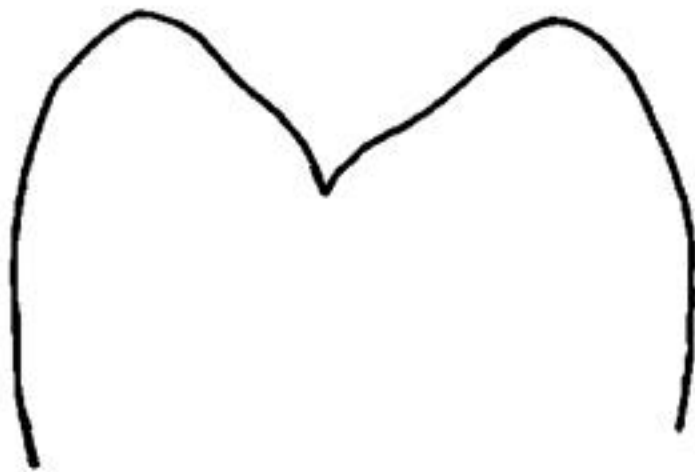


At ten year follow up,
traditional sealants showed a
92% failure rate...


Christiansen RP, Ploeger BJ, Palmer TM. The role of pit-and-fissure discoloration in caries assessment. *Compend Contin Educ Dent.* 2001 Nov;22(11A):996-1002, 1004-7



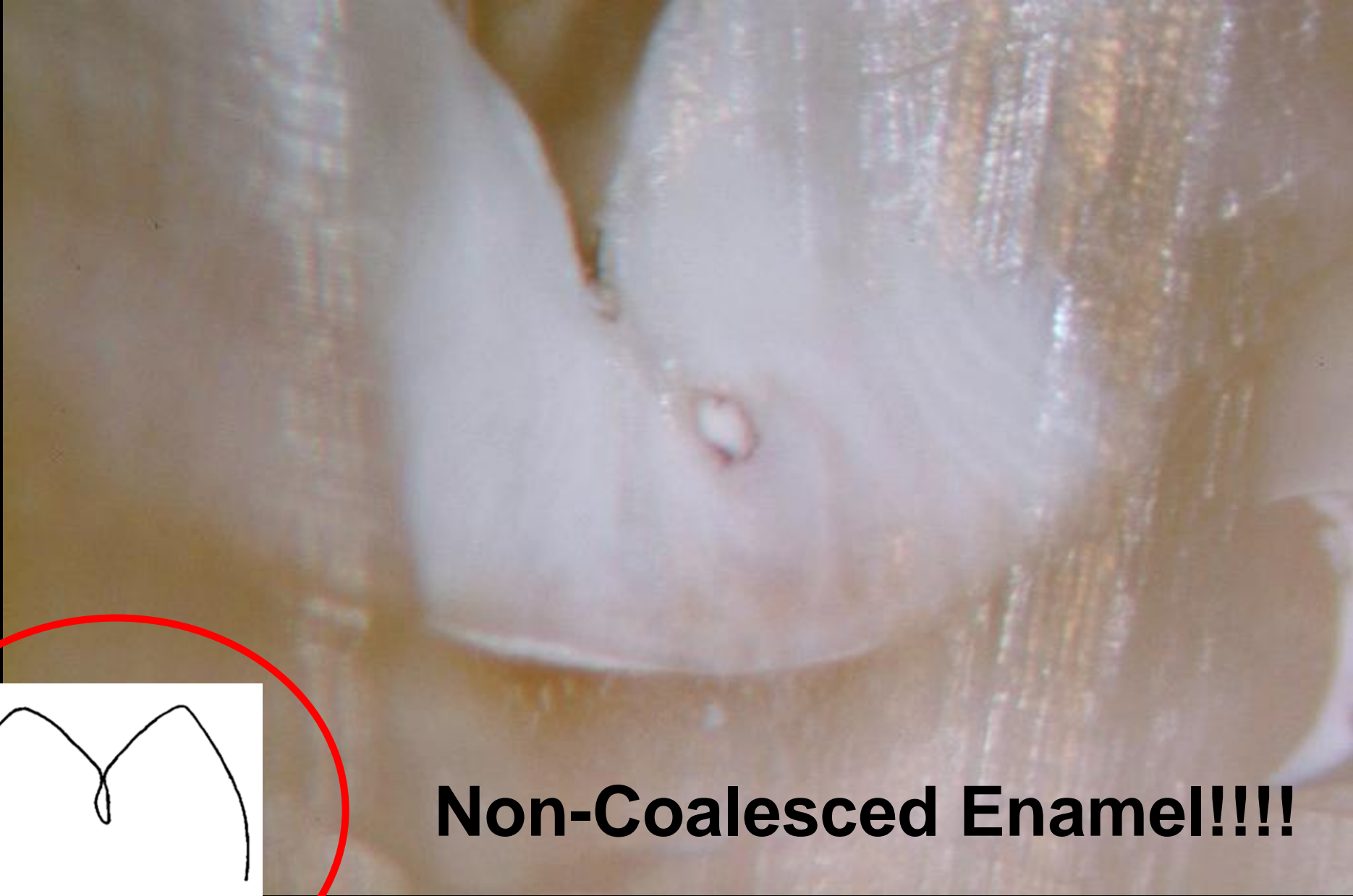The "Chee-to" phenomenon



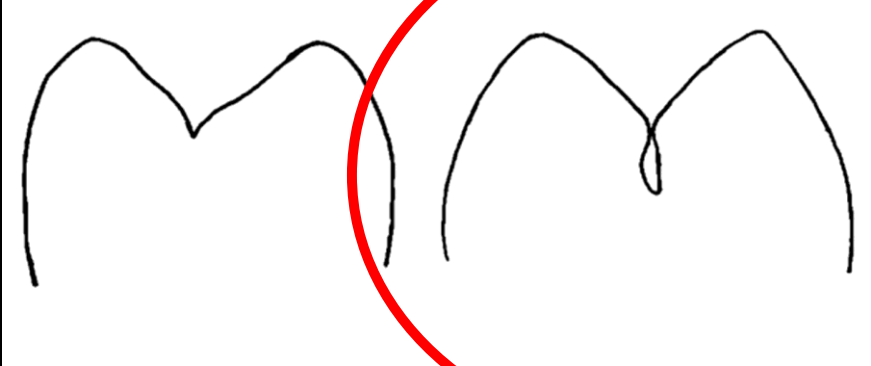
Coalesced Enamel



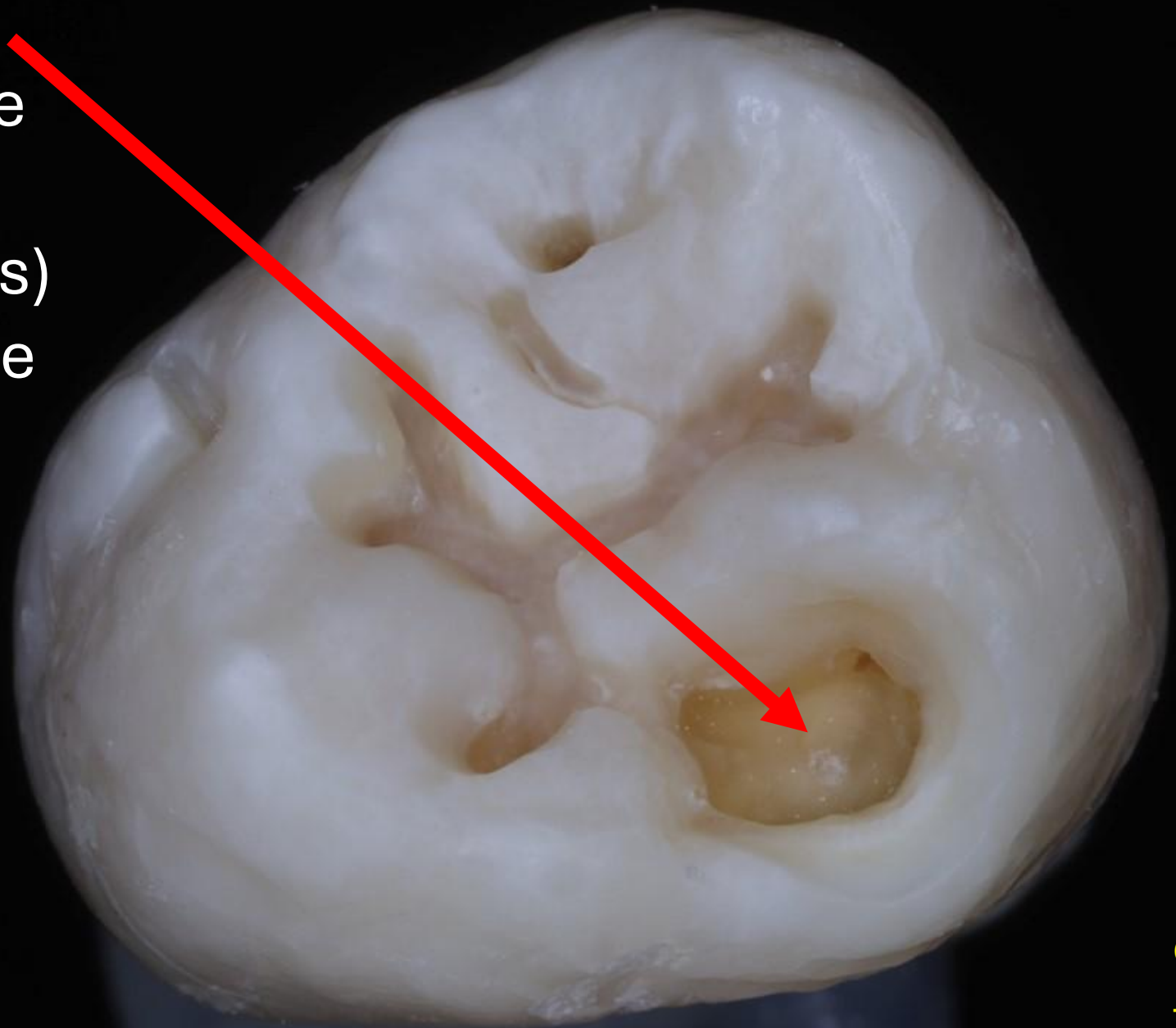Non-Coalesced Enamel



Non-Coalesced Enamel!!!!

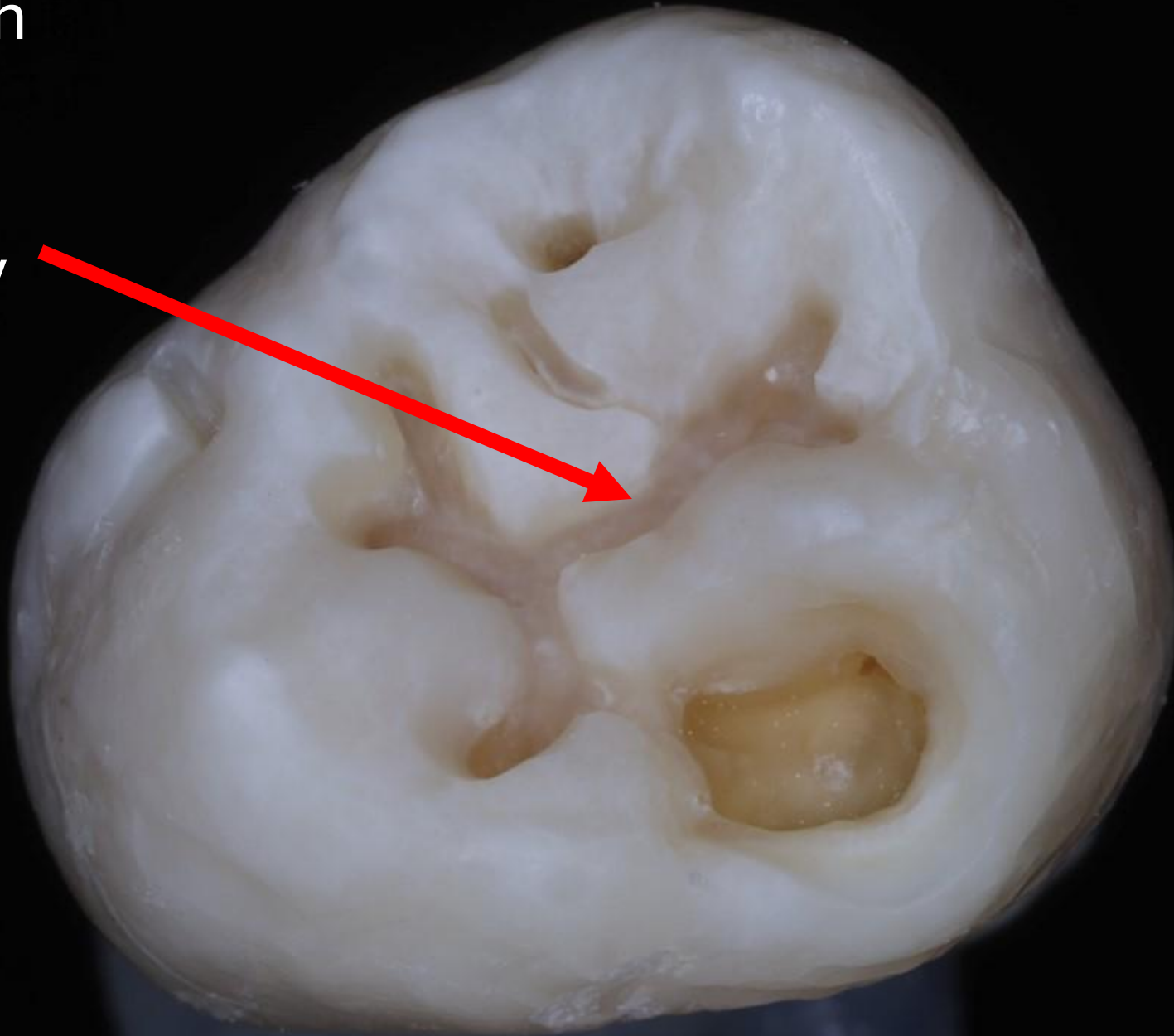


Occult decay
(invisible to the
eye and in
bitewing x-rays)
until the fissure
is opened and
inspected



Courtesy Dr.
Joshua Solomon

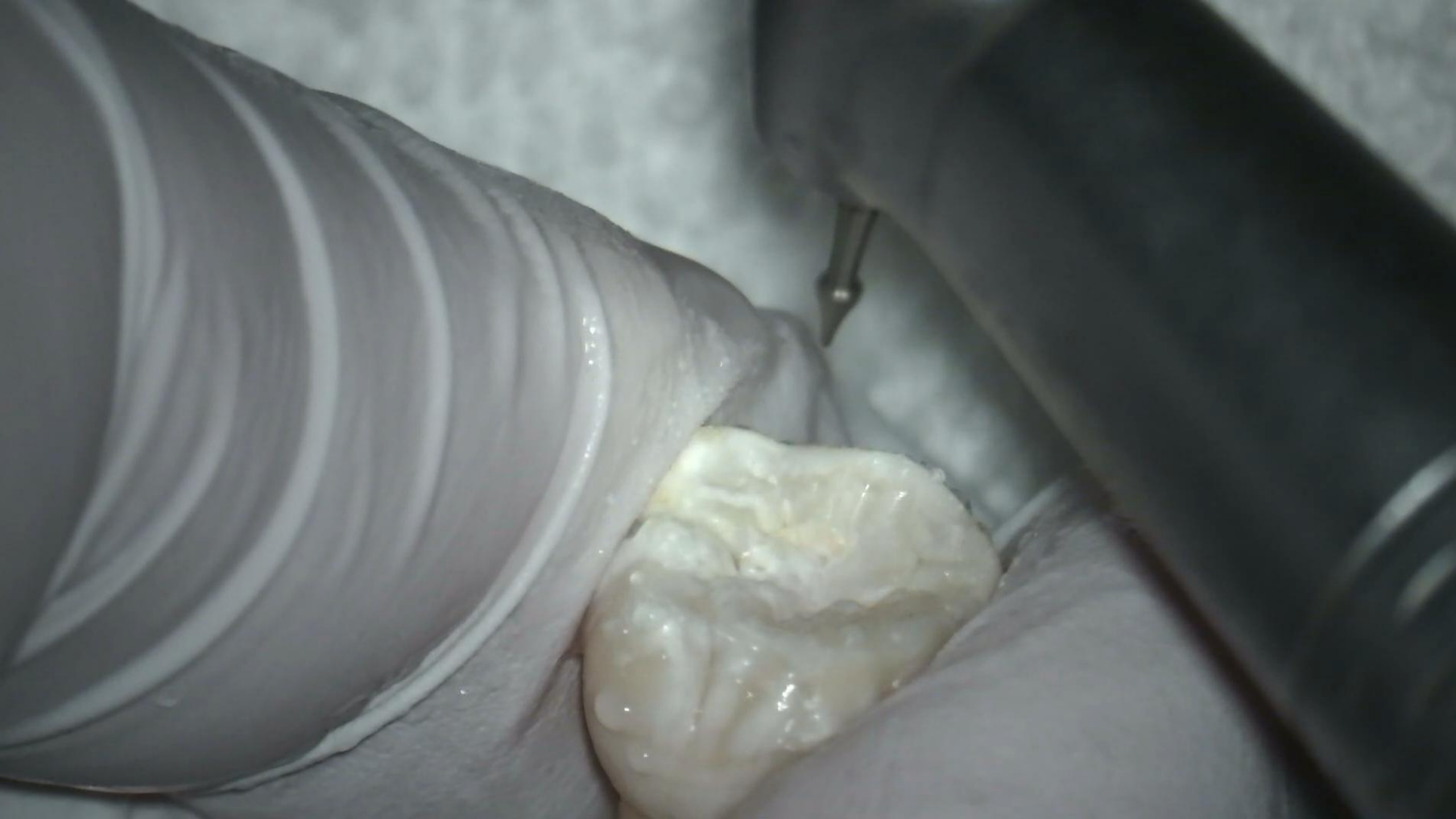Prep cut with
the Narrow
Calla Lily
Fissurotomy
carbide bur,
which is my
“go to” CLF
bur



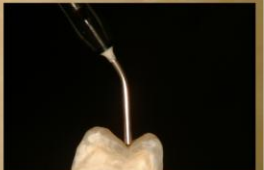
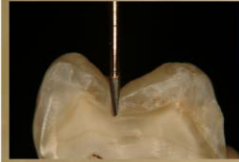
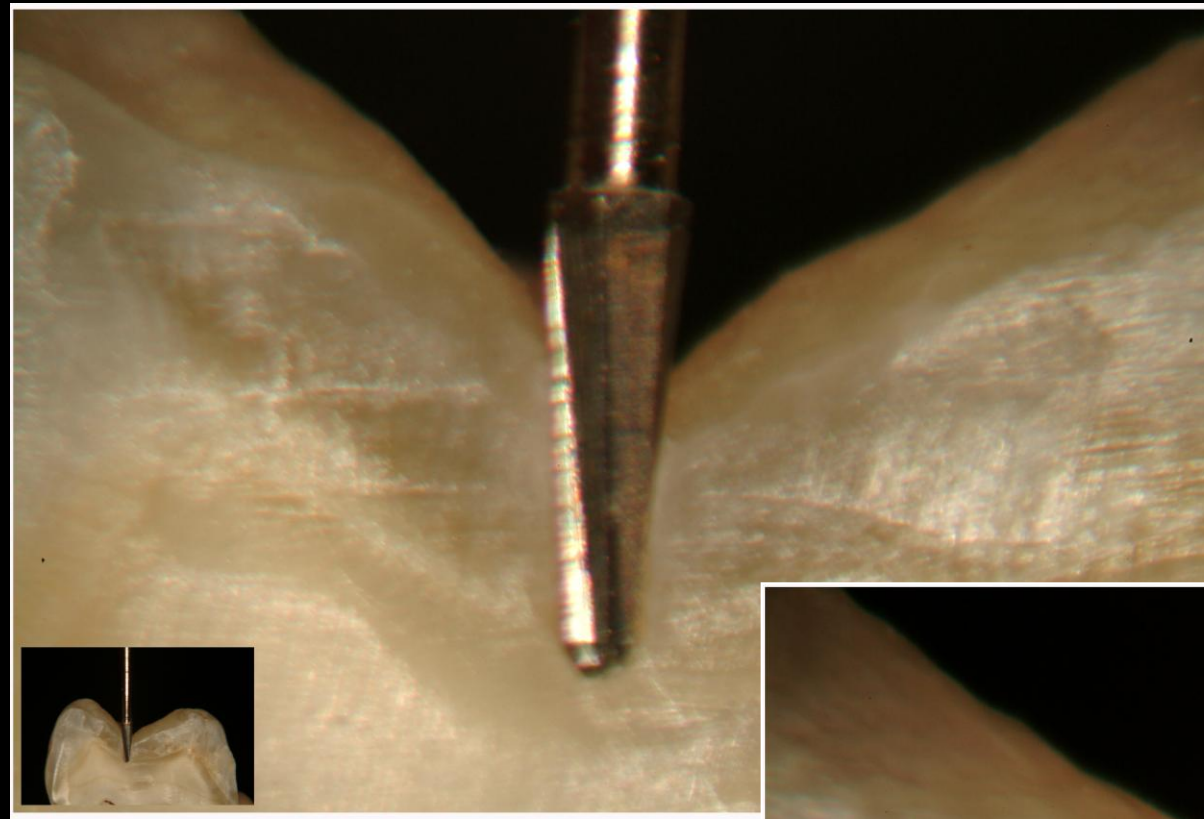
Courtesy Dr.
Joshua Solomon

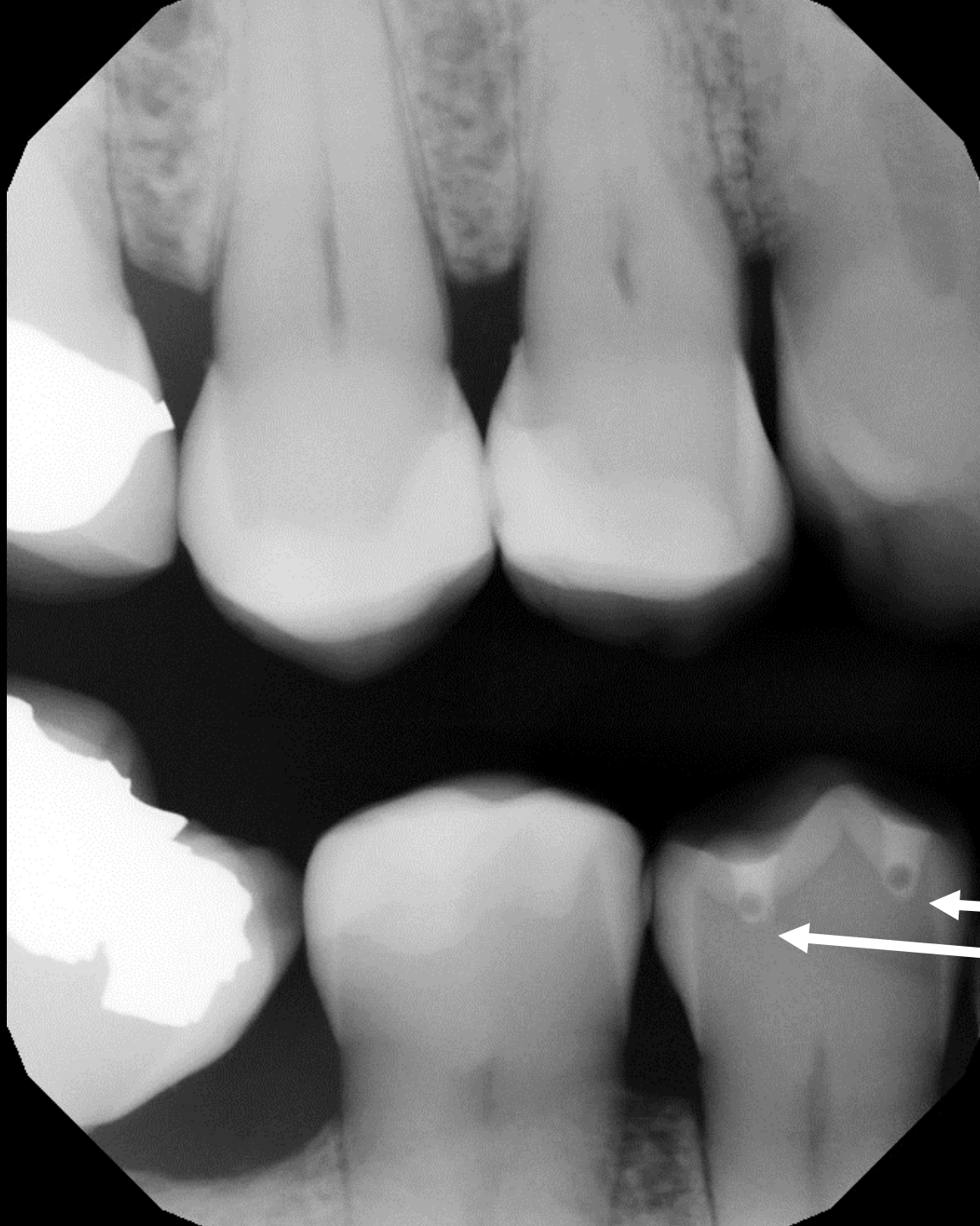The Calla Lily



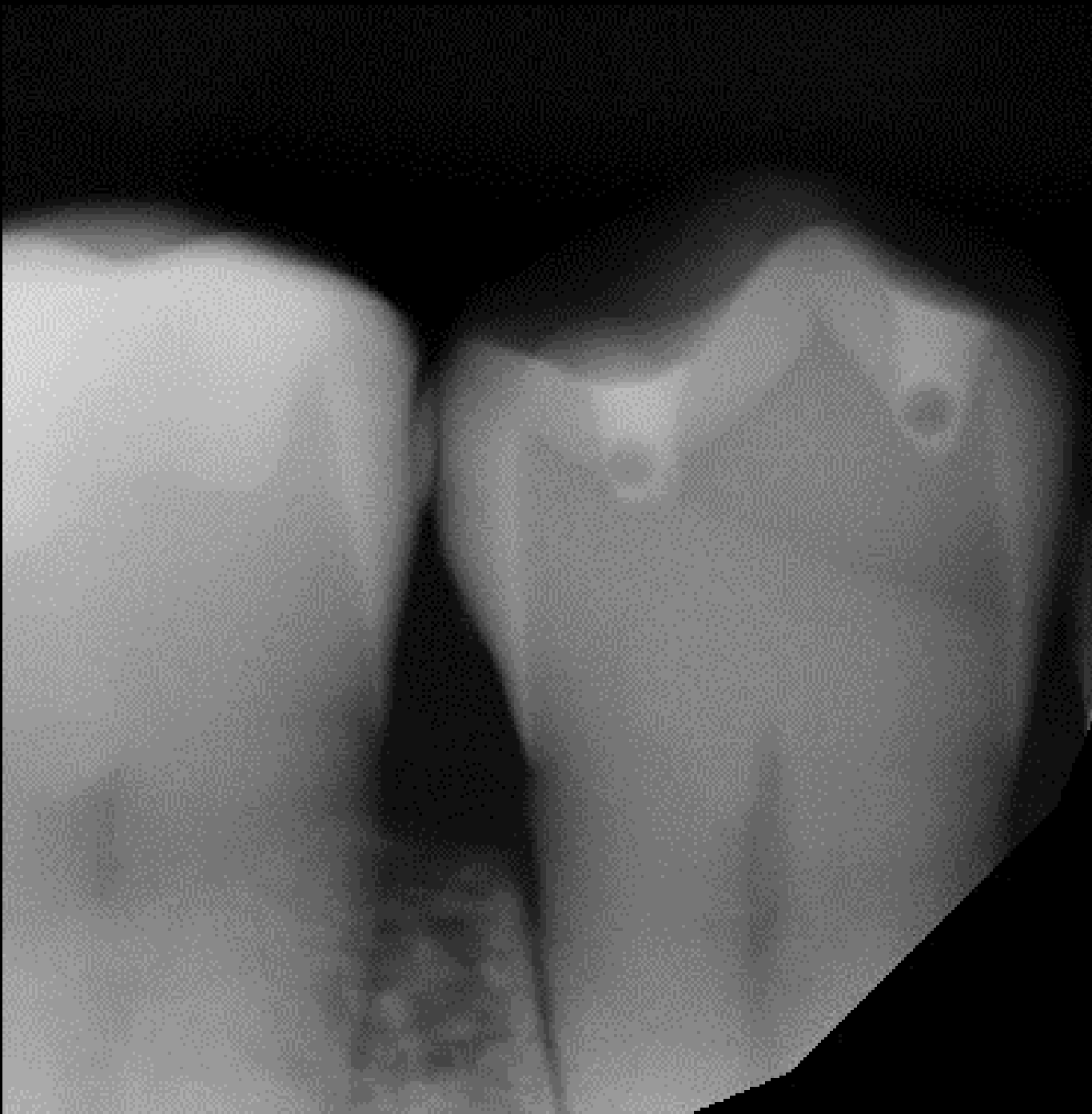

The Fissurotomy bur circa 1990, a great bur but when the fissures were deep, impossible to restore without trapping air





This bicuspid had fissurotomy preps cut and restored with flowable composite. I chased after deep stained pits and found no dentinal caries. This radiograph demonstrates the difficulty in restoring the shape created by the SS White Fissurotomy bur. I used a microscope and was unaware of the bubbles until the recall exam with updated xrays



Notice that I even beveled the opening. This bur creates a shape that is virtually unrestorable if the bur is dropped to its full 2.5mm depth



I've been
working and
waiting for the
CLF bur for 20
years!!!

Calla Lily Fissurotomy Bur for the Sealant - Class I Resin Continuum

SNCLF- Super Narrow Calla Lily Fissurotomy

NCLF- Narrow Calla Lily Fissurotomy

CLF- Cally Lilly Fissurotomy

WHITE Dental®

Better Patient Outcomes
Improved Efficiency
Faster Practice Growth



Calla Lily Fissurotomy Bur for the Sealant - Class I Resin Continuum

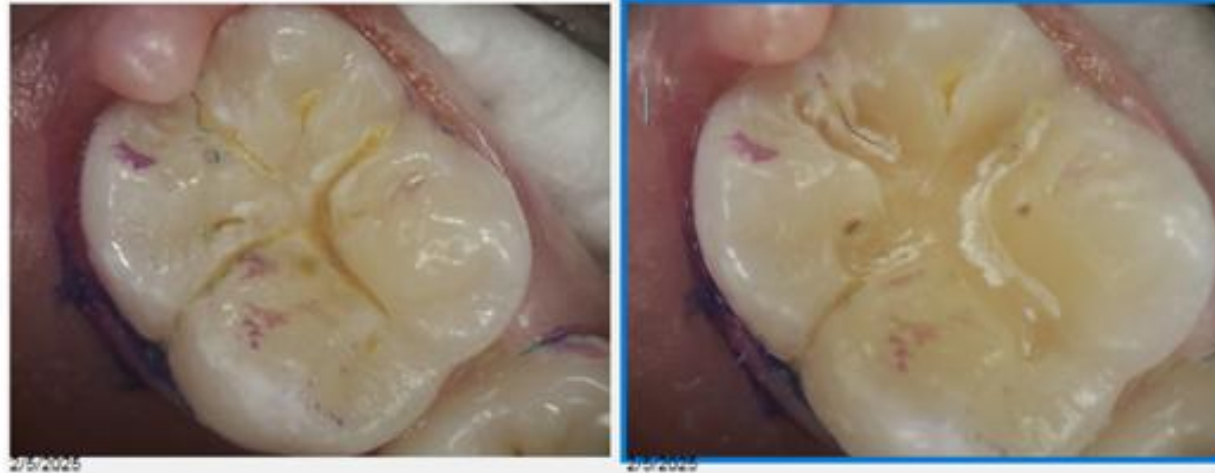
SNCLF- (Super-Narrow) virgin teeth, “stained” grooves or incipient caries. Planned restoration: sealant, PRR (preventative resin restoration) with flowable composite

NCLF- (Narrow) occlusal caries in the pits and fissures, dentin may or may not be affected, flowable or traditional composite as a restorative material

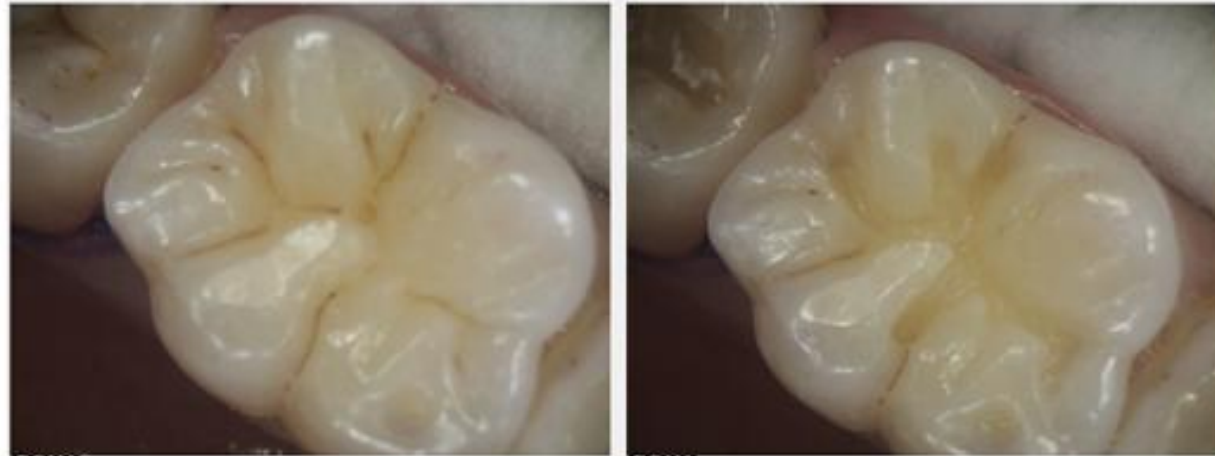CLF- Frank caries and or hypoplasia, dentin removal likely needed, may extend up cuspal inclines. Flow plus paste composite

Initial Caries Removal on Adjacent Virgin Teeth (#30 and #31)

#31 CLF



#30 NCLF



Advantages of the CLF burs

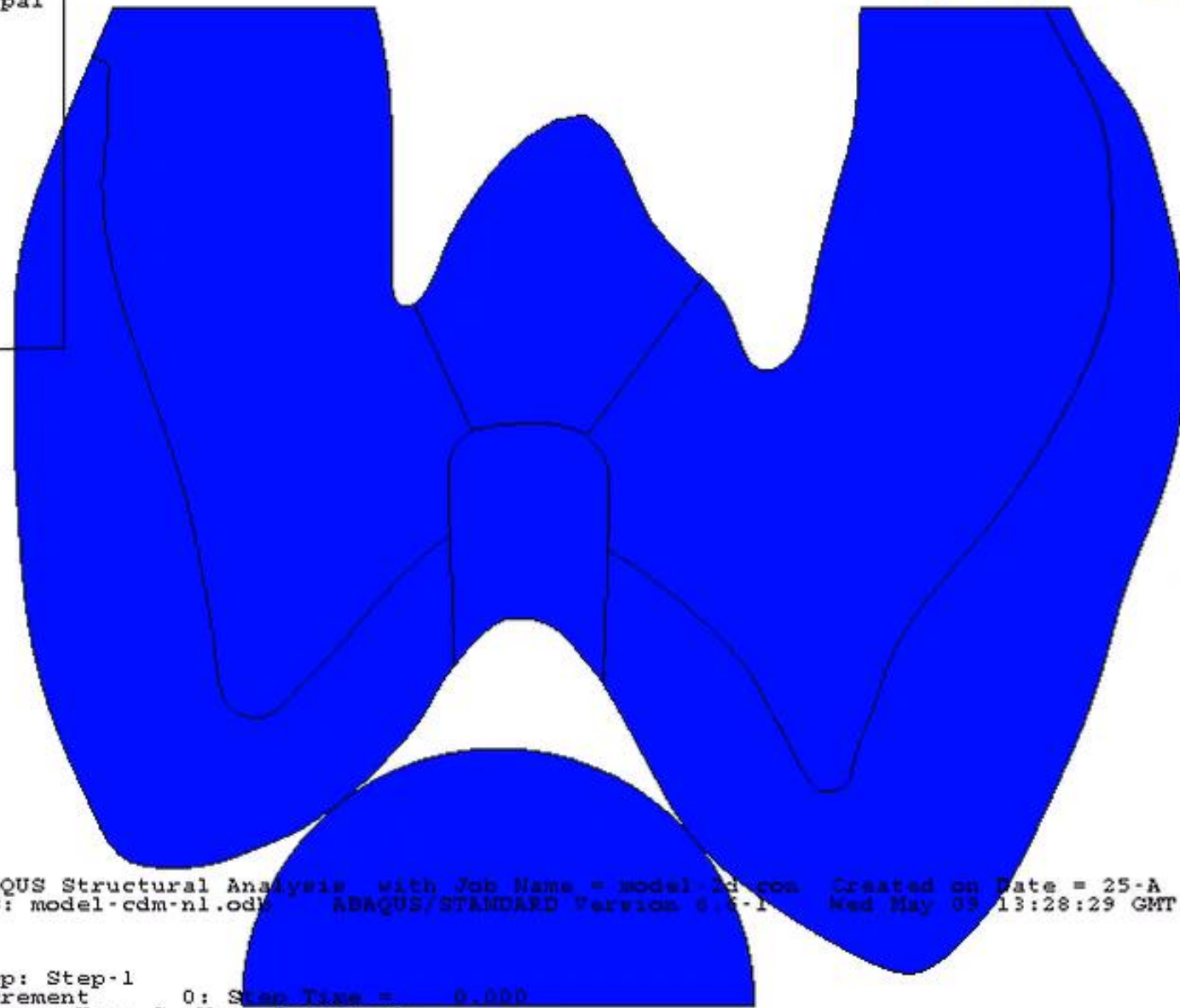
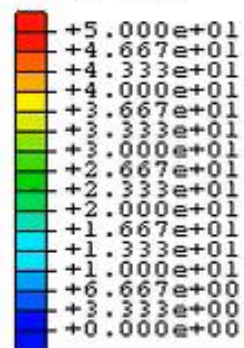
- Tip is super engineered to stay sharp with multi uses
- Fewer blades overall cut faster than 6 or 8 blades
- On the un-anesthetized tooth, it is safer than other burs to avoid pain from heating during cutting
- When dentinal caries is discovered, especially in the non anesthetized tooth, stop cutting and allow the enamel funnel to direct the Bioclear Blaster to painlessly remove dentinal caries. (10 -60 seconds).

Advantages of the CLF burs

- Better C Factor
- Better splinting of the tooth, less weakening. Weakening = $(2 \times \sqrt[L]{R})$
- Better vision when prepping especially the disto-occlusal of an upper molar where the transverse ridge blocks our view
- Easier identification of occult dentinal caries. Occult dentinal caries is often in a cul-de-sac and/or a dogleg of enamel and is challenging to visualize with Fissurotomy or NTF bur. Especially for students or doctors without microscopes.
- Great for investigating and expanding the R (radius) in a cracked virgin occlusal surface

Why can't I just use a 556 bur
for Class I composites?

S, Max. Principal
(Avg: 75%)



ABAQUS Structural Analysis with Job Name = model-cdm-nl.odb Created on Date = 25-A
ODE: model-cdm-nl.odb ABAQUS/STANDARD Version 6.5-1 Wed May 03 13:28:29 GMT Daylight

Step: Step-1
Increment 0: Step Time = 0.000
Primary Var: S, Max. Principal
Deformed Var: U Deformation Scale Factor: +1.000e+01

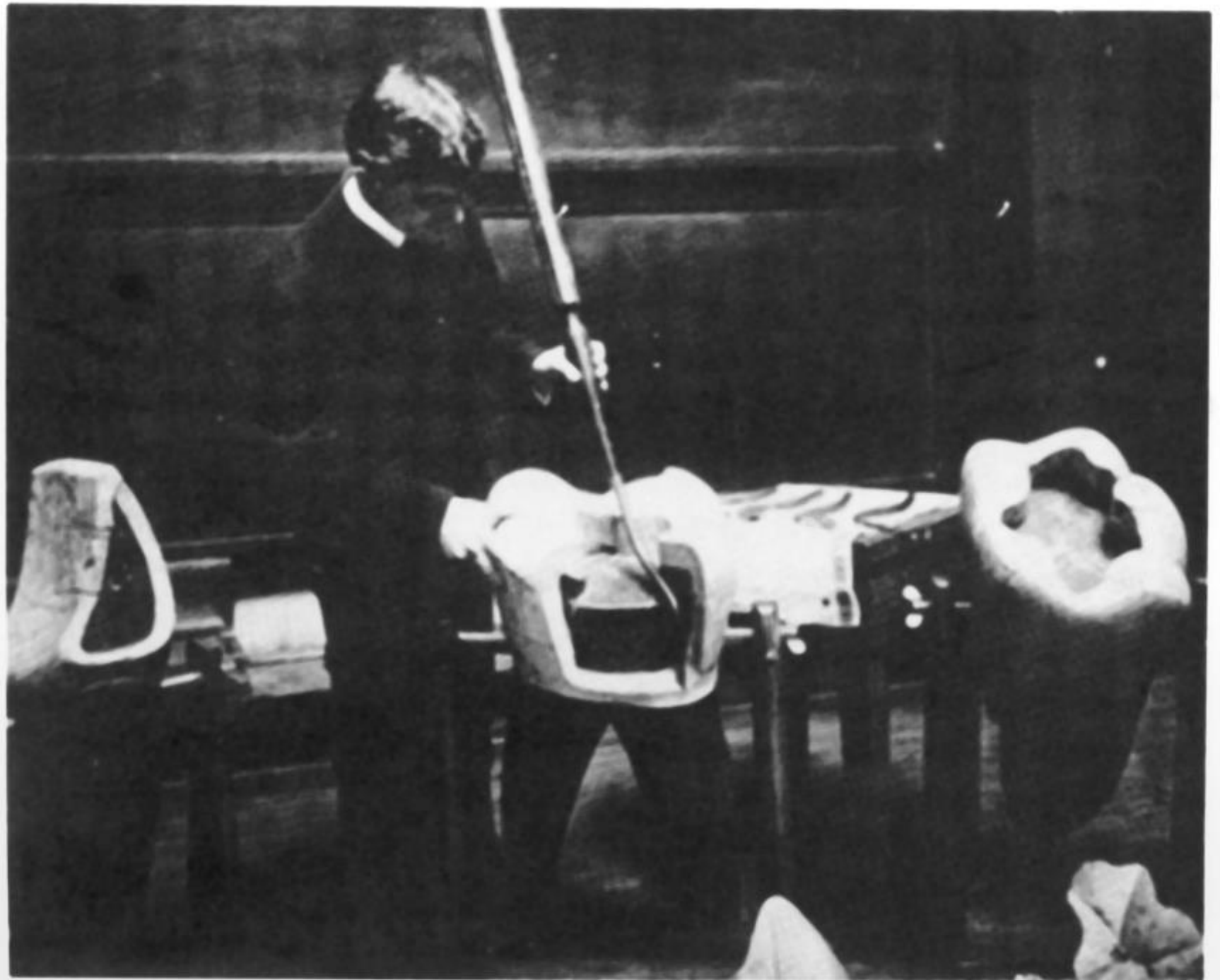
**WHERE ARE WE WITH
CAVITY SHAPES?**

1890

**G. V. BLACK,
M.D., D.D.S.,
Sc.D., LL.D.,
1836-1915**



**MORTICE AND
TENON JOINTS
NECESSARY FOR
MECHANICAL
RETENTION OF
AMALGAM**



EDGETAPER
PLATINUM™



PER GOLD® \$67/6pk
Taper Platinum™

95/6PK

ROTAPER GOLD®
ROTAPER®

FIREWIRE™ NITI

ance as PROTAPER GOLD®
ance as PROTAPER®

THE JOURNAL OF MULTIDISCIPLINARY CARE

Decisions™ IN DENTISTRY

CONSERVATIVE APPROACH TO DEEP CARRIES LESIONS

NATHANIEL LAWSON, DMD, PhD, and
AUGUSTO ROBLES, DMD, MS

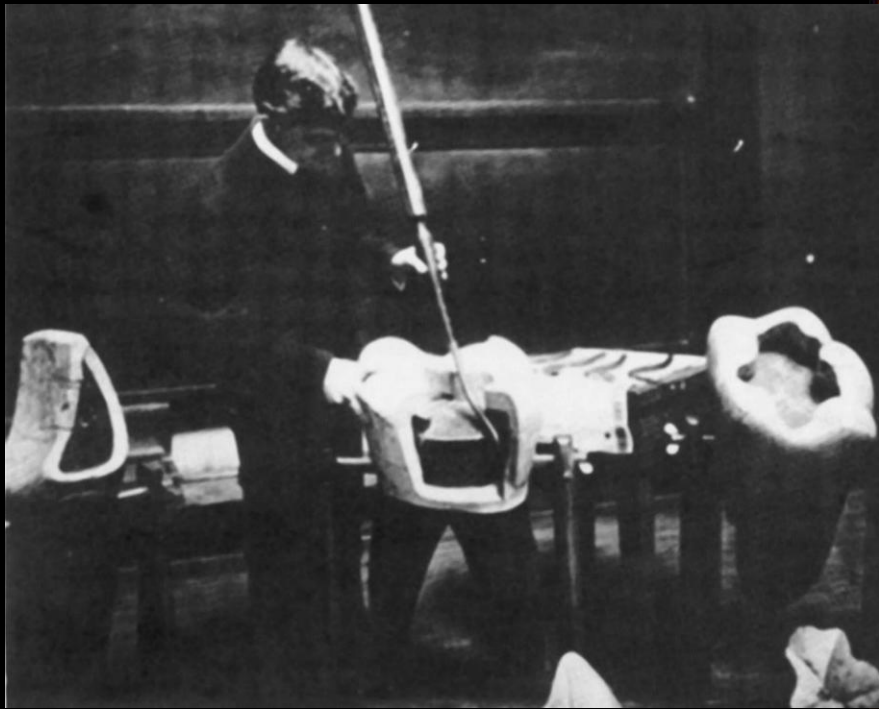
RISK FACTORS IN
ORAL CANCER
SCREENING
SARAH GLASS, DDS

HOW MANAGED
CARE WILL IMPACT
DENTAL PRACTICE
JOEL H. BERG, DDS, MS

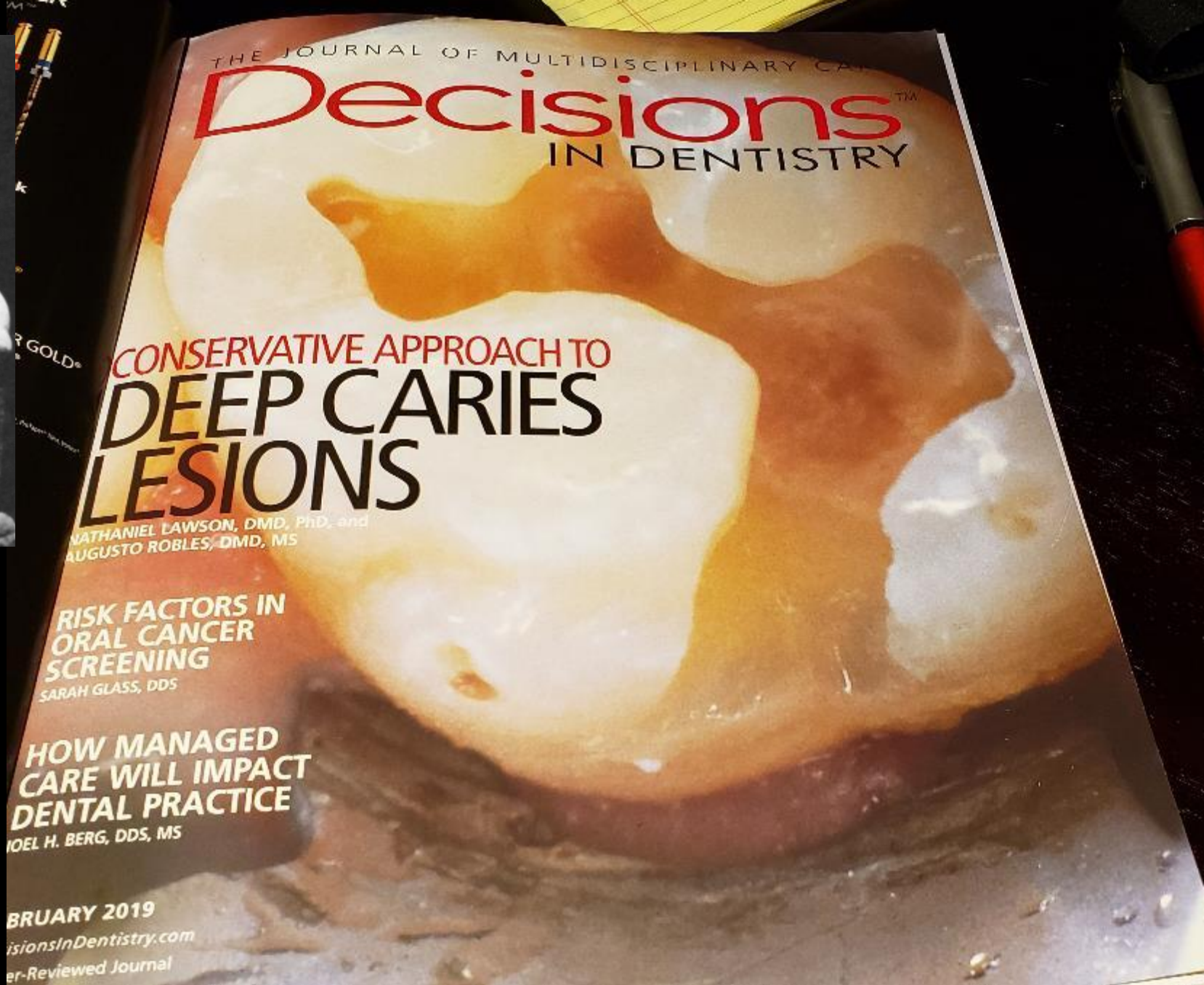
FEBRUARY 2019

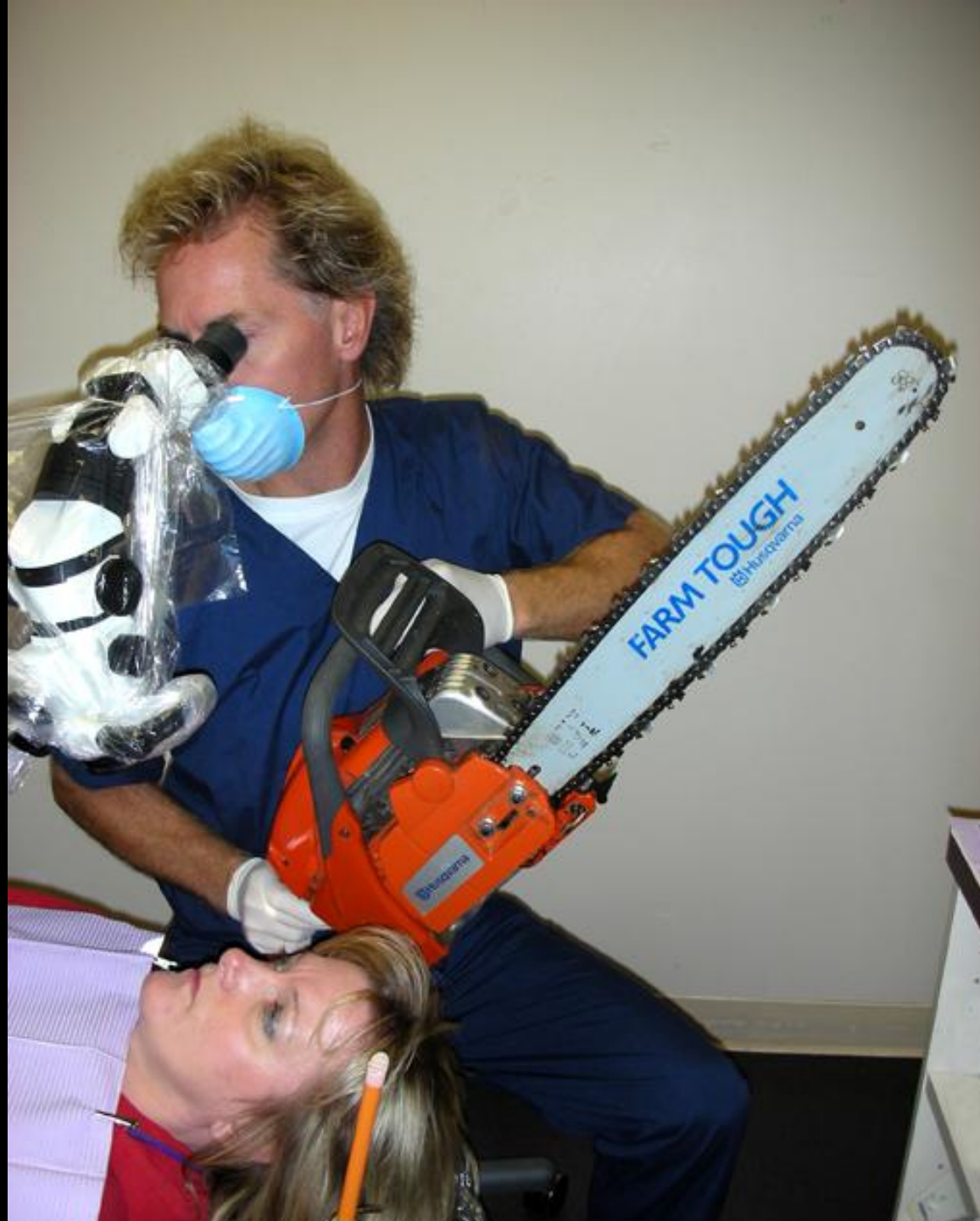DecisionsInDentistry.com

A Peer-Reviewed Journal



Is this the
year 2025
or 1890?





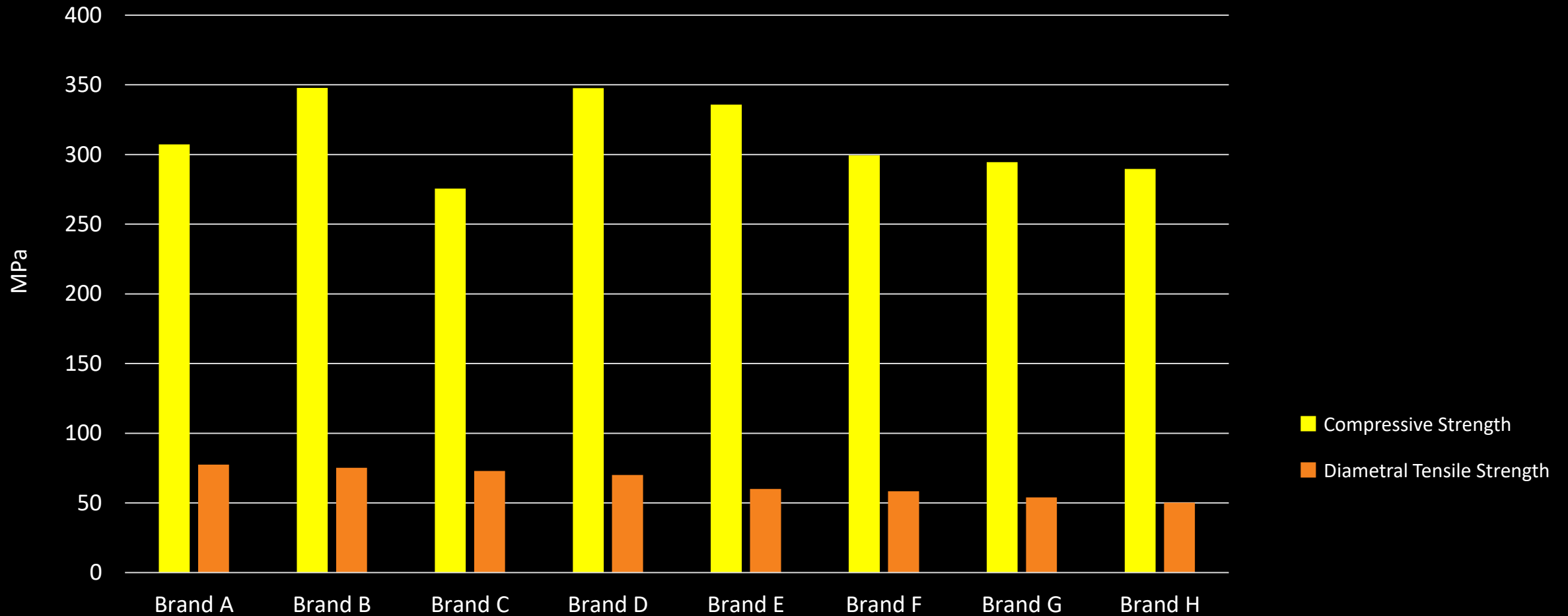
Why can't I just use a 556 bur
for Class I composites?

Epidemic of Cracked Teeth...Why?

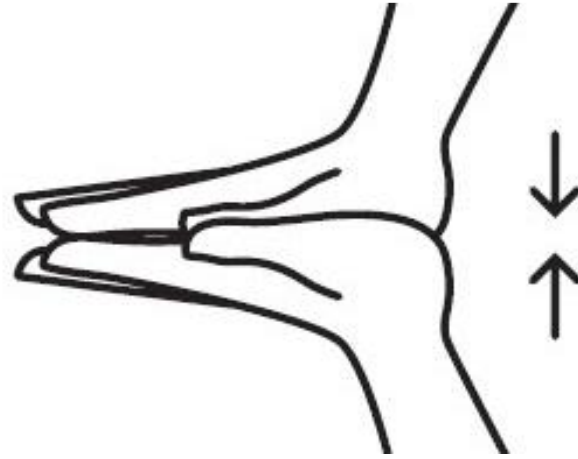
**Brittle Materials with
Tension joints**

Composite Resin Material Properties

Compressive vs Diametral Tensile Strength



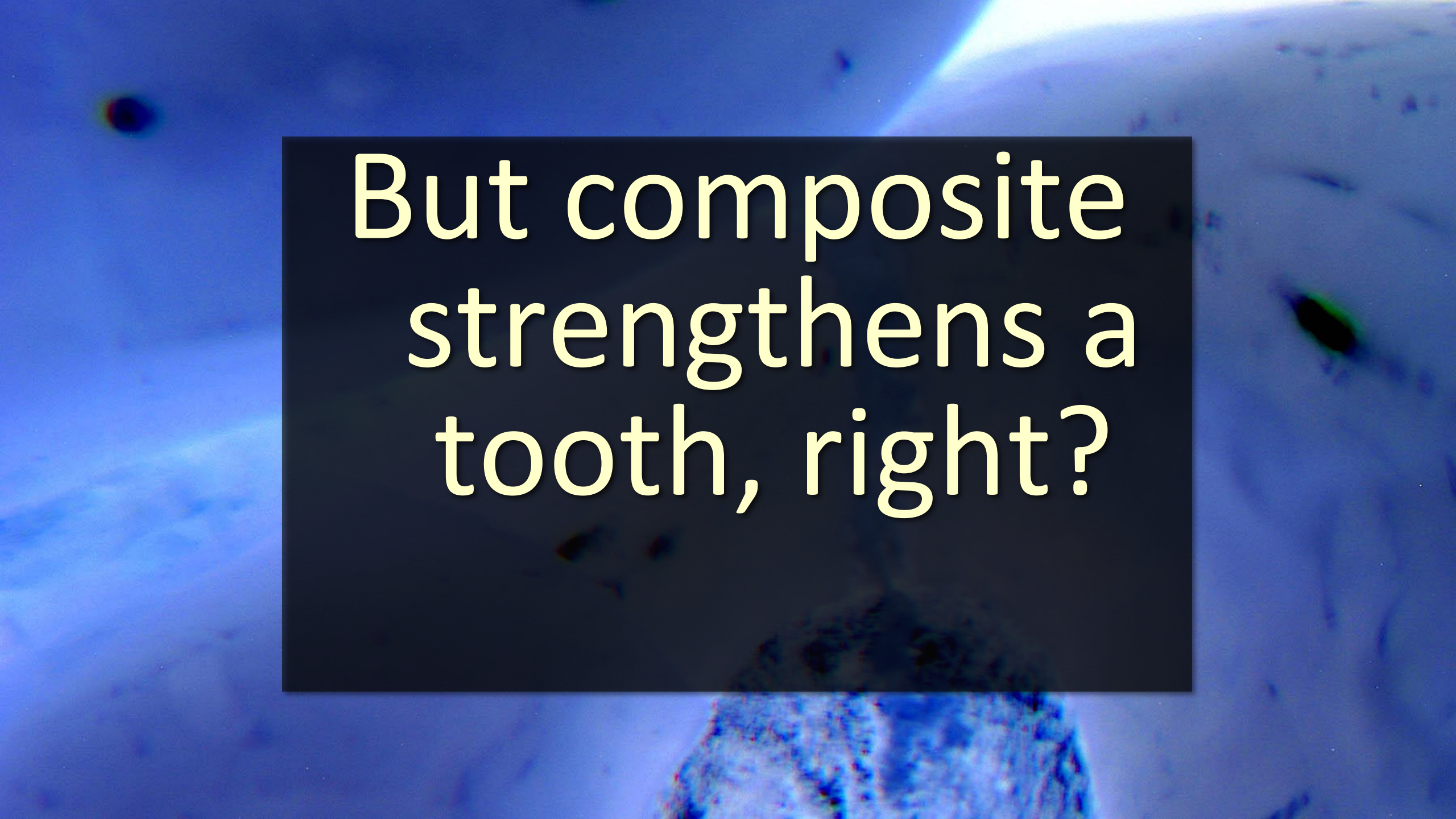
Compression vs. Tension is “Engineering 101”



compression



tension

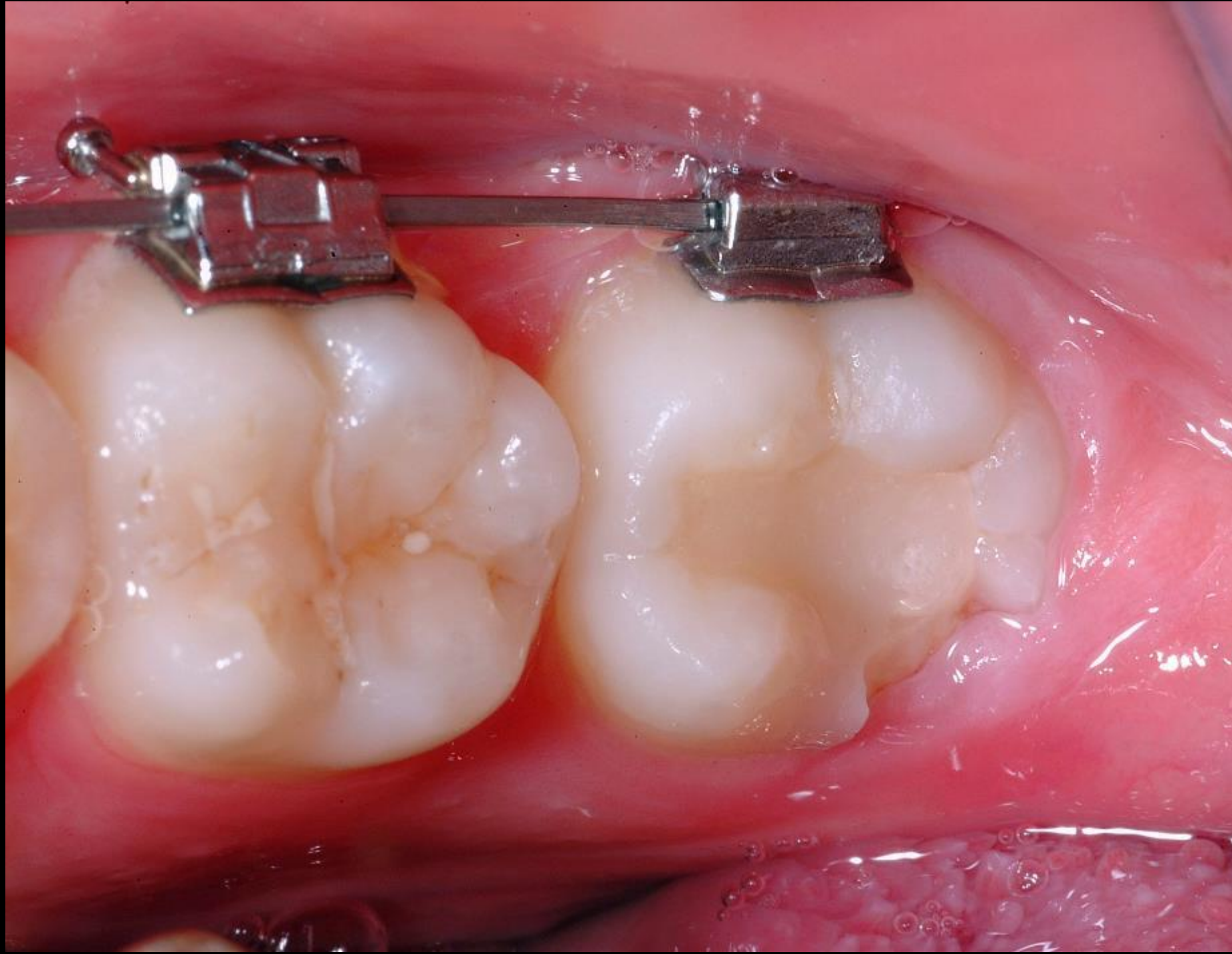
A microscopic view of a tooth with a composite filling. The background is a light blue, textured surface representing the tooth's enamel. A dark, irregularly shaped area at the bottom center represents the composite filling. The text is overlaid on a dark blue rectangular background in the center of the image.

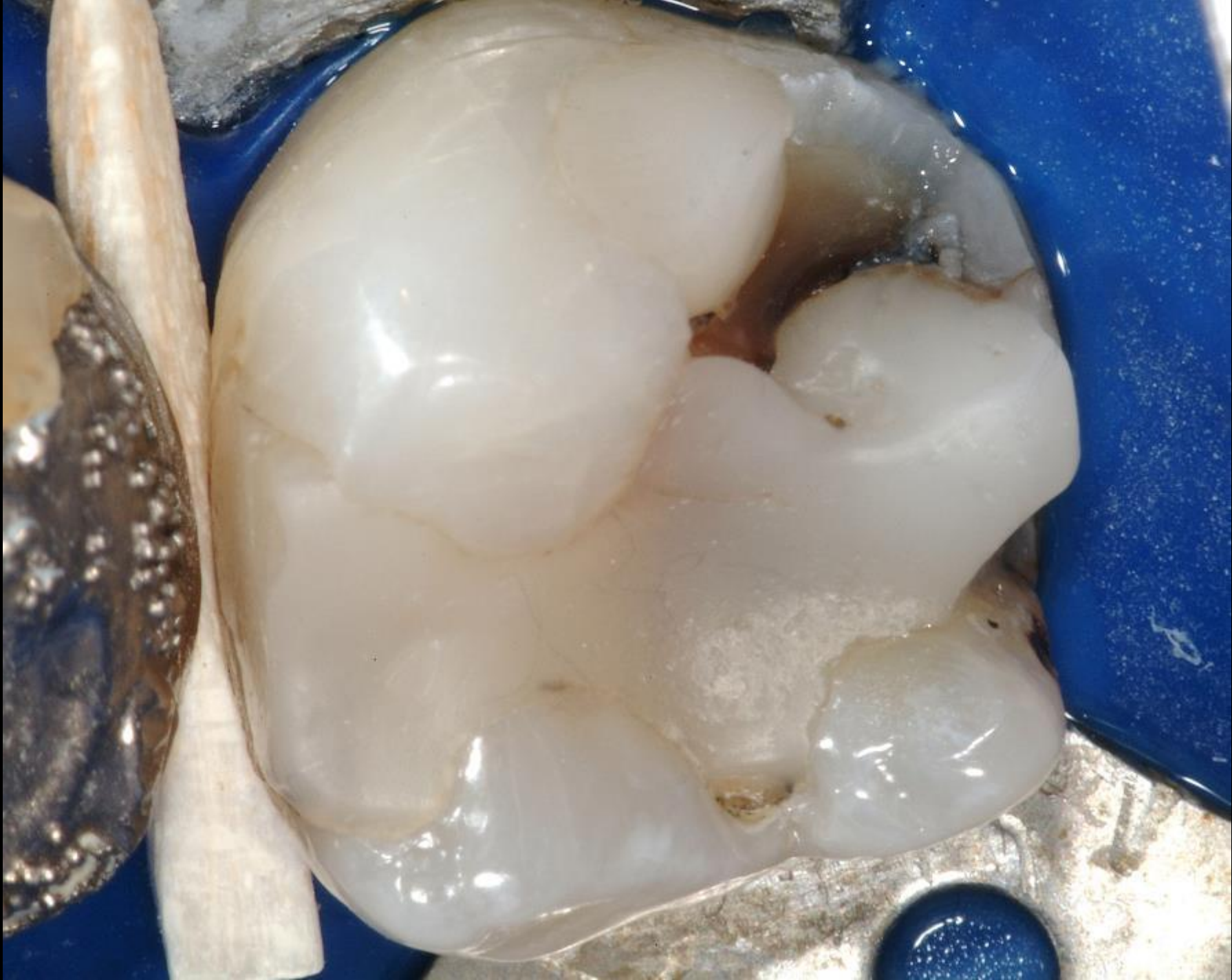But composite
strengthens a
tooth, right?

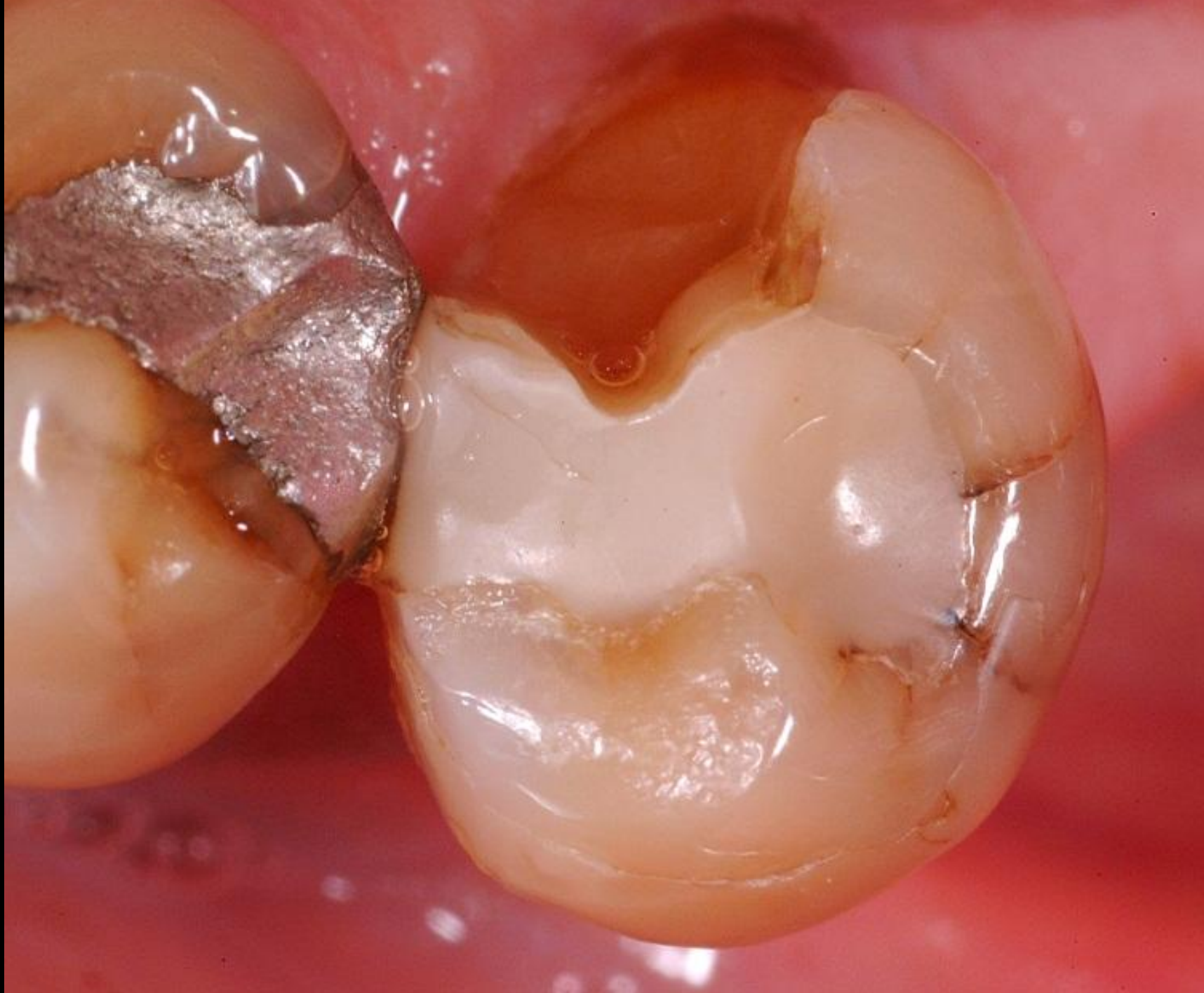Does composite strengthen the tooth?

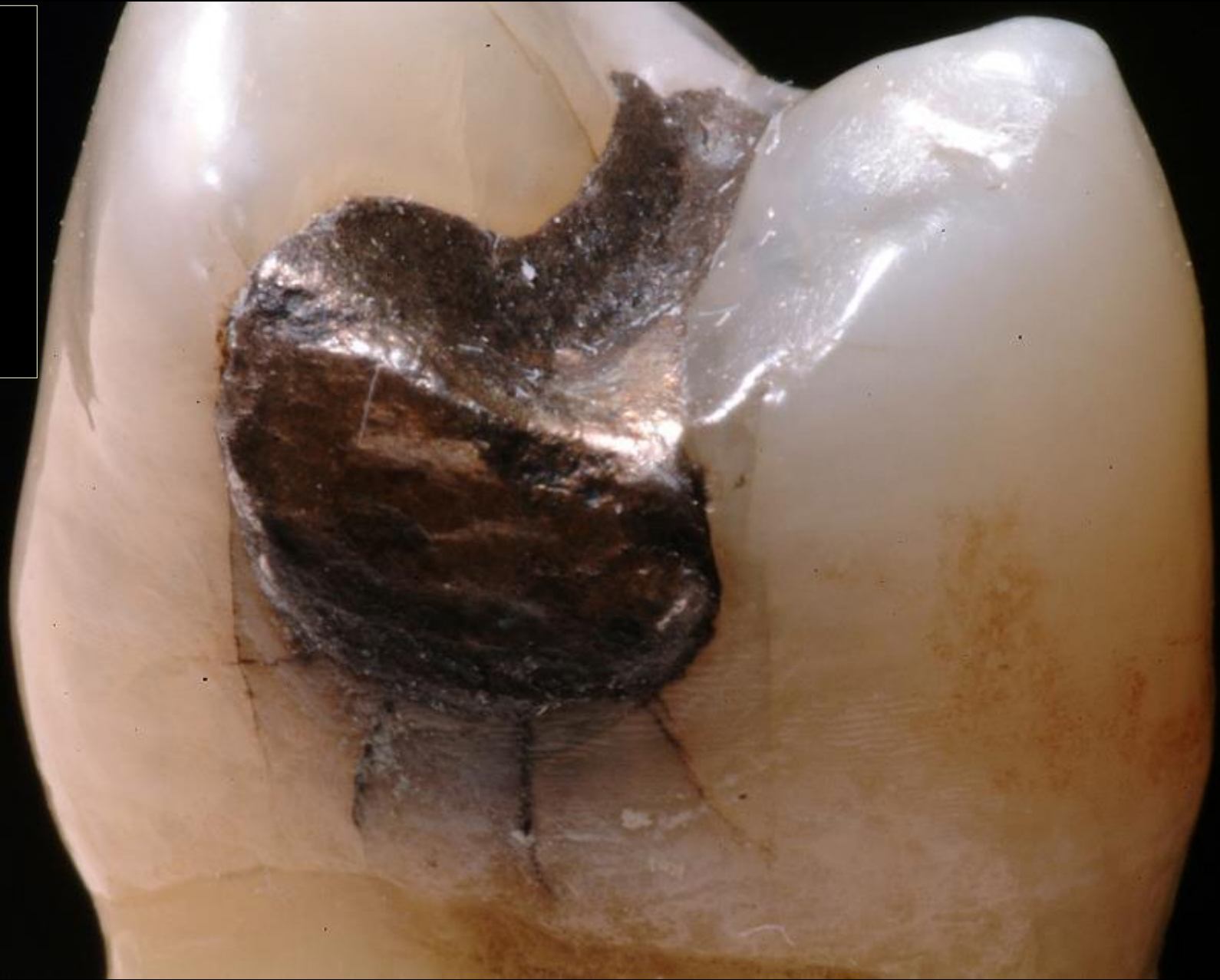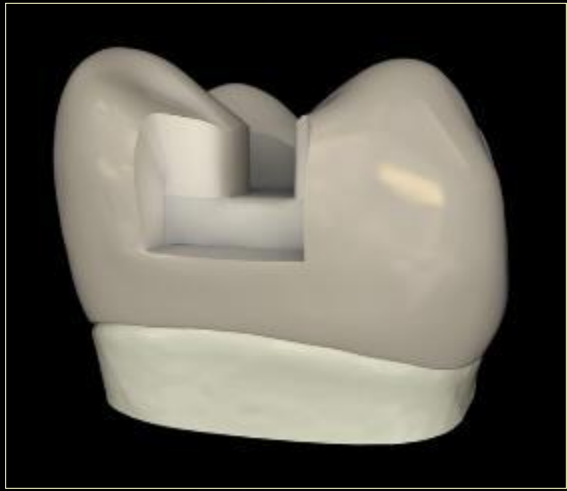
No more than does amalgam

Wahl MJ, Schmitt MM,
Overton DA, Gordon MK.
Prevalence of cusp
fractures in teeth restored
with amalgam and with
resin-based composite.
JADA 135:1127-1132
(2004)





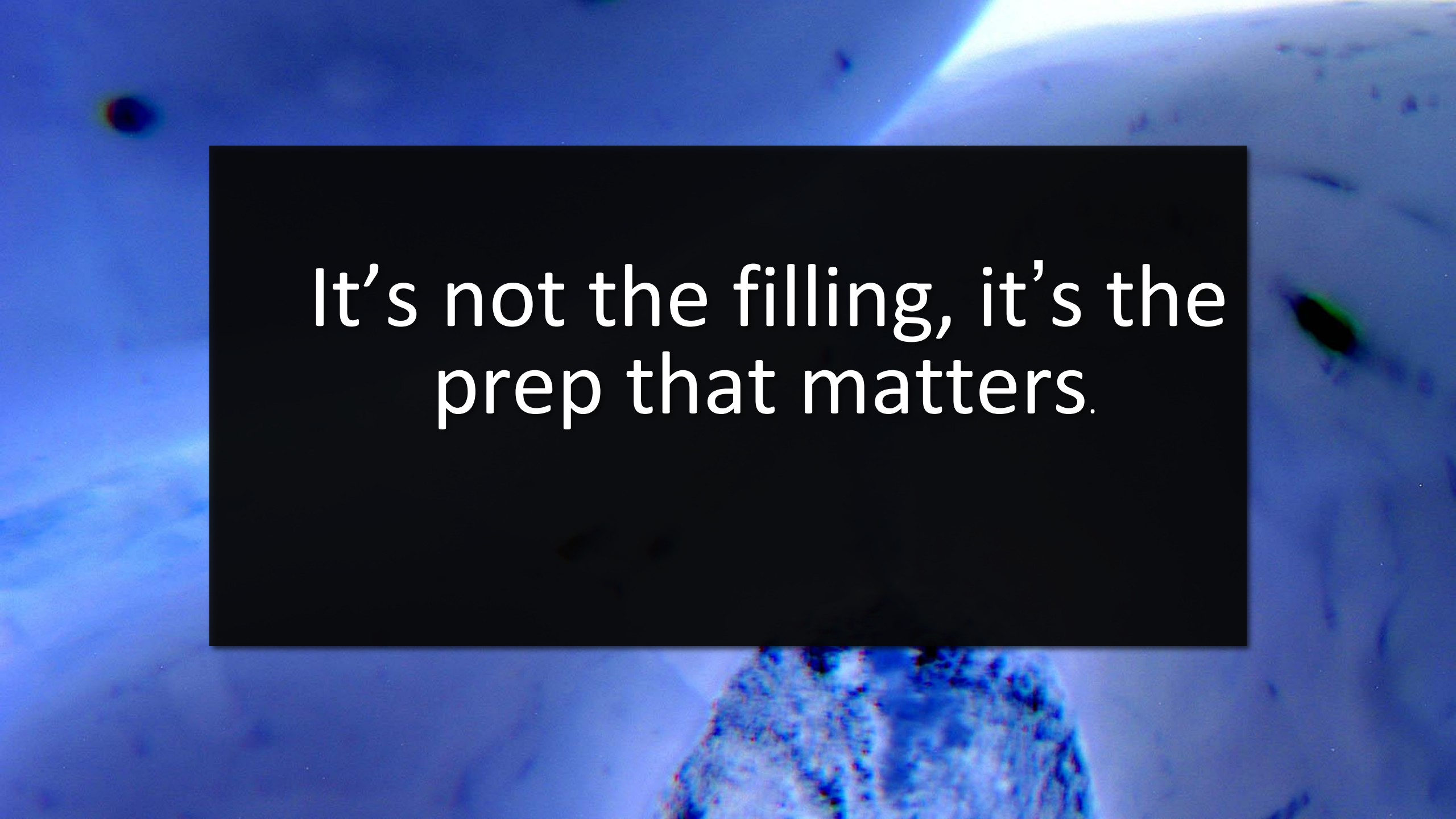




Boxes are bad.

Bevels make them less bad.

The Clark Class II replaces
beveling with radius walls.



It's not the filling, it's the
prep that matters.

Restoratively, It's Not the Size of the Hole, but the Shape of the Hole

The formula for determining stress concentration due to a cavity preparation is $(1+2\sqrt{\frac{L}{R}})$ where L is length of the cut and R is the radius of the cut. In simple terms, the longer the cut, the worse the cut. A long narrow cut, interestingly, is worse than a wide, round-bottomed cut. One reason that intracoronal composites do not protect the tooth from long-term from

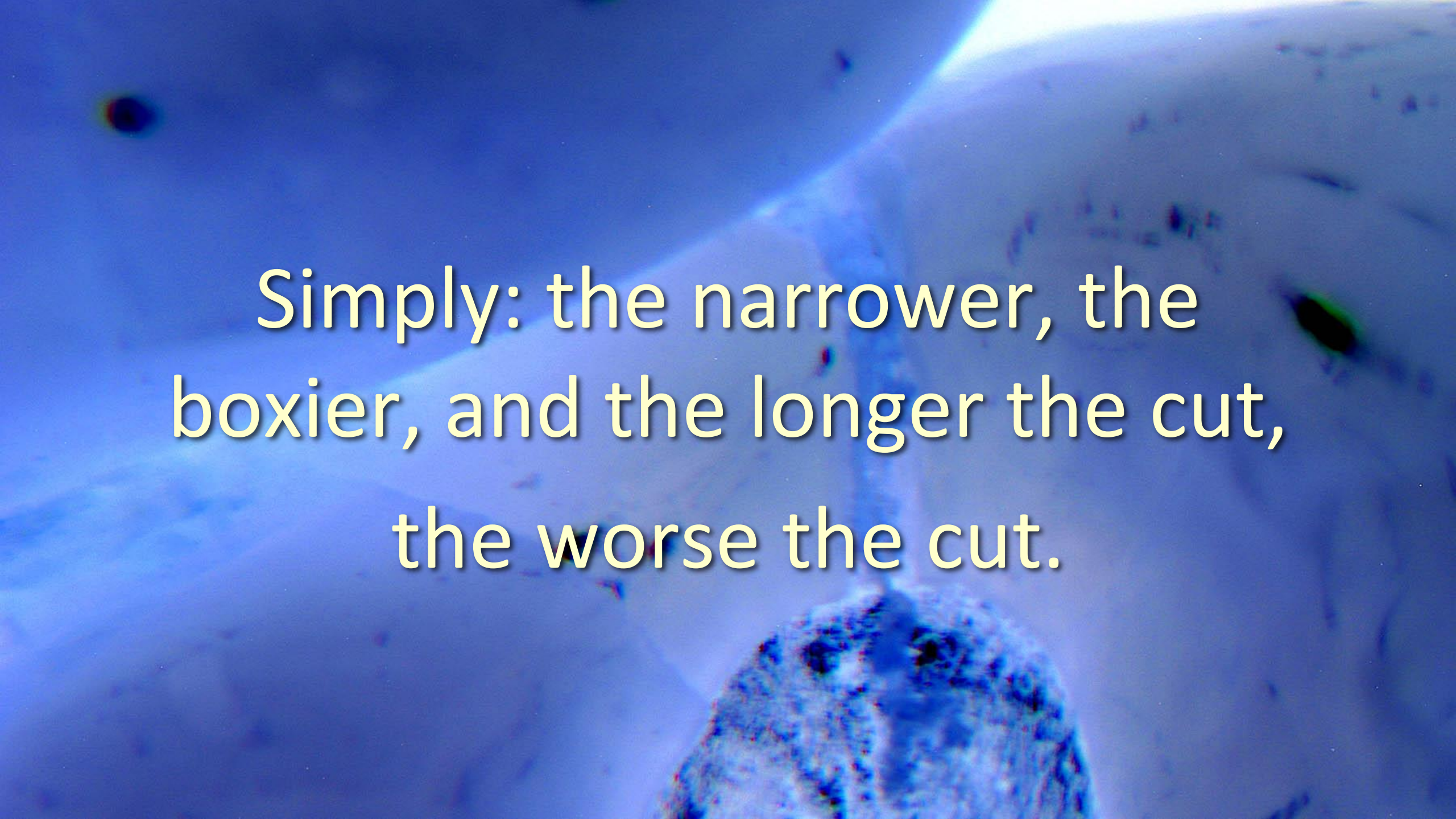


The formula for stress concentration in a cavity is

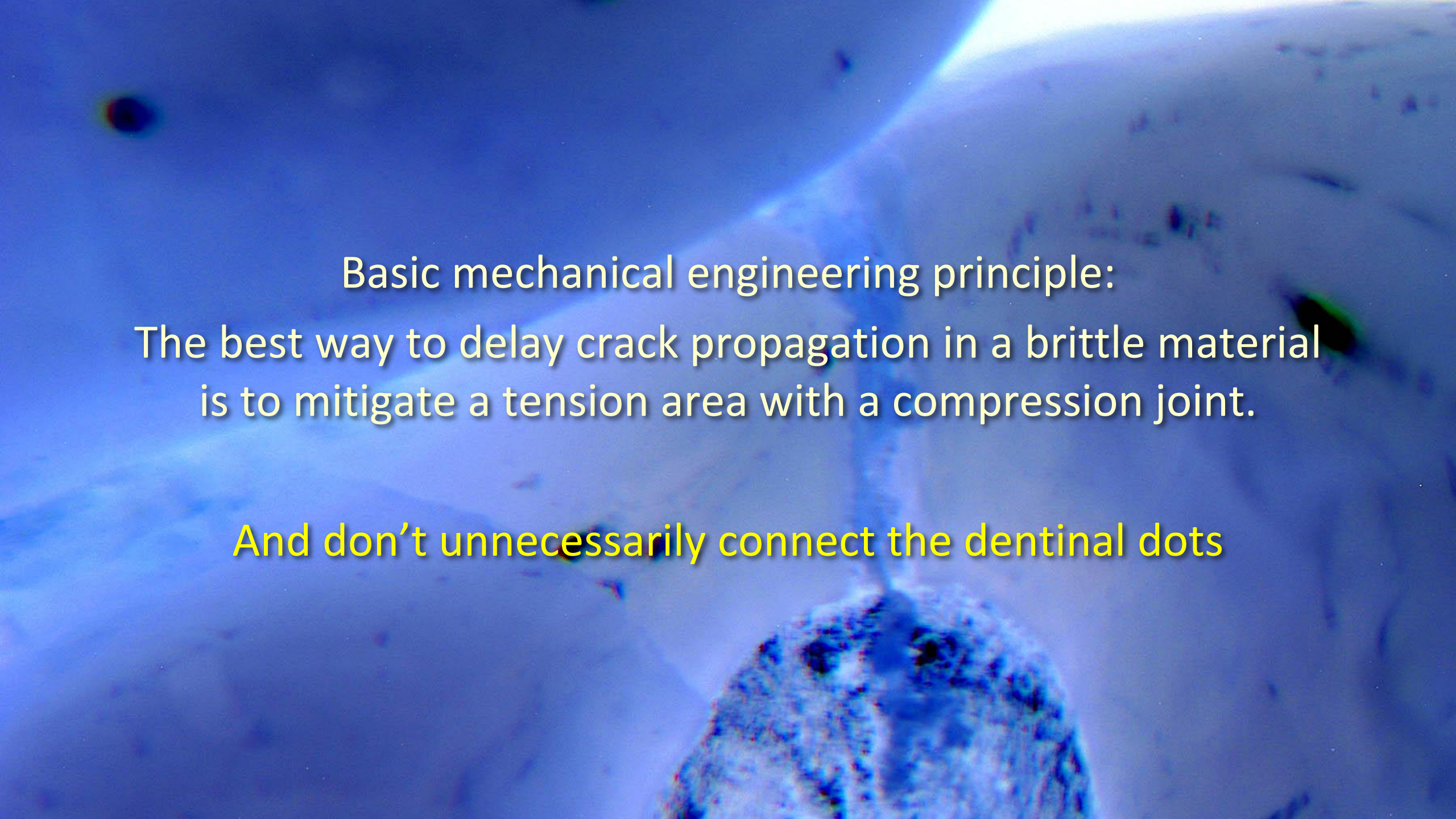
$$1 + 2 \sqrt{L/R}$$

L is the depth of the cut.

R is the radius of the cut.



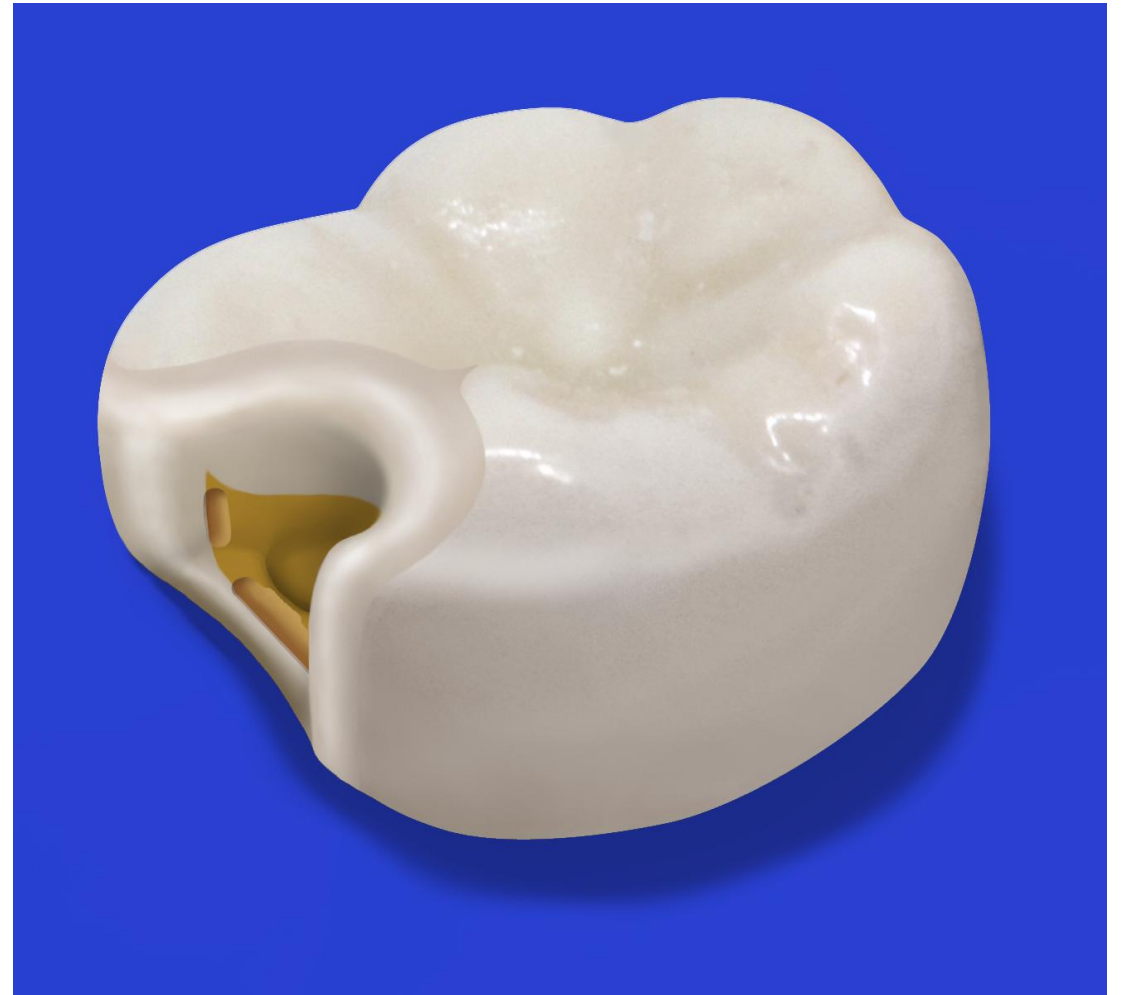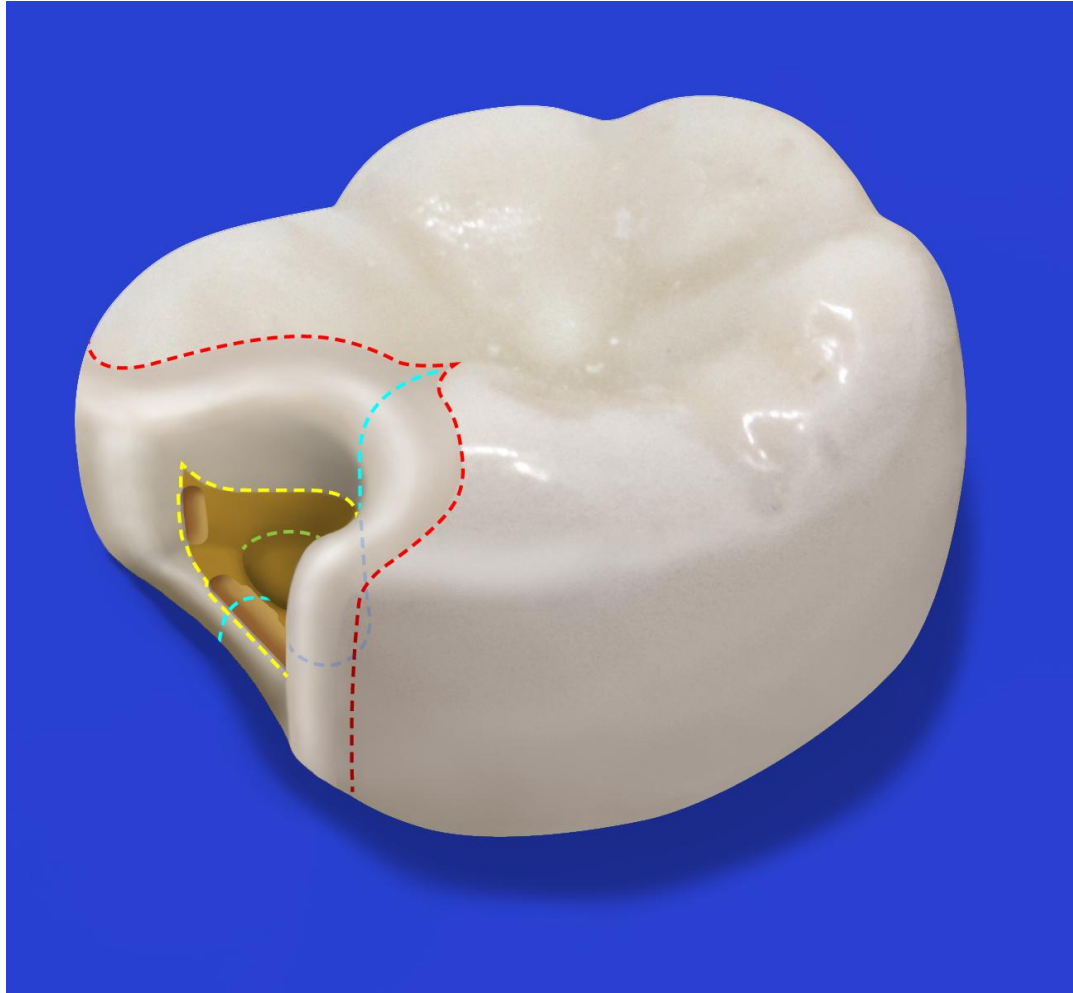
Simply: the narrower, the
boxier, and the longer the cut,
the worse the cut.

A microscopic image of a material surface, likely a metal or ceramic, showing a crack. The crack is a dark, irregular line running diagonally across the frame. The surface has a granular texture with various small features and imperfections. The lighting is bright, creating a strong contrast between the dark crack and the lighter surrounding material.

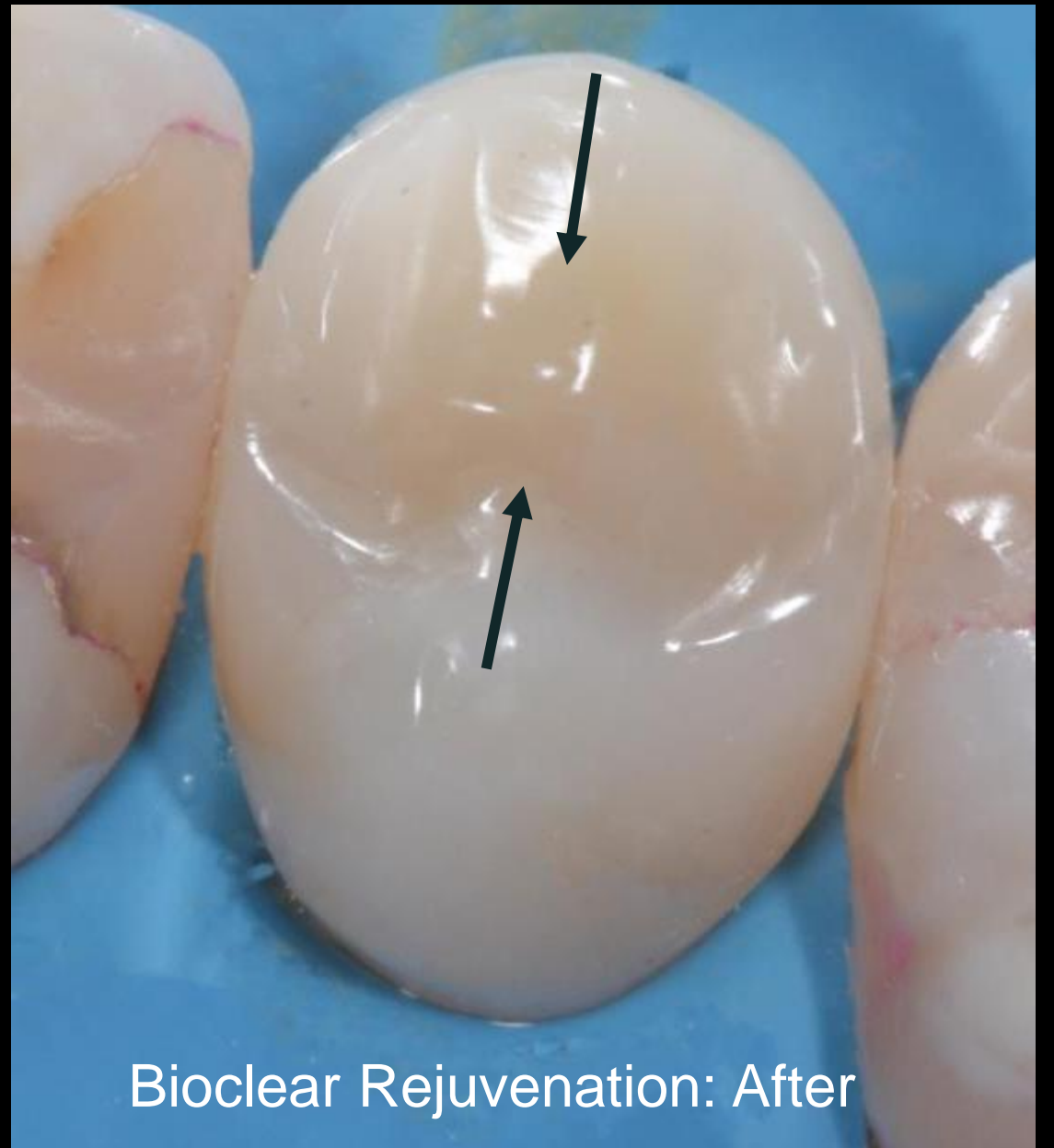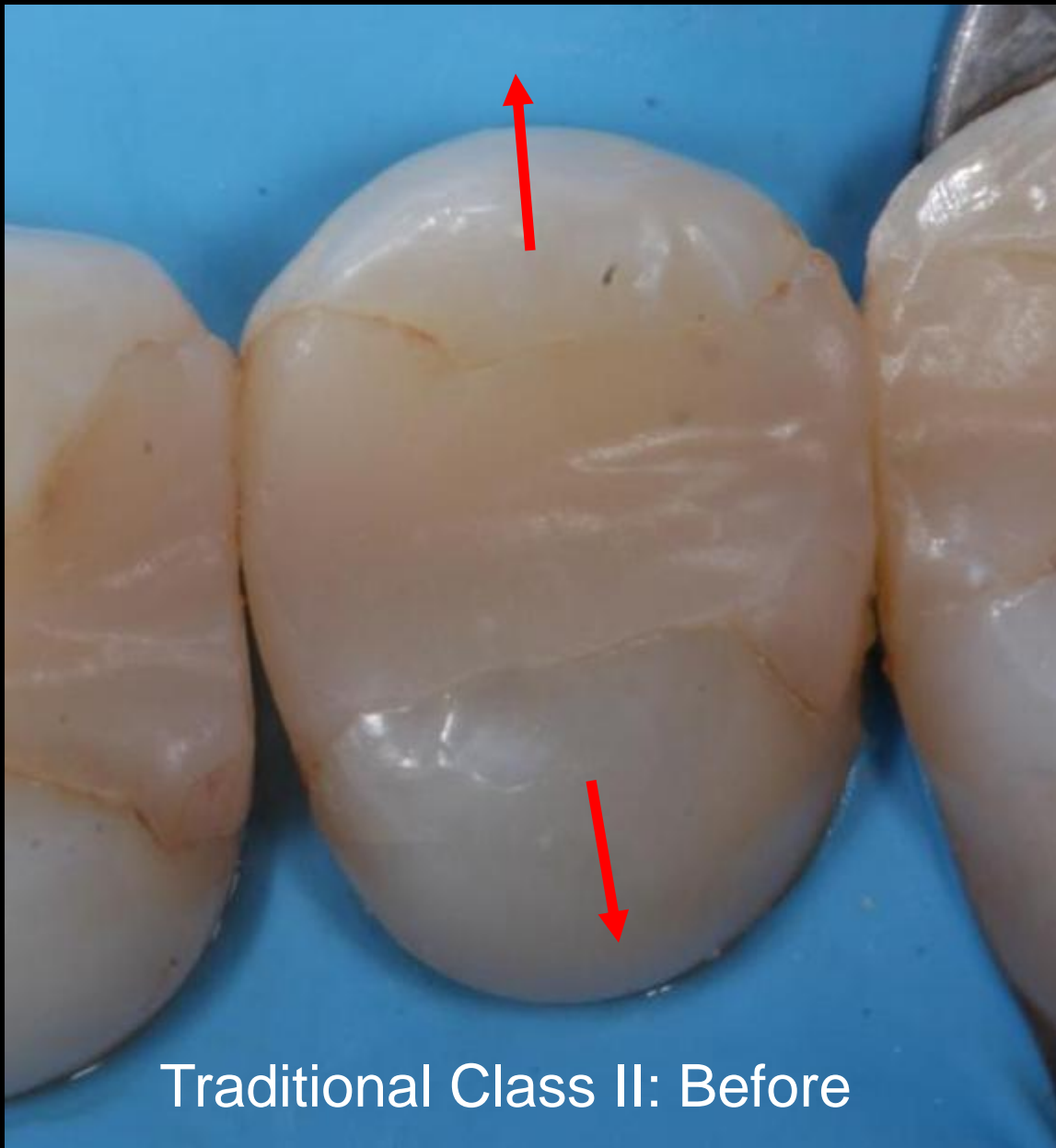Basic mechanical engineering principle:
The best way to delay crack propagation in a brittle material
is to mitigate a tension area with a compression joint.

And don't unnecessarily connect the dentinal dots

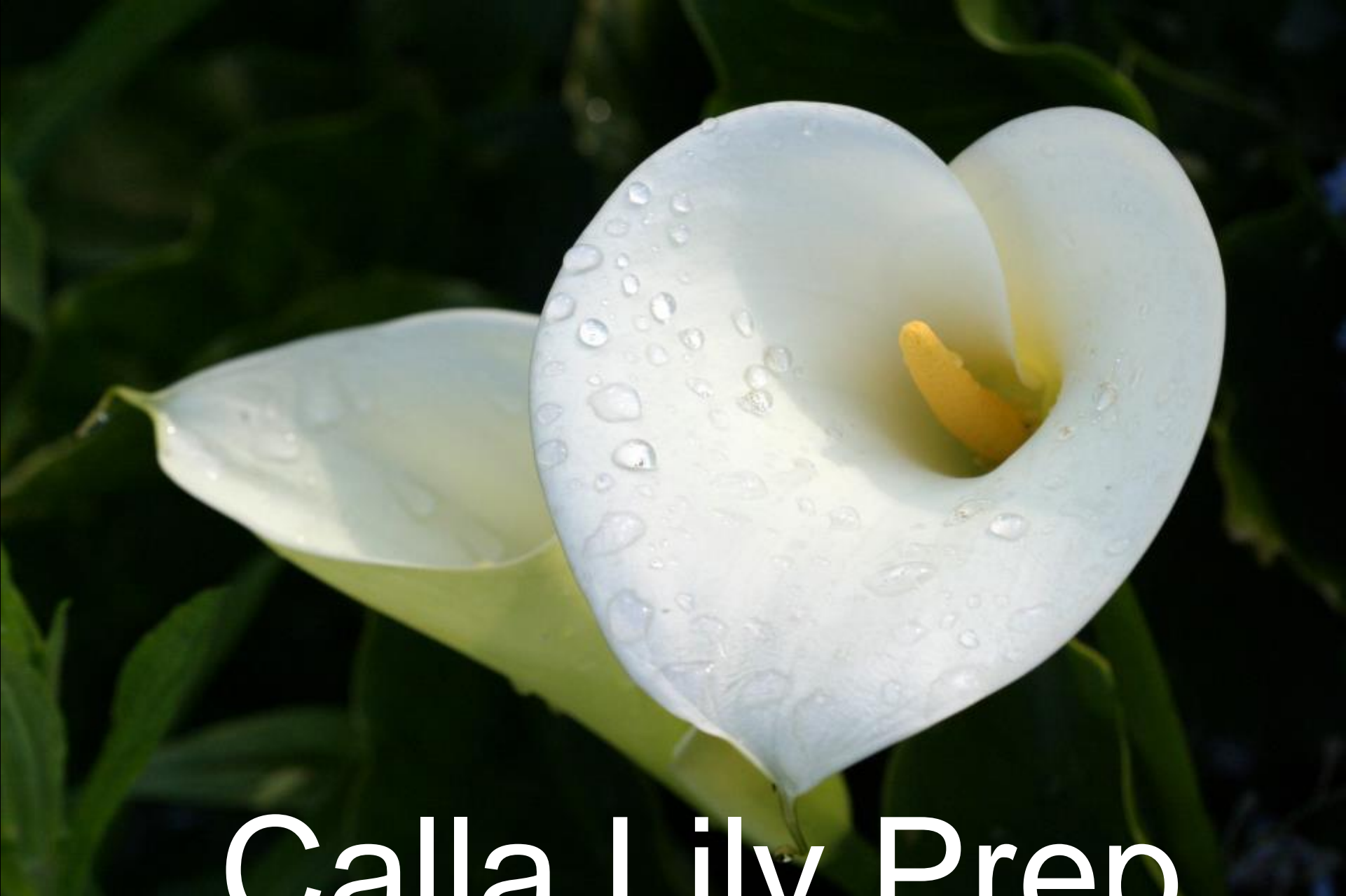Final views of completed Bioclear Class II Preparation.



Calla Lily Prep



Courtesy Dr. Charlie Regalado



Calla Lily Prep

Do you trust enamel bonding or **dentin bonding**?


Enamel



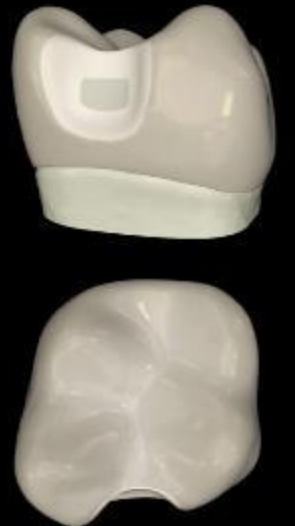Dentin



Enamel



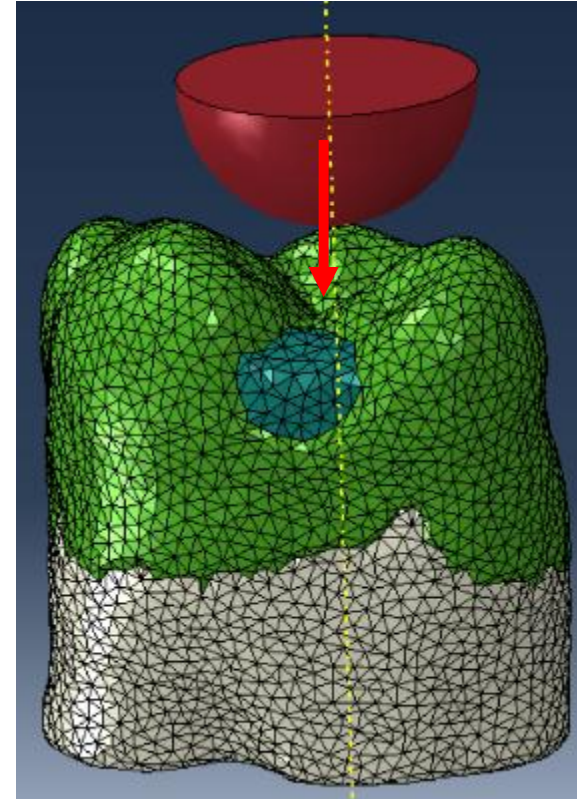
Dentin



2. Finite Element Analysis of Stresses in Restorations due to Occlusal Loading

Methods

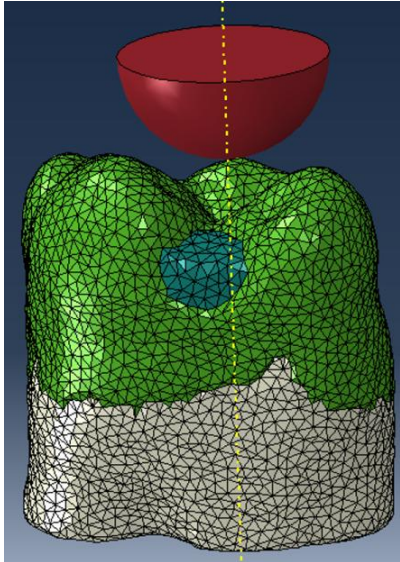
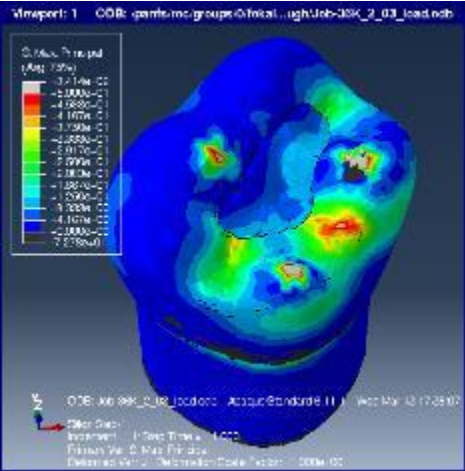
- Occlusal stress simulated by adding a hemisphere as an antagonist to the occlusal surface with downward vertical force (1000N) , resulting in three occlusal areas
- Principal stresses on the restorations and tooth were compared.



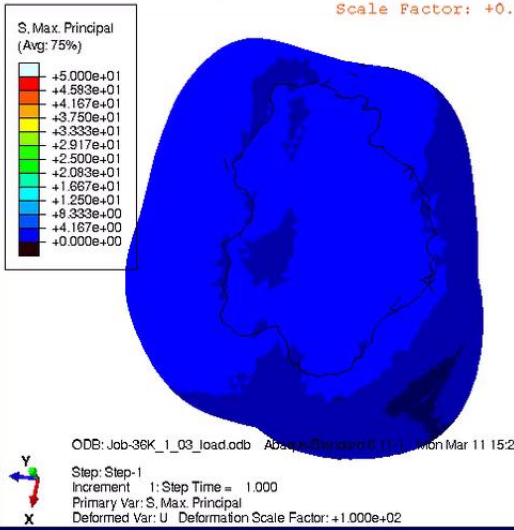
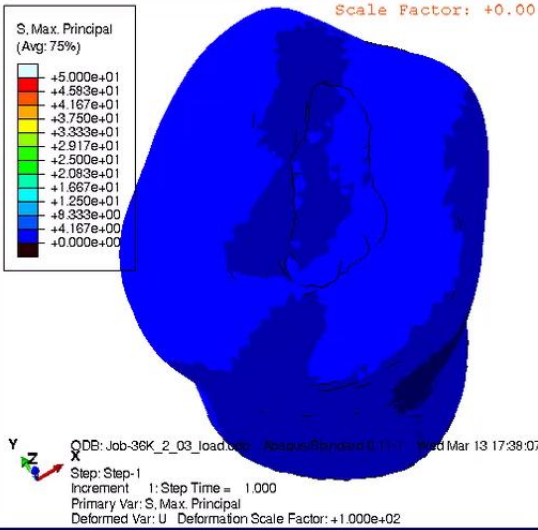
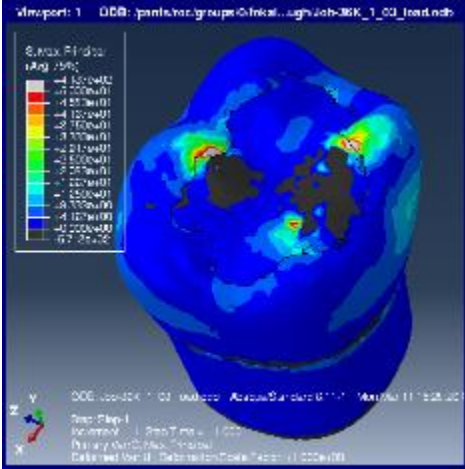
2. 3D Finite Element Analysis of Stresses in Class I Restorations due to Occlusal Loading

Max principal stress contours

Black



Clark



Studies Supporting the Bioclear Method

Complete

- Comparing Conventional to Saucer-Shaped Cavity Designs

Dr. Alex Fok, BEng, PhD, MSc

Dr. Hooi Pin Chew, BDS, PhD, FDSRCS

MN Dental Research Center for Biomaterials and Biomechanics

- Comparison of Class II Adaptation and Placement Times

Dr. Richard Price, BDS, DDS, MS, FDS RCS, FRCD(C), PhD

Dept. of Clinical Dental Sciences & Biomedical Engineering Dalhousie University

- Effect of Preheating/Fatiguing/Thermocycling on Mechanical Properties

Taiseer A. Sulaiman, DDS, PhD



Assistant professor, Division Director of Operative Dentistry and Biomaterials, UNC School of Dentistry

- 3M Extraction and Pulp Temperature Testing

Brad Bagley, PhD, DABT Advanced Toxicology Specialist

- 3M Material Property Testing Including Injection Molding

Timothy D. Dunbar, Ph.D. Advanced Product Development Specialist



In Process

- Biofilm Adhesion Study

Sabrina F. Sochacki, DDS, MS, PhD

Indiana University School of Dentistry

Preliminary Mechanical Assessments of the Bioclear Method

Ning Ye BSc, MS

Hooi Pin Chew BDS, FDSRCS, PhD

Alex Fok PhD

Minnesota Research Center for Biomaterials and Biomechanics

Disclosure: This study was funded by 3M



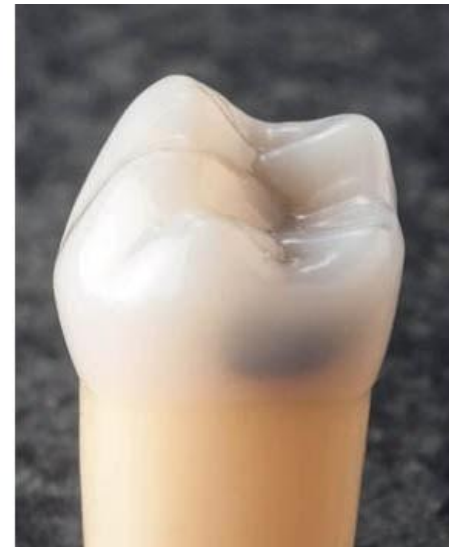UNIVERSITY OF MINNESOTA

Driven to Discover®

Assessments

1. Finite Element Analysis of Shrinkage Stress
2. Finite Element Analysis of Stresses in Restorations due to Occlusal Loading

Typodonts with simulated enamel layer, dentine layer and MOD caries were used.

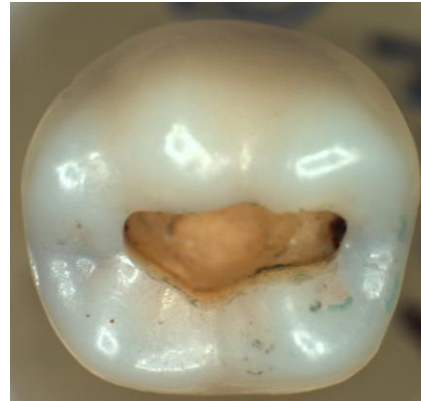


Methods

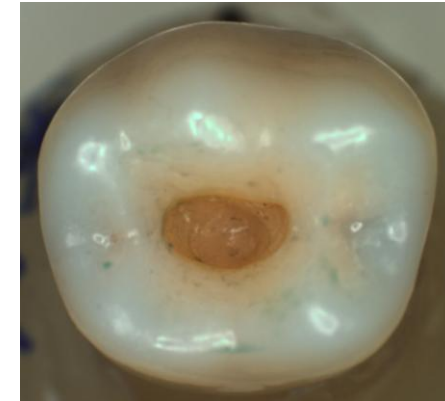
Five Cavity Designs

2 Class I s

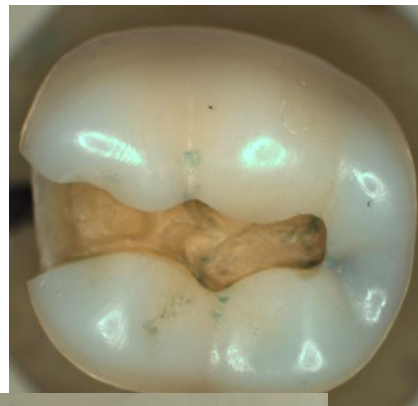
Black Class I



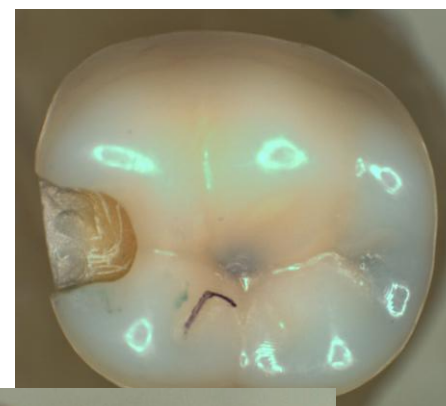
Clark Class I



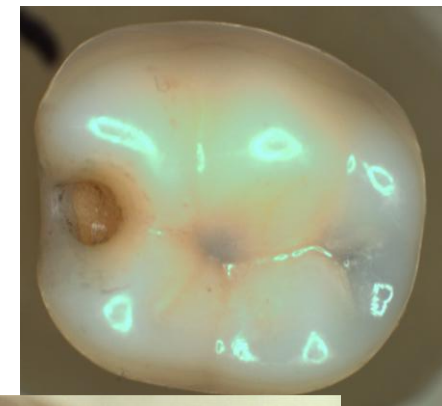
Black Class II



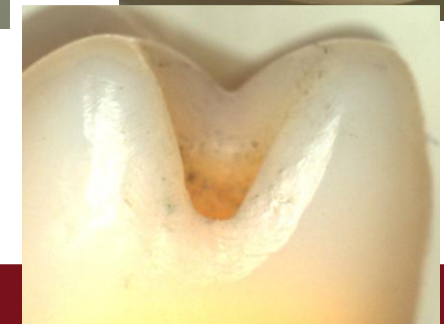
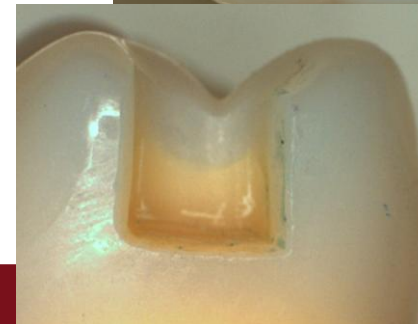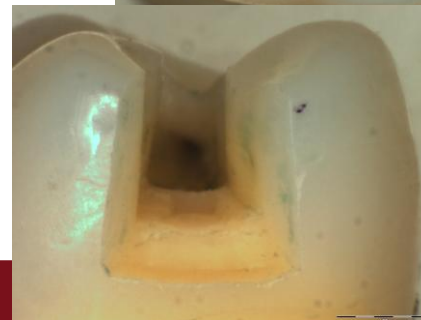
Slot Class II



Clark Class II

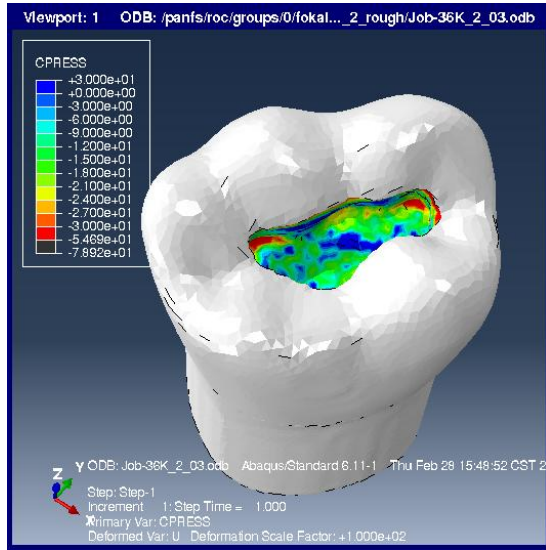


3 Class II s

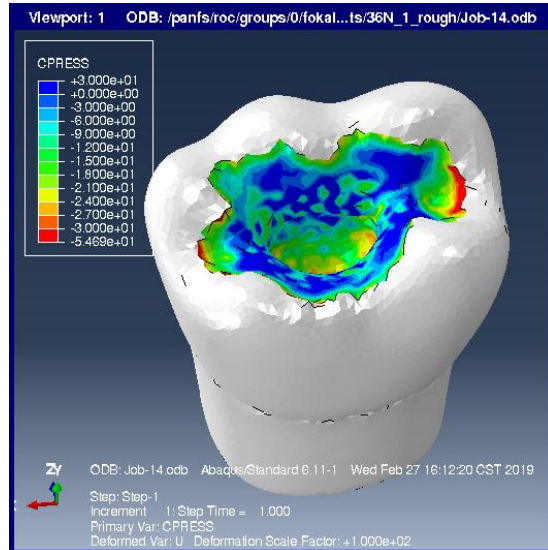


1. 3D Finite Element Analysis of Shrinkage Stress in Class I restorations

Interfacial shrinkage stress contours

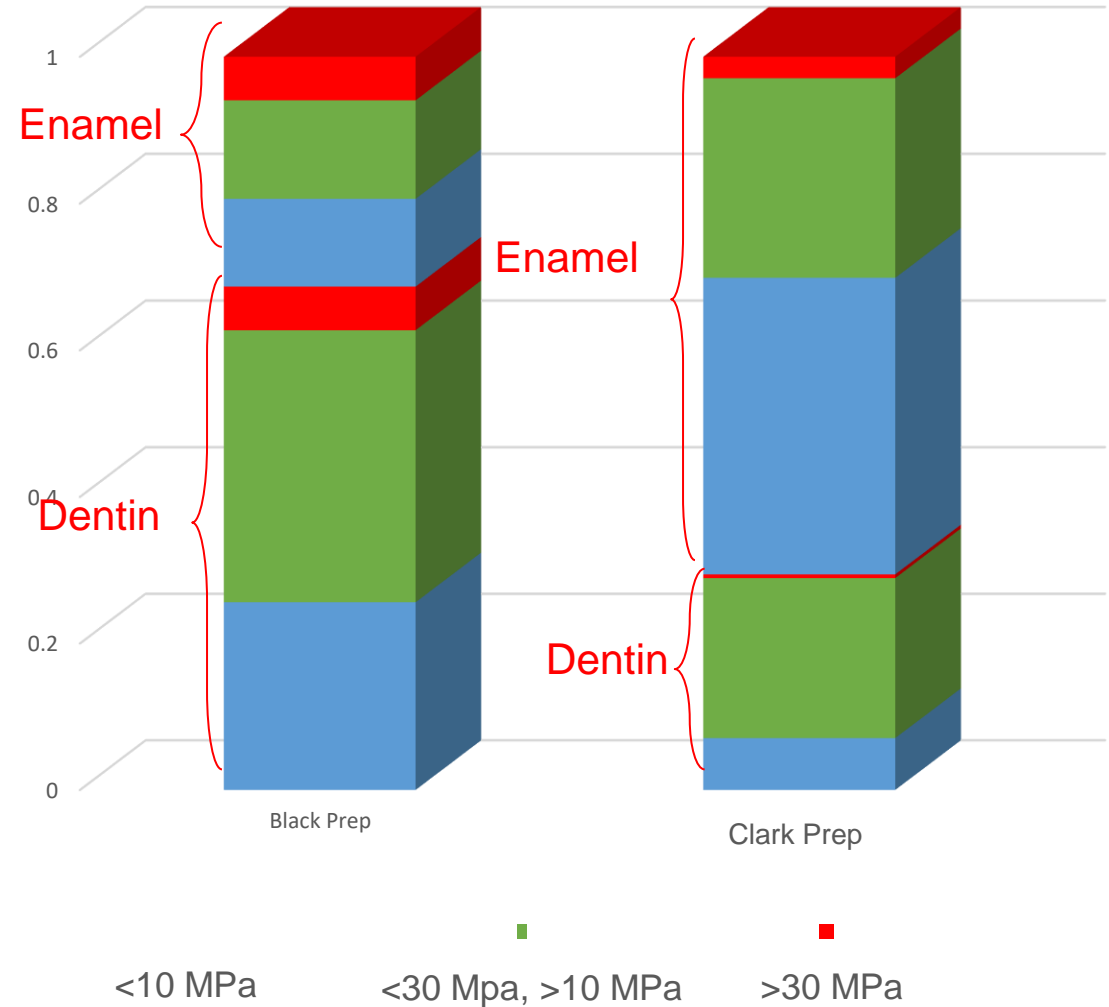


Black

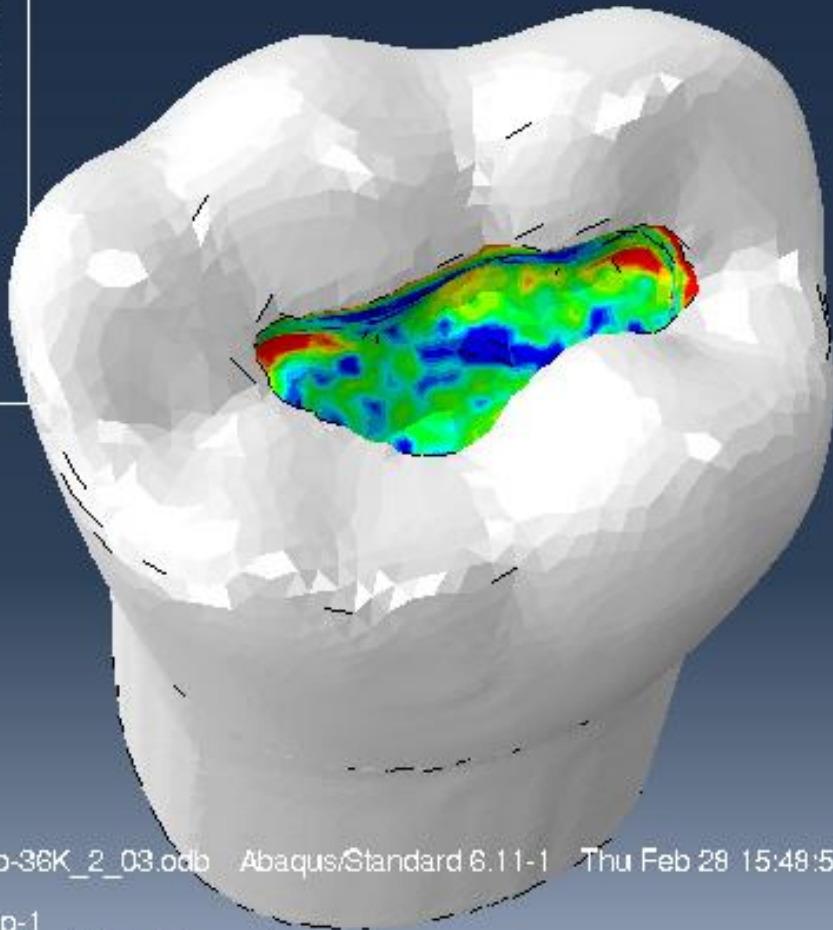
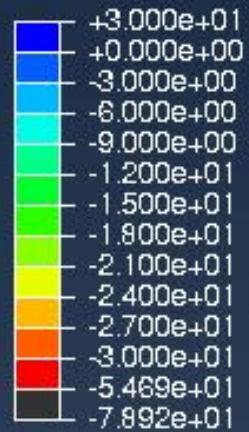

Clark

Distribution of normal stress over interfacial area



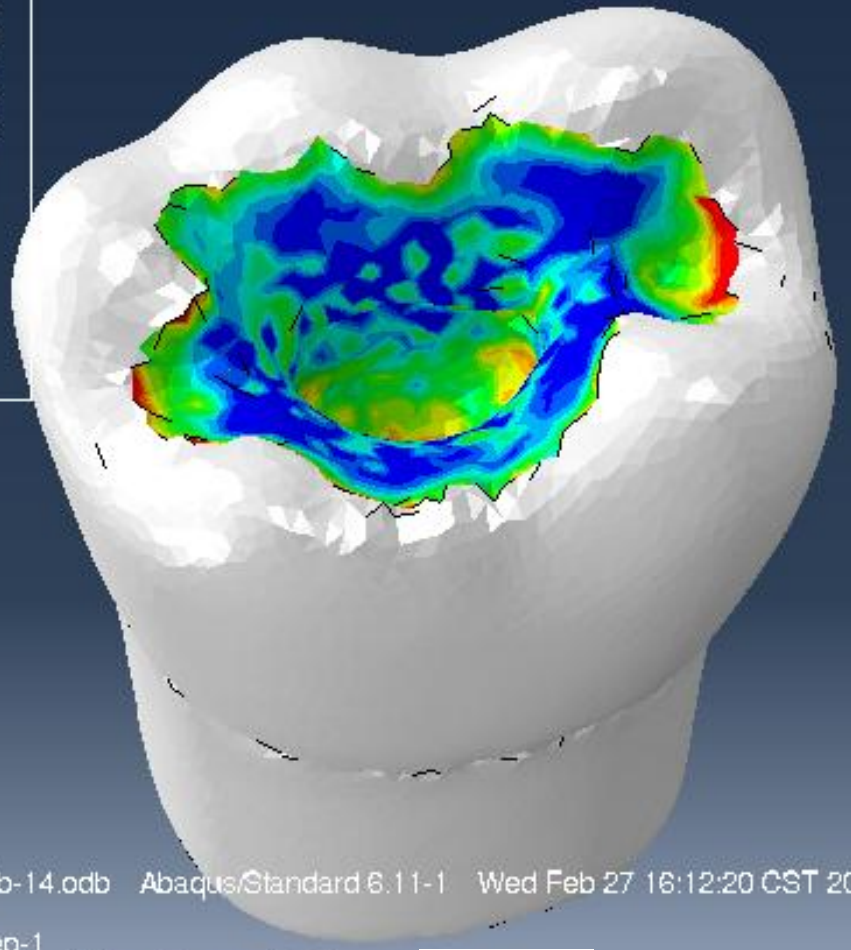
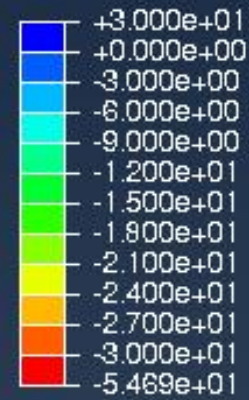
CPRESS



Y ODB: Job-36K_2_03.odb Abaqus/Standard 6.11-1 Thu Feb 28 15:48:52 CST 2019

Step: Step-1
 Increment 1: Step Time = 1.000
 Primary Var: CPRESS
 Deformed Var: U Deformation Scale Factor: +1.000e+02

CPRESS



Zy ODB: Job-14.odb Abaqus/Standard 6.11-1 Wed Feb 27 16:12:20 CST 2019

Step: Step-1
 Increment 1: Step Time = 1.000
 Primary Var: CPRESS
 Deformed Var: U Deformation Scale Factor: +1.000e+02

Clark Prep

<10 MPa

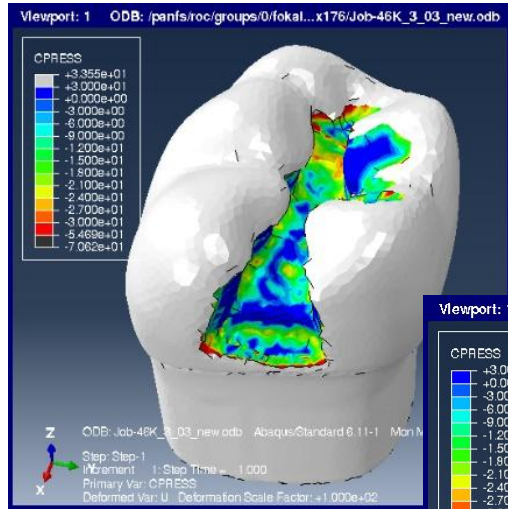
<30 Mpa, >10 MPa

>30 MPa

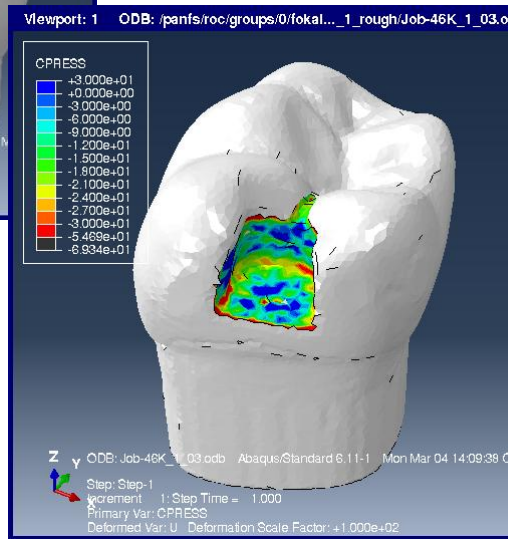


1. 3D Finite Element Analysis of Shrinkage Stress in Class II restorations

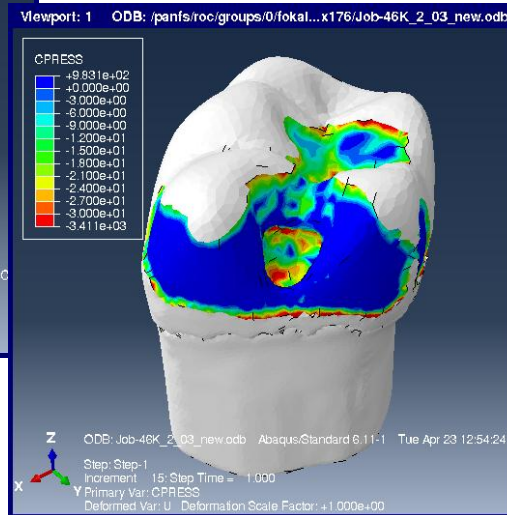
Interfacial shrinkage stress contours



Black

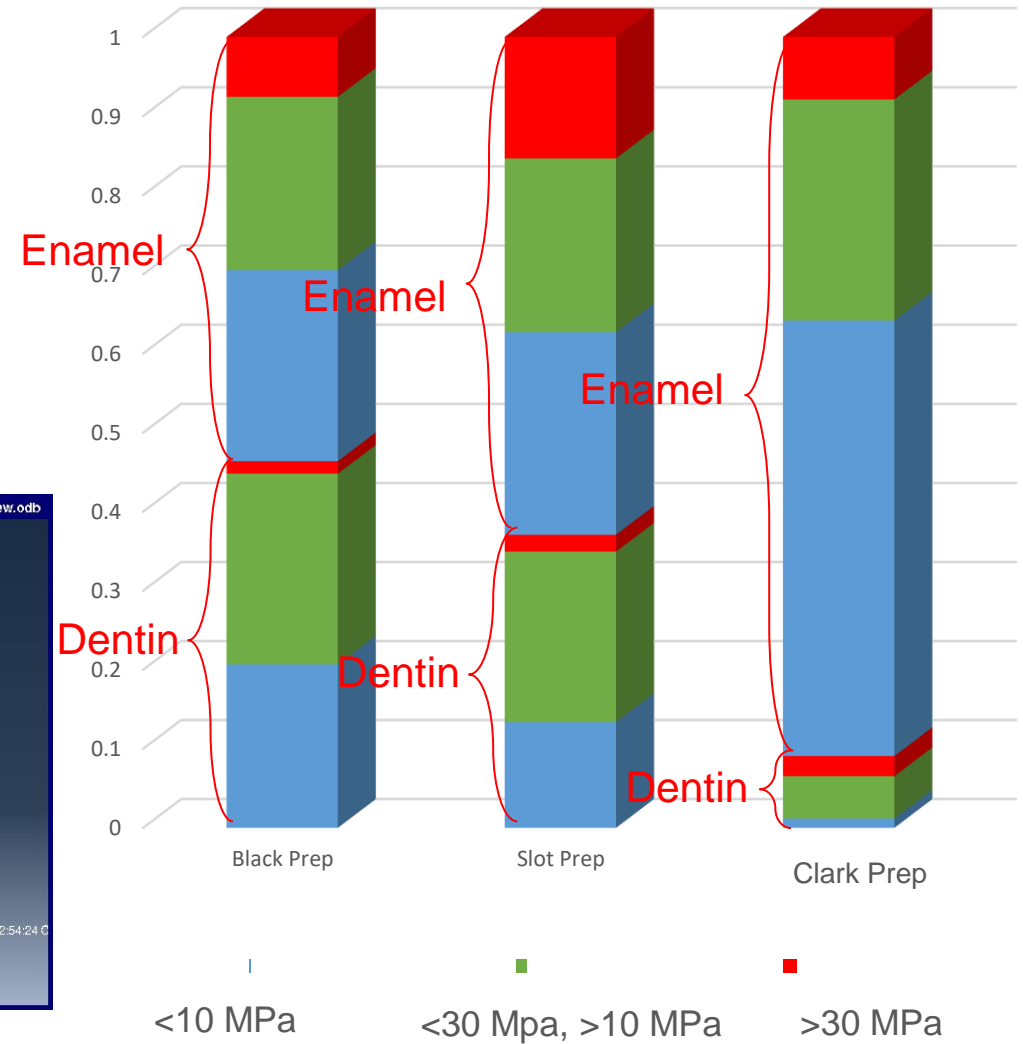


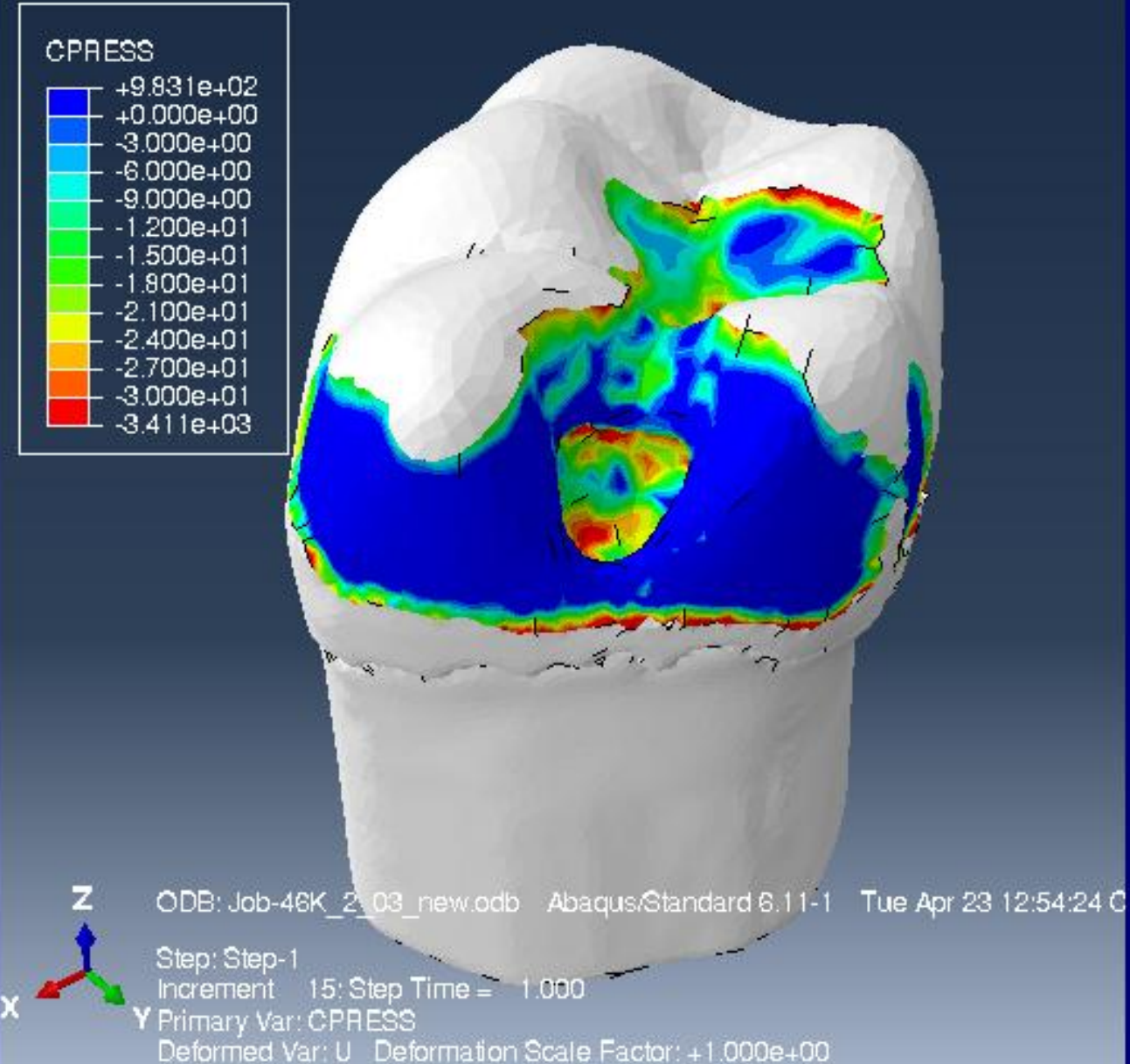
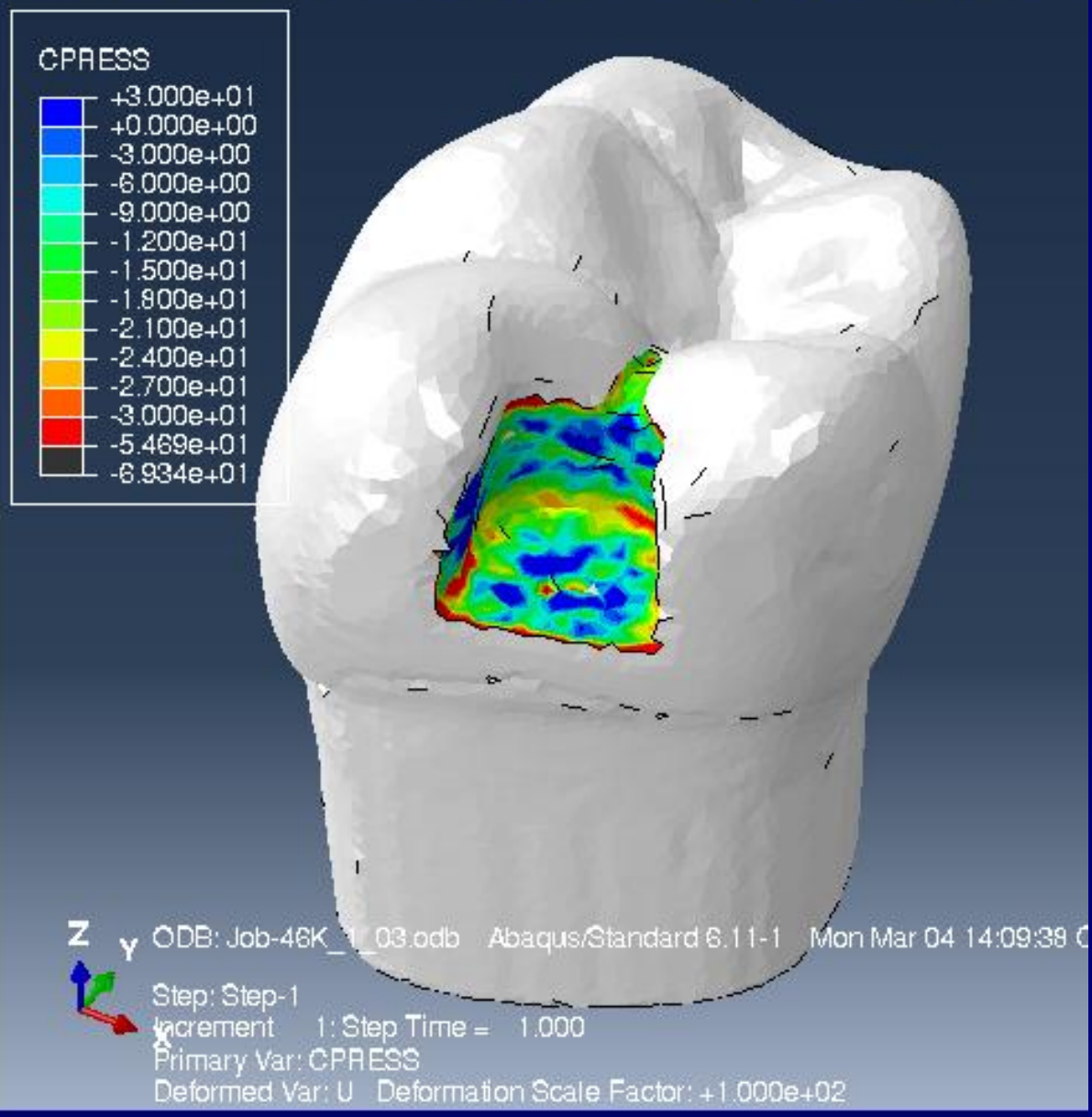
Slot



Clark

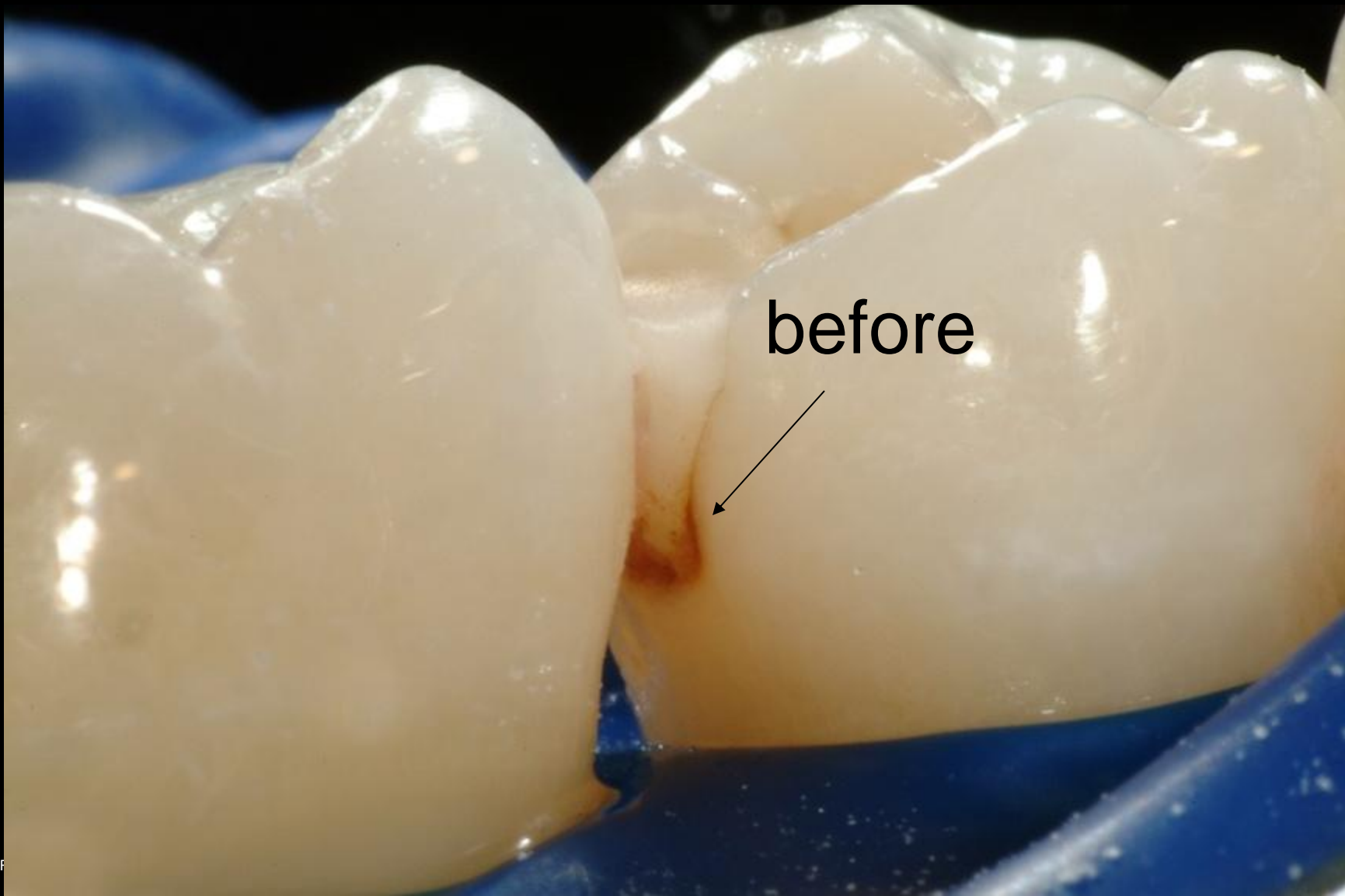Distribution of normal stress over interfacial area

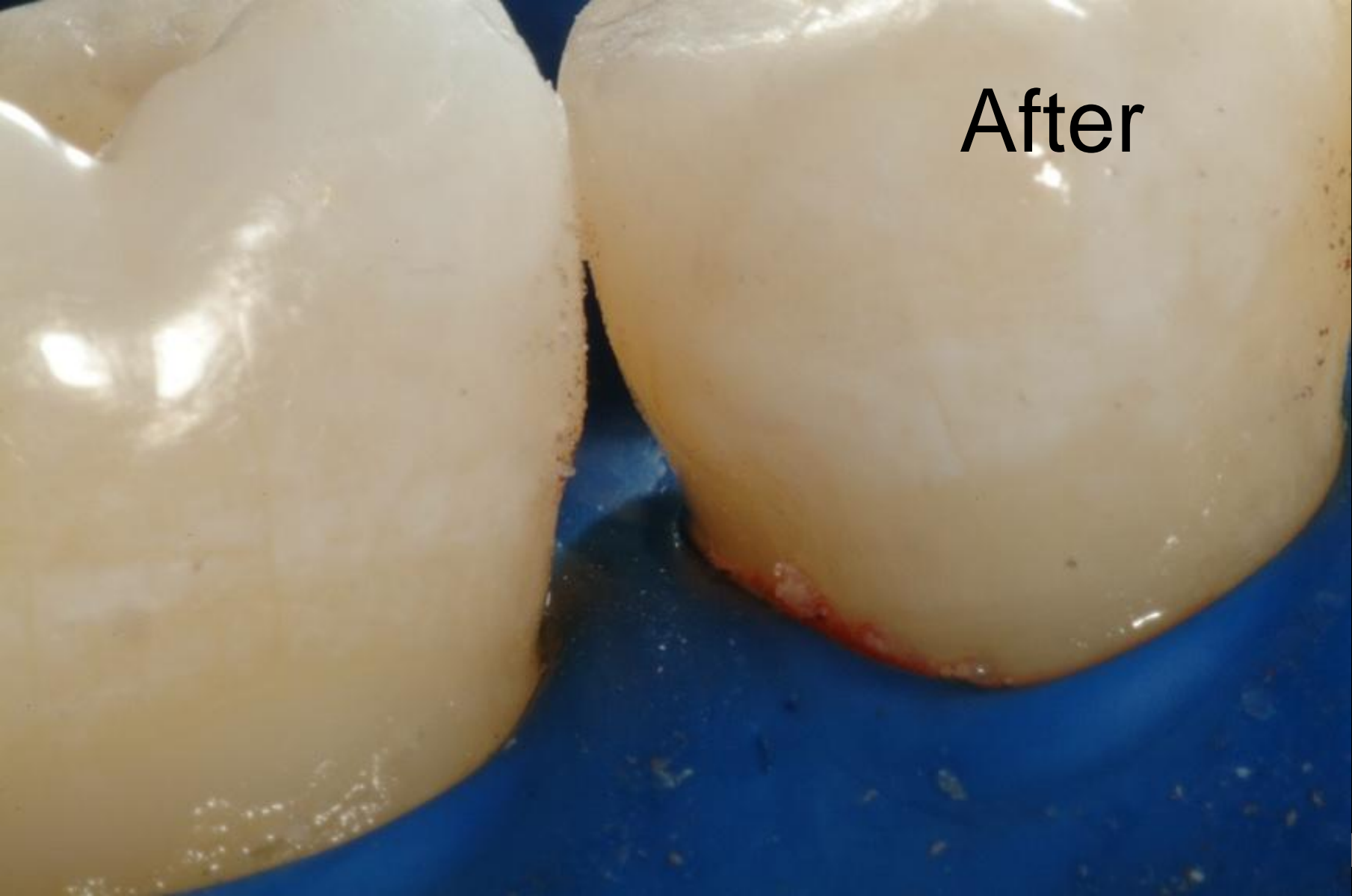



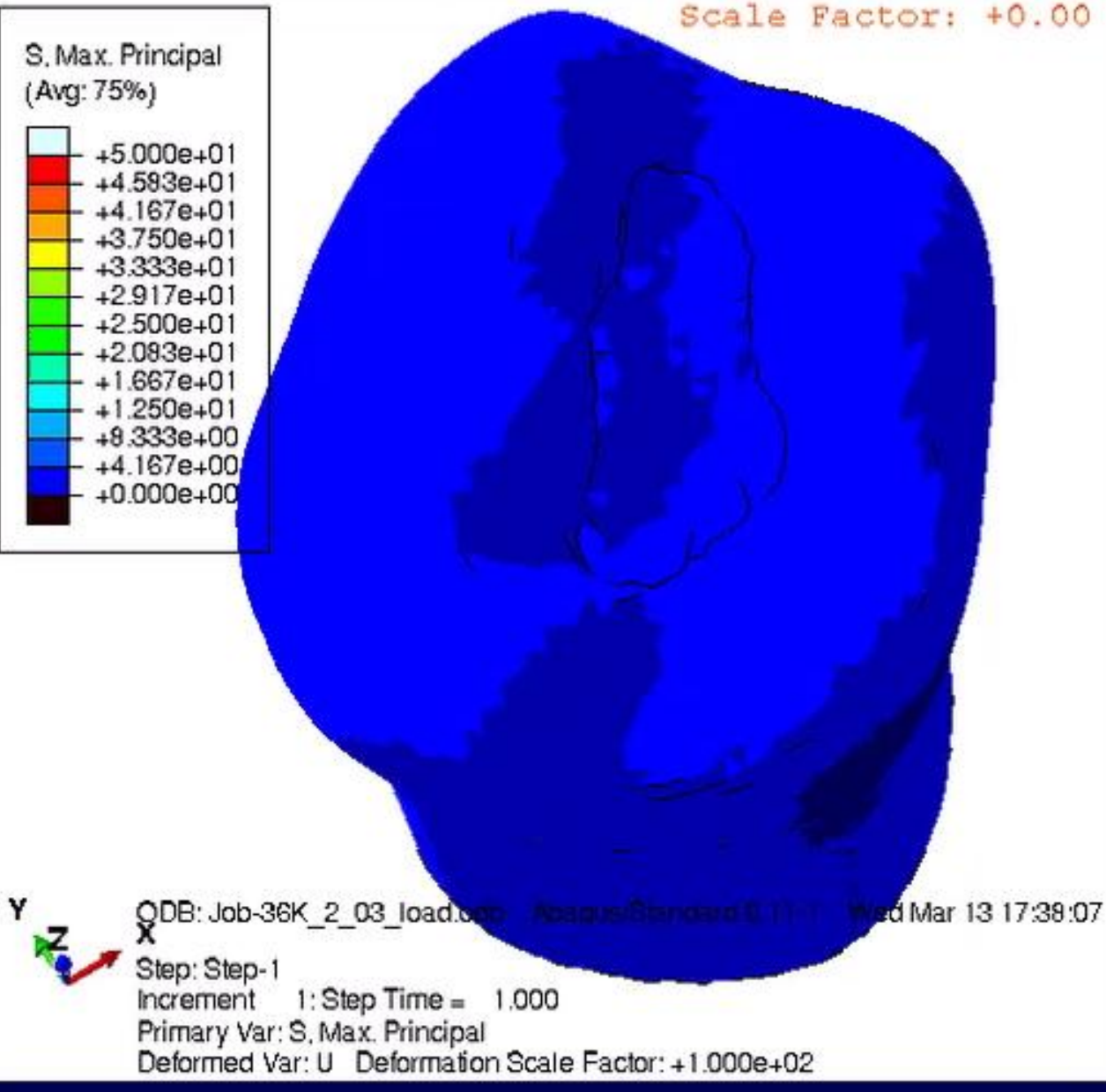
Clark



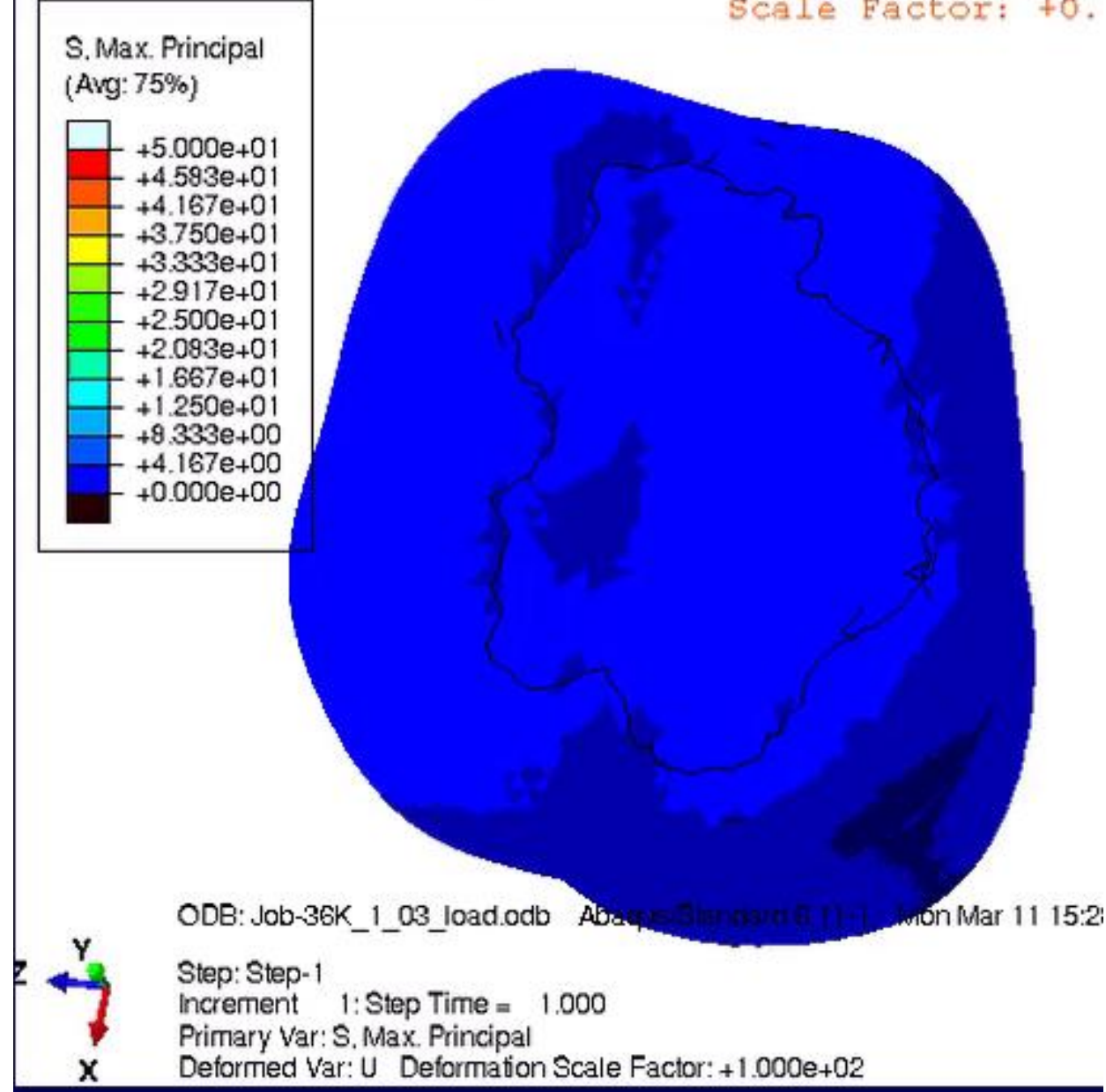




After



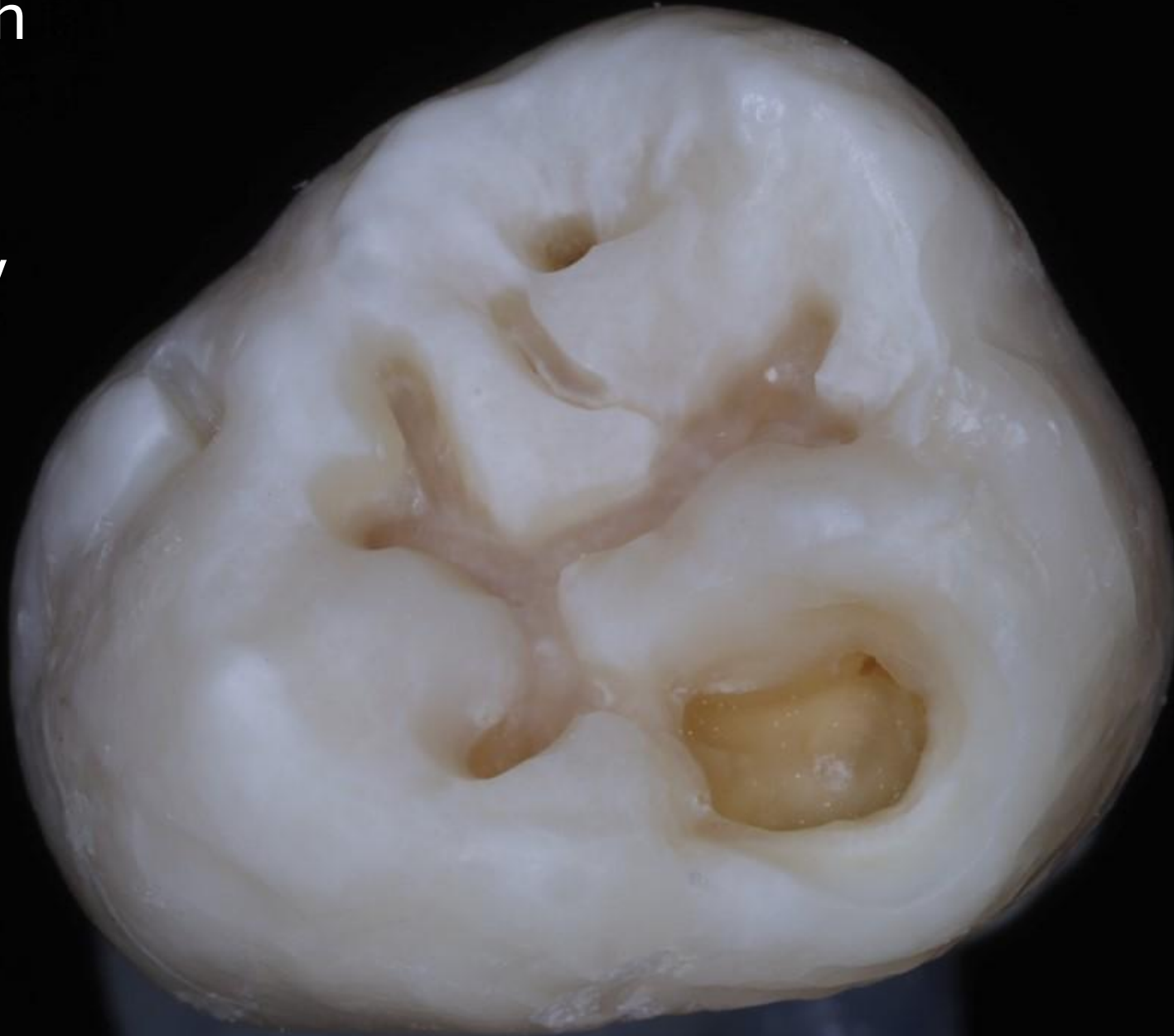Black



Clark



Prep cut with
the Narrow
Calla Lily
Fissurotomy
carbide bur,
which is my
“go to” CLF
bur



Courtesy Dr.
Joshua Solomon

Modern Restoration
Design=**I.C.E.**

Infinity edge

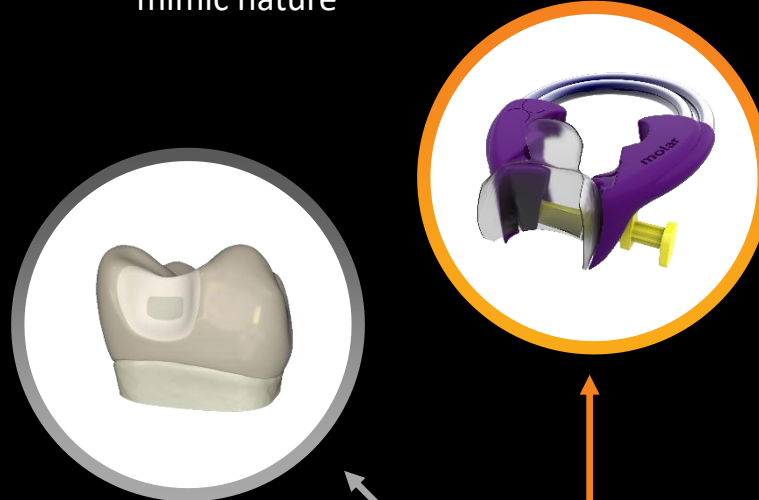
Compression based

Enamel driven

Modern Method for Composite Restorations

Clear Anatomic Matrices

- Anterior & Posterior Matrices designed to mimic nature



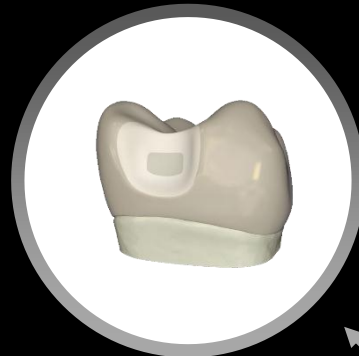Injection Mold Composite

- Injection mold warmed Restorative materials
- Industry leading polish, esthetic, strength & wear



Preparation Design

- Designed for composite
- Minimizes stress concentration
- Maximizes enamel involvement



Biofilm Removal

- Remove biofilm before bonding
- Allows bonding to uncut enamel
- Allows infinity edge margins



Systematic restorative protocol for esthetic long-term clinical outcomes

Final Polish

- 3M™ Sof-Lex™ XT coarse discs for reduction
- “Rock Star” polish with Bioclear Magic Mix & RS Polisher

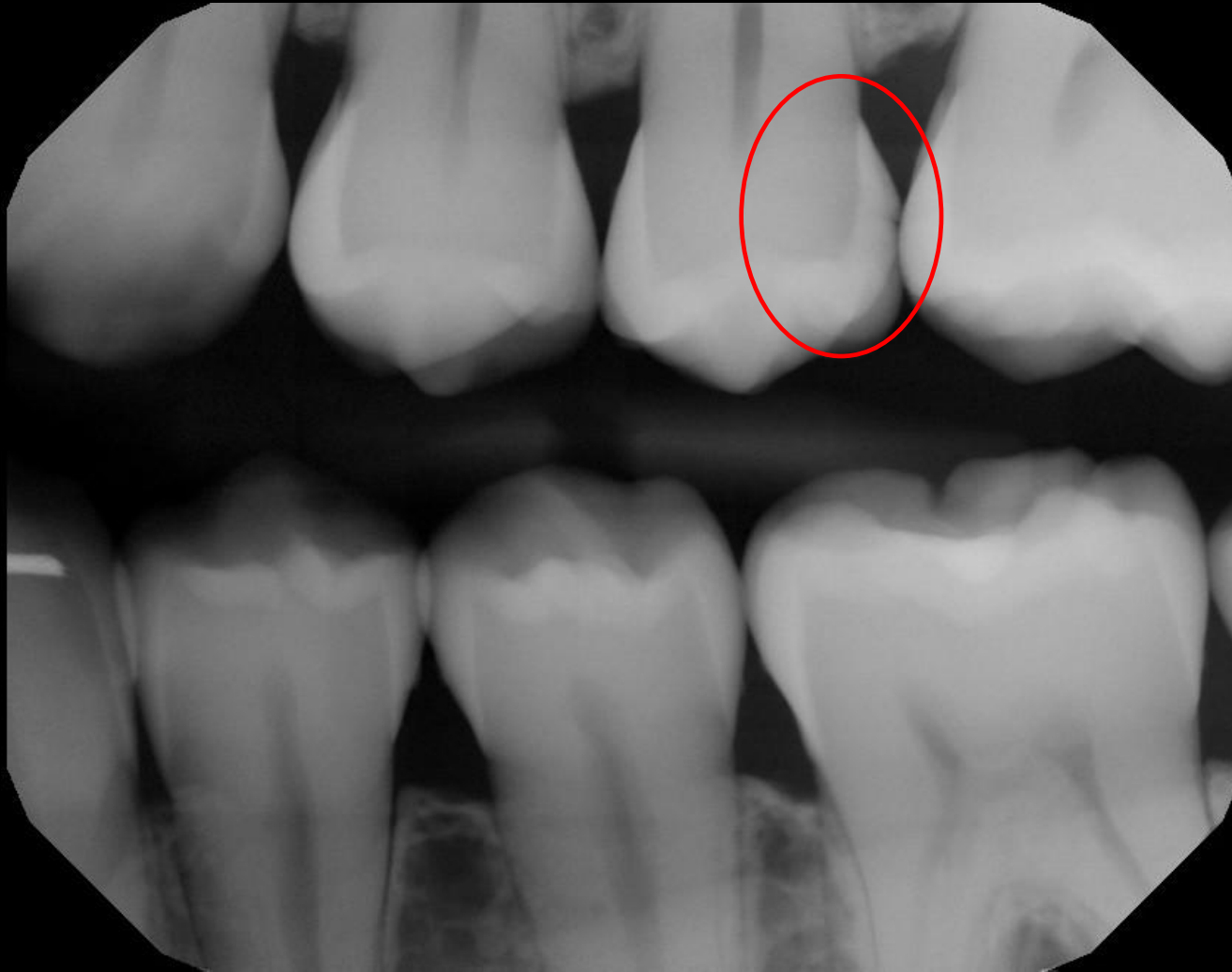

Class II Clinical Case



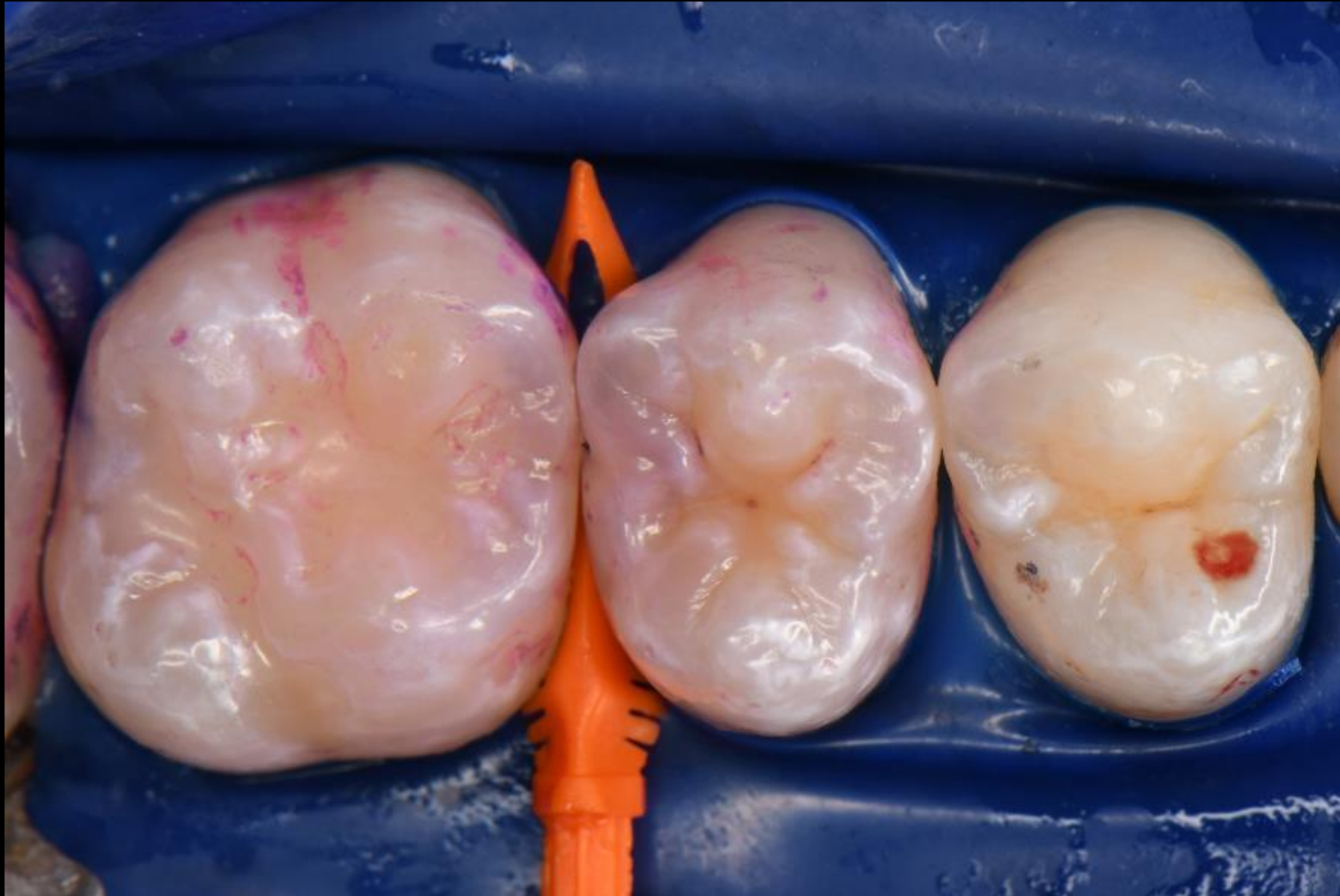
Pre-Operative Bitewing

∞ BIOCLEAR



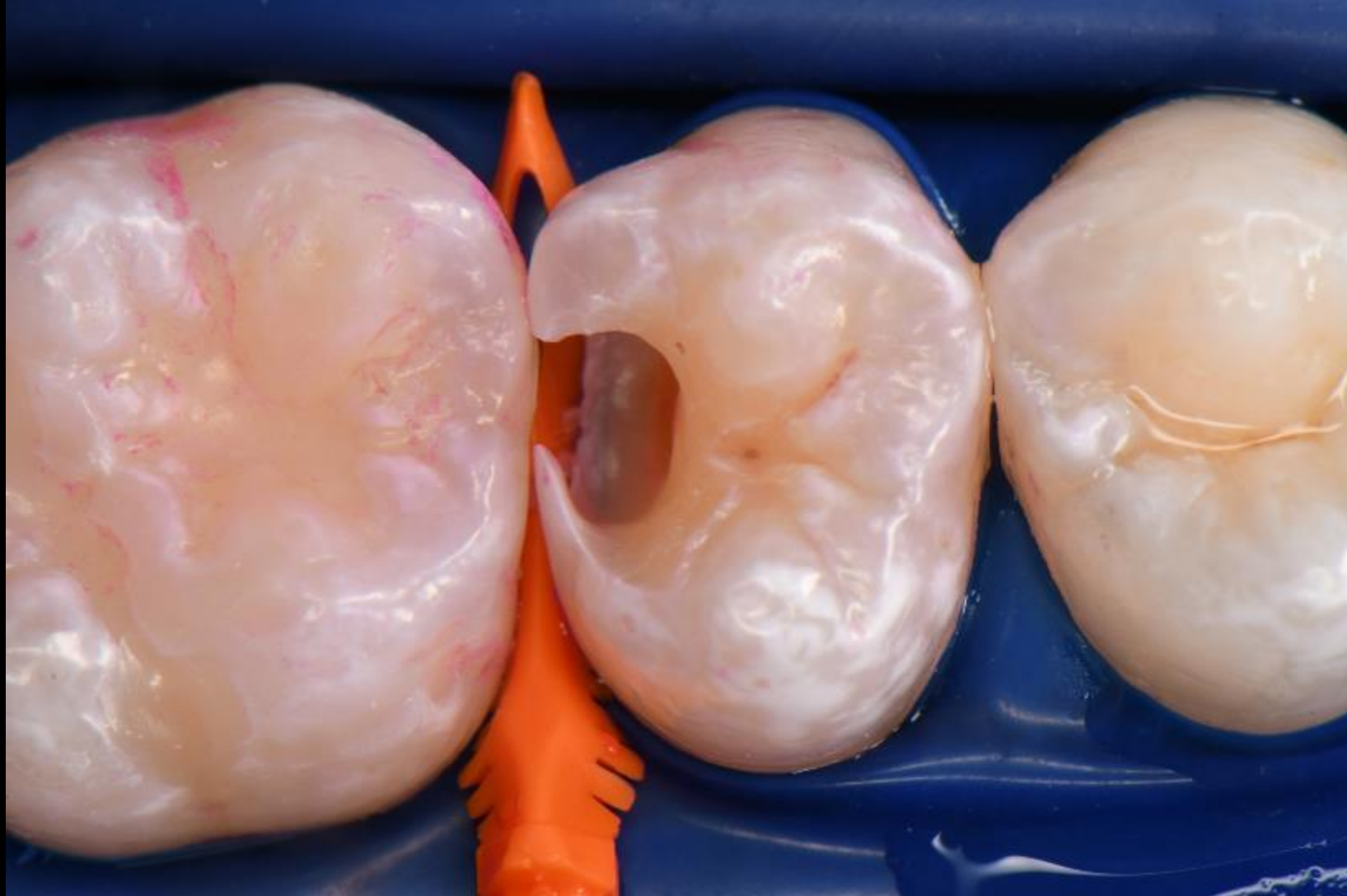Disclose and Pre-Wedge

∞ BIOCLEAR



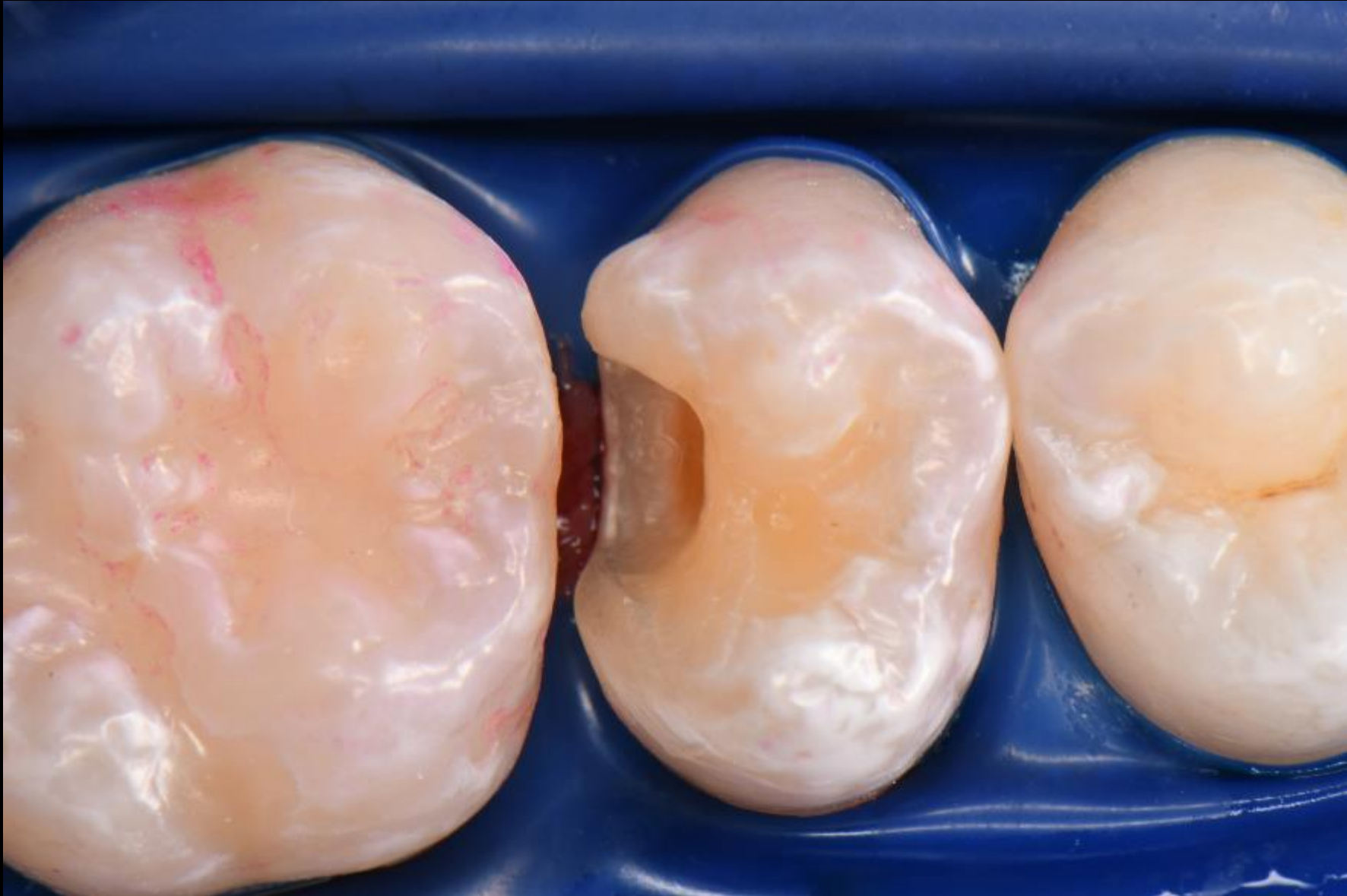Initial Preparation And Pre-wedge

∞ BIOCLEAR



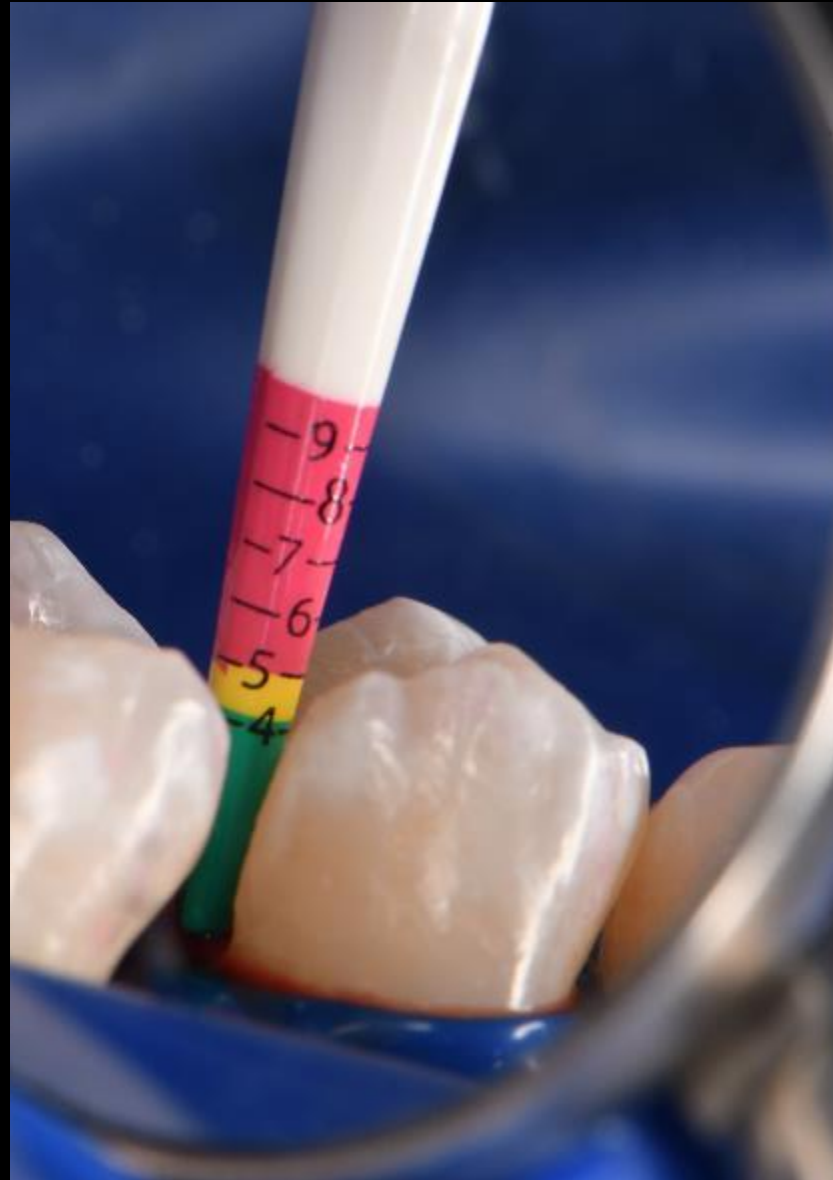Finished and Blasted Preparation

∞ BIOCLEAR



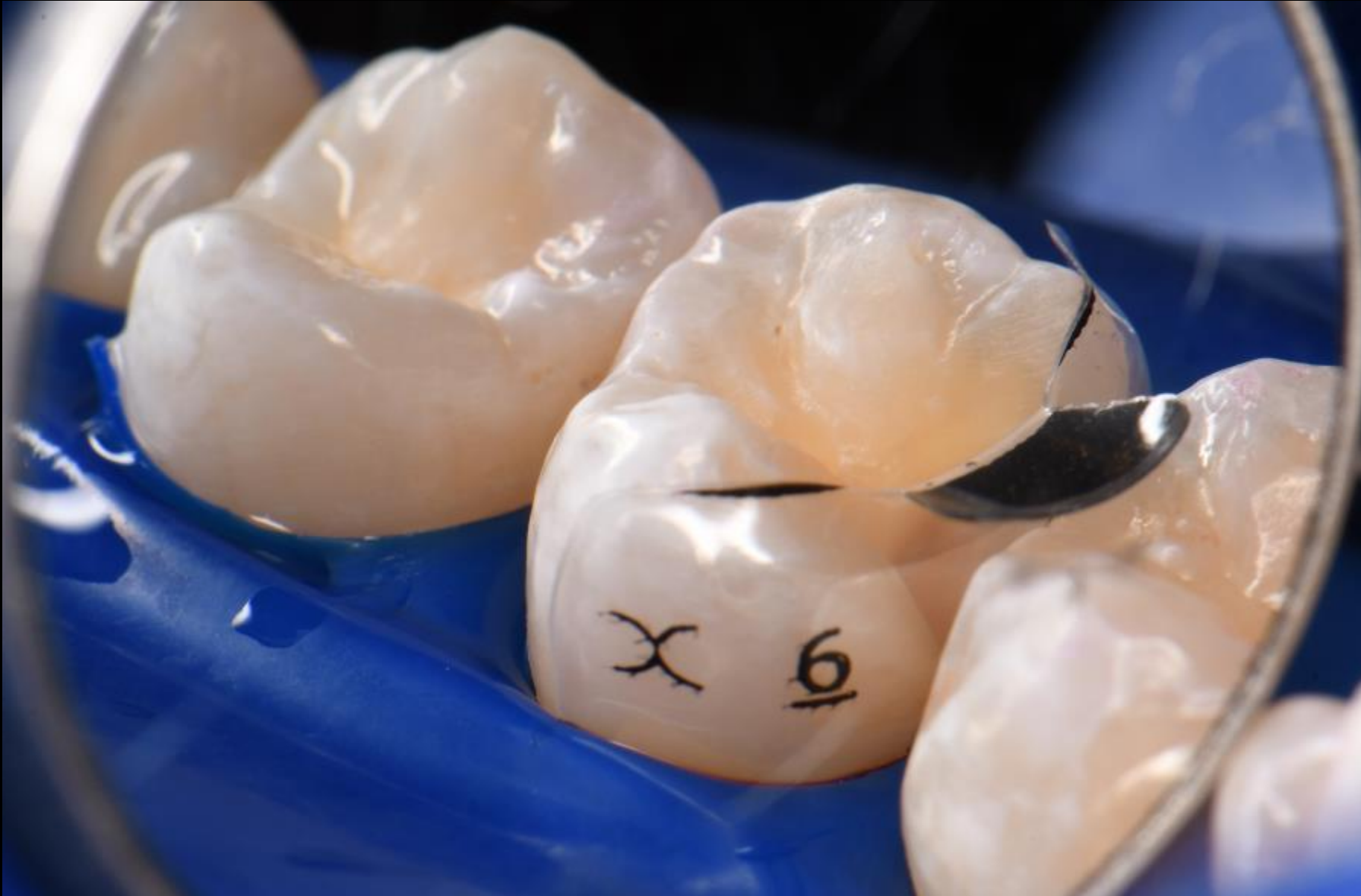Matrix Height Indicator Go/No Go Gauge

∞ BIOCLEAR



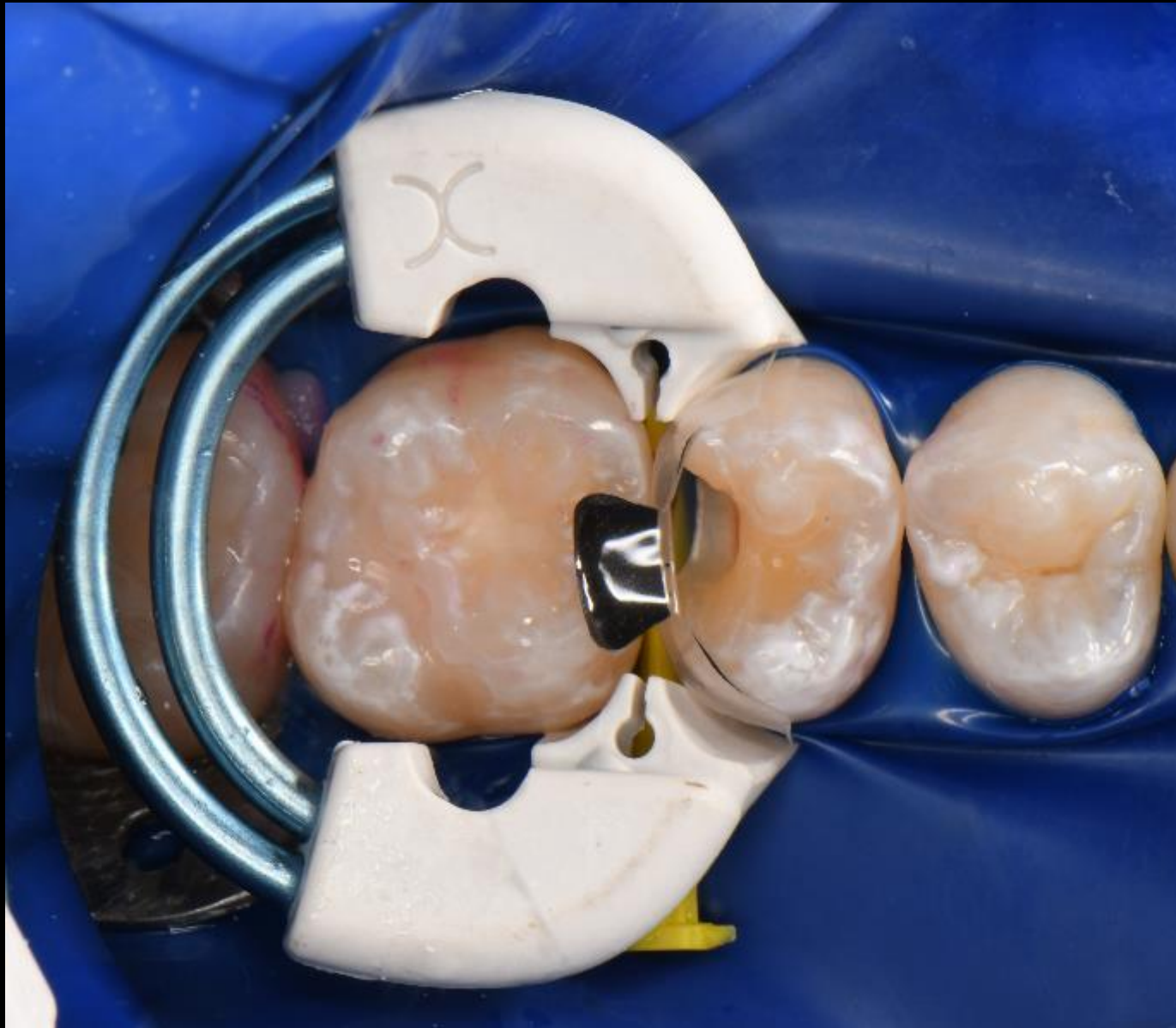
3D Anatomic Evolve Premolar Matrix

∞ BIOCLEAR



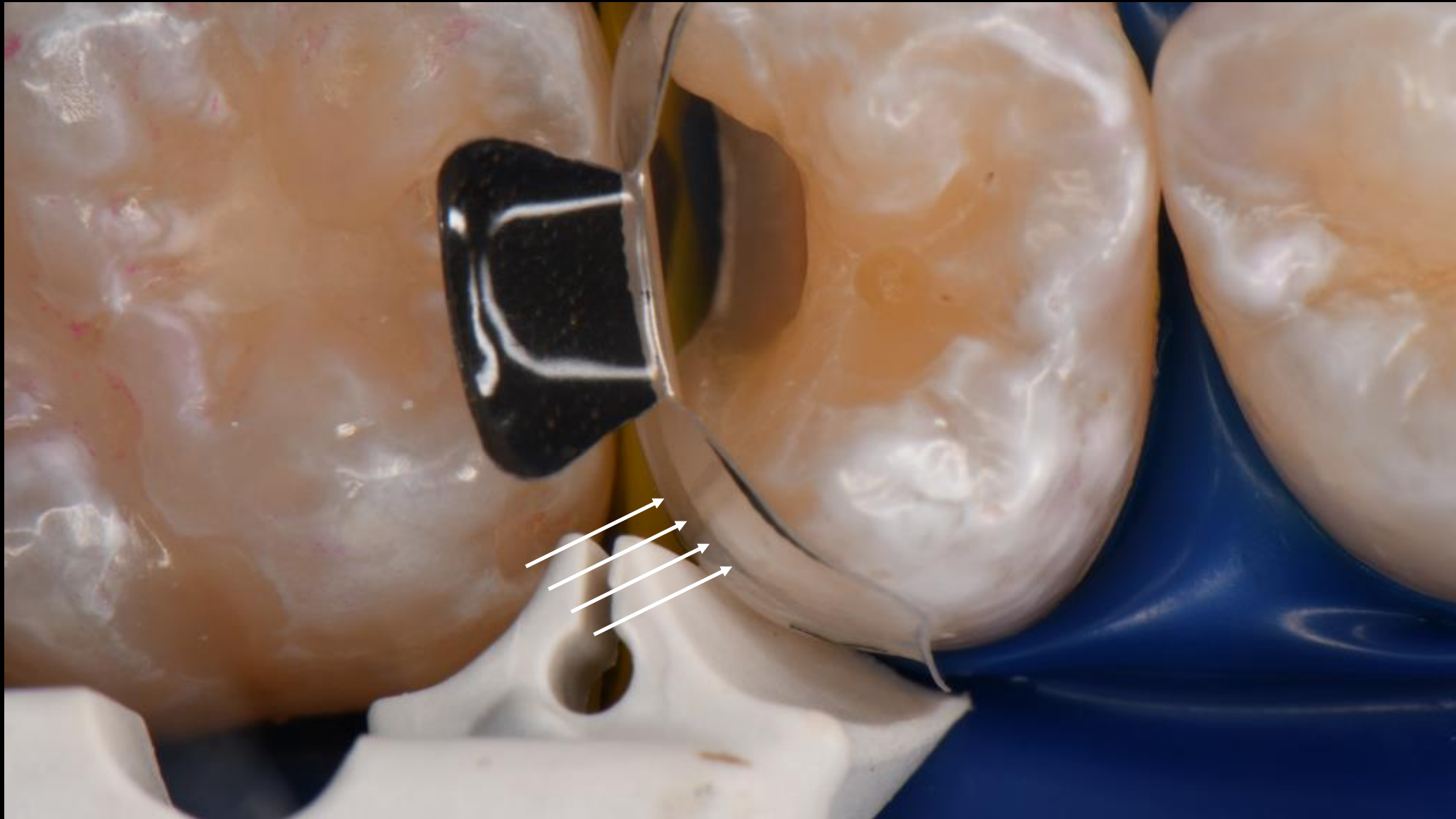
Evolve Matrix, Large Diamond Wedge, TwinRing Universal

∞ BIOCLEAR



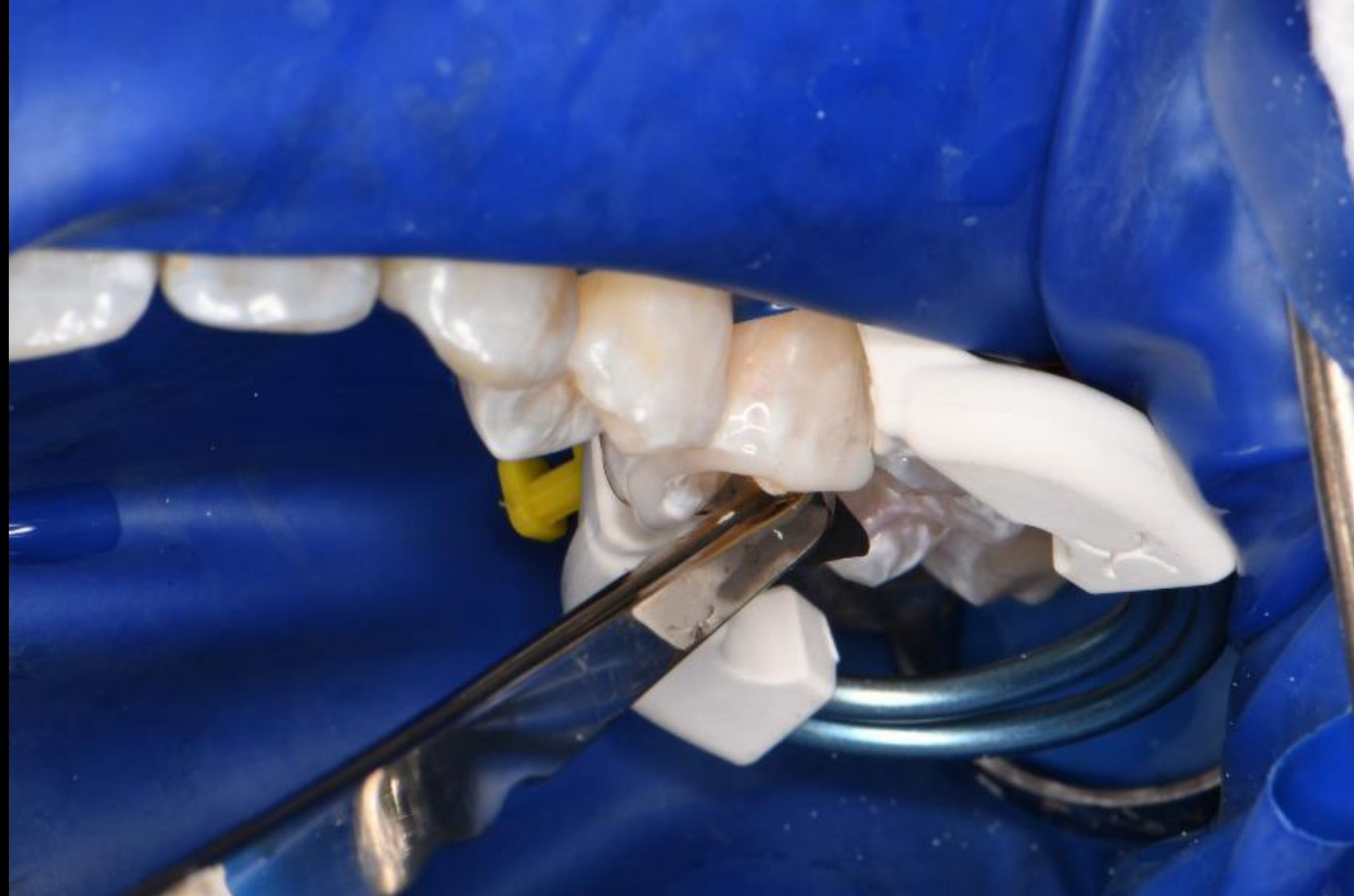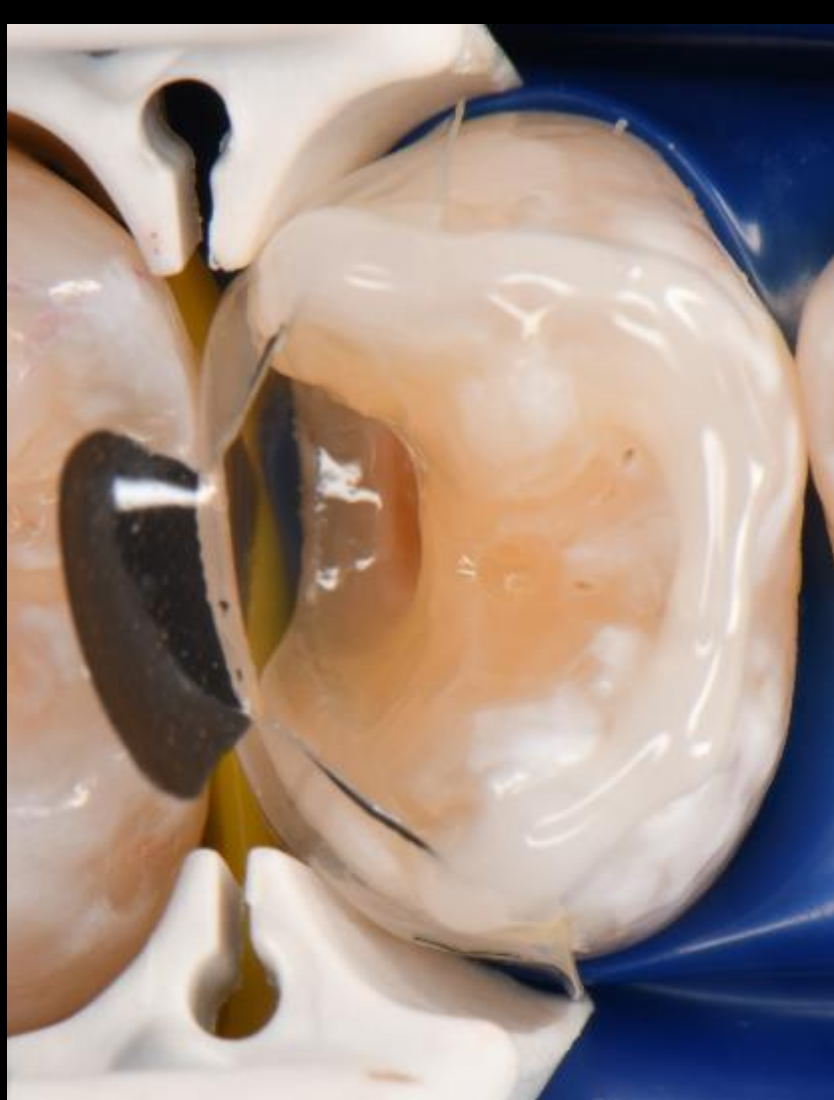
Note the Infinity Edge Zone Allowed by the System

∞ BIOCLEAR



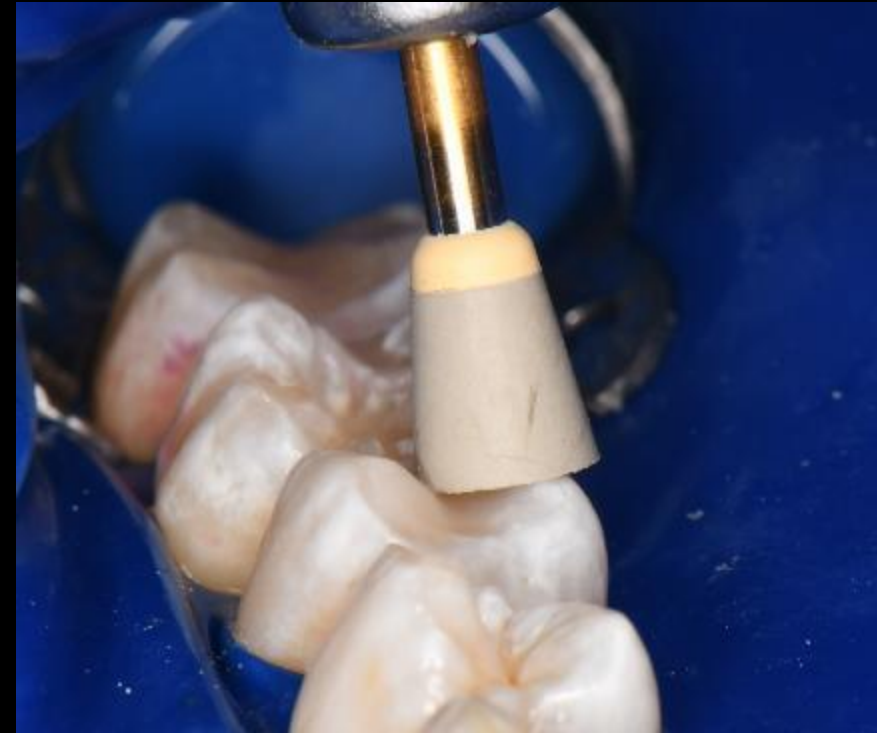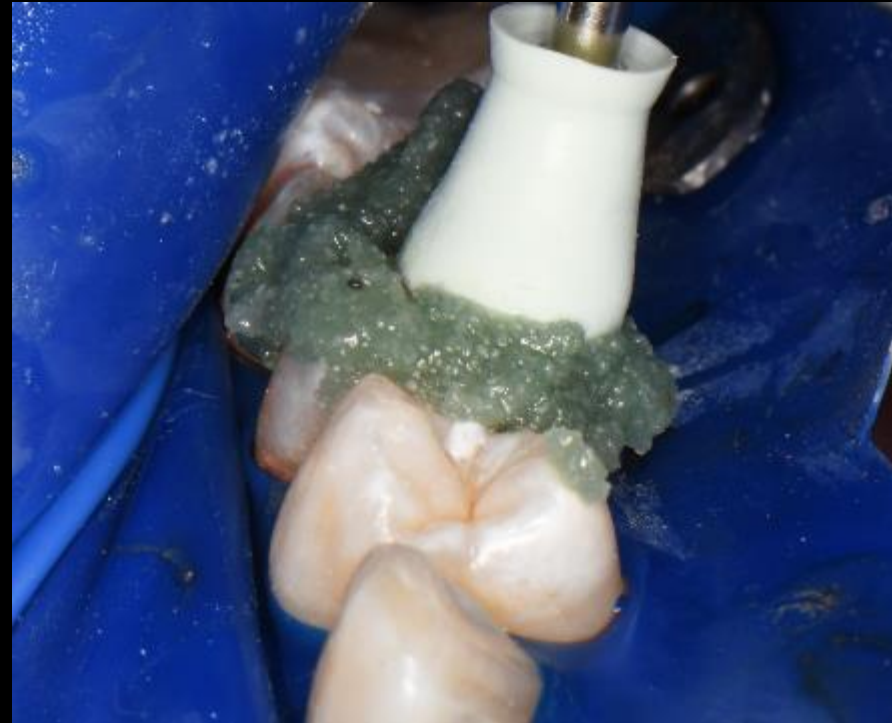Spot Weld, Push Pull

∞ BIOCLEAR



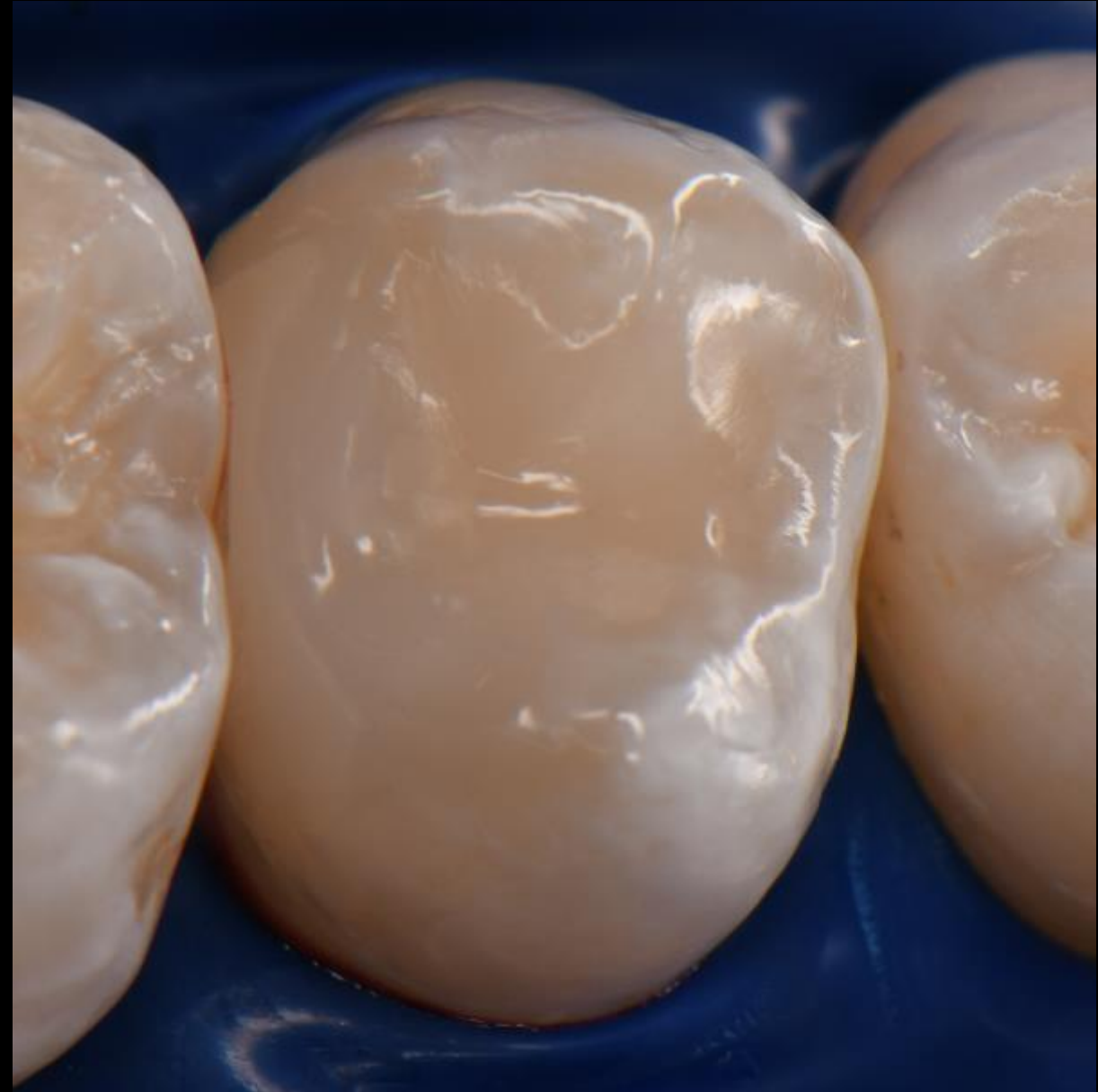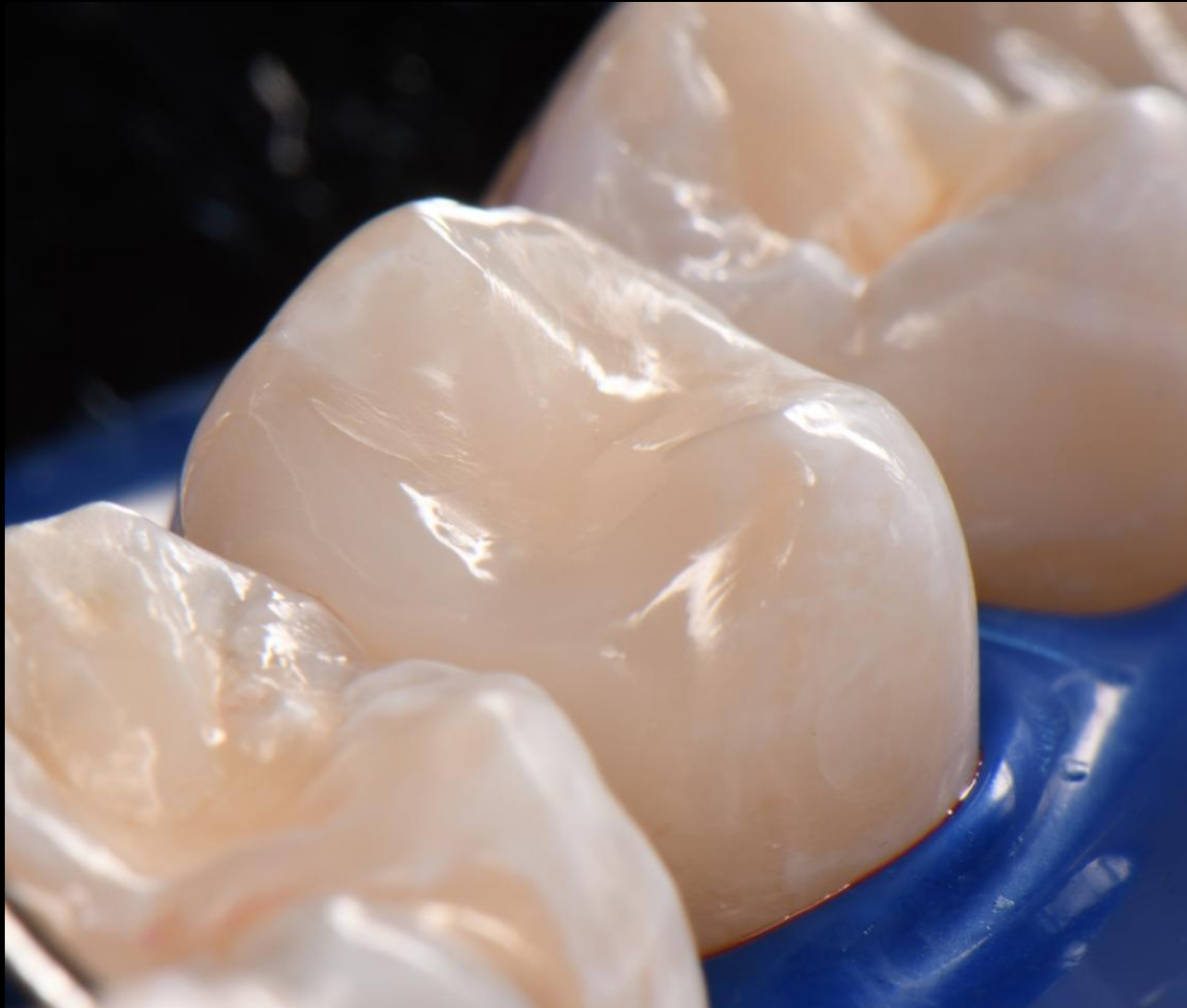Cutback, Disk, Magic Mix, R.S.P.

∞ BIOCLEAR



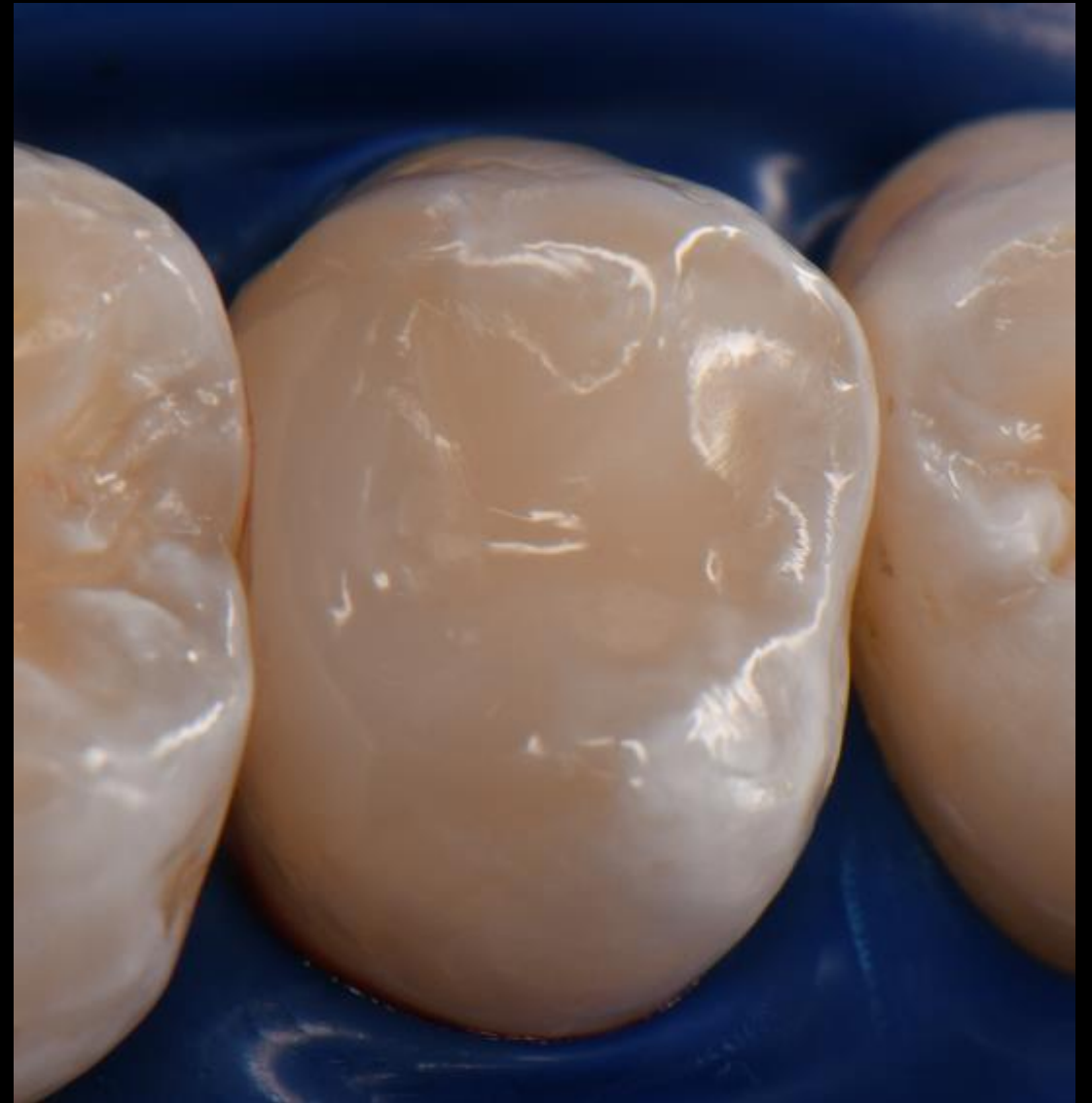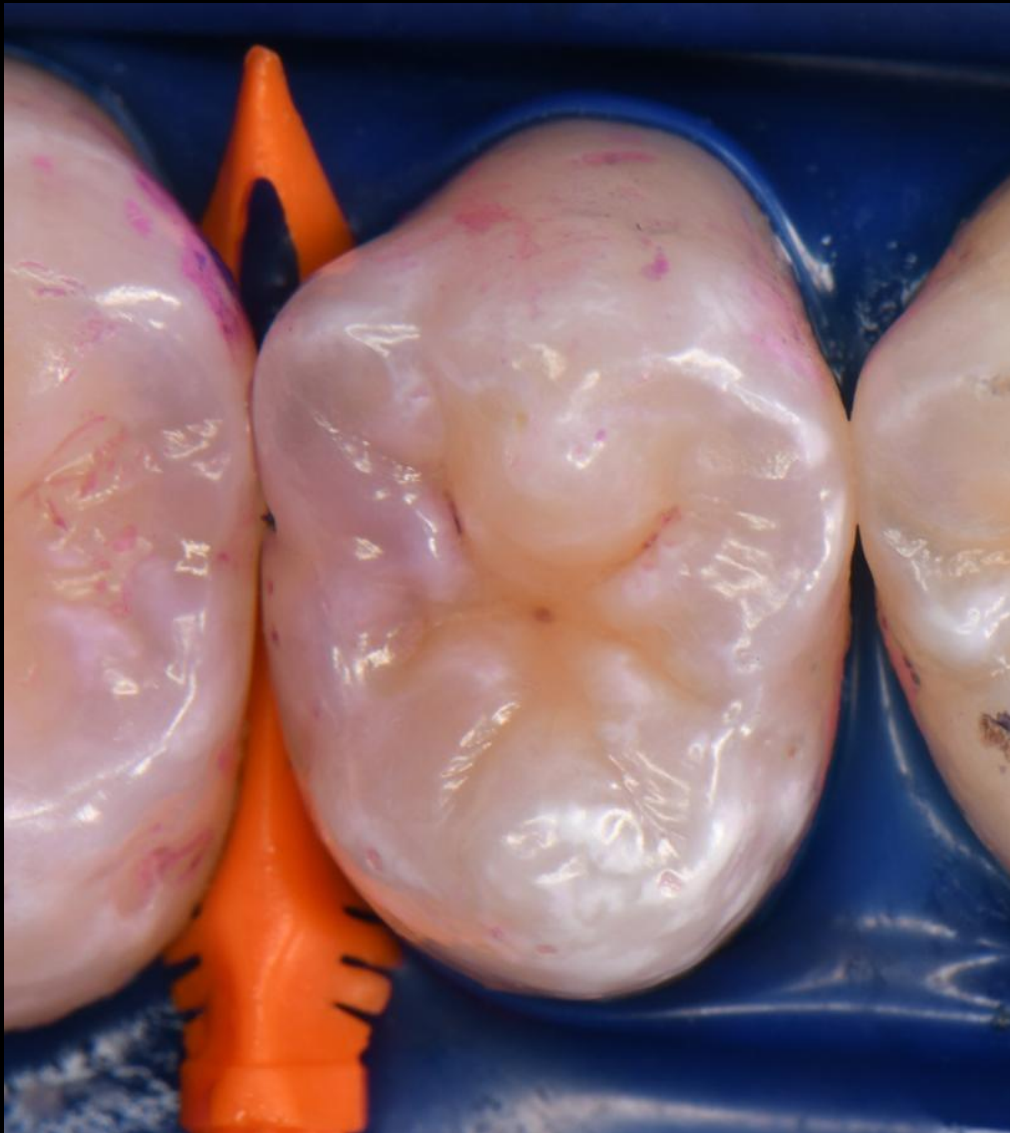
Completed Class II using the Bioclear Method

∞ BIOCLEAR



Infinity Margins with 70/30 Enamel to Dentin Ratio

∞ BIOCLEAR



WHY REINVENT THEW CLASS I?

- Using a 556 bur is a brutally outdated instrument to explore stained grooves or to do an occlusal preparation for incipient decay. It cuts the wrong shape, wrong in at least 3 ways
- Sealing over frank decay with just a sealant and no restorative investigation is questionable
- Occult dentinal decay under a leaking sealant is a recipe for catastrophic decay later

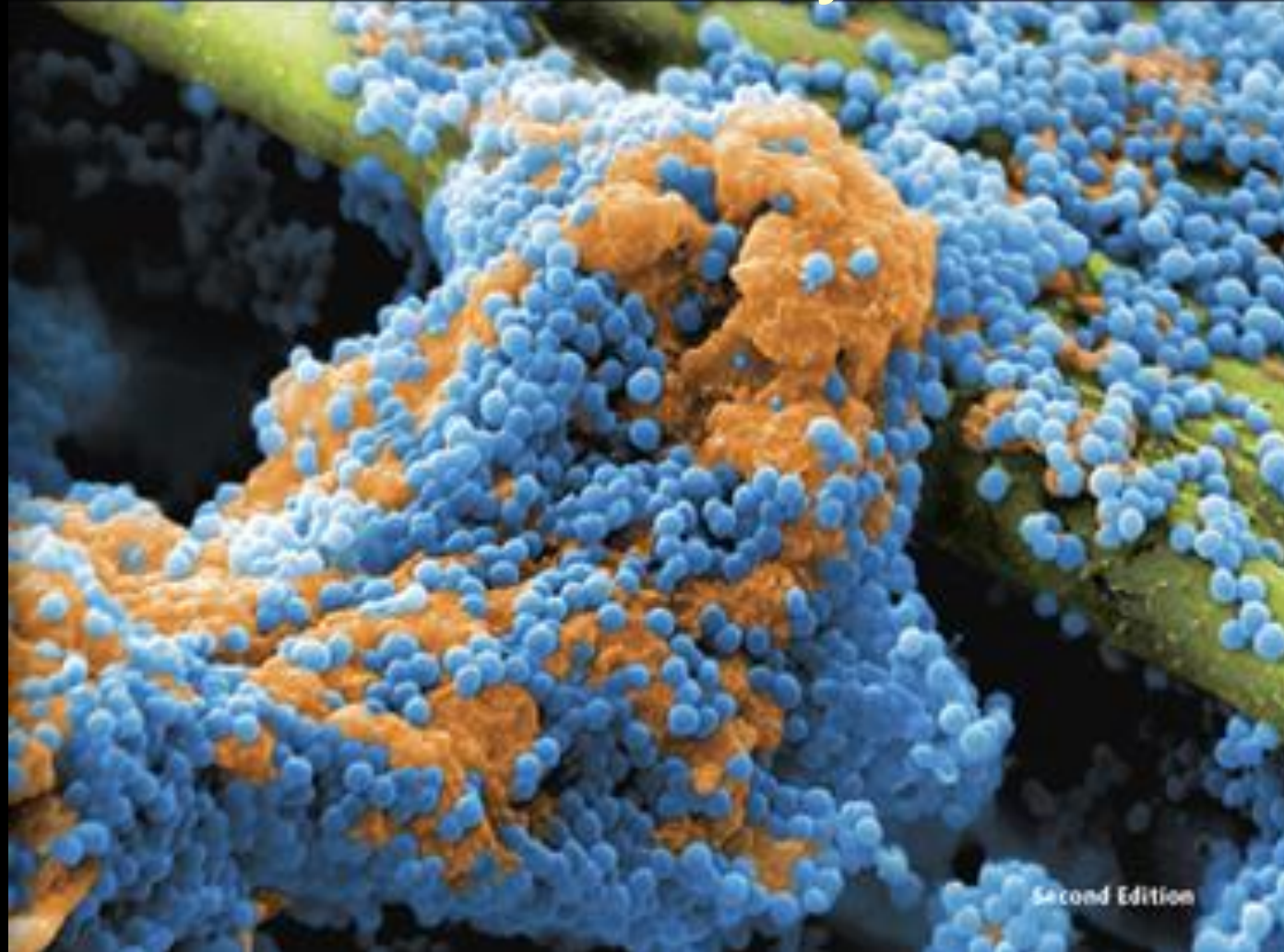
Cally Lily / Clark Class I Sequence with *no* anesthetic

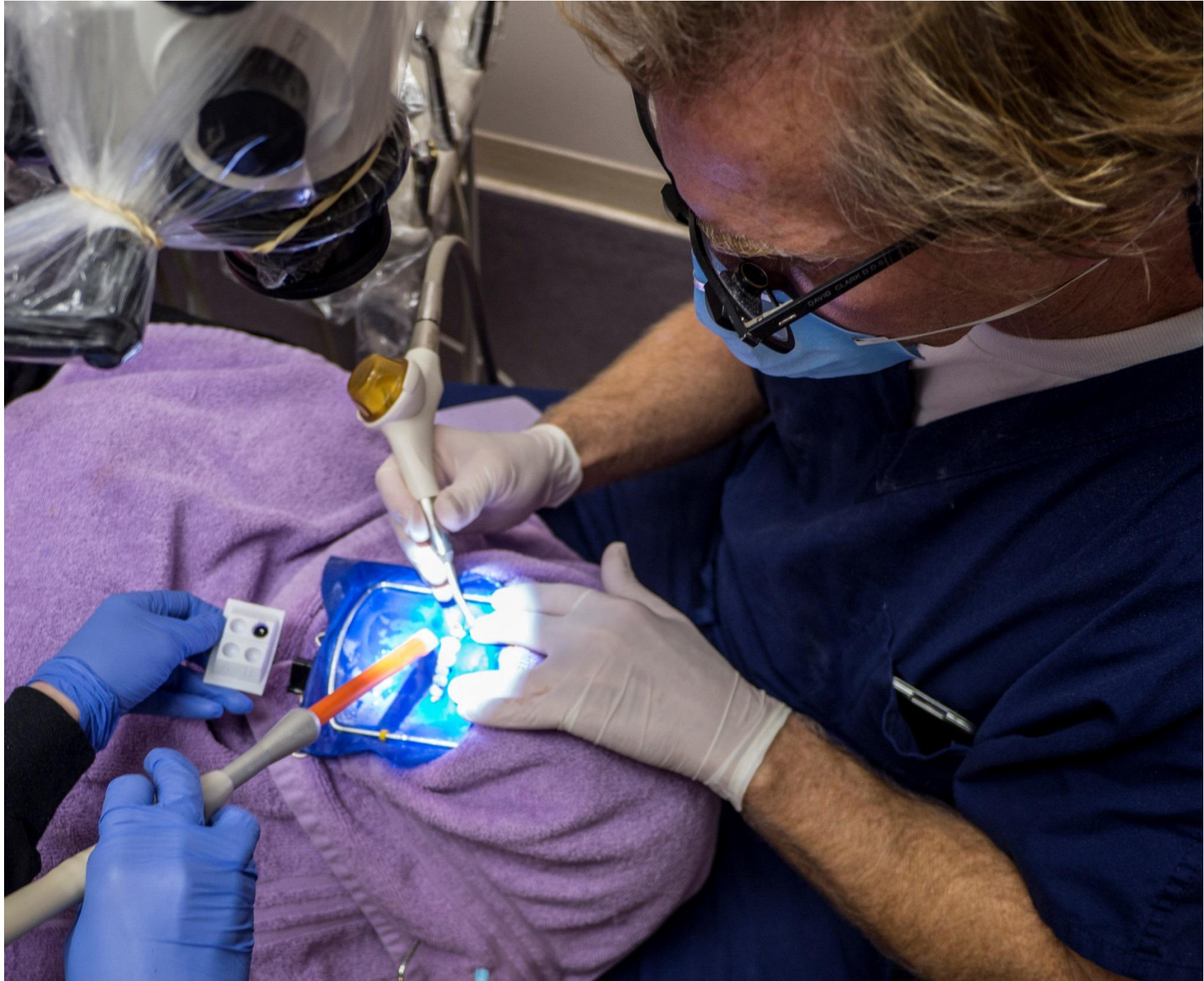1. Disclose
2. Blast
3. Remove stain from all grooves*
4. Angle CLF bur as needed to flare prep for proper shape (wobble)
5. NEVER use heavy occlusal pressure as you get near dentin, use lateral brushing movements. Practice make perfect
6. If you discover dentinal caries, stop and give anesthetic, or switch to Bioclear Blaster which SLOWLY and gently removes dentinal decay

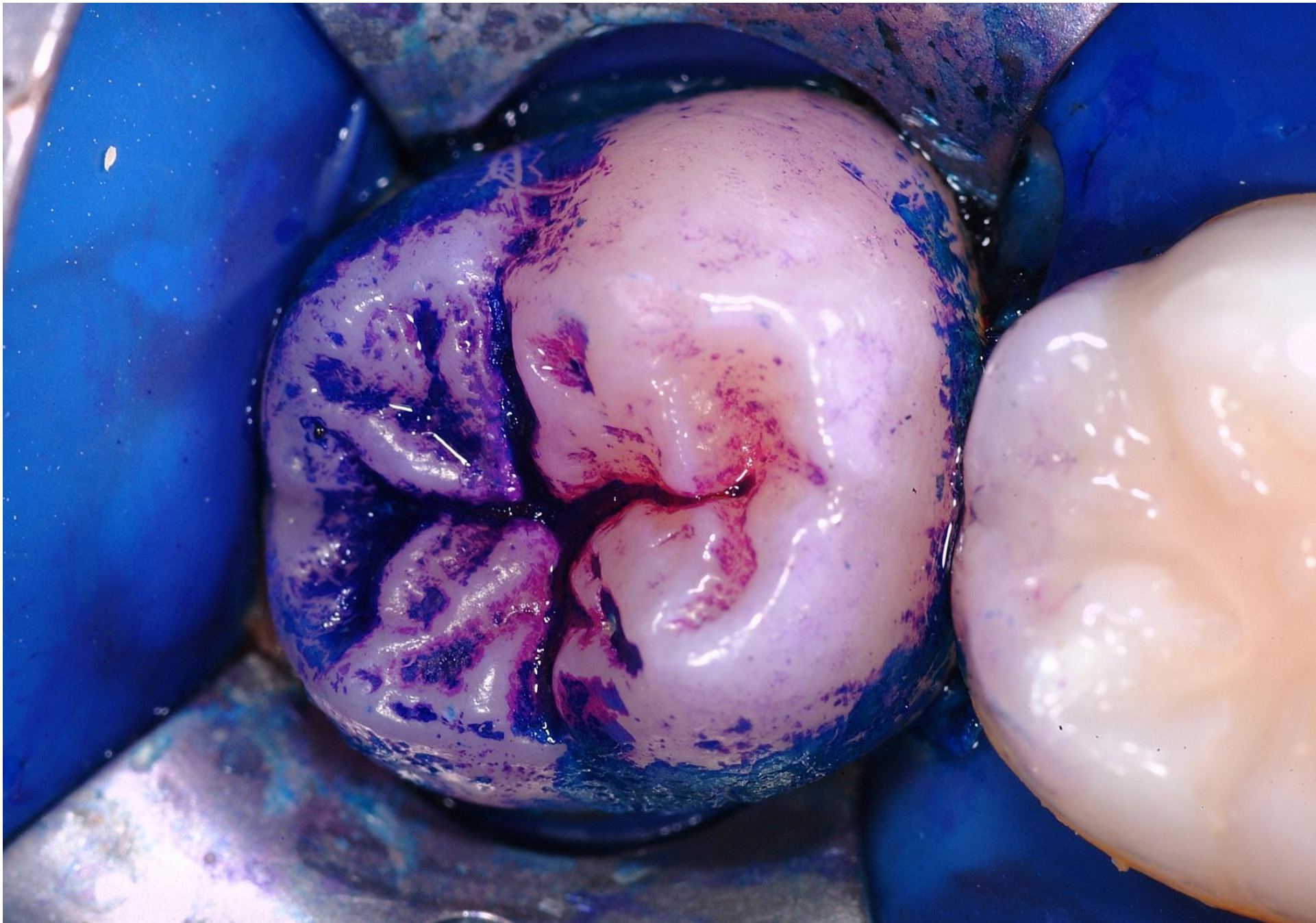
Cally Lily / Clark Class I Sequence: Restoration

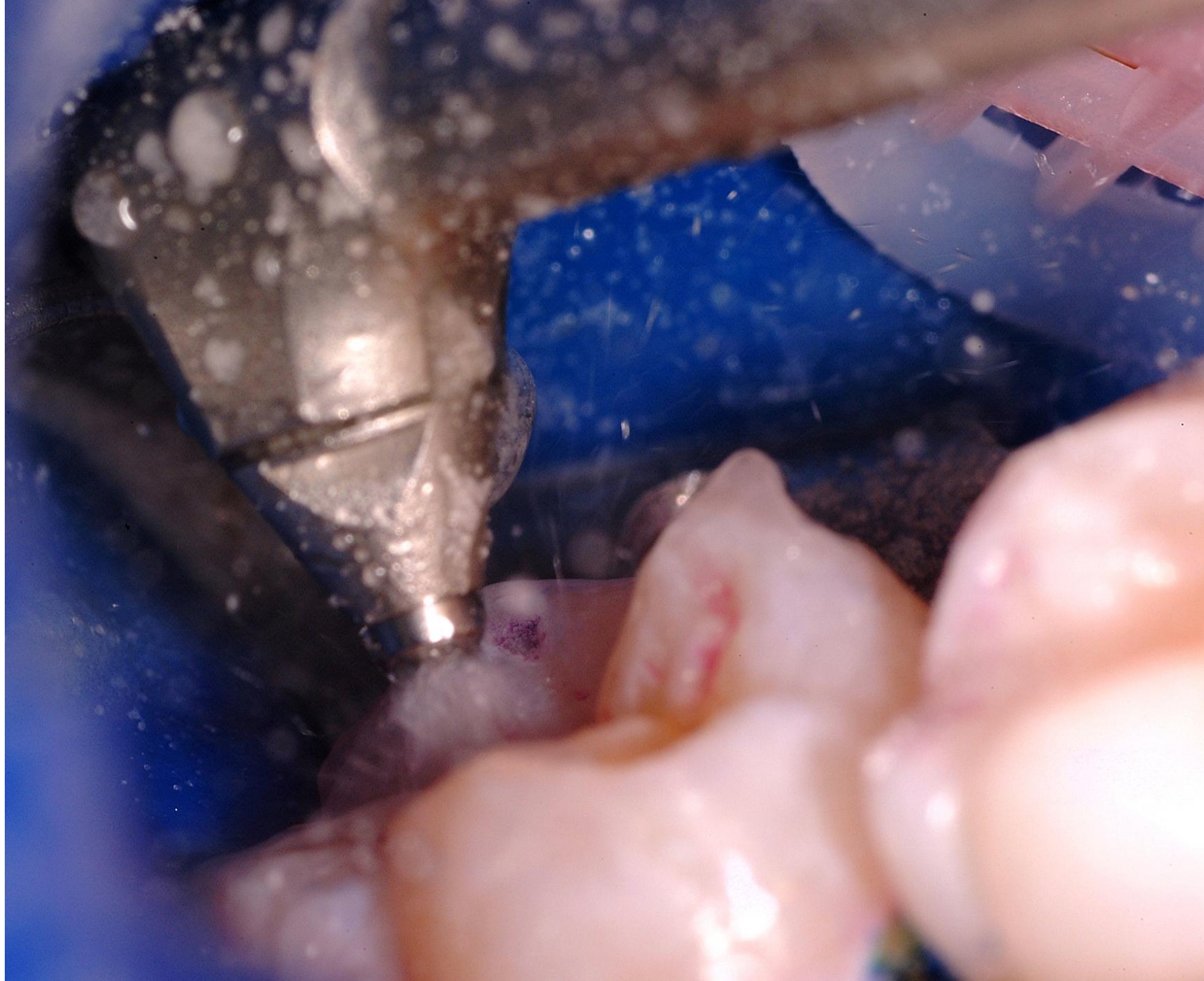
1. Total etch, 20 seconds on enamel, 10 seconds on dentin, rinse and dry
2. If you have encountered dentin, you must “PRE-CURE” the adhesive on dentin. (I use Scotchbond Universal Plus)
3. Wet the entire etched area and the adhered dentin with adhesive as a surfactant, DO NOT CURE
4. Carefully inject heated quality flowable composite (I use Filtek Flow)
5. If you discover dentinal caries, we need more than just flowable composite i.e., the restoration is too wide and unsupported for flowable alone. We recommend adding paste composite or the “super snowplow” technique

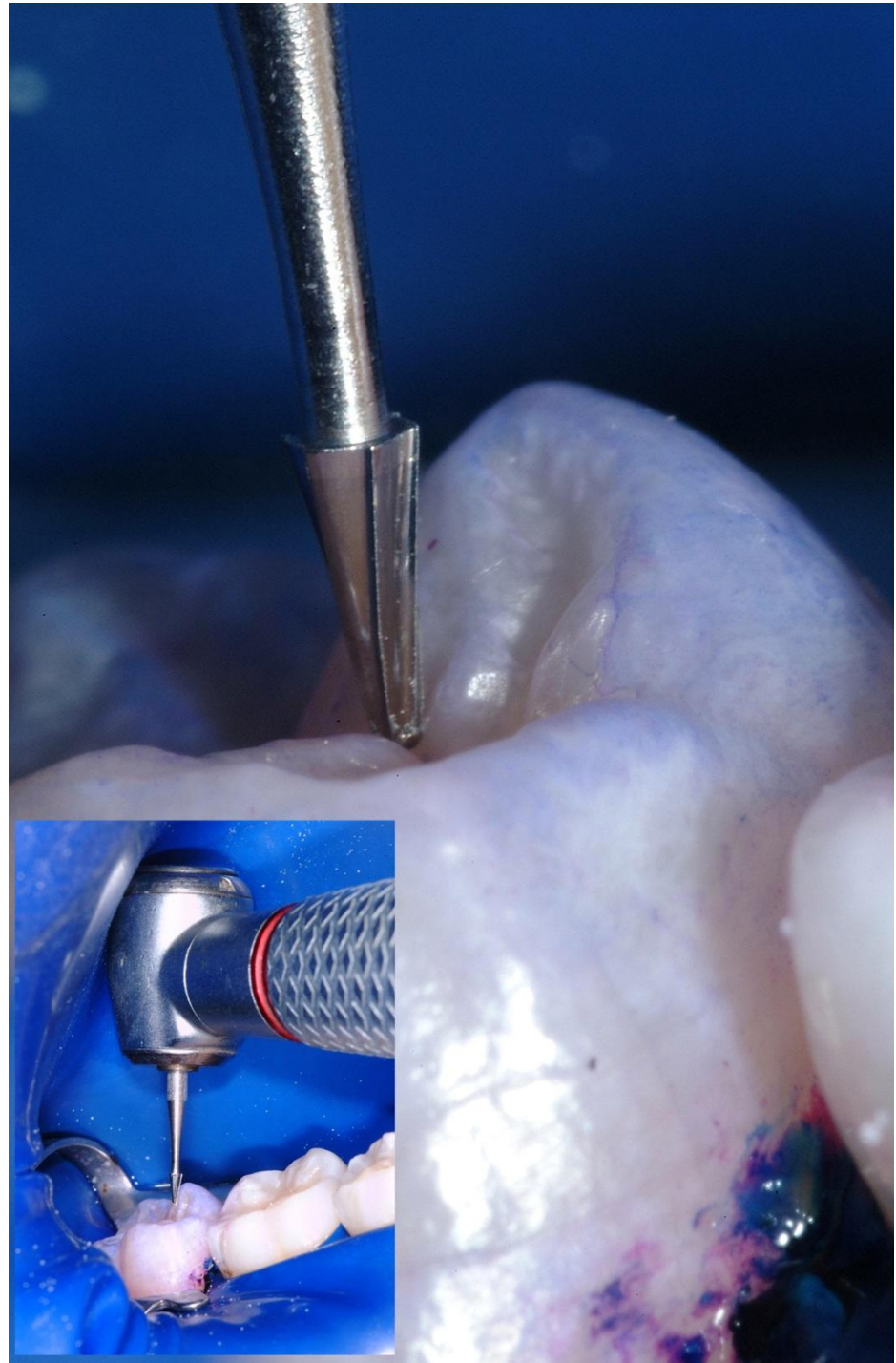
Biofilms: The root of all evil in dentistry

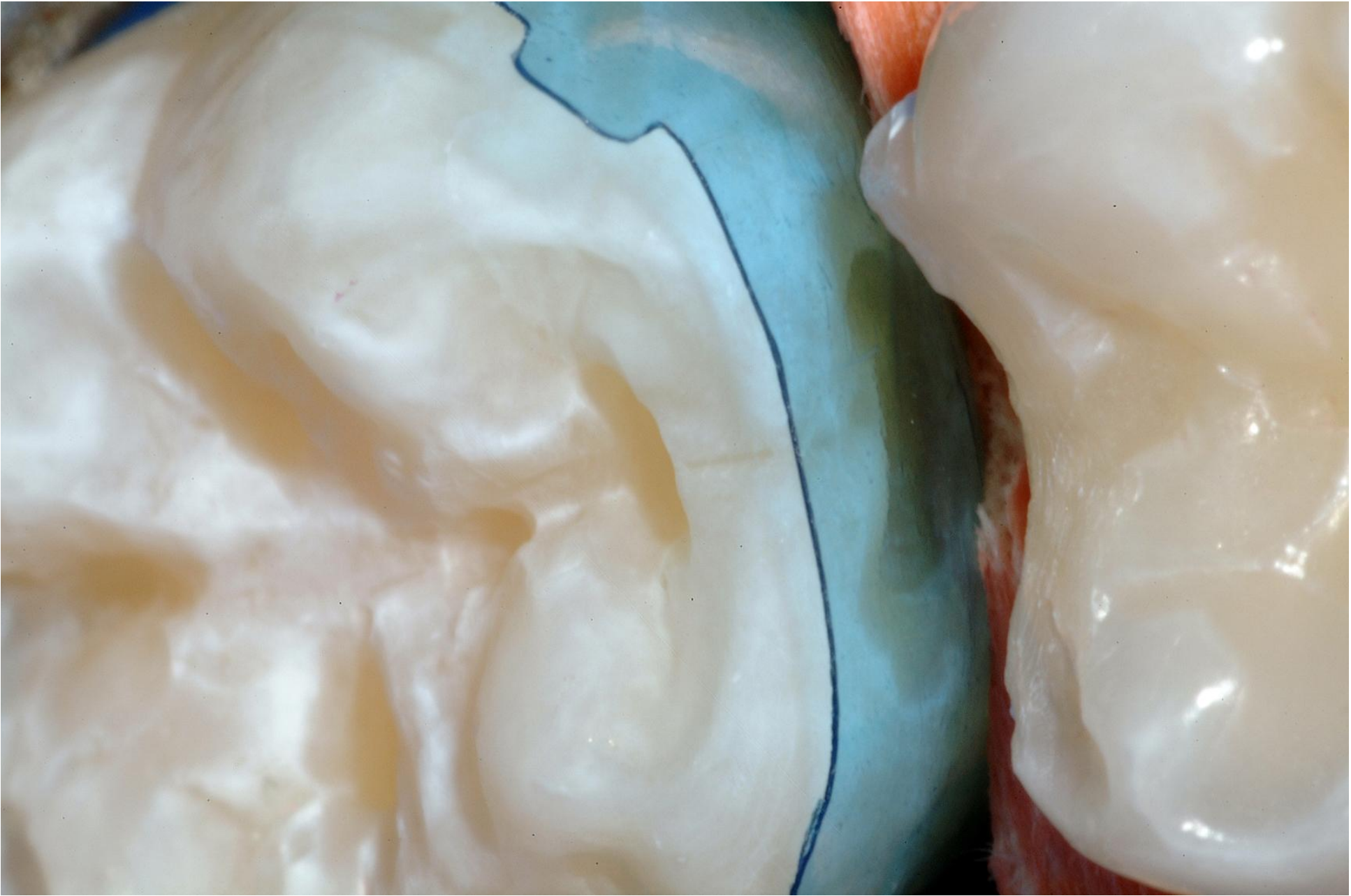


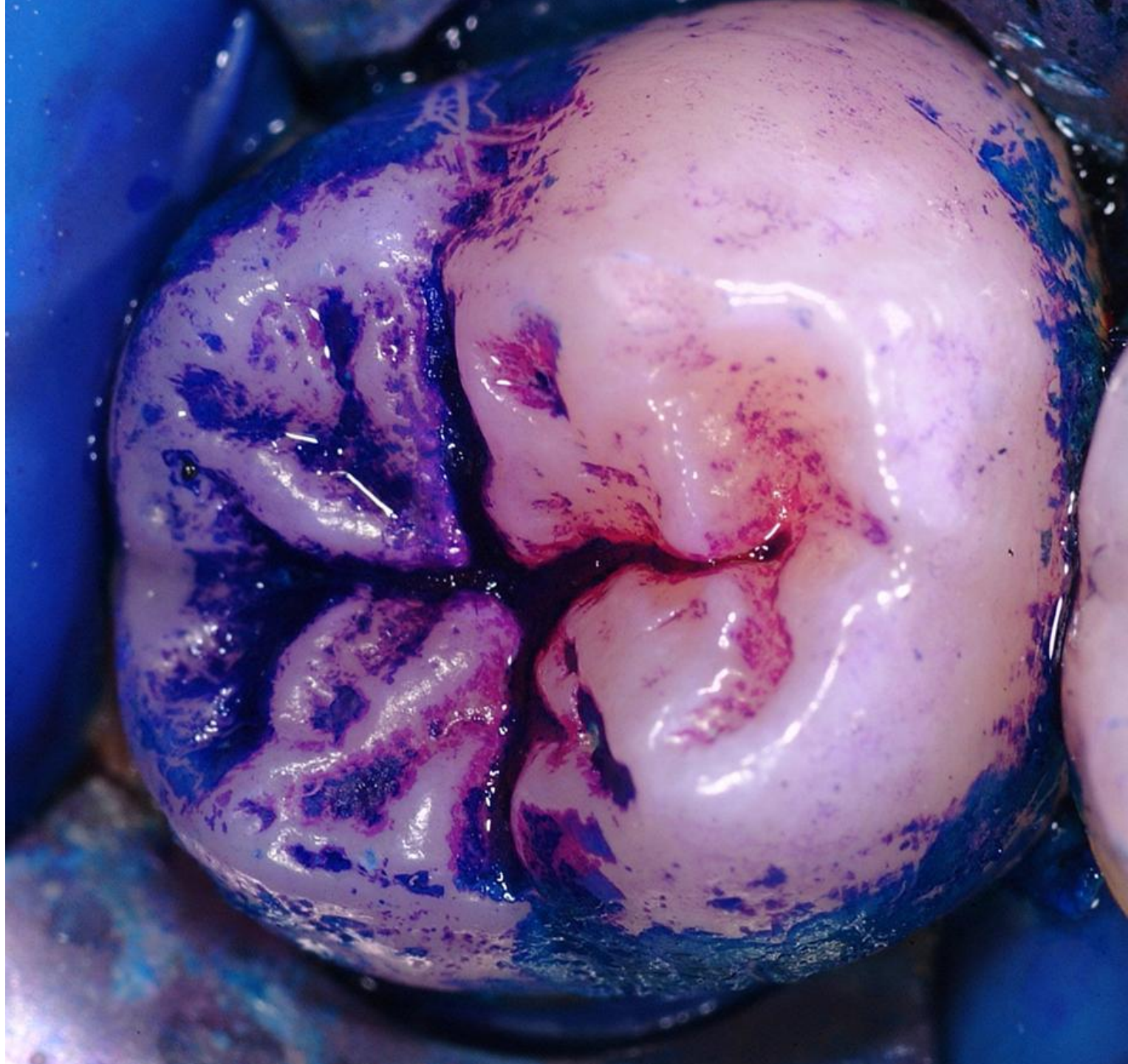




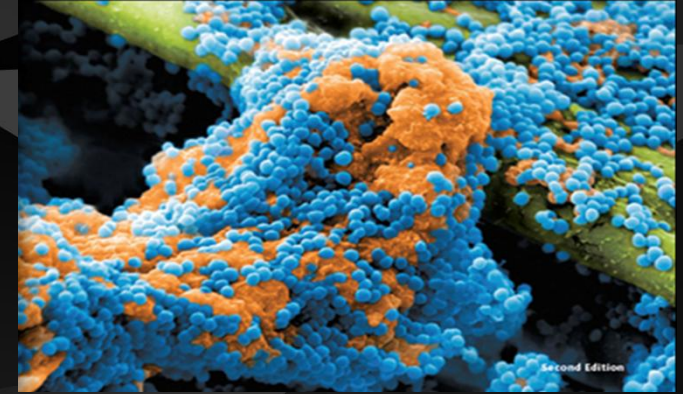








Biofilm Removal



Does 37% phosphoric acid
(gel etchant)
remove biofilm?

Absolute Hardness



MOHS HARDNESS SCALE

I
N
C
R
E
A
S
I
N
G

H
A
R
D
N
E
S
S




1 TALC




2 GYPSUM

← *FINGERNAIL*



3 CALCITE

← *COPPER COIN*



4 FLUORITE



5 APATITE

← *KNIFE / GLASS*



6 FELDSPAR

← *STEEL*



7 QUARTZ



8 TOPAZ



9 CORUNDUM



10 DIAMOND

Absolute Hardness

Talc Mg_3S

1

$Al(OH)_3$

9

Bio-Blasting $Al(OH)_3$

Dentin

Apatite

48

Enamel

Al_2O_3

400

Air Abrasion Al_2O_3

Diamond (C)

1600

MOHS HARDNESS SCALE



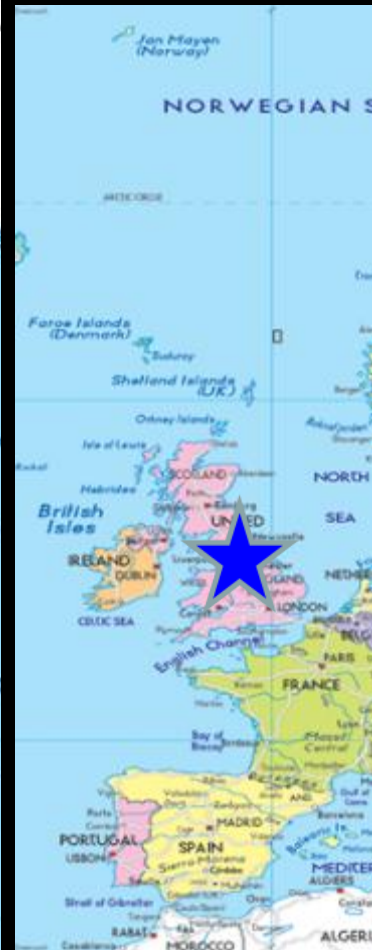
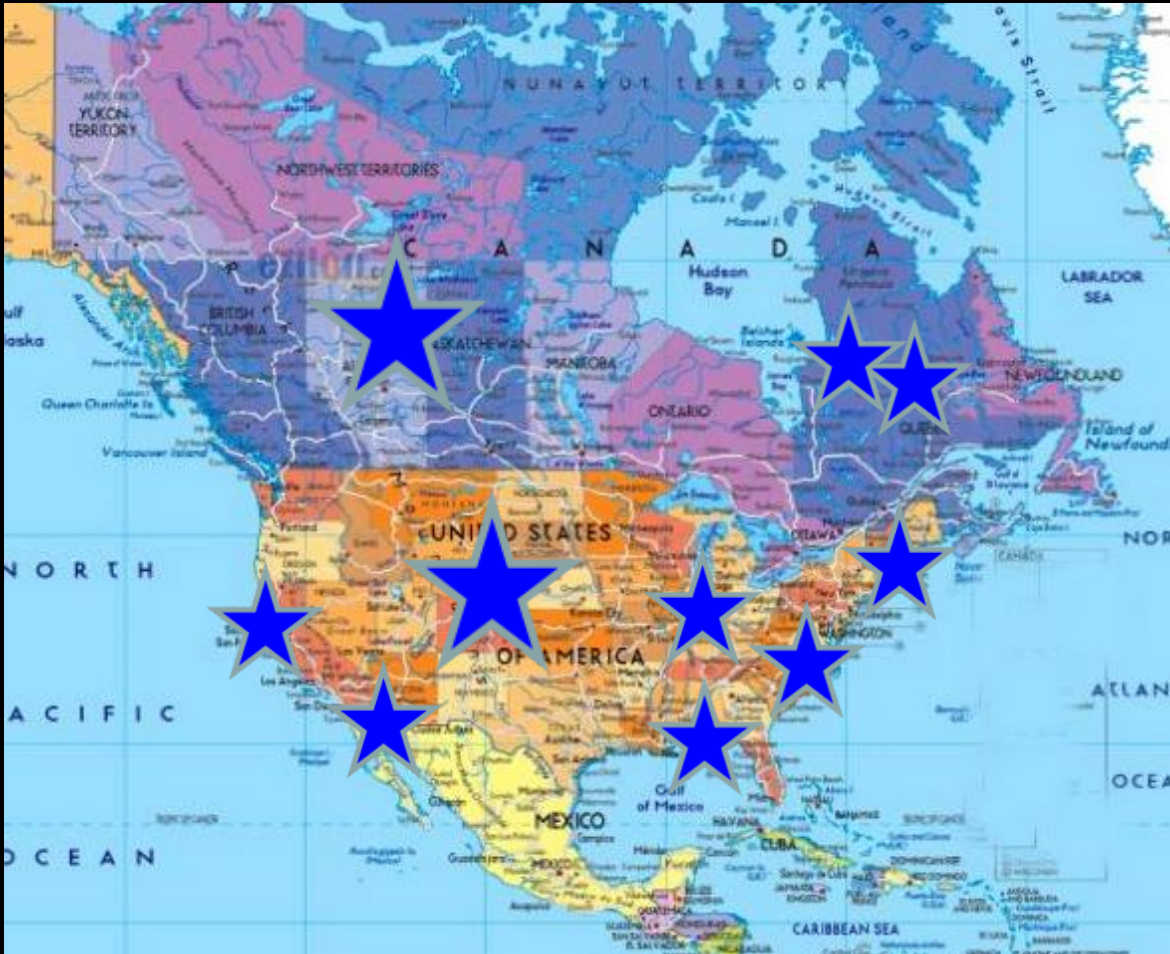I
N
C
R
E
A
S
I
N
G

H
A
R
D
N
E
S
S



- 1 TALC
- 2 GYPSUM
← FINGERNAIL
- 3 CALCITE
← COPPER COIN
- 4 FLUORITE
- 5 APATITE
← KNIFE / GLASS
- 6 FELDSPAR
← STEEL
- 7 QUARTZ
- 8 TOPAZ
- 9 CORUNDUM
- 10 DIAMOND

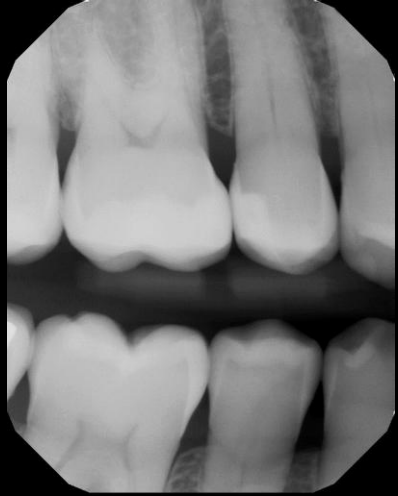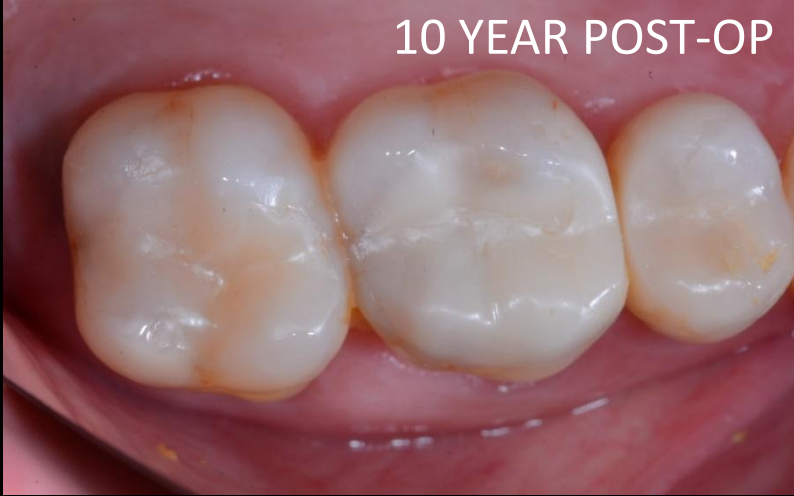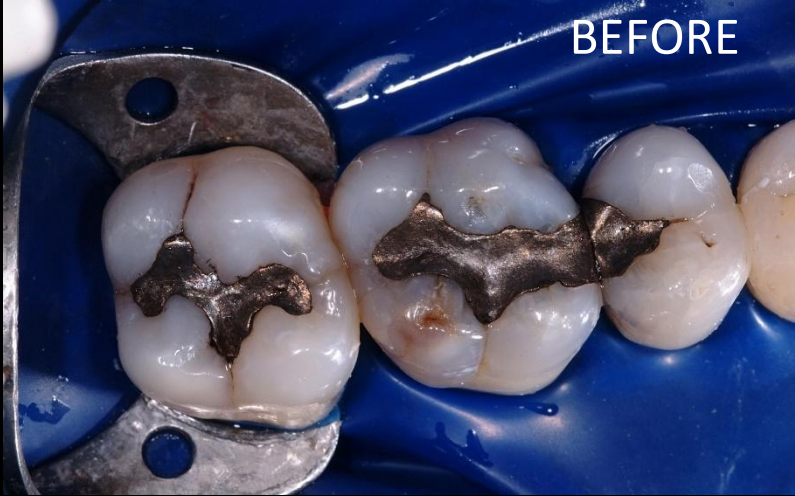Dental schools/institutions integrating the Bioclear Method



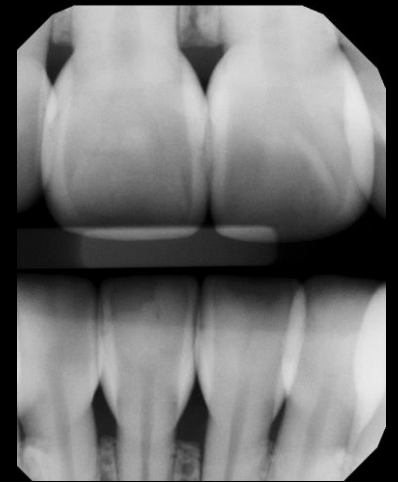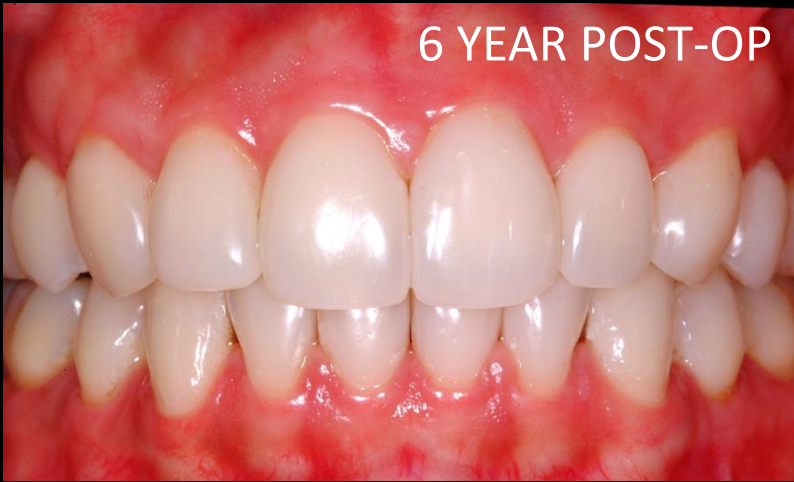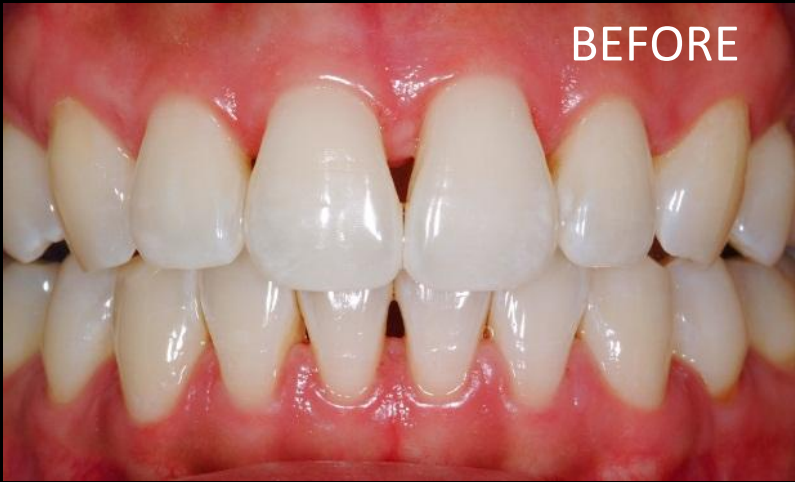Long Term Outcomes
of this Technique:

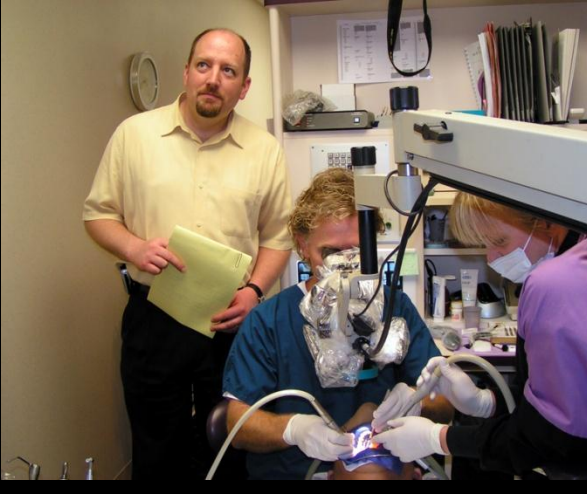Long term Outcomes with the Bioclear Method

Posterior Restoration

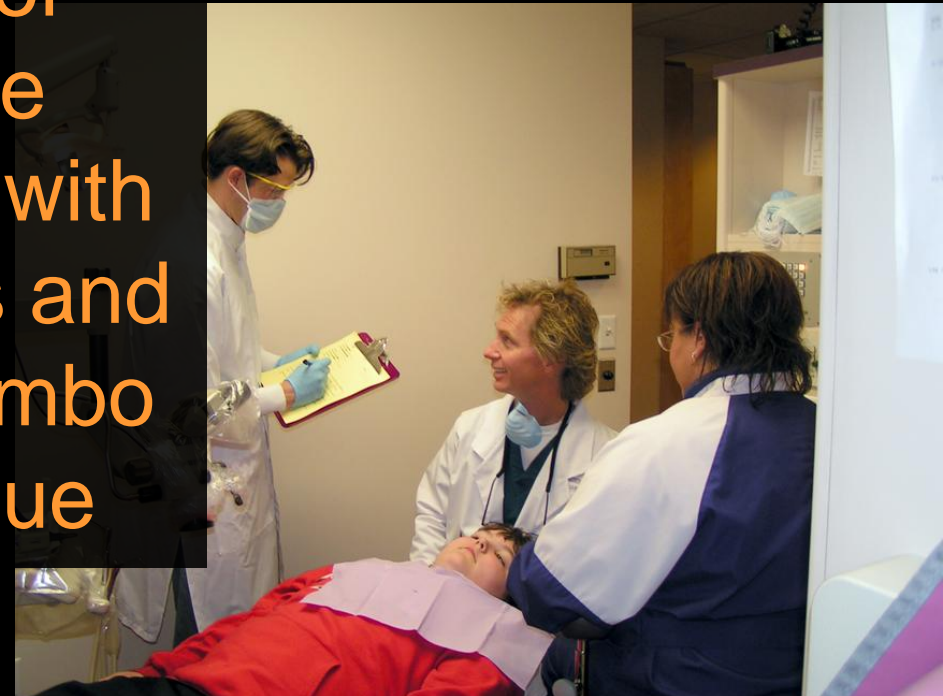
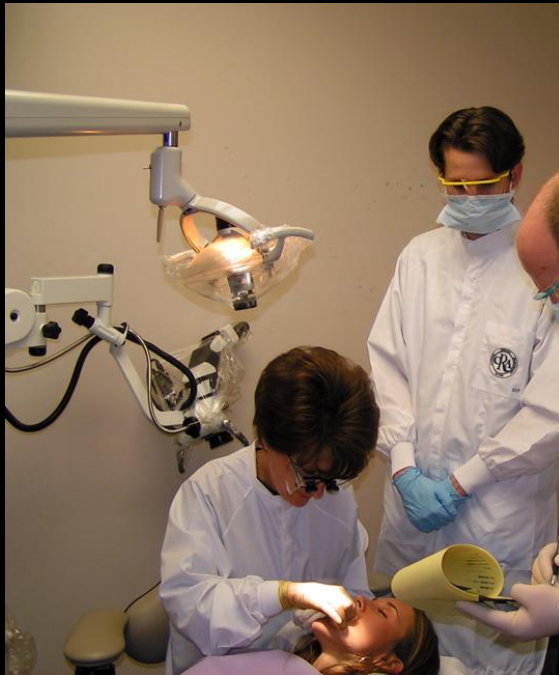
Black Triangle

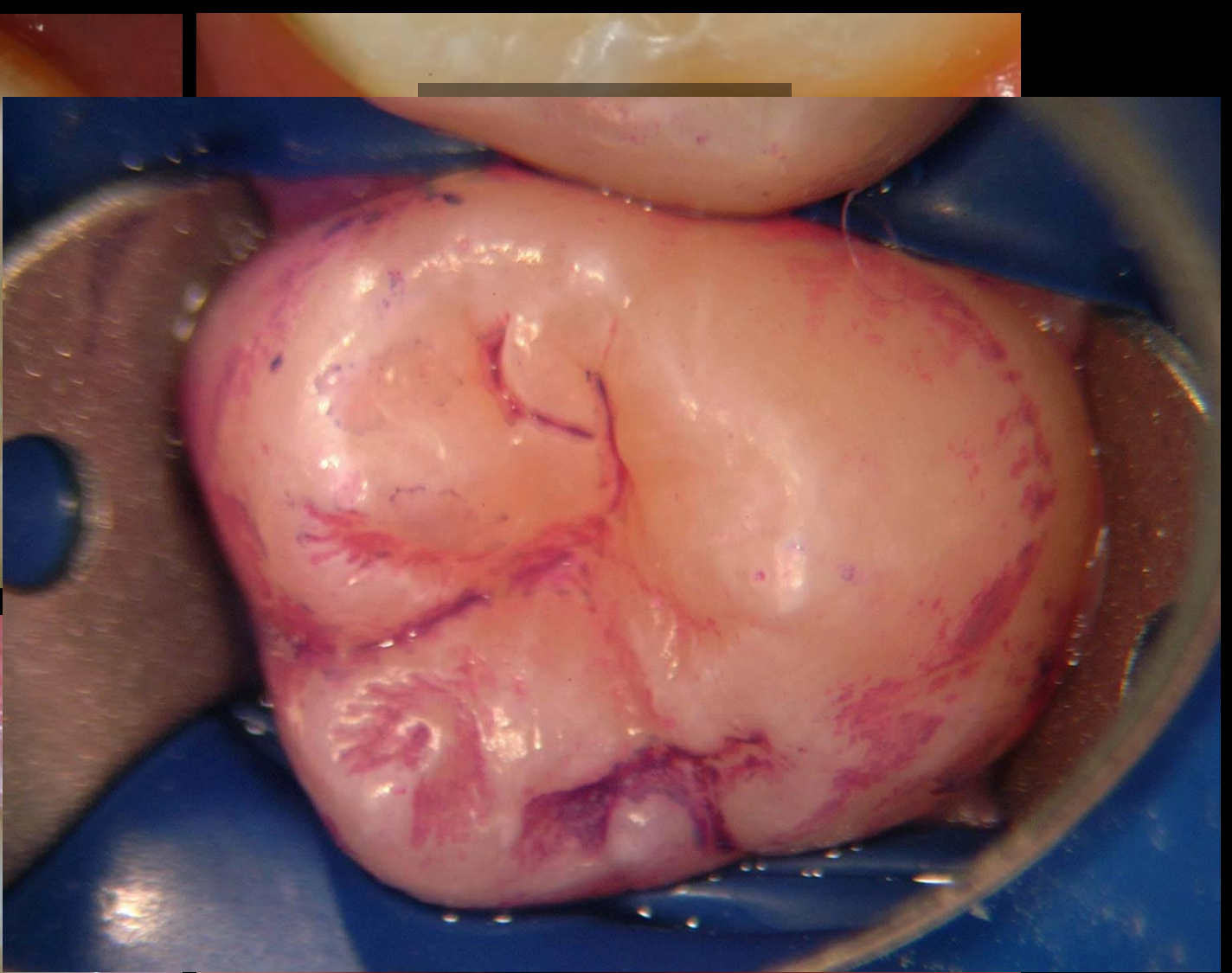
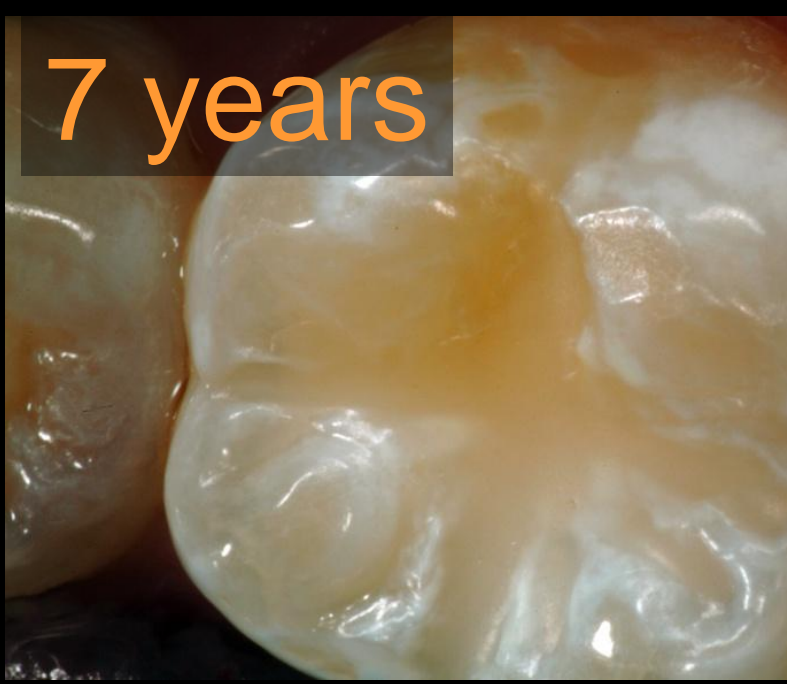



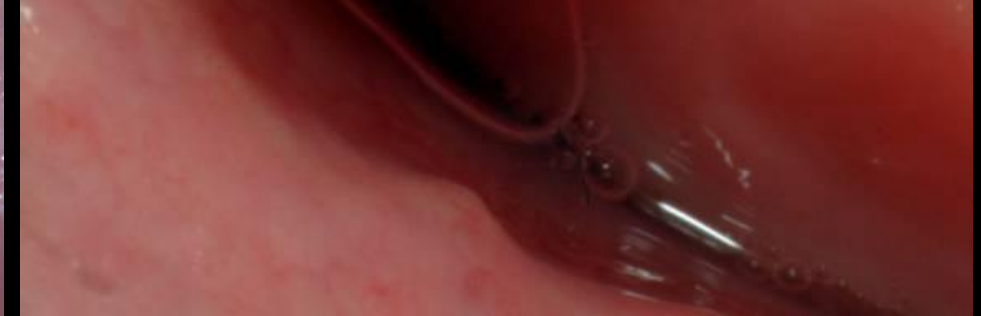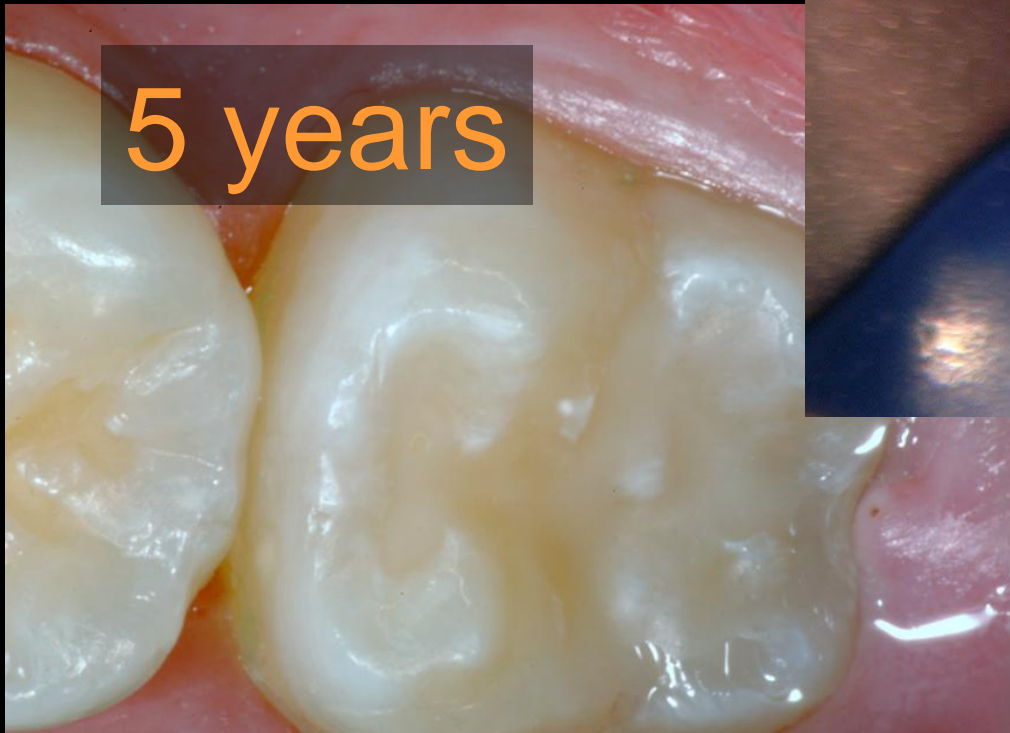2006
retrospective
study of 103
posterior
teeth: 3-7
years of
service
restored with
flowables and
some combo
technique



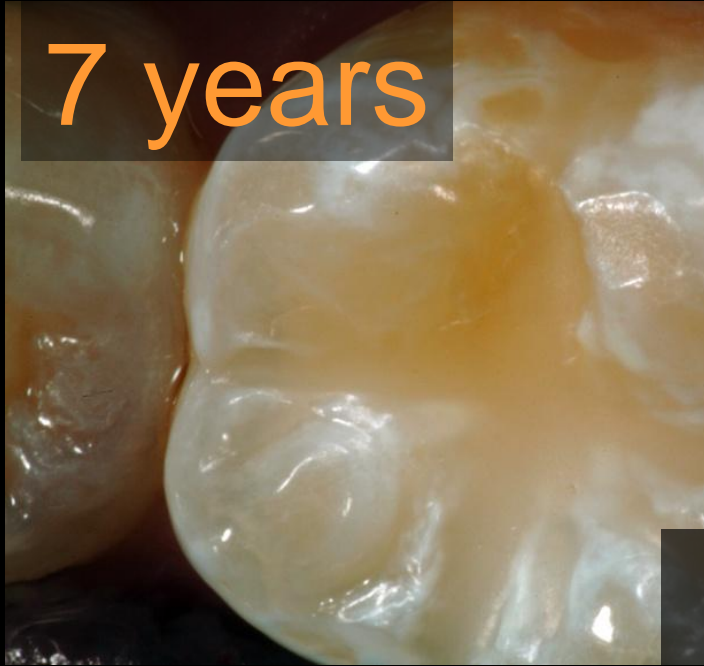7 years



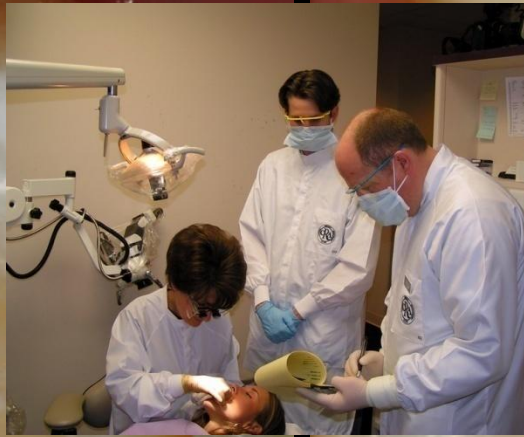5 years



7 years

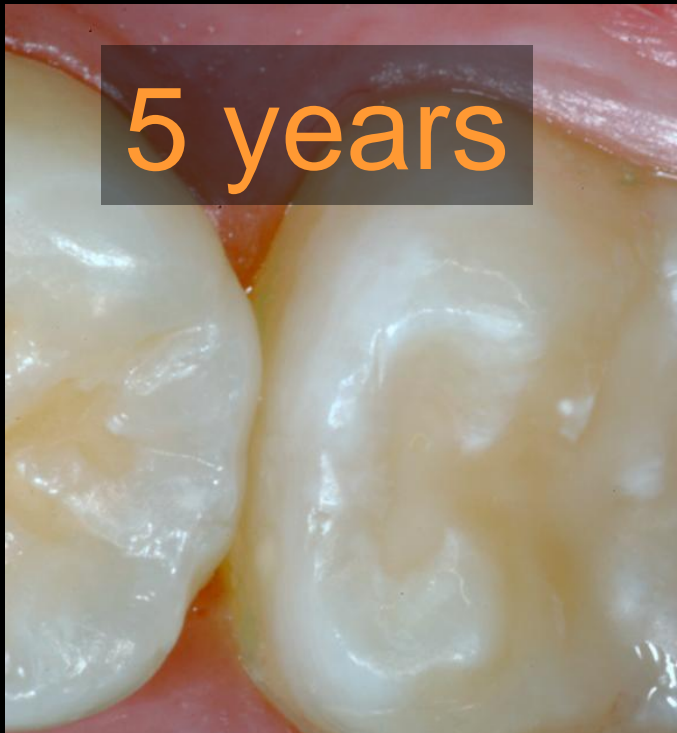

7 years

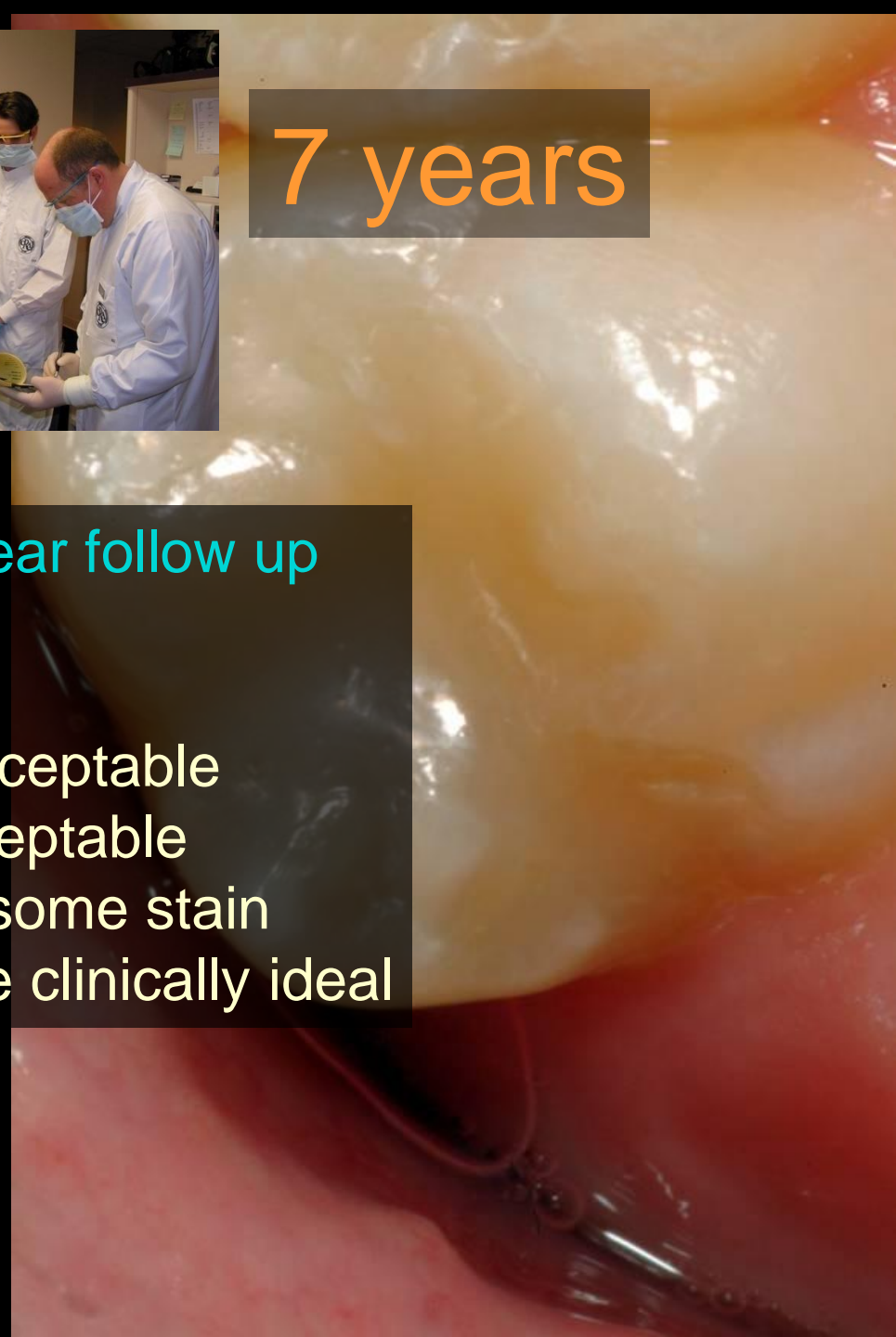


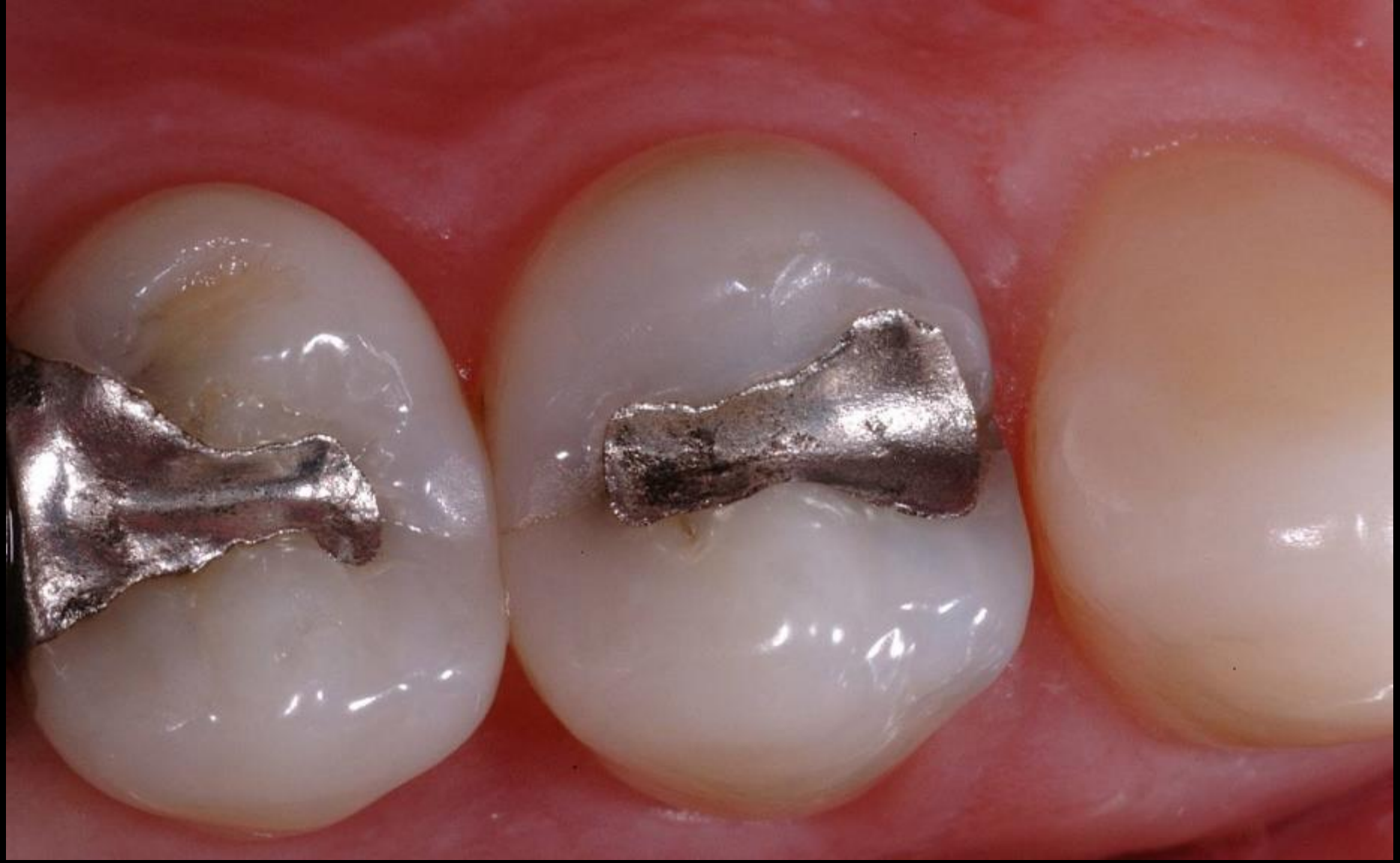At 3-7 year follow up

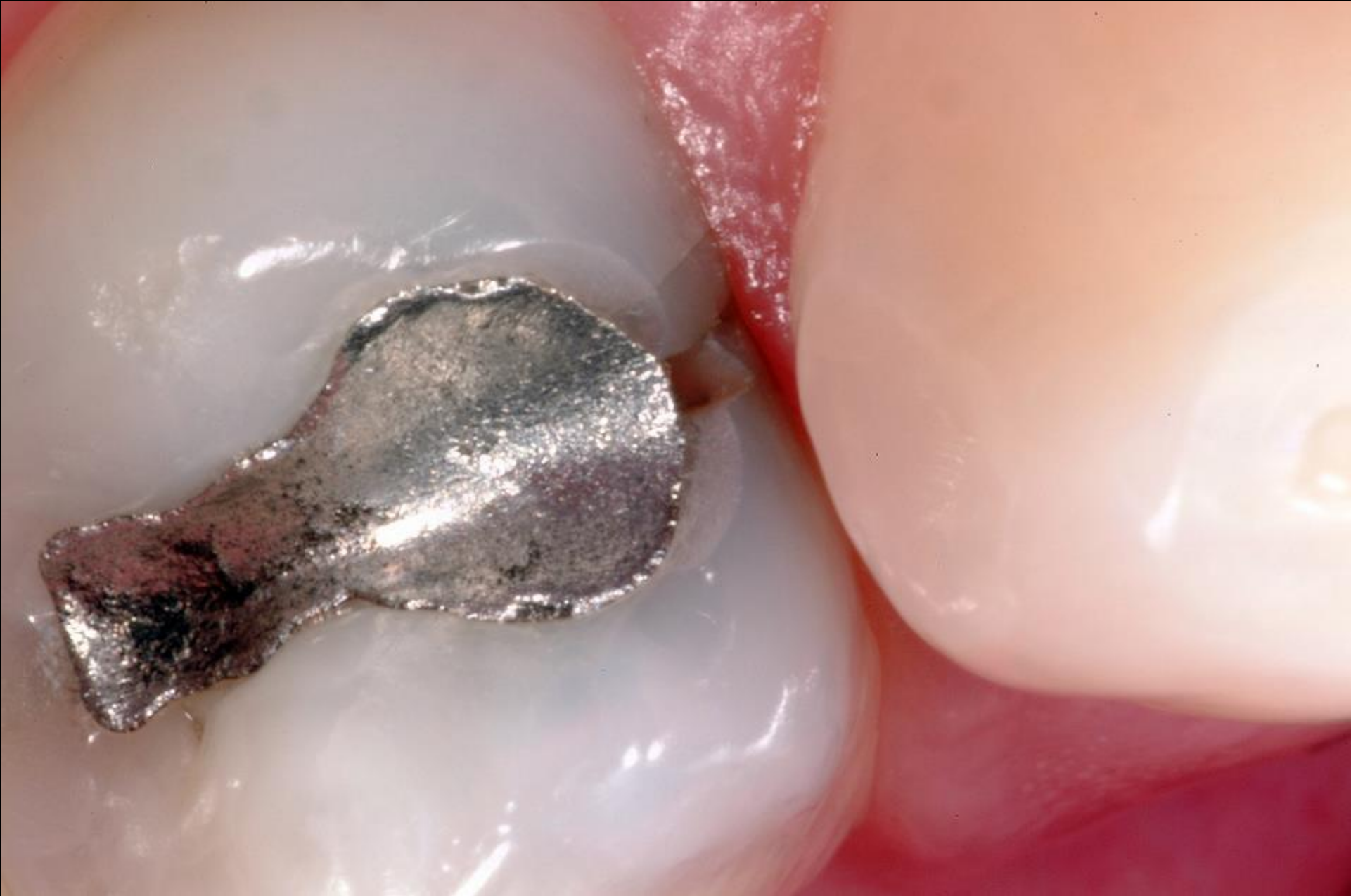5 years

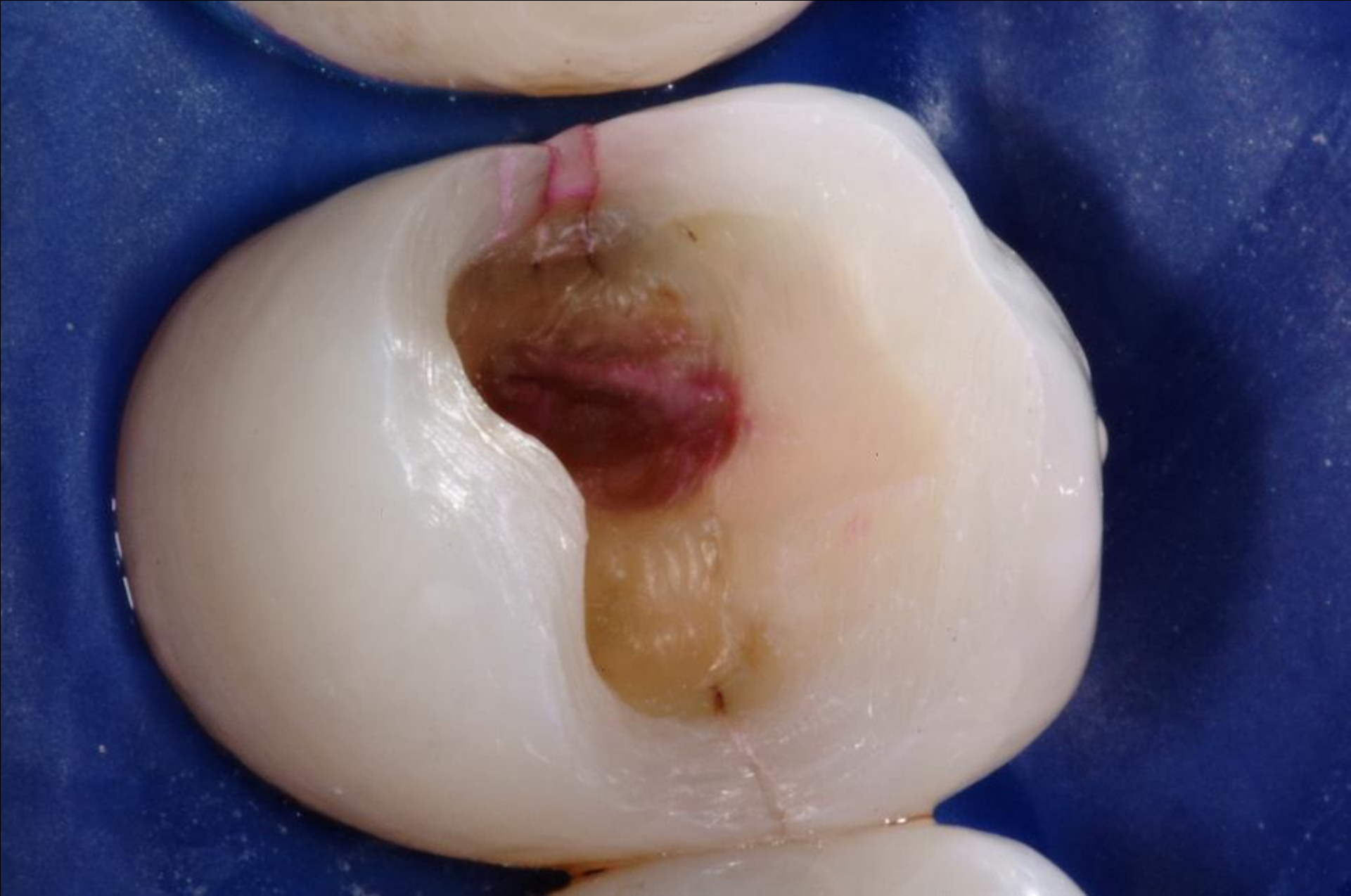

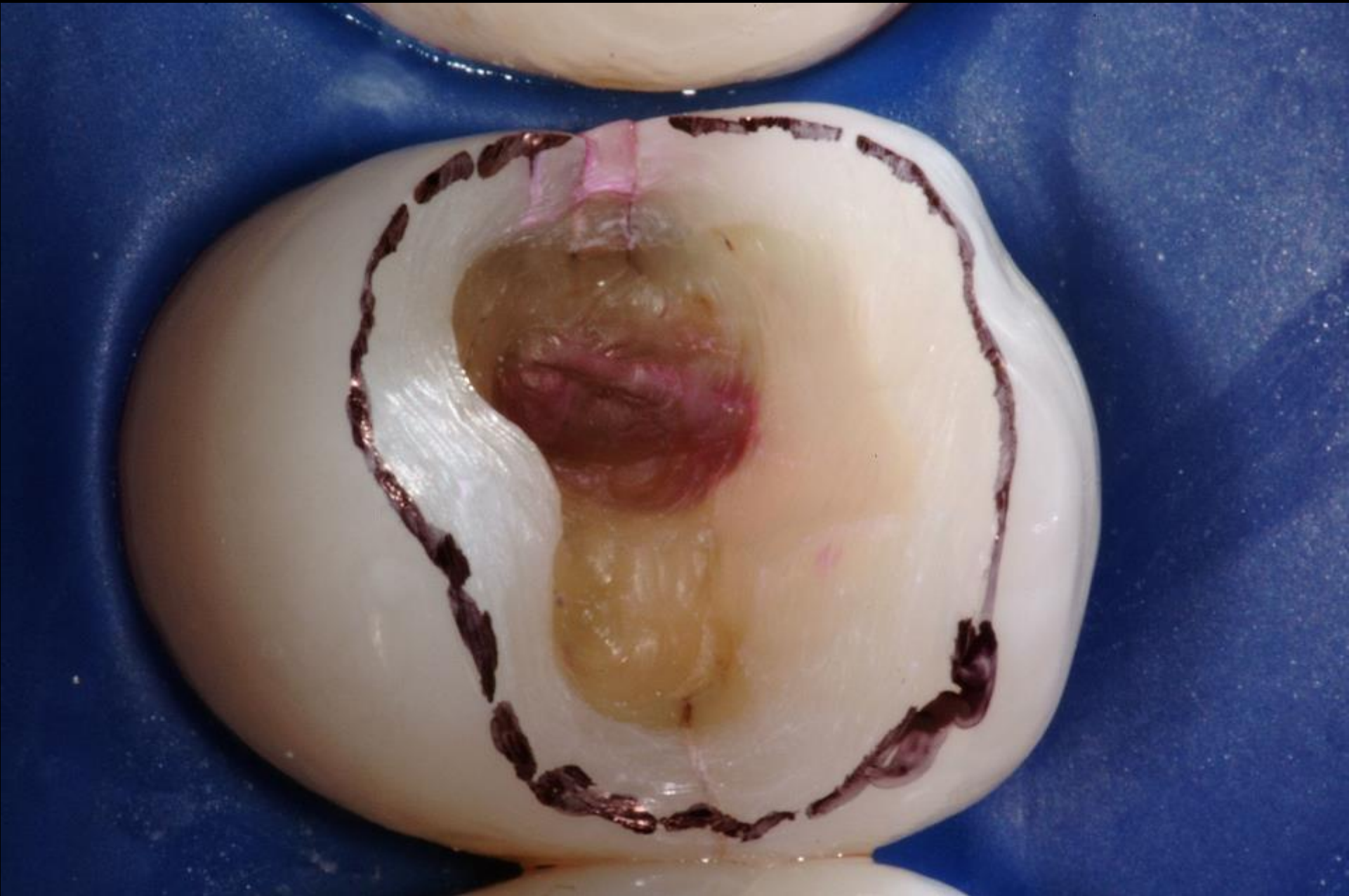- ✓ 103 teeth
- ✓ 2% unacceptable
- ✓ 98% acceptable
- ✓ 7% had some stain
- ✓ 91% were clinically ideal

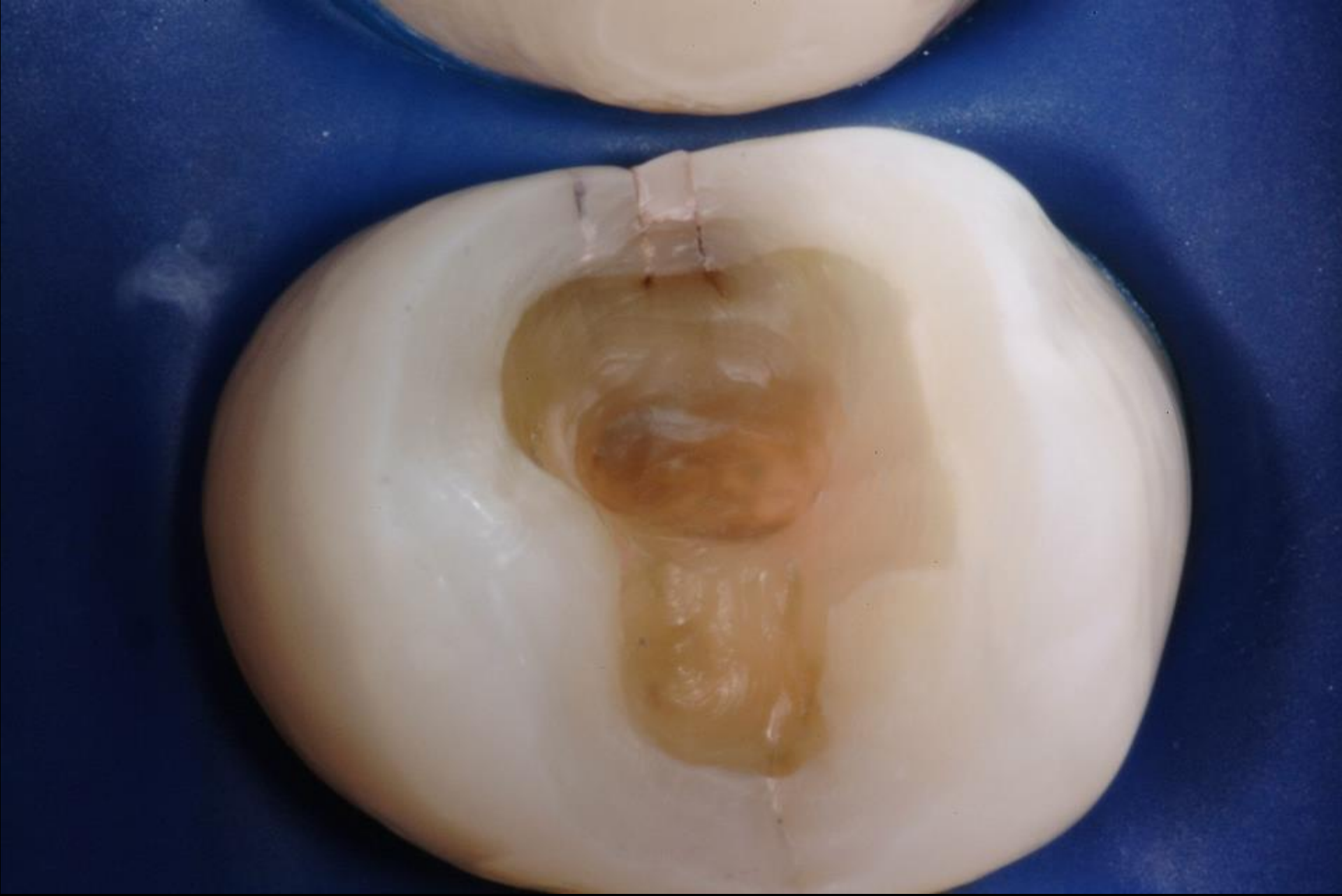


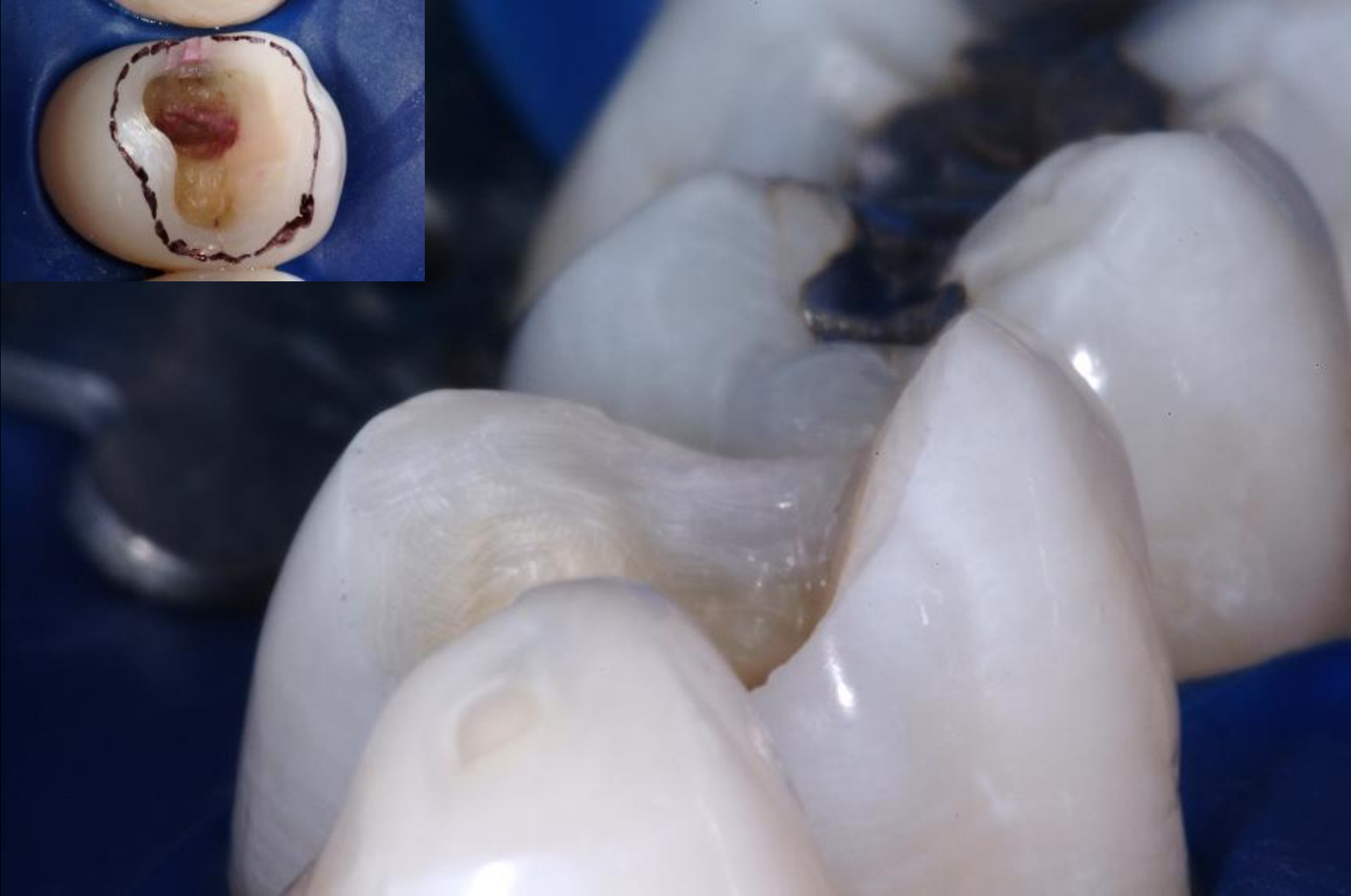
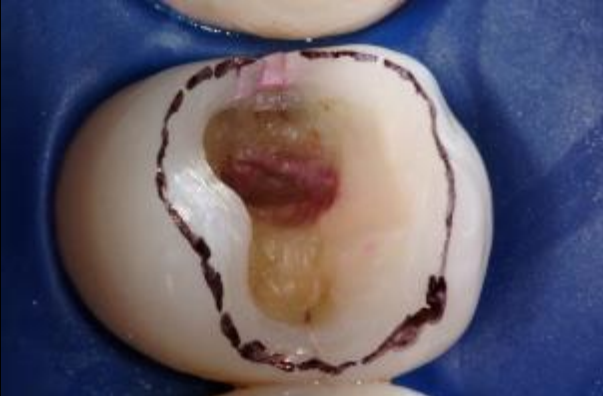




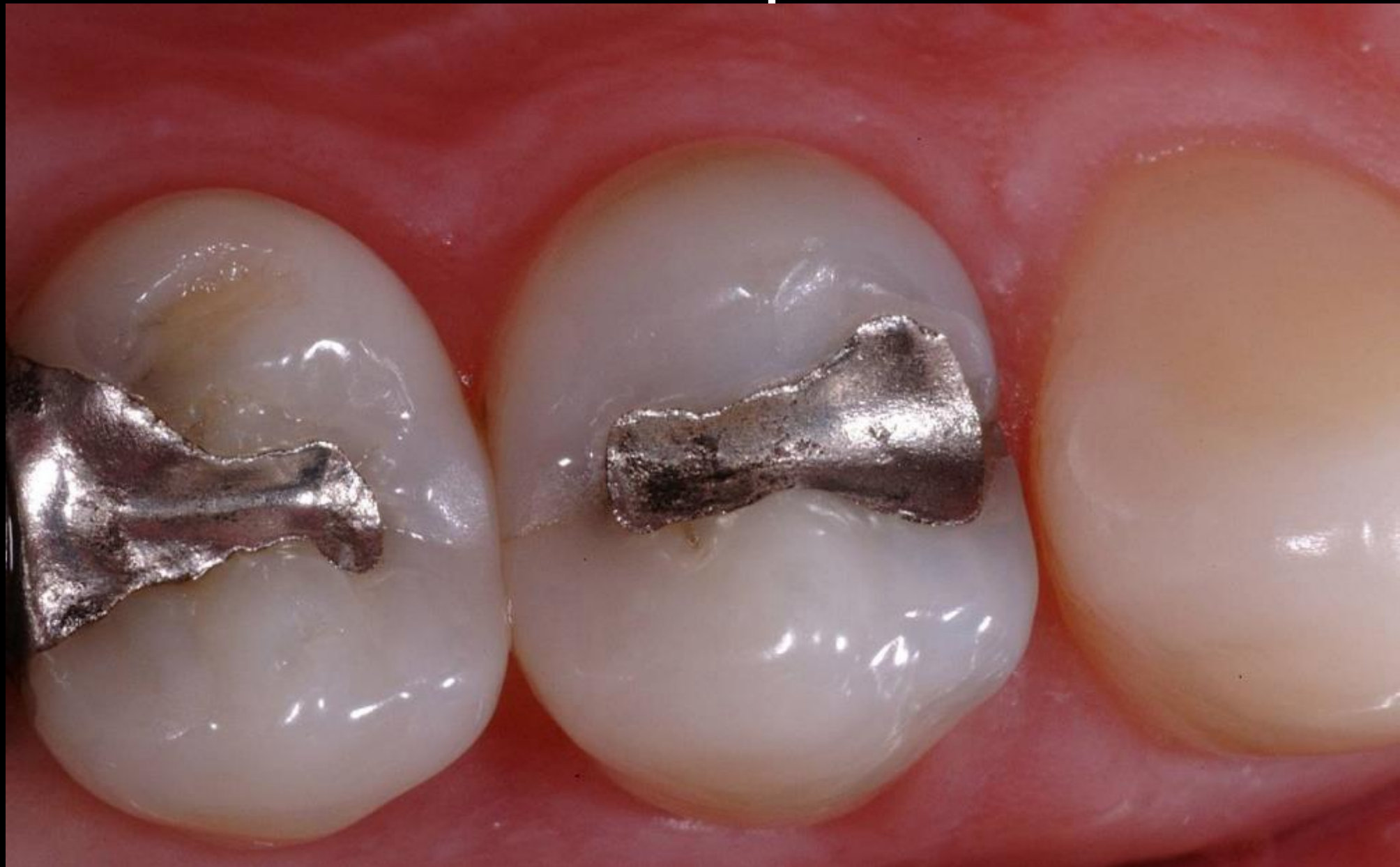




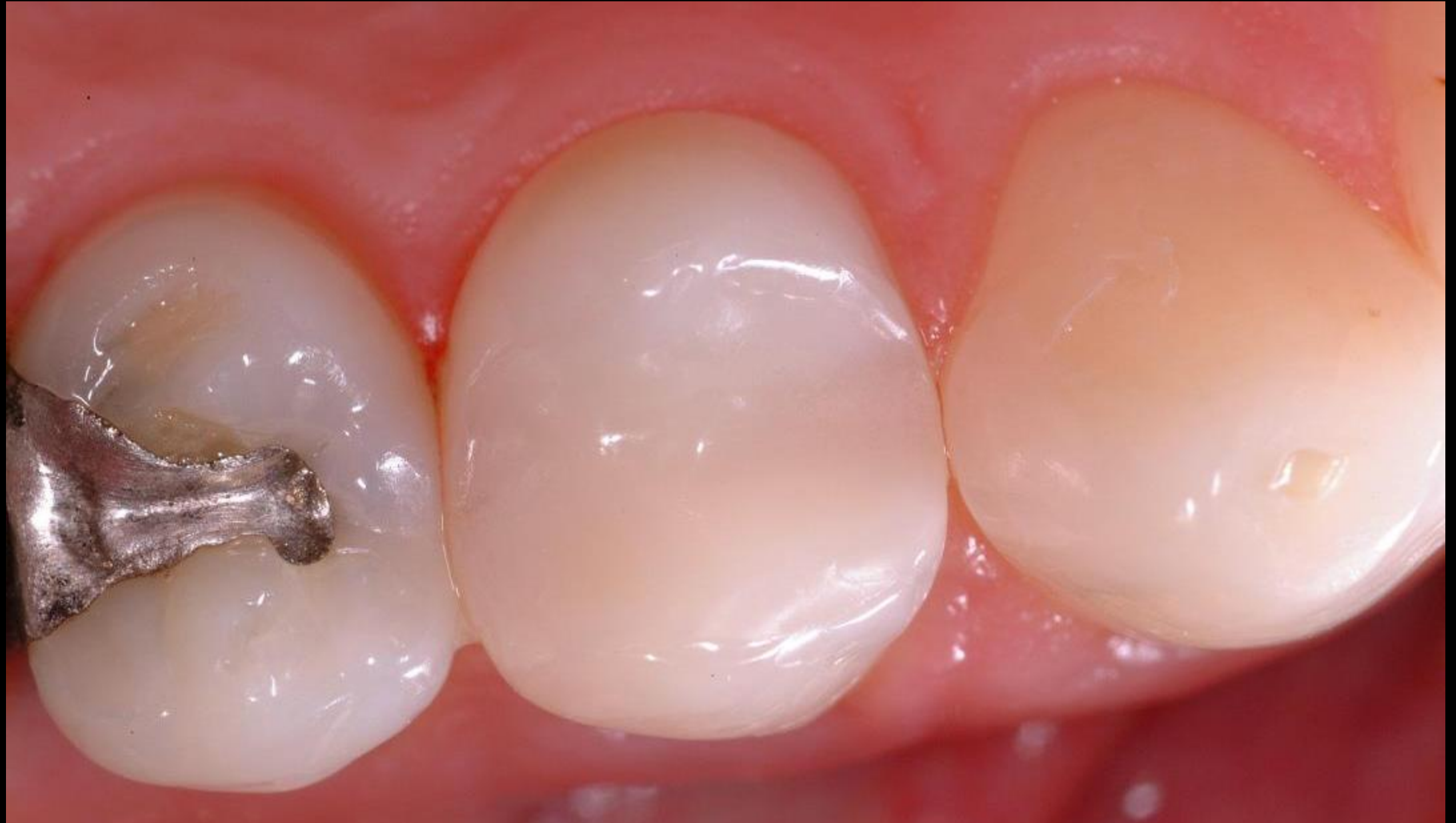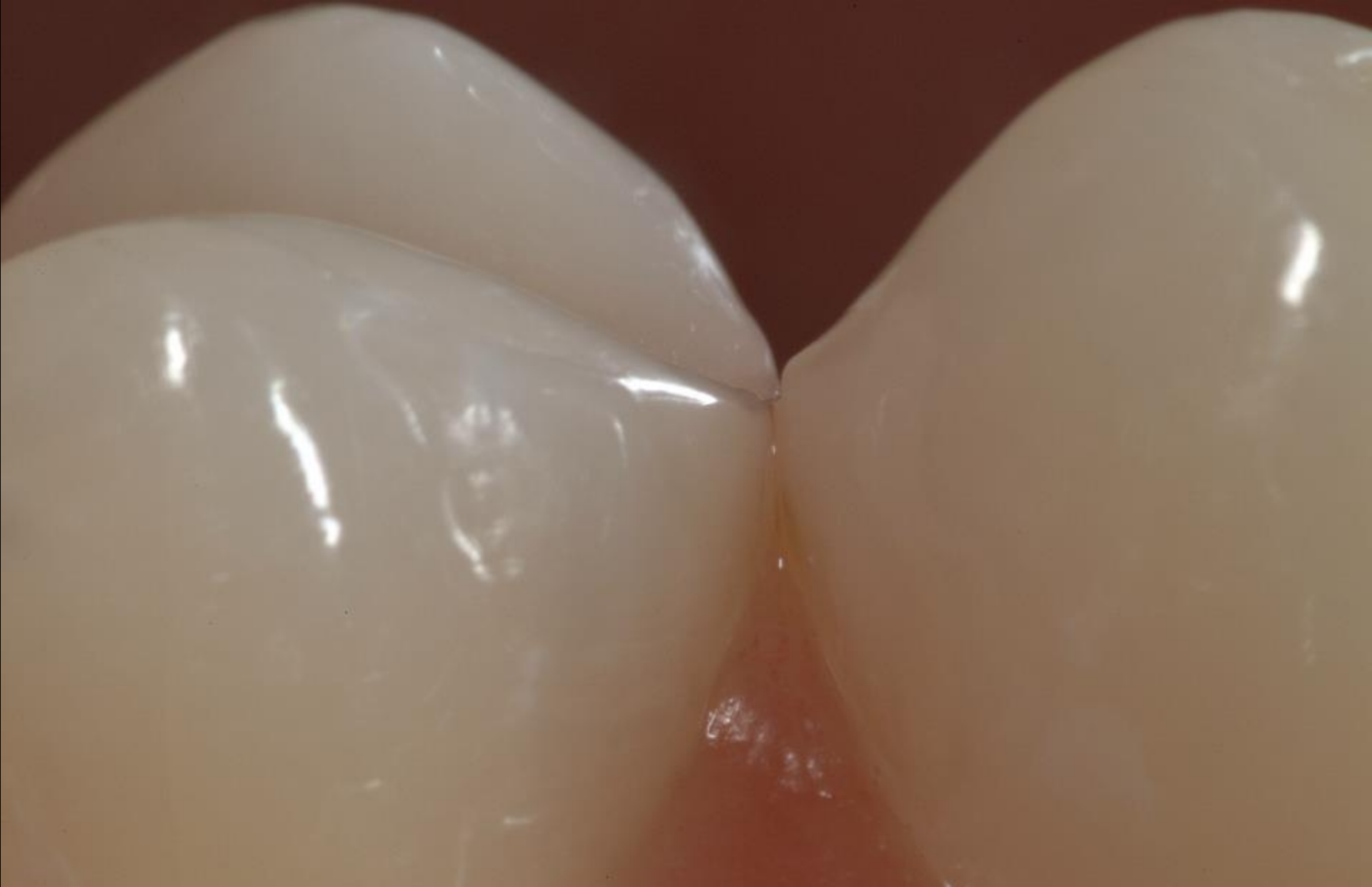Pre-op



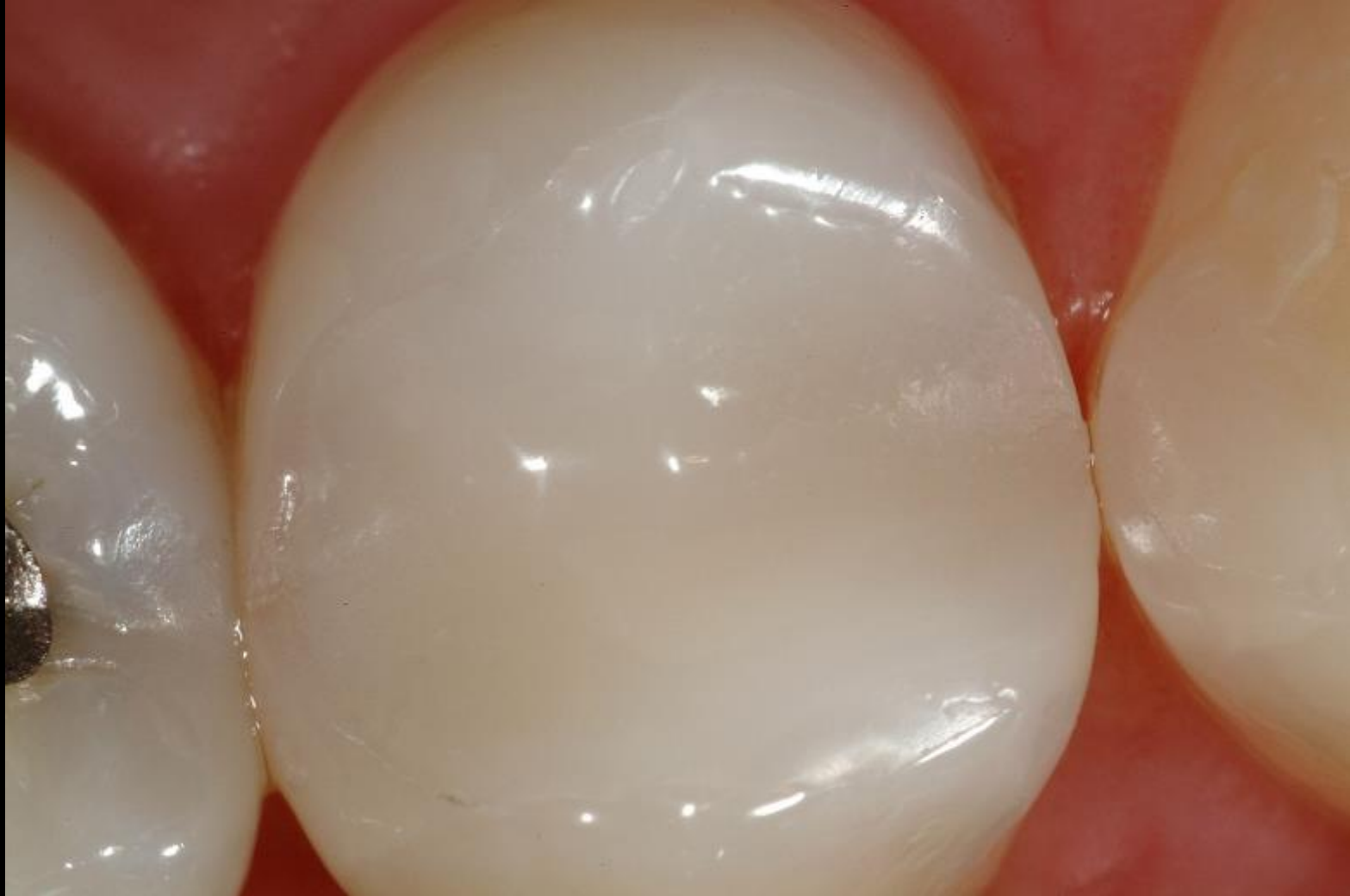1 year follow up



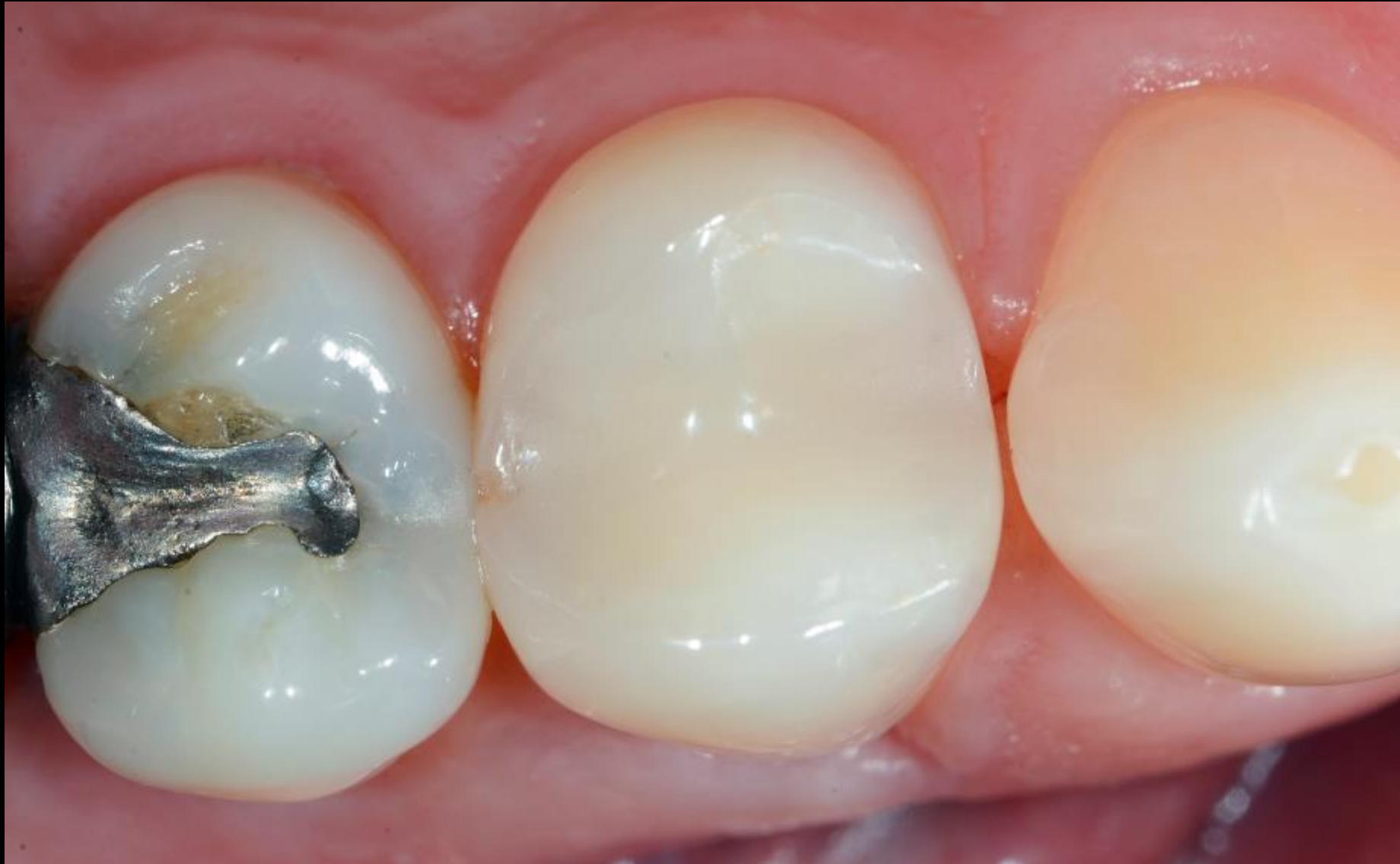1 year follow up



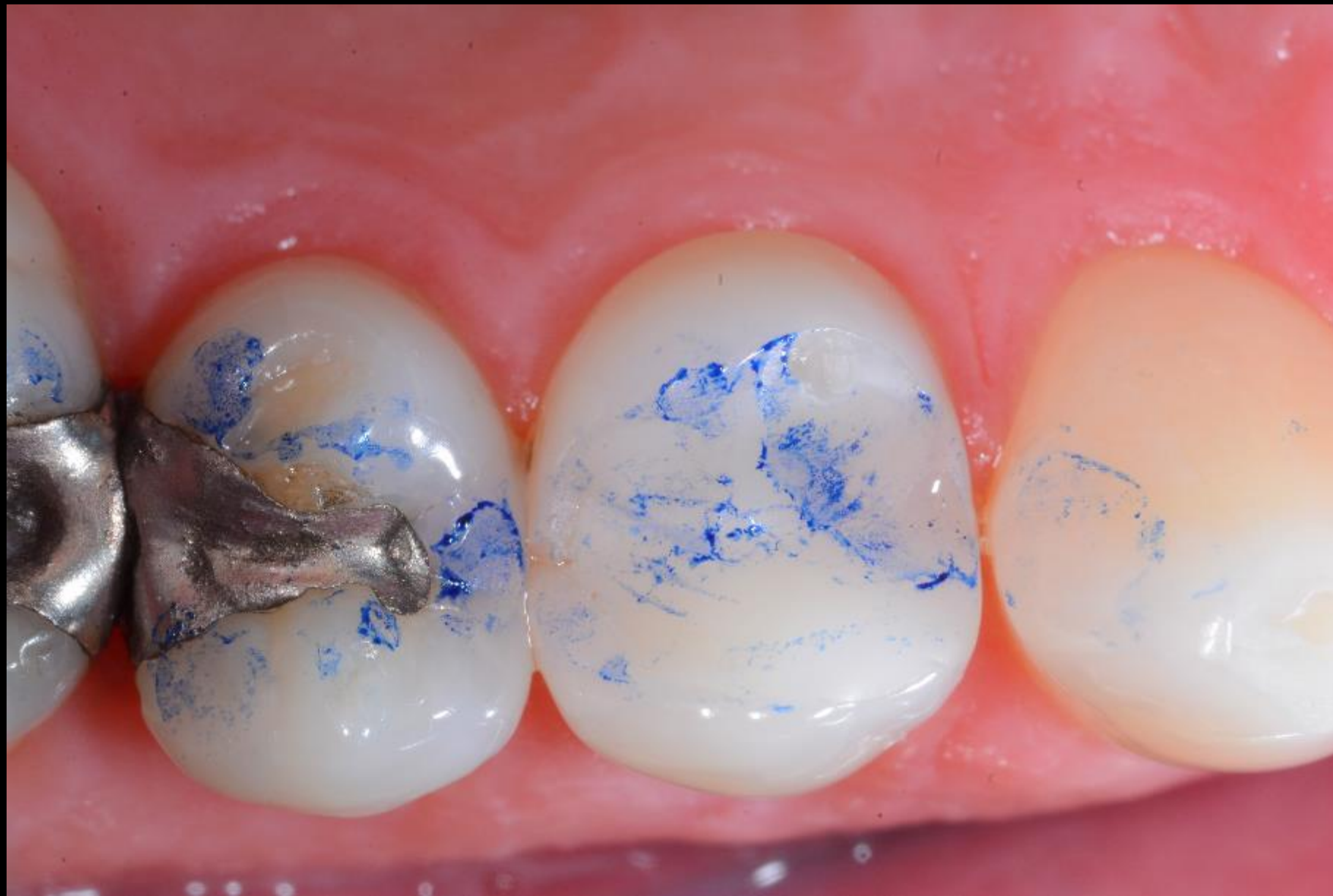2 year follow up



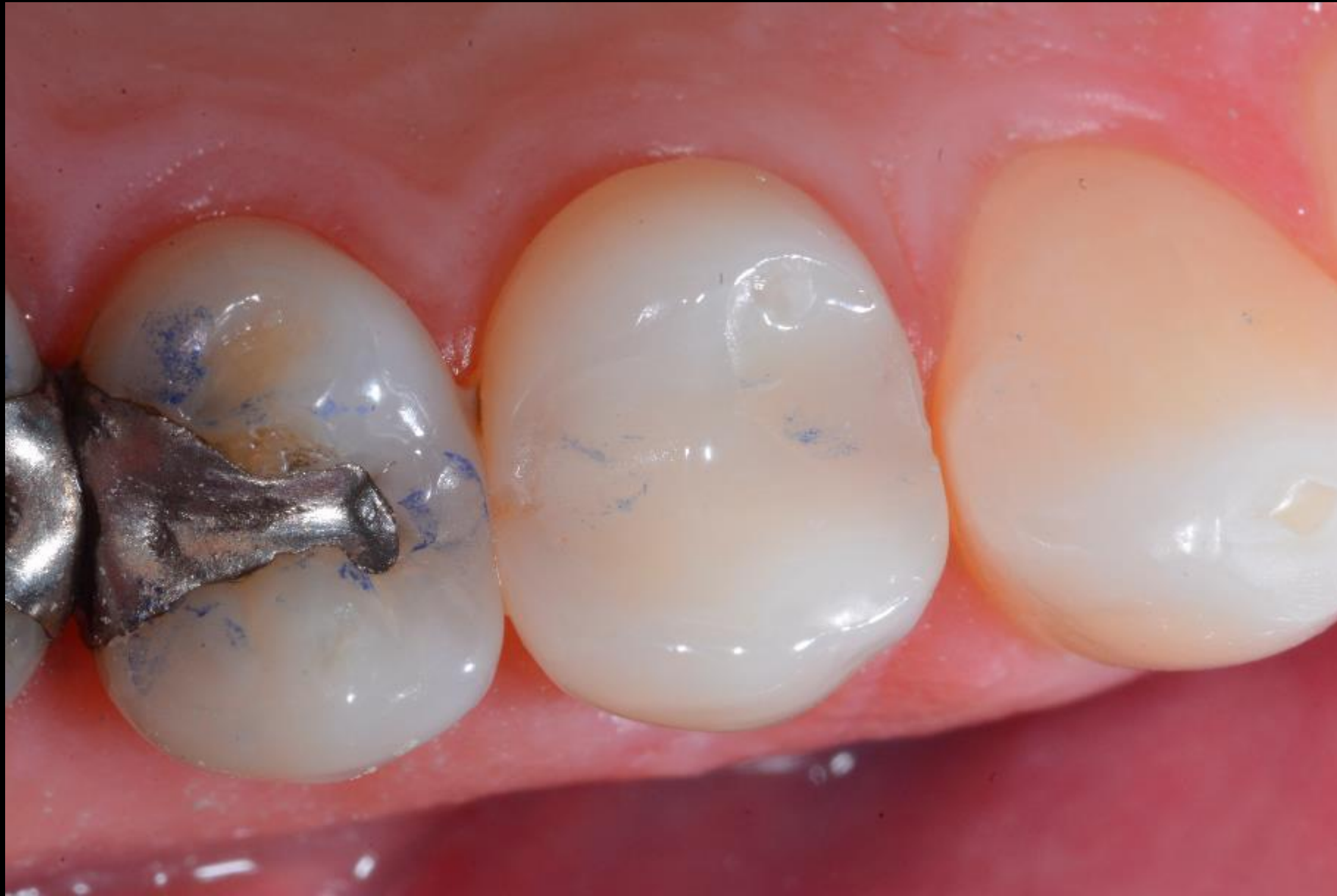7 year follow up



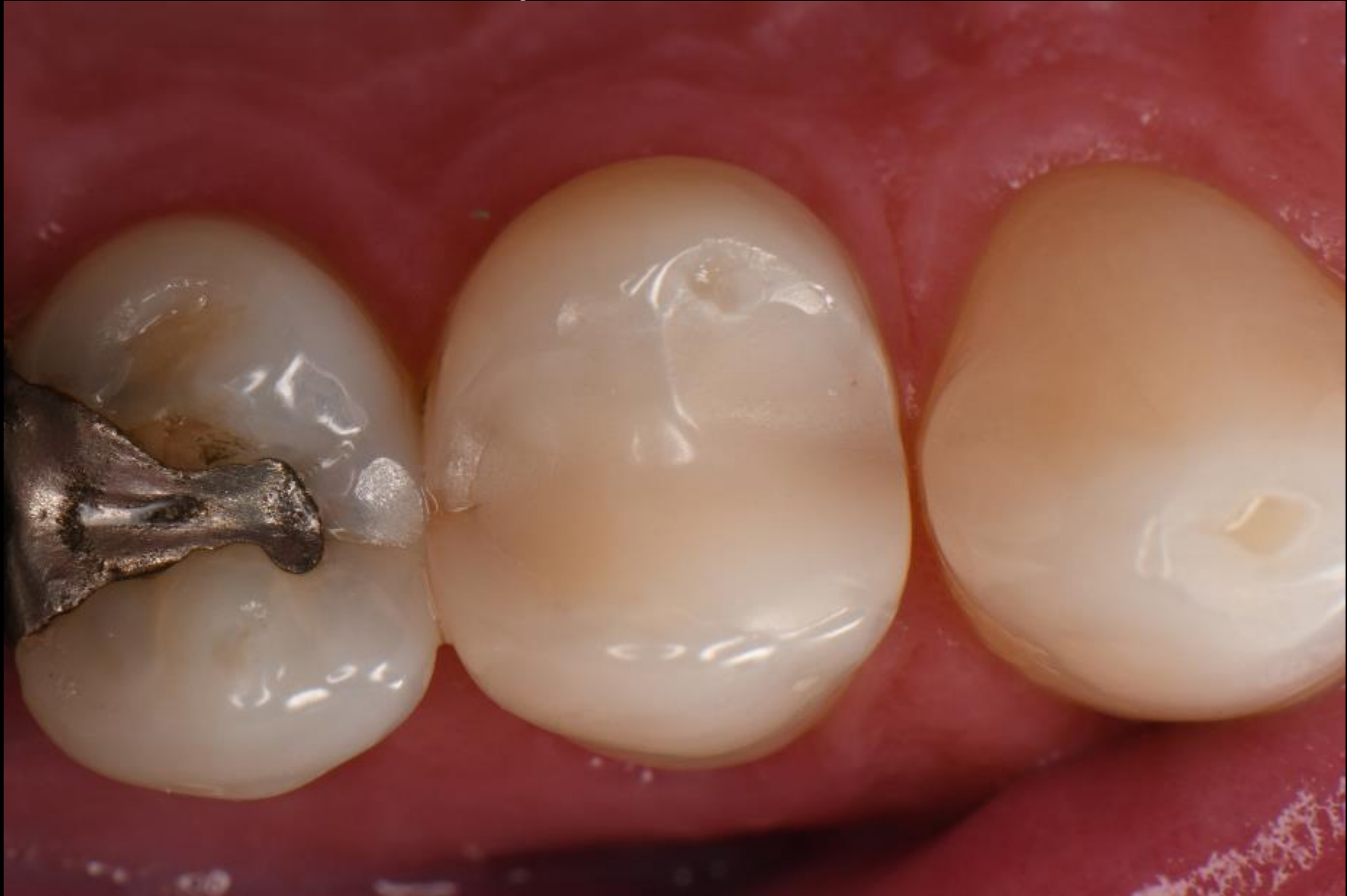9 year follow up



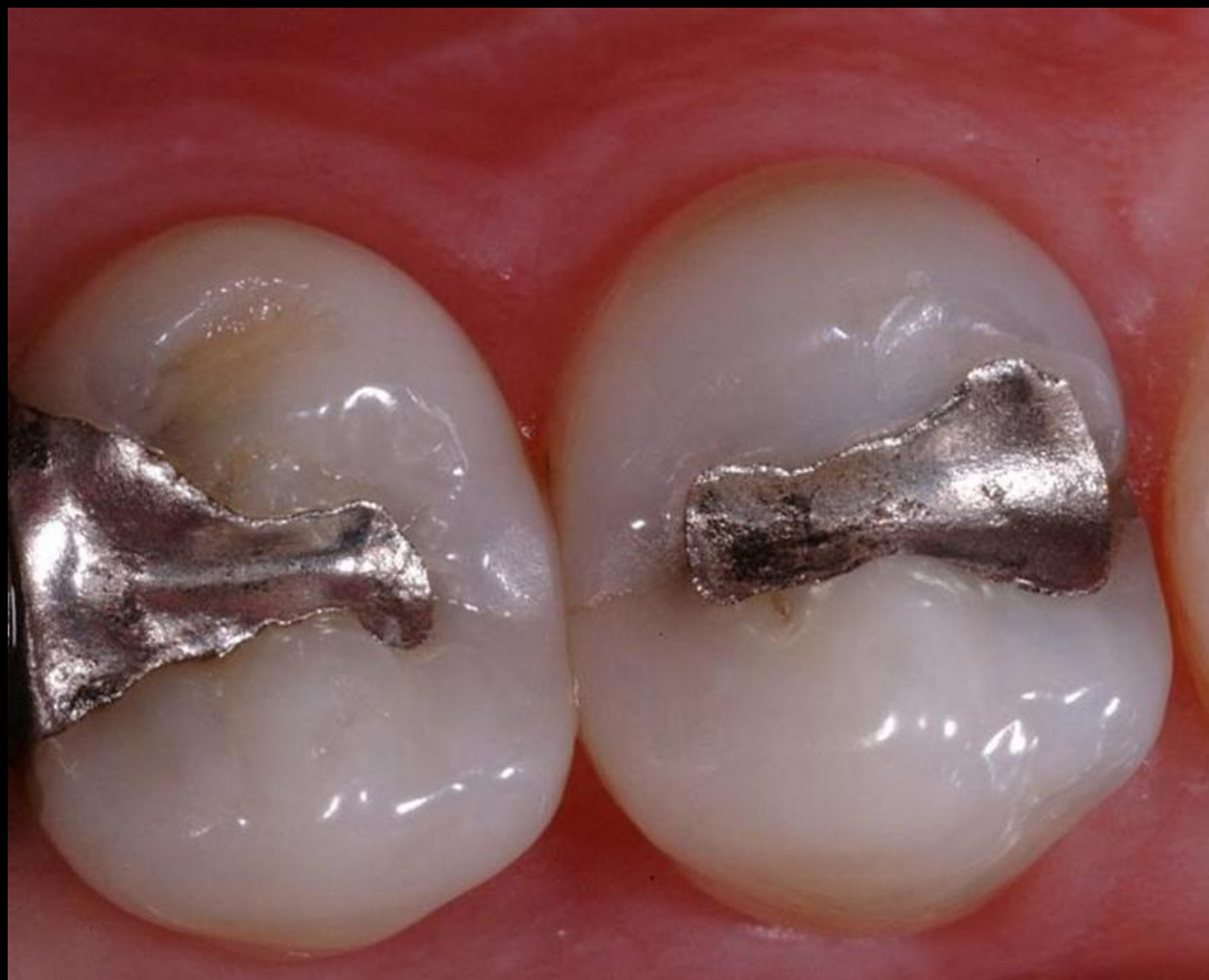9 year follow up



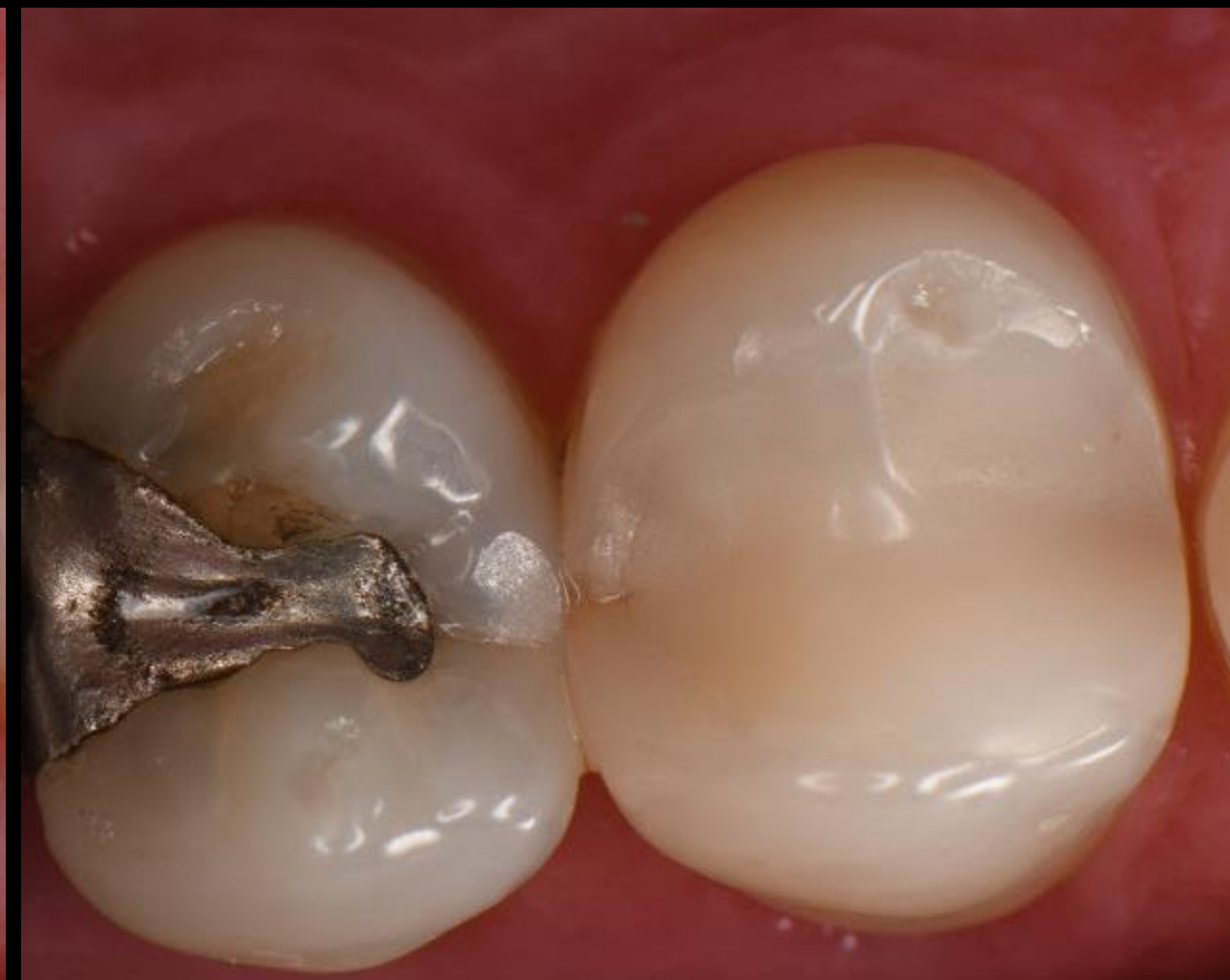12 year follow up



Pre-op



12 year follow up



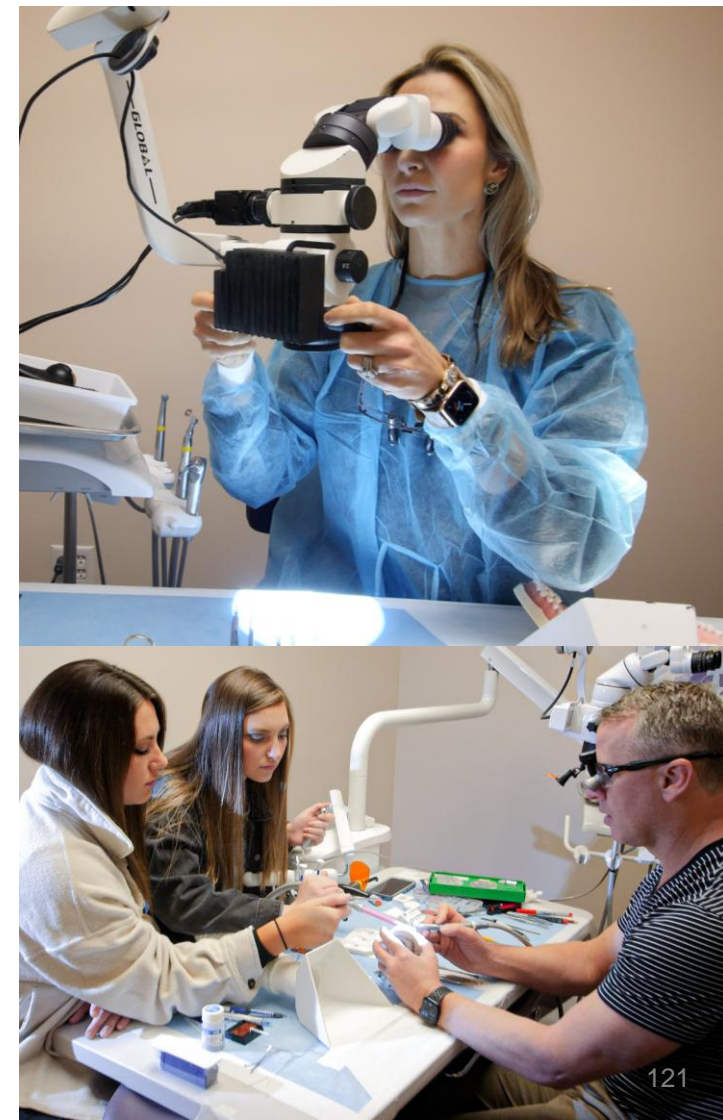
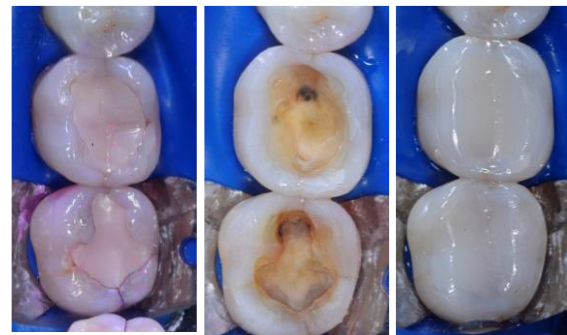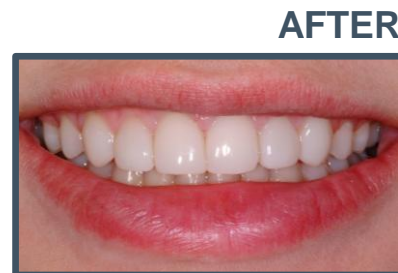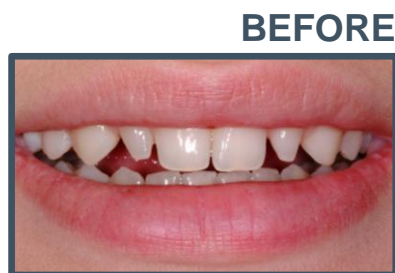
4-DAY CORE ANTERIOR & POSTERIOR COURSE

36 CE CREDITS

This course builds a strong foundation in the Bioclear Method and an understanding of Bioclear products. The focus of the course is indirect methods on adult dentitions as an alternative procedure to porcelain crowns and veneers.

Students will learn the foundation of posterior and anterior restorations and are introduced to the engineering principles involved in the design of the new non-retentive compression-based preps. Students collaboratively practice all applications of the Bioclear Method during intensive, hands-on exercises that simulate posterior and anterior restorations.

LEARN MORE



Last week's attendees at the certification course



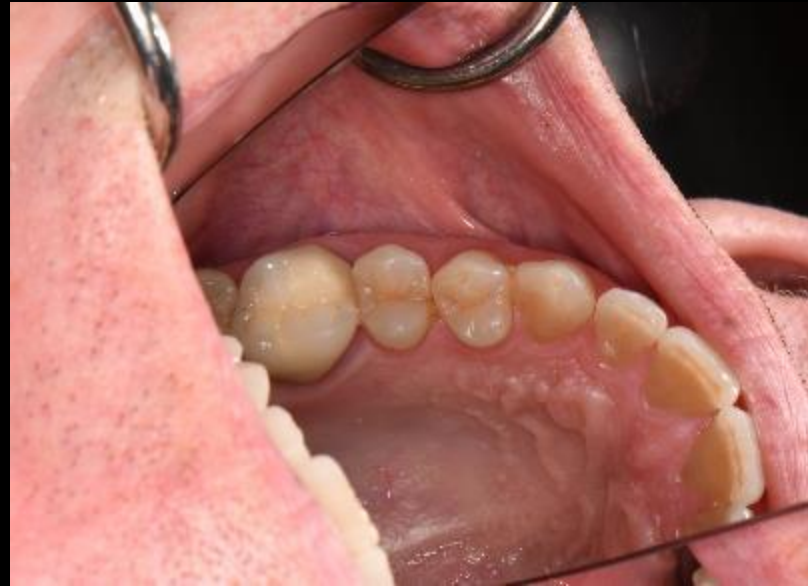To get access to an extensive library of these techniques in video and slides format email us:

lectures@bioclearmatrix.com

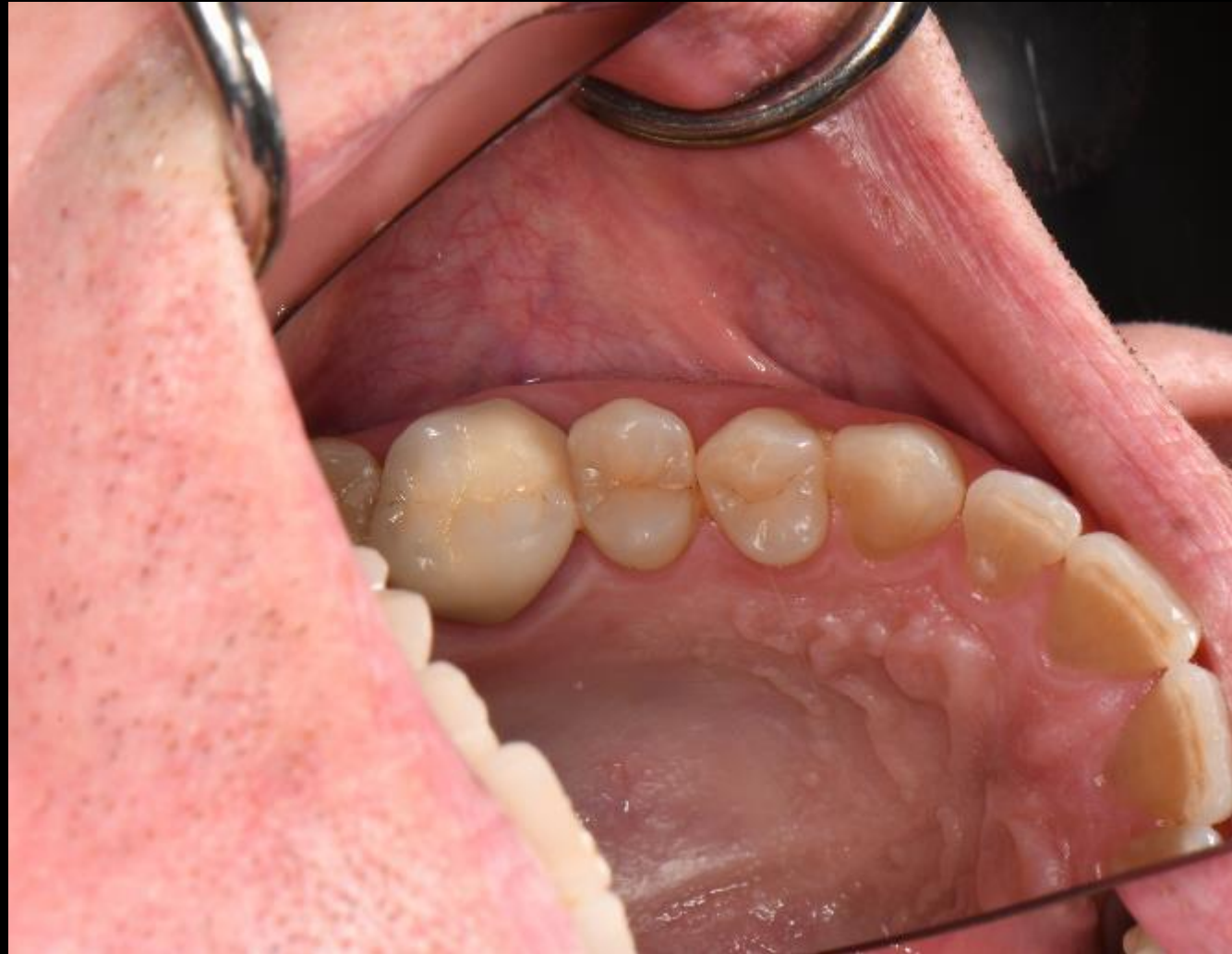joshua@bioclearmatrix.com

drclark@bioclearmatrix.com

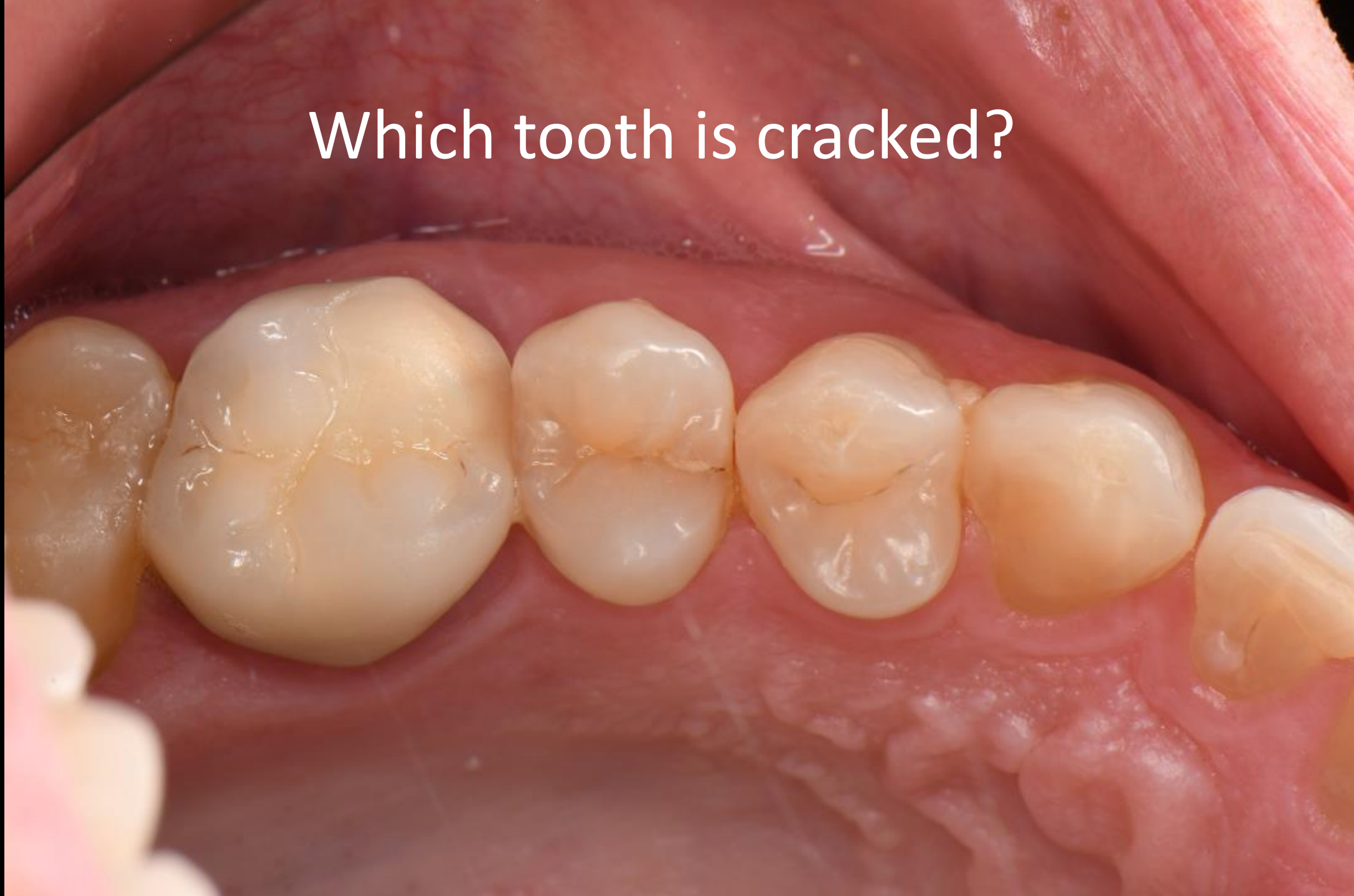
Which tooth is cracked?



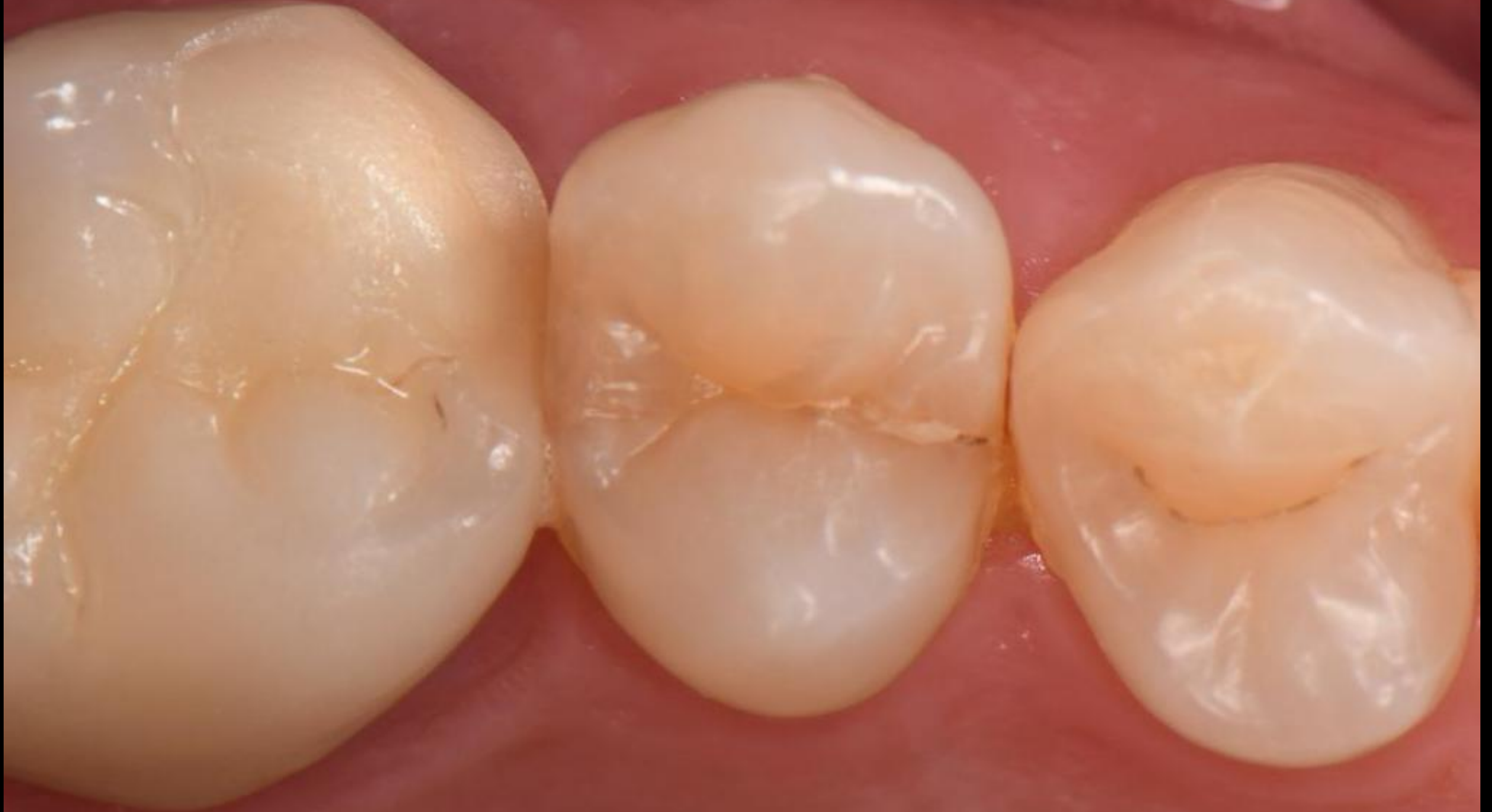Which tooth is cracked?



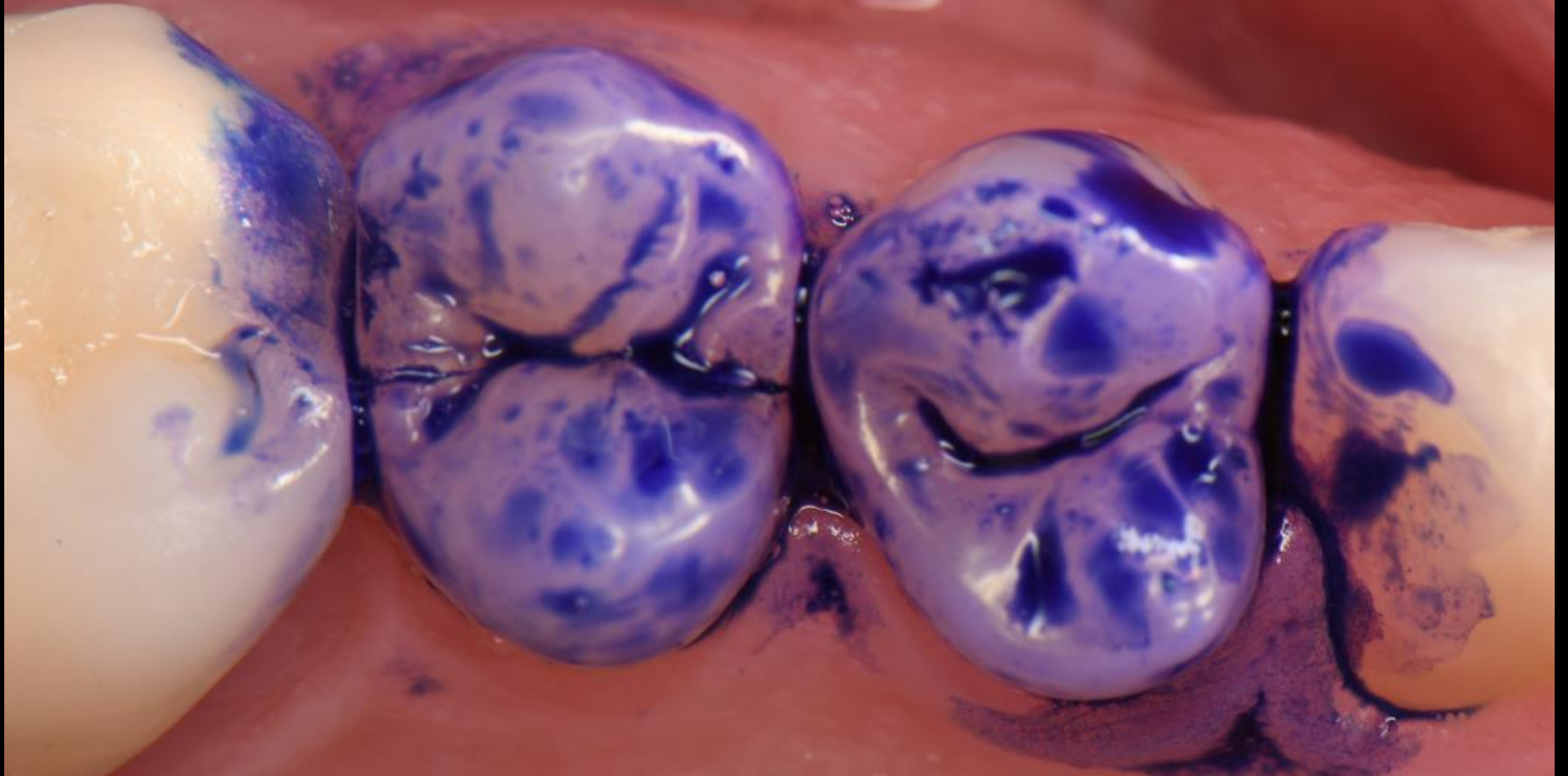Which tooth is cracked?

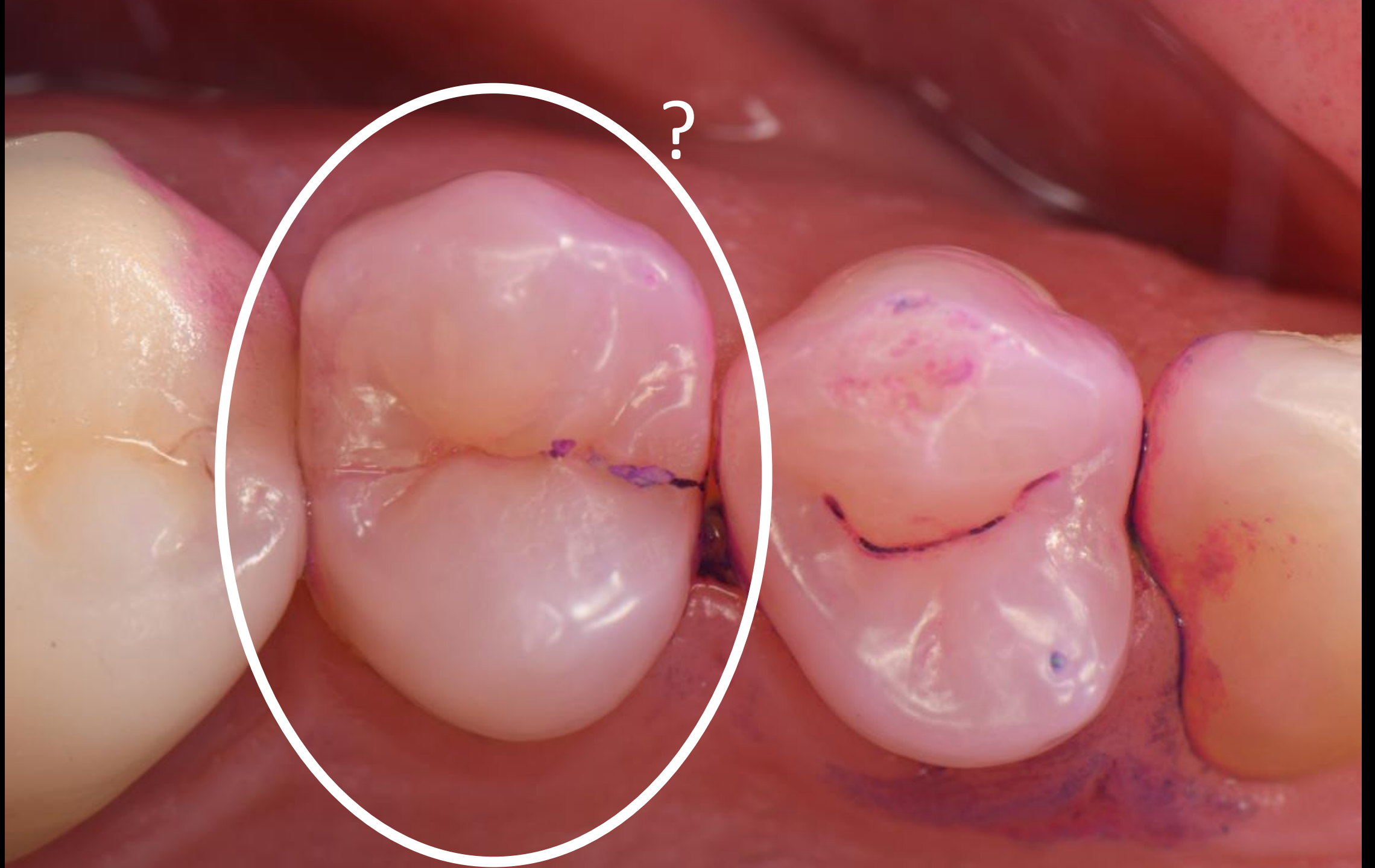


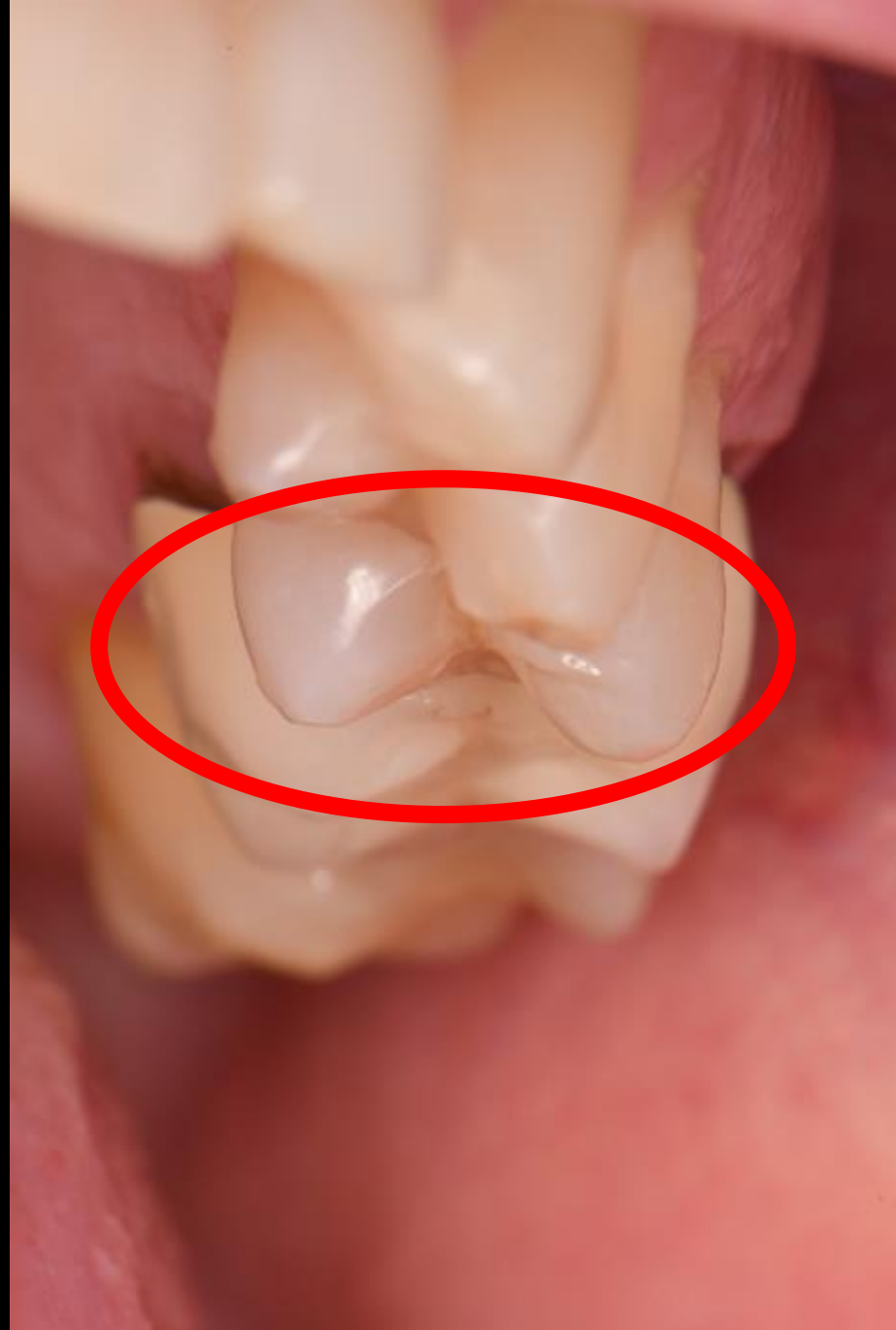Which tooth is cracked?

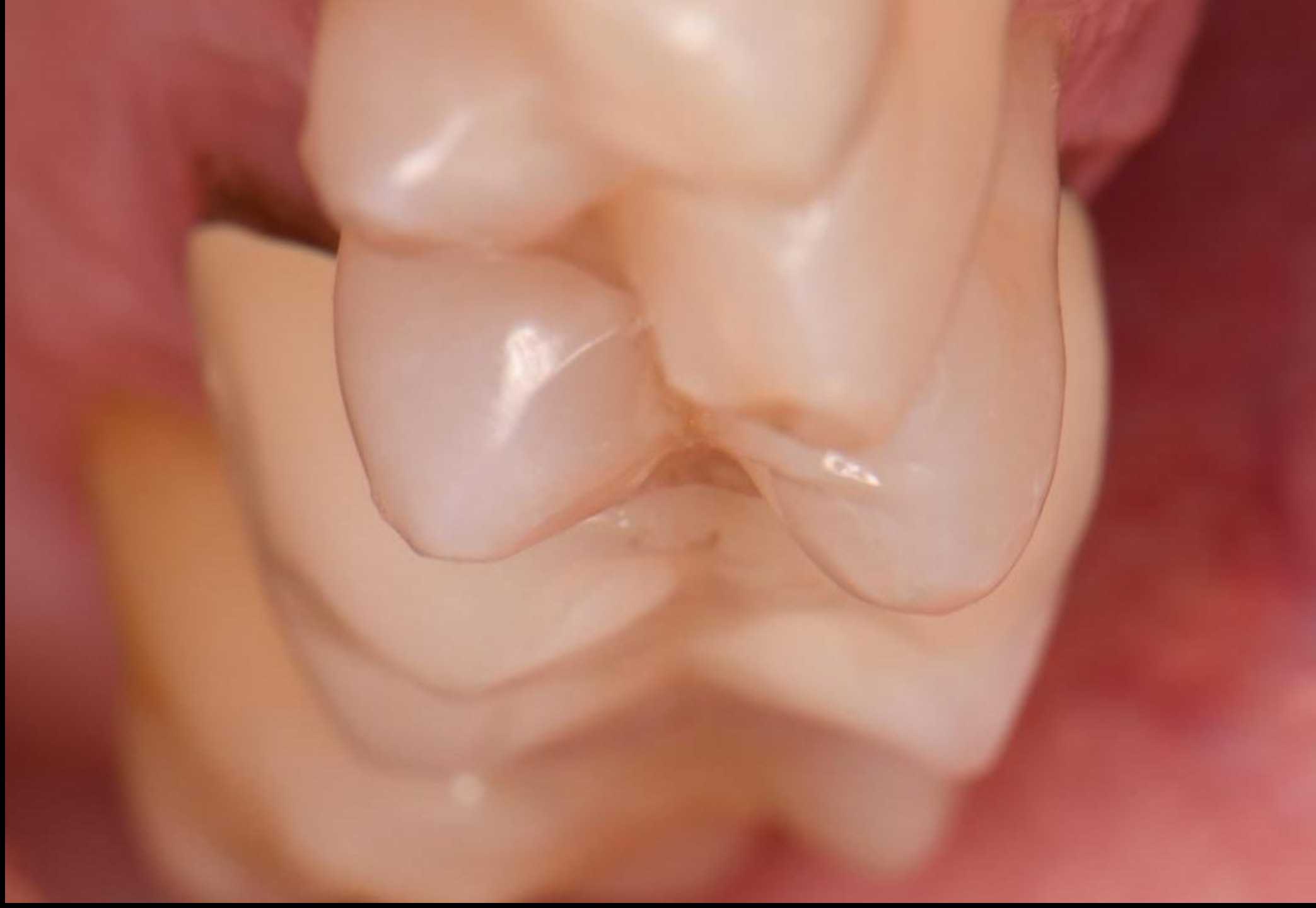

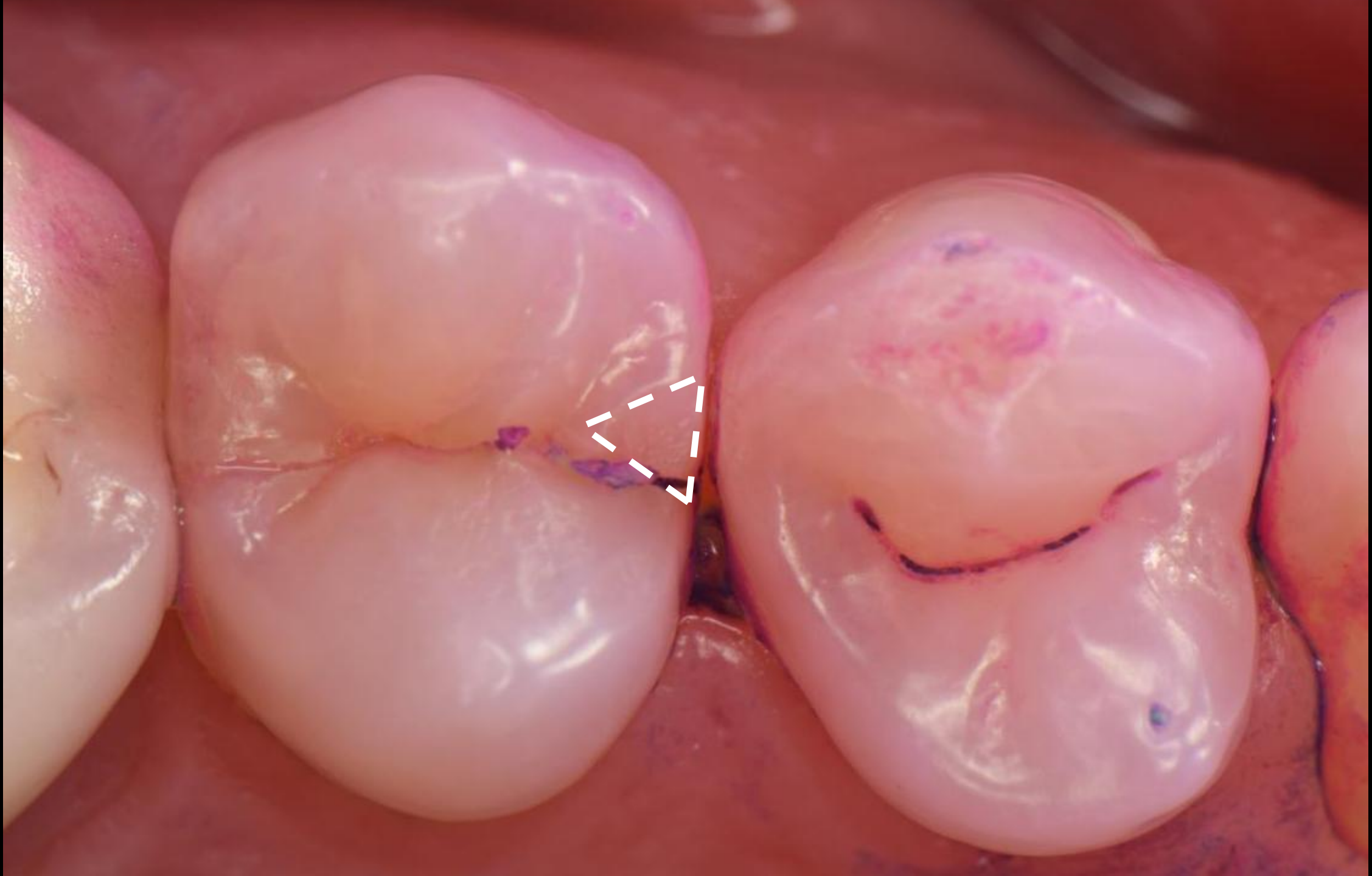?

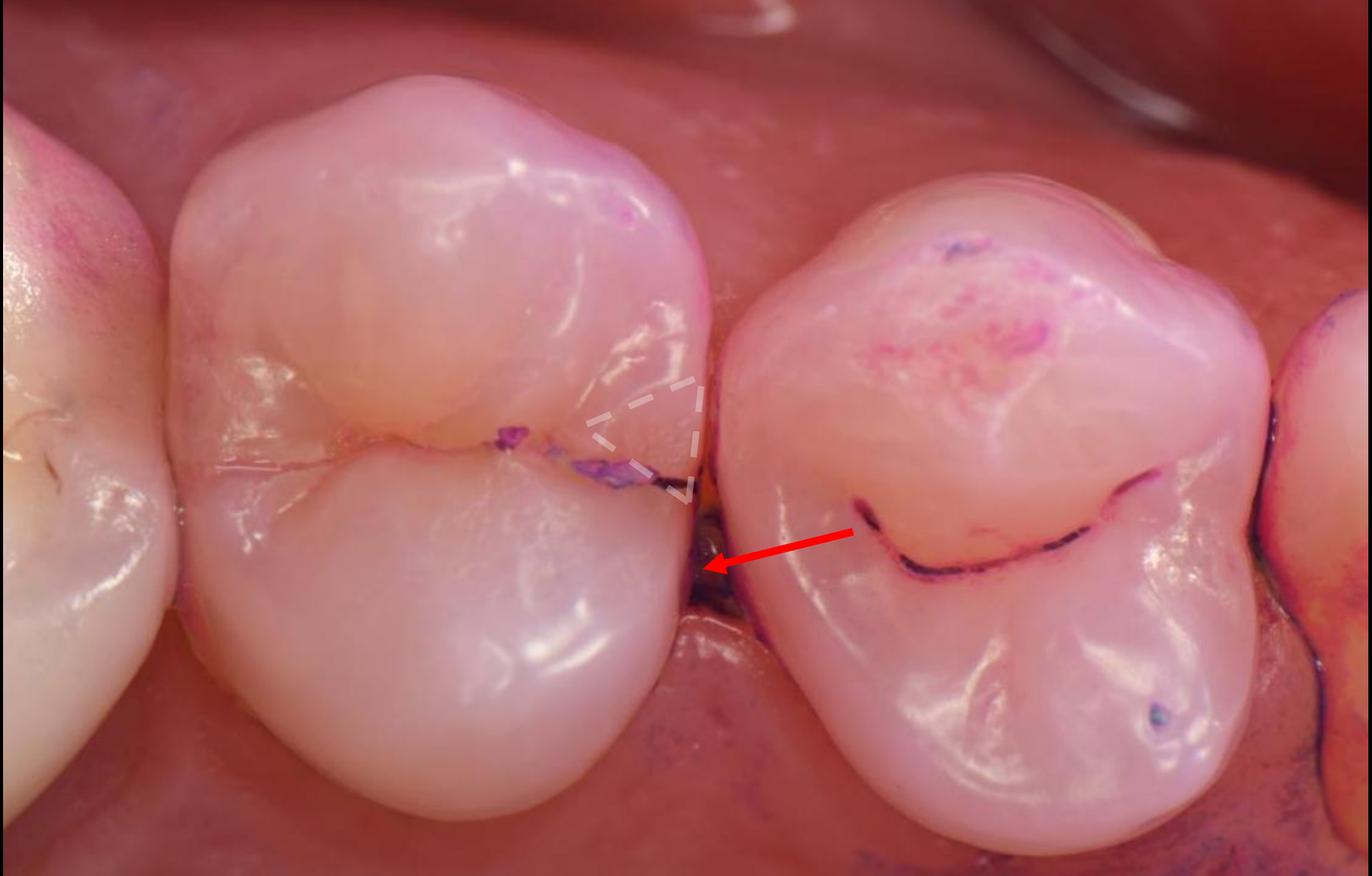


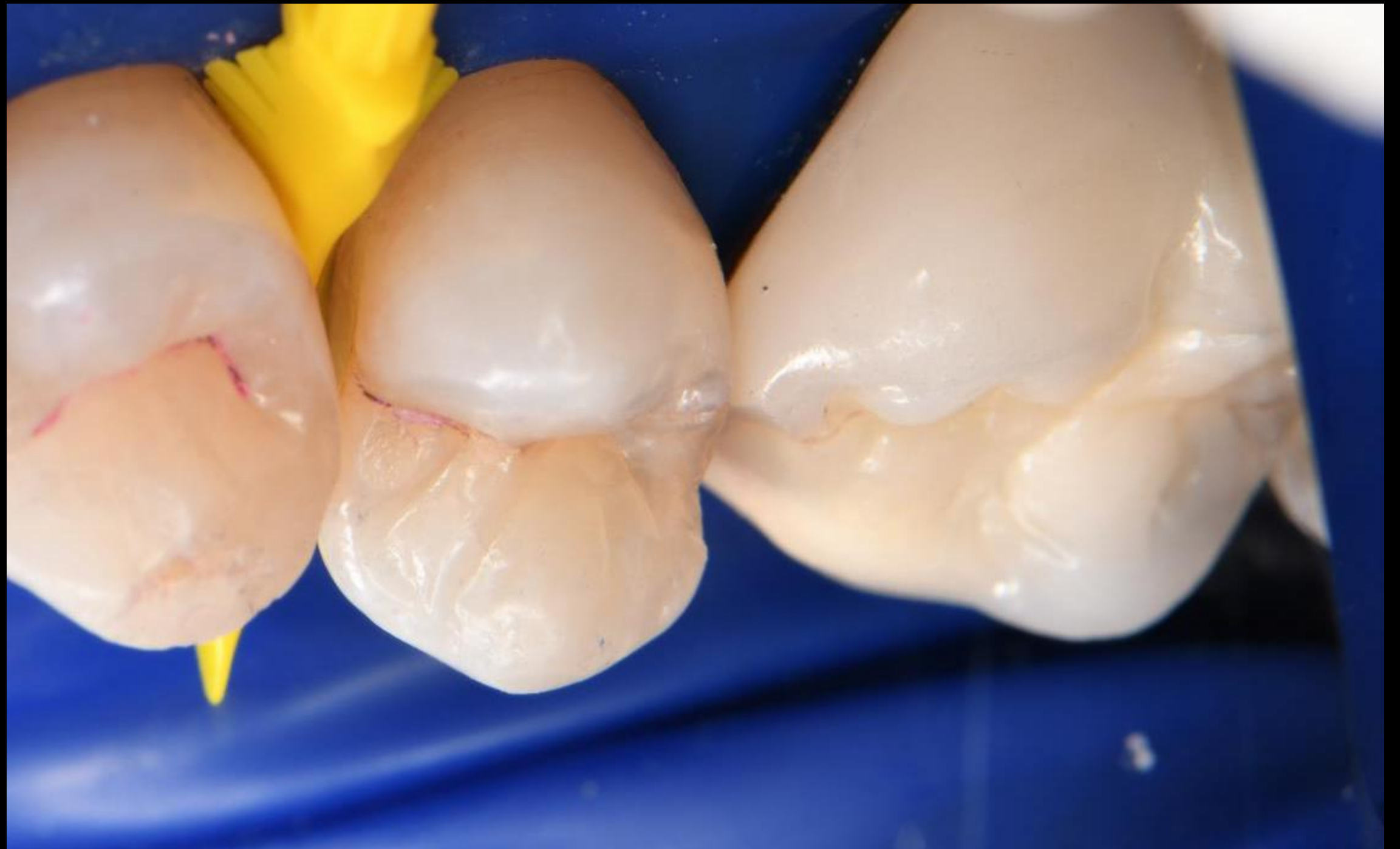


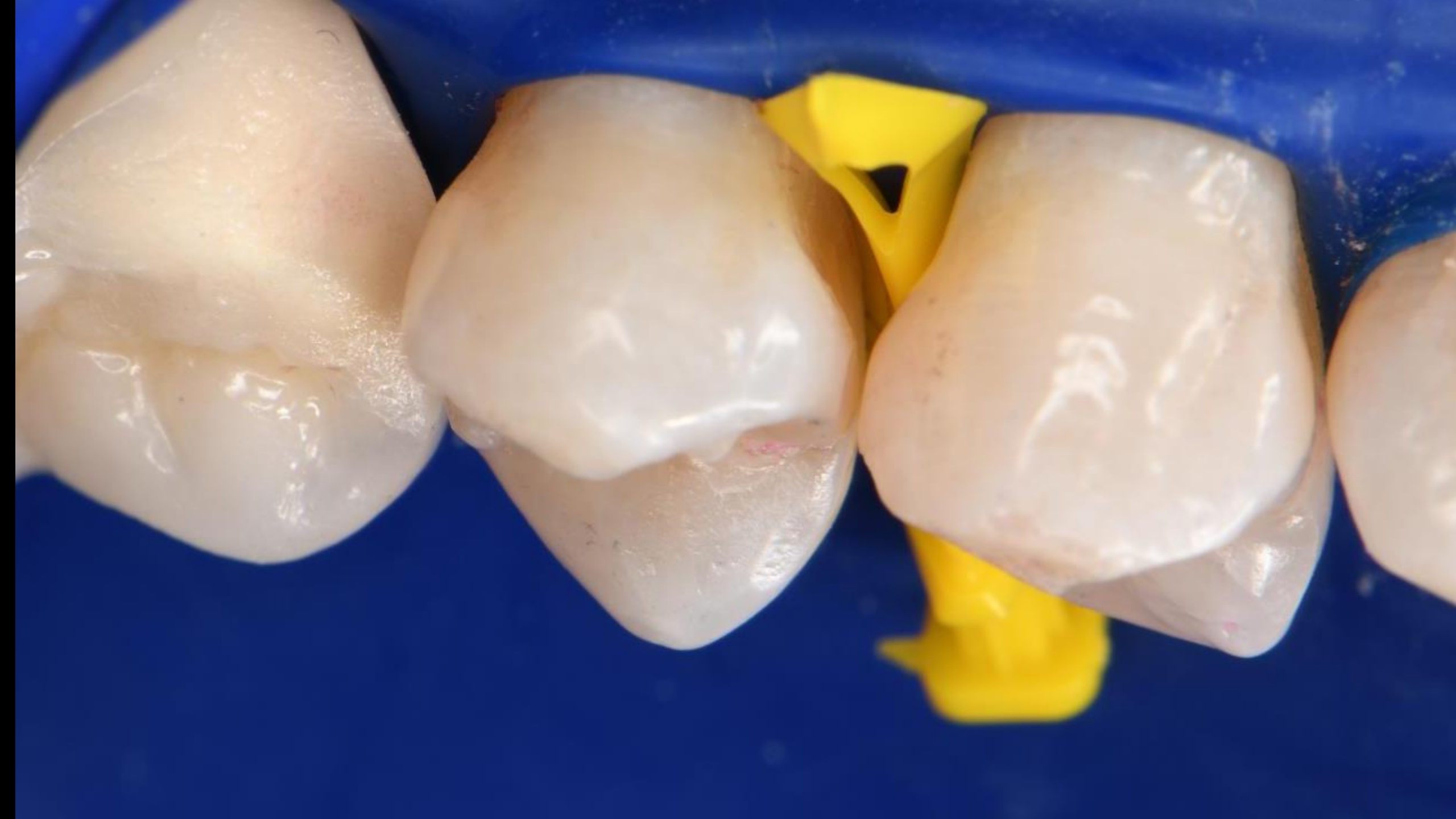


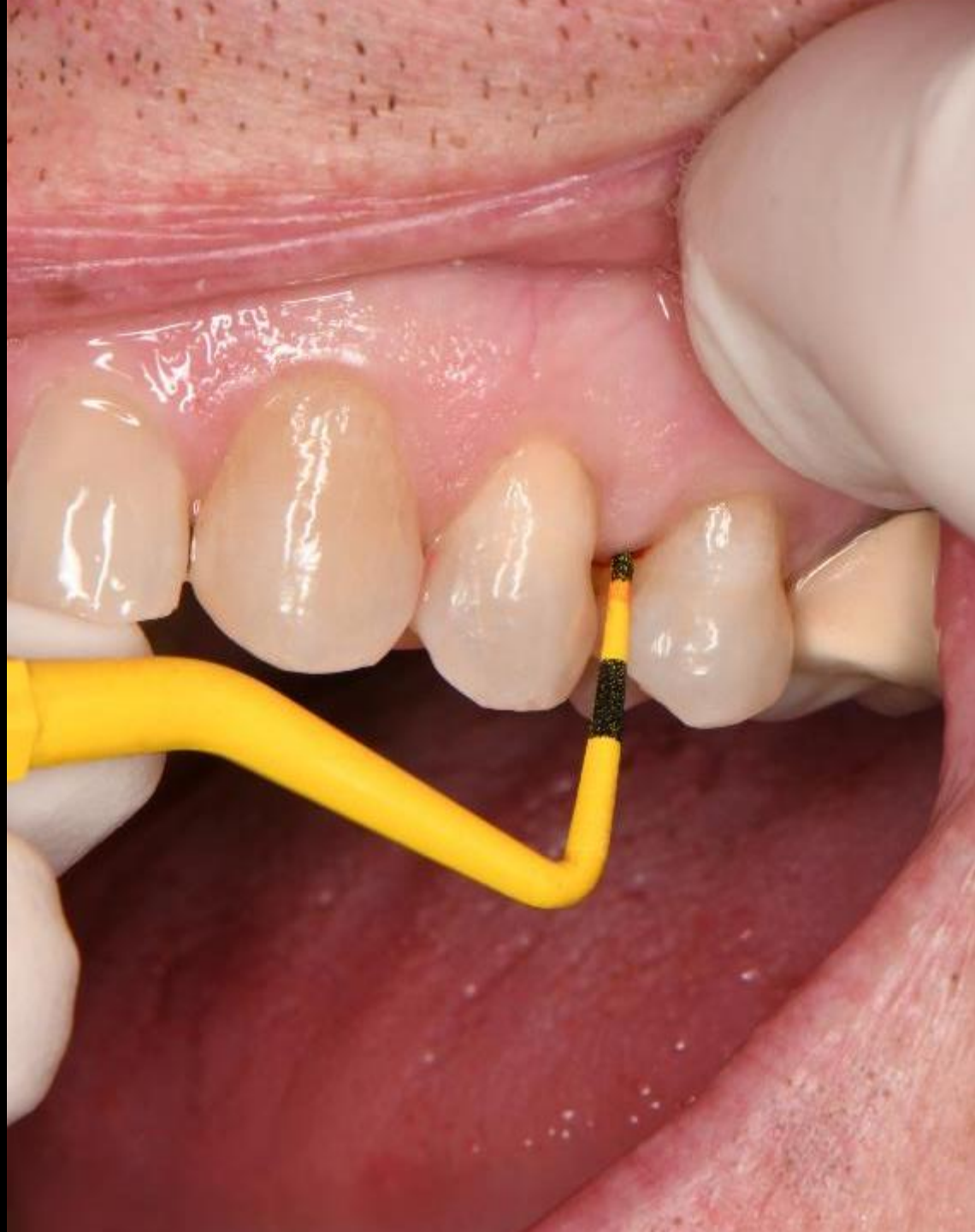







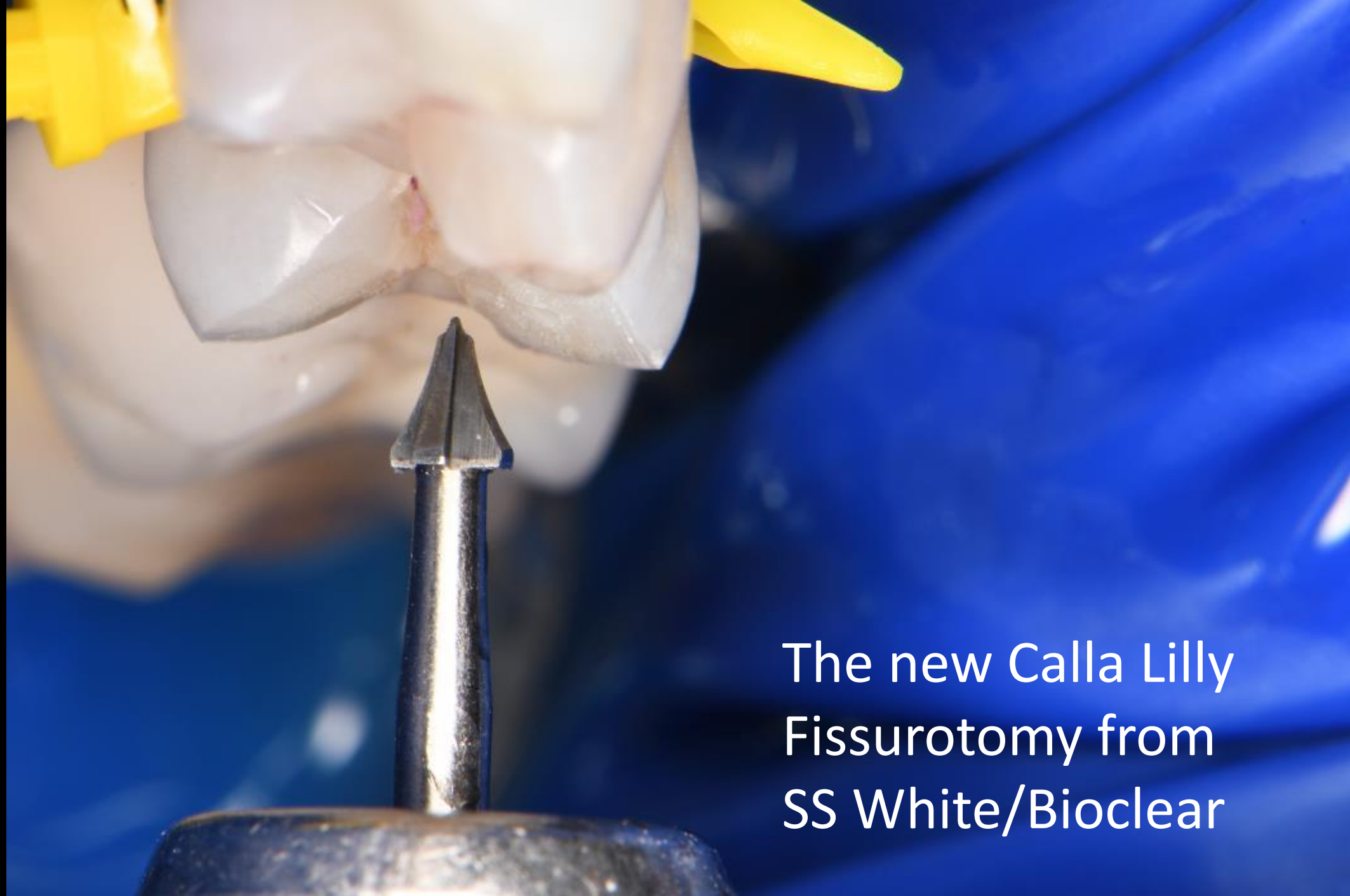


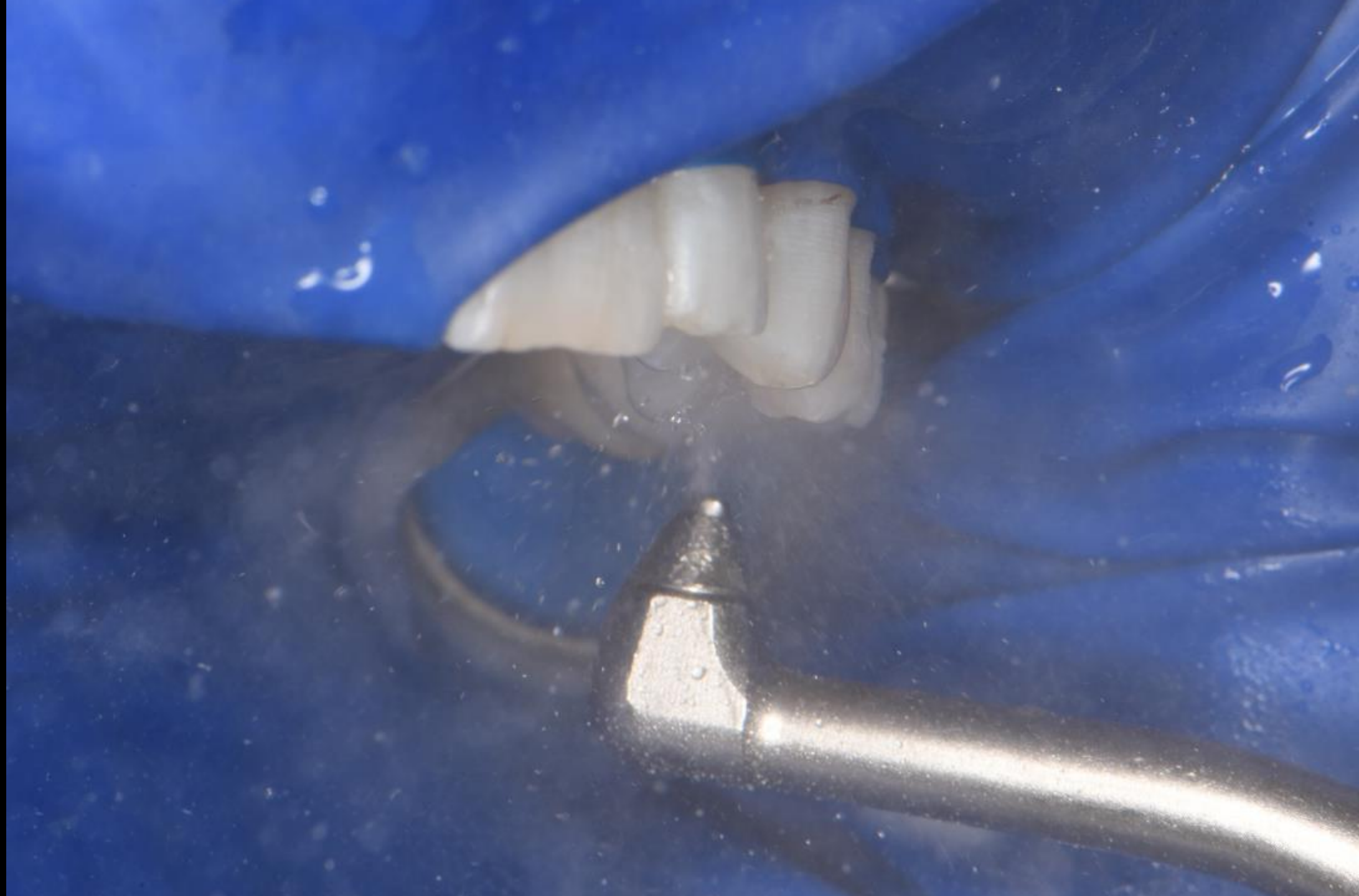A close-up photograph of a dental diamond bur being used on a white tooth model. The bur is a conical, textured metal tool mounted on a metal shaft. It is positioned against the lower part of a tooth. The background is a solid blue color. The text 'The new Calla Lilly Diamonds from SS White/Bioclear' is overlaid in the bottom left corner.

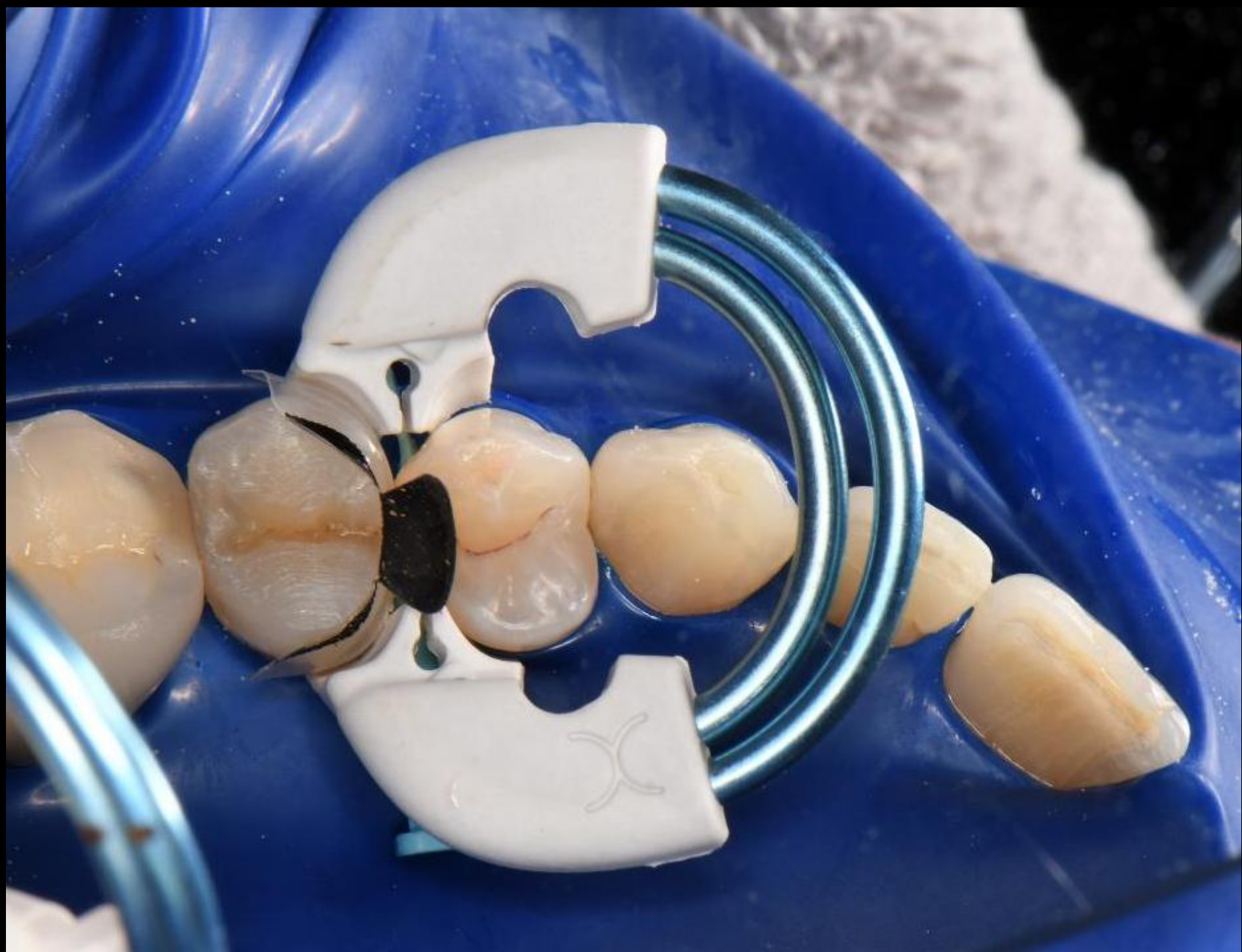The new Calla Lilly
Diamonds from SS
White/Bioclear

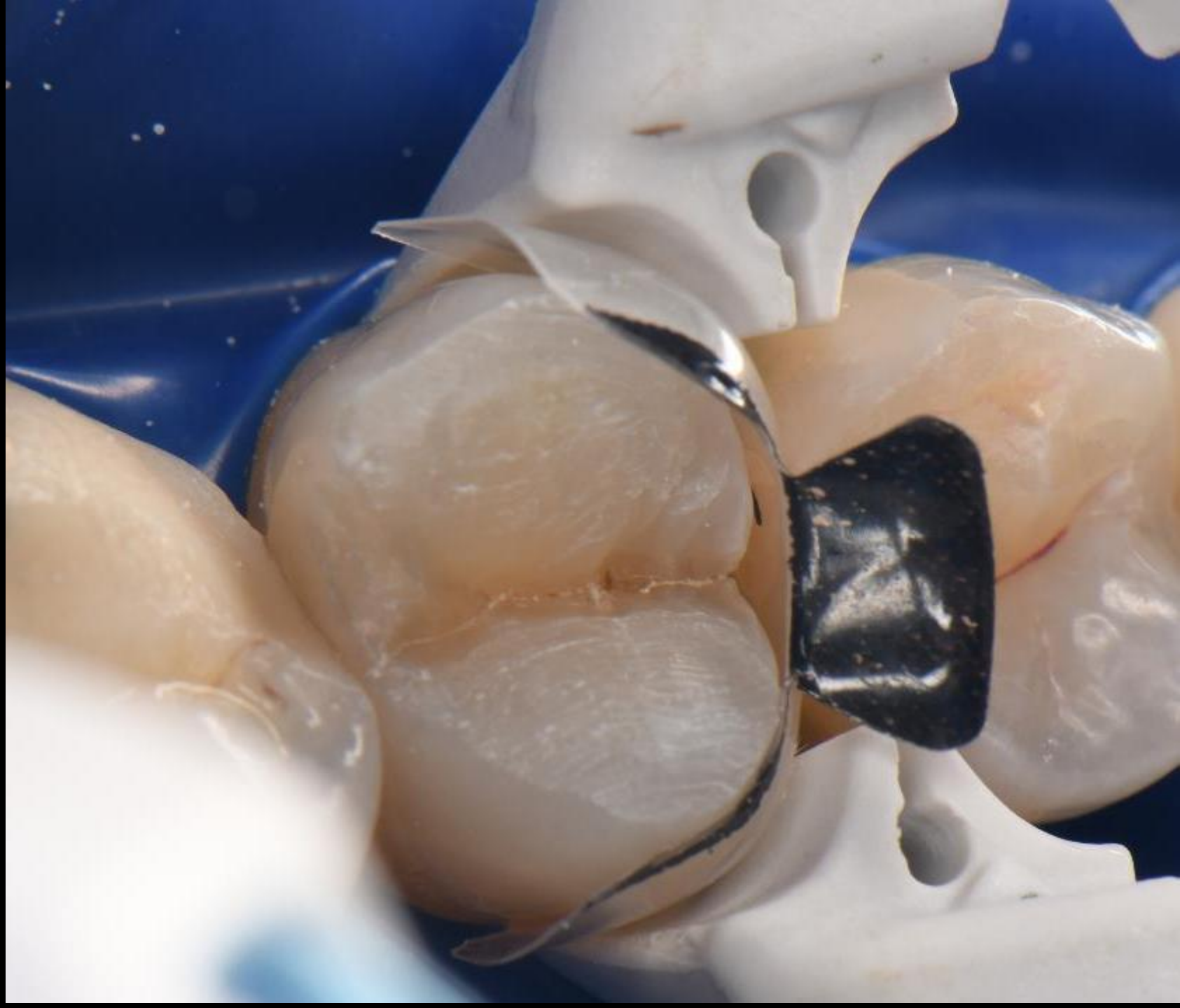

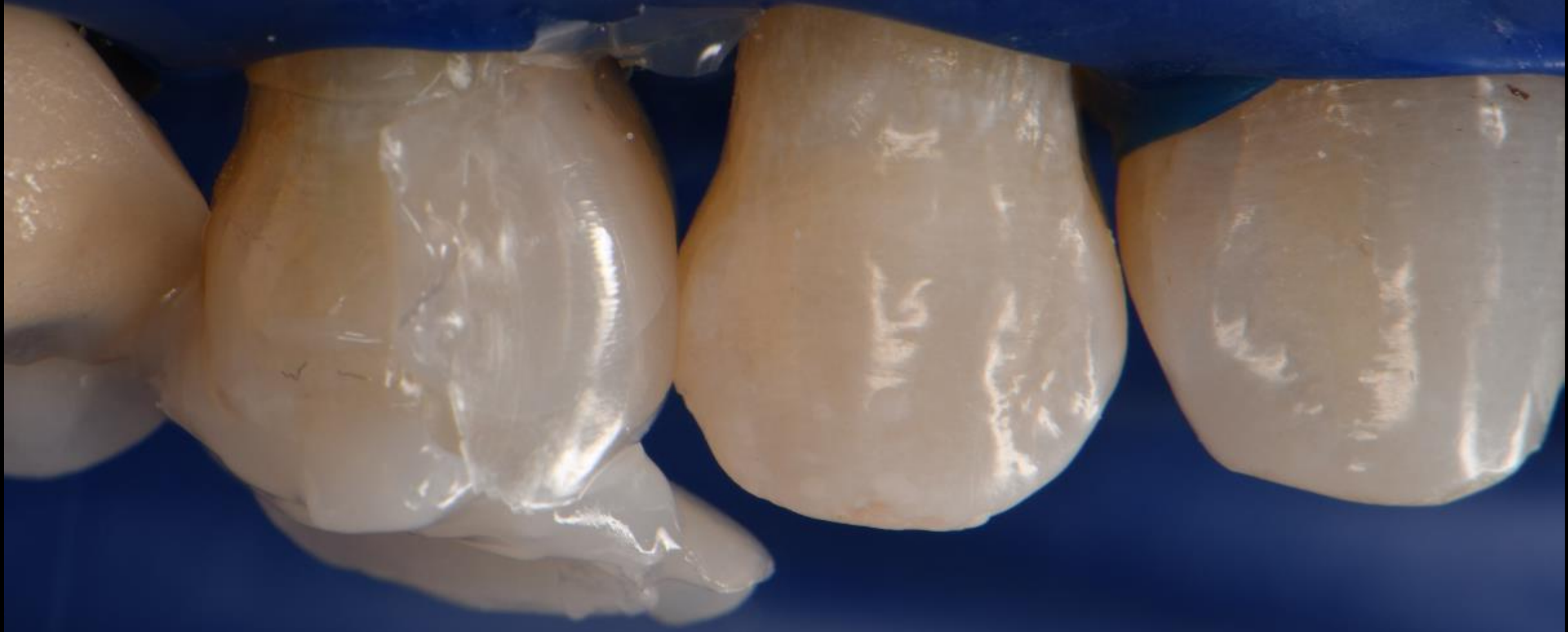The new Calla Lilly
Fissurotomy from
SS White/Bioclear

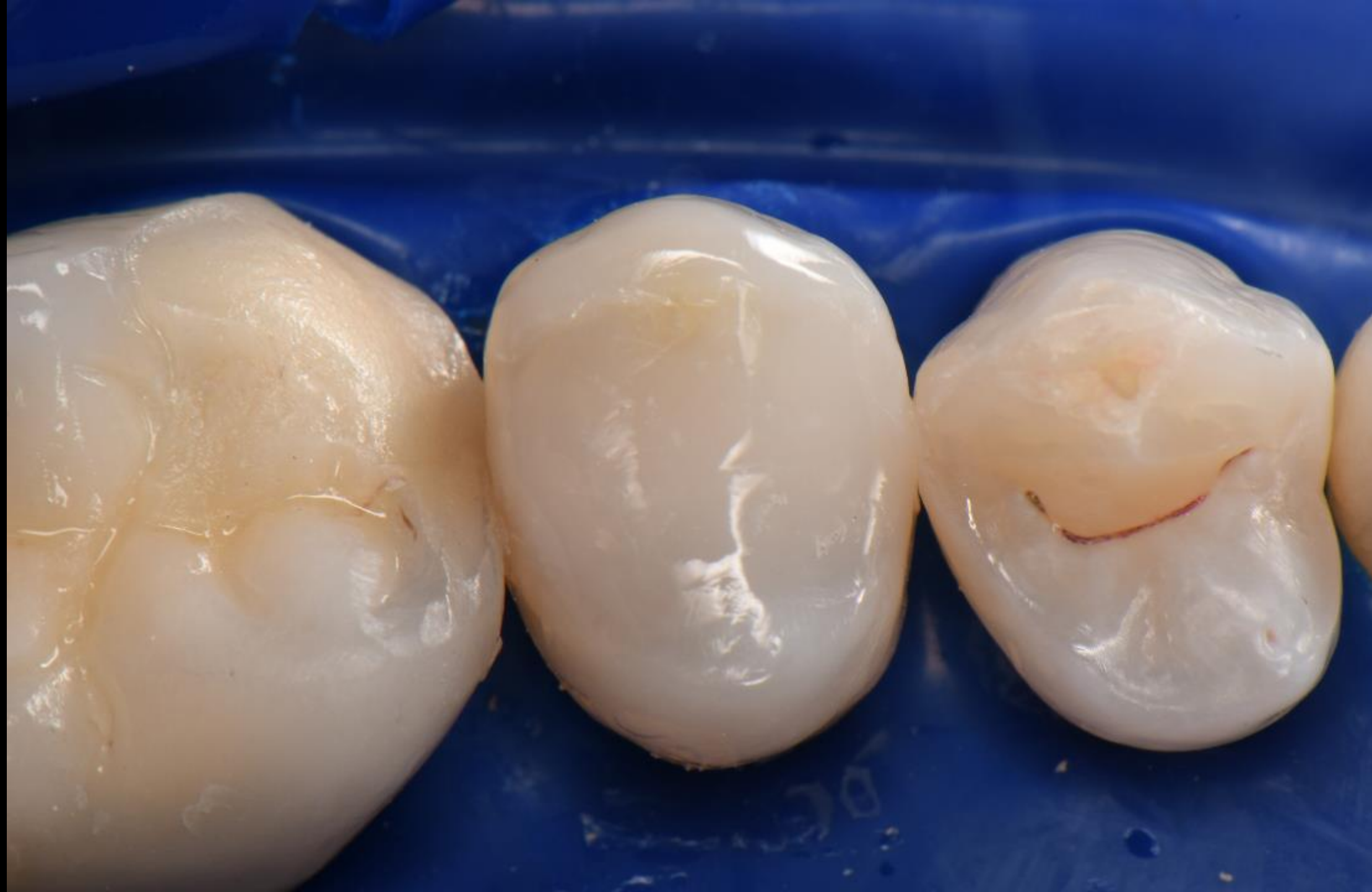


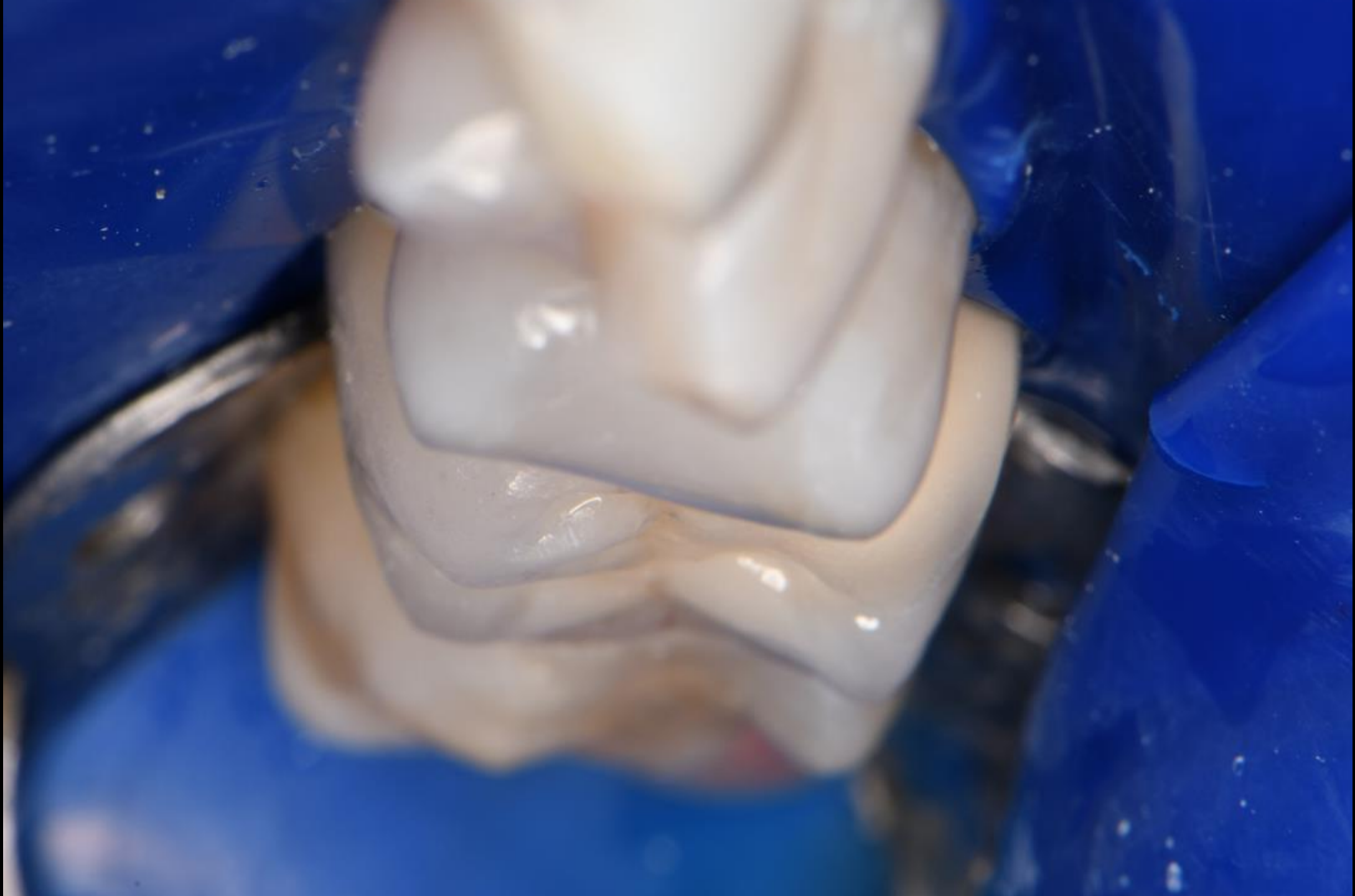


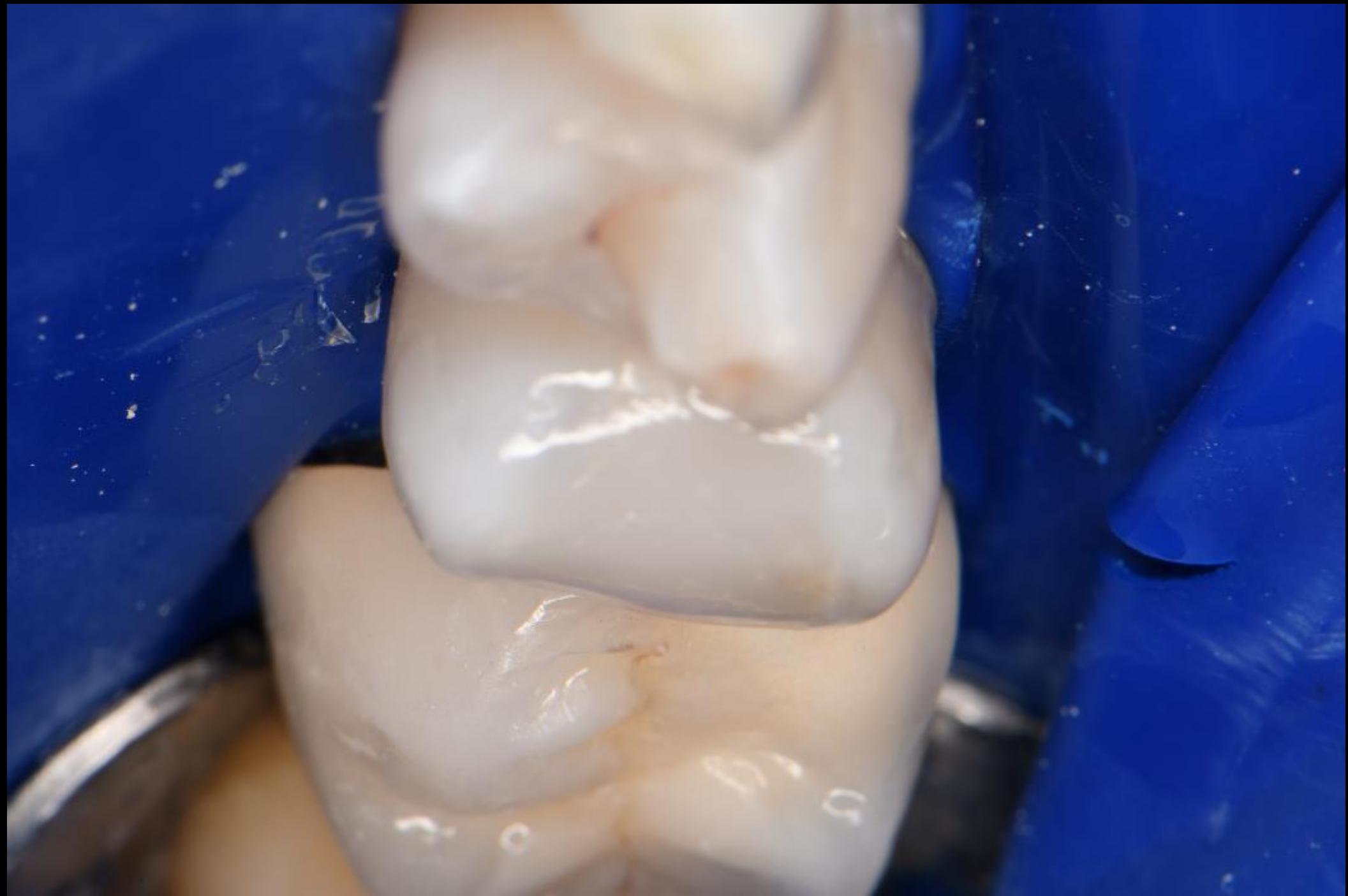


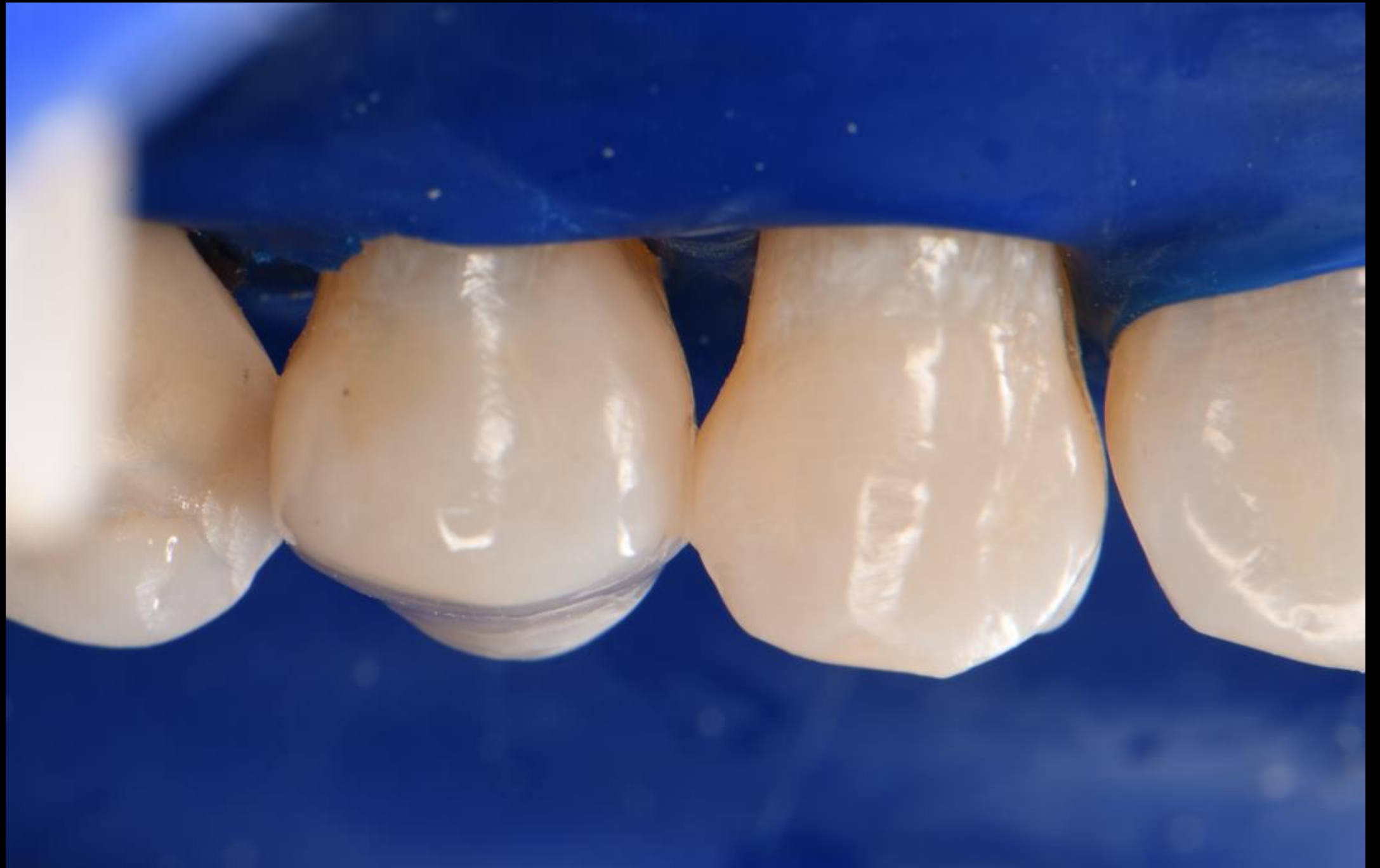


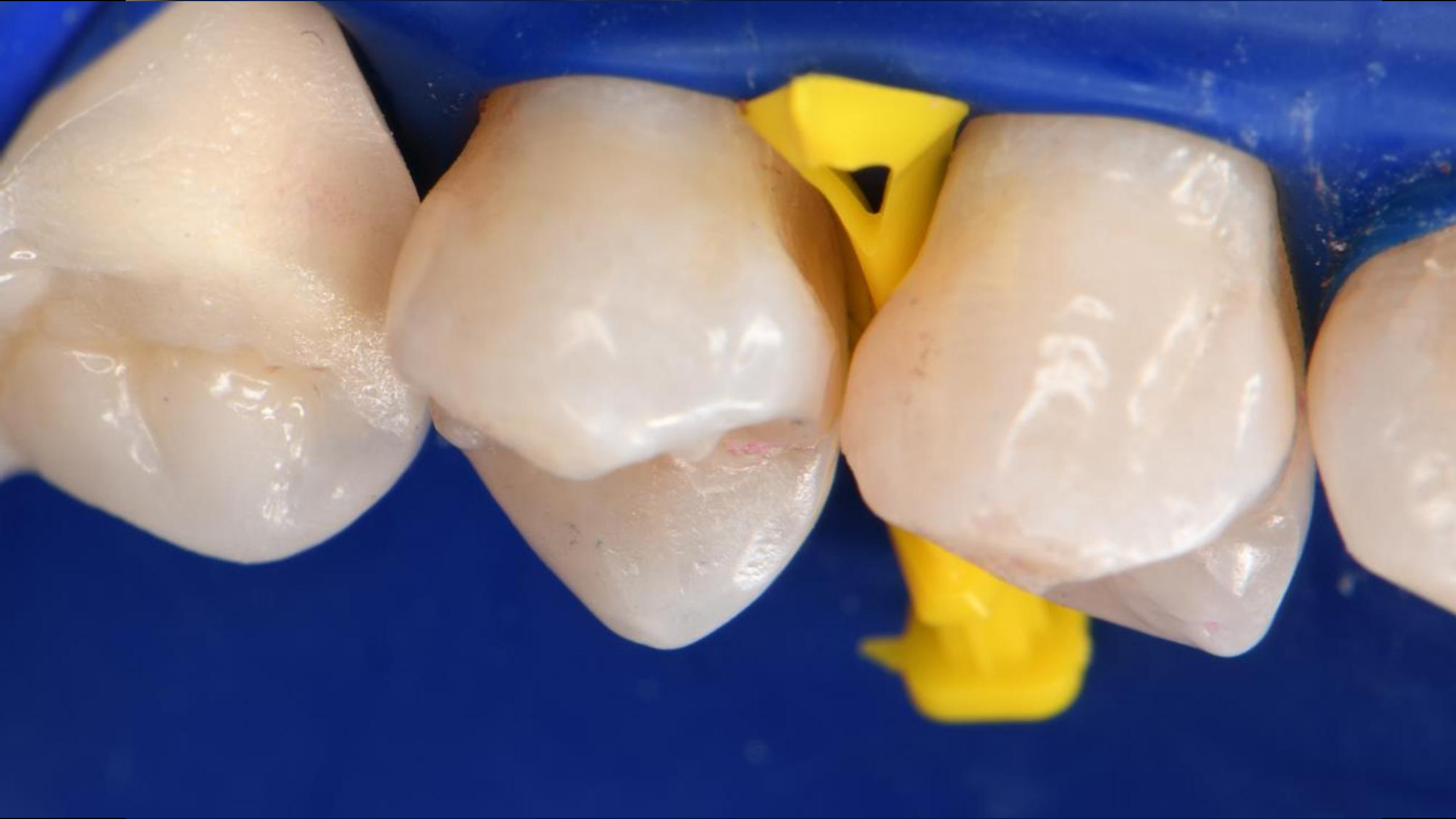


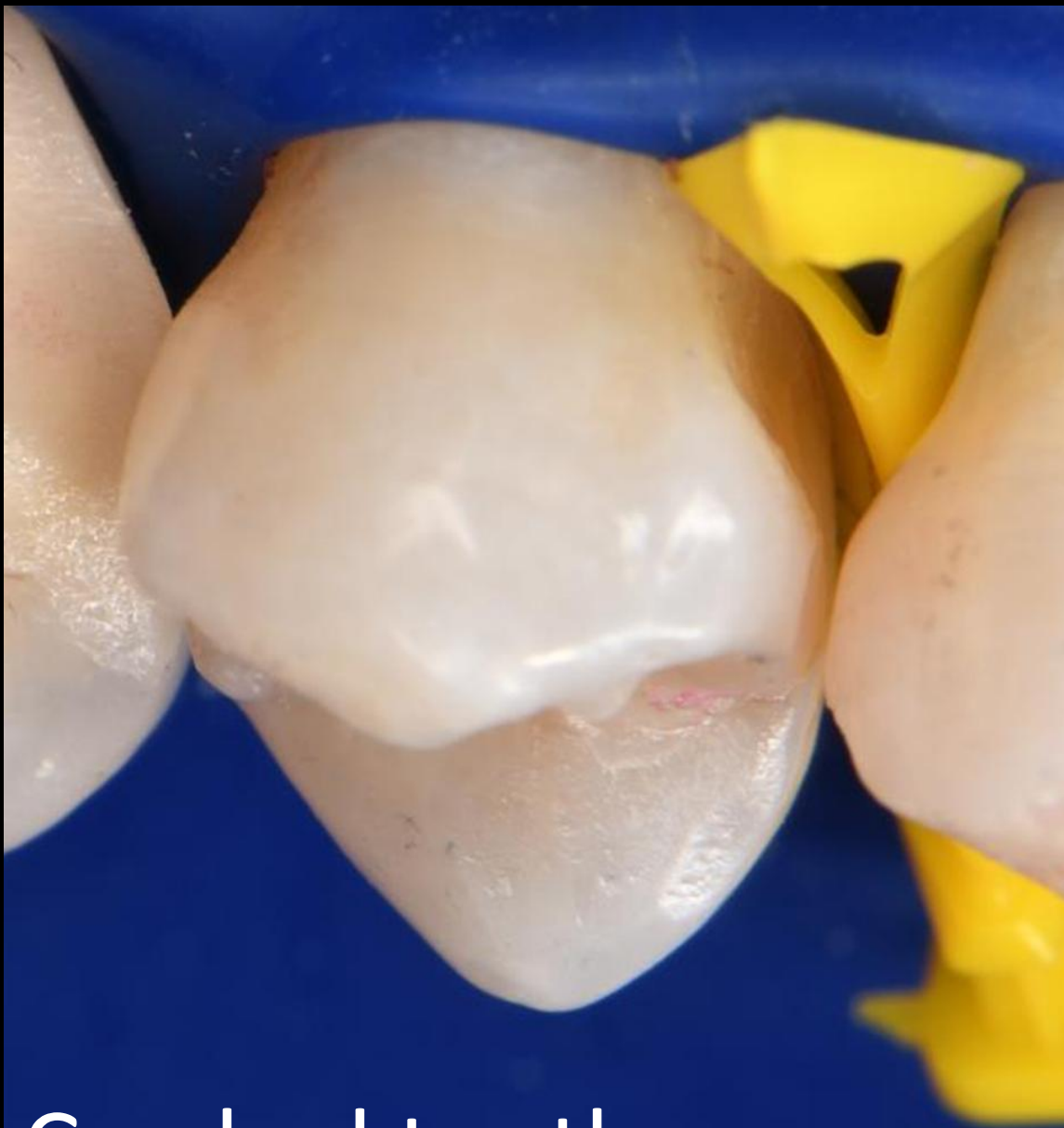




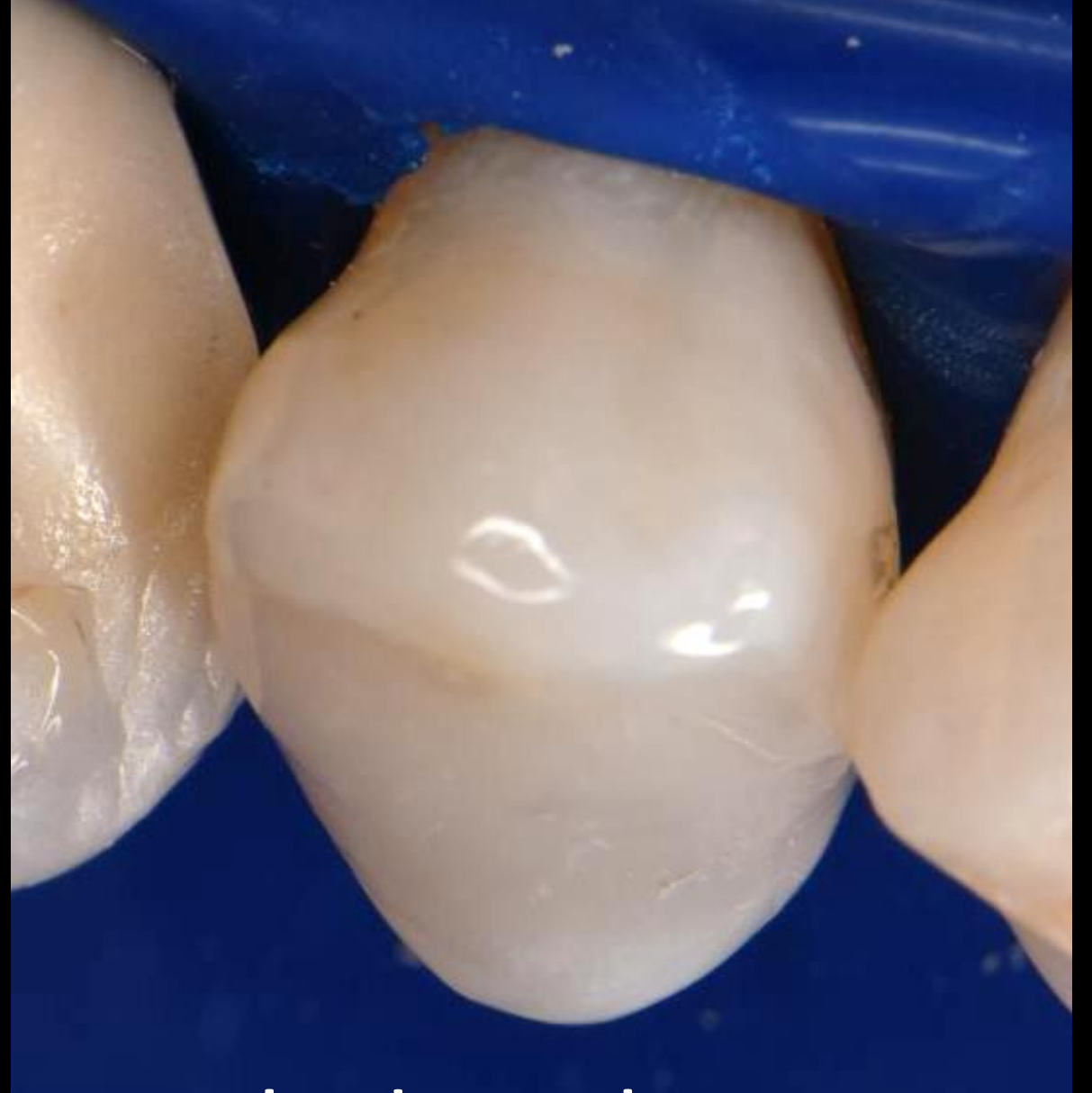

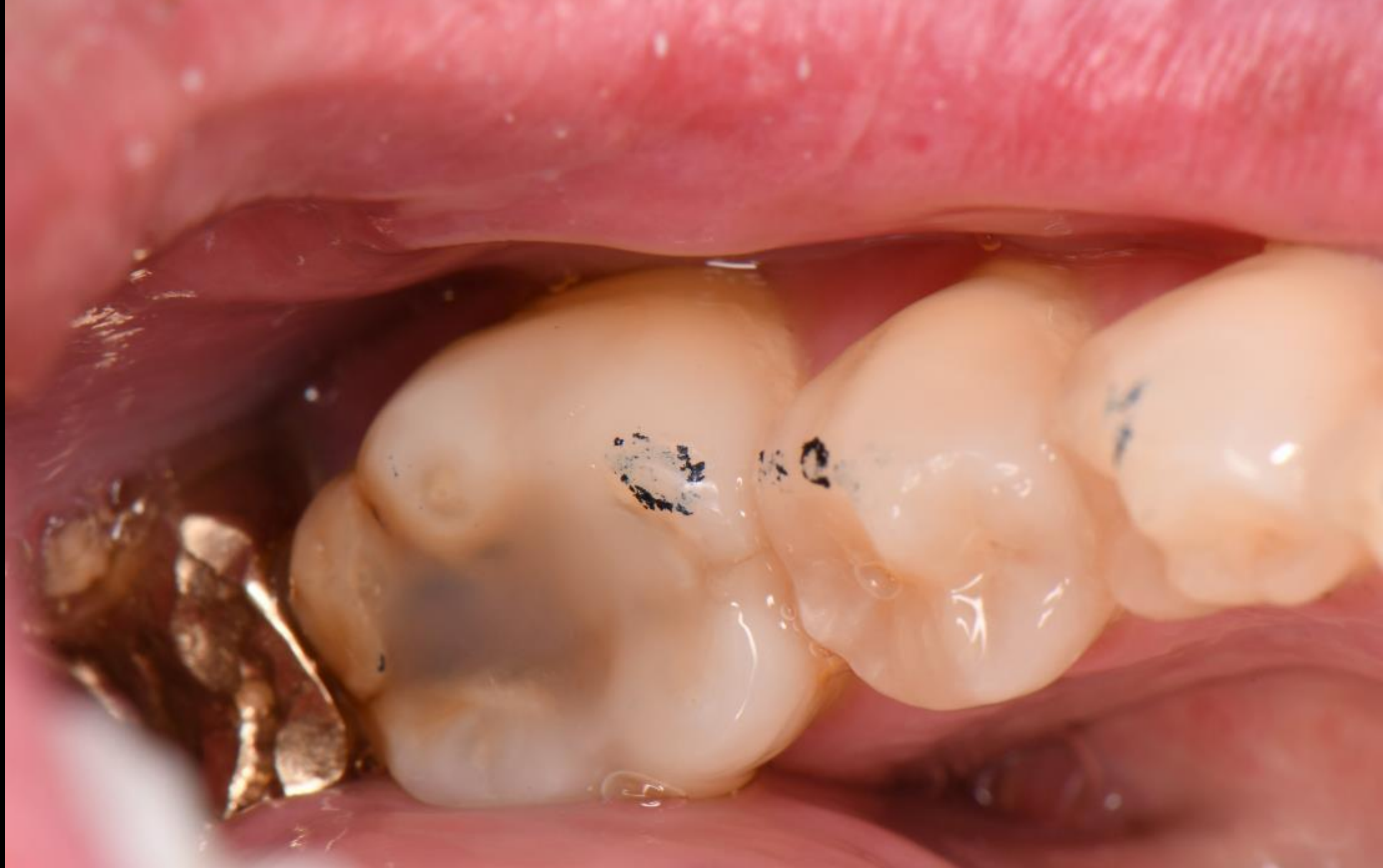Cracked tooth pre-op

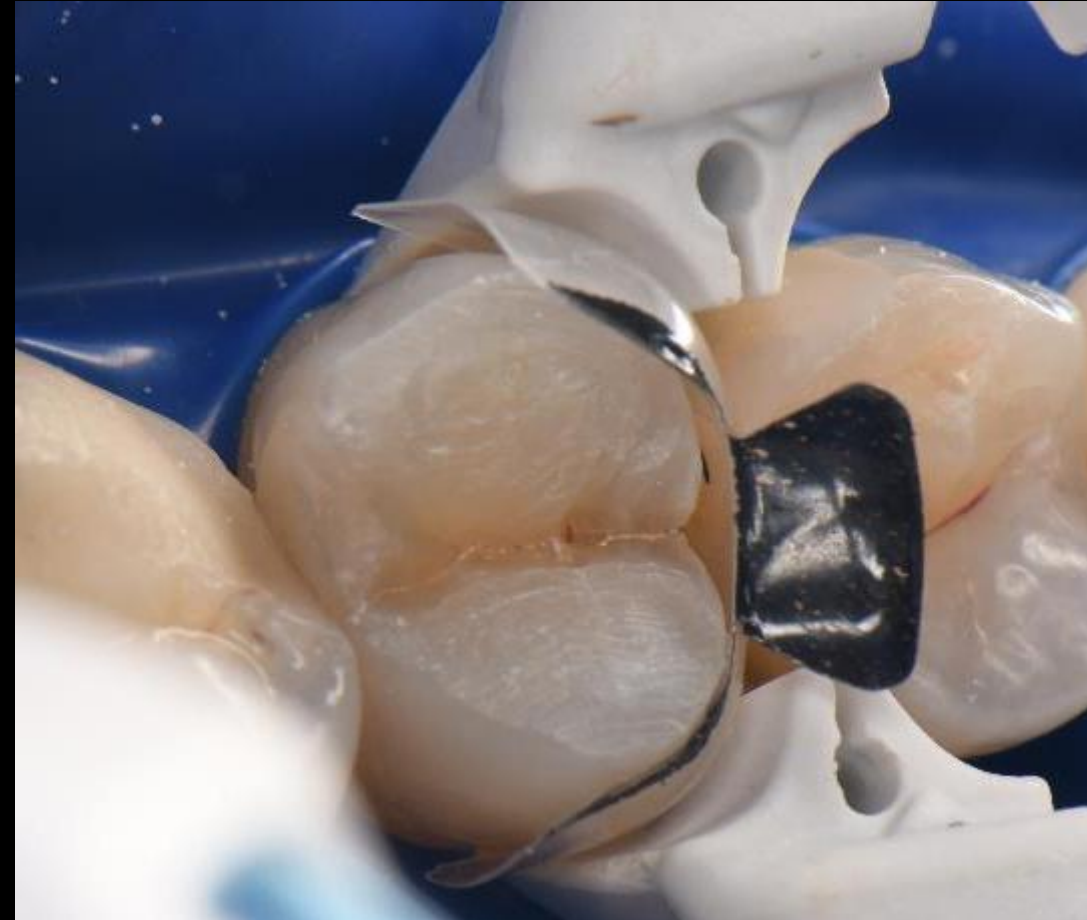


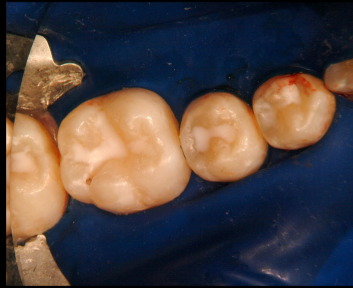Cracked tooth post-op



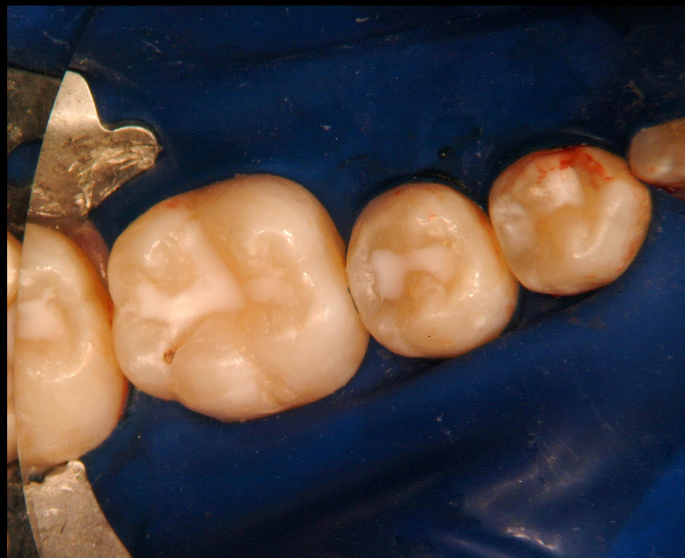Learning Objectives from the Case:

- Don't sweep the contacts*
- 3 mm thickness over the crack
- Build a bridge from buccal to lingual
- The crack becomes dormant
- "Harmonize" the opposing w/ consent
- If food impaction continues, so will pain and pocketing
- Contact technique works for other problems**
- We need a powerful separator

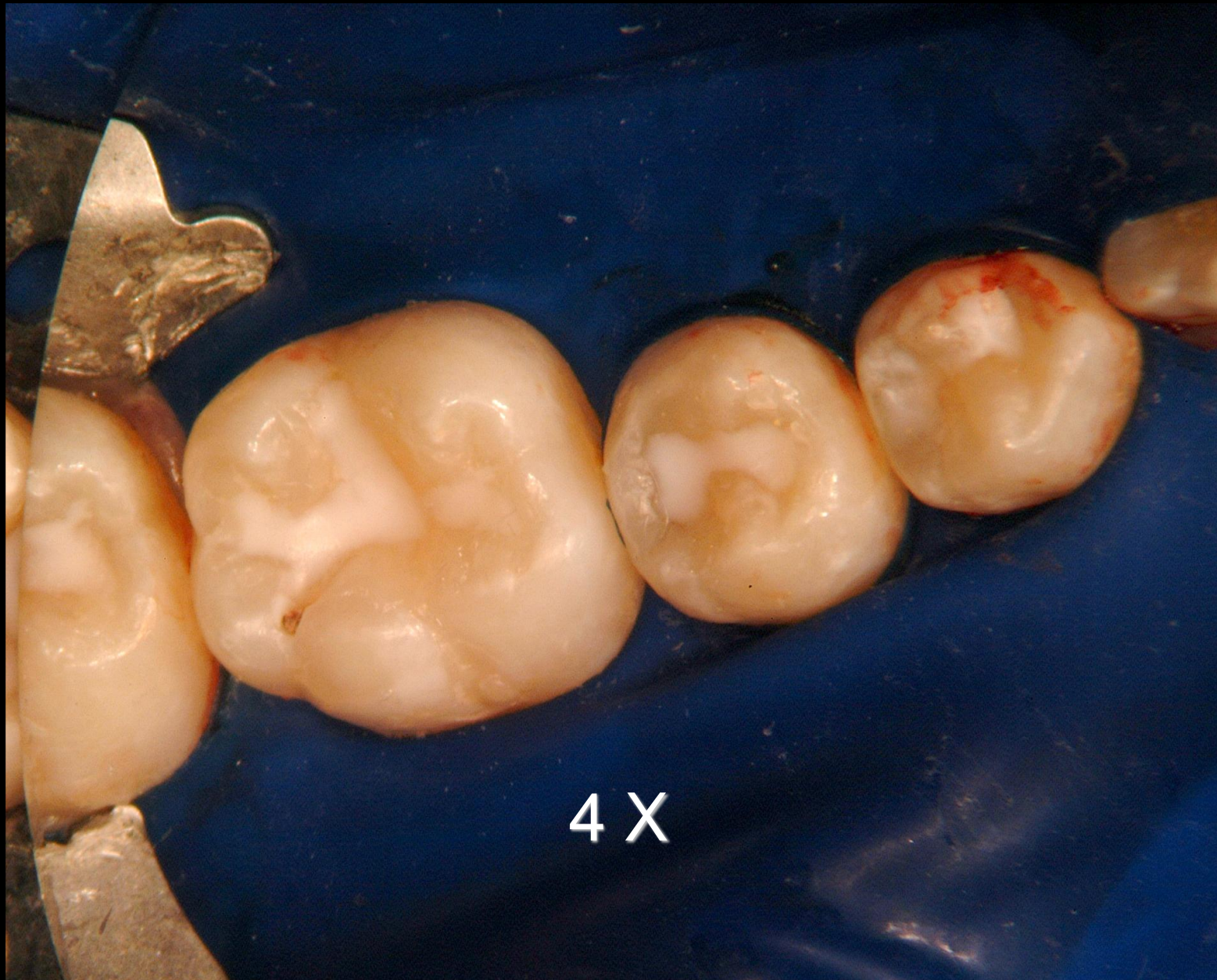



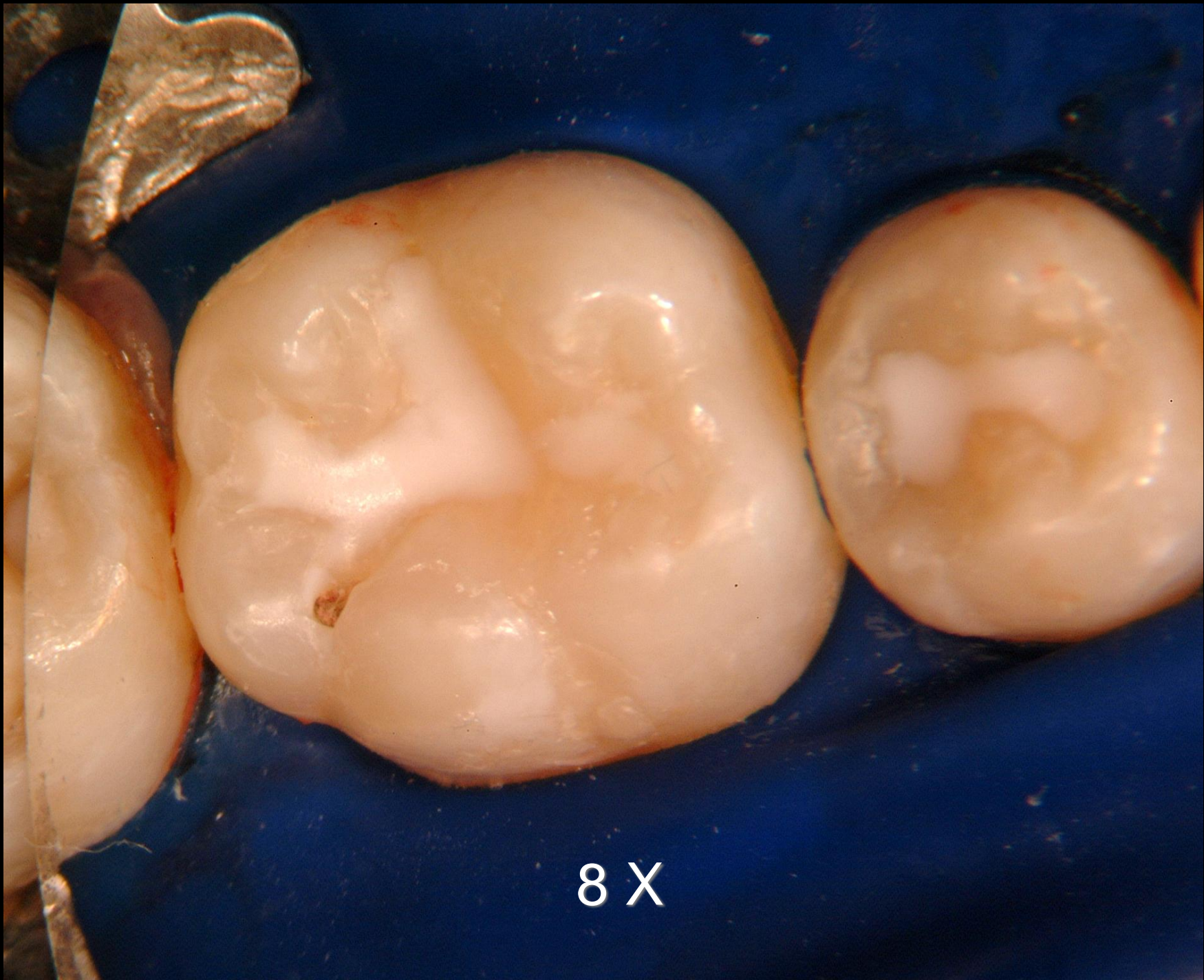1 X



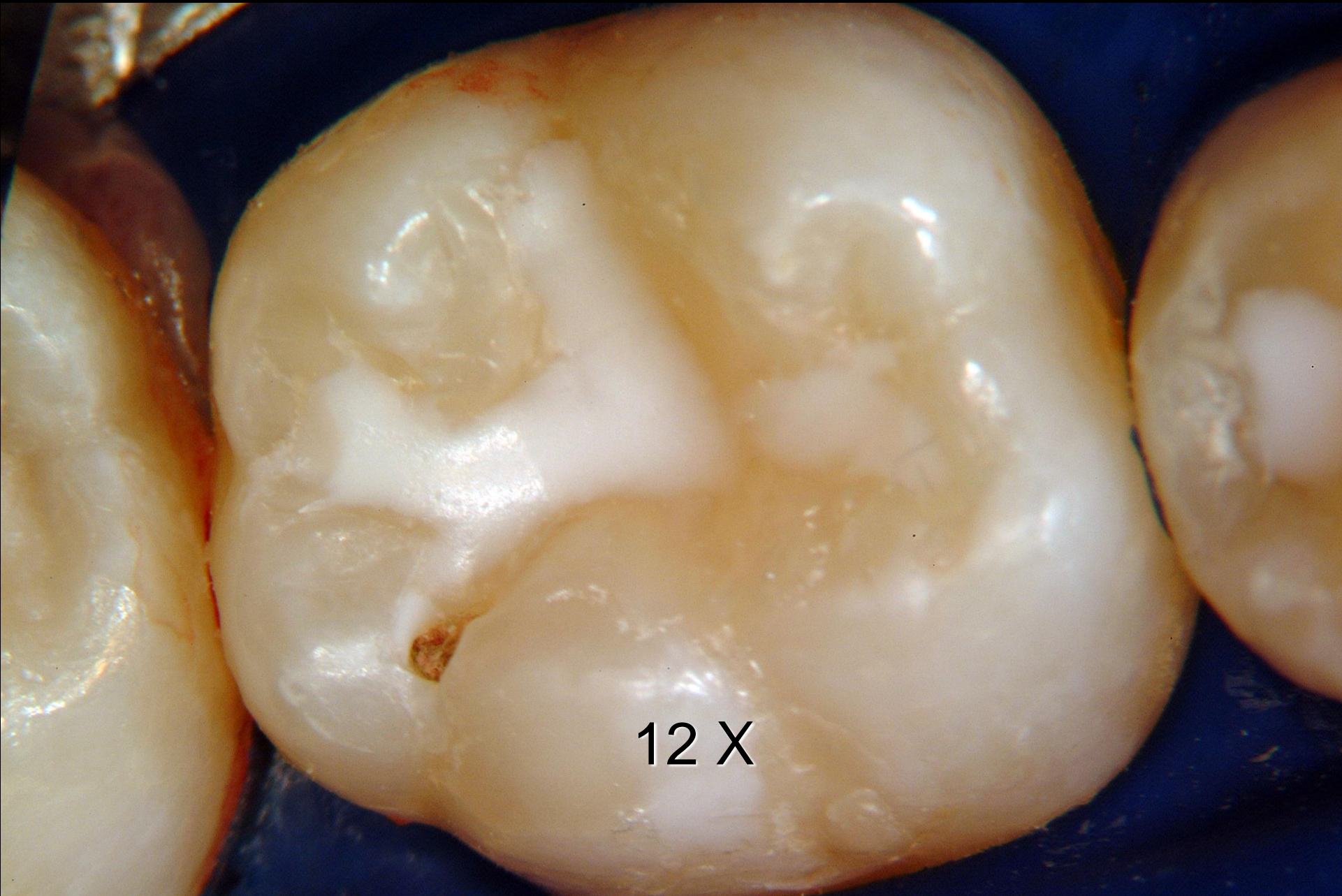
2X



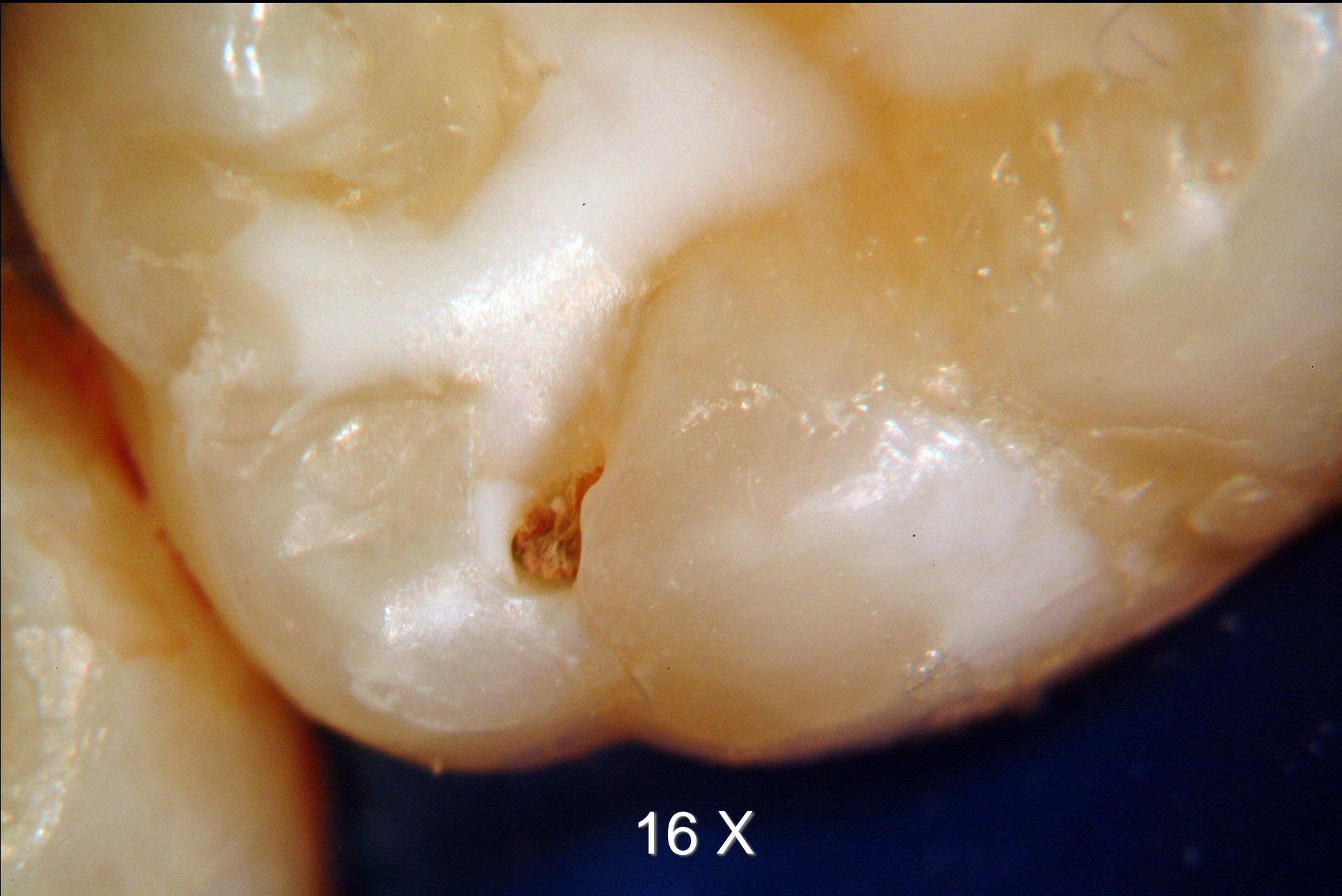
4 X



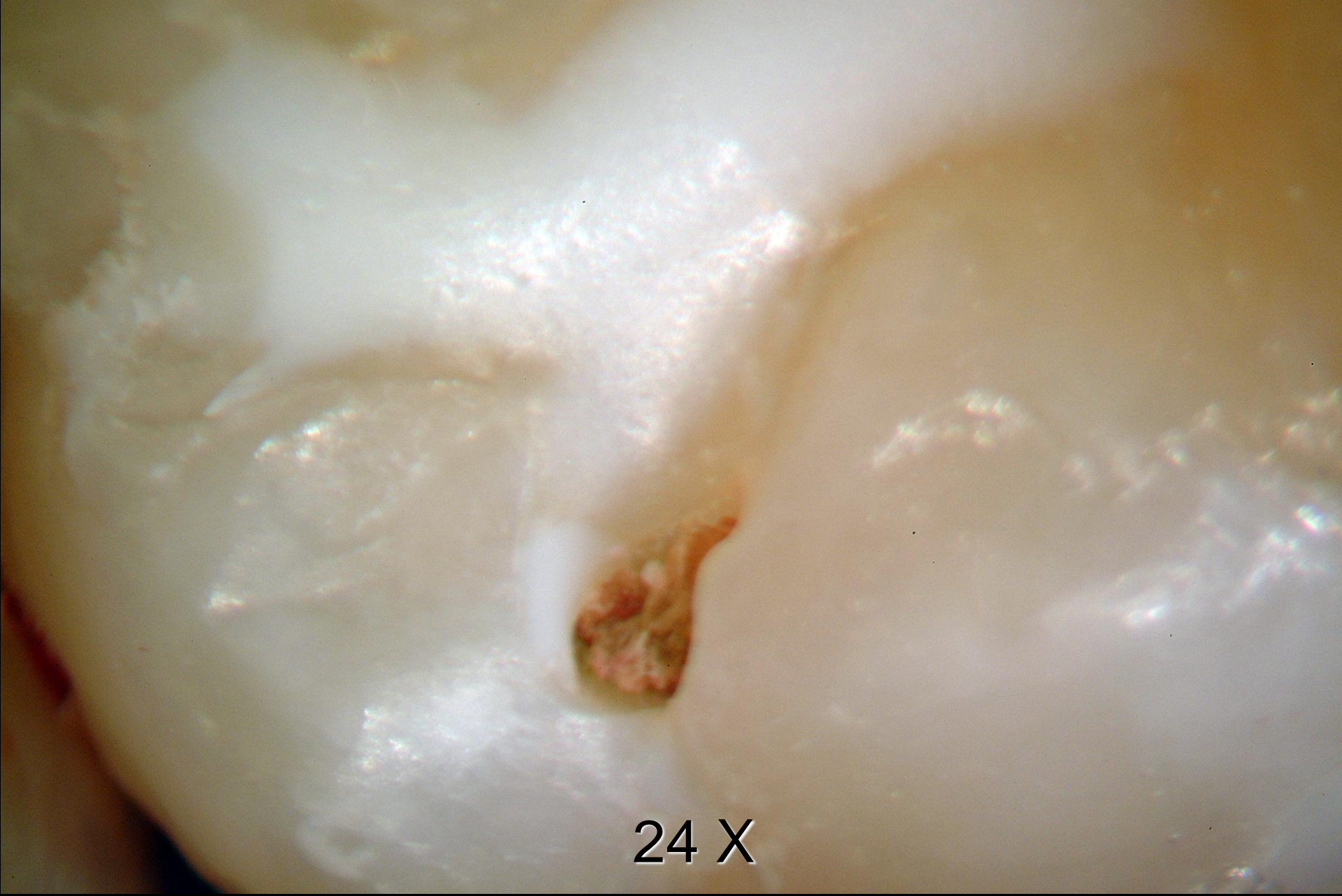
8 X



12 X



16 X



24 X



16 X

At ten year follow up, traditional sealants show a 92% failure rate...

And Rella and Brad didn't even critique them with a microscope

Chistensen RP, Ploeger BJ, Palmer TM. The role of pit-and-fissure discoloration in caries assessment. Compend Contin Educ Dent. 2001 Nov;22(11A):996-1002, 1004-7

Do traditional sealants
have a place in the
new magnified world?

The sealant philosophy is simple:

- Seal the occlusal surface of a tooth, because whatever is inside is rendered insignificant.
- Cut off the nutrient source for bacteria and caries process is arrested.

Problem

- Sealants leak.
- Caries may progress despite sealants that don't leak.

Definitive Diagnosis of Early Enamel and Dental Cracks Based on Microscopic Evaluation

DAVID J. CLARK, DDS*
 CHERILYN G. SHEETS, DDS†
 JACINTHE M. PAQUETTE, DDS‡

ABSTRACT

The diagnoses of cracked teeth and incomplete coronal fracture have historically been symptom based. The dental operating microscope at $\times 16$ magnification can fundamentally change a clinician's ability to diagnose such conditions.

Clinicians have been observing cracks under extreme magnification for nearly a decade. Patterns have become clear that can lead to appropriate treatment prior to symptoms or devastation to tooth structure occur. Conversely, many cracks are not structural and can lead to misdiagnosis and overtreatment. Methodic microscopic examination, an understanding of crack progression, and an appreciation of the types of cracks will guide a doctor to making appropriate decisions.

Teeth can have structural cracks in various stages. To date, diagnosis and treatment are very often at end stage of crack development.

CLINICAL SIGNIFICANCE

This article gives new guidelines for recognition, visualization, classification, and treatment of cracked teeth based on the routine use of $\times 16$ magnification. The significance of enamel cracks as they relate to dental cracks is detailed.

(*J Esthet Restor Dent* 15:XXX-XXX, 2003)

Macroscopic and symptom-driven diagnoses have been the accepted modalities for cracked teeth. The inherent limitations of the lack of visual confirmation result in therapies that often come too late in the treatment process. One lasting first impression of vision through a clinical microscope is the staggering array of cracks that exist within tooth structures. Traditional visualization (unaided

or ocular assisted) limits the clinician's ability to assess the presence or severity of the majority of these cracks (Figure 1).

At extreme magnification levels ($\times 14$ and greater), the translucent nature of enamel yields a wealth of information. Subtle color changes within the enamel may indicate early decay, microleakage, and a lack of structural integrity of dentin and

enamel. Being able to see previously invisible clues can lead restorative dentists to more appropriate early treatment of compromised teeth before devastating fractures, pulpal involvement, and periodontal breakdown occur. The value of early diagnosis of the structural breakdown of teeth will become even more significant with our aging population coupled with increased tooth retention in this population.

*President, Academy of Microscope Enhanced Dentistry

†Co-executive director, Newport Coast Oral Facial Institute, Newport Beach, CA; clinical professor, Restorative Dentistry, USC School of Dentistry, Los Angeles, CA, USA

‡Co-executive director, Newport Coast Oral Facial Institute Newport Beach, CA; associate professor, Restorative Dentistry, USC School of Dentistry, Los Angeles, CA, USA

Do Traditional Sealants Have a Place in the New, Super-Magnified World?



By David Clark, DDS

Traditional dental sealants, which have ostensibly become restorative dentistry's most promoted preventive procedure, have one of dentistry's highest failure rates. A well-publicized CRA study¹ confirmed a 92% failure rate at a 10-year follow-up. Not surprisingly, there is a little joke among microscope clinicians: when you buy your first microscope you have just done your last sealant.

At the inaugural meeting of the Academy of Microscope Enhanced Dentistry, there was unanimous consensus: traditional sealants rendered with no or low magnification are inappropriate in a microscope-centered practice. Many other aspects of sealants were also challenged. The questions are: "How much magnification is enough?" and "What is the microscope and research teaching us about the practical application of sealants?"

Not surprisingly, there is a little joke among microscope clinicians: when you buy your first microscope you have just done your last sealant.

FUNDAMENTALS OF CLINICAL MAGNIFICATION

The operating microscope is not just simply higher magnification than oculars (loupes). It is better magnification. Oculars have been very helpful and may always have a role in dentistry, but the optics are crude when compared to the infinity corrected optics of a stereoscopic microscope (Figures 1 to 4). When combined with the shadowless coaxial light source, they transform the clinician's potential for accuracy in nearly every aspect of the different disciplines in dentistry.

Think of magnification in terms of television screens: a 21-inch screen has twice the surface area of a 15-inch screen. Dr. Assad Mora, one of the pioneers of full-time microscope utilization in prosthodontics, explains that increasing levels of magnification produce a squared, not linear relationship to visual acuity. In other words, 10x magnification allows the human retina to acquire 100 times more information; 20x allows 400 times the visual information.

continued on page 94



Figure 1. Oculars (loupes) rely on convergent vision that essentially requires a crossing over of images. This form of magnification creates increasing problems and eye strain as magnification increases.



Figure 2. Convergent 8x magnification and a representation of the 2 images that your brain receives as you begin to focus.



Figure 3. Incomplete merging of images, which is a common occurrence. Both images also demonstrate the visual noise in the background of loupes.

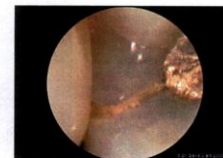

Figure 4. Infinity corrected (parallel) optics at 24x. There is no eye strain. Loupes magnification at 8x and above becomes excruciating for most humans.

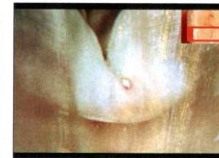

Figure 5. A sectioned molar is viewed at 16x. Note the cul-de-sac that is also divergent from the direction of the occlusal portion of the groove (a classic dogleg). Parallel-sided preparation of the groove, especially without the microscope, would not allow visualization of the true extent of the defect.

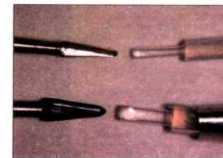
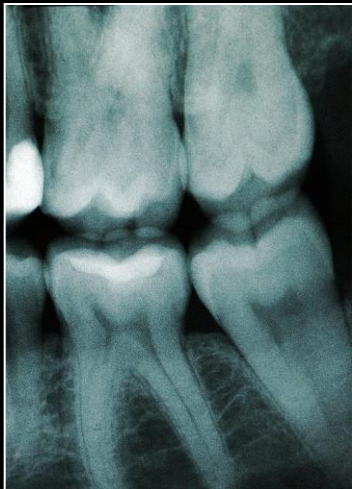
Figure 6. Microscopic comparison of fissurotomy burs. S.S. White Original and Micro NTF with typical laser tips. The fissurotomy burs are narrower at the tip. The width, depth, and continuity of the cuts into dentin are the most crucial in dental crack and fracture avoidance.

The Nine *Fatal Flaws* of Traditional Sealants

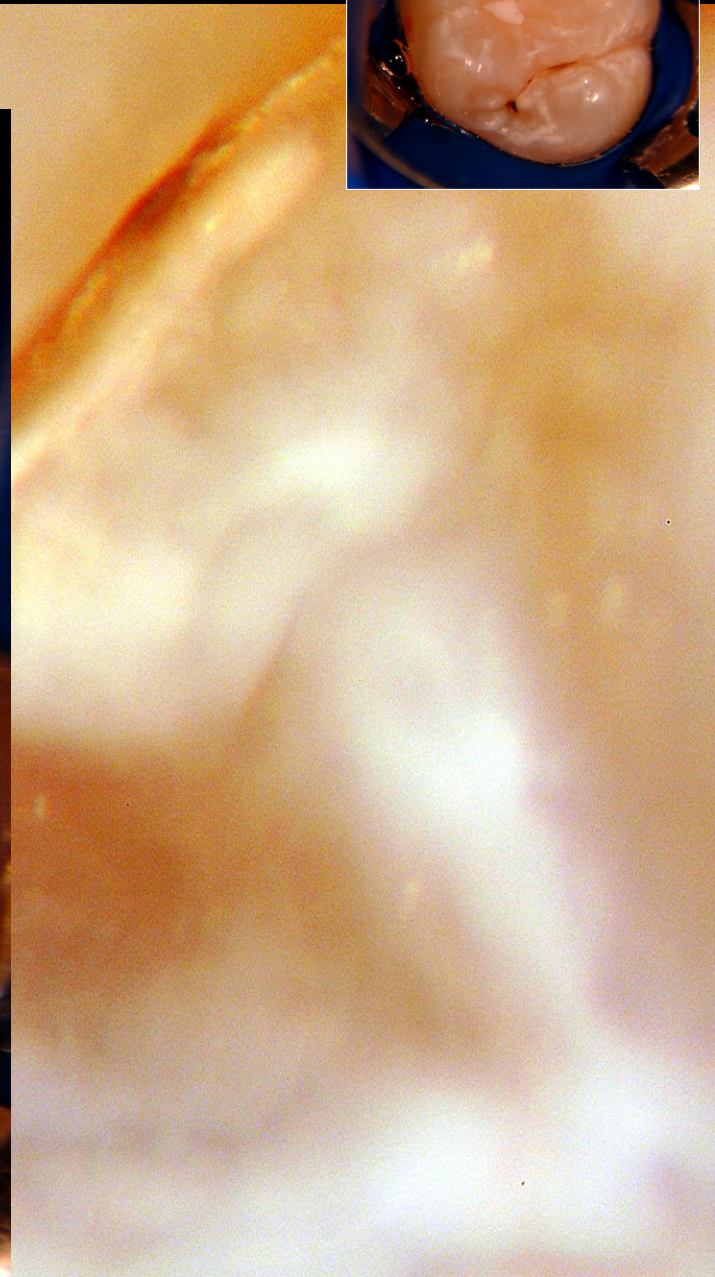
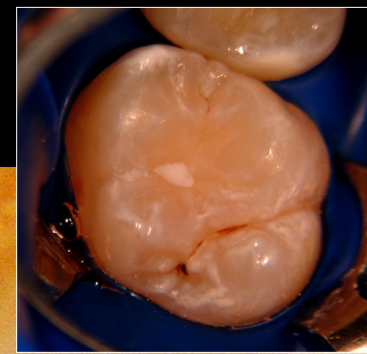
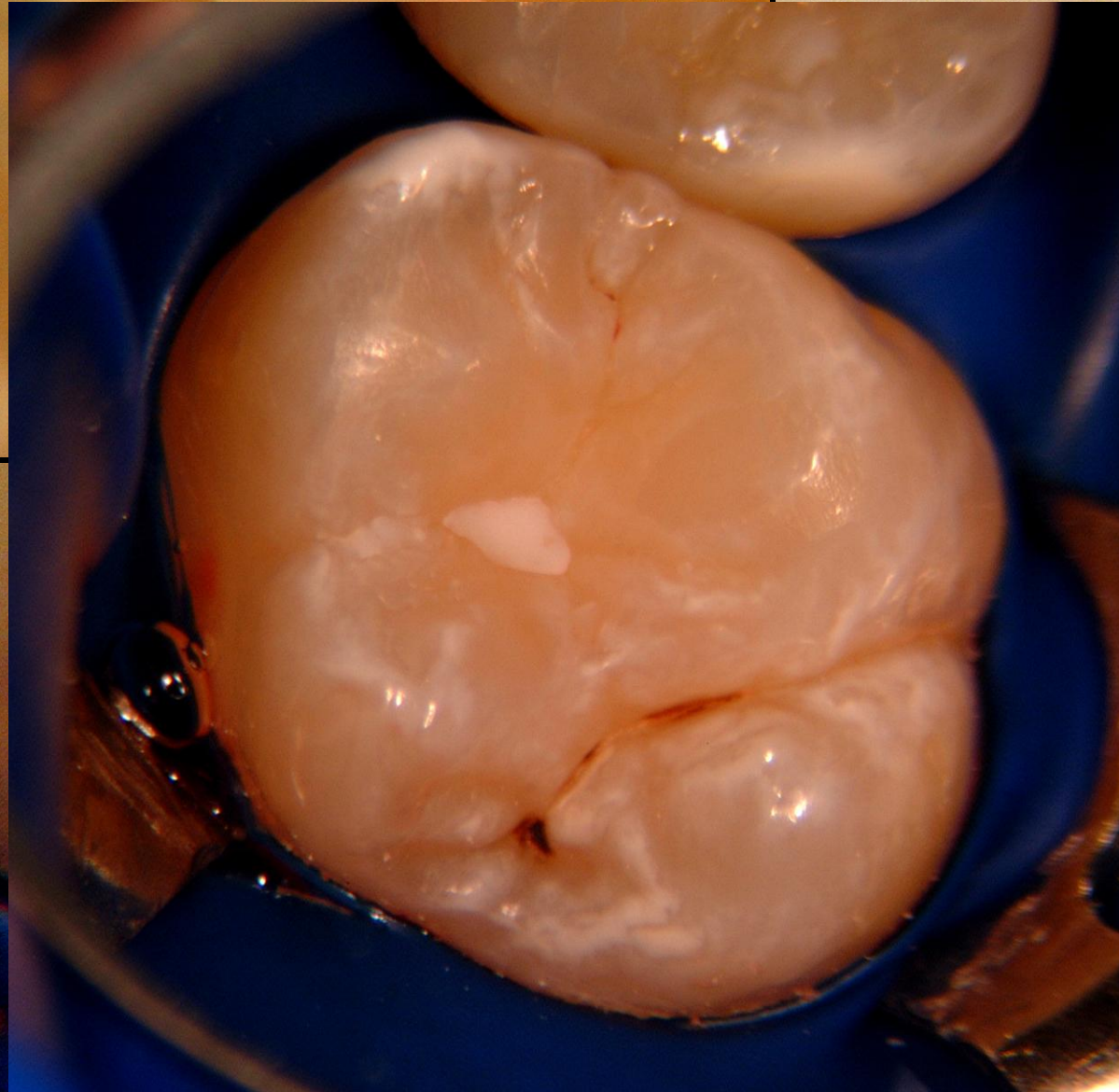
1. Traditional Diagnosis: No or low magnification visual inspection, caries indicator, probing with explorer, radiographs



The Nine *Fatal Flaws* of Traditional Sealants

1. Traditional Diagnosis
2. Sealing Over Stained Grooves

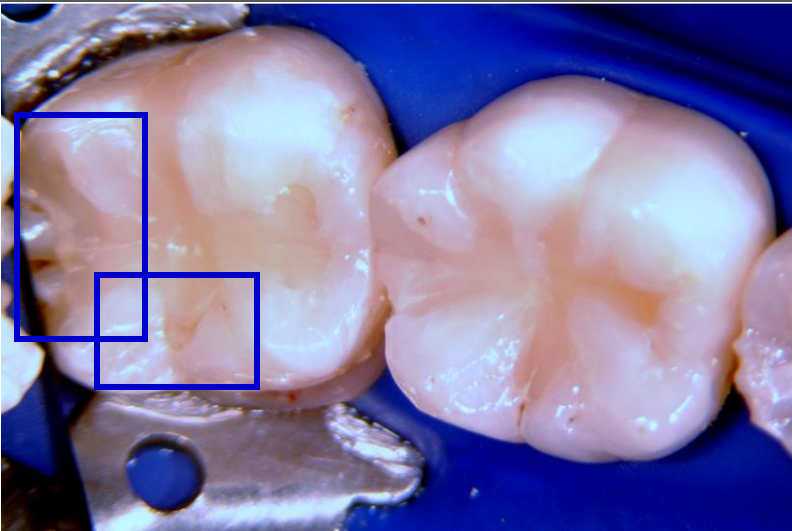
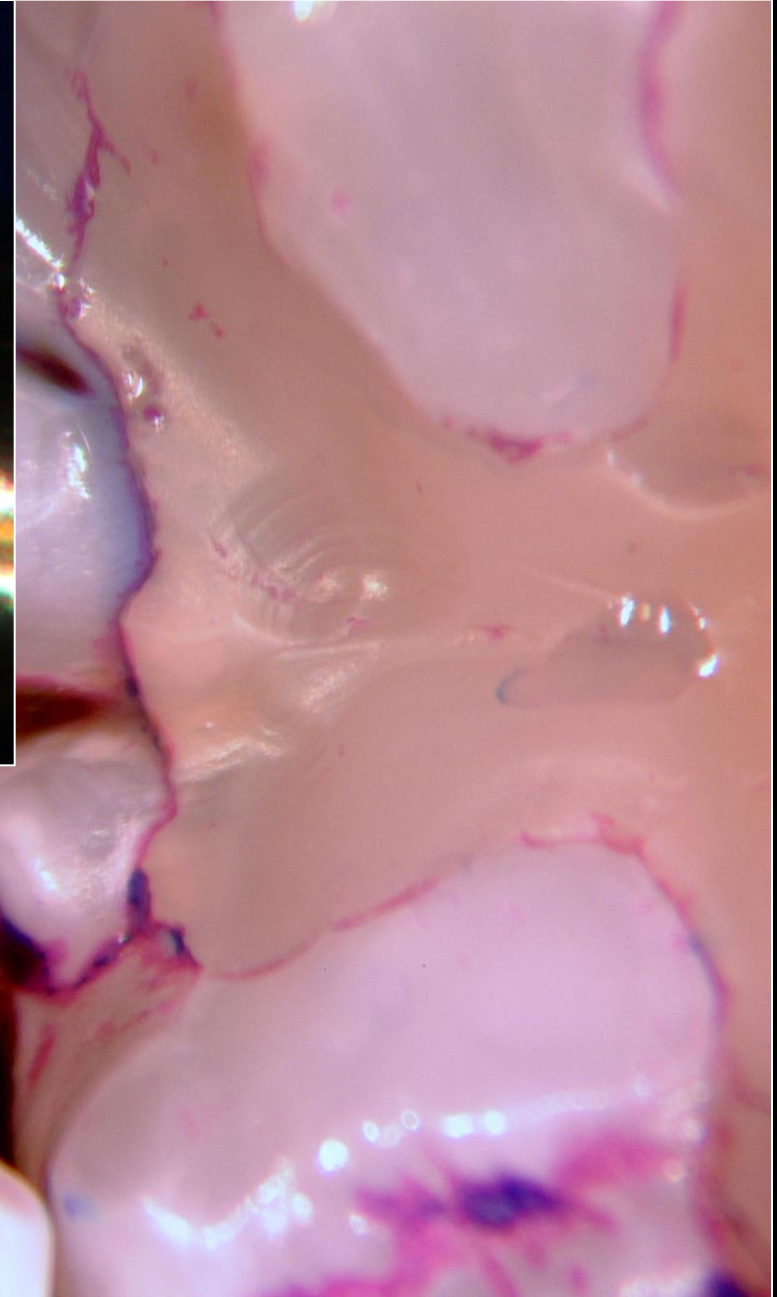
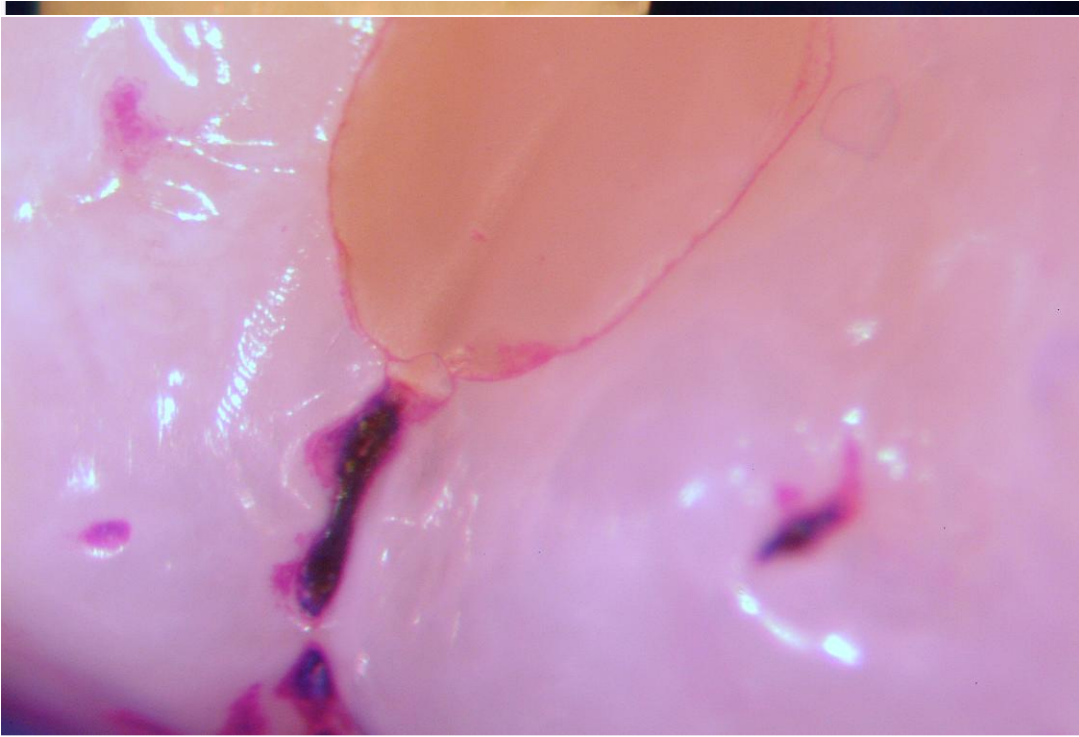
The Nine *Fatal Flaws*



The Nine *Fatal Flaws* of Traditional Sealants

1. Traditional Diagnosis
2. Sealing Over Stained Grooves
3. Using Paste Composite Alone to Restore Micro-Preps

The Nine *Fatal Flaws*: *Paste composite without flowable*

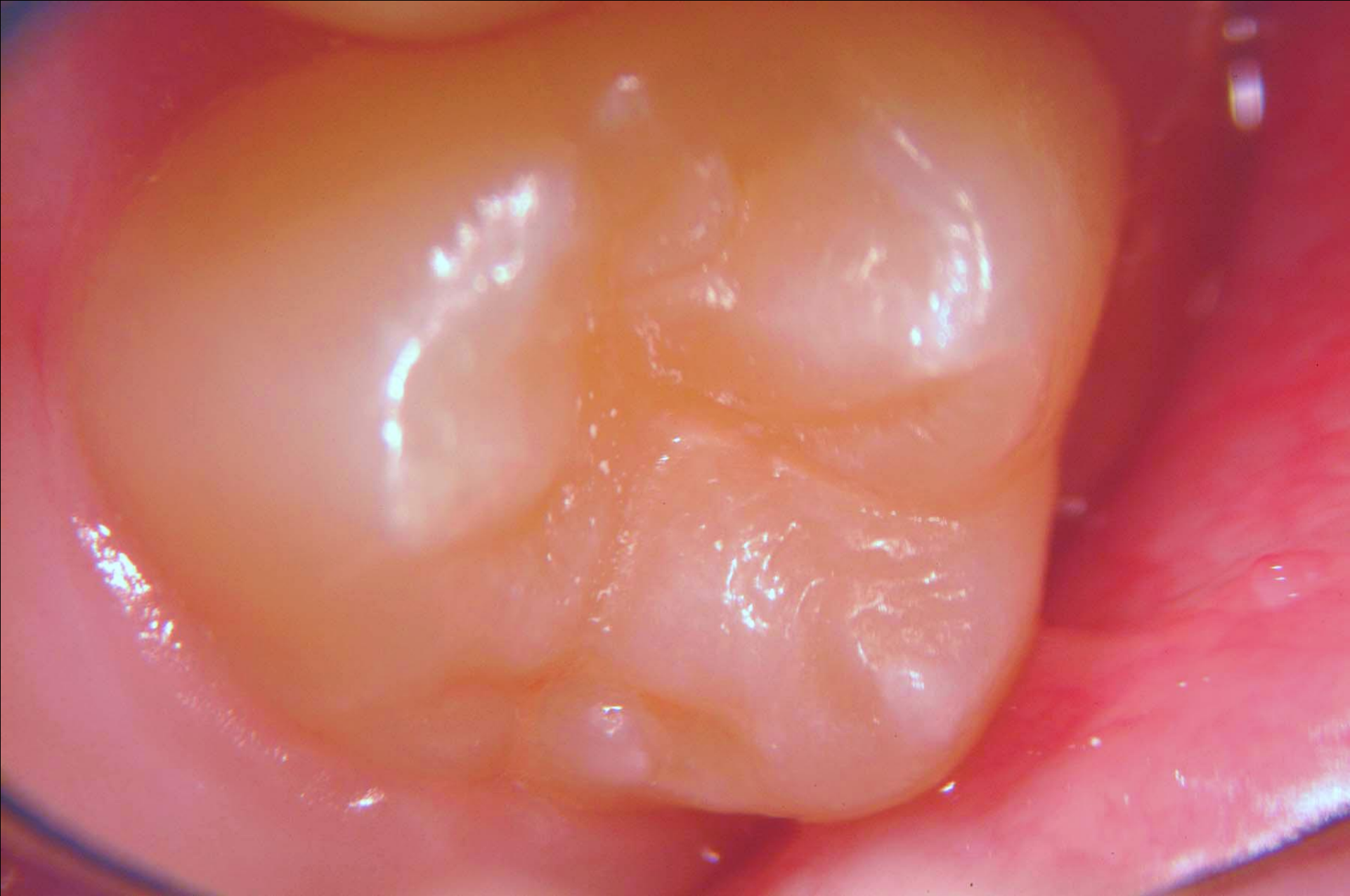

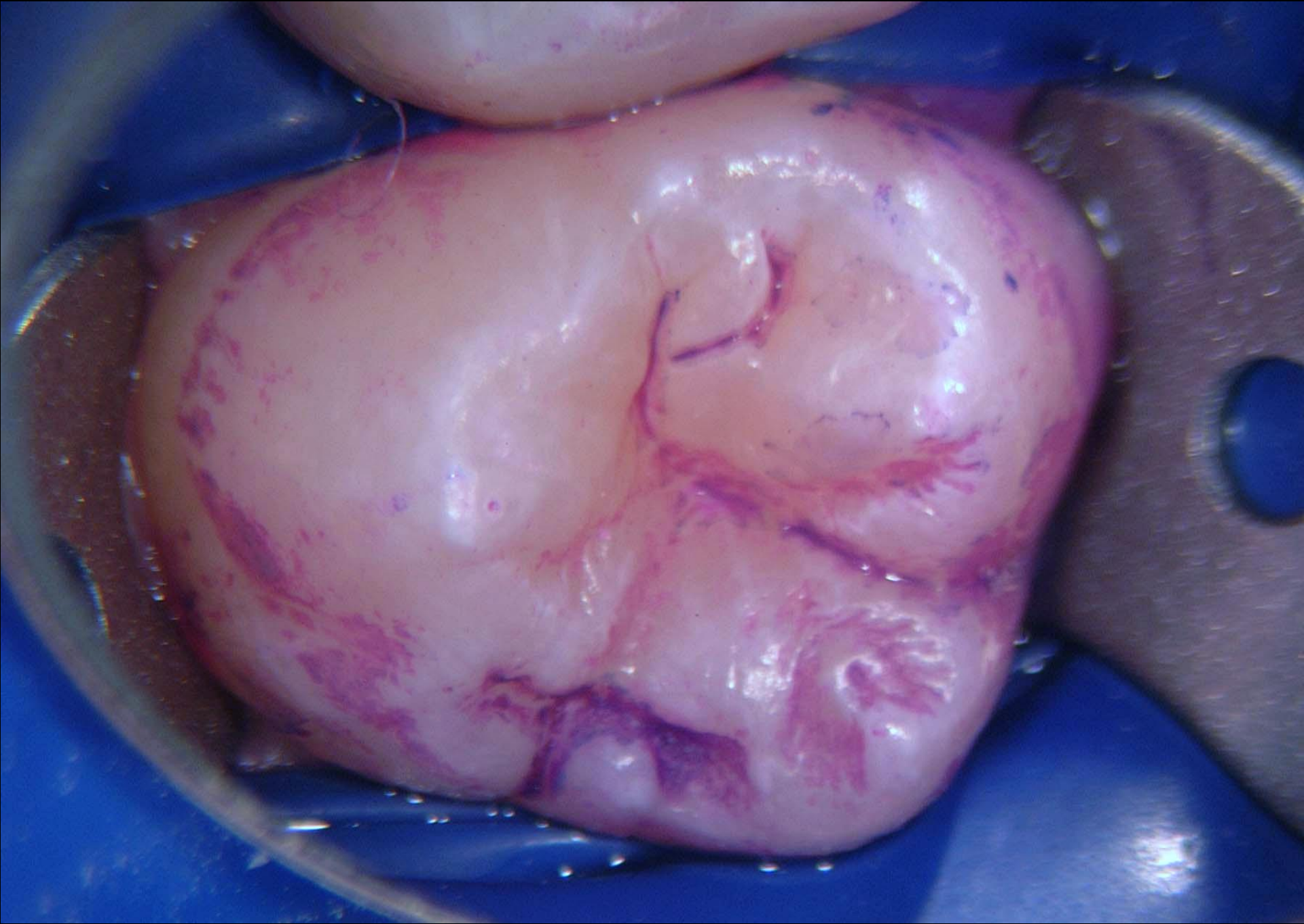
The Nine *Fatal Flaws* of Traditional Sealants

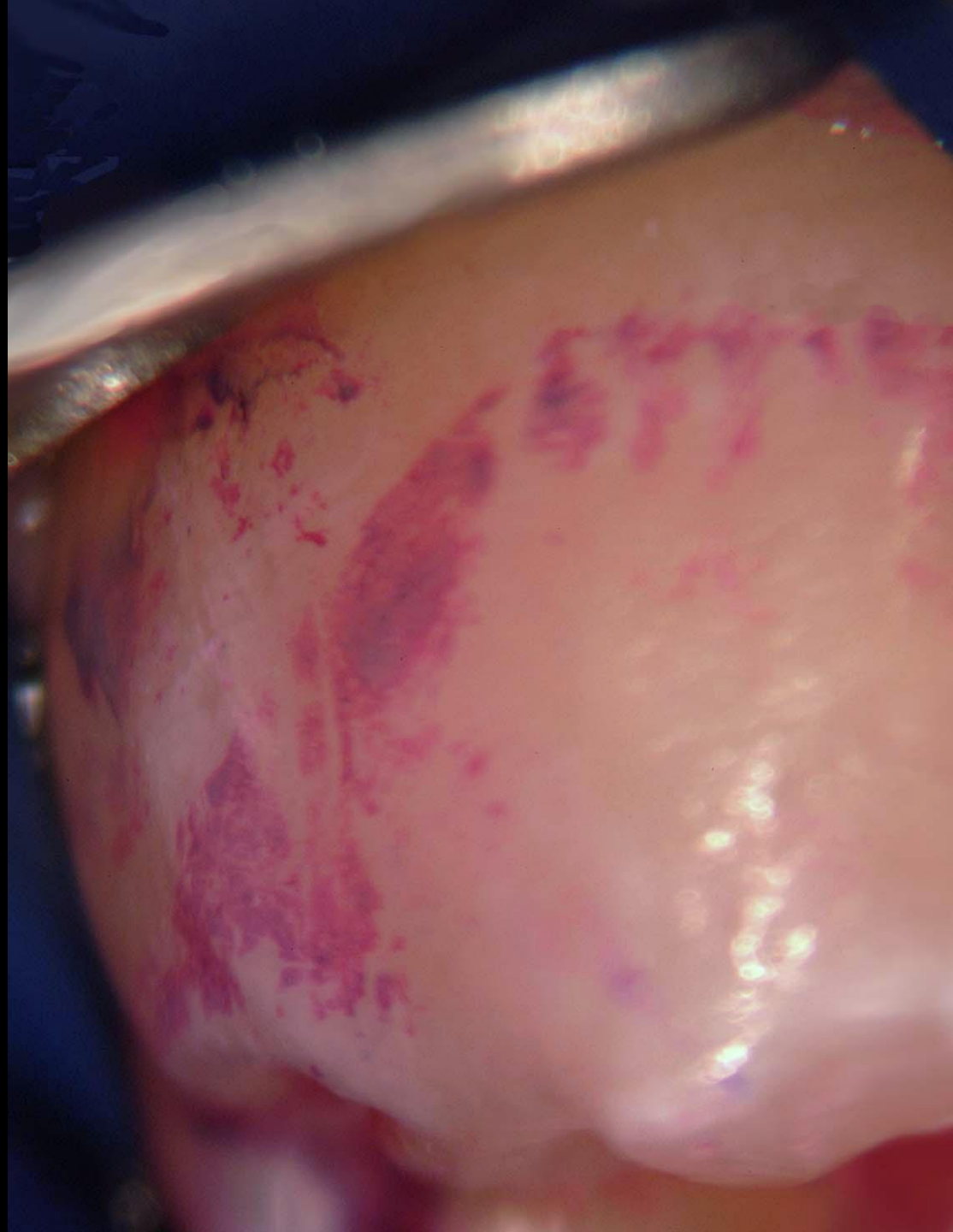
1. Traditional Diagnosis
2. Sealing Over Stained Grooves
3. Using Paste Composite Alone to Restore Micro-Preps
4. Battling the tissue on second molars

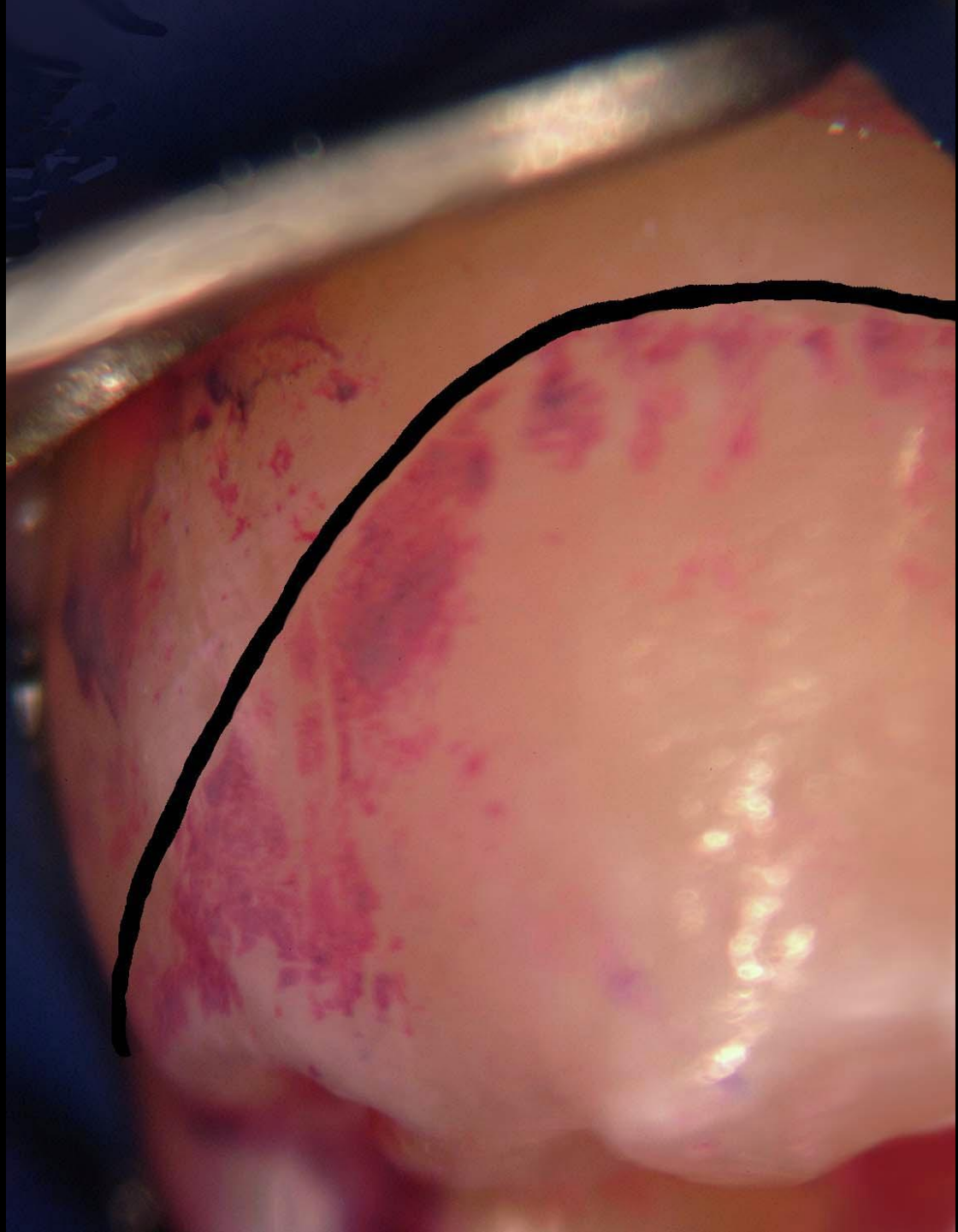Second Molar Issues

- Normally, the anatomic crown is only partially erupted, and tissue on the distal is often very near the occlusal table. This makes isolation, visualization, plaque removal, and crevicular fluid control challenging.
- A clamp provides perfect gingival retraction.
- Blasting and exfoliation, followed by Astringedent X works well also.







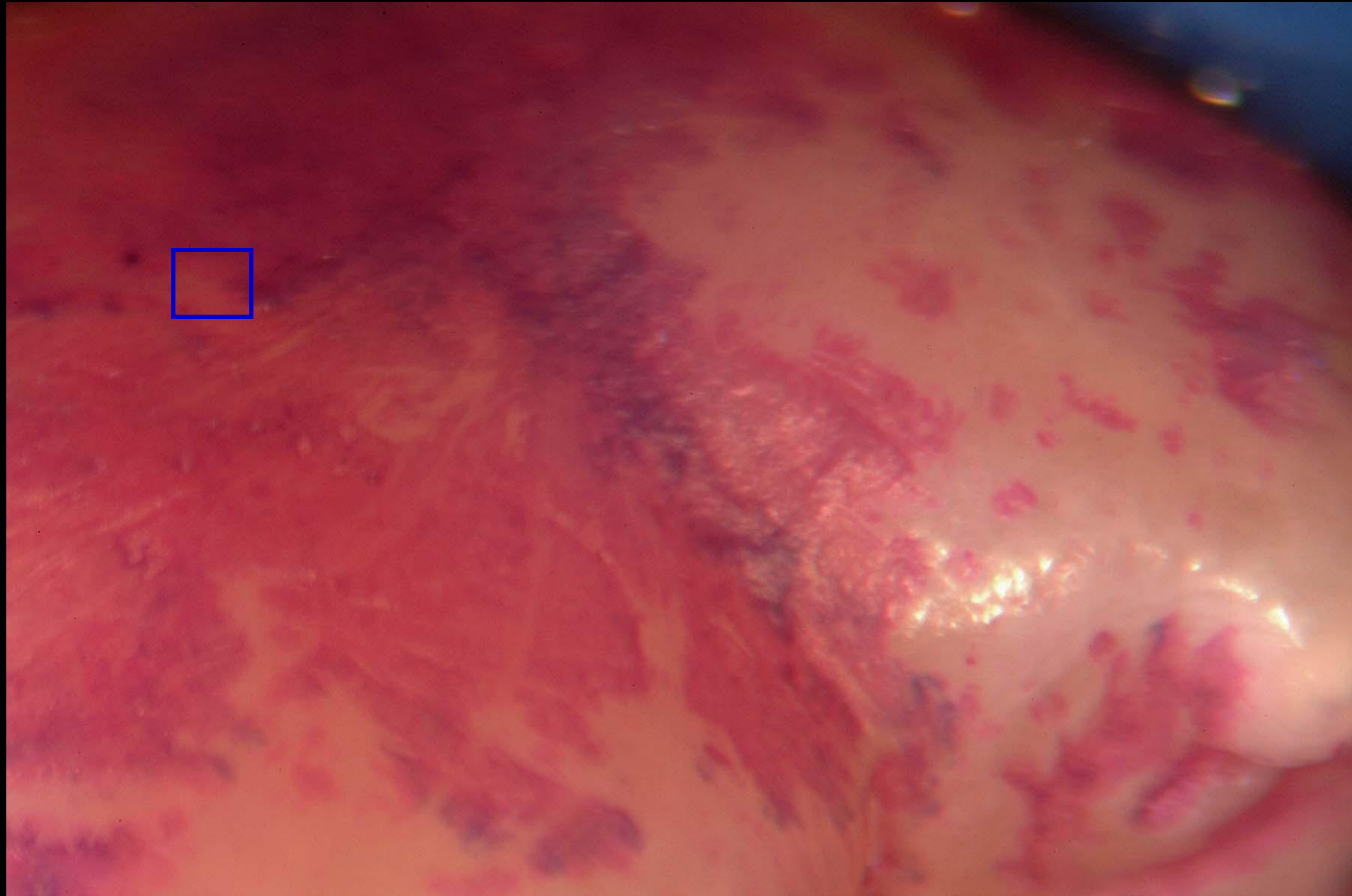


The Nine *Fatal Flaws* of Traditional Sealants

5. Sealing Over Decay

6. Relying on Phosphoric Acid to Clean the Tooth

The Nine *Fatal Flaws*



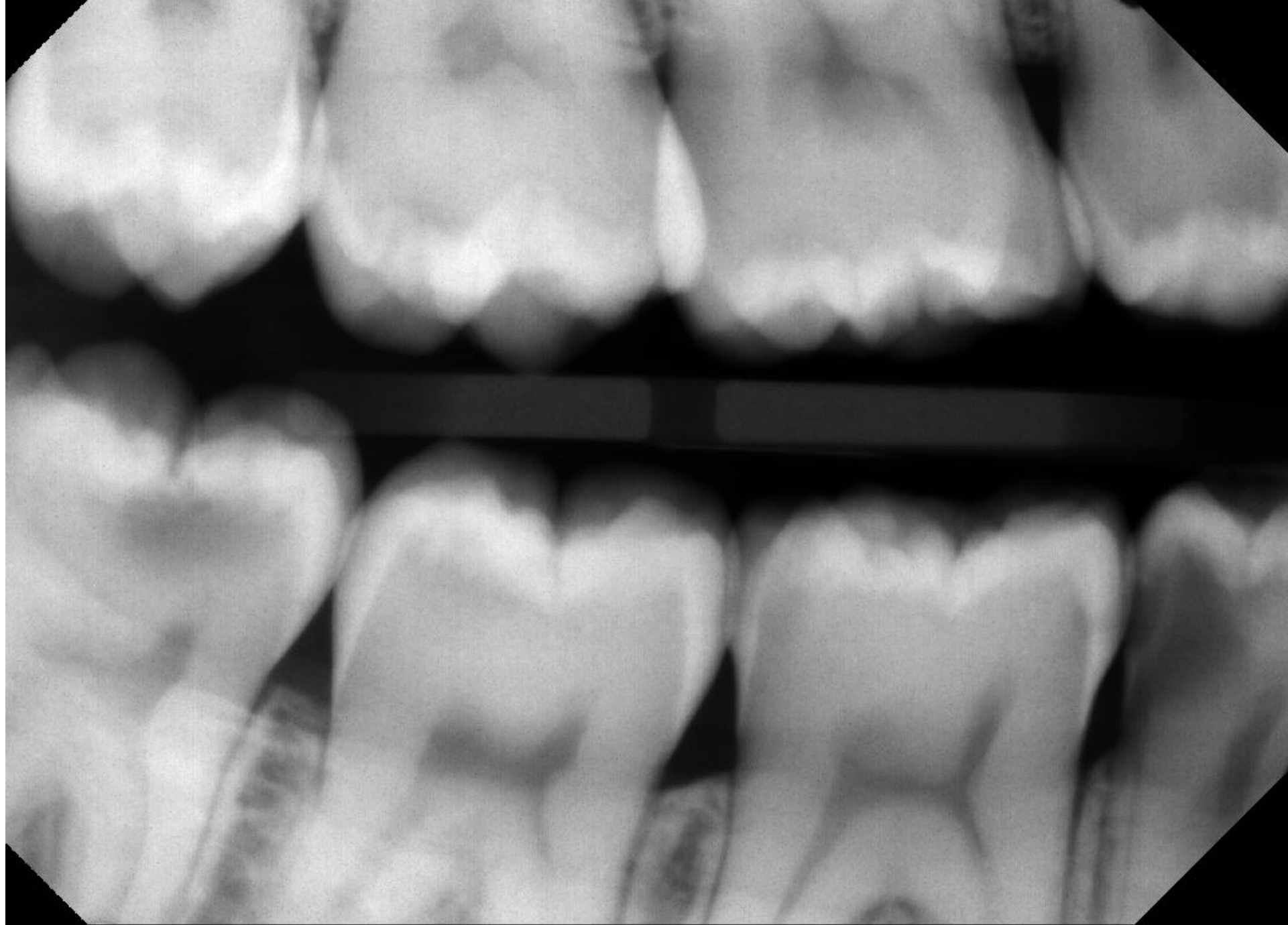The Nine *Fatal Flaws* of Traditional Sealants

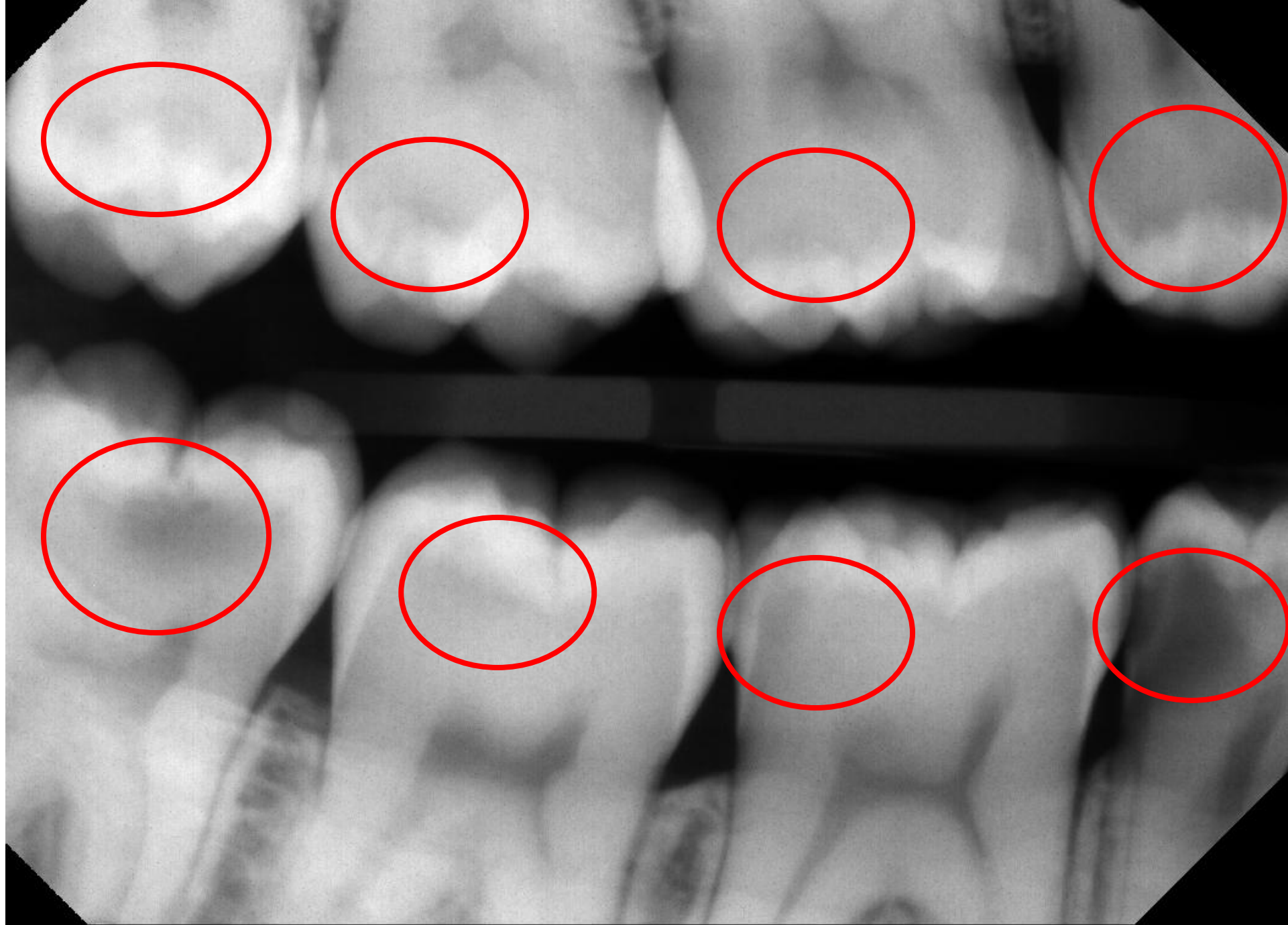5. Sealing Over Decay
6. Relying on Phosphoric Acid to Clean the Tooth
7. Sealant Maintenance

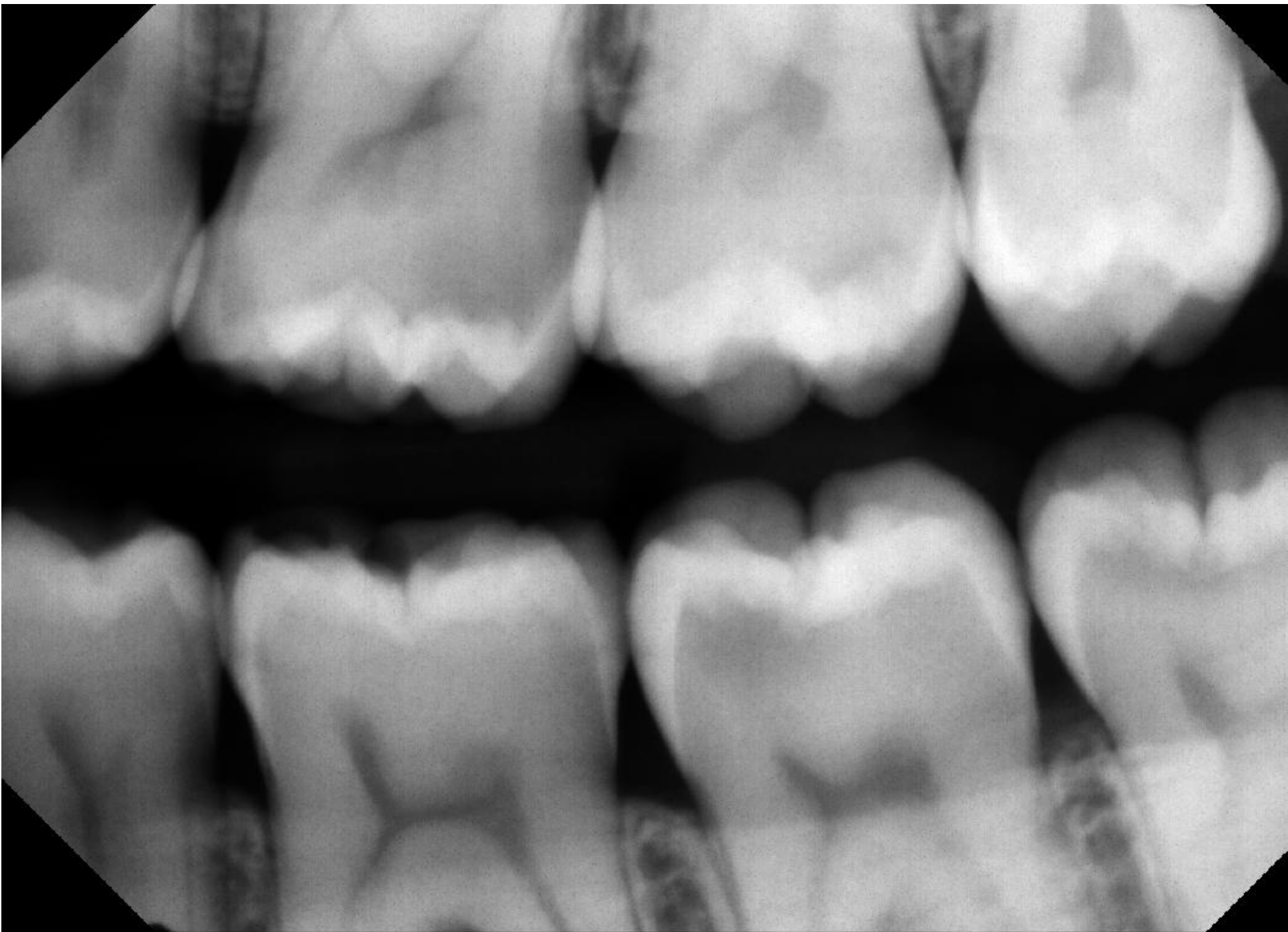

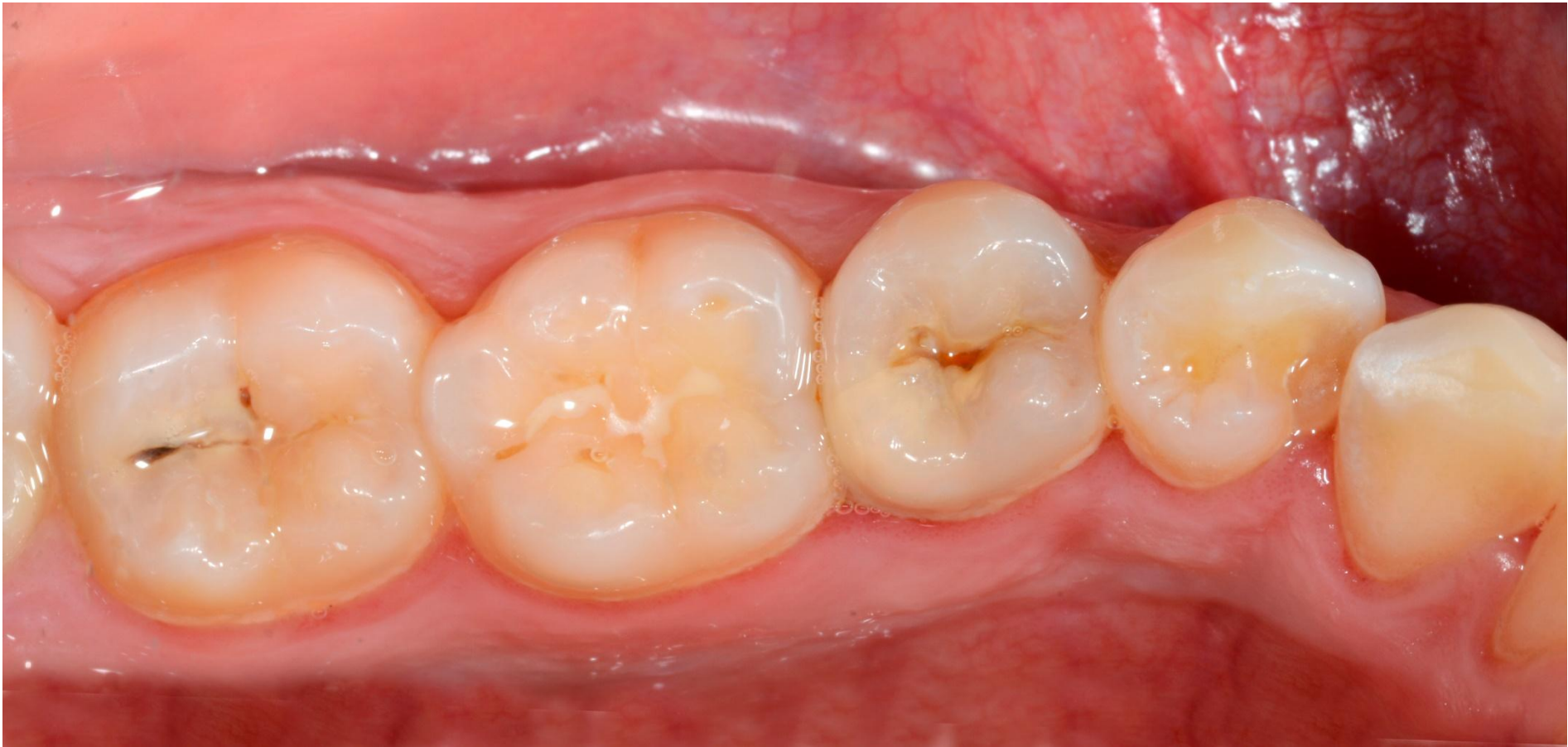Meet Victoria

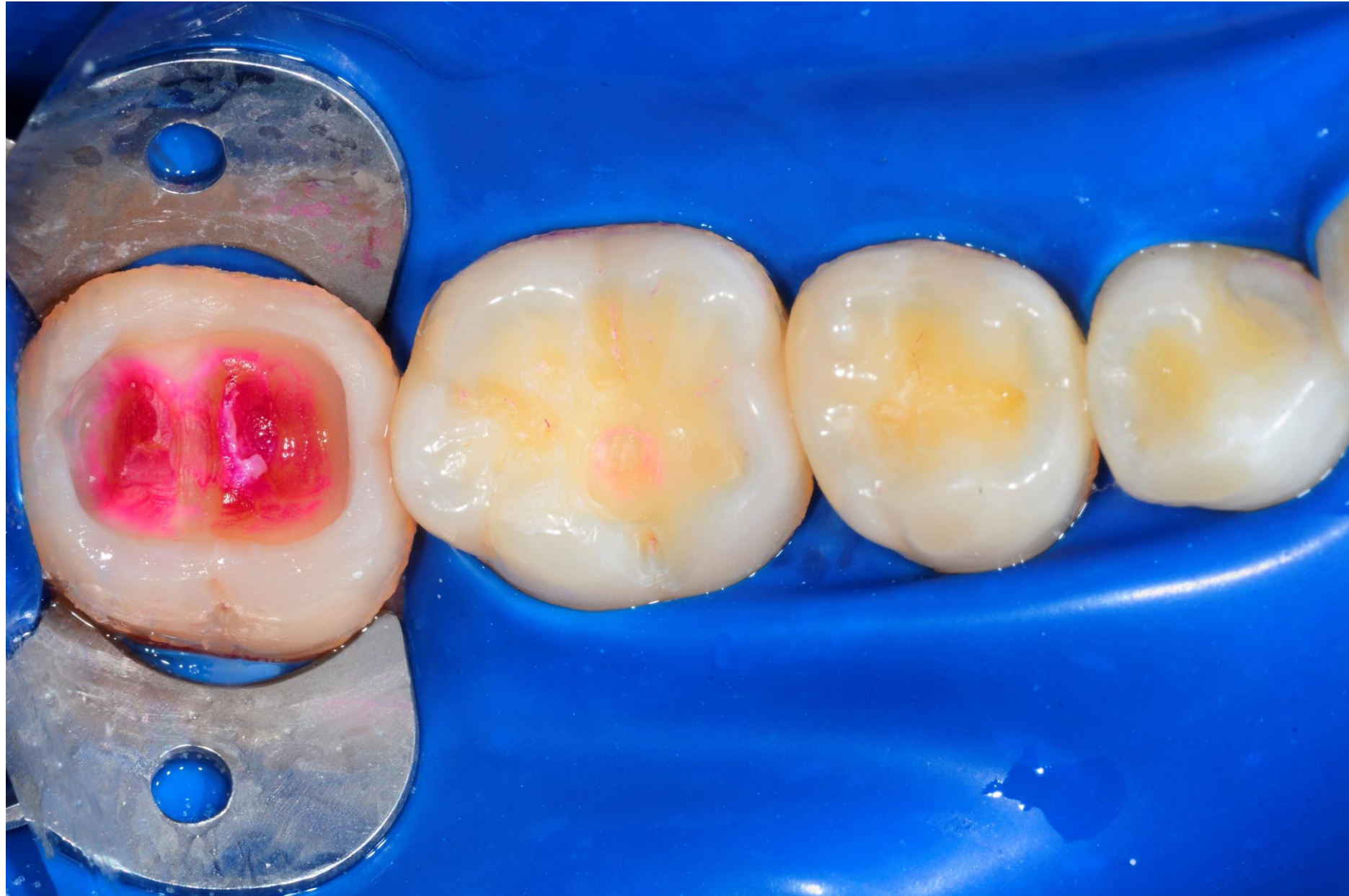- Age 16
- Diagnosis by her Oregon dentist: 16 failed sealants
- Will need approximately 9 root canals and crowns
- All teeth are asymptomatic







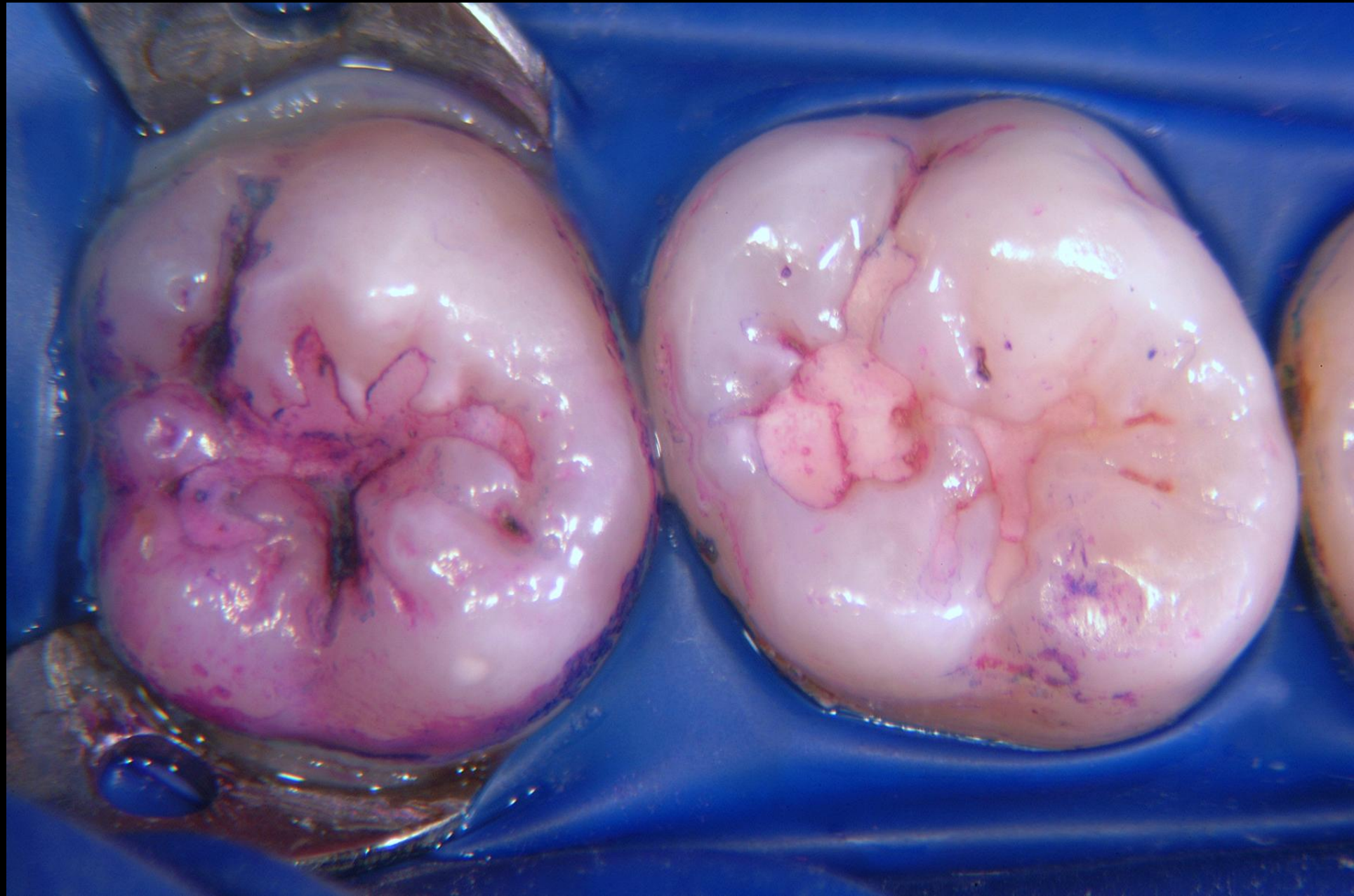




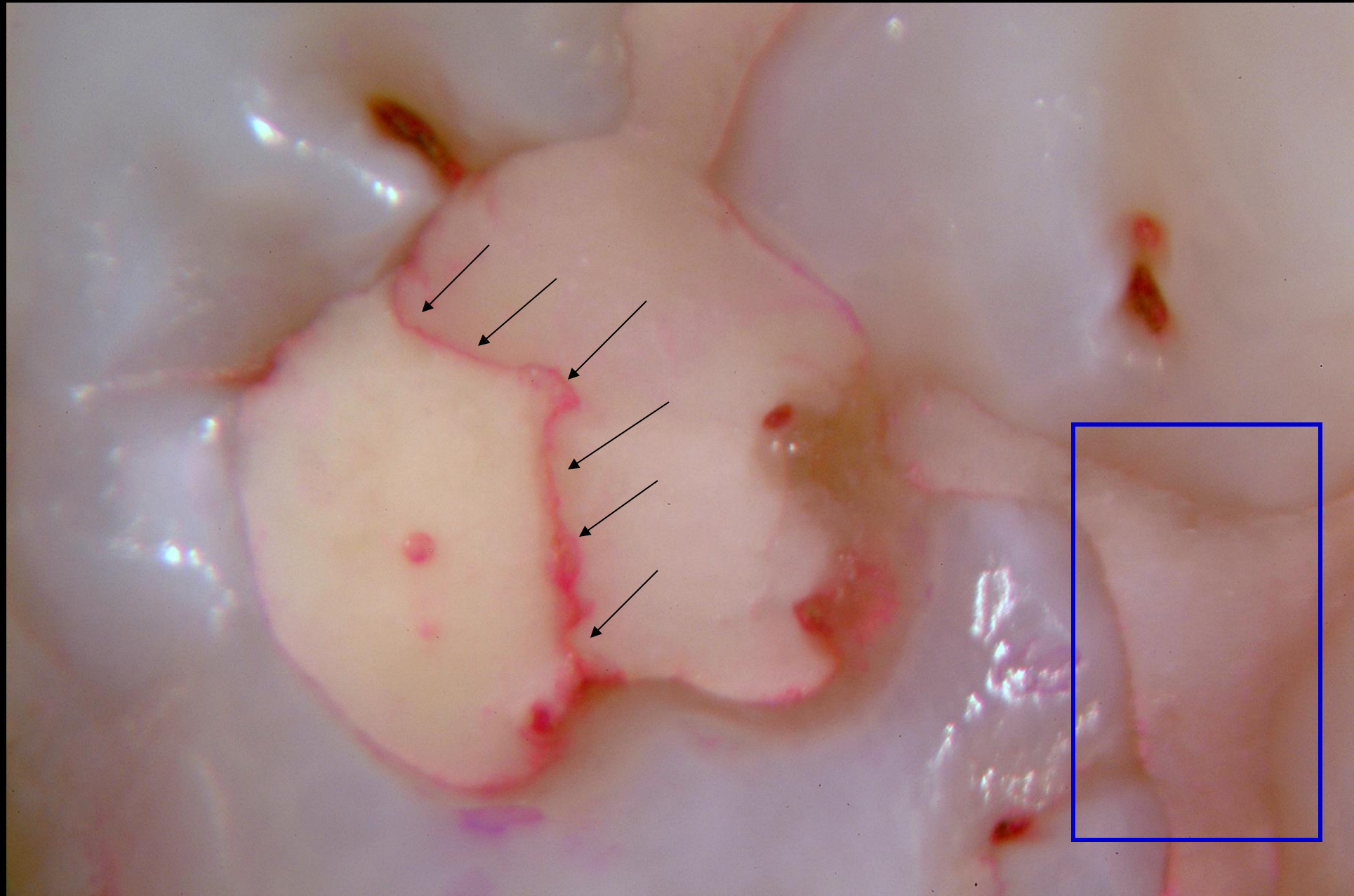
The Nine *Fatal Flaws* of Traditional Sealants

5. Sealing Over Decay
6. Relying on Phosphoric Acid to Clean the Tooth
7. Sealant “Maintenance”
8. Placement of Sealant Material in Prepared (bur, air abrasion, laser)

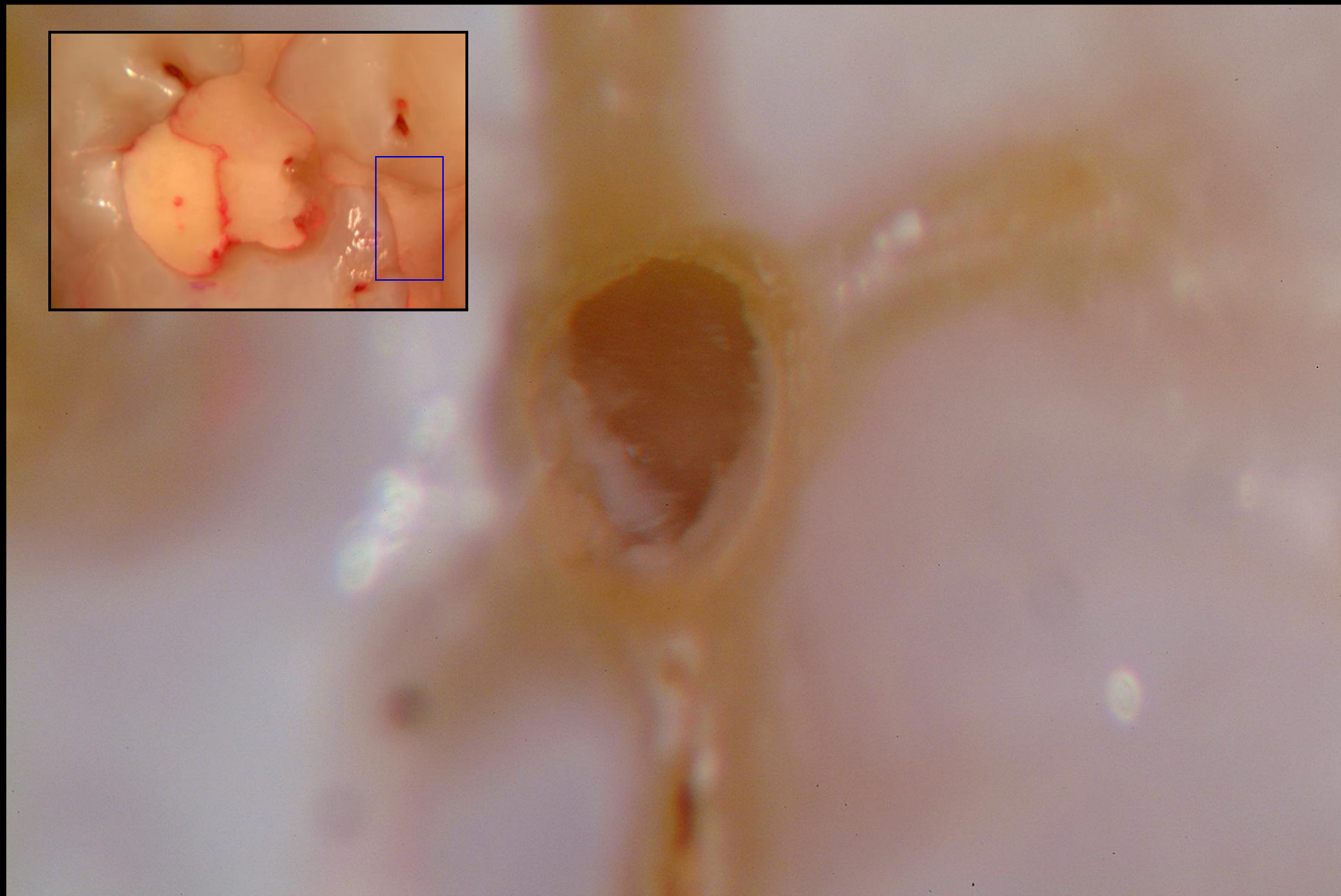
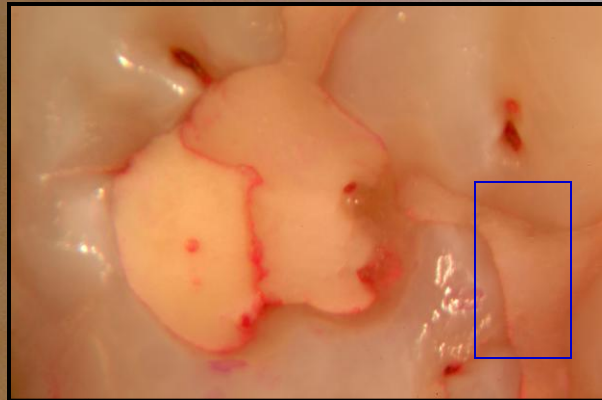
The Nine *Fatal Flaws*



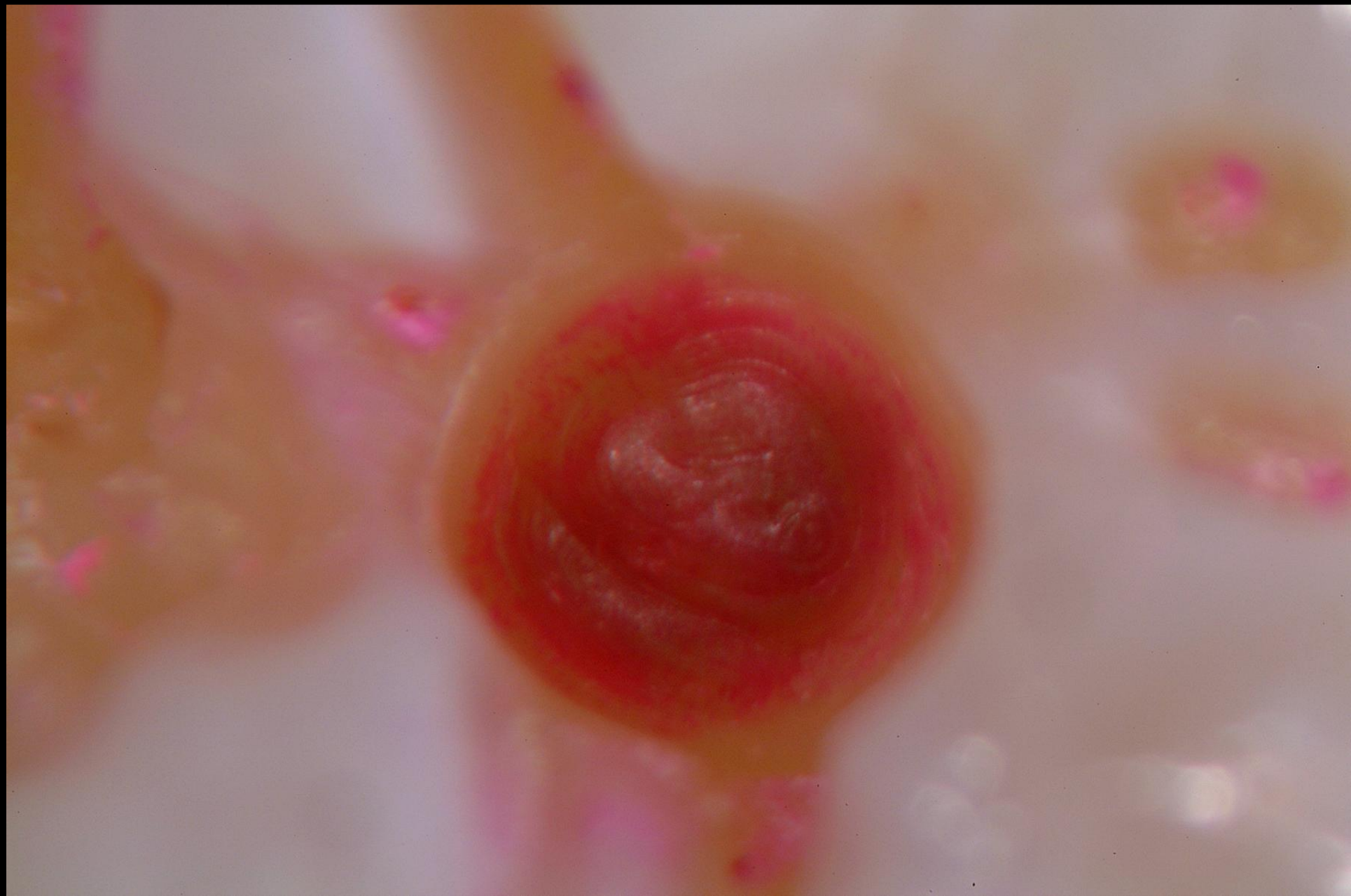
The Nine *Fatal Flaws*



The Nine *Fatal Flaws*

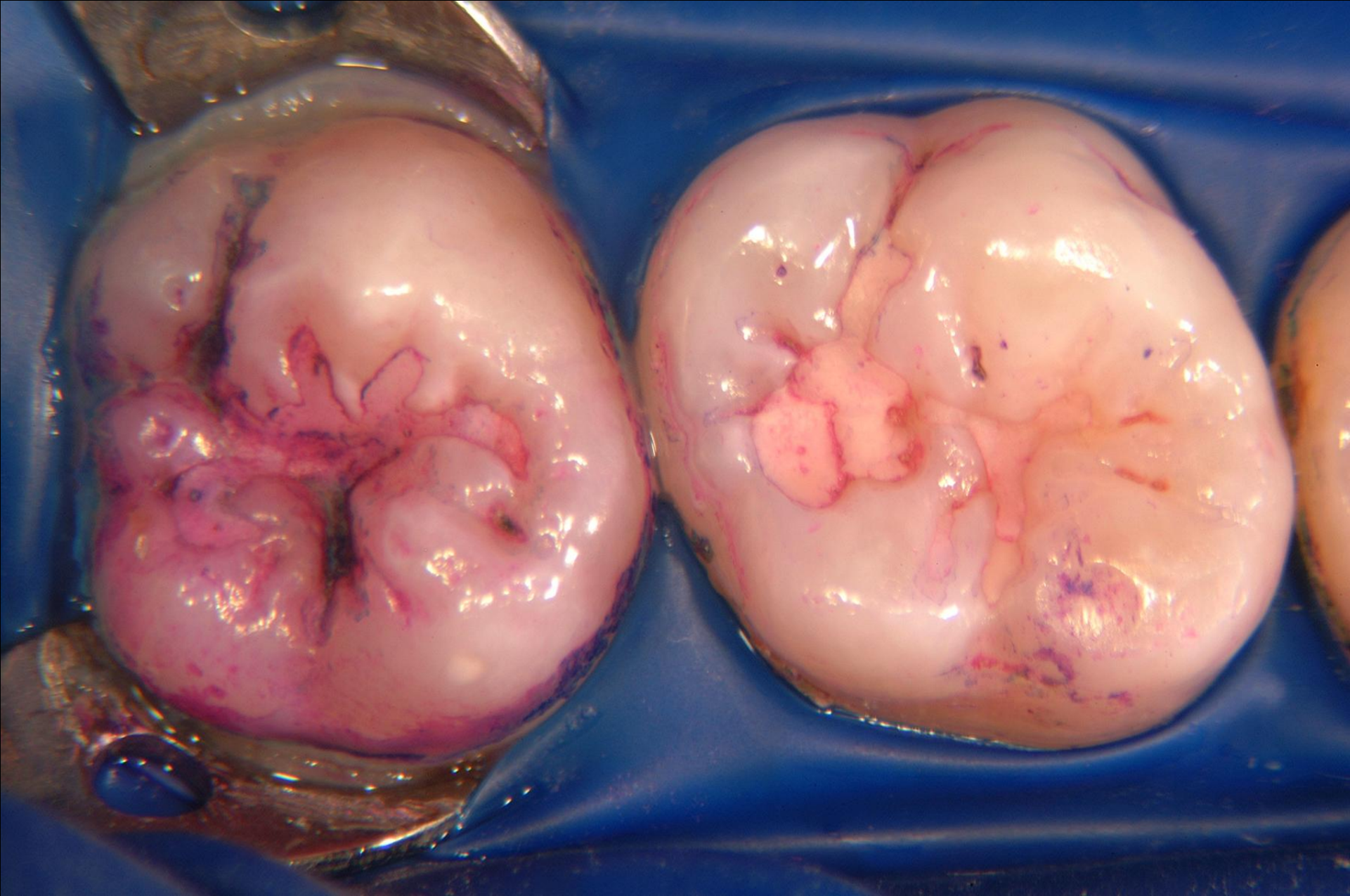


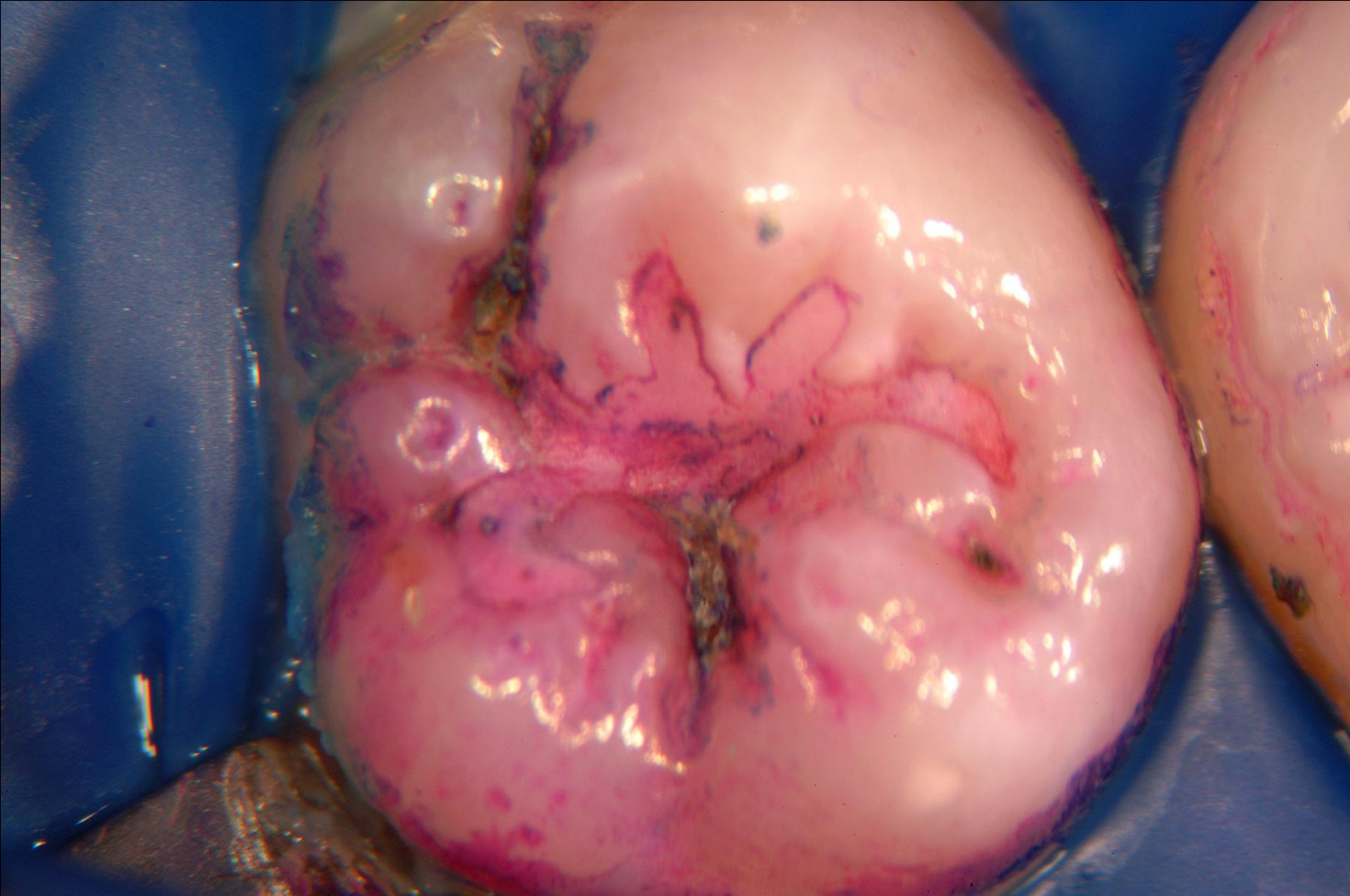
The Nine *Fatal Flaws*



Sealants often don't wear out; they chip out, fall out, and crumble at the margins

Sealants almost always leak.





Paste composite is neither packable nor condensable. Place flowable first!



