



# Treatment of the Dreaded Black Triangle: A Case Report and an Introduction to Injection Molded Composite Dentistry

David J. Clark, DDS

## AUTHOR

**David J. Clark, DDS,** founded the Academy of Microscope Enhanced Dentistry. He lectures worldwide and maintains a private practice in Tacoma, Wash.

*Conflict of Interest Disclosure: Dr. Clark has financial interest in Bioclear Matrix Systems and receives honoraria from 3M.*

Traditional composite placement for aesthetic rehabilitation of open gingival embrasures, or black triangles, has historically been viewed with skepticism by many restorative dentists, orthodontists and periodontists. Many patients are told there is no healthy option. Patients are often told that either nothing should be done or are offered aggressive and physiologically costly procedures such as crowns, veneers or physiologically inappropriate interproximal reduction (IPR) in conjunction with orthodontic treatment (TABLE 1).<sup>1,2</sup> The problem should not be underestimated, as one-third of adults suffer the aesthetic and functional dilemmas associated with black triangles.<sup>3</sup>

The etiologies of black triangles are decreased interproximal bone height from periodontal disease, attachment loss, periodontal surgery or trauma; excessive embrasure space and deficient papilla form affected by root angulation, interradicular distance, crown form and distance between alveolar bone and interproximal contact; a patient's biologic width and inherent or thinning gingival biotype; and age including patient habits, iatrogenic issues and adult orthodontics.

A full-mouth black triangles case originally treated in 2012 (FIGURES 1) is shown at six-year follow-up in FIGURES 2. Note the infinity-edge tooth-restoration

interface (TRI) allows for graceful color blending of the composite to tooth and has also retained its shine and resisted stain. Traditional hand-manipulated composite bonding is typically limited to certain regions of the tooth and then marginated. With this technique, the entire tooth is covered in composite then quickly sculpted and finished with a specific polishing technique. This marginless approach yields stubborn resistance to stain accumulation.

## Case Presentation

The patient presented with a desire to treat the black triangle between teeth Nos. 8 and 9 (FIGURE 3A). After a comprehensive evaluation and photographs (FIGURE 3B), the patient agreed to a more comprehensive approach involving injection overmolding involving the four maxillary incisors and elimination of three black triangles. The patient also wanted to brighten his teeth by using shade B-1. He did not want removal of any healthy tooth structure and accepted the treatment plan to add fullness to the teeth, approximately 1 mm, to mask the dark bands on the central incisors.

The Bioclear Smile Design gauge (Bioclear, Tacoma, Wash.) helped to show the tooth size discrepancy between his central incisors (FIGURES 4). The patient opted to forgo restorative orthodontics to move the midline.

TABLE 1

**Conventional Solutions for Open Gingival Embrasures**

- Orthodontic extrusion to coronally reposition interproximal bone and subsequent enameloplasty or restoration.
- Orthodontic repositioning of divergent roots or widely spaced roots along with enameloplasty to narrow the embrasure space and encourage gingival adaptation.
- Interproximal bone graft.
- Soft tissue graft or papilla reconstruction.
- Subtractive porcelain restorations or composite bonding (white and/or pink).
- Removable prosthesis in severely compromised cases.

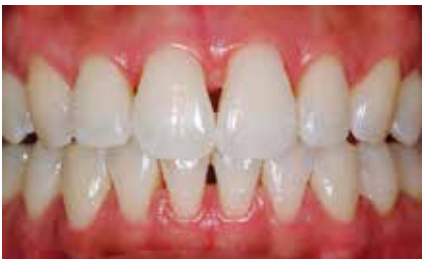

FIGURE 1A.

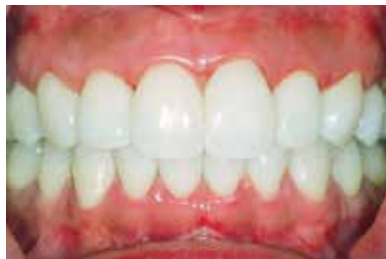

FIGURE 1B.

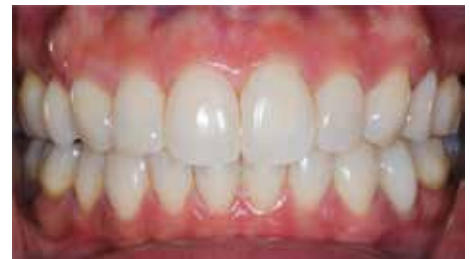

FIGURE 1C.

**FIGURES 1.** Preoperative (A), immediate postoperative (B) and six-year follow-up (C) photographs of a full-mouth black triangle case. The composites used were heated Filtek Supreme Ultra Body Shade (B-1) and a small amount of Filtek Supreme Flowable composite. This flowable comes in the same Body shade, which allows an ideal match between the different viscosity resins.

Injection molding requires attention to the four cornerstones of the method:

- A thorough preparation of the tooth surfaces before acid etching is critical to avoid staining or debonding. Nonsurgical tooth preparation is achieved with an air/water/abrasive slurry of aluminum trihydroxide. This procedure removes the biofilm. Inattention to biofilm removal is a leading cause of stain and debonding. Application of phosphoric acid alone does not properly address biofilm removal. Phosphoric acid selectively removes the mineral component of dentin and enamel. Biofilm is mostly organic and will therefore not be removed with phosphoric acid.
- Matrix selection, contact management and proper seating.
- Injection molding with uncured adhesive as a surfactant, heated flowable composite, followed immediately by heated paste composite. The three resins are then light cured together. The combination of flowable and regular paste composite can be compared

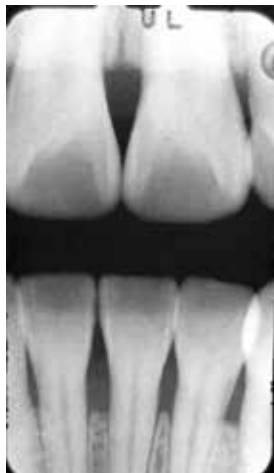

FIGURE 2A.

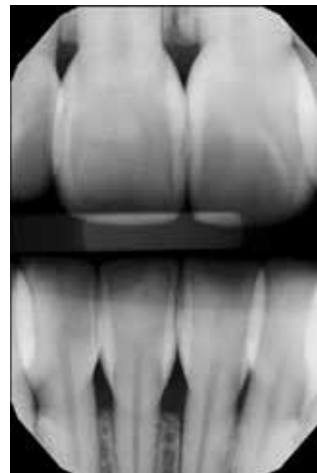

FIGURE 2B.

**FIGURES 2.**

Preoperative (A) and six-year radiographs (B) of the case in Figure 1. After viewing the radiographic integrity and the long-term favorable soft tissue response, most periodontists and orthodontists feel comfortable with this method as a conservative, permanent and healthy option.

to the use of light-body impression material followed by heavy-body impression material. Some clinicians perform the technique with flowable composite alone. However, most paste composites have better shine retention than their flowable counterparts. Therefore, the ideal restoration today should reach a 95% ratio of paste to flowable composite in aesthetic and load-bearing areas.

- The polish. The reader is encouraged to learn the simplified two-step polishing process by watching online videos. A prerequisite for long-term polish retention is dependent on the elimination of voids and bubbles often introduced with hand manipulation of composites. Injection-molded composite has a high degree of integrity without the bubble and voids of traditional bonding.

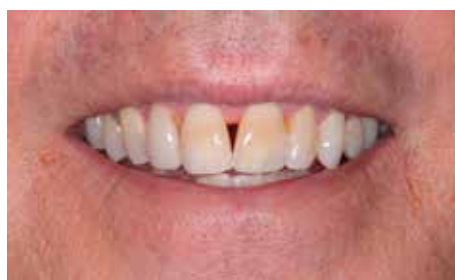

FIGURE 3A.

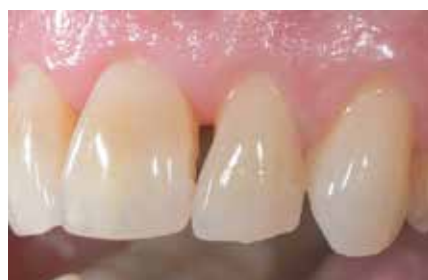

FIGURE 3B.

**FIGURES 3.** Preoperative photographs of the case to be treated in this article. The midline black triangle was likely caused by root position (A). The lateral incisor black triangle is resultant of concave tooth anatomy and a small root (B).

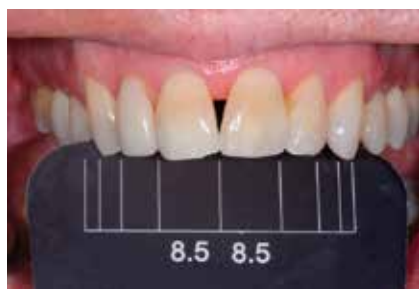

FIGURE 4A.

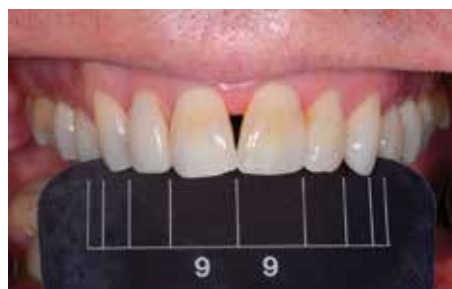

FIGURE 4B.

**FIGURES 4.** The Bioclear Smile design gauge is placed intraorally at a 45° angle and locked behind the maxillary canines or maxillary first bicusps. In this case, the left central incisor is significantly wider.

### Composite Heating

Composite warming is not new. However, it was rarely viewed as a necessary component of composite dentistry before the advent of injection molding and injection overmolding. The injection method utilizes Filtek Supreme Ultra (3M ESPE, St. Paul, Minn.) in the Body shades, plus the color-matched Filtek Supreme Ultra flowable composite. 3M has recently completed an extensive analysis of the safety of heating the above-mentioned composite and 3M's Filtek One Bulk Fill and Bulk Fill Flowable for posterior teeth. Their resins can safely be heated for more than an hour in the appropriate heater without degradation of the resins. Other studies showing the safety of heated composite are in **TABLE 2**.

### Can All Resins Be Heated?

We have observed two resins that should definitely not be heated and others that cannot be heated for very long. Clinicians can either use the 3M material or check with the manufacturer of their resins.

### Case Presentation and Technique Summary

Before the rubber dam is placed, the TruContact sanders (Bioclear) are used to smooth, remove calculus and lighten the tension of the contact areas and allow the matrices to seat fully (**FIGURE 5A**). Once the rubber dam is placed, disclosing solution is applied to highlight biofilm and then blasted with an air/water/abrasive slurry of aluminum trihydroxide (**FIGURE 5B**). Nowhere is this more critical than the interproximal area where access to traditional scaler and prophy cups is difficult.

Next, the black triangle gauge is inserted buccal-lingually below the contact to assess the mesiodistal size of the black triangle (**FIGURES 6**). The gauge will bind at one of the four colors. In this case, the gauge was binding between the yellow and green areas of the gauge. The patient preferred a complete elimination of the black triangle. Therefore, the

green-colored matrices that have more curvature than the yellow-colored matrices were chosen. Next, a pair of size-appropriate correspondingly color-coded Bioclear black triangle embrasure. Although we measure and pair the matrices for each embrasure, the injection molding is performed one tooth at a time to allow for a monolithic, stain-resistant outcome.

Tooth No. 8 is injection molded first. The green matrices are placed at the midline (**FIGURES 7-10**). The other embrasures have smaller black triangles. The pink-colored matrices, which are the least curvaceous of the four colors, are used in the other embrasures. "Shield" matrices (inactive matrices that shield the neighboring teeth) are placed on the neighboring teeth on either side of the tooth and will later be used as active matrices. These shield matrices help maintain the embrasure shape as the active matrix system becomes pressurized during injection molding. The matrixed tooth No. 8 is acid etched, rinsed and dried. Scotchbond Universal adhesive (3M ESPE, St. Paul, Minn.) is placed on enamel, massaged into dentin for 20 seconds, air thinned but not light cured. Then heated Filtek Supreme Ultra Flowable (3M ESPE) is injected into the active matrices followed with heated Filtek Supreme paste.

Injection molding using heated composite with the Bioclear method has similarities to industrial injection molding. In dentistry, the sides (mesial and distal) of the tooth are well-contained all the way to the bottom of the sulcus. In the center of the tooth, there is a gap that allows injection of the composite. This distinct injection zone is often referred to as the umbilical cord or umbilicus of the restoration.

TABLE 2

**Recent Research Validating Heating of Specific Composite Resins**

Benefits of heating	Citation
Heating of the composite does not affect mechanical characteristics of Filtek Supreme Ultra composite including diametral tensile strength, flexural strength, depth of cure and compressive strength.	Agre M, et al. Physical and Esthetic Properties of a Warmed Dental Composite. <i>J Dent Res</i> vol. 98A, abst no. 1670, 2019. <sup>4</sup>
This study concerns leaching of chemicals out of the composite. A comparison was performed to evaluate the relative amount of material extracted from warmed or nonwarmed, light-cured, resin-based composite material in three separate solvents to help determine the potential safety of warming techniques in composite use. There was no statistical difference between the room temperature and warmed samples at most extraction times.	Dunbar T, et al. Gravimetric Extraction of Warmed and Room Temperature Experimental Composite. <i>J Dent Res</i> vol. 98A, abst no. 1877, 2019. <sup>5</sup>
Fracture toughness was increased for Filtek One Bulk Fill when specimens were preheated.	Abdulmajeed A, et al. Fatiguing and Preheating Effect on Mechanical Properties of Composite Resins. <i>J Dent Res</i> vol. 98A, abst no. 1879, 2019. <sup>6</sup>
Heated composite is safe to the pulp. In the study, the extent of the increase in pulpal temperature with heated composite was only 0.8 C. In contrast, a 5 C intrapulpal temperature rise was seen for all groups during photopolymerization.	Daronch M, Rueggeberg FA, Hall G, De Goes MF. Effect of composite temperature on in vitro intrapulpal temperature rise. <i>Dental Mater</i> 2007 Oct;23(10):1283-8. Epub 2007 Jan 2. <sup>7</sup>

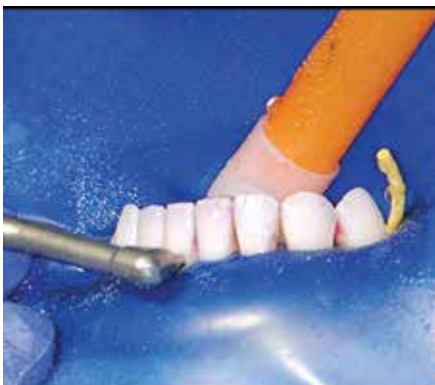

FIGURE 5A.

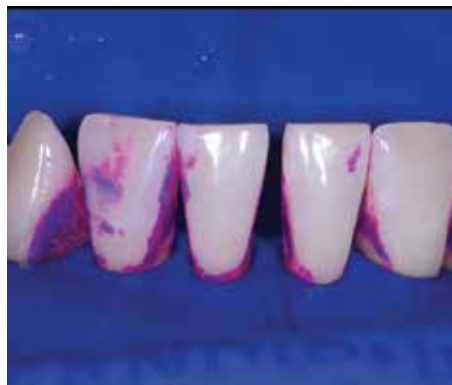

FIGURE 5B.

**FIGURES 5.** The teeth are isolated with a heavy rubber dam (A), dried, then disclosed with the dual-color disclosing solution (B). The contacts are sanded in sequence to lighten the tension of the contacts. This will in turn allow full seating of the matrices. A secondary benefit is to remove hard and soft biofilm, which are common to the peri-contact area.

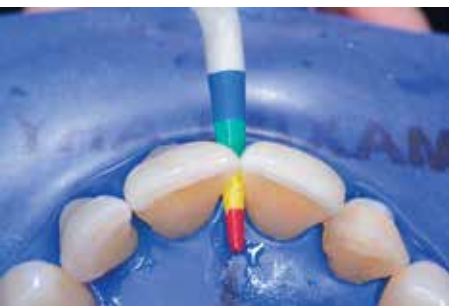

FIGURE 6A.

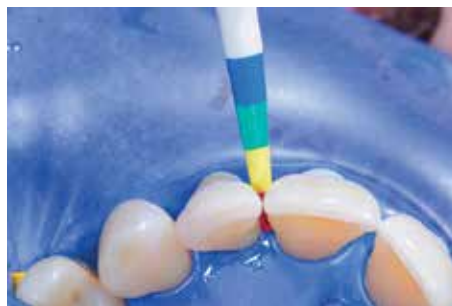
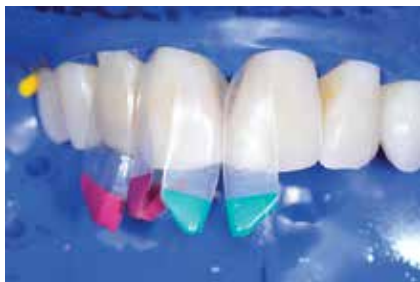

FIGURE 6B.

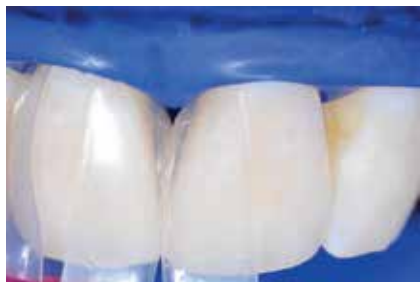**FIGURES 6.** The Bioclear Black Triangle Gauge (patent pending) is shown in two of the three embrasures that will subsequently be treated. Color-coded matrices will subsequently be utilized that match the colored area of the gauge where it binds when viewed from the incisal.

With industrial injection molding, the remnant of the injection zone is referred to as a “vestige.” When casting dental gold restorations, there is a “sprue” that connects the casting to the melted gold mass. It is purposeful excess that sits above the controlled contour that is later cut back and blended to the restoration surface. With dental injection molding, the umbilicus can be prone to voids. Therefore, it should be maintained as 1 mm to 3 mm of excess, light cured and then cut back to the grade of the matrix containment zone. The supragingival excess in the umbilicus is maintained as to not disturb the composite.

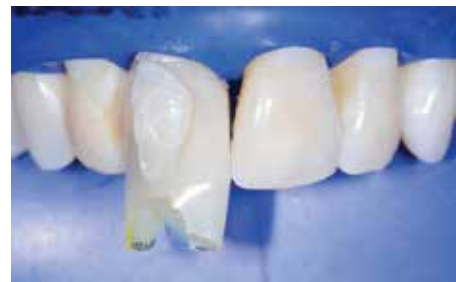The matrices are massaged back to shape with the unique paddle instrument, and any flowable composite in the gingival area is blotted away with dry brushes. Little to no hand manipulation of the composite is the goal with injection molding. Once thoroughly light cured, the shield matrices and the active matrices are removed. The excess areas are quickly removed with a dry coarse flame bur (Komet, Lemgo, Germany). Then the tooth is taken to 80% of the final shape with the 3M Sof-Lex coarse disc (3M ESPE) (FIGURE 10). The process



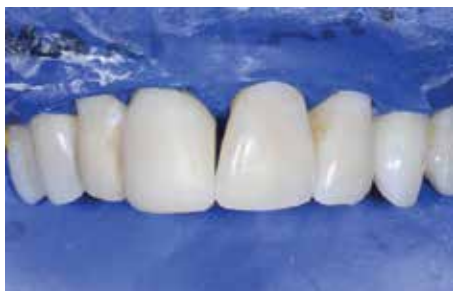**FIGURE 7.** At the midline area, the gauge was between yellow and green. The patient wanted absolute closure of the black triangle, so the green matrices were used. For a slightly open embrasure, the yellow matrices would have been utilized. The other embrasures were restored with the pink matrices. The “large” matrices from the “large” tub were utilized for this case. The “small” matrices are commonly used for lower incisors.



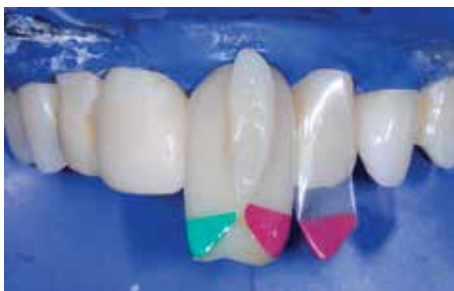**FIGURE 8.** A high-magnification view of the aggressive curvature of the black triangle matrices and tight gingival seal is demonstrated. If the contacts are not appropriately lightened with the sander mentioned previously, the operator may see a gingival gap. This indicates that the matrix is not fully seated, the matrices should be removed, the contact sanded more aggressively and then matrices reinserted.



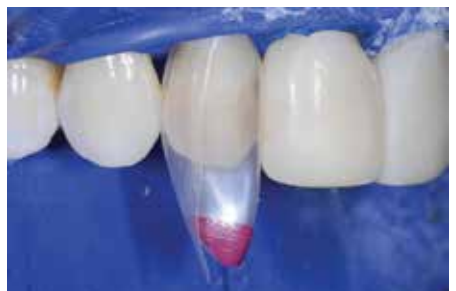**FIGURE 9.** The first tooth has been overmolded and matrices removed. Note the orange color along the incisal edge where the adhesive was transported to.



**FIGURE 10.** The excess or “umbilicus” has been quickly amputated with a dry coarse diamond bur; the tooth is then taken to the 80% completion state with a SoFlex XT Coarse disk (3M) before moving on to the next tooth.



**FIGURE 11.** The left central incisor is overmolded. The “shepherd” matrix on the mesial of the lateral is currently inactive but will later be used as an active or “aquarium” matrix.



**FIGURE 12.** The mesial is treated with the pink matrix and the distal is treated with the Bioclear A-102 matrix from the original Bioclear System in the HD thickness. Because the contacts were all naturally occurring in this case, the slightly thicker HD matrices can be used. The HD version of Bioclear Mylar at 75 microns is significantly stronger and stiffer than the 50-micron version. Each thickness version is used depending on the clinical situation.

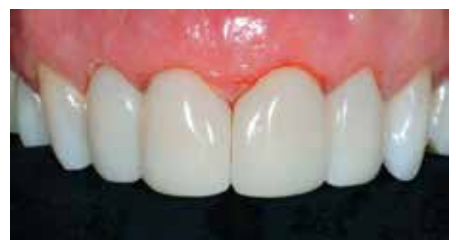is repeated one tooth at a time (**FIGURES 11 and 12**). The single porcelain veneer on tooth No. 7 was removed and replaced with the same basic injection overmolding process used on the other teeth. Because the original porcelain veneer was very conservative, no dentin was exposed. Another aid was the fact that the contacts were still present in enamel, which is very helpful to the clinician as the matrices are stabilized nicely.

### *The Final Step: The Polish*

First, the pre-polish is completed with a worn SoFlex XT disc (3M ESPE) to create a matte finish and to remove any deep scratches left by the diamond bur. Next comes the two-step polish. Magic Mix (Bioclear)

is used in a disposable cup to create omnidirectional super-fine scratches. Next, the Magic Mix is completely removed with air-water spray. Finally, a diamond impregnated cup (RSP Polisher, Bioclear) is used with light pressure. Care should be taken with any polisher used without water spray coolant, as it can create heat. Then the same diamond impregnated cup is used with copious air-water spray and heavy pressure to achieve the ultra-glossy appearance. This process sets the injection molded restoration apart from the often-grainy finish of “bonding.”

The immediate postoperative photograph (**FIGURE 13**) demonstrates immediate and complete black triangle closures. The matrices are specifically



**FIGURE 13.** Immediate postoperative view. Note the ultra-glossy finish imparted by the polish. Monolithic injection molded composite holds real promise as the structural and optical integrity of the composite, Filtek Supreme Ultra, is maximized.

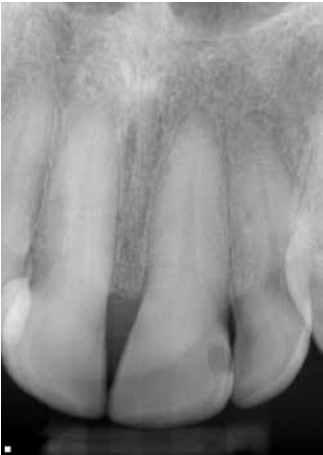

FIGURE 14A.

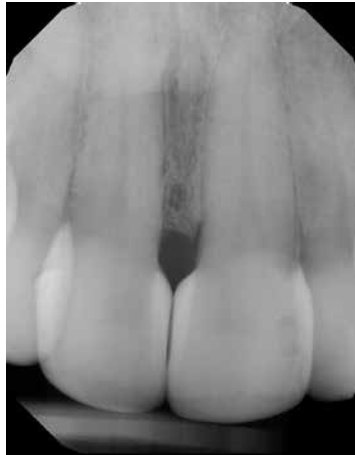

FIGURE 14B.

**FIGURES 14.** Preoperative (A) and immediate postoperative (B) radiographs are shown. Note the smooth transition of the tooth-restoration interface (TRI) and the aggressive change in emergence profile. One of the key elements of the method is the change in emergence profile begins subgingivally. That subgingival adaptation and aggressive emergence profile was difficult to achieve before the advent of a dedicated black triangle matrix.



FIGURE 15A.




FIGURE 15B.

**FIGURES 15.** Preoperative (A) and immediate postoperative full-face photographs (B).

designed to put the apical extent of the contact area within 5 mm of the bone level. This distance is the Tarnow guideline: The maximum distance from crestal bone to contact area to achieve a papilla in 100% of cases is 5 mm.

Pre- and postoperative radiographs (**FIGURES 14**) demonstrate evidence of the smoothness and healthy contours of a large black triangle closure of the central incisor embrasure.

Aesthetic transformation is not a new concept in restorative dentistry (**FIGURES 15**). However, injection overmold with heated multiviscosity resins in precise matrices with an exquisite gingival seal and without cutting the tooth to accommodate indirect ceramics is new. The reader can contact 3M Oral Care or Bioclearmatrix.com for more information. ■

#### REFERENCES

1. Kim J, Clark DJ. Full-mouth black triangle treatment protocol. *Dent Today* 2017 Aug;36:72-77.
2. Kim, J. Restorative orthodontics with injection molding: Intra-arch and inter-arch case solutions. *Dent Today* 2019 Jan;62-65.
3. Kurth J, Kokich V. Open gingival embrasures after orthodontic treatment in adults: Prevalence and etiology. *Am J Orthod Dentofacial Orthop* 2001 Aug;120(2):116-123.
4. Agre M, et al. Physical and Esthetic Properties of a Warmed Dental Composite. *J Dent Res* 2019 vol 98A, abstract 1670.
5. Dunbar T, et al. Gravimetric Extraction of Warmed and Room Temperature Experimental Composite. *J Dent Res* 2019 vol 98A, abstract 1877.
6. Abdulmajeed A, et al. Fatiguing and Preheating Effect on Mechanical Properties of Composite Resins. *J Dent Res* 2019 vol 98A, abstract 1879.
7. Daronch M, et al. Effect of composite temperature on in vitro intrapulpal temperature rise. *Dent Mater* 2007 Oct;23(10):1283-8. Epub 2007 Jan 2. doi.org/10.1016/j.dental.2006.11.024.

**THE AUTHOR,** David J. Clark, DDS, can be reached at drclark@bioclearmatrix.com.